Acta

candinavica

TOR: KNUD JANSEN, Copenhagen, Denmark

NKSGAARD, Copenhagen

Vol. 50, No. 1, February 1979

ACTA ORTHOPAEDICA SCANDINAVICA

INDEX

Vol 50, Fasc 1, February 1979

Langenskiold A Michelsson J E & Videman T Osteoarthritis of the knee in the rabbit produced by immobilization. Attempts to achieve a reproducible model for studies on pathogenesis and therapy 1

Havdrup T Trypsin induced mitosis in the articular cartilage of adult rabbits 15

Oikarinen J & Korhonen L. K. Repair of bone defects by bone inductive material 21

Suzuki K Takahashi S Ito K Tanaka Y & Sezai Y Tumoral calcinosis in [illegible] 27

[illegible] 33

Hansen Leth C Bone vascularization and bone healing in the amputation stump. An experimental study 39

Holstein P Sager P & Lassen N A Wound healing in below-knee amputations in relation to skin perfusion pressure 49

Holstein P Dovey H & Lassen N A Wound healing in above-knee amputations in relation to skin perfusion pressure 59

Boe S The neurovascular island pedicle flap 65

Slot [illegible] 73

[illegible] 79

[illegible] 85

[illegible] 89

[illegible] tibiae 93

[illegible] 97

[illegible] 103

[illegible] 107

[illegible] 123

[illegible] 127

[illegible] 128

should indicate the subjects of the investigation. The abstract should comprise a brief and factual summary of the contents and conclusions of the paper, a pointer to any new information which it may contain, and an indication of its relevance

It should be presumed that the reader has some knowledge of the subject but has not read the paper The abstract should therefore be intelligible in itself without reference to the paper It should only in exceptional cases exceed 200 words.

Key words 4–9 key words for indexing should be given by the author(s) together with the abstract They should be placed in alphabetical order and be in accordance with the Annual Bibliography of Orthopaedic Surgery (*J Bone Jt Surg* Boston, Mass., U S A.)

Introduction This should be a brief outline of the nature of the problem with particular emphasis on the state of knowledge at the start of the investigation, followed by a short description of the investigation itself

Patients and Methods/Materials and Methods For clinical work dealing with patients the first heading will be preferred. The second is used in articles dealing with laboratory work or animal experiments.

Results This part of the paper provides a description of the results obtained (but neither a discussion nor a review of the literature) Double documentation in text and tables should be avoided

Discussion The author is recommended to discuss, and not just recapitulate, the results, giving particular emphasis to unsettled and controversial points and [illegible]ating to some conclusion

Acknowledgements If applicable

References References should be mentioned in the text by name of author(s) and year of publication. Citations in the text should appear as Smith & Jones (1960) or (Smith & Jones 1960) When there are three or more authors, cite their paper as Doye et al (1960) All authors cited, and only these, must be listed at the end of the paper in alphabetical order according to the name of the first author

Examples

Lazcano, M A., Anzel, S H & Kelly, P J (1961) Complete dislocation and subluxation of the acromioclavicular joint *J Bone Jt Surg* 43-A, 379–391

Watson-Jones, R (1955) *Fractures and joint injuries* Vol. 2, 4th ed. pp 464–468 E and S Livingstone Ltd., Edinburgh.

Illustrations All illustrations are to be considered as [illegible] journal, the authors' names, and the figure number

Lettering should be stencilled in black India [illegible] enough for the necessary reduction *Line* [illegible] column width. Lettering on the figures should be [illegible] mm high. Helvetica Leight, 14°, obtainable as [illegible] letters, is recommended Graphs may be p[illegible] white or blue squared paper, grid lines [illegible] in the engraving should be inked in black.

[illegible] number, authors names and, if desi[illegible] magnification of the print Never use paper c[illegible] glossy print or write so firmly on the [illegible] damaged. Send photographs flat and protect [illegible] *stout cardboard backing*

Colour illustrations are expensive and [illegible] considered only when it is important to [illegible] particular feature that cannot be made clear [illegible] techniques. Original transparencies (not [illegible] 35 mm) as well as three sets of colour prints [illegible] submitted

Tables Tables should be used only when [illegible] clarify important points. They should [illegible] secutively in arabic numerals. Each table should [illegible] on a separate sheet. So far as possible [illegible] description should be included in the tit[illegible] self-explanatory

Abbreviations and Symbols Only abbreviati[illegible] symbols that have been generally accepted [illegible] used Unfamiliar abbreviations must be [illegible] first used

Proofs First proofs will be sent to the [illegible] should be returned with the least possible delay [illegible] will be required to pay for any major alterati[illegible] original manuscript.

Reprints Fifty reprints, without covers, of [illegible] will be supplied to the authors free of charge [illegible] reprints can be supplied if ordered on the [illegible] form which will accompany the proofs.

Supplements An article, or a series of [illegible] exceeding a total of 16 printed pages may [illegible] for publication as a supplement This applies [illegible] which have received national or international [illegible] recognition (e g doctoral thesis award). The [illegible] is dependent on the editor's approval. [illegible] the supplements are not subject to editorial [illegible] The full cost is paid by the author(s). [illegible] requested as soon as possible to contact [illegible] who will provide the necessary information [illegible] number of copies to be printed text on cover [illegible] page, size etc

ACTA ORTHOPAEDICA SCANDINAVICA

INDEX

Vol 50, Fasc. 2, April 1979

Koskinen E I S P Salenius & A. Alho Allogeneic transplantation in low grade malignant bone tumours. A new operative technique to avoid amputation 129

Nets P K. Eriksson & L. Stromberg Non-linear properties of diaphyseal bone An experimental study on dogs [illegible]

Sudmann E Treatment of chronic osteomyelitis by free grafts of cancellous autologous bone tissue A preliminary report 14[illegible]

Singh S & R Padmanabhan. Effect of chlorpromazine on skeletogenesis The result of maternal administration of the drug in experimental rats 15[illegible]

Jensen J Steen & E Tondevold Mortality after hip fractures [illegible]

Rønningen H & N Langeland Indomethacin treatment in osteoarthritis of the hip joint. Does the treatment interfere with the natural course of the disease? 1[illegible]

Uden A Thromboembolic complications following serious surgery in Scandinavia 1[illegible]

Gersh [illegible] 1[illegible]

Car [illegible] 1[illegible]

Edsberg B E Rubinstein & J Reimers Containment of the femoral head in Legg-Calvé-Perthes disease and its prognostic significance 191

Colville J & P Raunio Total hip replacement in juvenile rheumatoid arthritis. An [illegible] 197

Goldie I F [illegible] prosthesis [illegible] 20[illegible]

Pankovich A [illegible] injuries o[illegible] studies 217

Pankovich A M & M S Shivaram. Anatomical basis of variability in injuries of the medial malleolus and the deltoid ligament. II Clinical studies 225

Svend Hansen H I Bremerskov & P Ostri. Fracture-suspending effect of the patellar-tendon-bearing cast 237

should indicate the subjects of the investigation The abstract should comprise a brief and factual summary of the contents and conclusions of the paper, a pointer to any new information which it may contain and an indication of its relevance

It should be presumed that the reader has some knowledge of the subject but has not read the paper The abstract should therefore be intelligible in itself without reference to the paper It should only in exceptional cases exceed 200 words.

Key words 4–9 key words for indexing should be given by the author(s) together with the abstract They should be placed in alphabetical order and be in accordance with the Annual Bibliography of Orthopaedic Surgery (*J Bone Jt Surg* Boston, Mass., U S A)

Introduction This should be a brief outline of the nature of the problem with particular emphasis on the state of knowledge at the start of the investigation, followed by a short description of the investigation itself and an outline of the reasons for publication.

Patients and Methods/Materials and Methods For clinical work dealing with patients the first heading will be preferred The second is used in articles dealing with laboratory work or animal experiments

Results This part of the paper provides a description of the results obtained (but neither a discussion nor a review of the literature) Double documentation in text and tables should be avoided

Discussion The author is recommended to discuss, and not just recapitulate, the results giving particular emphasis to unsettled and controversial points and pointing to some conclusion No new findings should appear in this section

Conclusion In most articles a brief section summarizing the conclusions of the work is appropriate

Acknowledgements If applicable

References References should be mentioned in the text by name of author(s) and year of publication Citations in the text should appear as Smith & Jones (1960) or (Smith & Jones 1960) When there are three or more authors cite their paper as Doye et al (1960) All authors cited and only these, must be listed at the end of the paper in alphabetical order according to the name of the first author

Examples

Lazcano M A, Anzel, S H & Kelly, F J (1961) Complete dislocation and subluxation of the acromioclavicular joint *J Bone Jt Surg* 43-A, 379–391

Watson-Jones R (1955) *Fractures and joint injuries* Vol 2, 4th ed pp 464–468 E and S Livingstone Ltd, Edinburgh

Illustrations All illustrations are to be considered as figures and each graph, drawing or photograph must be numbered in sequence with arabic numerals. The approximate location in the text should be indicated by a circled marginal note Legends to illustrations should be listed on a separate sheet, identified with the name of the journal, the authors' names, and the figure number Lettering should be stencilled in black India ink large enough for the necessary reduction *Line drawings* should be drawn with black India ink on white paper order for line drawings to be reasonably consistent within the journal, they should be double their intended finished size and [illegible]

[illegible] Height, 14, obtainable as transfer letters, is recommended. Graphs may be plotted on plain white or blue squared paper, grid lines that are to show in the engraving should be inked in black

Photographs must be submitted as unmounted glossy enlargements showing good detail and contrast Indicate 'up' and 'down' Mark each photograph with figure number, authors' names and if desirable the magnification of the print Never use paper clips on glossy print or write so firmly on the back that the face is damaged Send photographs flat and protect them with stout cardboard backing

Colour illustrations are expensive and will be considered only when it is important to illustrate a particular feature that cannot be made clear by other techniques. Original transparencies (not smaller than 35 mm) as well as three sets of colour prints should be submitted

Tables Tables should be used only when necessary to clarify important points and elaborate tables should be avoided They should be numbered consecutively in arabic numerals. Each table should be typed on a separate sheet So far as possible sufficient description should be included in the titles to make tables self explanatory

Abbreviations and Symbols Only abbreviations and symbols that have been generally accepted should be used Unfamiliar abbreviations must be defined when first used

Proofs First proofs will be sent to the author They should be returned with the least possible delay Authors will be required to pay for any major alterations to the original manuscript

[illegible] each article form which will accompany the proofs

Supplements An article, or a series of articles [illegible] may be accepted [illegible] requested as soon as possible to contact the publisher who will provide the necessary information concerning number of copies to be printed, text on cover and title page, size etc.

Editor

ACTA ORTHOPAEDICA SCANDINAVICA

INDEX

Vol 50, Fasc 3, June 1979

Hulth A & O Johnell Parathyroid hormone secretion after operative bone trauma 241

Engesaeter, L. B & A G Skar Effects of cloxacillin doxycycline fusidic acid and lincomycin on the mechanical properties of bone and skin in young rats 245

Hjelmstedt A & S Ljunghall A case of Albright s syndrome treated with calcitonin 251

Thorngren K G & C O Werner Normal grip strength 255

Ljunggren A E Clavicular function 261

Sadr B & M Swann Spontaneous dislocation of the sterno-clavicular joint 269

Sahlstrand T, B Petruson & R Örtengren Vestibulospinal reflex activity in patients with adolescent idiopathic scoliosis. Postural effects during caloric labyrinthine stimulation recorded by stabilometry 275

Petersén I, T Sahlstrand & U Selldén Electroencephalographic investigation of patients with adolescent idiopathic scoliosis 283

Willner S Moiré topography for the diagnosis and documentation of scoliosis 295

Shneerson J M & R Madgwick. The effect of physical training on exercise ability in adolescent idiopathic scoliosis 303

McCullough C J & J Kenwright The prognosis in congenital lower limb hypertrophy 307

Almby B A Hjelmstedt & T Lonnerholm Neonatal hip instability Reason for failure of early abduction treatment 315

Oretorp N J Gillquist & S O Liljedahl Long term results of surgery for non acute anteromedial rotatory instability of the knee 329

Hedeboe J & A Johannsen Recurrent instability of the ankle joint. Surgical repair by the Watson Jones method 337

Proceedings of the Norwegian Orthopaedic Association 341

Proceedings of the Scandinavian Orthopaed c Association 345

Announcement 368

should indicate the subjects of the investigation The abstract should comprise a brief and factual summary of the contents and conclusions of the paper, a pointer to any new *information which* it may contain, and an indication of its relevance

It should be presumed that the reader has some knowledge of the subject but has not read the paper The abstract should therefore be intelligible in itself without reference to the paper It should only in exceptional cases exceed 200 words.

Key words 4–9 key words for indexing should be given by the author(s) together with the abstract They should be placed in alphabetical order and be in accordance with the Annual Bibliography of Orthopaedic Surgery (*J Bone Jt Surg* Boston, Mass., U S A)

Introduction. This should be a brief outline of the nature of the problem with particular emphasis on the state of knowledge at the start of the investigation, followed by a short description of the investigation itself and an outline of the reasons for publication

Patients and Methods/Materials and Methods For clinical work dealing with patients the first heading will be preferred The second is used in articles dealing with laboratory work or animal experiments.

Results This part of the paper provides a description of the results obtained (but neither a discussion nor a review of the literature) Double documentation in text and tables should be avoided

Discussion The author is recommended to discuss and not just recapitulate, the results, giving particular emphasis to unsettled and controversial points and [illegible] to some conclusion No new findings should [illegible] in this section

Conclusion. In most articles a brief section summarizing the conclusions of the work is appropriate

Acknowledgements If applicable

[illegible]

& Jones 1960) When there are three or more authors, cite their paper as Doye et al (1960) All authors cited, and only these, must be listed at the end of the paper in alphabetical order according to the name of the first author

Examples

Lazcano, M A, Anzel, S H & Kelly P J (1961) Complete dislocation and subluxation of the acromioclavicular joint *J Bone Jt Surg* 43-A, 379–391

Watson Jones, R (1955) *Fractures and joint injuries* Vol 2, 4th ed. pp 464–468 E and S Lavingstone Ltd, Edinburgh.

Illustrations All illustrations are to be considered as figures, and each graph, drawing or photograph must be numbered in sequence with arabic numerals. The approximate location in the text should be indicated by a circled marginal note Legends to illustrations should be listed on a separate sheet identified with the name o journal, the authors' names, and the figure nun Lettering should be stencilled in black India ink, enough for the necessary reduction. *Line draw* should be drawn with black India ink on white pape order for line drawings to be reasonably consi within the journal, they should be double their inte finished size and as such their width should be one of three following standard sizes 135 mm for single col width, 200 mm for 1½ column width, 280 mm for do column width. Lettering on the figures should be 3 8 mm high. Helvetica Leight, 14°, obtainable as tran letters, is recommended Graphs may be plotted on p white or blue squared paper, grid lines that are to sl in the engraving should be inked in black.

Photographs must be submitted as unmounted gl enlargements showing good detail and contrast Indic 'up' and 'down' Mark each photograph with fig number, authors' names, and, if desirable magnification of the print Never use paper clips o glossy print or write so firmly on the back that the fac *damaged Send photographs flat* and protect them w stout cardboard backing

Colour illustrations are expensive and will considered only when it is important to *illustrate* particular feature that cannot be made clear by ot techniques. Original transparencies (not smaller th 35 mm) as well as three sets of colour prints should submitted

Tables Tables should be used only when necessary clarify important points and elaborate tables should avoided They should be numbered consecutively arabic numerals. Each table should be typed on separate sheet So far as possible *sufficient* descripto should be included in the titles to make tables se explanatory

Abbreviations and Symbols Only abbreviations an symbols that have been generally accepted should b used Unfamiliar abbreviations must be defined whe first used

Proofs First proofs will be sent to the author The should be returned with the least possible delay Author will be required to pay for any major alterations to the original manuscript

Offprints Fifty offprints, without covers, of each article will be supplied to the authors *free of* charge Additional offprints can be supplied *if ordered on* the offprint order form which will accompany the proofs.

Supplements An article or a series of articles exceeding a total of 16 printed pages may be accepted for publication as a supplement This applies to papers which have received national or international academic [illegible] awards The acceptance [illegible] eptance [illegible] evision [illegible] ors are requested as soon as possible to contact the publisher who will provide the necessary information concerning number of copies to be printed text on cover and tit page, size etc.

Edit

ACTA ORTHOPAEDICA SCANDINAVICA

INDEX

Vol 50, Fasc 4, August 1979

Paavolainen, P, P Slätis, E Karaharju & T Holmström The healing of experimental fractures by compression osteosynthesis. I Torsional strength 369

Paavolainen P, R Penttinen, P Slätis & E Karaharju The healing of experimental fractures by compression osteosynthesis II Morphometric and chemical analysis 375

Tauber, C, I Farine, H Horoszowski & S Gassner Fracture healing in rabbits after osteotomy using the CO_2 laser 385

Sekiguchi, T & T Hirayama Assessment of fracture healing by vibration 391

Hansen Leth C The vascularization in the amputation stumps of rabbits. A microangiographic study 399

[illegible] 407

[illegible] 411

Paakkala, H Patiälä, & P Rokkanen Posterior fusion of the lumbosacral spine Evaluation of the operative results and the factors influencing them 415

Tunturi, T, P Niemelä, J Laurinkari, H Patiälä & P Rokkanen Cost-benefit analysis of posterior fusion of the lumbosacral spine 427

Vazeery, A K & O Lunde Controlled hypotension in hip joint surgery An assessment of surgical haemorrhage during sodium nitroprusside infusion 433

Frandsen, P A Osteosynthesis of displaced fractures of the femoral neck A comparison between Smith Petersen osteosynthesis and sliding nail plate osteosynthesis — a radiological study 443

Zetterberg, C, L. Irstam & G B J Andersson. Subcapital fractures of the femur Re-operations with internal fixation 451

Olsson, S S, A Jernberger & D Tryggö Total hip replacement by the Muller-Charnley prosthesis. A follow up study of 238 operations after 2 to 7 years 457

Videman, T, I Eronen C Friman & A Langenskiold Glycosaminoglycan metabolism of the medial meniscus, the medial collateral ligament and the hip joint capsule in experimental osteoarthrosis caused by immobilization of the rabbit knee 465

Bojsen Møller, F & L Lamoreux Significance of free dorsiflexion of the toes in walking 471

Announcement 480

should indicate the subjects of the investigation. The abstract should comprise a brief and factual summary of the contents and conclusions of the paper, a pointer to any new information which it may contain, and an indication of its relevance

It should be presumed that the reader has some knowledge of the subject but has not read the paper The abstract should therefore be intelligible in itself without reference to the paper It should only in exceptional cases exceed 200 words.

Key words 4–9 key words for indexing should be given by the author(s) together with the abstract They should be placed in alphabetical order and be in accordance with the Annual Bibliography of Orthopaedic Surgery (*J Bone Jt Surg* Boston, Mass, U S A)

Introduction. This should be a brief outline of the nature of the problem with particular emphasis on the state of knowledge at the start of the investigation, followed by a short description of the investigation itself and an outline of the reasons for publication

Patients and Methods/Materials and Methods For clinical work dealing with patients the first heading will be preferred. The second is used in articles dealing with laboratory work or animal experiments.

Results This part of the paper provides a description of the results obtained (but neither a discussion nor a review of the literature) Double documentation in text and tables should be avoided

Discussion The author is recommended to discuss, and not just recapitulate, the results, giving particular emphasis to unsettled and controversial points and pointing to some conclusion No new findings should appear in this section

Conclusion In most articles a brief section summarizing the conclusions of the work is appropriate.

Acknowledgements If applicable

References References should be mentioned in the text by name of author(s) and year of publication Citations in the text should appear as Smith & Jones (1960) or (Smith & Jones 1960) When there are three or more authors, cite their paper as Doye et al (1960) All authors cited, and only these, must be listed at the end of the paper in alphabetical order according to the name of the first author

Examples

Lazcano, M. A., Anzel, S H & Kelly, P J (1961) Complete dislocation and subluxation of the acromioclavicular joint *J Bone Jt Surg* 43-A, 379–391

Watson-Jones, R (1955) *Fractures and joint injuries* Vol. 2, 4th ed pp 464–468 E and S Livingstone Ltd., Edinburgh.

Illustrations All illustrations are to be considered as figures, and each graph, drawing, or photograph must be numbered in sequence with arabic numerals. The approximate location in the text should be indicated by a circled marginal note Legends to illustrations should be listed on a separate sheet, identified with the name of the journal, the authors' names, and the figure number Lettering should be stencilled in black India ink, large enough for the necessary reduction *Line drawings* should be drawn with black India ink on white paper In order for line drawings to be reasonably consistent within the journal they should be double their intended finished size and as such their width should be one of the three following standard sizes 135 mm for single column width, 200 mm for 1½ column width, 280 mm for double column width. Lettering on the figures should be 3 8 to 4 mm high. Helvetica Leight, 14°, obtainable as transfer letters, is recommended. Graphs may be plotted on plain white or blue squared paper, grid lines that are to show in the engraving should be inked in black.

Photographs must be submitted as unmounted glossy enlargements showing good detail and contrast. Indicate 'up' and 'down' Mark each photograph with figure number, authors' names, and if desirable the magnification of the print. Never use paper clips on a glossy print or write so firmly on the back that the face is damaged Send photographs flat and protect them with stout cardboard backing

Colour illustrations are expensive and will be considered only when it is important to illustrate a particular feature that cannot be made clear by other techniques. Original transparencies (not smaller than 35 mm) as well as three sets of colour prints should be submitted

Tables Tables should be used only when necessary clarify important points and elaborate tables should avoided. They should be numbered consecutively arabic numerals. Each table should be typed on separate sheet So far as possible sufficient descriptive should be included in the titles to make tables self explanatory

Abbreviations and Symbols Only abbreviations and symbols that have been generally accepted should be used Unfamiliar abbreviations must be defined when first used

Proofs First proofs will be sent to the author The should be returned with the least possible delay Author will be required to pay for any major alterations to the original manuscript

Offprints Fifty offprints, without covers, of each article will be supplied to the authors free of charge. Additional offprints can be supplied if ordered on the offprint order form which will accompany the proofs.

Supplements An article or a series of articles exceeding a total of 16 printed pages may be accepted for publication as a supplement This applies to papers which have received national or international academic recognition (e g doctoral thesis, award). The acceptance is dependent on the editor's approval. After acceptance the supplements are not subject to editorial revision The full cost is paid by the author(s). Authors are requested as soon as possible to contact the publishers who will provide the necessary information concerning number of copies to be printed, text on cover and title page, size etc.

Editor

ACTA ORTHOPAEDICA SCANDINAVICA

INDEX

Vol 50, Fasc. 5, October 1979

Larsson, S E, U Lorentzon, E Lundgren & L. Boquist Transplantable osteosarcoma in mice. Structural characterization of a transplantable osteosarcoma obtained in an allogenic system 481

Poussie [illegible] 491

Walto [illegible] Observations of an osteoarthrosis-prone strain of mouse 501

Kumar, S, P R. Davis & B Pickles Bone-marrow pressure and bone strength 507

Ahlberg A & H Pettersson. Synoviorthesis with radioactive gold in hemophiliacs. Clinical and radiological follow-up 513

Eriksen J, E Tøndevold, E Jansen & J E Petersen. Relationships between oxygen and carbon dioxide tensions and acid base balance in arterial blood and in medullary blood from long bones in dogs 519

Tøndevold, E, J Eriksen & E Jansen. Observations on long bone medullary pressure in relation to mean arterial blood pressure in the anaesthetized dog 527

Pintér, J, G Lénárt & G Ruschák. Physical and chemical investigation of free bodies in articular osteochondromatosis 533

Friberg, K. S I Remodelling after distal forearm fractures in children. I The effect of residual angulation on the spatial orientation of the epiphyseal plates 537

Jajić, I & J Ružnjević Myositis ossificans localisata as a complication of tetanus 547

Barquet, A Traumatic hip dislocation in childhood A report of 26 cases and a review of the literature 549

Collert, S & P Gillstrom. Osteotomy in osteoarthritis of the hip. A prospective study 555

Murray, M P, D R Gore, B J Brewer, G M Gardner & S B Sepic A comparison of the functional performance of patients with Charnley and Muller total hip replacement. A two-year follow up of eighty-nine cases 563

Kolind Sørensen, V & J Marqvertsen Distal blood pressure measurement in lower limb amputees 571

Sudmann, E The painful chronic anterior lower leg syndrome A prospective clinical and experimental study 573

Rauschning, W & P G Lindgren. Popliteal cysts (Baker's cysts) in adults. I Clinical and roentgenological results of operative excision 583

Kristensen, K D Tibial shaft fractures. The frequency of local complications in tibial shaft fractures treated by internal compression osteosynthesis 593

Andersen L. I & I Heid Bilateral hallux saltans. Report of a case 599

Proceedings of the Finnish Orthopaedic Association 601

Announcements 607

should indicate the subjects of the investigation The abstract should comprise a brief and factual summary of the contents and conclusions of the paper, a pointer to any new information which it may contain, and an indication of its relevance

It should be presumed that the reader has some knowledge of the subject but has not read the paper The abstract should therefore be intelligible in itself without reference to the paper It should only in exceptional cases exceed 200 words.

Key words 4–9 key words for indexing should be given by the author(s) together with the abstract. They should be placed in alphabetical order and be in accordance with the Annual Bibliography of Orthopaedic Surgery (*J Bone Jt Surg* Boston, Mass., U S A)

Introduction This should be a brief outline of the nature of the problem with particular emphasis on the state of knowledge at the start of the investigation followed by a short description of the investigation itself and an outline of the reasons for publication

Patients and Methods/Materials and Methods For clinical work dealing with patients the first heading will be preferred The second is used in articles dealing with laboratory work or animal experiments.

Results This part of the paper provides a description of the results obtained (but neither a discussion nor a review of the literature) Double documentation in text and tables should be avoided.

Discussion The author is recommended to discuss, and not just recapitulate, the results, giving particular emphasis to unsettled and controversial points and pointing to some conclusion No new findings should appear in this section

Conclusion In most articles a brief section summarizing the conclusions of the work is appropriate

[illegible] If applicable

References References should be [illegible] and only these, must be listed at the end of the paper in alphabetical order according to the name of the first author

Examples

Lazcano M A Anzel S H & Kelly P J (1961) Complete dislocation and subluxation of the acromioclavicular joint *J Bone Jt Surg* 43-A, 379–391

Watson Jones, R (1955) *Fractures and joint injuries* Vol 2, 4th ed. pp 464–468 E and S Livingstone Ltd., Edinburgh

Illustrations All illustrations are to be considered as figures, and each graph drawing or photograph must be numbered in sequence with arabic numerals. When a figure has several parts e g a b c this should be clearly [illegible] the authors names, and the figure number Lettering [illegible] following standard sizes 135 mm for single column width 200 mm for [illegible]

Photographic reproductions must be prepared so as to fit the columns of the journal Most illustrations can be properly shown within the width of one column (6 7 cm) *Micrographs* should be planned so that they can be produced without reduction.

[illegible] with figure number, authors' names, and, if desirable, the magnification of the print

Colour illustrations are expensive and will be considered only when it is important to illustrate a particular feature that cannot be made clear by other techniques. Original transparencies (not smaller than 35 mm) as well as three sets of colour prints should be submitted

Tables Tables should be used only when necessary to clarify important points and elaborate tables should be avoided. They should be numbered consecutively in arabic numerals. Each table should be typed on a separate sheet So far as possible sufficient description should be included in the titles to make tables self-explanatory

Abbreviations and Symbols Only abbreviations and symbols that have been generally accepted should be used Unfamiliar abbreviations must be defined when first used.

Proofs First proofs will be sent to the author They should be returned with the least possible delay Authors will be required to pay for any major alterations to their original manuscript

[illegible]

Supplements An article or a series of articles exceeding a total of 16 printed pages may be accepted for publication as a supplement. This applies to papers which have received national or international academic [illegible]

[illegible] cost is paid by the author(s) [illegible] requested as soon as possible to contact the publisher who will provide the necessary information concerning number of copies to be printed text on cover and title page size etc.

Editor

ACTA ORTHOPAEDICA SCANDINAVICA

INDEX

Vol 50, Fasc 6, Part 1, December 1979

Nordic Orthopaedic Association 60th Anniversary 609

Shitama K Calcification of aging articular cartilage in man 613

Sudmann E & G Bang Indomethacin induced inhibition of haversian remodelling in rabbits 621

Wu, H, L. B Engesaeter & E I Beck. Effects of cyclophosphamide on mechanical properties of bone and skin in rats 629

Houghton G R & S Dekel The periosteal control of long bone growth An experimental study in the rat 635

Nielsen H E, U Pedersen H H Hansen & O Elbrønd Serum calcitonin and bone mineral content in patients with osteogenesis imperfecta 639

Tønderold, E, J Eriksen & E Jansen Observations on long bone medullary pressures in relation to arterial PO_2 PCO_2 and pH in the anaesthetized dog 645

Panjabi M M, A A White III & J W Wolf, Jr A biomechanical comparison of the effects of constant and cyclic compression on fracture healing in rabbit long bones 653

Jørgensen, T M, J-H Andresen, P Thommesen & H H Hansen Scanning and radiology of the carpal scaphoid bone 663

Levy, Y, S Rosenheck, M Grieff & G Torok Osteoid osteoma of the distal phalanx of the thumb 667

Berglund, B & K Bergstrom Serum enzymes after hip joint surgery 671

Martinek, H, E Egkher, B Wielke & H Spängler Experimental tests concerning the biomechanical behaviour of pertrochanteric osteosyntheses 675

Ceder, L., L. Ekelund, S Inerot, L Lindberg, E Odberg & C Sjölin Rehabilitation after hip fracture in the elderly 681

Andersson, S M & B E Nilsson Post-traumatic bone mineral loss in tibial shaft fractures treated with a weight bearing brace 689

Markhede, G & L Nistor Strength of plantar flexion and function after resection of various parts of the triceps surae muscle 693

Hansen, H, V Damholt & N B Termansen Clinical and social status following injury to the lateral ligaments of the ankle Follow-up of 144 patients treated conservatively 699

Termansen N B, H Hansen & V Damholt Radiological and muscular status following injury to the lateral ligaments of the ankle Follow up of 144 patients treated conservatively 705

Newman, R J & J M Fitton An evaluation of operative procedures in the treatment of hammer toe 709

should indicate the subjects of the investigation The [illegible]

exceed 200 words

Key words 4–9 key words for indexing should be given by the author(s) together with the abstract. They should be placed in alphabetical order and be in accordance with the Annual Bibliography of Orthopaedic Surgery (*J Bone Jt Surg* Boston, Mass. U S A)

Introduction This should be a brief outline of the nature of the problem with particular emphasis on the state of [illegible]

Patients and Methods/Materials and Methods For clinical work dealing with patients the first heading will be preferred The second is used in articles dealing with laboratory work or animal experiments.

Results This part of the paper provides a description of the results obtained (but neither a discussion nor a review of the literature) Double documentation in text and tables should be avoided

Discussion The author is recommended to discuss, and not just recapitulate, the results, giving particular emphasis to unsettled and controversial points and pointing to some conclusion No new findings should appear in this section

Conclusion In most articles a brief section summarizing the conclusions of the work is appropriate

knowledgements If applicable

References should be mentioned in the text by name of author(s) and year of publication Citations in the text should appear as Smith & Jones (1960) or (Smith & Jones 1960) When there are three or more authors, [illegible] author

Examples

Lazcano M A Anzel S H & Kelly P J (1961) Complete dislocation and subluxation of the acromioclavicular joint *J Bone Jt Surg* 43-A, 379–391

Watson Jones, R (1955) *Fractures and joint injuries* Vol. 2, 4th ed pp 464–468 E and S Livingstone Ltd, Edinburgh

Illustrations All illustrations are to be considered as figures, and each graph drawing or photograph must be numbered in sequence with arabic numerals. When a [illegible] the authors names, and the figure number Lettering should be stencilled in black India ink in capitals and large [illegible]

journal they should be outline then attached in [illegible] and as such their width should be one of the three following standard sizes 135 mm for single column width, 200 mm for 1½ column width 280 mm for double [illegible] be prepared so as [illegible]

Photographs must be submitted as unmounted glossy [illegible]

Colour illustrations are expensive and will be considered only when it is important to illustrate a particular feature that cannot be made clear by other techniques. Original transparencies (not smaller than 35 mm) as well as three sets of colour prints should be submitted

Tables Tables should be used only when necessary to clarify important points and elaborate tables should be avoided They should be numbered consecutively in arabic numerals. Each table should be typed on a separate sheet So far as possible sufficient description should be included in the titles to make tables self explanatory

Abbreviations and Symbols Only abbreviations and symbols that have been generally accepted should be used Unfamiliar abbreviations must be defined when first used

Proofs First proofs will be sent to the author They should be returned with the least possible delay Authors will be required to pay for any major alterations to their original manuscript

[illegible] of each article [illegible]

Supplements An article or a series of [illegible] exceeding a total of 16 printed pages may be accepted for publication as a supplement This applies to papers which have received national or international academic recognition (e g doctoral thesis award). The acceptance is dependent on the editor s approval. After acceptance, the supplements are not subject to editorial revision The full cost is paid by the author(s). Authors are requested as soon as possible to contact the publishers who will provide the necessary information concerning number of copies to be printed text on cover and trim page size etc.

Editor

Acta orthop scand. 50, 1–14, 1979

OSTEOARTHRITIS OF THE KNEE IN THE RABBIT PRODUCED BY IMMOBILIZATION

Attempts to Achieve a Reproducible Model for Studies on Pathogenesis and Therapy

ANDERS LANGENSKIÖLD, JARL-ERIK MICHELSSON & TAPIO VIDEMAN

Department of Orthopaedics and Traumatology, Helsinki University Central Hospital and the Orthopaedic Hospital of the Invalid Foundation, Helsinki, Finland

In order to obtain a reproducible experimental model of osteoarthritis a method of immobilizing the rabbit's knee in extension by means of a plastic splint was developed The right knees of the rabbits were immobilized for periods varying from 4 days to 24 weeks. With the left knees as controls the knees were studied in a variety of ways among these being radiography (126 rabbits), histological sections stained with Alcian Blue (88 rabbits) analysis of ^{35}S-sulphate uptake (22 rabbits) and ^{35}S-autoradiography (6 rabbits). In 27 rabbits the regaining of mobility after immobilization was studied After 5–6 weeks of immobilization most of the knees showed moderate or severe changes including loss of articular cartilage and osteophyte formation Immobilization of the rabbit's knee by this method provokes a fairly easily reproducible type of degenerative joint disease showing similarities to advanced osteoarthritis as seen in humans.

Key words animal experiments immobilization, osteoarthritis, knee

Accepted 5 vi 78

Studies in man have not been able to clarify the pathogenetic chain of factors giving rise to progressive osteoarthritis Bentley wrote in 1974 " a model arthrosis which is consistently reproducible in animals, capable of recognition radiographically without sacrifice of the animal and irreversible, would be valuable in facilitating further study of the pathogenesis of the disease and the effect of different methods of treatment on it"

Reviews of the methods for the production of experimental models of osteoarthritis have been given by several authors (Moskowitz 1972, Bentley 1974) That degenerative changes are caused by long-term immobilization of joints with or without compression of the articular cartilage has been demonstrated in many studies (Ely & Mensor 1933, Evans et al 1960, Salter & Field 1960, Trias 1961, Hall 1963, 1964, Thaxter et al 1965, Field & Hueston 1970, Roy 1970, Thompson & Basset 1970, Sood 1971, Finsterbush & Friedman 1973, 1975, Videman et al 1976) However, an attempt at a systematic mapping of the changes appearing after different periods of immobilization of joints in experimental animals has not been made The purpose of this investigation has been to develop a method of producing a "standard osteoarthritis" of the knee of the rabbit without operative trauma, to define the immobilization time producing the most suitable model and to map the changes appearing in different parts of the joint

0001-6470/79 010001-14$02.50 0

© 1979 Munksgaard, Copenhagen

MATERIALS AND METHODS

In pilot studies it was soon found that immobilization of the rabbit's knee in extension for 6 weeks or more gave rise to degenerative joint disease However, the standardization and reproducibility of the condition necessarily required standardization of the method of immobilization The animal should be able to keep the immobilizing device on the limb for months without direct damage to skin and muscles Immobilization by plaster of Paris or by plastic tubes was tried in various ways but these methods did not fulfil the requirements. For the development of a standard method of immobilization, 152 rabbits were used These experiments were considered preliminary and although most of the animals developed osteoarthritic changes they are not included in the series reported in this article The rabbits were considered adult when older than 9 months (Heikel 1959) In addition to the reported series of adult rabbits, the right knees of 65 immature rabbits were immobilized

The methods used for studying the changes in the knee joints following immobilization are shown in Table 1 In the same table the number of rabbits studied after different periods of immobilization is seen

Method of immobilization The method of immobilization finally adopted and used in the reported series of 154 adult and 65 growing rabbits is shown in Figure 1 A straight and somewhat elastic splint of PVC-plastic measuring about 300 × 30 × 1 mm was applied on the dorsal aspect of the right leg from the proximal end of the thigh to the distal end of the limb The splint was tied to the limb by 3–6 turns of a



Figure 1 The immobilization method A rabbit with right hind limb immobilized with the knee in extension showing the splint and bandage used In the left lower corner of the picture the cross sections of two different splints used (PVC—plastic, 300 × 30 × 1 mm)

Tensoplast* bandage The splint and the band kept the knee straight or somewhat flexed. Flex up to 20 degrees was possible with the applied A too-tight bandage causing hyperext sion and rapid deterioration of the joint avoided

When the splint was applied, the hamstr muscles and the muscles of the calf were tight, flexion of the hip joint was restricted and the f was drawn into an equinus position

The non-immobilized left knees were used controls. These were compared with 15 knees non-immobilized rabbits.

Radiography In 126 rabbits both knees w radiographed in the antero posterior projection intervals varying from 1 week, in most periments, to 4 months when the follow-up per was over a year These radiographs were tak with the animal lying prone with the hips a knees extended Side views were taken of bo knees at least at the beginning and the end the immobilization period The film used w Kodak* PE 4006 and the focus distance w 100 cm The results were analyzed statistic using the *t* test

Histological methods Histological sections we made of both knees of animals (61 adult). T whole limbs with the skin stripped off or t separated ends of the femur and the tibia we fixed in 10 per cent neutral formalin and we decalcified in New Decalc* solution (Hist La Betlehem Trading Ltd, Goteborg Sweden) an average for 1 week at room temperature The the knees, mostly including periarticular tissues were embedded in hard paraffin in th usual way Sections were made in different plane and most of them were stained with the Alcia Blue—PAS method

With Alcian Blue—PAS staining the acid glycosaminoglycans of connective tissue an sialomucins give a blue colour while neutr mucosubstances all polysaccharides an mucosubstances containing hexoses or deoxy hexoses with vicinal glycol groups, stain re (McManus & Mowry 1964, Luna 1968). Th appearance of the blue colour in the areas o cartilage with pathological location in connective with immobilization chemically indicates enrich ment of acidic glycosaminoglycans. Histologically indicates newly formed cartilaginous tissue (Eronen et al 1978)

Changes in mobility of the knee joint In T rabbits the mobility of the knee was estimated after periods of immobilization varying between 2 and 14 weeks (regaining of mobility

ble 1 The number (n) of rabbits (the right knee immobilized in extension) used for the different methods of examination In parentheses the number of growing rabbits

amination ethod	Immobilization time in days					Total
	4–14 *n*	15–28 *n*	29–42 *n*	43–80 *n*	>80 *n*	
idiographic follow up	6 (2)	12 (2)	39 (23)	15 (6)	[illegible] (3)	90 (36)
stological examination	15 (2)	13 (2)	10 (15)	5 (6)	[illegible] (2)	61 (27)
gaining of mobility study	— (3)	3 (2)	1 (7)	2 (3)	[illegible] (—)	12 (15)
^{35}-sulphate uptake analysis	9	—	6 (2)	3	2	20 (2)
itoradiography with ^{35}S-sulphate	2	3	1	—	—	6 (—)
lycosaminoglycan analysis	10	4	2	—	—	16 (—)
iotography	1	3	3	— (1)	1	8 (1)
canning electron microscopy	— (1)	3	3 (1)	2	—	8 (2)
xytetracycline fluorescence	1	—	1 (6)	3 (4)	5 (1)	10 (11)
otal	44 (8)	41 (6)	66 (54)	30 (20)	50 (6)	231 (94)

mobilization) The measurements were ade with a goniometer regularly once a eek for at least 10 weeks after removal of the oint. All measurements were made by only two ersons in order to minimize variations in chn que The measurements were made without naesthesia and the knees were extended and xed with caution until abnormal resistance was lt. The generally adopted expression of mobility f the knee was used the fully extended position xpressed as [illegible]° and full flexion as 180° Hyperex nsion was expressed with negative numbers he range of movement from maximal extension as expressed in degrees

ross appearance In specimens where the distal nd of the femur and the proximal end of the tibia ere separated the gross appearance of the joint urfaces and the periarticular soft tissues was oted In nine rabbits the soft tissues from the distal nds of the femora and the proximal ends of the biae were carefully removed and the gross ppearance of the joint surfaces was recorded by hotography

Methods and results described earlier *^{35}S ulphate uptake* (Videman et al. 1976) *^{35}S utoradiography* (Videman et al. 1976) *Labelling ith oxytetracycline* (Michelsson et al 1977a) *Scanning electron microscopy* (Videman et [illegible] 1977) *Glycosaminoglycan analysis* (Eronen et al 1978).

RESULTS

Table 1 shows the number of immobilized knees studied by the various methods after different periods of immobilization The methods used disclosed the changes in the joint from different aspects

Progression of changes caused by immobilization

Changes appearing after 4–14 days of immobilization On the fourth day of immobilization a marked increase of uptake of ^{35}S-sulphate in the ligaments of the knee and in the joint capsule could already be demonstrated (Videman et al 1976) After 6 days thickening of the joint capsule, the collateral ligaments and the patellar tendon could be seen histologically (Figures 2A and 2B) This thickening of the periarticular soft tissue was regularly seen at all stages of immobilization (Figures 2B-D) After [illegible] days, abnormally proliferating cartilage could be seen peripheral to the edges of the joint cartilage both on the femur and the tibia

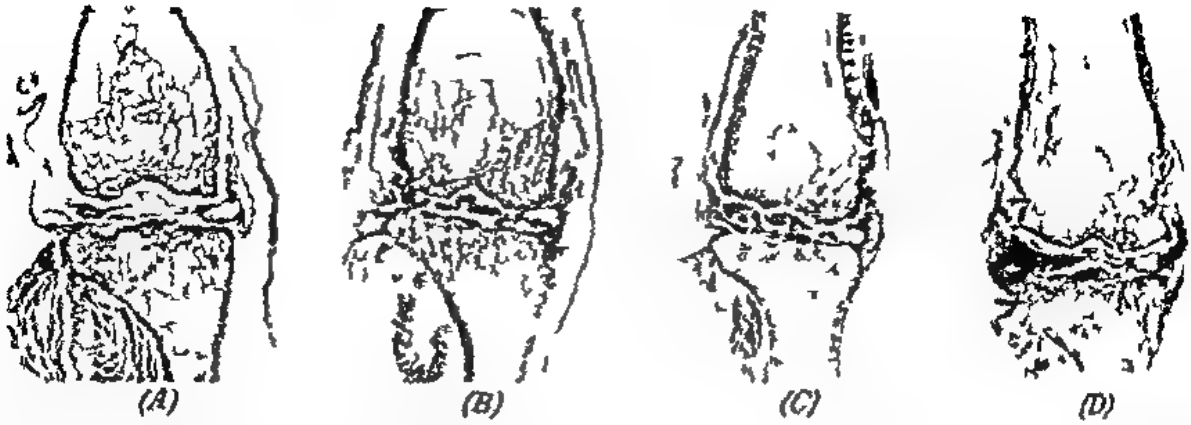

Figure 2A D Histological sections of adult rabbit knees [illegible] immobilized animal). B Section of rabbit kn[illegible] compared with normal is the thickening of the [illegible] D Section of rabbit knee immobilized for 10 weeks Marked thickening and increased density of cap[illegible] tissue Note diminished amount of cancellous bone in the distal end of the femur with increasing duration of immobilization (Stained with Alcian Blue—PAS and 2 5 × magnification)

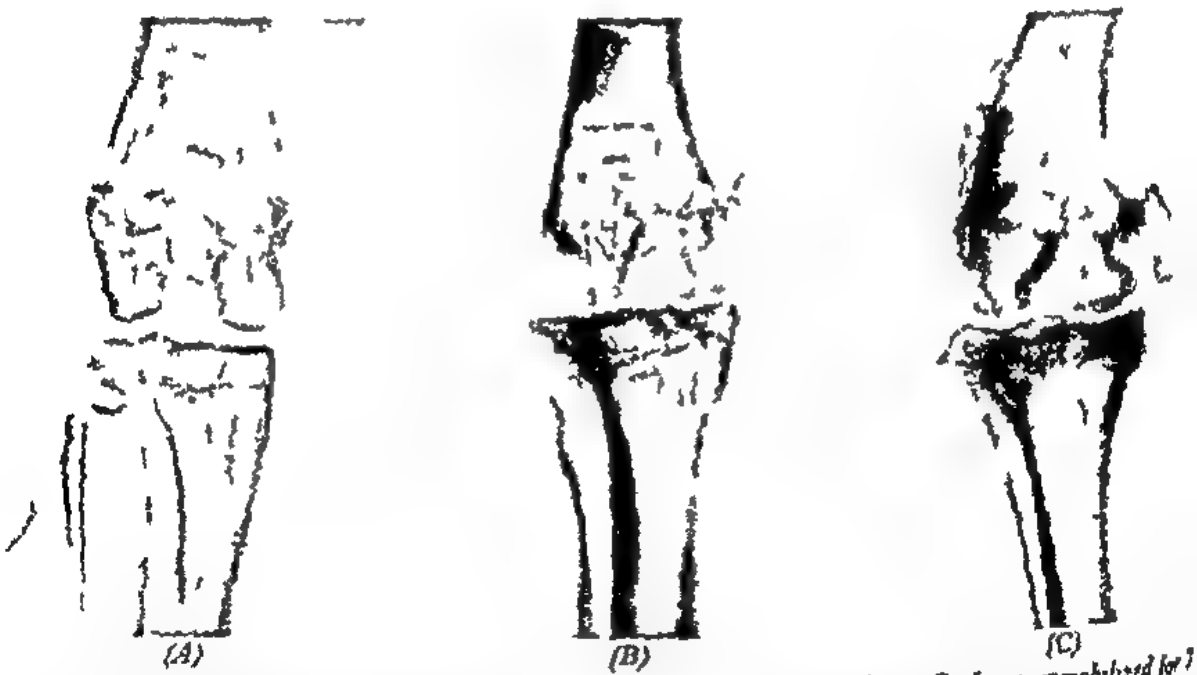

Figure 3A C Antero-posterior radiographs of rabbit knees A Normal knee B Knee immobilized for 7 weeks showing moderate osteoarthritic changes (followed for 6 weeks after immobilization). C Knee immobilized for 12 weeks showing severe osteoarthritic changes (followed for 2 years and 2 months after immobilization)

(Figure 5A and B) After 14 days the definite beginnings of osteophyte formation on the medial side of the tibia could be seen in histological sections. Within 14 days of immobilization only slight narrowing of the joint space was noted as the single sign of joint degeneration in the radiographs.

Changes appearing after 15–28 days of immobilization After 21 days, fibrillation and loss of cartilage were repeatedly seen at the joint surfaces both on the femoral and the tibial condyles and on the facies patellaris of the femur (Figure 6) All signs of erosion and necrosis of articular cartilage seen by one

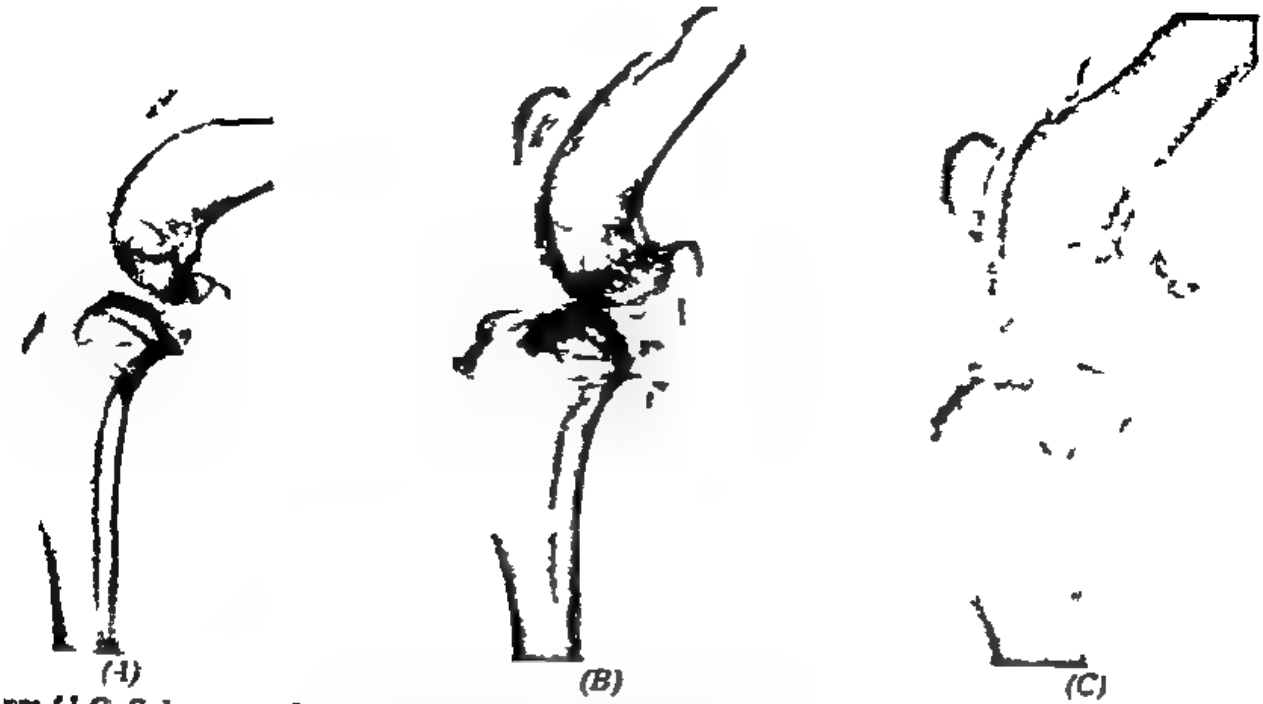

ure 44-C Side-view radiographs of rabbit knees. A Normal knee. B Knee immobilized for 8 weeks showing moderate osteoarthritic changes (followed for 2 months after immobilization). C Knee showing severe osteoarthritic changes after 6 weeks of immobilization (followed for 10 months after immobilization)

hors (Hall 1963 Finsterbush & Friedman 73 1975), including fragmentation and ation of fissures, were observed. As tilage artefacts make interpretation of se regressive changes uncertain, less



emphasis is here put on the changes sugges- can for erosion of cartilage and preceding the stage at which subchondral bone is denuded. Abundant abnormal cartilage proliferation at the edges of the joint surfaces was common (Figure 7A and B). Osteophyte formation caused thickening of the distal end of the femur. On the medial aspect of the tibia osteophyte formation was a constant finding (Figures 7A and B 8A and B). Radiographs often showed osteophytes both on the femur and the tibia.

Changes seen after 29–80 days of immobilization. Loss of articular cartilage at the joint surfaces was more marked than after a shorter period, especially at the contact

Figure 6 Histological sections of weight-bearing areas of femoral condyles. The upper picture shows a normal articular cartilage. The lower picture shows the corresponding area of a knee after immobilization for 1a days. In one region the articular cartilage has disappeared (arrow a). Other parts show fibrillation (arrow b) or hypertrophy of articular cartilage (arrow c). (Stained with Alcian Blue—PAS and 30 x magnification).

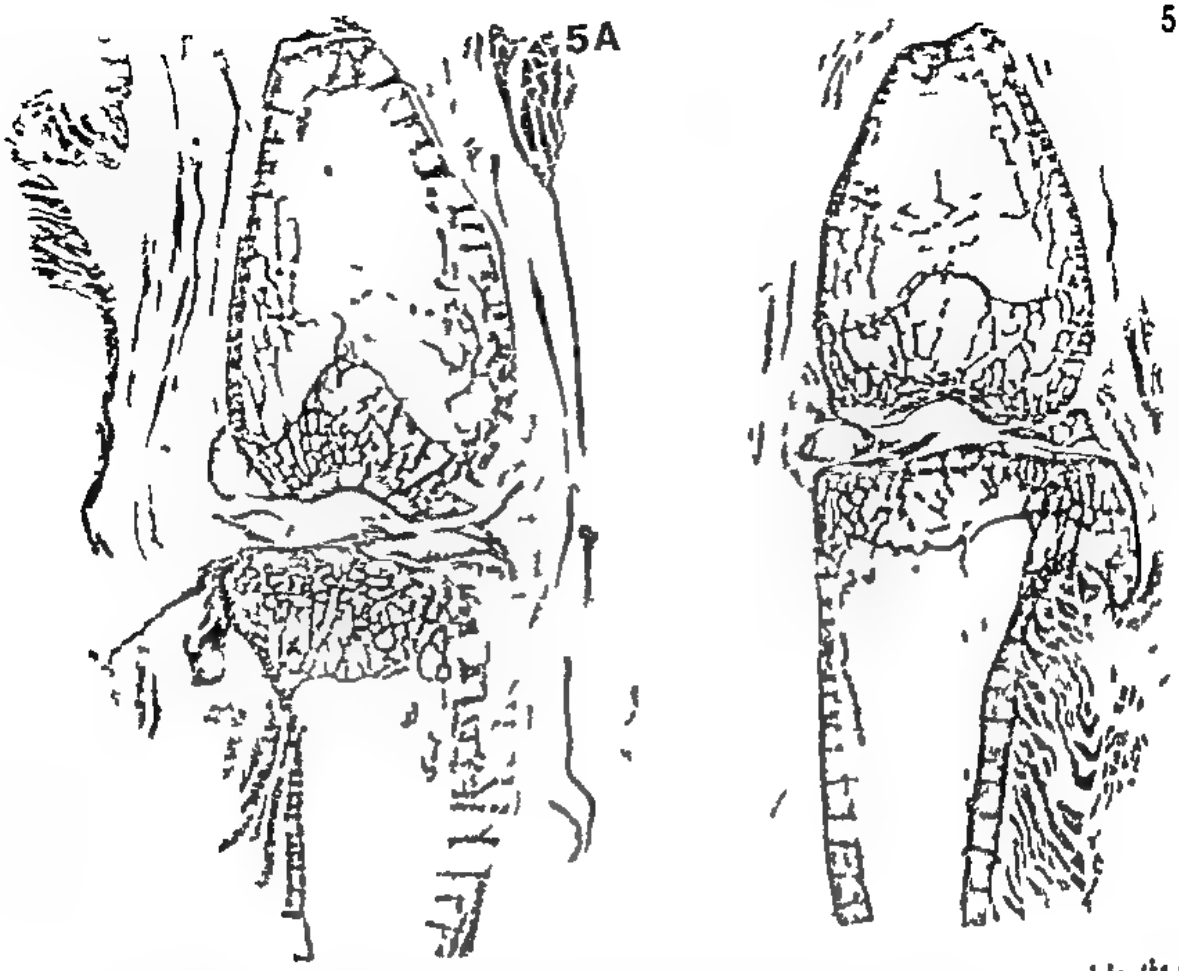

Figure 5A and B Histological sections of rabbit knees in the frontal plane stained by the Alcian Blue—PAS method B Non immobilized knee A The other knee of the same animal after immobilization for 2 weeks Note the thickened capsule and the pathologically situated blue stained portions of cartilage in the immobilized knee (Stained with Alcian Blue—PAS and 1 5 × magnification)

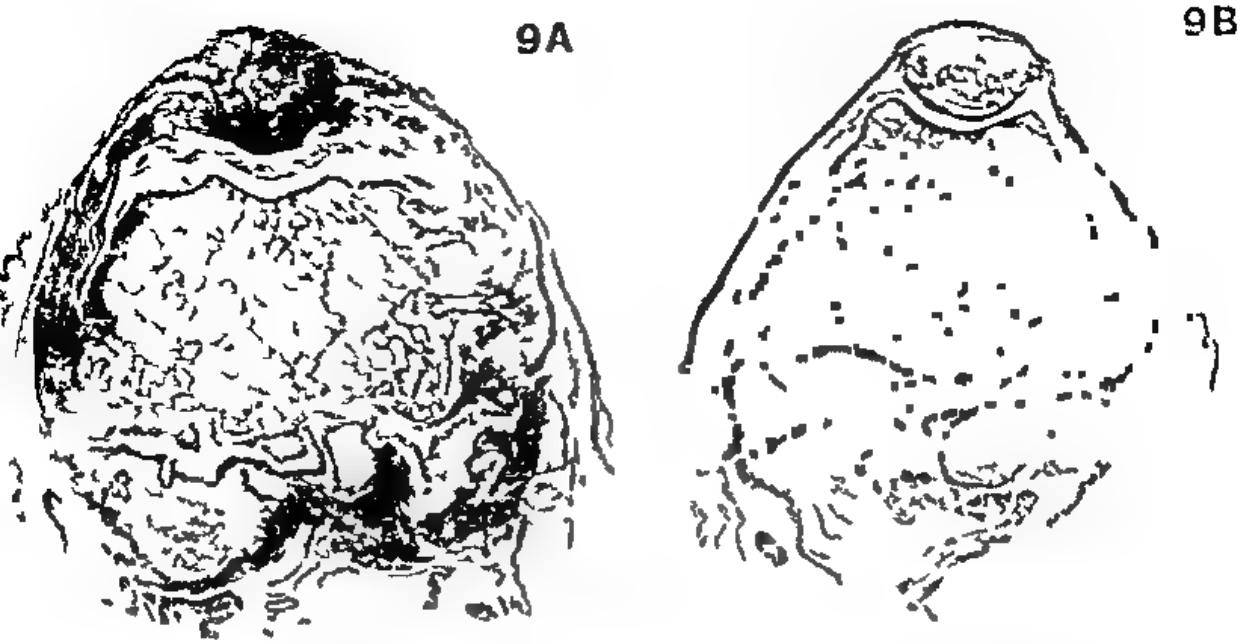

same rabbit B A
is immobilized for 6
artilage (blue) and
enlargement of the condyles and the sesamoid bones are evident (Alcian blue—PAS staining and 2x magnification)

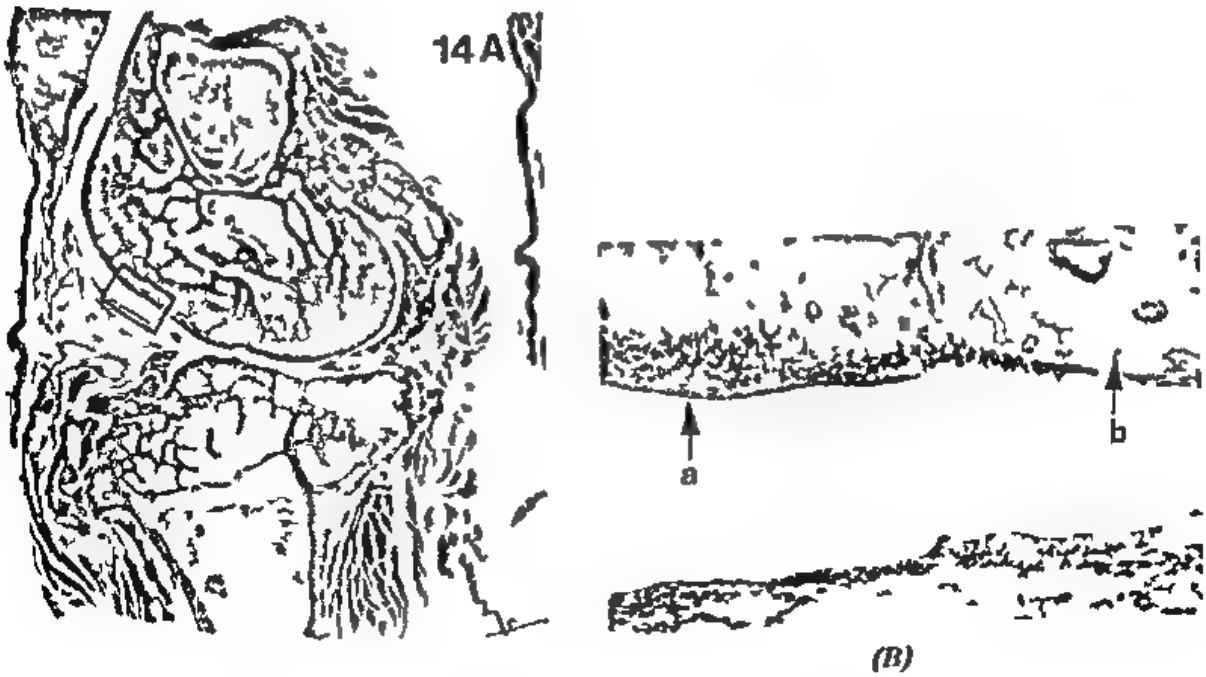

Figure 14A and B H. tolog. al sag ttal sect on of a knee immobilized for 7 weeks and thereafter followed for 3
ton)
of bor

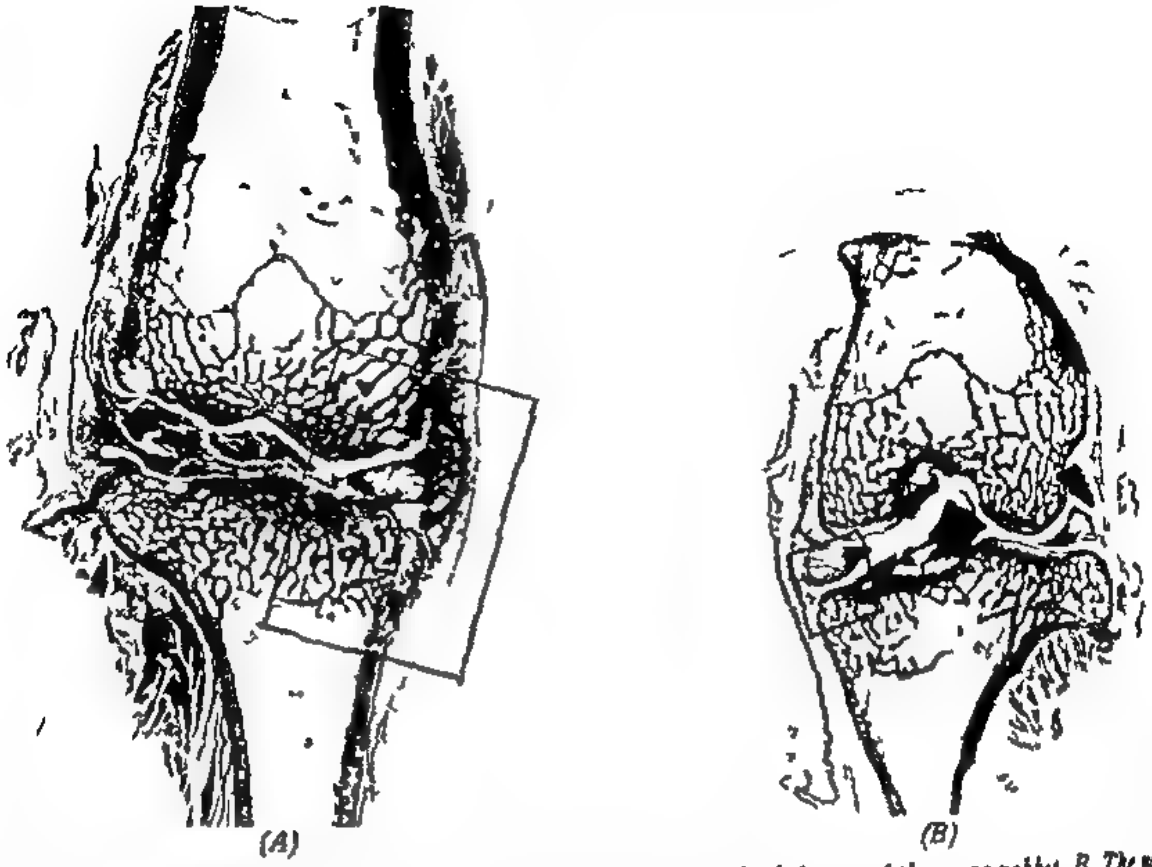

Figure 7A and B Histological sections in the frontal plane of both knees of the same rabbit B The

areas The cortex of the femur appeared ickened and the cancellous bone at the l end of the femur was markedly diminished After 6 weeks of immobilization the sesamoid bones were enlarged and the femoral facies patellaris showed abundant marginal osteophyte formation (Figures 3B and 4B) A regular phenomenon was a marked thickening of the distal end of the femur (Figures 9A and B 10A and B, 11) A round area of denuded bone at the cranial end of the facies patellaris of the femur was seen in almost every case at this stage (Figures 12A and B 13)

Changes after more than 80 days of immobilization Eburnation of denuded bone and areas of hypertrophied cartilage were regularly seen at this stage although these phenomena could appear at earlier stages (Figure 14)

Mobility of the joint in relation to immobilization time

Marked degenerative changes usu appeared after 4 weeks of immobilization, b after prolonged immobilization joint mobil was lost and severe destruction of the jo often followed It was thus desirable to de the length of the immobilization peri provoking osteoarthritis without cau permanent contracture of the joint. A pr liminary report of a series of 15 immat and 12 adult rabbits studied for this purpo has been presented (Michelsson et al. 197 From the curves shown in Figure 15 appears that an immobilization peri exceeding 6 weeks was followed by prolonge restriction of movement Thus immobiliz of the knee in extension for a period of weeks is a means of provoking degener

igure 8A and B Detail [illegible]
on immobilized kne
meniscus and the
mmation of new ca
lue—PAS staining and 7 5 × magnification)

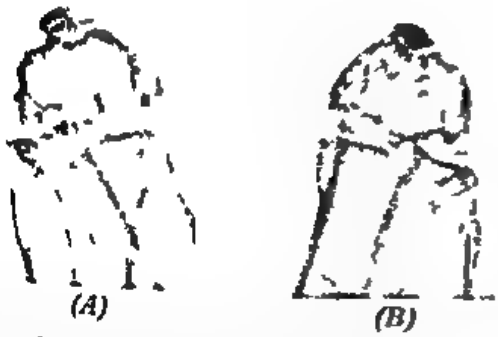

igure 10A and B Radiographs of the flexed nees of a rabbit taken in a projection tangential the facies patellaris of the femur B The non-mmobilized knee A The other knee, which was mmobilized for 6 weeks (followed for 5½ months fter immobilization) The marginal osteophytes f the patella and the thickening of the distal end f the femur are clearly seen



Figure 11 Photographs of the distal ends of both femora of the same rabbit To the right the non-immobilized knee To the left the contralateral knee which was immobilized for 6 weeks (followed for 2 months after immobilization) Compare with Figures 9 and 10

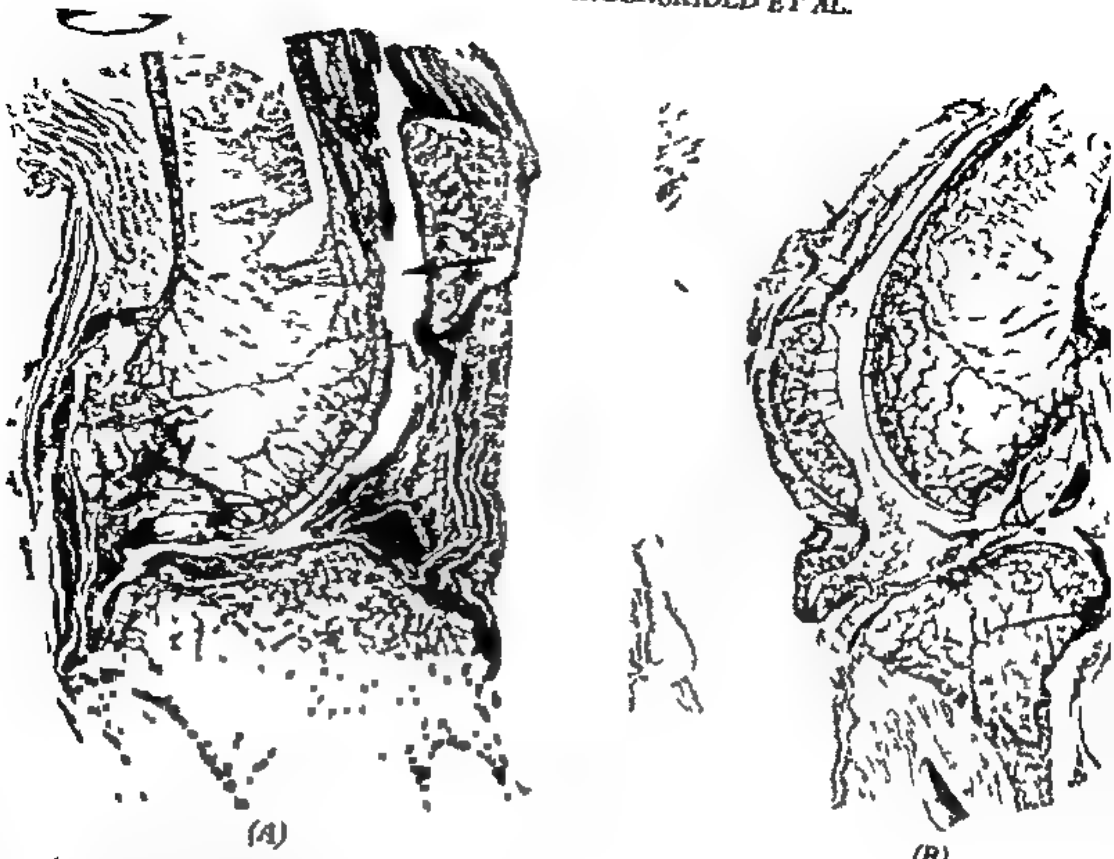

(A) (B)

Figure 12A and B Histo[illegible] knee A The oppos[illegible] mobilization) Note t[illegible] (Alcian Blue—PAS s[illegible] magnification)

Figure 13 Photographs of the distal ends of both femora of the same rabbit To the right the femur from the non immobilized leg To the left the femur from the opposite leg which was immobilized for 8 weeks (followed for 1½ years after immobilization) Note the round depression in the proximal part of the facies patellaris (arrow, compare with Figure 12)

disease of this joint without ca[illegible] permanent restriction of movement

Radiological assessment of osteoarthritis

The severity of changes suggest[illegible] degenerative joint disease in the radiogra[illegible] was assessed as follows Grade 0 no cha[illegible] (Figure 3A and 4A) Grade 1 slight j[illegible] space narrowed, bone trabeculae somew[illegible] thickened, lipping at edges of joint surfa[illegible] Grade 2 moderate, joint space narrowe[illegible] marked osteophytes, bone trabec[illegible] markedly thickened, sesamoid bones enlarg[illegible] joint surface irregular (Figures 3B and 4B[illegible] Grade 3 severe, as grade 2 but more marke[illegible] changes (Figures 3C and 4C)

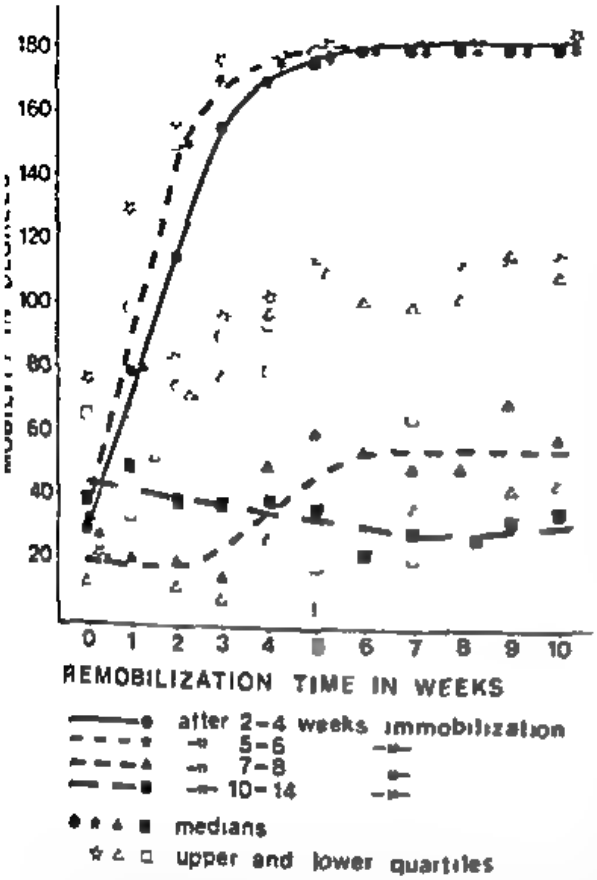

igure 15 The development of mobility of the nee after different periods of immobilization The urves are drawn according to the medians and he distribution symbols are the upper and lower uartiles In both the 2–4 and the 5–6 weeks immobilization groups there were 8 rabbits The imitation of mobility was irreversible when the mmobilization period was increased from 6 to 8 eeks with this immobilization method During he first month after immobilization the mobility as greater in the 10–14 week immobilization group 5 rabbits) than in the 7–8 week group (5 rabbits) his phenomenon was due to the hyperextension in he 10–14 week group

he effect of the length of the immobilization eriod on radiographic changes

The result of assessment of the adiographic changes of 126 knees is seen in Table 2 It shows that slight or moderate hanges were already present after 2–4 weeks of immobilization, but also that the period after the end of immobilization affects the final condition When the duration of immobilization increases, the radiographic grade of degenerative signs also changes statistically significantly The shortest statistically significant period was when the immobilization period was increased from 15–28 days to 29–42 days

The effect of the length of the immobilization period on histological changes

The progression of the proliferative changes in the joint capsule and ligaments around the knee was most marked during the third week of immobilization During further immobilization for 2 months progression of these changes was slower The signs of cartilage necrosis and erosion and eburnation of bone progressed continuously with increasing immobilization time

The effect of the time following the immobilization period

It appears from Table 2 that moderate or severe radiographic changes dominated when the follow-up period after removal of the immobilizing splint exceeded 57 days The degenerative changes progressed during the remobilization period The difference in severity between the radiographic changes present at the end of immobilization and those found 8 weeks later was statistically highly significant ($P < 0.001$)

Moderate osteoarthritis predominated in the group immobilized for more than 8 weeks Histologically, it was noted that the proliferated cartilage close to the osteophytes was less abundant when a long time had elapsed from the immobilization period

DISCUSSION

Osteoarthritis has earlier been considered an incurable condition because of the inability of the articular cartilage to repair itself after injury However, it has recently been shown in experiments that regeneration of joint cartilage is possible (Sokoloff 1974) Clinical facts have also provided evidence which

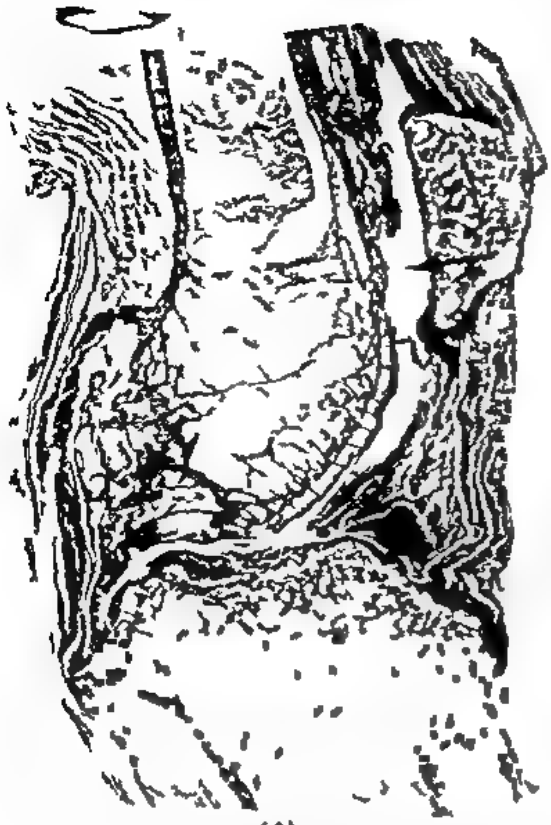

(A)

(B)

Figure 12A and B Histological sagittal sections of both knees of the same rabbit B The non immob knee A The opposite knee which was immobilized for 3 months (followed for 3 months after mobilization) Note the area of denuded bone in the femoral facies patellaris opposite the patella (arr (Alcian Blue—PAS staining and 1 5 × magnification)

Figure 13 Photographs of the distal ends of both femora of the same rabbit To the right the femur from the non immobilized leg To the left the femur from the opposite leg which was immobi li ed for 8 weeks (followed for 1½ years after immobilization) Note the round depression in the proximal part of the facies patellaris (arrow compare with Figure 12)

disease of this joint without caus permanent restriction of movement

Radiological assessment of osteoarthritis

The severity of changes suggesti degenerative joint disease in the radiogra was assessed as follows Grade 0 no cha (Figure 3A and 4A) Grade 1 slight j space narrowed bone trabeculae somewh thickened lipping at edges of joint surf Grade 2 moderate joint space narrow marked osteophytes, bone trabecu markedly thickened sesamoid bones enlarg joint surface irregular (Figures 3B and 4 Grade 3 severe as grade 2 but more mar changes (Figures 3C and 4C)

justifies optimism as far as the curability of osteoarthritis is concerned The improvement which has been seen in osteoarthritic hips after intertrochanteric osteotomy is still unexplained (Ottolenghi & Frigerio 1962 Nissen 1963 Blount 1964 Ferguson 1971, Nissen 1971 Salenius et al 1971, Hirsch et al 1972 Detenbeck et al 1972 Byers 1974) Our knowledge of the pathogenesis of osteoarthritis and its curability would greatly increase if the curative factors released by osteotomy were discovered and studied by means of experiments in animals

The purpose of this investigation the production of a reproducible degenerative joint disease in rabbits with changes corresponding to those seen in a severe and advanced stage of human osteoarthritis has been fulfilled This can be seen in Table 2 and Figure 15 Characteristic of the early changes in the model described is the hypertrophy of the capsule of the joint and of the collateral ligaments It seems that this phenomenon is an important link in the pathogenetic chain when immobilization of the rabbit's knee leads to degeneration of the joint

The importance of thickening of the capsule and the periarticular ligaments in the pathology and pathogenesis of advanced osteoarthritis of the hip in the human has been especially stressed by Lloyd Roberts (1953 and 1955)

The condition seen after 5–6 weeks of immobilization of the rabbit knee is regarded as a model of advanced disease suitable for studies on pathogenesis and treatment of the corresponding stage of human osteoarthritis

ACKNOWLEDGEMENTS

This study was supported by grants from the Sigrid Juselius Foundation and the Juho Vainio Foundation. We wish to express our gratitude to the Institute of Occupational Health for their help

REFERENCES

Bentley G (1974) Experimental osteoarthrosis. Normal and osteoarthrotic articular cartilage Ed Ali S Y Elves M W & Leaback D H pp 259–284 Kingswood Press England

Blount W P (1964) Osteotomy in the treatment of osteoarthritis of the hip *J Bone Jt Surg* 46-A 1297–1325

Byers, P D (1974) The effect of high femoral osteotomy on osteoarthritis of the hip *J Bone Jt Surg* 56-B 279–290

Detenbeck L C., Coventry M B & Kelly P J (1972) Intertrochanteric osteotomy for degenerative arthritis of the hip *Clin Orthop* 86, 73–78

Ely L. W & Mensor M C (1933) Studies on the immobilization of normal joints *Surg Gynec Obstet* 57, 212 215

Eronen I Videman T Friman, C & Michelsson J E. (1978) Glycosaminoglycan metabolism in experimental osteoarthrosis caused by immobilization *Acta orthop scand* 49, 329–334

Evans, E. B Eggers G W N Butler J K & Blumel J (1960) Experimental immobilization and remobilization of rat knee joints. *J Bone Jt Surg* 42 A 737–758

Ferguson A B (1971) The pathology of degenerative arthritis of the hip and the use of osteotomy in its treatment *Clin Orthop* 77, 84–97

Field F L & Hueston, J T (1970) Articular cartilage loss in longstanding immobilization of interphalangeal joints. *Brit J Plast Surg* 23, 186–191

Finsterbush A & Friedman B (1973) Early changes in immobilized rabbits knee joints A light and electron microscopic study *Clin Orthop* 92, 305 319

Finsterbush, A & Friedman B (1975) Reversibility of joint changes produced by immobilization in rabbits. *Clin Orthop* 111, 290–298

Hall M C (1963) Cartilage changes after experimental immobilization of the knee joint of the young rat *J Bone Jt Surg* 45-A 36–44

Hall, M C (1964) Articular changes in the knee of the adult rat after prolonged immobilization in extension *Clin Orthop* 34, 184 195

Heikel H V A (1959) On ossification and growth of certain bones of the rabbit with a comparison of the skeletal age in the rabbit and in man *Acta orthop scand* 39, 171–184

Hirsch C Goldie I R Ryba W (1972) Intertrochanteric osteotomy for osteoarthritis of the hip A radiological evaluation *Clin Orthop* 86, 63–67

Lloyd Roberts G C (1953) The role of capsular changes in osteoarthrosis of the hip joint *J Bone Jt Surg* 35 B 627 642

Llo

Luna, L G (Editor) (1968) *Manual of histologic staining methods of the Armed Forces Institute of Pathology* 3rd ed, pp 163–165 The Blakiston Division McGraw-Hill Book Company, New York, Toronto, London, Sydney

McManus, I F A & Mowry, R W (1964) *Staining methods histological and histochemical*, pp 63–64 Harpes & Row, New York, Evanston & London (A Hoeber International Reprint)

Michelsson, J-E, Videman, T & Langenskiöld, A (1977a) Changes in bone formation during immobilization and development of experimental osteoarthritis. A study using oxytetracycline in rabbits. *Acta orthop scand* 48, 443–449

Michelsson, J-E, Videman, T & Langenskiold, A (1977b) Contractures of the knee in provoking osteoarthritis in rabbits by immobilization *Int res comm syst Med Sci* 5, 61

Moskowitz, R W (1972) Experimental models of degenerative joint disease *Seminars in Arthritis and Rheumatism* 1, 95–116

Nissen, K. I (1963) The arrest of early primary osteoarthritis of the hip by osteotomy *Proc roy Soc Med* 56, 1051–1060

Nissen, K I (1971) The rationale of early osteotomy for idiopathic coxarthrosis (epichondro-osteoarthrosis of the hip) *Clin Orthop* 77, 98–104

Ottolenghi C E & Frigerio, E (1962) Intertrochanteric osteotomies in osteoarthritis of the hip *J Bone Jt Surg* 44-A, 855–895

Roy, S (1970) Ultrastructure of articular cartilage in experimental immobilization *Ann rheum Dis* 29, 634–642

Salenius, P, Langenskiold, A & Osterman, K (1971) Intertrochanteric displacement osteotomy in the treatment of osteoarthrosis of the hip Results of follow-up examination. *Acta orthop scand* 42, 63–77

Salter, R B & Field, P (1960) The effects of continuous compression on living articular cartilage An experimental investigation. *J Bone Jt Surg* 42-A, 31–49

Sokoloff, L (1974) The general pathology of osteoarthritis. *Normal and osteoarthritic articular cartilage*, Ed Ali, S Y, Elves, M W & Leaback, D H, pp 111–124 Kingswood Press, England

Sood, S C. (1971) A study of the effects of experimental immobilization on rabbit articular cartilage *J Anat (Lond)* 108, 497–507

Thaxter, T H Mann, R A & Anderson, C E (1965) Degeneration of immobilized knee joints in rats *histological and autoradiographic* study *J Bone Jt Surg* 47-A, 567–585

Thompson, R. C & Basset, C. A. L (19[illegible]) Histological observations on experimentally induced degeneration of articular cartilage *Bone Jt Surg* 52-A, 435–443

Trias, A (1961) Effect of persistent pressure the articular cartilage An experimental study *J Bone Jt Surg* 43-B, 376–386

Videman, T, Langenskiöld, A, Michelsson, J & Candolin, T (1977) A macroscopic and scanning electron microscopic study of experimental osteoarthritis of the knee *Int res comm syst Med Sci* 5, 232–233

Videman, T, Michelsson, J-E, Rauhamäki, R, Langenskiöld, A (1976) Changes in [illegible] teoarthritis. *Acta orthop scand* 47, [illegible]

Correspondence to Anders Langenskiold, M D, Mellstensvägen 17B (6 SF—02170 Esbo 17, Finla

Acta orthop scand 50, 15–19, 1979

TRYPSIN-INDUCED MITOSIS IN THE ARTICULAR CARTILAGE OF ADULT RABBITS

T HAVDRUP

Department of Orthopaedic Surgery,
Malmo General Hospital (University of Lund), Malmo, Sweden

Full-grown rabbits were injected in the knee joints with solutions of trypsin of various concentrations The animals were sacrificed 2 weeks after the trypsin injection Twenty-four hours before sacrifice they received 40 μCi ^{3}H-thymidine intra articularly The changes in the knee joints were then studied by histological and autoradiographical methods The injection of

of the cartilage The explanation put forward is that the mitosis of the chondrocytes may be the result of a decrease in the concentration of a growth controlling factor (chalone) initiated by the administration of trypsin

Key words trypsin, cartilage, mitosis, autoradiography, chalones

Accepted 19 vii 78

ble collapse of rabbit ears after intravenous administration of papain is due to the release of chondroitin sulphate from the protein-polysaccharide complex of the matrix (Thomas 1956, Spicer & Bryant 1957, Bryant et al 1958, Tsaltas 1958, McElligott & Potter 1960) Intravenous or intra-articular administration of papain results in degenerative and necrotic changes, somewhat similar to those seen in human osteoarthritis (Murray 1964, Bentley 1971, Farkas et al 1974, 1976, Havdrup & Telhag 1977) It has never been possible to demonstrate with certainty mitotic figures in normal adult joint cartilage (Crelin & Southwick 1960, 1964, Mankin 1963, 1964, 1968, Hulth et al 1970, Telhag 1972) Mitosis of the chondrocytes is induced in adult joint cartilage in association with the development of osteoarthritic changes (Crelin & Southwick 1960, 1964 Hulth et al 1970, Telhag 1972) When papain is administered intra articularly, the degenerative changes are accompanied by the appearance of mitosis of the chondrocytes (Havdrup & Telhag 1977) Papain solutions of decreasing concentrations result in progressively less degeneration of the cartilage, whereas the occurrence of mitosis remains high (Havdrup & Telhag, to be published)

In the present study trypsin, another proteolytic enzyme, is studied Trypsin, injected intravenously in rabbits, does not produce the same changes as seen after papain administration (Blumberg & Ogston 1957) Trypsin splits the peptide bonds which follow one or other of the two positively charged side-chains, i e lysine and arginine

Financial support was obtained from Ulla and Gustaf af Ugglas fond, Herman Jarnhardts stiftelse and Riksförbundet mot Reumatism

0001-6470/79/010015-05$02.50 0

© 1979 Munksgaard Copenhagen

The aim of the present investigation was to find out if trypsin, injected intra articularly, induces degenerative changes in adult joint cartilage and if it initiates mitosis of the chondrocytes

MATERIAL AND METHODS

The material consisted of 10 full grown rabbits with roentgenographically closed epiphyseal lines The rabbits were caged under normal conditions and given a normal diet The animals weighed 3600–5550 g (mean 4075 g) Solutions of trypsin (Trypure® Novo) in 0 9 per cent NaCl were prepared in the following concentrations 3750 E/ml 7500 E/ml, 15000 E/ml 30000 E/ml and 60000 E/ml Each concentration was used in two rabbits They were injected in the right knee joints with 0 2 ml of the trypsin solution. In all the animals the left knee joints were used as controls and were injected with 0 2 ml of 0 9 per cent NaCl The animals were killed 2 weeks after the injection of trypsin by an intravenous injection of Nembutal® (Abbot) Twenty-four hours before sacrifice 40 µCi of ^{3}H thymidine was injected into both knee joints No signs of infection were seen

The knee joints were dissected free and fixed in 10 per cent formalin solution The patella tibia and femur were dissected free and treated separately The tibia and femur were divided in the frontal plane into two halves with a circular saw The pieces were decalcified in 50 per cent formic acid and 20 per cent sodium citrate Afterwards the pieces were embedded in paraffin and cut into sections 5–7 µ thick The sections were stained with haematoxylin-eosin, according to van Gieson safranin O and toluidine Autoradiograms of routine histological sections were prepared from both knee joints according to the dipping method with Ilford K2 liquid emulsion The autoradiograms were exposed for 3 weeks after which they were developed in Gevaert X ray developer G 230 and fixed in Gevaert X-ray fixer G 305 The sections were then stained through the emulsion with Mayer s haematoxylin As a rule 10 12 autoradiograms from each knee joint were examined

RESULTS

The animals all survived the experimental period and none showed signs of infection of the knee joints. There were no signs of a generalized toxic reaction to the administered trypsin

Histological examination

None of the left control knee joints show signs of degeneration The staining properties the matrix were normal

After the injection of trypsin in the right kn joints, only sparse histological changes were se

3750 E/ml No changes in the histology could b seen Staining properties were normal.

7500 E/ml The cartilage seemed to be norm except for suspected fibrillation in one of th joints Slight proliferative changes in synovial m osteoblastic cells were seen at the margins T staining properties of the matrix were normal.

15000 E/ml One of the knee joints showed sig of degeneration with necrosis of chondrocyte fibrillation and cluster formation. At the jo margins there was proliferation of synovial ce and proliferation of osteoblasts. The cartilage o the other knee joint was normal Slight prol tion of synovial cells could be seen at the jo margins Osteoblastic activity was low Th staining properties of the matrix were normal i both knee joints

30000 E/ml The structure of the cartilage wa normal but some of the chondrocytes appeared t be swollen in comparison with norma chondrocytes and others showed signs of necros with fragmentation of the nucleus The proliferat tion of cells at the margins was still more pr nounced than mentioned above Osteoblas activity was seen at the joint margins Th staining properties of the matrix were normal.

60000 E/ml The cartilage showed no histologic signs of degeneration One of the knee joi showed the presence of a marginal osteoph Proliferation of synovial cells and osteoblas activity were seen at the joint margins.

Autoradiographical evaluation

None of the control knee joints showed sig ^{3}H thymidine labelling

In the knee joints injected with trypsin, labe chondrocytes were seen in all parts of the jo ce in the patella femur and tibia Seven of th ten knee joints studied showed ^{3}H thymidi labelled cells The knee joints showing no labelli belonged to the animals receiving dilutions co taining 3750 E/ml 30000 E/ml and 60000 E/m The labelled chondrocytes were distributed in th following manner

	Patella	Tibia	Femur	Total	Number of autoradiograms	Labelled cells/section
3750 E/ml	0	3	5	[illegible]	19	0 4
7500 E/ml	6	16	4	26	23	1 1
15000 E/ml	[illegible]	5	20	25	25	1 0
30000 E/ml	0	1	0	1	22	0 04
60000 E/ml	1	6	4	11	21	0 5

DISCUSSION

In order to study the metabolism and the treatment of osteoarthritis, it is very useful to have experimental models resulting in joint changes resembling those seen in human osteoarthritis.

Degenerative joint disease can be induced in many different ways, i e, mechanical, chemical, infectious, immunological and endocrinological (Gardner 1960) Many of these methods, however, result in changes resembling those seen in rheumatoid arthritis.

By making a joint unstable (Hulth et al. 1970, Telhag 1972), it has been possible to produce degenerative and reparative joint changes similar to those seen in osteoarthritis. When degenerative changes appear in the cartilage, the chondrocytes recover their ability to divide (Telhag 1972) Scarification of the articular cartilage of the patella in adult rabbits does not result in generalized degenerative changes of the cartilage The scarification, however, gives rise to scattered mitosis of the chondrocytes in all parts of the joint cartilage (Havdrup et al 1975)

After intra articular injection of concentrated papain solutions, extensive degenerative and necrotic changes of the joint cartilage appear In the remaining cartilage, single dividing chondrocytes can be seen (Havdrup & Telhag 1977) When weaker solutions of papain are injected, the degenerative and necrotic changes are not so prominent but, in spite of this, the number of dividing chondrocytes is higher

In the present investigation another proteolytic enzyme, trypsin, was used Only slight degenerative changes were found histologically in the articular cartilage Autoradiographically, mitosis of the chondrocytes was found after injection of trypsin in all the above-mentioned dilutions, and the greatest number of dividing cells were seen when the solution containing 15000 E/ml was used

When articular cartilage is damaged, the accompanying mitosis of the chondrocytes might be explained as an attempt to restore cartilage It is more difficult to explain why mitosis occurs when the degenerative changes are sparse or even absent If the theories of chalones are applied to this experiment, the findings can be explained Dormant tissue cultures have been stimulated to new growth by the addition of trypsin (Simms & Stillman 1937) This was suggested to be due to the elimination of an inhibitor to cell growth which had been produced by the cells themselves and was present in the culture medium A chalone has been defined as "an internal secretion produced by a tissue for the purpose of controlling by inhibition the mitotic activity of the cells of the same tissue" The existence of chalones in epidermis has been proved by Bullough & Laurence (1960), and later in other tissues by other workers (Saetren 1956, Mohr et al. 1968, Rytomaa & Kiviniemi 1969, Lasalvia et al 1970, Houck & Hennings 1973, Maharajan & Batra 1976 and Janakivedi et al 1976) When applied to joint cartilage, the chalone might be reduced in the joint cavity either by chemical (papain and trypsin) or mechanical (osteoarthritis and scarification) factors.

In earlier investigations it has been mentioned that chalone preparations are destroyed by the addition of trypsin solutions

(Boldingh & Laurence 1968, Lasalvia et al 1970, Houck et al 1973)

The present results do not, at least, contradict the theory of chalones applied to articular cartilage The histological findings are slight and the changes in one of the animals, belonging to the animals having received 15000 E/ml, can hardly be explained as due to the injection of trypsin The animals which have received more concentrated solutions of trypsin do not show corresponding changes Possibly the relatively grave changes were present even before the injection of trypsin One has to consider that the animals are old, and that "normally" occurring osteoarthritis can be present The appearance of dividing chondrocytes can be regarded as an effect of chalone reduction due to trypsin digestion Why peak mitosis occurs with a trypsin concentration of 15000 E/ml is difficult to explain One explanation is that in the groups of animals receiving the 30000 and the 60000 E/ml trypsin solutions, respectively, only one of the animals in each group showed mitosis of cartilage The number of labelled cells/section must then be diminished

REFERENCES

entley G (1971) Papain-induced degenerative arthritis of the hip in rabbits *J Bone Jt Surg* 53-B 324–337

Blumberg B S & Ogston A G (1957) The effects of proteolytic enzymes on the hyaluronic acid complex of the ox synovial fluid *Biochem J* 66, 342–346

Boldingh W H & Laurence, E B (1968) Extraction purification and preliminary characterisation of the epidermal chalone A tissue specific inhibitor obtained from vertebrate skin *Europ J Biochem* 5, 191–198

Bryant J H, Leder, I G & DeWitt Stetten, Jr (1958) The release of chondroitin sulfate from rabbit cartilage following the intravenous injection of crude papain *Arch Biochem* 76, 122–130

Bullough W S & Laurence E B (1960) The control of epidermal mitotic activity in the mouse *Proc roy Soc B* 151, 517–536

Crelin, E. S & Southwick W O (1960) Mitosis of chondrocytes induced in the knee joint articular cartilage of adult rabbits *Yale J Biol Med* 33, 243–244

Crelin E S & Southwick W O (1964) Changes induced by sustained pressure in the knee joint articular cartilage of adult rabbits *Anat Rec* 149, 113–133

Farkas, T, Bihari-Varga, M & Biró, T (19 Thermoanalytical and histological study of intra-articular papain-induced degradation and repair of rabbit cartilage I Immature animals *Ann rheum Dis* 33, 385–390

Farkas, T, Bihari-Varga, M & Biró T (19 Thermoanalytical and histological study of intra articular papain induced degradation and repair of rabbit cartilage II Mature animals *Ann rheum Dis* 35, 23–26

Gardner, D L (1960) The experimental production of arthritis *Ann rheum Dis* 19 297–317

Havdrup, T, Hulth A & Telhag H (19 Scattered mitosis in mature joint cartilage in rabbits after local trauma *Clin Orthop* 113 246–248

Havdrup T & Telhag H (1977) Papain-induced changes in the knee joints of adult rabbits *Acta orthop scand* 48, 143–149

Houck, J C & Hennings H (1973) Chalones Specific endogenous mitotic inhibitors *FEBS Lett* 32, 1–8

Hulth, A, Lindberg L & Telhag H (19 Experimental osteoarthritis in rabbits *Acta orthop scand* 41, 522–530

Janakivedi, K, Thomas W A, Florentin, R A, Reiner, J M & Lee, K T (1976) Inhibition of ³H-thymidine incorporation into aortic DNA of rats injected with extracts "chalone" prepared from aortic intima media *Fed Proc* 35, 2

Lasalvia E, Garcia-Giralt E & Maciera-Coelho A (1970) Extraction of an inhibitor of DNA synthesis from human peripheral blood lymphocytes and bovine spleen *Rev Eur Etud Clin Biol* 15, 789–792

Mankin H J (1963) Localization of tritiated thymidine in articular cartilage of rabbits I Mature articular cartilage *J Bone Jt Surg* 45-A, 529–540

Mankin, H J (1964) Mitosis in articular cartilage of immature rabbits A histologic study [illegible] aging [illegible] *Med* 4 545–552

Maharajan, V & Batra B K (1976) Chalone possible probe for embryonic differentiation *Indian J Exp Biol* 14, 324–325

McElligott, T F & Potter, J L (1960) Increased

fixation of sulphur[35] by cartilage in vitro following depletion of the matrix by intravenous papain *J exp Med* **112**, 743–750

Mohr U., Althoff J Kinzel B Suss. B & Volm M (1968) Melanoma regression induced by "chalone" a new tumour inhibiting principle acting in vivo *Nature (Lond)* **220**, 138–139

Murray D G (1964) Experimentally induced arthritis using intra articular papain *Arthr and Rheum* **7**, 211–219

Rytomaa T & Kiviniemi K (1969) Chloroma regression induced by the granulocytic chalone *Nature (Lond)* **222**, 995–996

Saetren H (1956) A principle of auto-regulation of growth Production of organ specific mitose-inhibitors in kidney and liver *Exp Cell Res* **11**, 229 232

Simms, H S & Stillman N P (1937) Substances affecting adult tissue in vitro I The stimulating action of trypsin on fresh adult tissue *J gen Physiol* **20**, 603 619

Spicer S S & Bryant J H (1957) Cartilage changes in papain treated rabbits. *Amer J Path* **33**, 1237–1244

Telhag H & Lindberg L (1972) A method for inducing osteoarthritic changes in rabbits knees. *Clin Orthop* **86**, 214 223

Telhag H (1972) Mitosis of chondrocytes in experimental osteoarthritis in rabbits. *Clin Orthop* **86**, 224–229

Thomas, L. (1956) Reversible collapse of rabbit ears after intravenous papain and prevention of recovery by cortisone *J exp Med* **104**, 245–251

Tsaltas, T T (1958) Papain induced changes in rabbit cartilage *J exp Med* **108**, 507 513

Correspondence to T Havdrup Department of Orthopaedic Surgery General Hospital S 214 01 Malmo Sweden.

Acta orthop scand 50, 21–26 1979

REPAIR OF BONE DEFECTS BY BONE INDUCTIVE MATERIAL

JORMA OIKARINEN & L. KALEVI KORHONEN

Department of Anatomy, University of Oulu, Finland

Experimental fibular defects in 16 rats were filled with an acid decalcified homogenous bone matrix (bone inductive material) Autogenous bone grafts in corresponding defects in the other legs of the same rats served as controls After 3 months, 11 of the 16 defects filled with bone inductive material healed with bony union, but only 4 of the 16 defects treated with autogenous bone grafts had healed The results suggest that bone inductive material can repair bone defects which are too large to be healed by autogenous bone grafts.

Key words bone, bone induction, bone transplants, fractures

Accepted 5 x 78

Major bone defects represent a difficult problem in orthopaedic surgery A fresh graft of autogenous cancellous bone with haemopoietic bone marrow is generally considered to be the most effective treatment in these cases. The clinical application of such grafts, however, is limited A better method would be to use some more readily available material Several authors have therefore studied bone induction, and promising results have been published regarding the bone inductive capacity of decalcified bone matrix (e g Bang 1973, Büring & Urist 1967, Summons et al 1974, Urist & Strates 1971) In spite of high success rates in the induction of new ectopic bone in animal experiments, decalcified bone matrix in the treatment of major bone defects has been used clinically only on a few occasions (Boyne 1973)

In this study, we compared the repair of experimental bone defects in rats by decalcified bone matrix (bone inductive material) with repair by autogenous fresh bone grafts. The results suggest that bone inductive material can repair bone defects which are too extensive to benefit from autogenous bone grafts used under experimental conditions

MATERIAL AND METHODS

Preparation of the bone inductive material (BIM)

Long bones from adult rats of a Long Evans strain were collected periosteum and bone marrow tissue were mechanically removed and the bone pieces were washed in distilled water The bones were then dehydrated in three changes of absolute ethanol over a period of 3 hours, and fat was extracted by a 1 hour bath in diethyl ether Subsequently the bone pieces were again washed in ethanol, and transferred through an alcohol gradient down to distilled water The washed bone tissue was then demineralized by incubating in 0 6 N HCl at +4°C for 4½ hours, using 25 mMol HCl/g of bone tissue After decalcification, pieces of organic matrix were washed several times in distilled water (approximately six times for 5 minutes each) until the washing water remained neutral The material was freeze-dried and stored in sterile tubes at −20°C. This material is called bone inductive material (BIM) in this paper

0001-6470/79/010021-06$02.50/0

c 1979 Munksgaard, Copenhagen

Testing the bone inductive capacity

The bone inductive material was divided into small pieces which were compressed to form small cylinders in a device made from a tuberculin syringe Cylinders of 0 05 cm^3 were implanted into pouches under the fascia of the latissimus dorsi muscle of adult rats Cylinders of cellulose fibre sheets of the same size were implanted in the opposite side of the same animals as controls Wounds were closed with silk sutures Implants were removed after 1 2 3, 4 and 6 weeks fixed in neutral formalin decalcified if necessary embedded in paraffin and sections of 5 µm were stained by the Weigert – van Giesson method For histochemical demonstration frozen sections were prepared from fixed samples and stained for the demonstration of alkaline and acid phosphatase activity (Pearse 1968)

Testing the capacity to repair bone defects

Sixteen Long Evans rats (150–200 g) served as experimental animals The operations were performed under open ether anaesthesia The instruments were kept sterilized during the operation with ethanol and flaming and the skin over the site of the operation was cleaned with an ethanol-ether mixture The skin over the lateral side of the left leg was opened and the fibula freed from adjacent tissues by blunt dissection A 2 mm section was removed and the defect in the fibula was filled by a piece of BIM of the same size and shape The muscles were closed with a single catgut suture and the skin with silk sutures No additional measures were taken in order to fix the transplants As a control a similar operation was performed on the right legs of the same rats but the periosteum was scraped off the pieces removed from the fibulas and these were returned to their original positions between the cut ends of the fibulas The wounds healed *per primam intentionem*

Evaluation of the repair

Evaluation of the repair of the bone defects was performed in all cases by macroscopic inspection and by histological examination of microscopic preparations. In addition an X ray examination was performed in a group of eight rats on the 45th and 90th postoperative days. Tetracycline labelling was used in another group of eight rats as follows

Tetracycline hydrochloride (Achromycin® Lederle) or oxytetracycline (Terramycin® Pfizer) 100 mg/kg were given i v on the 10th 60th and 75th days after the operation The animals were killed on the 90th postoperative day the bones removed and embedded in Epon by a routine method The Epon blocks were split longitudinally with a dentist s circular saw so that the fibulas were divided into two parts The cut surfaces were examined and photographed using an incident fluorescent outfit Ploem (Leitz Gmbh) with an HBO 200 lamp and GB 12 and K 54 filters in a Leitz Orthoplan microscope The lines of the two tetracyclines could be distinguished from each other because of their different fluorescent tone

RESULTS

Bone inductive capacity

The homogenous bone inductive material (BIM) implanted beneath the latissimus dorsi muscle of rats was surrounded with a fibrous connective tissue capsule and after 1 week small islands of hyaline cartilage could occasionally be observed between the pieces of BIM Connective tissue cells and blood vessels proliferated and invaded the implanted material filling the canals in the BIM After 2 weeks hyaline cartilage was present in abundance in all samples, and islands of ossifying tissue could be observed (Figure 1) After 6 weeks bone marrow with haemopoetic islands was seen Alkaline phosphatase activity estimated by histo-

Figure 1 Newly formed cartilage (Ca) and bone (Nb) with osteoblast lining (arrow) on a decalcified bone matrix (Db) after 3 weeks in rat dorsi muscle No signs of rejection are seen.

chemical staining reaction, increased during the first 4 weeks, and declined thereafter The activity was observed in certain cell groups on the surface of the pieces of BIM, these cells were regarded as young osteoblasts. Acid phosphatase activity followed the same pattern, but was confined to the giant cells in the areas of bone resorption

In some areas of the samples a mild leucocytic infiltration was observed, as well as some foreign-body giant cells, but signs of more extensive inflammatory reactions were absent and no rejection reaction occurred

In control experiments, where cylinders of cellulose fibres were implanted, only a granulomatotic foreign-body reaction was observed No cartilage or bone formation could be found either macroscopically or microscopically

Repair of bone defects

The results of the experiment of the repair of fibular defects by BIM are given in Table 1 and illustrated in Figures 2–5 All but one of the 16 defects treated with BIM showed abundant callus formation, and in 11 cases bony union was present Five cases in the experimental groups showed incomplete healing without a continuous bone bridge across the area of defect, although abundant cartilaginous and fibrous calli were present in three cases In two cases of the experimental group the healing was unsatisfactory with only fibrous tissue in the area of the bone defect and extensive lysis of the BIM graft In one case the healing was so complete that the fibula was remodelled to the normal appearance, and most of the healed fibulas showed a continuous marrow cavity 90 days after the operation

On the control side where the defects were filled with fresh allogenous bone grafts without periosteum, four of the sixteen defects healed with a continuous bony bridge In these cases, the calli were small in size and the bone remodelled to its normal shape The allogeneic bone graft could still be seen with deposits of new bone on its surface In five cases, fibrous and cartilaginous calli formed pseudoarthrotic unions even with a cavity lined with cartilage and resembling a real joint cavity in some cases. In seven cases, the allogeneic graft had undergone extensive lysis and only fibrous tissue was left in place of the bone defect

Signs of more extensive inflammatory reactions or any signs of rejection were not observed in the defects filled with BIM or allogeneic bone grafts.

Table 1 Repair of fibular defects by bone inductive material or autogenous bone grafts

Result of experiment	Bone defect filled with bone inductive material	Bone defect filled with autogenous bone graft	Total
Healed with bony union	11	4	15
Not healed	5	12	17
Total	16	16	

Experimental fibular defects in the right legs of 16 rats were filled with acid decalcified homogenous bone matrix (bone inductive material) and correspondi[illegible] autogenous [illegible] tion of the [illegible] with bony [illegible] ($P \leq 0.026$ X^2 test)



Figure 2 A pseudoarthrosis in a rat fibula repaired 3 months previously with an autogenous bone graft The tetracycline fluorescence lines are clearly visible in the calcified tissue

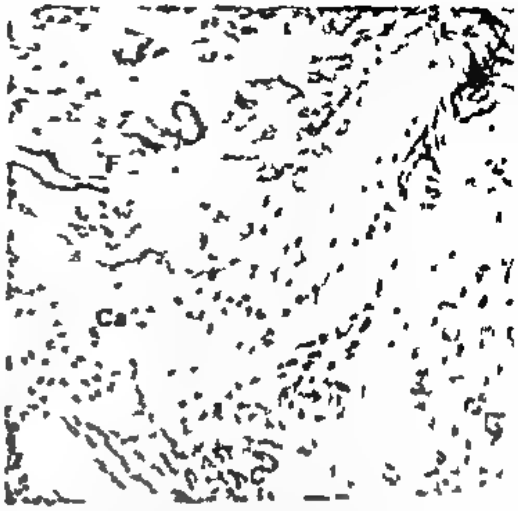

Figure 4 The same bone as in Figure 3 incomplete cartilaginous bridge (Ca) is between the fibula (F) and the callus (C) in control side (autogenous graft)

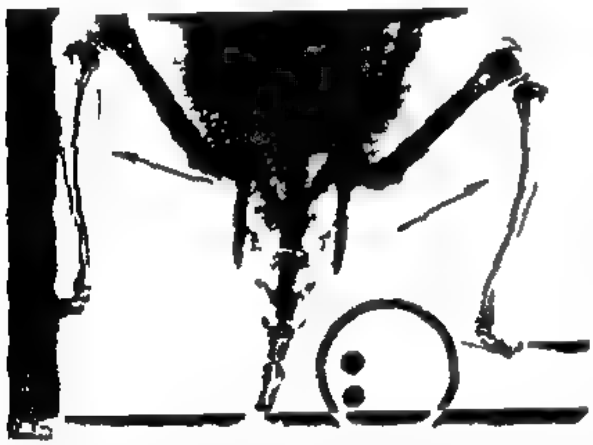

Figure 3 A X-ray of a rat 90 days after the operation On the right (marked) side repaired with an autogenous bone graft a pseudoarthrosis is seen On the contralateral side the callus is angulated but continuous calcification is present

Figure 5 Callus formation in the fibula repaired with bone inductive material Remnants of material (Db) are still seen in the middle of callus (C) (F) fibula

DISCUSSION

The unanimous opinion is that fresh allogenous bone, preferably with cancellous bone and marrow tissue, is the best material for bone grafts. This has been proved both by clinical experience and in numerous experiments (e g Boyne 1973, Puranen 1966) Even freshly frozen material stored in deep freezers (bank bone) is less satisfactory Two phases in the formation of new bone are observed when fresh bone grafts are used (Axhausen 1956) The early phase during the first weeks may be due to the activity of surviving cells in the graft, and the late phase beginning within 4 to 8 weeks after transplantation, is supposed to be accomplished by cells derived from the host tissue (Chalmers 1959, Puranen 1966 Fives & Pratt 1967)

When grafts of living bone are used surviving transplant cells may participate in the formation of new bone tissue The immune response can cut short the activity of transplanted cells if the material used

identified as foreign The immune response against bone tissue, however, is generally mild, and practically absent if grafts are frozen before the transplantation (Heiple et al 1963)

The results obtained during the present experiment confirmed the osteoinductive capacity of an acid decalcified homogenous bone matrix. The method of BIM preparation destroys its antigenity, so that rejection did not occur even with heterogenous BIM transplants in a series of preliminary experiments. These observations agree with the extensive studies of Urist & Strates (1971) and Iwata & Urist (1972) The bone inductive capacity of BIM is believed to reside in the organic matrix and requires the immediate contact of host cells with the inductive material (Urist & Strates 1971) Progenitor cells which are capable of being transformed into chondroblasts and osteoblasts are blood borne or derived from the connective tissues and blood vessels of the granulation tissue which rapidly grows and invades the transplanted material (Friedenstein 1973)

Boyne (1973) obtained good results when he repaired an artificial defect in the mandibles of Rhesus monkeys with surface decalcified bone, and also reported promising results when this method was used in patients Jonck (1975) observed that when a bone defect was filled with undecalcified bone shavings, decalcination took place with the formation of new bone These observations together with the extensive studies of Urist & Strates (1971) suggest that the bone inductive capacity resides in the organic matrix of bone and that calcium has to be removed before the inductive material can work

In the present experiment, BIM was more effective in repairing bone defects than autogenous fresh bone transplants This may be because the periosteum was removed from the living bone transplants thus slowing down the first rapid phase of production of the new bone Furthermore, the response to the BIM is species dependent and in rats BIM works efficiently (Urist & Craven 1970)

The results obtained during this investigation suggest that the problem of seeking suitable material for bone grafting still requires further experimentation Although it is very likely that autogenous grafts are superior to all other means, it may be possible to also obtain other materials which give comparable or at least satisfactory results clinically in selected cases.

REFERENCES

Axhausen, W (1956) The osteogenetic phases of regeneration of bone *J Bone Jt Surg* 38-A, 593–600

Bang, G (1973) Induction of heterotopic bone formation by demineralized dentin in guinea pigs. *Acta path microbiol scand* (Sect A) Suppl 236, 60–70

Boyne, P J (1973) Induction of bone repair by various bone grafting materials *Hard tissue growth, repair and remineralization*, Ciba Foundation Symposium 11, pp 121–141, Assoc Scient Publ, Amsterdam

Buring, K & Urist, M R (1967) Transfilter bone induction *Clin Orthop* 54, 235–242

Chalmers, J (1959) Transplantation immunity in bone homografting *J Bone Jt Surg* 41-B, 160–179

Elves, M W & Pratt, L M (1975) The pattern of new bone formation in isografts of bone *Acta orthop scand* 46, 549–560

Friedenstein, A J (1973) Determined and inducible osteogenic precursor cells. *Hard tissue growth, repair and remineralization*, Ciba Foundation Symposium 11, pp 169–185, Assoc Scient Publ, Amsterdam.

Heiple, K G, Chase W W & Herndon, C H (1963) A comparative study of the healing process following different types of bone transplantation *J Bone Jt Surg* 45-A, 1593–1616

Iwata, H & Urist M. R. (1972) Protein polysaccharide of bone morphogenetic matrix *Clin. Orthop* 87, 257–274

Jonck, L M (1975) Bone induction effect of fine bone shavings in polyester fibre. *S Afr med J* 49, 697–702.

Pearse, A G E (1968) *Histochemistry Theoretical and applied* J & A. Churchill Ltd, London.

Puranen, J (1966) Reorganization of fresh and preserved bone transplants. *Acta orthop scand*, Suppl. 92, 1–75

Simmons D J, Sherman N E & Lesker, P A (1974) Allograft induced osteoinduction in rats A circadian rhythm *Clin Orthop* **103**, 252–261

Urist, M R & Strates B S (1971) Bone morphogenetic protein *J dent Res* 50 Suppl 1392–1406

Urist M R & Craven, P I (1970) Bone differentiation in avian species *Fed Proc* 2 1680–1693

Correspondence to Prof L Kalevi Korhonen, M D, Department of Anatomy Kajaanintie 5 SF 90220 Oulu 25 Finland

ta orthop scand 50 27–31, 1979

TUMORAL CALCINOSIS IN A PATIENT UNDERGOING HEMODIALYSIS

ATSUMI SUZUKI*, SADAO TAKAHASHI†, KENZO ITO†, OICHI TANAKA† & YOSHINORI SEZAI†

Department of Orthopaedic Surgery, School of Medicine, University of Occupational and nvironmental Health, Yawatanishiku, Kitakyushu City, and †Section of Orthopaedic Surgery, Kanto-osai Hospital, Nakaharaku, Kawasaki City, Japan.

Recently, tumoral calcinosis was found in a patient who had been undergoing haemodialysis in this hospital The tumor was partially removed and subsequently regressed The tumoral calcinosis of hemodialysis patients seems to be different from classical tumoral calcinosis.

Key words calcium phosphate, hemodialysis, hypercalcemia, hyperphosphatemia, surgical excision, tumoral calcinosis

Accepted 12.vi 78

umoral calcinosis is a rare condition which vas first reported by Inclan in 1943

Of the 50 patients who have been dialyzed n this hospital, extraskeletal calcifications vere found in only two one was a metastatic alcification from a complication of secondary yperparathyroidism and the other was the ase reported here

ASE REPORT

n January 1976, a tumor was discovered in the ft cubital region of a 37-year-old male suffering om chronic renal failure, who had been undergoig hemodialysis twice a week since November 974 Before the tumor was found, the patient had ad repeated subcutaneous bleeding whenever the emodialysis was performed through an inner hunt made in his left cubital region

Prior to December 1976, the calcium content of e dialyzate was 3 5 mEq/l and of acetate 35 1Eq/1, thereafter, the calcium content was educed to 2.5 mEq/l.

The tumor grew gradually larger and finally restricted the movement of his left elbow joint The patient was admitted to our hospital on January 6, 1977 The tumor became as large as his fist It was elastic and tender on palpation and was not attached to the covering skin The range of movement in the affected elbow joint was from −20 degrees extension to 100 degrees flexion and showed full pronation-supination (Figure 1)

The patient's blood was anemic and his blood chemistry showed increased urea-N, increased creatinine and decreased chlorine and sodium (Table 1)

An X-ray of the patient's left elbow showed a large tumoral calcinosis which was extraskeletal and appeared to consist of many lobules of dense material (Figure 2)

On January 10, 1977, surgical excision was attempted The tumor was found to consist of multiple lobules which contained a milky sand like substance It was attached to the deep muscles and partially to the anterior capsule of the elbow joint Complete excision could not be achieved technically A postoperative X-ray of the patient's left elbow showed the dense tumor, largely unchanged

001-6470 79/010027-05$02 50/0

© 1979 Munksgaard Copenhagen

Figure 1 Large tumor at the elbow (January 6, 1977)

Figure 2 X-ray of the left elbow (January 1977)

Table 1 Blood study (January 6, 1977)

R B C 310 × 10⁴/mm³	T p	7 2 g/dl
W B C 7600/mm³	G O T	23 u
Ht 30%	G P T	11 u
Hb 8 8 g/dl	Al. ptase	5 9 u (K. A.)

	Before dialysis	After dialysis
Urea-N (mg/dl)	88	52
Creatinine (mg/dl)	20 1	12.0
Na (mEq/l)	134	134
K (mEq/l)	5 0	3 7
Cl (mEq/l)	97	94
Uric acid (mg/dl)	9 6	5 0

Figure 3 A new calcification in the right kn

Figure 4 Histological findings

Figure 5 Histological findings

Other new extraskeletal calcinoses were detected in the right hip and left knee of the same patient (*Figure 3*) However no calcifications of the cornea skin, blood vessels or kidneys were detected

From histological studies the walls of the tubules were found to consist of thick fibrous tissue which was calcified and contained some foreign body giant cells, foam cells and small round cells (Figures 4 and 5)

By infrared absorption spectrum analysis and the X-ray diffraction techniques, the excised calcium was proved to be composed of calcium phosphate (*Figure 6*)

An X ray in *July 1977* showed that the calcified deposits were disappearing (*Figure 7*) The patient's left elbow joint regained a full range of motion.

DISCUSSION

Tumoral calcinosis was first reported by Inclan in 1943 and has since appeared in the literature from all parts of the world (Baldursson et al 1969 Harkess & Peters 1967, Leape 1975 Morohashi et al 1972 Sammarco & Makley 1973 Slavin et al. 1973 Thompson & Tanner 1949 Tominaga & Isobe 1974 and Ueyama et al 1971)

In the case reported here hypercalcemia and hyperphosphatemia were always present and the calcium to-phosphorus product was recorded as high However his alkaline phosphatase was always normal. There was no sub-periosteal erosion and no osteopenia On the other hand, corneal dermal vascular and renal calcification were not detected Therefore a secondary hyperparathyroidism was excluded in this case

In healthy adults, the product of serum calcium and serum phosphorus contents, in mg/dl ranges from 25 to 45 In cases of chronic renal failure the serum phosphorus

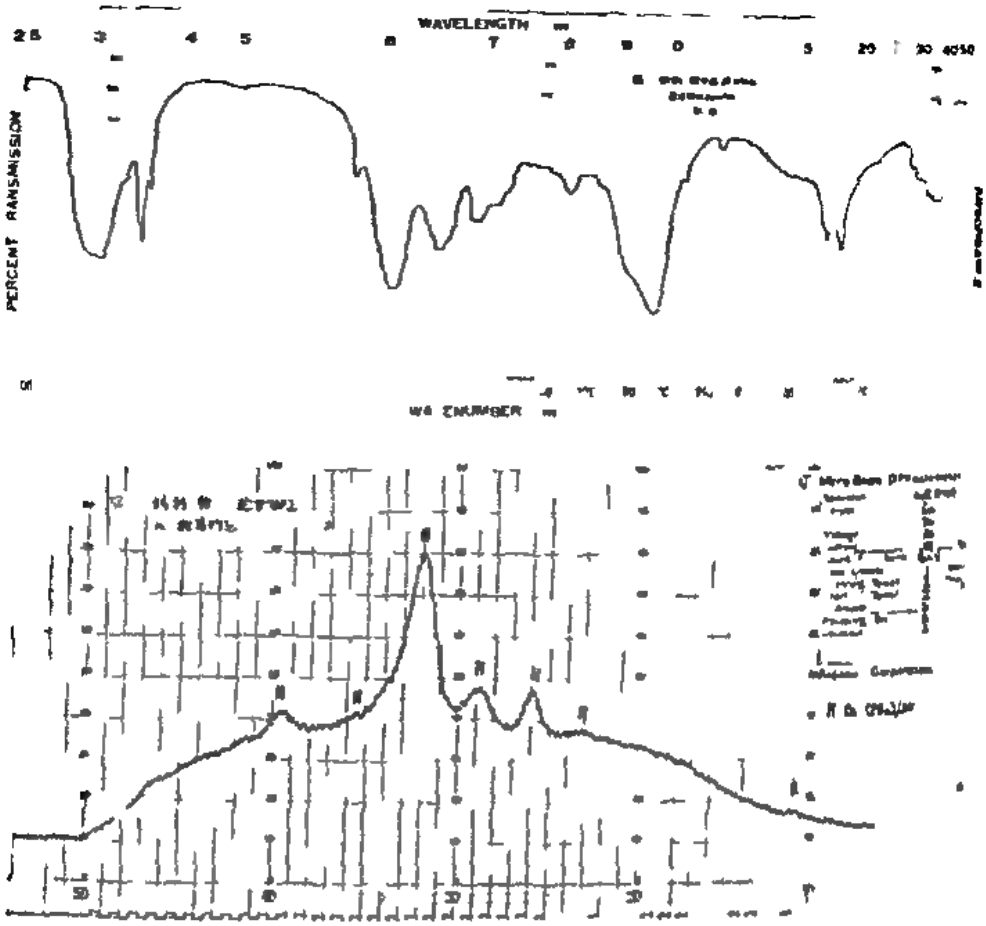

Figure 6 Data from infrared absorption spectrum analysis and the X ray diffraction techn que

Table 2 Differences between classical tumoral calcinosis and tumoral calcinosis in hemo patients

	Classical tumoral calcinosis	Tumoral calcinosis in hemodialysis patients
Age distribution	3–60 years (average 16 7)	35 46 years (average 4
Male/Female	15/9	3 2
Normal serum Ca	6/9 (66 7%)	None
Hypercalcemia	3/9 (33 3%)	3/4 (75%)
Normal serum P	6/12 (50%)	None
Hyperphosphatemia	6/12 (50%)	4 4 (100%)
Normal Al Ptase	8/11 (72.7%)	2 3 (66.7%)
Multiple/Solitary	6/13	2 3
Osteopenia	None	1 5
Renal failure	None	5 5 (100%)
Hemodialyzing period	None	3 months 6 years
Constituent	All calcium phosphate	4/5 calcium phosphate
Spontaneous remission	May be	May be

igure 7 X-ray of the left elbow (July 1977) howing regression of the tumor

ases, while the serum calcium may drop Akaoka et al 1977, Hou et al 1976, Johnson t al 1967 and Jowsey 1977) When the alcium-to-phosphorus product is greater han 45 mg/dl, calcium phosphate precipitates n the soft tissues (Jowsey 1977)

Recently, hemodialysis for chronic renal ailure has become widespread Tumoral alcinoses of hemodialysis patients (Akaoka et l 1977, Hou et al 1976, Johnson et al 1967 nd Jowsey 1977) seems to be different from lassical tumoral calcinoses as defined by Darkness (1967) In Table 2 the main lifferences between classical tumoral alcinosis and that following hemodialysis, as eported in the literature, are shown These nusual tumoral calcinoses may increase in he future

Although spontaneous disappearance of the umor had also been reported, revising the prescription for the dialyzate and surgical excision of the tumor may be necessary However, a complete excision is a difficult procedure

REFERENCES

Akaoka, K, Terayama, K. & Watanabe, S (1977) Tumoral calcinosis at the shoulder in a hemodialyzing patient *Kanto Seisai Shi* **8**, 12–17

Baldursson, H, Evans, E B, Dodge W F & Jackson, W T (1969) Tumoral calcinosis with hyperphosphatemia *J Bone J Surg* **51-A**, 913–924

Harkess, J W & Peters, H J (1967) Tumoral calcinosis *J Bone J Surg* **49-A**, 721–731

Hou, K, Kaneda, H, Haruyama, T & Tabata, S (1976) Large metastatic calcification in a hemodialyzing patient *Bone Metabolism* **9**, 52–55

Inclan, A (1943) Tumoral calcinosis *J Amer med Ass* **121**, 490–495

Johnson, C, Graham, C B & Curtis, F K. H (1967) Roentgenographic manifestations of chronic renal disease treated by periodic hemodialysis *Amer J Roentgenol* **101**, 915–926

Jowsey, J (1977) *Metabolic diseases of bone* pp 243–244 and 282 W B Saunders Co, Philadelphia

Leape, L L (1975) Calcification of the leg after calcium infusion *J Pediat Surg* **10**, 831–834

Morohashi, M, Ito, H, Kikuchi S & Miyamoto, F (1972) A case of tumoral calcinosis *Tohoku Seikei Saigai Geka Kiyo* **15**, 229–235

Sammarco, G J & Makley, J T (1973) Tumoral calcinosis and mongolism *Clin Orthop* **91**, 164–168

Slavin, G, Klenerman, L, Darby, A & Bansal, S (1973) Tumoral calcinosis in England *Brit med J* **20**, 147–149

Thompson J E M & Tanner, F H (1949) Tumoral calcinosis. *J Bone J Surg* **31-A**, 132–140

Tomitaga, S & Isobe, T (1974) On tumoral calcinosis. *Rinsho Seikei Geka* **9**, 787 791

Ueyama, H, Ipichi, M & Abe, M (1971) A case of tumoral calcinosis. *Kanto Sei Sai Shi* **2**, 33–36

Correspondence to Katsumi Suzuki, M D Department of Orthopaedic Surgery, School of Medicine, University of Occupational and Environmental Health, Honjo, Yawatanishiku, Kitakyushu City, 807 Japan

Acta orthop scand. 50 33 38 1979

MYOSITIS OSSIFICANS PROGRESSIVA

Clinical and Metabolical Observations in a Case Treated with a Diphosphonate (EHDP) and Surgical Removal of Ectopic Bone

H HOLMSEN* S LJUNGHALL† & T HIERTON*

Departments of Orthopedic Surgery* and Internal Medicine† University Hospital, Uppsala Sweden

A 20-year-old woman with a severely crippling myositis ossificans progressiva was treated with a diphosphonate (EHDP) 10–20 mg/kg/day While being treated with this drug surgical removal of ectopic bone was performed Although ectopic calcification recurred postoperatively considerable functional improvement was achieved At the highest dosage of EHDP hypercalcaemia gradually appeared but was reversible upon cessation of drug treatment. It is probably related to a direct effect of EHDP on the bone

Key words diphosphonate (EHDP) metabolism myositis ossificans progessiva surgery

Accepted 8 viii 78

Myositis ossificans progressiva (MOP) is a rare disorder characterized by ectopic ossification occurring mainly in the connective tissue of muscle and joints Calcification appears spontaneously or after trauma and certain infections. Widespread involvement produces a crippling illness in young people Skeletal abnormalities particularly of the toes and fingers, are also part of the clinical picture Hereditary factors are probably involved but the mode of inheritance has not been established Blood chemistry is normal and calcium balance studies are generally unremarkable (Smith et al 1976)

Many therapeutic regimens have been tried and advocated including cortisone (Eaton et al. 1957) ACTH (Dixon et al. 1954) or measures to prevent mineralization such as the use of calcium chelating agents or dietary restriction of calcium (Davis & Moe 1959) None have however been effective until the recent use of diphosphonate in several patients (Geho & Whiteside 1973) These compounds among which the most widely used is disodium ethane 1 hydroxy 1,1 diphosphonate (EHDP) prevent the formation and dissolution of apatite crystals *in vitro* In experimental animals they prevent both ectopic calcification (Fleisch et al 1970) and excessive bone resorption and turnover (Gasser et al 1972) In patients with MOP therapy with EHDP has been used to prevent mineralization of areas of active myositis (Bassett et al 1969 Weiss et al 1971 Schnakenburg et al 1972 Smith et al 1976) or to prevent recurrence after surgical removal of established ectopic bone (Russel et al 1972) The exact mechanism of their action is not known and it is possible that they may have an additional important effect on bone cells either directly or indirectly by reducing their activity The main side effects observed in a few patients, have been an inhibition of normal bone mineralization pre-

ISSN 0001 6470/79 010033 06$02.50 0

© 1979 Munksgaard, Copenhagen

Table 1 Biochemical findings before, during and after therapy with EHDP in a case of myositis ossificans progressiva (normal ranges within parentheses)

	Before therapy	On therapy 2 months	6 months	12 months	After therapy
Serum calcium mmol/l (2.20–2.60)	2.55	2.50	2.45	2.80	2.55
Serum phosphate, mmol/l (0.76–1.44)	0.9	1.4	1.4	2.1	1.4
Serum alkaline phosphatase, µkat/l (0.8–4.8)	3.3	3.3	4.1	5.1	3.3
Urinary calcium, mmol/24 h (0.6–5.0)	1.5	3.0	3.0	1.5	
Urinary hydroxyproline mg/24 h (6–22)	30	13	33		
Fractional intestinal calcium absorption, % (35–65)	85	50			
Serum parathyroid hormone, ng/ml	2.3			1.8	
Dose of EHDP, mg/kg/day	—	10	10	20	

of calcium, phosphate, alkaline phosphatase and creatinine were all within the normal range as were determinations of parathyroid hormone and calcitonin (*Table 1*) The urinary excretion of calcium was at the lower end of the normal range Measurement of the intestinal calcium absorption, using an isotope technique (Ljunghall et al 1977), indicated a [illegible]

urinary

free die

(Procter and Gamble Company) was started with an initial dosage of 10 mg/kg/day On this dose there was a significant increase in the serum phosphate concentration, while the serum calcium and alkaline phosphatase remained constant The intestinal calcium absorption was reduced and the urinary calcium increased (Table 1).

The aim of our treatment was primarily to reduce the fixed deformity of both hip joints and if possible make the patient able to stand and to walk. EHDP was given in an attempt to suppress recalcification and make a surgical removal of ectopic bone worthwhile

After 2 months of uneventful drug treatment surgical removal of ectopic bone around the hips was performed Postoperatively the patient experienced markedly increased mobility and 3 weeks after the last operation done on the left hip joint the maximum range of movement was 25 degrees in the right and 40 degrees in the left hip joint and she was mobilized with crutches. After another 2 months, however, progressive limitation of hip mobility occurred X ray showed reappearance of calcification which gradually became as dense as before in spite of an increasing dosage of EHDP (Figure 3)

One year after institution of the therapy both restriction of the movement of both knee joints was noticed and the right ankle joint was ankylotic. However, the patient was still able to stand and to walk some 50 meters with the use of two sticks.

When the EHDP dosage was increased, the serum phosphate rose further and the serum calcium concentration also increased up to frank hypercalcaemia (Table 1) When therapy was stopped the serum calcium was 2.8 mmol/l but 2 weeks later both the serum calcium and phosphate concentration had returned to the pretreatment levels

DISCUSSION

The first studies concerning the effects of EHDP in MOP reported considerable improvement in most of the patients, particularly as regards prevention of

(A)

(B)

Figure 3 Radiographs of the right hip joint (A) 2 weeks after excision of ectopic bone bridge (B) 2 years postoperatively there is reappearance of ectopic bone

recurrence of ectopic bone after surgery positive attitude towards operative corrections followed Now more experience has been accumulated and it appears that probably only about half of all MOP patients benefit from this treatment (Smith et al 1976) The reasons for the variability of response are not known but there appears to be a dose-dependent relationship and a decreased absorption of the drug has been suggested as one possible mechanism of therapeutical failure A high activity of the disease also appears to be an unfavourable prognostic sign Unfortunately at the present time there seems to be no particular features recognized that can be applied to predict the outcome of surgical and medical therapy in the individual patient In the present case the disease had been apparently quiescent some years. Despite the use of a rather dose of EHDP (10–20 mg/kg/day) yielding substantial rise in the serum phosphate concentration and indicating an adequate testinal absorption of the drug there little beneficial effect Recurrence of calcification thus appeared within weeks of the operation However in spite of para art cu recalcification of both hip joints and a po operative limitation of the movement in bo knee joints the treatment brought about a improved position of the ankylosed hips and facilitated standing and some walkin (Figure 4) This improvement was greatl appreciated by the patient

Some biochemical events merit further discussion The intestinal calcium absorption, initially high was reduced during the treatment period Such a decrease has also been observed in experimental animals (Morgan et al 1971) and children (Uttley et al 1975) whereas conflicting data have been presented on the effects of EHDP on calcium absorption in adults (Walton et al 1974) The observed reduction has been presumed to be the result of an interference with the normal vitamin D metabolism and can be corrected with small doses of active vitamin D (Bonjour et al 1973a)



(A) (B)

Figure 4 Photographs showing the patient s position (A) preoperatively (B) 2 years postoperatively

Hypercalcaemia has, to our knowledge, eviously been observed only in experimental imals on a much higher dose of EHDP an in the present case (Bonjour et al 173b) In our patient, however, hyperlcaemia appeared shortly after the EHDP osage was increased and disappeared within ys of the withdrawal of the drug Thus there as a clear relationship between the treatment id the hypercalcaemia As the intestinal or nal handling of calcium did not change in the rection of increasing the serum calcium conntration it seems reasonable to suggest that e hypercalcaemia was related to the effect of HDP on the mineralization process although ot of the magnitude to cause a frank ineralization defect of normal bone

In this disorder, where the underlying cause remains unknown therapeutic progress is likely to be small However, the advantage of a relatively small increase in mobility or a more functional position of a fixed joint in a young patient as in our case, can be worthwhile Our own limited experience is not favourable as regards the effect of EHDP on ectopic bone formation However, it is apparent from several studies that within the group of diphosphonates there are differences between the various compounds (Lemkes et al 1977) Possibly therefore further research will provide new analogues, for example, with a more selective action on ectopic calcification, and with limited side effects, thus making the drug more useful in clinical practice

REFERENCES

Bassett, C A L, Donath, A, Macagno, F, Preisig, R, Fleisch, H & Francis, M D (1969) Diphosphonates in the treatment of myositis ossificans. *Lancet* ii, 845

Baxter, L. A, DeLuca, H F, Bonjour, J-P & Fleisch, H (1974) Inhibition of vitamin D metabolism by ethane-1-hydroxy-1,1-diphosphonate *Arch Biochem Biophys* 164, 655–662.

Bonjour, J-P, DeLuca, H F, Fleisch, H, Trechsel, U, Matejowec, L. A & Omdahl J L (1973a) Reversal of the EHDP inhibition of calcium absorption by 1,25-dihydroxycholecalciferol *Europ J clin Invest* 3, 44–48

Bonjour, J-P., Fleisch, H & Copp, D H (1973b) Influence of a diphosphonate on serum calcium homeostasis. *Proc Soc exp Biol Med* 143, 404–407

Davis, H & Moe, P J (1959) Favourable response of calcinosis universalis to edathamil disodium *Pediatrics* 24, 780

Dixon, T F, Mulligan, L., Nassim, R & Stevenson, F H (1954) Myositis ossificans progressiva *J Bone Jt Surg* 36-B, 445–449

Eaton, W L, Conkling, W S & Daeschner, C W (1957) [illegible] occurring [illegible] pathologic [illegible]

Fleisch, H, Russell, R G G, Bisaz, S, Muhlbauer, R C & Williams, D A (1970) The inhibitory effect of phosphonates on the formation of calcium phosphate crystals *in vitro* and on aortic and kidney calcification *in vivo* *Europ J clin Invest* 1, 12–18

[illegible] A B, Morgan, D B, Fleisch, H A & Richelle, L J (1972) The influence of two diphosphonates on calcium metabolism in the rat *Clin Sci* 43, 31–45

Geho, W B & Whiteside, J A (1973) Experience with disodium [illegible]idronate in diseases of ectopic calcification *Clinical aspects of metabolic bone disease* Ed Frame B, Parfitt A M & Duncan, H Excerpta Medica, International Congress Series no. 270, 506–511

Lemkes, H P J J, Reitsma, F H, Frijlink W & Bijvoet, O L. M (1977) Pharmacology of diphosphonates, Reduction of mineralization disturbance and clinical trial with ADP *Calcif Tiss Res* 24, Suppl 55

Ljunghall, S, Backman, U, Danielson, B G, Johansson, G, Jung B, Kallsen, R., Wibell, L & Wälinder, O (1977) Mechanisms of hypercalciuria in recurrent renal stone formers. *Scand J Urol Nephrol*, Suppl 41 77–96.

Morgan, D B, Bonjour, J-P, Gasser A E, O Brien, K & Fleisch H A. (1971) The influence of a diphosphonate on the intestinal absorption of calcium. *Israel J Med Sci* 7, 384–386

Russel, R G G, Smith R, Bishop M C, Price, D A & Squire, C M (1972) Treatment of myositis ossificans progressiva with a diphosphonate *Lancet* i, 10–12

Schnakenburg, K V, Gross Selbeck G & Wiedemann, H-R (1972) Zur Behandlung der Fibrodysplasia ossificans progressiva mit "Diphosphonat" (EHDP) *Dtsch med Wschr* 97, 1873–1876

Smith R, Russel, R G G & Woods, C G (1976) Myositis ossificans progressiva Clinical features of eight patients and their response to treatment *J Bone Jt Surg* 58 B 48–57

Uttley, W S, Belton, N R, Syme J & Sheppard, H (1975) Calcium balance in children treated with diphosphonates. *Arch Dis Childh* 50 187–190

Walton, R J, Russel, R G G, Smith R & Warner, G (1974) Some effects of disodium ethane-1-hydroxy-1,1-diphosphonate (EHDP) on calcium metabolism in man *Clin Sci* 47, 13–14

Weiss, I W, Fischer, L & Phang J M (1971) Diphosphonate therapy in a patient with myositis ossificans progressiva *Ann intern Med* 74, 933–936

Correspondence to Dr Sverker Ljunghall, Department of Internal Medicine, University Hospital, S-7 0 14 Uppsala, Sweden

Acta orthop scand 50 39–47 1979

BONE VASCULARIZATION AND BONE HEALING IN THE AMPUTATION STUMP

An Experimental Study

CHR HANSEN LETH

Department of Orthopaedic Surgery U, Rigshospitalet, and
Orthopaedic Hospital, Copenhagen, Denmark

The osseous healing process of the amputation stump was investigated in adult rabbits Histological investigation showed that the medullary cavity was closed after 2–3 weeks, chiefly by endosteal callus. After closure of the cavity there was a gradual spongious change in the bone tip and simultaneously the cortex atrophied and the medullary cavity dilated After amputat on on the [illegible] is after amputa [illegible] A combination [illegible] n the course of healing The medullary cavity did not close until 7–10 weeks after operation and there was distinct periosteal callus formation

The microangiographic investigation showed a transient hyper vascularization in the cortex 3–4 weeks after amputation, whereas after simultaneous plugging of the medullary cavity the hypervascularization continued for up to 7 weeks after operation Following amputation proximally on the crus the arterial supply of the cortex came mainly from the periost whereas the cortex after distal amputation was vascularized from the medullary cavity This finding can be due to an interruption of the arterial supply from the nutrient artery associated with proximal amputation, whereas this artery remains intact with amputation distally on the crus

Key words amputation, bone healing, bone vascularization, plugging of the medullary cavity

Accepted 23 v 78

Previous experimental studies of amputation (Hulth & Olerud 1962, Hansen-Leth & Reimann 1972) have shown hypervascularization in the bone in the amputation stump Hulth & Olerud (1962) proved that the osseous healing process of the stump was the same as in an experimental fracture Hypervascularization in fractured bone results from the interruption of bone vascularization (Rhinelander 1968) The changes in bone vascularization after interruption of the arterial supply have been investigated by Trueta (1968) and Brookes (1971), who found that vascularization of the diaphyseal cortex changed after interruption of the nutrient artery

The aim of the present experimental study was to investigate whether the technique used for closure of the medullary cavity influences healing in the amputation stump, and to elucidate the relation between bone healing and bone vascularization especially as

0001 6470/79 010039–09$02.50/0

© 1979 Munksgaard Copenhagen

REFERENCES

Bassett, C. A. L., Donath, A, Macagno, F, Preisig, R., Fleisch, H & Francis, M D (1969) Diphosphonates in the treatment of myositis ossificans. *Lancet* ii, 845

Baxter, L. A., DeLuca, H F, Bonjour, J-P & Fleisch, H (1974) Inhibition of vitamin D metabolism by ethane-1-hydroxy-1,1-diphosphonate *Arch Biochem Biophys* **164**, 655–662.

Bonjour, J-P., DeLuca, H F., Fleisch, H, Trechsel, U., Matejowec, L. A. & Omdahl, J L. (1973a) Reversal of the EHDP inhibition of calcium absorption by 1,25-dihydroxycholecalciferol *Europ J clin Invest* **3**, 44–48

Bonjour, J-P., Fleisch, H & Copp, D H (1973b) Influence of a diphosphonate on serum calcium homeostasis. *Proc. Soc exp Biol Med.* **143**, 404–407

Davis, H & Moe, P J (1959) Favourable response of calcinosis universalis to edathamil disodium. *Pediatrics* **24**, 760

Dixon, T F, Mulligan, L., Nassim, H & Stevenson, F H (1954) Myositis ossificans progressiva. *J Bone Jt Surg* 36-B, 445–449

Eaton, W L., Conkling W S & Daeschner, C [illegible]

Fleisch, H., Russell, R. G G, Bisaz, S, Muhlbauer, R. C. & Williams, D A (1970) The inhibitory effect of phosphonates on the formation of calcium phosphate crystals *in vitro* and on aortic and kidney calcification *in vivo* *Europ J clin Invest* **1**, 12–18

[illegible], A. B, Morgan, D B., Fleisch, H A & Richelle, L. J (1972) The influence of two diphosphonates on calcium metabolism in the rat. *Clin Sci.* **43**, 31–45

Geho, W B & Whiteside, J A. (1973) Experience with disodium etidronate in diseases of ectopic calcification. *Clinical aspects of metabolic bone disease* Ed Frame, B, Parfitt, A M Duncan, H Excerpta Medica, International Congress Series no 270, 506–511

Lemkes, H P J J, Reitsma, P H., Frijlink W Bijvoet, O L. M (1977) Pharmacology of diphosphonates, Reduction of mineralization disturbance and clinical trial with ADP *Calc Tiss Res* **24**, Suppl 55

Ljunghall, S, Backman, U, Danielson, B G Johansson G., Jung B, Källsen, R., Wibell, L & Wilander, O (1977) Mechanisms of hypercalciuria in recurrent renal stone formers *Scand J Urol Nephrol.*, Suppl 41 77–96

Morgan, D B., Bonjour, J-P., Gasser A B O Brien, K. & Fleisch, H A (1971) The influence of a diphosphonate on the intestinal absorption of calcium. *Israel J Med Sci.* 384–386

Russel, R G G, Smith, R., Bishop, M. C., Preston D A & Squire, C M (1972) Treatment of myositis ossificans progressiva with diphosphonate *Lancet* i, 10–12.

Schnakenburg K V., Gross-Selbeck, G Wiedemann, H-R (1972) Zur Behandlung der Fibrodysplasia ossificans progressiva mit "Diphosphonat" (EHDP) *Dtsch med Wschr* **97**, 1873–1876

Smith, R, Russel, R G G & Woods, C G (1976) Myositis ossificans progressiva. Clinical features of eight patients and their response to treatment *J Bone Jt Surg* **58** B, 43–57

Uttley, W S, Belton N R., Syme J & Sheppard H (1975) Calcium balance in children treated with diphosphonates. *Arch Dis Ch Ldh.* 50 187–190

Walton, R J, Russel, R G G., Smith, R & Warner G (1974) Some effects of disodium ethane-1-hydroxy-1 1-diphosphonate (EHDP) on calcium metabolism in man. *Clin. Sci.* 47 13–14

Weiss, I W, Fischer, L & Phang J M (1977) Diphosphonate therapy in a patient with myositis ossificans progressiva. *Ann. intern Med* **74**, 933–936

Correspondence to Dr Sverker Ljunghall, Department of Internal Medicine, University Hospital, S-[illegible] 14 Uppsala, Sweden

Acta orthop scand 50, 39–47, 1979

BONE VASCULARIZATION AND BONE HEALING IN THE AMPUTATION STUMP

An Experimental Study

CHR HANSEN LETH

Department of Orthopaedic Surgery U, Rigshospitalet, and
Orthopaedic Hospital, Copenhagen, Denmark

The osseous healing process of the amputation stump was investigated in adult rabbits Histological investigation showed that the medullary cavity was closed after 2–3 weeks, chiefly by endosteal callus After closure of the cavity there was a gradual spongious change in the bone tip and simultaneously the cortex atrophied and the medullary cavity dilated After amputation on the crus bone rebuilding dominated, whereas after amputation on the femur deterioration of bone was most noticeable A combination of amputation and medullary plugging caused a change in the course of healing The medullary cavity did not close until 7–10 weeks after operation and there was distinct periosteal callus formation

The microangiographic investigation showed a transient hypervascularization in the cortex 3–4 weeks after amputation, whereas after simultaneous plugging of the medullary cavity the hypervascularization continued for up to 7 weeks after operation Following amputation proximally on the crus the arterial supply of the cortex came mainly from the periost, whereas the cortex after distal amputation was vascularized from the medullary cavity This finding can be due to an interruption of the arterial supply from the nutrient artery associated with proximal amputation, whereas this artery remains intact with amputation distally on the crus

Key words amputation, bone healing, bone vascularization, plugging of the medullary cavity

Accepted 23 v 78

Previous experimental studies of amputation (Hulth & Olerud 1962, Hansen-Leth & Reimann 1972) have shown hypervascularization in the bone in the amputation stump Hulth & Olerud (1962) proved that the osseous healing process of the stump was the same as in an experimental fracture Hypervascularization in fractured bone results from the interruption of bone vascularization (Rhinelander 1968) The changes in bone vascularization after interruption of the arterial supply have been investigated by Trueta (1968) and Brookes (1971), who found that vascularization of the diaphyseal cortex changed after interruption of the nutrient artery

The aim of the present experimental study was to investigate whether the [illegible] used for closure of the medullary cavity influences healing in the amputation stump and to elucidate the relationship between bone healing and bone vascularization [illegible]

0001-6470 79 010039-09$02.50 0

regards the effect of interruption of the nutrient artery

MATERIAL AND METHODS

Seventy adult rabbits were used in the investigation and apportioned according to the amputation technique performed, as shown in Table 1 The operations were performed under Nembutal anaesthesia With proximal crus amputation the bone was sawn through at the tibio-fibular synostosis in cases without myoplasty the muscles were cut at the same level, and in cases with myoplasty they were cut approximately 1 cm further distally With distal crus amputation the bone was sawn through at a level distal to the course of the nutrient artery Femur amputation was performed at the midbone level and the stump was closed with myoplasty With knee exarticulation the gastrocnemius muscles were removed and the quadriceps sutured to the crucial ligaments. Medullary plugging was performed with cortex from the amputated bone After amputation on the crus the animals as a rule put on weight in the amputation stump, which in eight cases resulted in minor defects on the stump tip After amputation on the femur the stump was immobilized as a result of a flexion contracture in the hip

The rabbits were sacrificed at intervals from 1 hour to 130 days after operation and an angiographic investigation was performed Under Nembutal anaesthesia the peritoneum was opened and saline was perfused at 1 m pressure through a catheter into the aorta abdominalis, as simultaneously the animal heparinized beforehand was bled through the vena cava. Perfusion was continued with 25 per cent micropaque for approximately 30 min followed by micropaque with 10 per cent formalin and 1 per cent Berliner blue for 10 min Finally, after removing the skin the hind part body was fixed in 10 per cent formalin.

For evaluation of bone healing in the su cm of the tip was removed fixed in 10 pe formalin phosphate, and without pr decalcification embedded in methyl meth and cut lengthwise, and sections 7 μ thick stained according to Goldner The vascular of the bone was evaluated by mea microangiography of cross sections, sa about 1 cm proximal to the stump tip decal embedded in methyl methacrylate ground to a thickness of 1 mm and photographed spectroscope plate As control specimens, sections from the contralateral tibia in 10 amputated animals and from the tibia of the operated rabbits were used.

RESULTS

Histological investigation of the bone amputation stump showed increased blastic and osteoclastic activity ponding to the outermost part of endosteum 3–4 days after amputation, formation of osteoid tissue and beak-fo spongious bone on the inside of the med aperture (Figure 1) Periosteally only a increase in osteoblastic activity was obs located proximal to the stump tip formation of periosteal exostoses.

After *proximal amputation on the with myoplasty* the stump was closed w thin spongious layer from 18 days surgery (Figure 2) The same was obs after *proximal amputation without myop* while after *amputation distally on the* the *medullary* cavity was seen to

Table 1 The material apportioned according to amputation level and the technique used for closure medullary cavity

	cases	−myoplasty	+myoplasty	+medullary pluggin
Amp prox. cruris	35	11	13	11
Amp distalis cruris	15		15	4
Amputatio femoris	14		10	
Exarticulatio genu	3			
−operation	3			
	70	11	38	15

F gure 1 Six days after proximal amputation on the crus w th myoplasty The tip of the amputa on stump Cortex is seen on the left and beak formed spongious bone on the inside of the medullary aperture

Figure 3 Twelve days after amputation distally on the crus Spongious cloture of the medullary cavity

'gure 2 Twenty four days after proximal mputat on on the crus with myoplasty The edullary cavity is closed with a thin spongious yer

Figure 4 Forty eight days after amputation distally on the crus Increased spongiosity of the whole stump tip

losed already on the 12th day Following losure of the medullary cavity (Figure 3) icreased spongiosity of the whole stump tip as observed and furthermore the cortex was trophied and the medullary cavity dilated ' gure 4) After *amputation on the femur* the edullary cavity was closed 9 days after perat on with a thin spongious layer overed with cartilage and fibrous tissue No urther bone formation was seen and about 5 eeks later an increasing atrophy of bone th dilation of the medullary cavity was bserved (Figure 5)

Figure 5 Twenty days after amputation on the

After *proximal crus amputation with plugging of the medullary cavity* there was increased periosteal reaction, as compared with amputation without plugging, and large periosteal, spongious exostoses with cartilage islands gradually developed Forty days after amputation the stump was still not closed (Figure 6), after 50 days there was incipient closure, and after 70 days the medullary cavity was finally closed At this stage a spongious change had occurred in the whole stump tip The inserted plugs were mostly avital the first 3 weeks after operation After this time an increased osteoblastic activity was seen around these plugs.

Figure 6 Forty days after amputation on the crus with plugging of the medullary cavity Abundant periosteal spongious tissue is seen, but the medullary cavity is not closed

Microangiographical investigation of the unoperated tibia showed only a few medullary arteries with ramifications into the central half of the cortex and a few vessels running radially from the periosteum into the superficial fifth of the cortex, and the medullary sinusoids dominated the cross section angiogram.

After amputation a hypervascularization was seen in the amputation stump, in the cortex as well as in the periosteum and the medullary cavity In the cortex the vascularization depended on the amputation level (Table 2) After *proximal amputation on the crus* the microangiograms showed an initial reduction in cortical vascularization fr medullary arteries (Figure 7). After about days the vascularization in the cortex creased, mainly as a result of hyperplasi of the periosteum (Figure 8) After 30 d vascularization in the cortex again norm ized, and vascularization in the periost decreased, but in the medulla a hyp vascularization was seen during the invest tion period *Distal amputation on the c* caused immediate hypervascularization in cortex and up to 40 days postoperati there was an increased number of cort arteries, mainly from the medulla (Figure After that period vascularization normaliz in the cortex as well as in the periosteum medulla The vascular reaction in the b was identical after stump closure with a

Figure 7 Microangiogram of the amputat stump One hour after proximal amputation the crus The medullary sinusoids are seen bel

Table 2 Microangiographical investigation of cortical vascularization

Time	Amputation level			
	Amp distally on crus		Amp proximally on crus	
	PERIOSTEUM	MEDULLARY CAVITY	PERIOSTEUM	MEDULLARY CAVITY
unoperated tibia	XX	XXXX	XX	XXXX
½ hour	XXXX	XXXX	X	XX
½ week	XXX	XXXXXXX	XX	XX
—	XXXX	XXXXXX	X	XXX
1 —	XX	XXXXXXX	XX	XXX
—	XXX	XXXXXX	XXX	XXXXX
2 weeks	XXX	XXXXXXXX	XXXXX	XXX
—	XXX	XXXXXXX	XXXXXXX	XXXX
—	XXX	XXXXXXXXX	XXXXX	XXXXX
3 —	XXX	XXXXXXX	XXXX	XXXX
—	XXX	XXXXXXX	XXXX	XXXXXX
4 —	XXXXX	XXXXXXX	XXXXXXXXX	XXX
6 —	XXX	XXXXXX	XX	XXX
—			XXX	XXXXX
7 —	XX	XX		
9 —	XX	XX	XX	XX
13 —	XX	X	XXXX	XX

The cortical vascularization seen in cross sections of the tibial diaphysis of the amputation stump after amputation distally and proximally on the crus

After *proximal crus amputation with plugging of the medullary cavity* there was increased periosteal reaction as compared with amputation without plugging and large periosteal spongious exostoses with cartilage islands gradually developed Forty days after amputation the stump was still not closed (Figure 6) after 50 days there was incipient closure, and after 70 days the medullary cavity was finally closed At this stage a spongious change had occurred in the whole stump tip The inserted plugs were mostly avital the first 3 weeks after operation After this time an increased osteoblastic activity was seen around these plugs.

Figure 6 Forty days after amputation on the crus with plugging of the medullary cavity Abundant periosteal spongious tissue is seen but the medullary cavity is not closed

Microangiographical investigation of the unoperated tibia showed only a few medullary arteries with ramifications into the central half of the cortex and a few vessels running radially from the periosteum into the superficial fifth of the cortex and the medullary sinusoids dominated the cross section angiogram

After amputation a hypervascularization was seen in the amputation stump, in the cortex as well as in the periosteum and the medullary cavity In the cortex the vascularization depended on the amputation level (Table 2) After *proximal amputation on the crus* the microangiograms showed an initial reduction in cortical vascularization from medullary arteries (Figure 7) After about 10 days the vascularization in the cortex increased mainly as a result of hyperplasia of the periosteum (Figure 8) After 30 days vascularization in the cortex again normalized and vascularization in the periosteum decreased but in the medulla a hypervascularization was seen during the investigation period *Distal amputation on the crus* caused immediate hypervascularization in the cortex and up to 40 days postoperatively there was an increased number of cortical arteries, mainly from the medulla (Figure 9). After that period vascularization normalized in the cortex as well as in the periosteum and medulla The vascular reaction in the bone was identical after stump closure with and

Figure 7 Microangiogram of the amputation stump One hour after proximal amputation on the crus The medullary sinusoids are seen below

Table 2 Microangiographical investigation of cortical vascularization

Time	Amputation level			
	Amp distally on crus		*Amp proximally on crus*	
	PERIOSTEUM	MEDULLARY CAVITY	PERIOSTEUM	MEDULLARY CAVITY
unoperated tibia	XX	XXXX	XX	XXXX
1 hour	XXXX	XXXX	X	XX
½ week	XXX	XXXXXXX	XX	XX
—	XXXX	XXXXXX	X	XXX
1 —	XX	XXXXXXX	XX	XXX
—	XXX	XXXXXX	XXX	XXXXX
2 weeks	XXX	XXXXXXXX	XXXXX	XXX
—	XXX	XXXXXXX	XXXXXXX	XXXX
—	XXX	XXXXXXXXX	XXXXX	XXXXX
3 —	XXX	XXXXXXX	XXXX	XXXX
—	XXX	XXXXXXX	XXXX	XXXXXX
4 —	XXXXX	XXXXXXX	XXXXXXXXX	XXX
6 —	XXX	XXXXXX	XX	XXX
—			XXX	XXXXX
7 —	XX	XX		
9 —	XX	XX	XX	XX
13 —	XX	X	XXXX	XX

The cortical vascularization seen in cross sections of the tibial diaphysis of the amputation stump after amputation distally and proximally on the crus

Figure 8 Microangiogram of the amputation stump Fifteen days after proximal amputation on the crus The hyperplastic, richly vascularized periosteum is seen above

Figure 9 Microangiogram of the amput stump Three days after amputation distall the crus The medullary cavity is seen on the r

without myoplasty, and after *amputation combined with plugging of the medullary cavity* there was a moderately increased vascularization from the periosteal arteries in the cortex for up to 50 days after amputation Bone vascularization did not change after *knee disarticulation*, whereas after *femur amputation* there was a short period of slight hypervascularization of the cortex coming from the periosteum

DISCUSSION

Several previous studies have dealt with the normal circulation in the rabbit tibia The diaphysis of the tibia is supplied from the nutrient artery, the metaphyseal and the periosteal arteries, but there is disagreement amongst the different investigators as to the normal arterial supply of the tibial cor Morgan (1959), Gothman (1960) Rhinelan (1968) and Trueta (1968) found perios branches in the outer third of the cor whereas Brookes (1971) was not able demonstrate branches from the perios arteries to the cortex, and he considered subperiosteal vessels to be solely effere veins If one or more of the arterial syste to the tibia is obliterated the remaini vessels will, to a varying degree, take o their function (Danckwardt-Lillestrom 196 Trueta (1968) found no changes in the tibi vascularization after ligature of the nutrien artery, while Brookes (1971) proved th ligature of the artery caused an ischaemia o the diaphysis and hypervascularization in th cortex through the periosteal arteries.

In the present investigation micro-angiography of the non-operated tibia ha

shown that the central half of the cortex is supplied by medullary arteries while a few radially running vessels, possibly ramifications from periosteal arteries, were seen in the superficial fifth of the cortex After amputation on the crus vascularization of the tibial cortex depended on the level of amputation Proximal amputation produced delayed hypervascularization in the cortex, mainly from the periosteum, whilst distal amputation caused immediate hypervascularization in the cortex through the medullary arteries This difference may be due to the relation between the amputation level and the course of the nutrient artery (Figure 10) With proximal amputation the bone is deprived of the arterial supply from the nutrient artery, whereas this artery remains intact with distal amputation In accordance with this, the histological investigation showed that the medullary cavity closed later after proximal amputation on the crus than after distal crus amputation and amputation on the femur where the bone has not been deprived of blood supply from the nutrient artery

In the present investigation periosteal hypervascularization was followed by a sparse periosteal callus development, seen as exostoses slightly proximal to the stump tip, generally the periosteal callus was not involved in the closure of the medullary cavity This observation is not in agreement with Hulth & Olerud (1962) who found that periosteal callus developed parallel with and adjacent to the periosteal vessels, while endosteal sealing callus was initiated by the appearance of fan-shaped proliferation of new

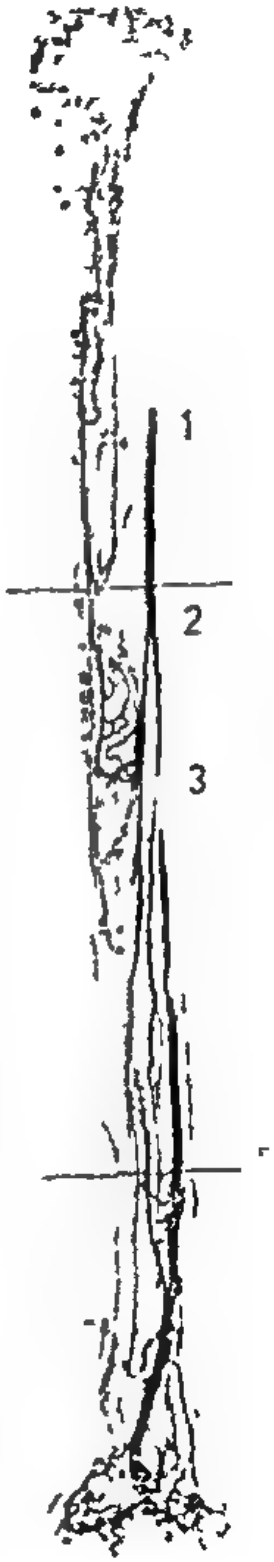

Figure 10 Microangiogram of the whole tibia of a rabbit (L. Gothman. The normal arterial pattern of the rabbit's tibia Acta chir scand 120, 201–210 1960).
The nutrient artery (1) passes at the level 2 through the lateral cortex In the medullary

a [illegible]
access
lateral malleolus
b proximal amputation level
c distal amputation level

vessels emerging from the marrow cavity A similar fan-shaped vascular proliferation was observed after crus amputation on young rabbits in the investigation by Hansen-Leth & Reimann (1972) who also showed an extensive development of periosteal exostoses on the amputation stump After amputation on adult rabbits, as used in the present investigation, the periosteal reaction was not so extensive as in young animals (Trueta 1968)

Histological investigation showed formation of osteoid tissue and beak-formed spongious bone on the inside of the medullary aperture, and in some cases islands of spongious bone which had developed in the peripheral part of the cavity Previous investigations have shown that the medullary cavity reacts to intramedullary devascularization by formation of osteogenetic granulation tissue from which trabecular bone is formed (Foster et al 1951, Richany et al 1965, Danckwardt-Lillestrom 1969) After proximal crus amputation and interruption of the nutrient artery, intramedullary vascularization is transitorily reduced and bone formation from osteogenic tissue in the peripheral part of the medullary cavity is a possibility

After amputation the closure of the medullary cavity was followed by a gradual change in the whole stump tip, on the crus there was an increasing spongiosity of the stump whereas on the femur bone resorption and dilation of the medullary cavity occurred Trueta (1968) and Brookes (1971) have previously observed bone resorption and dilation of the venous sinusoids through lack of muscle function, and Geiser & Trueta (1958) found that tenotomy of the Achilles tendon on rabbits caused osteoporosis of the calcaneus and a transient hypervascularization followed by hypovascularization They were of the opinion that these changes were due partly to abolished muscle pulling force and partly to loss of pressure strength caused by the lost weight Brookes (1971) found likewise that insufficient muscle function resulted in increased vascularization of bo The present investigation has shown hyp vascularization in the cortex after the clos of the medullary cavity This hypervascula zation as well as the gradual changes in t bone tip and the dilation of the medulla cavity can be due to muscle inactivity In t crus, the bone re-building dominated, b after amputation on the femur, where mus inactivity was combined with loss of press strength, bone resorption was the ch feature

The present investigation has shown th plugging of the medullary cavity changes th course of healing in the amputation stum The medullary cavity was normally close after 2–3 weeks, with plugging however th cavity was still open 5–7 weeks after amput tion At the same time, there was a stron periosteal reaction with formation of larg periosteal exostoses The inserted plugs we mostly avital in the first weeks and did no contribute to the formation of callus insid the medullary cavity Previous investigation have shown extensive periosteal vasculariza tion and development of subperiosteal bon after intramedullary intervention, and seven explanations have been suggested for th subperiosteal bone formation Richany et al (1965) found that local stasis and oedema le to anoxia and prompted formation o periosteal bone, while Trueta & Cavadu (1955) were of the opinion that ischaemia caused by intramedullary procedure provoked proliferation of periosteal vessel with accompanying new bone formation, a the same time no bone formation occurred from osteogenetic tissue in the medullary cavity This fact can explain the delayed closure of the medullary cavity after amputa tion combined with osseous plugging

In a previous experimental study (Hansen Leth & Reimann 1972) it was found that hypervascularization in the amputation stump occurred in the soft tissues as well as in the bone In experimental investigations Zuchman (1960) and Whiteside & Lesker (1978) have shown a rich anastomotic

vascular network between muscle and periosteum. Periosteum may serve as an important source of collateral circulation to the muscles. After amputation the technique used for closure of the medullary cavity influences the vascularization in the bone and furthermore the muscular vascularization in the amputation stump. Periosteal hypervascularization was seen after amputation proximally on the crus and an extensive periosteal reaction was seen after amputation combined with plugging of the medullary cavity. These findings can explain the increased muscular blood flow in the amputation stump after proximal crus amputation combined with plugging of the medullary cavity (Hansen-Leth 1976). This effect of medullary plugging may be of interest for amputation surgery in man.

REFERENCES

Brookes, M (1971) *The blood supply of bone* Butterworths, London

Blanckwardt-Lilliestrom, G (1969) Reaming of the medullary cavity and its effect on diaphyseal bone *Acta orthop scand*, Suppl 128

Foster, L N Kelly, Jr, R P & Watts, W M (1951) Experimental infarction of bone and bone marrow *J Bone Jt Surg* 33-A, 396–406

Geiser, M & Trueta J (1958) Muscle action bone ratification and bone formation *J Bone Jt Surg* 40-B 282–311

Gothman L (1960) The normal arterial pattern of the rabbit's tibia – a microangiographic study *Acta chir scand* 120, 201–210

Hansen-Leth, C & Reimann, I (1972) Amputations with and without myoplasty on rabbits with special reference to the vascularization *Acta orthop scand* 43, 68 77

Hansen-Leth C (1976) Muscle blood flow after amputation with special reference to the influence of osseous plugging of the medullary cavity – Assessed by 133 Xenon and Histamine An animal experiment *Acta orthop scand* 47, 613–618

Hulth, A & Olerud, E (1962) Studies on amputation stumps in rabbits *J Bone Jt Surg* 44-B 431–435

Morgan, J D (1959) Blood supply of growing rabbits' tibia *J Bone Jt Surg* 41 B, 185 203

Rhinelander, F W (1968) The normal microcirculation of diaphyseal cortex and its response to fracture *J Bone Jt Surg* 50-A 784–800

Richards S F Spritz H Kraner K, Ashby, J & Merrill T G (1965) The role of the diaphyseal medulla in the repair and regeneration of the femur shaft in the adult cat *J Bone Jt Surg* 47-A, 1565–1584

Trueta J (1968) *Studies of the development and decay of the human frame* W Heinemann Medical Books London

Trueta J & Cavadias, A X (1955) Vascular changes caused by the Kuntscher type of nailing *J Bone Jt Surg* 37-B 492–505

Whiteside, L O & Lesker P A (1978) The effects of extraperiosteal and subperiosteal dissection I On blood flow in muscle *J Bone Jt Surg* 60 A 23–26

Zuchman J (1960) Studies on the vascular connexions between periosteum bone and muscle *Brit J Surg* 48, 324–328

Correspondence to Chr Hansen Leth Centralsygehuset 7400 Herning Denmark

cta orthop scand. 50 49–58 1979

WOUND HEALING IN BELOW-KNEE AMPUTATIONS IN RELATION TO SKIN PERFUSION PRESSURE

P HOLSTEIN P SAGER & N A LASSEN

Department of Clinical Physiology and Surgical Department M, Bispebjerg Hospital Copenhagen Denmark.

In [illegible] below-knee amputations the healing of the stumps was correlated with the local skin perfusion pressure (SPP) measured preoperatively as the external pressure required to stop isotope washout using ^{131}I or ^{125}I - [illegible] Of the eight cases with an SPP below 20 [illegible] uired reamputa [illegible] between 20 and [illegible] 40 cases with an [illegible] cent) which did not heal The difference in failure rate is highly significant ($P < 0.01$) Four [illegible] as against 10 out of 30 [illegible] as higher in the diabetic [illegible] with 34 mmHg (range [illegible] 8–68 mmHg) in the non-diabetic group ($P < 0.001$) The postoperative SPP measured on the stumps was on average 8 mmHg higher than the preoperative SPP ($P < 0.001$) The increase took place mainly in stumps with an SPP above 20 mmHg explaining why the preoperative SPP values related so closely to the postoperative clinical course We conclude that a low SPP can be used to predict ischaemic wound complications, leading to reamputation at a higher level

Key words amputation, diabetes ^{131}I antipyrine ischaemia, occlusive arterial disease, skin blood pressure, skin perfusion pressure

Accepted 13 ix 78

To save the knee is one of the crucial issues in major leg amputation for peripheral occlusive arterial disease In recent years a number of reports have demonstrated that the local blood pressure as well as the local blood flow correlates with healing of the wound of a below knee (BK) amputation (Holstein 1973, Moore 1973 Lassen & Holstein 1974, Barnes et al. 1976, Raines et al 1976, Kostuik et al 1976 Hammersgaard & Baadsgaard 1977, Lund & Sager 1977) The present paper presents the pre- and postoperative measurements of the local skin perfusion pressure (SPP) by the isotope washout technique in patients undergoing BK amputations.

PATIENTS AND METHODS

Patients The study is prospective and comprises [illegible] according to the age of the patients and the presence of diabetes mellitus is shown in Table 1 Diabetes mellitus, which was present in 34 patients, was of more than 10 years duration in 18 patients and of less than 5 years duration in 7 patients. In 16 cases the patients were being treated with insulin In most cases the blood sugar was satisfactorily controlled during the course of the hospitalization for amputation Nine patients had previously had a contralateral major amputation.

0001 6470/79/010049–10$02.50 ⊡

© 1979 Munksgaard, Copenhagen

Table 1 Age distribution in 67 cases of below knee amputation

	41–50	51–60	61–70	71–80	81–90	Total
Cases without diabetes mellitus	0	7	8	13	5	33
Cases with diabetes mellitus	3	3	13	11	4	34

Male/female ratio 41/26 = 1 58 Arithmetic mean age Without diabetes mellitus (DM) – 70 0 years, with DM = 68 2 years.

Measurements of the SPP

The technique, consisting of measurement of the external pressure required to stop the washout of an intradermal depot of isotopes, has previously been described (Holstein & Lassen 1973, Holstein et al 1977) and is only briefly summarized

Approximately 0 1 ml of a sterile solution containing 10–20 μCi $^{131}I^{-}$-antipyrine (or 30–40 μCi ^{125}I -antipyrine) and 50 mg histamine diphosphate was injected intradermally and a washout curve was recorded The external pressure was applied by a blood pressure cuff and measured by a square air-filled plastic cushion (inflatable part, 11 by 11cm) interposed between the labelled skin and the cuff and connected to an ordinary mercury manometer When the washout rate, which accelerates during the first 2 to 15 minutes, had [illegible] constant for about 3 to 5 minutes the external pressure was raised in steps resulting in a stepwise decrease in washout rate until cessation At each of the final steps the tracing was observed for about 5 minutes and after washout cessation the external pressure was released to zero in order to secure that the washout was re-established The washout cessation pressure, viz the SPP, was determined within an interval of 5 mmHg and was defined as the highest external pressure which allowed a minimal washout to be discerned, plus 3 mmHg

The site of measurement was approximately 10 cm distal to the knee joint on the anterolateral side of the calf just superficial to the anterior tibial muscle The SPP was also measured below the knee on the contralateral leg In patients in whom a contralateral above-knee (AK) amputation had previously been performed the control point was chosen to be 15 cm proximal to the end of the stump on the anterolateral side

About 4 to 8 weeks after surgery the SPP was again measured at the same sites. The patients were examined in the supine position with horizontal legs. Repeated i.v. doses of analgesics (demerole, 35 mg) sufficient to prevent involuntary movements from rest pains were given and, in addition, the legs were supported by sandbags. Conventional auscultatory arm blood pressure was repeatedly measured using a 12 by 26cm cuff placed around the left arm Before the examinations the thyroid gland was blocked with 0 5 g potassium iodide given perorally in solution.

Surgery Forty-nine of the BK amputations were performed using the conventional technique with an anterior and a posterior flap In 13 cases one long posterior flap was used (Bickel 1943 Rorrison & Burgess 1971) and in five cases the sagittal technique (Persson & Sundén 1971) was applied. All the SPP measurements were known by the surgeons The amputation wounds were loosely dressed (Tube gauze®) and suction drainage was employed in most cases. Sutures were removed after [illegible] to 3 weeks. Immediate fitting systems were not used but the patients were mobilized as soon as possible on crutches possibly with a splint. Infections were treated by antibiotics after culture

Primary healing was defined as complete healing of the wound at the end of the fourth postoperative week Healing by second intention was defined as healing at a later time possibly after surgical revision, provided that the BK level was maintained Revision amputation to an above the knee level was considered as a failure

Statistics Statistical analysis included rank sum tests, Fisher's exact test and Wilcoxon's test for paired comparisons

RESULTS

Mortality Four patients (6 1 per cent) died within the first month after the amputation, but a total of six patients undergoing seven BK amputations died before the final result with regard to healing of the amputation could be established In four of these cases there was ulceration of the stump In three cases the stump was intact, but the sutures were not yet removed These seven BK amputations are excluded from the following analysis of wound healing in relation to SPP

The preoperative SPP Figure 1 and Table 2 show the correlation between the preoperative SPP and the healing of the wounds Of the total number of cases with an SPP below 20 mmHg only two out of eight cases healed (25 per cent) The six failures were caused by skin necrosis With an SPP between 20 and 30 mmHg eight out of twelve cases (67 per cent) healed The failures were caused by skin necrosis in one case and by skin necrosis in combination with infection in three cases Above 30 mmHg, 36 out of 40 cases healed (90 per cent) The four failures were due to infection in two cases, infection and necrosis in one case and haematoma and necrosis in one case The differences in failures in these three groups according to the level of SPP are highly significant ($P<0.01$)

In the 43 cases amputated using the conventional technique (Table 2) the differences in healing rate for the various SPP intervals parallel the results of the whole series and are highly significant ($P<0.01$) The results of the amputations applying a long posterior flap and those with the sagittal technique were too small for analysis.

In the 30 non-diabetic cases the differences in healing rates correlated significantly with the level of the SPP ($P<0.05$, Table 2), but in the 30 diabetic cases no correlation with the SPP was found and there were only four failures in this group compared to 10 failures in the non-diabetic group ($0.05<P<0.10$)

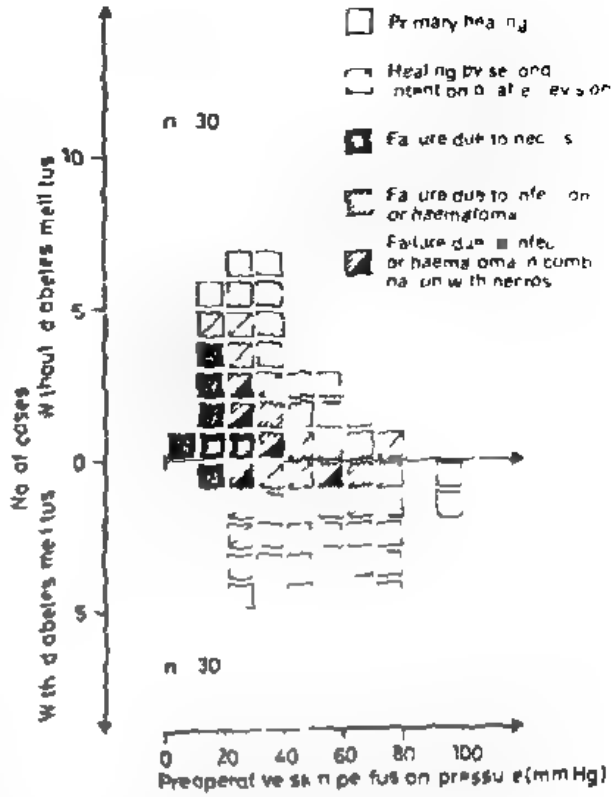

Figure 1 Wound healing in 60 BK amputations in relation to the local skin perfusion pressure measured preoperatively (Failure – re-amputation at AK level)

These findings should be seen against the impressive difference in distribution of SPP in the two groups The SPP averaged 33 7 mmHg (range 8–68 mmHg) in the non-diabetic group and 56 7 mmHg (18–93 mmHg) in the diabetic group ($P<0.001$) and there were only six cases in the diabetic group with an SPP below 30 mmHg

The level of the most distally palpable pulsations correlated significantly with wound healing and with the SPP (Table 3) All cases with palpable pulsations in the popliteal artery healed The absence of pulsations in the femoral artery did not, however, rule out healing of a BK amputation

The postoperative SPP Postoperative measurements of the SPP on the amputation stumps including control measurements on the contralateral leg, were made in 54 cases. Figure 2 and Table 4 show the preoperative SPP compared with the postoperative SPP The SPP on the stumps was on average 8

Table 2 The preoperative skin perfusion pressure (SPP) in relation to wound healing in 60 below-knee amputations

	< 20 mmHg			21–30 mmHg			< 30 mmHg		
	Primary healing	Secondary healing	Failure	Primary healing	Secondary healing	Failure	Primary healing	Secondary healing	Failure
Without diabetes mellitus $n=30$	1 (a)	1	5 (71 4%) (b)	2 (a)	2	3 (42 9%) (b)	11 (a)	3	2 (12 5%) (b)
With diabetes mellitus $n=30$	0	0	1 (100 0%)	2	2	1 (20 0%)	18	4	2 (8 3%)
Total $n=60$	1 (c)	1	6 (75 0%) (d)	4 (c)	4	4 (33 3%) (d)	29 (c)	7	4 (10 0%) (d)
Conventional surgical technique $n=43$	1 (e)	0	5 (83 3%) (f)	2 (e)	3	2 (28 6%) (f)	24 (e)	4	2 (6 7%) (f)

P value (Rank sum test)
Distribution a) 0 0180 d) 0 0028
b) 0 0120 e) 0 0044
c) 0 0050 f) 0 0022

Table 3 Healing of BK amputations and preoperative skin perfusion pressure (SPP) in relation to the level of the most distally palpable pulsations

	Pulsations in the popliteal artery $n=7$	P value	Pulsations in the femoral artery $n=46$	P value	No pulsations in the femoral artery $n=7$
Number of failures	0	>0 1	9	<0 05	5
SPP mean (mmHg)	71 6	<0 01	43 3	<0 01	22.2
range (mmHg)	38–93		13–78		8–48

mmHg higher than the SPP at the identical site as measured preoperatively ($P<0\,001$) Corrections of the SPP for changes in systemic blood pressure did not significantly influence this difference These corrections of SPP were made in proportion to variations in systemic mean blood pressure On the contralateral leg no significant difference was found between the preoperative and the postoperative measurements.

The figures of the postoperative SPP in relation to wound healing parallel the preoperative figures (Figure 2 and Table 5) In the diabetic cases the average SPP was again significantly higher than in the non-diabetic group 61 5 mmHg (range 28–108 mmHg) compared with 41 9 mmHg (range 0–83 mmHg) ($P<0\,01$)

Rehabilitation. The patients returned to their own homes in 41 out of 56 cases (73 per cent). Of the 66 cases where the patients could

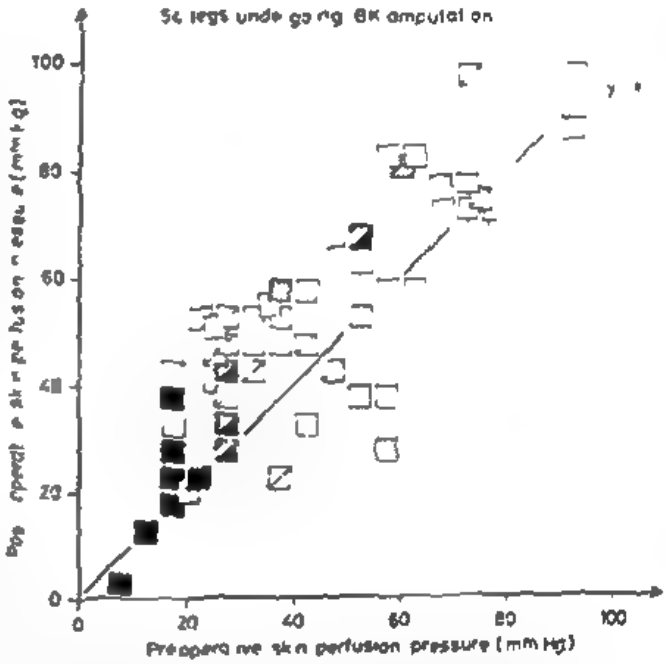

Figure 2 The preoperative skin perfusion pressure correlated with the postoperative skin perfusion pressure in 54 legs undergoing BK amputation (The symbols are identical to those used in Figure 1)

Table 4 The preoperative skin perfusion pressure compared with the postoperative skin perfusion pressure

	Preoperative values mean mmHg	Preoperative values range mmHg	P value	Postoperative values mean mmHg	Postoperative values range mmHg
Amputated leg $n=54$	43 9	8–93	<0 001	51 7	0–108
			<0 001	52.4 x)	0–93 x)
Contralateral leg $n=54$	63 4	28–98	>0 10	62.4	28–103
			>0 10	62.6 x)	23–95 x)

x) values corrected for changes in systemic blood pressure.

Table 5 The postoperative skin perfusion pressure (SPP) in relation to wound healing in 56 below knee amputations

	<20 mmHg			21–30 mmHg			>30 mmHg		
	Primary healing	Secondary healing	Failure	Primary healing	Secondary healing	Failure	Primary healing	Secondary healing	Failure
Without diabetes mellitus *n* 27	0	0	3(100.0%)	1	1	2(50.0%)	11	5	4(20.0%)
With diabetes mellitus *n* 27	0	0	0	1	0	2(66.7%)	17	5	2(8.3%)
Total *n* 54	0	0	3(100.0%) (a)	2	1	4(57.1%) (a)	28	10	6(13.6%) (a)
Conventional surgical technique *n* 41	0	0	2(100.0%) (b)	2	1	3(50.0%) (b)	23	6	4(12.1%) (b)

P value (Rank sum test)
Distribution a) 0.0136
b) 0.0292

Table 6 Number of weeks spent in hospital in relation to the healing of the BK amputation and to rehabilitation

No of BK amputations	Healing of the BK amputation	Weeks in hospital preoperatively mean	range	postoperatively mean	range
34	Primary healing	2.7	(0 5–12)	15 4	(1–39)
12	Secondary healing	2.7	(0 5–7)	24 2	(7–53)
14	Revision to AK level	6 3	(0 5–20)	22.2	(4–51)
7	Death before healing	1 5	(0–3)	4 2	(0–17)

No of BK amputations	Rehabilitation	preoperatively mean	range	postoperatively mean	range
26	Ambulant with BK prosthesis*)	2.4	(0 5–8)	18 8	(4–53)
7	Ambulant with AK prosthesis	5 8	(2–11)	22.8	(9–53)
15	Failed attempt at walking	3 8	(0 5–12)	23 5	(10–51)
19	No attempt at walking	3 4	(0- 20)	8 0	(0–29)

*) 14 of these were the PTB type

walk independently prior to amputation, rehabilitation as regards walking with a prosthesis was achieved in only 33 cases (50 per cent) The ability to walk was not regained in the remaining 33 cases due to death in 10 cases, disability from arthritis or blindness in 5 cases, poor mental and physical condition in 11 cases and to bilateral major amputation in 7 cases.

The period of hospitalization (Table 6) increased by about 8 weeks, on average, in cases of wound complications Rehabilitation or attempts at rehabilitation approximately doubled the period of hospitalization

One of the two stumps which healed in spite of a preoperative SPP of below 20 mmHg broke down later because of mechanical stress from the prosthesis In the other case the stump was never fitted with a prosthesis because the patient died Thus none of the eight BK amputations with a preoperative SPP below 20 mmHg were successful from a point of view of walking rehabilitation For SPP above 20 mmHg the ability of the stump to tolerate a prosthesis did not correlate with the SPP

Out of the 14 BK failures, i e reamputations at the above-knee level, the AK stump healed in 13 cases. In one case the patient died with infection of the stump

DISCUSSION

In the past 5 years a number of reports on objective methods of determining the amputation level have been published These studies concern a variety of methods including determination of the local blood pressure and the local blood flow (see survey in Table 7) It appears that preoperative blood pressure values of above 20 to 40 mmHg and flow values of above 1 6–2 6 ml/min/100 g tissue are indicative of a high success rate At lower blood pressures or blood flow values the prognosis is doubtful

In none of the larger series reported did a precise value indicating wound failure appear Our series points to the preoperative SPP as a very sensitive means of predicting the results, when the SPP is below 20 mmHg the results are poor and when it is above 30

Table 7 Index of healing of major amputation according to assessment of local blood pressure and local blood flow

	Investigator	Method	Amputation	Poor arterial supply Criterion	Healed	Failed	Good arterial supply Criterion	Healed	Failed
Local blood pressure	Holstein 1973 Lassen & Holstein 1974	Skin perfusion pressure (isotope washout) Preliminary investigations	BK and AK	<20 mmHg	0	5	>40 mmHg	31	3
	Barnes et al 1976	Systolic pressure by Doppler technique	BK	Undetectable signal	1	5	>20 mmHg	43	4
	Raines et al 1976	Systolic pressure by Doppler technique	BK	Undetectable signal	0	3	> ? not indicated	24	0
	Lund & Sager 1977	Skin perfusion pressure (isotope washout)	BK	<40 mmHg	10	6	>40 mmHg	21	4
	Hammersgaard & Baadsgaard 1977	Skin perfusion pressure (isotope washout)	BK	<20 mmHg	4	2	>30 mmHg	49	1
	Holstein Dohn and Jansen (in preparation)	Skin perfusion pressure (isotope washout)	BK	<20 mmHg	1	8	>30 mmHg	61	2
Local blood flow	Moore 1973	^{133}Xe washout (injection)	BK	<0 6 ml/min/ 100 g tissue	0	3	>0 6 ml/min/ 100 g tissue	29	1
	Moore 1974	^{133}Xe washout (injection)	BK	<2 6 ml/min/ 100 g tissue	0	3	>2 6 ml/min/ 100 g tissue	[illegible]	0
	Kostuik et al 1976	^{133}Xe washout (epicutaneous)	BK TK* AK	< 1 5 ml/min/ 100 g tissue	8	2	> 1 5 Ml/min/ 100 g tissue	22	0

*TK = Through knee

mmHg the results are good At borderline pressures from 20 to 30 mmHg a number of clinical factors, however, are liable to influence the result The general condition of the patient, the condition of the skin at the selected level, the surgical technique and the postoperative treatment are all involved Moreover, the SPP is not constant along the line of a planned amputation The SPP varies with the systemic blood pressure and with the condition of the main arterial pathway In addition the elimination of a greater part of the leg i e. of the low pressure tissues may cause the stump pressure to rise In another paper (Holstein & Lassen) the postoperative increase in average stump pressure observed in the present series will be discussed The average postoperative increase in stump pressure was only 8 mmHg and a significant effect of amputation occurred mainly in legs with an SPP above 20 mmHg (Figure 2) This also explains why the preoperative figures relate so closely to the postoperative course

Diabetic patients are often better candidates for BK amputations than non-diabetic patients (Cranley et al 1969, Condon & Jordan 1970, Persson & Sundén 1971, Romano & Burgess 1971, Termansen 1977) This is also the case in our series and can be explained by the finding of a significantly higher SPP in the diabetic group

It is not surprising that the arterial supply at the BK level is on average better in the diabetic patients Typically a BK amputation in vascular insufficiency is required because of tissue lesions localized peripherally, i e on the foot and the diabetic foot is especially vulnerable. This is so because the frequent major artery lesions of the thigh and pelvis are often combined with small artery lesions on the foot (Pedersen & Olsen 1962, Ferrier 1967, Faris 1975) implying peripheral ischaemia Moreover skin lesions from minor trauma such as pressure ulcers are liable to occur due to peripheral neuropathy and finally infection always threatens the diabetic foot Thus the diabetic patient is liable to lose his foot (leg) in spite of a good arterial supply at the BK level—and at an age a few years younger (Table 1) than the non-diabetic patient

There were only six diabetic cases with preoperative SPP below 30 mmHg at the BK level in this series More data are required to evaluate the prognosis of BK amputations at low pressures in diabetes Such data will be published (Holstein Dohn and Jansen) demonstrating that no substantial difference exists between the healing of amputation wounds in diabetics and non-diabetics in the various SPP intervals

Three out of four failures in the diabetic BK amputations were caused by or complicated by infection However, it should be emphasized that infection was a common complication too in the non-diabetic group—especially at low pressures

The high costs of amputation with regard to occupancy of hospital beds have previously been reported (Hansson 1964) Wound complications and rehabilitation take time and since BK amputees are more frequently rehabilitated to walking than the AK amputees, the average time spent in hospital is longer for the BK amputees (Warren & Kihn 1968, Weaver & Marshall 1973, Holstein et al 1979)

The use of objective methods in determine the amputation level will reduce the number of reamputations caused by a poor blood supply Moreover it is important to have reliable objective figures of the blood supply in case of wound complications caused by haematoma and/or infection If ischaemia can be excluded the stump may often be saved by early surgical revision and proper antibiotics

ACKNOWLEDGEMENTS

This study was supported in part by grants from "Hjerteforeningen" and from "Den laegevidenskabelige forskningsfond for Storkøbenhavn, Faerøerne og Grønland"

amputation and in 15 patients the AK amputation was secondary to a failed major amputation at a more distal level in 14 cases below the knee and in one case through the knee (TK) Forty nine of the patients undergoing AK amputation were capable of independent walking up to the period of major amputation

The surgical technique used was simple amputation at midthigh or low midthigh level the anterior flap often being longer than the posterior flap Myoplasty was not used Suction drainage was employed in most cases and the wound was dressed loosely (Tube gauze®) Sutures were removed on the 14th to the 21st postoperative day The patients were mobilized as soon as possible in a wheel chair or on walking appliances Prosthetic fitting was undertaken when the stump was well healed

Measurement of the SPP The SPP was determined as that external counterpressure which was just sufficient to stop the washout of an intradermal depot of radioactive isotopes (^{133}I - or ^{125}I antipyrine mixed with histamine) The technique has been described previously (Holstein et al. 1977) The site of measurement preoperatively was 10 cm proximal to the upper margin of the patella on the anterolateral side of the thigh i e. in most cases within a range of about 5 cm from the selected level of amputation In the 4th to 8th postoperative week measurements were again performed 10 to 15 cm proximal to the end of the stump Thus the postoperative measurements were often made at a more proximal site than the preoperative measurements. Control measurements were performed pre- and postoperatively on the contralateral leg preferably below the knee

Statistics P values were determined by rank sum tests, by Fisher's exact test and by Wilcoxon's test for paired comparisons.

RESULTS

Mortality Fourteen patients (24 per cent) died postoperatively during hospitalization six of these (10 per cent) within 1 month after the amputation Six patients (10 per cent) died with severe wound complications of the stump Two of these had bilateral AK amputations one died with bilateral stump necrosis and the other died with necrosis of one stump and with the sutures still in situ on the other – intact – stump Six patients died with well healed stumps and two patients died with the sutures not yet removed from an intact stump

Thus analysis of wound complications in relation to the preoperatively measured SPP (see below) could be made in 59 AK amputations in 56 patients – excluding the three intact stumps with sutures in situ at the time of death

The preoperative SPP Figure 1 and Table (upper panel) show the healing of the stumps in relation to the SPP The three cases with an SPP below 20 mmHg all had major wound complications In one case the patient died with total rupture and severe necrosis of the wound In two cases severe necrosis postponed the healing which was not complete until after 4 and 5 months respectively

Only one out of eight cases (12 per cent) with a preoperative SPP between 20 and 30 mmHg healed primarily In one case

Table 1 Age distribution in 62 cases of above knee amputation

	41–50	51–60	61–70	71–80	81–90	Total
Cases without diabetes mellitus		3	12	18	12	45
Cases with diabetes mellitus	1	1	4	6	5	1

Male/female ratio 38/24=1 58 Arithmetic mean age without diabetes mellitus (DM) 74 0 years With DM 72.6 years

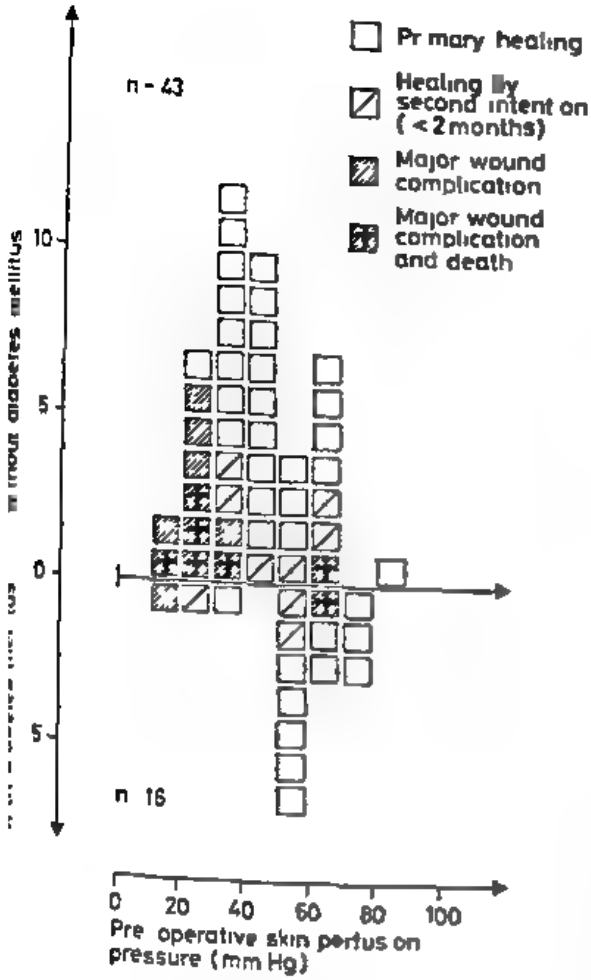

ure 1 Wound complications in 59 AK butations in relation to the local skin perfusion ture measured preoperatively

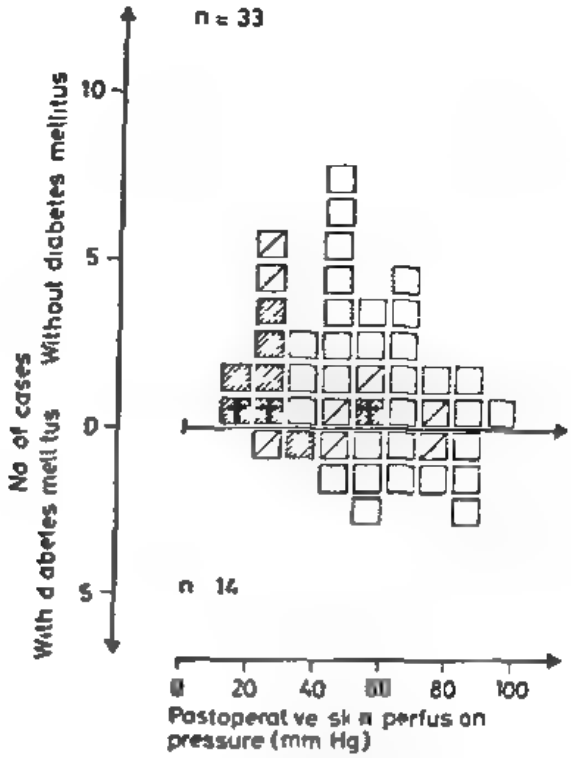

Figure 2 Wound complications in 47 AK amputations in relation to the local skin perfusion pressure measured postoperatively (The symbols are identical to those used in Figure 1)

ling of a minimal defect took place by ond intention within 6 weeks. The aining six patients all had major wound plications in one case severe necrosis yed the healing for 4 months, in two s major surgical revisions because of rosis and infection were necessary and in e cases the patients died with severe rosis of the stumps Thus, summarizing cases with SPP below 30 mmHg, 9 out of (82 per cent) suffered severe wound com- ations.

hirty-six out of the 48 cases (75 0 per) with a preoperative SPP of above mmHg healed primarily In eight cases ll defects healed rapidly, i e. within 2 ths. In four cases (8 per cent) major wound complications developed. In two of these cases – both with a preoperative SPP of 30–40 mmHg – i e on the borderline of the high risk group with an SPP below 30 mmHG – surgical revision because of severe necrosis was carried out In one of these cases the patient died with necrosis of the revised stump In two cases with normal SPP, i e 60 to 70 mmHg, the patients died with severe wound complications in one case with infection of the wound and sepsis (Klebsiella) and in the other case with rupture of the infected wound (Staph aureus) The clinical picture, a swelling, warm, red stump in these two cases with normal SPP and infection was very different from the necrotic appearance of the low pressure stumps.

These differences in primary healing rate and in major wound complication rate in the various SPP groups are highly significant for the total number of cases and for the 43 non-diabetic cases (Table 2 and Figure 1) In the

Table 2 The skin perfusion pressure (SPP) in relation to wound healing

		<20 mmHg			21–30 mmHg			>30 mmHg			Total
		Primary healing	Secondary healing <2 months	Major wound complication	Primary healing	Secondary healing <2 months	Major wound complication	Primary healing	Secondary healing	Major wound complication	
Pre-operative SPP	Without diabetes mellitus	0 (a)	0	2 (100 0%) (b)	1 (a)	0	6 (85 7%) (b)	25 (a)	6	3 (9 0%) (b)	43
	With diabetes mellitus	0	0	1	0	1	0	11	2	1	16
	Total	0 (c)	0	3 (100 0%) (d)	1 (c)	1	6 (75 0%) (d)	36 (c)	8	4 (8 3%) (d)	59
Post operative SPP	Without diabetes mellitus	0 (e)	0	2 (100 0%) (f)	0 (e)	2	4 (66 7%) (f)	21 (e)	3	1 (40%) (f)	33
	With diabetes mellitus	0	0	0	0	1	0	10	2	1	14
	Total	0 (g)	0	2 (100 0%) (h)	0 (g)	3	4 (57 0%) (h)	31 (g)	5	2 (5 2%) (h)	47

P value (rank sum test)
Distribution (a) 0 02
Distribution (b) 0 0006
Distribution (c) 0 006
Distribution (d) 0 0004

P value (rank sum test)
Distribution (e) 0 0016
Distribution (f) 0 0014

16 diabetic cases there were only two major wound complications (12 per cent) compared with 11 major complications (26 per cent) in the non-diabetic group ($0.5 < P < 0.10$). The SPP in the diabetic group (on average 58.1 mmHg) was however, significantly higher than in the non-diabetic group (on average 42.9 mmHg) ($P < 0.01$) and only two of the diabetic cases had an SPP of below 30 mmHg.

The SPP correlated significantly with the presence of palpable pulsation in the femoral artery but the healing rate did not (Table 3).

Among the 14 cases with AK amputations secondary to failed BK amputations the wound healed primarily in 12 cases. In one case the wound healed slowly (in 6 months) and in one case the patient died from wound infection. The average SPP at the BK level before the BK amputations in these 14 cases was 31.0 mmHg (range 8–63 mmHg) as against 54.3 mmHg (range 23–68 mmHg) at the AK level before the AK amputations ($P < 0.01$).

The postoperative SPP. It was technically possible to perform a postoperative measurement on the amputation stump in 47 cases. Primary healing and major wound complications correlated significantly with the postoperative SPP (Figure 2 and Table 2 lower panel) in the total number of cases as well as in the non-diabetic cases. Healing of the wounds in the 14 diabetic cases did not correlate significantly with the SPP. However there was only one case with an SPP below 30 mmHg and the SPP was on average significantly higher in the diabetic group than in the non-diabetic group: 60.5 mmHg (range 18–98 mmHg) compared with 50.1 mmHg (range 28–88 mmHg) ($0.02 < P < 0.05$). The rates of primary healing and of severe wound complications were better in the diabetic group although the differences were not significant.

The average SPP in the 47 cases measured postoperatively was 53.[illegible] mmHg (range 18–98 mmHg). This is slightly above the preoperative values 52.0 mmHg. However the site of the postoperative measurement was often more proximal than the preoperative site.

The amputation did not affect the SPP on the contralateral leg: the preoperative SPP averaged 56.7 mmHg (range 23–98 mmHg) and the postoperative SPP averaged 53.2 mmHg (range 23–88 mmHg) ($P > 0.10$). Correction of the postoperative SPP for changes in systemic blood pressure did not influence the result: corrected postoperative average SPP values 53.4 mmHg (23–87 mmHg) ($P > 0.10$).

Rehabilitation. The patients returned to their own homes in 28 out of 48 cases (58 per cent). Of the 49 patients who could walk prior to major amputation rehabilitation as

Table 3. Wound healing and skin perfusion pressure (SPP) in relation to the presence of pulsations in the femoral artery

	Pulsations in the femoral artery		
	No pulsations $n = 22$	Pulsations present $n = 37$	P value
SPP mean	30.2 mmHg	56.4 mmHg	$P < 0.01$
range	18–48 mmHg	18–88 mmHg	
Severe wound complications	8	5	$P > 0.05$
Primary healing	11	11	$P > 0.05$

Table 2 The skin perfusion pressure (SPP) in relation to wound healing

		<20 mmHg			21–30 mmHg			>30 mmHg			Total
		Primary healing	Secondary healing <2 months	Major wound complication	Primary healing	Secondary healing <2 months	Major wound complication	Primary healing	Secondary healing	Major wound complication	
Pre-operative SPP	Without diabetes mellitus	0 (a)	0	2 (100.0%) (b)	1 (a)	0	6 (85.7%) (b)	25 (a)	6	3 (9.0%) (b)	43
	With diabetes mellitus	0	0	1	0	1	0	11	2	1	16
	Total	0 (c)	0	3 (100.0%) (d)	1 (c)	1	6 (75.0%) (d)	36 (c)	8	4 (8.3%) (d)	59
Post operative SPP	Without diabetes mellitus	0 (e)	0	2 (100.0%) (f)	0 (e)	2	4 (66.7%) (f)	21 (e)	3	1 (40%) (f)	33
	With diabetes mellitus	0	0	0	0	1	0	10	2	1	14
	Total	0 (g)	0	2 (100.0%) (h)	0 (g)	3	4 (57.0%) (h)	31 (g)	5	2 (5.2%) (h)	47

P value (rank sum test)
Distribution (a) 0.02
Distribution (b) 0.006
Distribution (c) 0.006
Distribution (d) 0.0004

P value (rank sum test)
Distribution (e) 0.0016
Distribution (f) 0.0014
Distribution (g) 0.0016

who have lost the ability to walk for reasons other than the peripheral ischaemia and in these patients the aim of the amputation is to relieve a painful useless extremity with a minimum of discomfort In 13 cases in our series the patients belonged to this category In six cases the patients suffered wound complications which in four cases were related to an SPP below 30 mmHg These findings point towards the selection of a short stump in cases of inadequate blood supply in a weak patient. Only if the blood supply is adequate should a long stump, which is more comfortable during sitting and when moving in bed, be chosen

The level selection is more difficult in the second group where the patients have been able to walk up to the time of amputation. In these cases the result of the treatment should be considered satisfactory only if the ability to walk is regained by means of a prosthesis, 41 per cent achieved this in this series. In principle a long stump facilitates walking with a prosthesis and when this advantage is added to the previously mentioned comfort during sitting and moving in bed it seems justified to take the risk of ischaemic wound complications in order to obtain a long stump Slow healing may be obtained even when the SPP is of the order of 20 to 30 mmHg But this must be balanced against the risk of loss of ambulation in the event of a long period with a painful, slowly healing ulcer prohibiting prosthetic training – and early surgical revision should be considered in case of ulcers in order to shorten the healing time

There were fewer wound complications amongst the diabetic patients. This result can be explained by the significantly higher average SPP in the diabetic group This finding parallels the results in our series of BK amputations (Holstein et al 1979) and is discussed in that paper

Compared with our figures for BK amputations (Holstein et al 1979) the average duration of hospitalization for AK amputations was less. This finding agrees with Weaver & Marshall's observation (1973) A high mortality, a number of patients discharged to nursing homes soon after surgery and only a few reamputations, reduced average period of hospitalization in patients undergoing AK amputations

To summarize the SPP is a very reliable means of predicting ischaemic wound complications in AK amputations The implications of wound complications are however, very variable, ranging from healing by second intention with preservation of stump length to a life-threatening complication If ischaemic wound complications are to be avoided meticulous surgery is required and in non-mobile weak patients a short stump length is advocated in the case of a low SPP

ACKNOWLEDGEMENTS

This study was supported in part by grants from "Hjerteforeningen" and from "Den laegevidenskabelige forskningsfond for Storkøbenhavn, Faeroerne og Grønland"

REFERENCES

Dale, W A & Capps, W (1959) Major leg and thigh amputations. *Surgery* 46, 333–342

Hall, R & Schucksmith, H S (1971) The above-knee amputation for ischaemia *Brit J Surg* 58, 656–659

Hansson, J (1964) *The leg amputee*, pp 44–61 Thesis. Munksgaard, Copenhagen

Holstein, P (1973) Distal blood pressure as guidance in choice of amputation level. *Scand J clin Lab Invest* 31, (Suppl 128) 245–247

Holstein, P & Lassen, N A. (1977) Assessment of safe level of amputation by measurement of the skin blood pressure *Vascular surgery*, pp 107–111 W B Saunders Company Philadelphia, London, Toronto

Holstein, P, Lund, P., Larsen, B & Schoemacker, T (1977) Skin perfusion pressure measured as the external pressure required to stop isotope washout. Methodological considerations and normal values on the legs. *Scand J clin. Lab Invest* 37, 649–659

Holstein, P, Sager, P & Lassen, N A. (1979) Wound healing in below-knee amputations in

Table 4 Number of weeks spent in hospital in relation to primary or secondary AK amputation and rehabilitation

No of AK amputations	No of patients	Type of AK amputation	Weeks in hospital preoperatively mean*	range	postoperatively mean*	range
47	43	Primary	1 8	(0 1–8 0)	10 2	(0 5–52 0)
15	15	Secondary to failed BK or TK amputation	16 9	(4 0–39 0)	12 1	(0 5–48 0)

No of AK amputations	No of patients	Rehabilitation	preoperatively mean*	range	postoperatively mean*	range
20	20	Discharged walking	6 8	(0 1–38 5)	15 3	(3 0–31 0)
8	8	Failed attempt at walking	8 8	(0 5–24 0)	24 1	(6 0–56 0)
34	30	No attempt at walking	3 5	(0 5–9 0)	4 7	(0 5–40 0)

* Arithmetic mean per AK amputation

regards walking with a prosthesis was obtained in 20 cases (41 per cent) The walking ability was not regained in the remaining 29 cases due to death in 9 cases, to poor mental and physical condition in 15 cases and to bilateral major amputation in 5 ases

The average time spent in hospital per AK amputation was 15 8 weeks Table 4 shows that the *preoperative* period was about nine times longer in patients with failed major amputation at a lower level Rehabilitation or an attempt at rehabilitation as regards walking increased the *postoperative* time about three to five times Wound complications did not on average increase the period of hospitalization, but some of these patients died in the early postoperative period

DISCUSSION

The high mortality (24 per cent during hospitalization) reflects the often poor condition of the patients undergoing AK amputations Our figure falls within the rang of mortality rates of about 10–40 per cent i larger series in the literature (Dale & Capp 1959, Lempke et al 1963, Warren & Kih 1968, Hansson 1964, Otteman & Stahlgre 1965, Hall & Schucksmith 1971)

The healing of the AK amputations co related significantly with the pre- an postoperative SPP The poor results t patients with an SPP below 30 mmHg agre with previous findings in BK amputation (Holstein & Lassen 1977, Holstein et a 1979) Apart from a preliminary report on th series (Holstein 1973) no studies of wound healing in above-knee stumps in relation t objective measurements of the arterial suppl have previously been published Our rate o primary healing (62 7 per cent) is, however o the same order as that reported in large series in the literature (Dale & Capps 195 Schlitt & Serlin 1960, Warren & Kihn 196 Hall & Schucksmith 1971, Kihn et al 1972

In discussing the consequences of the SP in relation to AK amputations one must di tinguish between two different groups o patients The first group consists of patient

who have lost the ability to walk for reasons other than the peripheral ischaemia and in these patients the aim of the amputation is to relieve a painful useless extremity with a minimum of discomfort In 13 cases in our series the patients belonged to this category In six cases the patients suffered wound complications which in four cases were related to an SPP below 30 mmHg These findings point towards the selection of a short stump in cases of inadequate blood supply in a weak patient Only if the blood supply is adequate should a long stump which is more comfortable during sitting and when moving in bed be chosen

The level selection is more difficult in the second group where the patients have been able to walk up to the time of amputation In these cases the result of the treatment should be considered satisfactory only if the ability to walk is regained by means of a prosthesis, 41 per cent achieved this in this series In principle a long stump facilitates walking with a prosthesis and when this advantage is added to the previously mentioned comfort during sitting and moving in bed it seems justified to take the risk of ischaemic wound complications in order to obtain a long stump Slow healing may be obtained even when the SPP is of the order of 20 to 30 mmHg But this must be balanced against the risk of loss of ambulation in the event of a long period with a painful slowly healing ulcer prohibiting prosthetic training – and early surgical revision should be considered in case of ulcers in order to shorten the healing time

There were fewer wound complications amongst the diabetic patients. This result can be explained by the significantly higher average SPP in the diabetic group This finding parallels the results in our series of BK amputations (Holstein et al. 1979) and is discussed in that paper

Compared with our figures for BK amputations (Holstein et al 1979) the average duration of hospitalization for AK amputations was less. This finding agrees with Weaver & Marshall's observat 19 A high mortality, a number of pat charged to nursing homes soon afte and only a few reamputations re lu average period of hospitalization in p undergoing AK amputations

To summarize the SPP is a very reli means of predicting ischaemic wound co plications in AK amputations The im plications of wound complications are however, very variable ranging from healing by second intention with preservation of stump length to a life threatening complica tion If ischaemic wound complications are to be avoided meticulous surgery is required and in non mobile weak patients a short stump length is advocated in the case of a low SPP

ACKNOWLEDGEMENTS

This study was supported in part by grants from Hjerteforeningen' and from Den laegevidenskabelige forskningsfond for Storkebenhavn Faerøerne og Grønland'

REFERENCES

Dale W A & Capps, W (1959) Major leg and thigh amputations. *Surgery* 46, 333–342

Hall R & Schucksmith H S (1971) The above knee amputation for ischaemia *Brit J Surg* 58, 656–659

Hansson J (1964) *The leg amputee* pp 44–61 Thesis. Munksgaard Copenhagen

Holstein P (1973) Distal blood pressure as guidance in choice of amputation level *Scand J clin Lab Invest* 31, (Suppl 128) 245–247

Holstein P & Lassen N A (1977) Assessment of safe level of amputation by measurement of the skin blood pressure *Vascular surgery* pp 107–111 W B Saunders Company Philadelphia London Toronto

normal values on the legs. *Scand J clin Lab Invest* 37, 649–659

Holstein P Sager P & Lassen N A (1979) Wound healing in below knee amputations in

relation to skin perfusion pressure *Acta orthop scand* **50**, 49–58

ihn, R B, Warren, R & Beebe, G W (1972) The "geriatric" amputee *Ann Surg* **100**, 305–314

assen, N A & Holstein, P (1974) Use of radioisotopes in assessment of distal blood flow and distal blood pressure in arterial insufficiency *Surg Clin N Amer* **54**, 39–55

empke, R F, King, R D, Kaiser, G C, Judd, D & Nahrwold, D (1963) Amputation for arteriosclerosis obliterans *Arch Surg* **86**, 406–413

)tteman, M G & Stahlgren L H (1965) Evaluation of factors which influence mortality and morbidity following major lower extremity amputations for arteriosclerosis. *Surg Gynec Obstet* **120**, 1217–1220

Schlitt, R J & Serlin, O (1960) Lower extremity amputations in peripheral vascular disease *Amer J Surg* **100**, 682–689

Warren, R & Kihn, H H (1968) A survey of lower extremity amputations for ischaemia *Surgery* **63**, 107–120

Weaver, P C & Marshall, S A (1973) A functional and social review of lower-limb amputees. *Brit J Surg* **60**, 732–737

Correspondence to P Holstein, Surgical Department M, Bispebjerg Hospital 2400 Copenhagen NV Denmark

Acta orthop scand 50 67–71 1979

THE NEUROVASCULAR ISLAND PEDICLE FLAP

SVEND BOE

Department of Orthopaedic Surgery, Århus, County Hospital, Århus, Denmark

Nine patients with irreparable damage to the nerves of the thumb, treated with a neurovascular island pedicle flap from the third or fourth finger to the defect thumb, have been re-examined 9 months to 8 years after the operation

Eight patients had a 2-point discrimination of less than 15 mm corresponding to the flap and all had a positive Ninhydrin test. Two had complete cortical reorientation and three partial reorientation Six found the function of the thumb to be good or fair Three described the result as poor and three had to be reoperated because of contractures of the donor finger and/or thumb

The method can be recommended for use in young well motivated patients.

Key words peripheral nerve damage, neurovascular island pedicle flap reconstruction of the thumb, sensory loss in the hand

Accepted 18 vii 78

In the treatment of peripheral nerve damage to the functionally important areas of the hand, the principle of transferring a skin flap with associated neurovascular pedicle from a functionally less important area has been employed in cases where the continuity of the nerve could not be restored

The method was introduced by Moberg in 1955 Since then several minor modifications have been described (Littler 1960, Tubiana & Dupare 1961, Hueston 1965, Omer et al 1970) Also radial-innervated skin from the dorsum of the hand and fingers has been employed (Gaul 1969, Holevich 1963)

While originally used for restoring sensation to the thumb, it has also been used to protect the little finger in irreparable lesions of the ulnar nerve (Ranney & Lennox 1978)

Several reports concerning the long term results have been published (Murray et al 1967, Omer et al 1970, Krag & Bang Rasmussen 1975). Most authors have found the results to be less than optimal

As the indications and contraindications for the procedure have not been definitively established it was considered relevant to publish the results obtained in nine patients who during the last 8 years have had a neurovascular island pedicle flap transfer performed at the Department of Orthopaedic Surgery, Århus County Hospital All the patients have therefore been re-examined

PATIENTS AND METHODS

The age and sex of the patients is shown in Table 2 and the nature of the lesions in Table 1 All the patients had open, often dilacerated lesions, in several cases with associated damage to bones joints and tendons

The patient with the iatrogenic lesion sustained damage to the ulnar volar nerve during a resection of a recidivating epitheloid cyst.

0001 6470/79 010067–5$92.50/0

© 1979 Munksgaard, Copenhagen

The island transfer has in no case been performed as a primary procedure The time elapsing between the accident and the transfer is shown in Table 2.

In one case (patient no 2) we used the skin from the volar aspect of the proximal phalanx of the third finger, where the bones, joints and tendons were totally destroyed necessitating an amputation but the skin with vessels and nerves was left intact primarily In the other cases a healthy finger has been used The donor finger is stated in Table 2. In one patient (no 5) the radial part of the pulpa was used, in the others the ulnar part The operations were performed in a bloodless field, and under a general anaesthesia By a volar incision the volar artery and nerve in the donor site were dissected free The volar artery to the neighbouring finger and in some cases a dorsal perforant was divided between ligatures To obtain a sufficiently long pedicle the nervus digitalis palmaris communis was cleared bluntly After this an incision from the base of the pedicle to the ulnar aspect of the pulpa of the thumb was made, except in the first patient, where the flap was passed through a subcutaneous tunnel to the recipient site Defective skin corresponding in size to the flap was removed and the flap was fixed with sutures Hereafter the tourniquet was released to check the vitality of the flap and to secure haemostasis The defect on the donor finger has in some cases been covered with the excised skin from the thumb in other cases with a full thickness or a split skin graft taken from the elbow crease or from the femur After the wounds had healed sensory training was started (patients nos 1, 2 and 9) In this the blindfolded patient palpates and tries to recognize objects of various forms and textures

Table I The nature of the lesion

Pt no	Aetiology	Localization of lesion	Loss of thumb length	Associated lesions
1	moulding machine	thumb	distal phalanx	tendon the long flexor of the thumb
2	moulding machine	thumb	distal + part of proximal phalanx	nerve and flexor tendon to 2nd finger partial amputation of 3rd finger ½ distal phalanx of 4th finger
3	iatrogenic	thumb	—	—
4	spike wound	thenar	—	tendon of the long flexor of the thumb
5	roller	thenar	—	severe skin lesion on volar and dorsum surfaces. Lesion of rad coll ligament in 1st metacarpo-phalangeal joint Lesion of nervus digitalis palmaris communis 2
6	circular saw	thumb	—	severe skin lesion of the thumb, lesion of distal interphalangeal joint tendon of the long flexor of the thumb
7	hand ball	thumb	—	open luxation of inter phlangeal joint of thumb
8	grease gun	thumb	distal phalanx (secondary necrosis)	—
9	horse-riding accident	thenar	—	tendon of the long flexor of the thumb adductor muscle of the thumb severe skin lesion in 1st intertice

Table 2 Summary of patient's data, treatment and results

Patient no.	1	2	3	4	5	6	7	8	9
Sex	m	m	m	m	m	m	m	m	f
Age at accident	21	36	16	16	52	36	17	24	16
Months from accident to operation	24	11	9	8	9	4	6	24	5
Lesion of dominant hand	—	—	+	+	+	+	+	—	+
Donor finger	3	3	3	4	4	3	3	3	3
Observation time (years)	8	6½	5	4½	4	2	1	1	3/4
Work	ch	co	co	co	o	ch	co	ch	co
Change of dominant hand	—	—	—	—	+	—	—	—	—
Reorientation	+	+/—	+/—	—	—	—	+/—	—	+
Cold intolerance	(+)	(+)	(+)	(+)	++		—	+	—
Ninhydrin	+	+	+	+	+	+	+	+	+
2 pd flap area	14	8	12	7	—	8	4	8	4
Donor's ulnar neighbour	2	8	4		10	2	4	8	2
Picking-up open eyes	0.8	0.5	1.0	0.9	0.7	1.1	1.0	0.4	0.8
Picking-up closed eyes	1.0	0.4	1.0	0.6	0.4	0.8	0.8	0.3	0.8
Power total grip	0.7	0.6	1.1	0.9	0.4	1.0	0.9	0.1	0.9
Power pinch	0.9	0.9	1.0	0.8	0.3	0.8	1.0	[illegible]	0.8
Sharp/blunt discrimination	+	+	+	+	—	+	+	+	+
Touch	+	+	+	+	+	+	+	+	+
Temperature	+	+	+	+	—	+	+	—	+
Subjective judgement	G	G	F	P	P	F	G	P	G

Abbreviations
Sex m=male, f=female
Work ch=change, co=continued, o=out of work
Subjective judgement G=good, F=fair, P=poor
2 pd=2 point discrimination.
For further explanation see text

RESULTS

In no case has necrosis of the flap developed. In patient no 9 anaesthesia of the radical aspect of the donor finger's ulnar neighbour was found after the operation. The anaesthesia vanished completely during the next 2 months.

In three patients it has been necessary to undertake corrective procedures. Patient no 6 developed contractures of both the thumb and the donor finger, and callosities at the donor site, 4 months after the transfer a Z-plasty [illegible] of callosities and transplantation was [illegible] with good results. In another [illegible] (no 4) an arthrodesis of the [illegible]alangeal joint of the thumb was [illegible] 11 months after the transfer because of [illegible]racture. The third patient required excision of fibrous tissue from the donor site on four occasions, before a good result was achieved.

All nine patients have been re-examined by the author. The observation time was between 9 months and 8 years. The results are as stated in Table 2. Some of the points are commented upon below.

Dominant hand One patient changed the dominant hand. He continued to write with the right hand, while other activities were transferred to the left hand.

Paraesthesia Patient no 5 complained of paraesthesia in the flap area when pressure was applied in the first interstice. Patient no 3 complained of paraesthesia in the donor finger whenever the flap was touched.

Cold intolerance One patient had severe cold intolerance, most patients mentioned a slight, not annoying cold intolerance

Reorientation Four patients had no cortical reorientation (–) Three stated that they felt stimuli of the flap as coming both from the thumb and from the donor finger (+/–) Two had complete reorientation (+), but stated that sudden, unexpected painful stimuli of the flap area were felt as coming from the donor finger All patients with complete and partial reorientation stated that even several years after the operation the orientation was continuing to improve

Ninhydrin test In all patients a positive test was found in the flap area, although there was a great variation in the intensity of the reaction Corresponding to the donor area all had a negative reaction

Two point discrimination The test was performed by an ergotherapist experienced in 2-point discrimination testing, and with no former knowledge of the patients

Pain It was noted whether the patients were able to distinguish between the sharp and the blunt end of a needle

Touch It was noted whether the patients could feel anything at all in the flap area

Picking-up test The test was performed with open and with closed eyes During the test the index finger was covered with a rubber tip For convenience, not the actual values, but the ratio healthy hand/operated hand is given Thus values less than 1 0 indicate a poorer function

Power The total grip strength of the hand and the pinch between the thumb and index finger were measured with a dynamometer The value of the healthy hand was fixed at 1 0 and the value of the damaged hand calculated as a proportion of this

Mobility The mobility of all the joints of the upper extremity was measured with goniometer

One patient, as mentioned above had a arthrodesis of the metacarpophalangeal joint of the thumb In this patient a contracture resulted in a lack of extension of 45° in the interphalangeal joint of the thumb In all the other patients normal mobility was found apart from the limitations in mobility which were caused by associated lesions from the original injury

Trophic All the flaps were vital with no signs of atrophy

Subjective judgement The patient's own estimation of the functional value of the thumb is described as good (G) fair (F) or poor (P)

DISCUSSION

Six out of nine patients described the result as good or fair It is seen that all the patients have complete or partial reorientation A 2-point discrimination better than 1 mm is according to Moberg a condition of tactile gnosis A value better than 15 mm was found in eight patients No connection between the numerical value and the functional result was found, thus patient no 1 had poor 2 point discrimination but was functionally among the best The picking-up test is valuable but is very much affected by the sequelae of associated lesions The intensity of the Ninhydrin test was not found to be related to function, 2 point discrimination or the picking-up test

Three patients described the result as poor The main complaint of patient no 4 was the contracture which made the thumb sit in an awkward position for working He is now recommended for a Z-plasty, which most likely will improve the result

Patient no 5 had a severe lesion of the hand necessitating placement of the

eurovascular pedicle in cicatricial tissue He ras 52 years old The chances of a good esult were therefore rather dubious but the peration was tried as a last resort

Patient no 8 had a severe grease gun sion Postoperatively he developed deficient ensibility in the fingers innervated by the edian nerve, with a 2-point discrimination f 8 mm against 4 mm on the healthy hand Ve have no explanation for this

Major complaints from the donor finger vere not found but in three patients with ontractures or callosities reoperations were ecessary before a good result was achieved

Permanent disability due to the cleaving of ervus digitalis communis was not found but ne patient had a transient anaesthesia of the djoining finger, so the risk must be kept in and

Conclusions

The most important factor leading to a good result is cortical reorientation Therefore the method can be recommended for young patients who are well motivated, and who are able to cooperate in the training of cortical reorientation

2. Placing the pedicle in cicatricial tissue should be avoided.

Later corrective operations will often be necessary

Postoperative sensory training is important.

APPENDIX

ince this article was written we have treated wo more patients by this method As a con- ice of the importance of reorientation t shown in the article, sensory training was started even before the sutures could be removed The preliminary results are very encouraging However, the observation time is as yet too short so that these two patients have not been included in the review

REFERENCES

Gaul J S (1969) Radial innervated cross finger flap from index to provide sensory pulp to injured thumb *J Bone Jt Surg* 51 A 1257–1263

Holevich, J (1963) A new method of restoring sensibility to the thumb *J Bone Jt Surg* 45-B 496–502

Hueston J (1965) The extended neurovascular island flap *Brit J plast Surg* 18, 304–305

Krag, C & Bang Rasmussen K (1975) The neurovascular island flap for defective sensibility of the thumb *J Bone Jt Surg* 57-B 495–499

Littler, J W (1960) Neurovascular skin island transfer in reconstructive hand surgery *Transactions of the International Society of Plastic Surgeons*, Second Congress, London 1959 Ed Wallace, A B pp 175–178, E and

me

Murray, J F, Ord J V R & Gavelin, G E (1967) The neurovascular island pedicle flap *J Bone Jt Surg* 49-A 1285–1297

Orner, G E, Day, D J Raibf H & Lambert, P (1970) Neurovascular cutaneous island pedicles for deficient median nerve sensibility *J Bone Jt Surg* 52 A, 1181 1192

Ranney D A & Lennox, W M (1978) The protective value of a neurovascular island pedicle transfer in hands partially anesthetic due to ulnar denervation in leprosy *J Bone Jt Surg* 60-A 328–334

Tubiana R & Duparc, J (1961) Restoration of sensibility in the hand by neurovascular skin island transfer *J Bone Jt Surg* 43 B, 474–480

to Svend Boe Stationsgade 20 8240 Risskov Denmark

IEDIAL DISLOCATION OF THE TENDON OF THE ONG HEAD OF THE BICEPS BRACHII

IR SLATIS & KARI AALTO

ivision of Orthopaedic Surgery and Traumatology, Surgical Hospital
niversity Central Hospital, Helsinki, Finland

Medial displacement of the long tendon of the biceps brachii muscle [illegible] a rare condition associated with degenerative or traumatic ruptures of the rotator cuff This condition was recorded in nine shoulders during 45 reconstructive procedures on the rotator cuff Five of the displacements were complete, leaving the tendon medially displaced in a fascial sling, four were incomplete, allowing a to-and fro medial displacement of the tendon out of the intertubercular groove

[illegible]

be medially displaced

There was no pathognomonic clinical sign of the luxation or subluxation Since abnormal movement of the tendon in the sulcus may be an important cause of shoulder pain, the condition should be carefully looked for during reconstructive procedures on the rotator cuff Tenodesis of the displaced tendon is recommended, either as the sole procedure or in combination with other reconstructive measures

Key words shoulder joint, tendon injuries, ligaments

Accepted 6 VII 78

n 1926, Meyer observed among 286 natomical specimens of shoulder joints, four istances of complete medial displacement of e tendon of the long head of the biceps rachii He attributed this lesion to destruction of the anterior portion of the rotator cuff aused by forcible abduction and lateral otation. Later, Meyer (1928) described subluxations of the tendon, and drew attention o the high incidence of accompanying legenerative changes and fraying of the endon which predisposed to subsequent upture of the tendon's intra-articular portion Abbott & Saunders (1939) reported the first ix clinical cases of medial dislocation of the endon of the long head of the biceps brachii Later studies showed that medial dislocation of the tendon of the long head of the biceps is often associated with degenerative and traumatic ruptures of the rotator cuff (DePalma 1963) Heikel (1968) observed two medial dislocations of the tendon of the long head of the biceps in 72 patients operated on for cuff tears, Godsil & Linschied (1970) three dislocations in 79 shoulders. Wolfgang (1974) noted two luxations and six subluxations in 65 shoulders, in 27 of the 65, arthrotomy revealed definite concomitant changes in the biceps tendon

During reconstructive operative procedures on the rotator cuff in 45 shoulders we observed five cases of total medial displacement and four cases of subluxation of the tendon of the long head of the biceps brachii

001 6470/79 010073 05$02.50/0

© 1979 Munksgaard, Copenhagen

Prompted by these observations, we dissected anatomical specimens to try to elucidate the mechanics of the lesion. Because in reconstructive procedures of the rotator cuff recognition of this lesion is obviously important, we report here the results of the anatomical study and the features of the lesion

MATERIAL AND METHODS

Anatomical dissections At the Department of Forensic Medicine, University of Helsinki, eight shoulders in six cadavers were dissected. The cause of death was severe trauma or suicide, and the victims were all in the third to sixth decade The anatomical dissection focused on the interrelationship between the structures of the rotator cuff and the tendon of the long head of the biceps By transecting, one by one, the ligaments that enclose the tendon along its course in the intertubercular groove, we identified the ligament, which when transected permitted dislocation of the tendon. The depth of the sulcus was not measured.

Patient series The series comprised eight men and one woman from 26 to 62 years of age All had a definite history of trauma to the affected shoulder 2 to 48 months preoperatively In three patients a fall from a height had caused a forcible abduction and external rotation of the humerus, in one an anterior dislocation of the humeral head was the initial lesion, in one, weight lifting had stretched the shoulder in hyperextension, in one, a lateral impact on the shoulder was inflicted in a car accident and in three patients the lesion was initiated by a fall on the outstretched hand Indications for surgery in all patients were persistent pain in the shoulder combined in five patients with an inability to elevate the extremity to the horizontal plane and in four patients, with a painful snapping sensation in the shoulder on abduction and external rotation.

RESULTS

Anatomical observations

In the supratubercular area, the tendon is guided along its course by the stout coracohumeral ligament, which arises at the base

Figure 1 Cranial view of the head of the left humerus in an anatomical specimen showing the intra articular portion of the tendon of the long head of the biceps, and the coracohumeral ligament held away, by forceps, from its normal attachment to the coracoid process Note the tunnel formed in the supratubercular area by the two insertions of the ligament S=tendon of the subscapularis muscle, C=coracoid process

of the coracoid process and inserts both medially on to the lesser tubercle and laterally on to the greater tubercle of the humerus (Figure 1) The coracohumeral ligament fills the space between the superior border of the subscapularis muscle and the anterior border of the tendon of the supraspinatus muscle The ligament is an integrating part of the rotator cuff with which it blends and can only be distinguished by sharp dissection from the tendinous junctions bordering it

In the intact specimen we were unable to dislocate the tendon medially over the lesser tubercle Transection of the intertubercular transverse ligament allowed for no appreciable lateral or medial movement of the tendon However, when the portion of the rotator cuff above the lesser tubercle was additionally transected, the tendon could easily be displaced medially over and beyond the lesser tubercle, taking a new course across the tendon of the subscapular muscle (Figure 2)

Further anatomical dissection showed that the key ligament guiding the course of the

Figure 2 Excision of the supratubercular medial insertion of the coracohumeral ligament allows medial displacement of the tendon of the long head of the biceps Symbols as in Figure 1

endon of the long head of the biceps in the ntertubercular groove was the medial portion f the coracohumeral ligament close to its nsertion in the lesser tubercle When this igament was transected, the tendon could asily be displaced medially

Peroperative findings

In five patients arthrotomy revealed a omplete tear in the tendon of the upraspinatus muscle In all cases the rupture xtended anteriorly and medially into the corohumeral ligament, in two of the five patients he tear further extended posteriorly into the tendon of the infraspinatus muscle In all patients, the biceps tendon was medially displaced over the lesser tubercle, and lay on the ventral aspect of the tendon of the sub scapularis muscle (Figure 3) The sulcus was abnormally flattened due to a wearing down of the lesser tubercle by the attrition of the luxating tendon and to a shallowing of the sulcus by scar tissue The tendon itself was usually frayed and thick but easily movable sidewards In four patients the tendon of the long head of the biceps was subluxated with only a limited simultaneous lesion to the rotator cuff In these cases the tendon was located in the bicipital groove, but could easily be displaced medially into a fascial sling, formed from the ruptured edge of the medial portion of the coracohumeral ligament

Operative procedures

All five complete medial displacements and three of the four subluxations of the tendon of the long head of the biceps were treated by tenodesis. The tendon was severed from its supraglenoidal attachment and sutured to a cancellous bed in the greater trochanter close to the bicipital groove (Crenshaw & Kilgore 1966) In the remaining patient a weight-lifter, the tendon was replaced in its anatomical location after the sulcus had been deepened with care taken to preserve the gliding surface of the floor of the groove

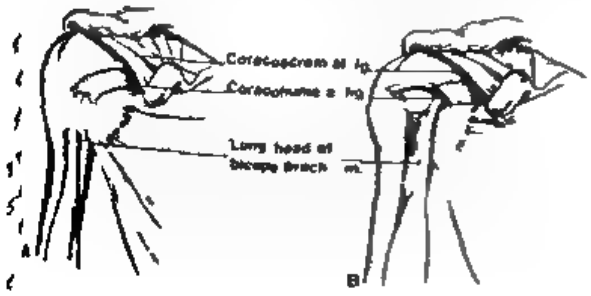

Figure 3A Diagram of the anterior aspect of the right glenohumeral joint showing the coracohumeral ligament (stippled area), the tendon of the long head of the biceps muscle and the subscapularis muscle

Figure 3B Diagram of the peroperative finding in five patients with medial displacement of the tendon of the long head of the biceps muscle Rupture of the coracohumeral ligament in the supratubercular area permitted dislocation of the tendon over the lesser tubercle on to the tendon of the subscapularis muscle The lesion was associated with degenerative changes in the rotator cuff varying from a local avulsion of the medial insertion of the coracohumeral ligament to an extensive rupture of the rotator cuff

In cases with severe simultaneous rupture of the rotator cuff, the intra-articular portion of the tendon above the tenodesis was interposed between the retracted edges of the ruptured cuff This enabled closure of the tear without tension When the associated lesion to the cuff was limited, the portion of the tendon above the site of the tenodesis was resected

After the operation, a Velpeau dressing was kept on for 3 weeks, and active exercises were begun from the third postoperative week. In the one patient who was treated by replacement of the tendon in the groove, the tendon ruptured 3 weeks after the operation and a tenodesis was performed

All patients were eventually relieved of their shoulder pain. Of those in whom the torn rotator cuff was reconstructed, function was good in two, fair in two and poor in one All patients treated with tenodesis, in whom the rotator cuff had been only partly affected, regained good function in the shoulder joint

DISCUSSION

Two anatomical features in the human glenohumeral joint may predispose to medial displacement of the long tendon of the biceps muscle Firstly, because the human thoracic cage is flattened, the shoulder is more outwardly rotated in man than in other primates. Hence, the bicipital groove faces ventrally, and the bicipital tendon, even in the normal position, is pressed against the medial wall of the intertubercular sulcus Secondly, the medial wall of the bicipital groove is often inadequately developed, with a slanting wall that offers only a tiny fulcrum for the tendon during its course from the supraglenoidal attachment above to the muscle belly below (Hitchcock & Bechtol 1948)

Pathological changes in the adjacent ligaments and tendinous attachments must occur, however, before the tendon can dislocate out of the groove The results of this study indicate that the key ligament which keeps the tendon down in the sulcus and guides its movements in the upper aperture of the sulcus is the medial portion of the coracohumeral ligament. Rupture of this ligament, either because of degenerative disease or trauma makes pathological medial excursions of the tendon possible Degenerative ruptures initiate a traumatic synovitis in the synovial pouch around the tendon, which provokes subsequent adhesions, fraying of the tendon, a susceptibility to medial subluxation and, finally, a persistent medial displacement of the tendon A severe trauma may rupture the anterior part of the rotator cuff and cause an immediate medial displacement In both instances the peroperative finding is similar the tendon is located in a newly formed fascial sling on the ventral aspect of the subscapularis tendon The medial wall of the sulcus is eventually worn down by attrition and the sulcus becomes filled with scar tissue

Clinically, there is no pathognomonic sign of a medial dislocation of the long head of the biceps brachii A history of trauma seems to be common, especially a forcible abduction and external rotation of the arm, as may occur when adjacent solid structures are grasped at during a free fall Our anatomical study showed that such a movement stretches the coracohumeral ligament, a forcible overstretch can obviously cause a tear in the anterior part of the rotator cuff including the coracohumeral ligament Abbott & Saunders (1939) noted that some patients experienced a snapping sensation as the tendon slipped in and out of the groove, four of our patients experienced similar sensations Lippmann (1943) and Crenshaw & Kilgore (1966) regard bicipital synovitis as a clinical entity in which there is local tenderness in the bicipital groove

The role of the long tendon of the biceps muscle in the puzzling problem of shoulder pain is still poorly understood. Current clinical observations indicate that pathological changes in the tendon are common and may be of prime aetiological importance Ruptures of the rotator cuff are often accompanied by

fraying and thickening of the tendon, by synovitis and adhesions in the intertubercular groove, as well as by pathological medial excursions of the tendon. During reconstructive procedures on the shoulder capsule these changes should be carefully looked for and evaluated Medial displacement of the tendon is easily recognized, and should be treated either by tenodesis alone or in combination with other reconstructive procedures on the rotator cuff

REFERENCES

Abbott, L C & Saunders, J B de C M (1939) Acute traumatic dislocation of the tendon of the long head of the biceps brachii *Surgery* **6**, 817–840

Crenshaw, A. H & Kilgore, W E (1966) Surgical treatment of bicipital tenosynovitis. *J Bone Jt Surg* **48 A**, 1496–1502.

DePalma, A F (1963) Surgical anatomy of the rotator cuff and the natural history of degenerative periarthritis *Surg Clin N Amer* **43**, 1507–1520

Godsil, R D Jr & Linschied R L (1970) Intratendinous defects of the rotator cuff *Clin Orthop* **69**, 181–188

Heikel, H V A (1968) Rupture of the rotator cuff of the shoulder *Acta orthop scand* **39**, 477–492

Hitchcock, H H & Bechtol, C O (1948) Painful shoulder *J Bone Jt Surg* **30-A**, 263–273

Lippmann, R K (1943) Frozen shoulder, periarthritis, bicipital tenosynovitis *Arch Surg* **47**, 282–296

Meyer, A W (1926) Spontaneous dislocation of the tendon of the long head of the biceps brachii *Arch Surg* **13**, 109–119

Meyer, A W (1928) Spontaneous dislocation and destruction of tendon of long head of biceps brachii *Arch Surg* **17**, 493–506

Wolfgang G L (1974) Surgical repair of tears of the rotator cuff of the shoulder *J Bone Jt Surg* **56-A**, 14–26

Correspondence to Par Slatis, M D, Surgical Hospital Kaserngatan 11 13, 00130 Helsinki 13, Finland

Acta orthop. scand 50, 79–83, 1979

THE SIGNIFICANCE OF ASSOCIATED LESIONS INCLUDING DISLOCATION IN FRACTURES OF THE NECK OF THE RADIUS IN CHILDREN

STEN LINDHAM ■ CLAES HUGOSSON

Department of Paediatric Surgery and Department of Paediatric Radiology, Karolinska Hospital, Sweden

A series consisting of 29 children with markedly dislocated fractures of the neck of the radius has been analysed The method of measuring the angular dislocation is discussed A true dislocation not exceeding 30° may be left unreduced Associated skeletal lesions of the elbow imply a less favourable prognosis

Key words associated lesions, childhood, dislocation, fracture, radial neck

Accepted 13 IX.78

According to Blount (1955) 4 5 per cent of all elbow fractures in children affect the proximal radial epiphysis or the radial neck Fractures through the head of the radius are less common

Fractures of the radial neck occur with equal frequency in boys and girls (Jeffrey 1950, Henriksson 1969, Jones & Esah 1971), whereas most other fractures in childhood show male preponderance

The mechanism of injury is a fall on the outstretched hand. An increased carrying angle is common in these patients (Henriksson 1969) and might be regarded as a predisposing factor The trauma produces a compression force on the radial side and distraction on the medial side of the elbow joint (Jeffery 1950) In fractures involving the neck of the radius the head may become tilted in any direction, lateral dislocation is, however, most common The head may even become completely displaced Fractures of the proximal part of the radius are often associated with other injuries of the elbow joint (Watson-Jones 1976)

The purpose of this investigation was to establish the significance of the recorded dislocation of the head of the radius in children and to assess the prognostic implications of associated skeletal lesions in the same elbow

PATIENTS AND METHODS

From January 1964 through June 1976, 1928 elbow fractures were treated at the Department of Paediatric Surgery, Karolinska Hospital. Of these, 141 or 7 0 per cent were fractures of the neck of the radius. Only one patient (not included in this series) sustained a fracture through the head of the radius. The films of the 141 patients were reviewed in order to reassess the dislocation recorded at the initial examination In most cases films of the contralateral elbow had been exposed for comparison. The degree of dislocation was measured on the a p and the lateral films of the elbow

In children the normal angle between the long axis of the neck of the radius and the long axis of the upper part of the shaft amounts to 12–15° This angle, measured on films of the contralateral elbow, was subtracted from the primary recorded angulation in order to give the true dislocation Associated lesions of the injured elbow were also registered

0001 6470 79 010079–05$02.50/0

© 1979 Munksgaard Copenhagen

A corrected dislocation of less than 10° was found in 112 patients. Among them were 16 children with minor associated lesions, mostly fissures of the olecranon. All these 112 patients had been treated with immobilization for 3 weeks. They all recovered uneventfully according to the charts, and were therefore dismissed from further studies.

The remaining 29 patients, all with angular displacement of the neck of the radius exceeding 10°, were subjected to a follow-up study. There was no difference in sex distribution. Both elbows were affected with equal frequency. The mean age of the patients at the time of injury was 9 years and 4 months (range 6–14 years). In 16 of the 29 patients one or more associated lesions of the same elbow were radiologically demonstrable. All the 29 patients received questionnaires 1–10 years after the accident, in which inquiries were made about deformity, pain, sensibility disorders, weakness and/or limitations of movement in the injured arm.

Table 1 Degree of true angular dislocation and treatment given

Dislocation		Treatment		
Degree	Number	Immobilization	Closed reduction	Open reduction
11–30	13	5	2	3
31–45	4	2	2	0
> 45	12	0	2	10
Total	29	10	6	13

Clinical and radiological follow-up examinations were performed in all patients who complained of any of these disabilities. The material is summarized in Figure 1.

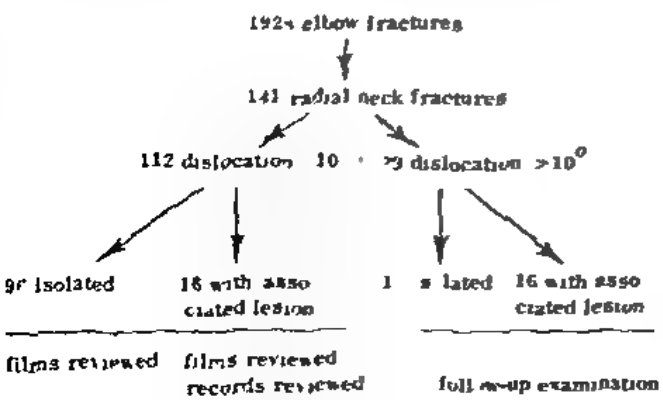

Figure 1 Summary of 141 radial neck fractures in the present investigation

RESULTS

The true angular dislocation of the radial head among the 29 patients with dislocations exceeding 10° and their treatment are shown in Table 1. Ten patients were treated with immobilization only. In 13 closed reduction was attempted. It was successful in six, while open reduction had to be performed in seven. In six additional cases with severe dislocation open reduction was performed primarily. Internal fixation of the radial head was not utilized.

Table 2 illustrates the difference in angulation of the radial neck before and after treatment. The 22 associated lesions found in 16 patients are listed in Table 3. The four patients with dislocation of the elbow were treated with reduction. One of the seven fractures of the olecranon had to be treated with open reduction and osteosynthesis. The

Table 2 Dislocation before and after treatment

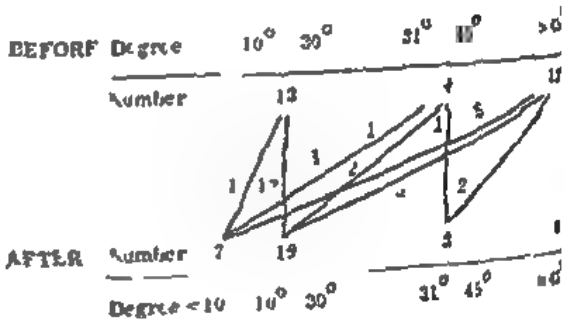

Table 3 Associated lesions found in 16 children with dislocated radial neck fracture. Except for one fracture of the olecranon the associated fractures showed only minor or no dislocation

Type of lesion	Number
Dislocation of elbow	4
Fracture of	
olecranon	6
medial epicondyle	4
lateral epicondyle	1
capitulum humeri	1
Total	22

remaining 17 associated lesions consisted of small fragments sheared from the epicondyles and infractions of the olecranon, the epicondyles or the capitulum humeri None of these 17 injuries was given any specific treatment All injured elbows were immobilized in plaster for 3–5 weeks. After immobilization active exercises but no passive stretching was employed.

The results were classified as excellent, good or poor The result was excellent if the patient had a normal range of movement, no apparent deformity, no pain, sensibility disorder or weakness in the arm The result was considered good if the patient had minimal subjective symptoms and restriction of motility less than 20° in either pronation, supination flexion or extension In cases with more marked limitation of motility, marked subjective symptoms or apparent deformity, the result was classified as poor

In Table 4 the functional results are compared with the remaining angulation of the radial neck after treatment No significant correlation could be established Table 5 illustrates that a correlation was found between the results and the presence of associated lesions demonstrated radiologically The result was excellent in 11 out of 13 patients with an isolated fracture of the neck of the radius but in only 2 out of 16 patients with associated lesions.

Table 4 Dislocation after treatment and results No correlation was found

Dislocation after treatment		Results		
Number	Degrees	Excellent	Good	Poor
7	10	2	3	2
19	10 30	9	4	6
3	31 – 45	2	1	0

Table 5 The results correlated with the presence of associated lesions

Associated lesions	Results		
	Excellent	Good	Poor
Demonstrable	2	[illegible]	8
Not demonstrable	11	2	0

DISCUSSION

Fractures of the proximal radius comprised 7 per cent of all elbow fractures in our department during the last 12 years The therapeutic approach to this lesion, especially whether or not reduction should be performed, is still discussed in the literature In children above the age of 8 Jones & Esah (1971) and Pollen (1973) considered 15° of angulation of the radial neck as the upper limit for treatment without reduction, while Blount (1955) and Salter (1970) accepted an angle of 40°, and Watson-Jones (1976) an angle of 45° In cases with displacement exceeding the figures given above closed reduction and, that failing, subsequent open reduction has been recommended All authors agree that removal of the radial head is contraindicated in children, because it results in severe deformity and reduced motility of the elbow joint

With the exception of Jeffery (1950), very little attention has been paid to the problems involved in the estimation of the angular dislocation of the fractured neck of the radius In the frontal view of an uninjured arm, there is laterally an open angle between the long axis of the neck and the long axis of the upper part of the shaft of the radius This angle represents a projection of the true neck-shaft angle on the a-p film and of course changes with rotation of the radius. It is closest to the true angle with the forearm in supination In a large number of intact elbows we found this angle to have a mean value of 12° with the forearm in supination and to decrease to 5° when the forearm was pronated to midposition (Figure 2) The valgus strain caused by the typical



Figure 2 The normal appearance, on the a p film, of the radius in (A) supination with a shaft neck angle of 12°, (B) midposition with a shaft neck angle of 5°

Figure 3 A-p and lateral view of the elbow Direction of dislocation and true angular dislocation is not adequately shown



Figure 4 Same case as Figure 3 A p and lat views of the forearm demonstrate both direction of dislocation and the true angle of fracture (49°)

mechanism of injury tilts the radial head i lateral direction If the forearm is supina at the moment of impact the ensuing dislo tion is a truly lateral one However, with forearm pronated at the time of the vali strain, the head will be tilted towards facies dorsalis of the radius. Thus, the t angular dislocation can only be estima when attention is paid to the normal ne shaft angle as well as to the direction

which the dislocation has occurred We recommend the use of a-p and lateral views of the forearm instead of the routinely used a-p and lateral views of the elbow which have not proved sufficient for the assessment of the true angular dislocation (Figures 3 and 4)

On the basis of our experience we feel that a true tilting of less than 30° may be left unreduced with impunity In cases with more marked dislocation closed reduction should be tried If unsuccessful, open reduction is recommended In cases where the head of the radius is completely avulsed and the angular dislocation approaches 90° we have refrained from attempts at closed reduction in order to avoid further damage to the epiphysis. The technique for closed and open reduction has been described in the literature by several authors (Jeffery 1950, Blount 1955, Judet et al. 1962 and Watson-Jones 1976) Internal fixation was not necessary in any of our cases.

As shown in Tables 4 and 5 the result of treatment was poor in 8 of our 29 patients, although the dislocation after treatment in all cases was less than 30° In all these patients, however, one or several associated injuries of the elbow were seen In the literature, there are very few comments on the clinical importance of associated skeletal injuries of the ipsilateral elbow in children with radial neck fractures. Most of the associated lesions in the present series were considered to be minor injuries We feel that the associated lesions should be considered as an indication of a violent trauma to the elbow joint and the surrounding soft tissues Thus the presence of associated skeletal injuries is a premonition of a less favourable prognosis At the follow-up radiological examination the development of spurs could be demonstrated only in patients with associated lesions Occasionally the head of the radius appeared enlarged with somewhat irregular contours This feature equally frequent in patients who had been treated with closed or open reduction, did not, however, influence the functional result

REFERENCES

Blount, W P (1955) *Fractures in children* pp 56–57 Williams and Wilkins Co, Baltimore

Henriksson B (1969) Isolated fractures of the proximal end of the radius *Acta orthop scand* 40, 246–260

Jeffery, C C (1950) Fractures of the head of the radius in children *J Bone Jt Surg* 32 B, 314–324

Jones, [illegible] R. L & Esah, M (1971) Displaced fractures of the neck of the radius in children *J Bone Jt Surg* 53-B 429–439

Judet, J, Judet, R & Lefranc, J (1962) Fracture du col radial chez l'enfant *Ann Chir* 16, 1377 1385

Pollen, A G (1973) *Fractures and dislocations in children*, pp 68–74 Churchill Livingstone Edinburgh and London.

Salter, R B (1970) *Textbook of disorders and injuries of the musculoskeletal system* p 431

Wa

York.

Correspondence to Sten Lindham Department of Paediatric Surgery, Karolinska Hospital 104 01 Stockholm Sweden

85–86 1979

LOCATION OF THE TRAPEZIUM (MULTANGULUM MAJUS)

Case Report

BOE

of Orthopaedic Surgery, Århus County Hospital, Århus, Denmark

A case of complete, closed dislocation of the trapezium is reported. The treatment was open reposition and fixation with two Kirschner wires. No avascular necrosis occurred. Two and a half years after the injury there were no subjective complaints, the mobility and strength of the thumb were normal and there were no radiological signs of arthrosis.

Key words carpal bones, dislocations multangulum majus, trapezium, wrist injuries

Accepted 12 vi.78

Dislocation of the trapezium is an extremely rare injury. Only 14 cases have been described in the literature and only about one third of these were complete dislocations. A case of complete, closed dislocation is presented here.

CASE REPORT

A 23 year-old man, a truck-driver, had his left hand compressed between a container and a truck he was unloading. At a local hospital he was treated with elevation of the hand and a dorsal plaster slab. Five days after the injury he was admitted to the Orthopaedic Department, Århus County Hospital. Diffuse oedema of the hand was still present, and distinct pain was elicited by palpation in the tabatière. There was no apparent deformity. The sensibility was normal and the movement of the thumb was only slightly restricted. X ray examination including tomography and stereoscopic investigation showed the trapezium to be dislocated in a radial and dorsal direction. The articulation with the scaphoideum, the trapezoideum and the first metacarpal bone was involved. Thus, it was a complete dislocation. Furthermore, a couple of small, bony avulsions from the ulnar and volar parts of the trapezium were seen (Figure 1).

Closed reduction was attempted but was unsuccessful. Open reduction was performed through a transverse incision in the tabatière, and the bone was fixed with two Kirschner wires (Figure 2). The arm was immobilized in a circular plaster cast, including the proximal phalanx of the thumb, and including the elbow to prevent pronation-supination. After 4 weeks the Kirschner wires were removed, but the immobilization was continued for a further 3 weeks. After 4 weeks of training there were no subjective complaints, and the mobility and strength of the thumb were normal. The patient returned to his former occupation. There was no avascular necrosis and two and a half years later no radiological signs of arthrosis were found.

DISCUSSION

The ligaments attaching the trapezium to the surrounding bones are very strong. Therefore complete dislocaton of the trapezium is only seen after violent, direct trauma. Indirect trauma, transmitted by the thumb, may produce an incomplete dislocation, leaving the carpometacarpal joint intact while the trapezio-carpal articulations are disturbed.

3001–6470/79/01008[illegible]–02$02.50 0

© 1979 Munksgaard, Copenhagen

igure 1 Preoperative X ray Complete dislocation f the trapezium

Figure 2 The dislocation has been reduced and t trapezium transfixed with Kirschner wires

The case reported by *Siegel & Hertzberg* 1969) was complicated by a *lesion of the* notor branch of the *median* nerve This was ot found *in the present case*

As regards treatment, *opinions are divided* 'losed reduction ■ *sometimes possible (Dunn* 972) *Russell (1949)* reported a case of anterior lislocation where reposition was not possible, he dislocation was accepted and almost iormal function of the thumb was achieved lowever, this case was an *incomplete* dis ocation with an *intact carpometacarpal* joint 'eterson *(1950)* recommended excision of the rapezium and reported good results in *two* atients treated ■ this way *His reason for* xcision was the avascularity of the luxated one Siegel & Hertzberg *(1969)* and Seimon *1972)* used open reposition and fixation with Kirschner wires Both patients developed a tiff carpometacarpal joint, *however* the unctional result was *good Both the cases* vere open dislocations, *with* severe soft tissue injury, and this may have contributed to t stiffness They did not report avascul necrosis, neither was ■ seen in the prese case Considering this open reposition a Kirschner wire fixation are recommended.

REFERENCES

Dunn A. W (1972) Fractures and dislocations the carpus *Surg Clin N Amer* 5 1513–1538

Peterson C L (1950) Dislocation of the m tangulum majus or trapezium and ■ treatme in 2 cases with extirpation *Arch chir ner* 2, 369–376

Russell T B (1949) Intercarpal dislocations ■ fracture-dislocations. *J Bone Jt Surg* 31 B 524–531

[illegible] 1972 Compound dislocation of th [illegible] 1300 [illegible]

orrespondence ■ Svend Boe Stationsgade 20 8240 Risskov Denmark.

cta orthop scand. 50, 87–91, 1979

TORSION DEFORMITIES AFTER TRACTION TREATMENT OF FEMORAL FRACTURES IN CHILDREN

RÅL BENUM KÅRE ERTRESVÅG & KÅRE HØISETH

urgical Department II and the Department of Radiology,
Ullevål University Hospital, Oslo, Norway

The torsion of both femurs was investigated in 55 patients who had been treated 5–13 years earlier at the age of 1–16 years for femoral shaft fractures. By comparing the anteversion angle of the contralateral hips, determined by the Rippstein method, torsion deformities exceeding 10 degrees were found in the fractured femur of 10 patients. The maximum deformity found was [illegible] degrees. None of [illegible]

tion between age at the time of injury and torsion abnormalities and no correlation between the length of the observation period and the residual deformity, indicating growth correction Examination of the rotational mobility of the hips was found to be a suitable screening test in the diagnosis of deformities exceeding 10 degrees Radiological investigation of the anteversion angle of the femoral neck is necessary in the final assessment of a torsion deformity

Key words femoral fracture, children torsion deformities, growth correction

Accepted 5 VIII 78

Numerous studies of the development of axial deformities following femoral fractures in children have been performed Most of these studies (Conwell 1929, Stray 1938, Neer & Cadman 1957, Barfod & Christensen 1958, Staheli 1967, Burwell 1969 and Griffin et al 1972) have dealt with the problems of discrepancy of bone length and angular [illegible]ies. Little attention has been paid to [illegible]ion deformities following the traditional [illegible] treatment methods in these fractures. [illegible]ontobel et al. (1961) seem to be the first in[illegible]gators to have tackled this problem by [illegible] of radiological determination of the anteversion deformity of the fractured femur They found that significant torsion deformities may develop as a result of traction treatment More recently only a few studies have dealt with this problem (Hupfauer & Balan 1971, Parvinen et al 1973) The purpose of the present study was to present additional information about the occurrence of torsion deformities after traction treatment of femoral fractures in children

MATERIAL AND METHODS

During the years 1963–1970, 102 children with dislocated femoral shaft fractures were treated in Surgical Department II, Ullevål University Hospital Oslo The material consists of 55 of

0001 6470 79 010087 05$02.50/0

© 1979 Munksgaard, Copenhagen

Table 1 Material

Total number of patients		55
Patients treated with adhesive traction		15
Patients treated with wire traction		40
Age at injury		1–16 years
	mean	6 5 „
Observation period		5–13 years
	mean	8 0 „

these patients who were available for re-examination 5 to 13 years after injury Their age at the time of injury varied between 1 and 16 years All were treated conservatively Most children under 3 years of age were treated by vertical adhesive traction of the fractured extremity only All children older than 3 years, with the exception of two, were treated with tibial or femoral Kirschner wire traction with the limb resting on an oblique frame (Table 1)

Methods of investigation

Radiological examination The anteversion angle of the femoral neck of both femurs was determined using the projections described by Rippstein (1955) For this technique two projections are required one AP-projection of the hips in neutral position and one AP-projection of the neutrally

angles (AV-angles) were measured in the respective radiographs with a roentgen-ischiometer in accordance with Müller (1957) The true AV-angles were then calculated from the

Clinical investigation. The patients were questioned regarding function and complaints. Their gait was studied in order to detect torsion deformities The rotational mobility of the hips was examined with the patients in the prone position, their knees flexed 90 degrees. The range of rotational mobility of the hips was measured with a device with 5 degree steps, the nearest step on the scale being recorded as internal and external rotational mobility when the legs were turned maximally outwards and inwards, respectively

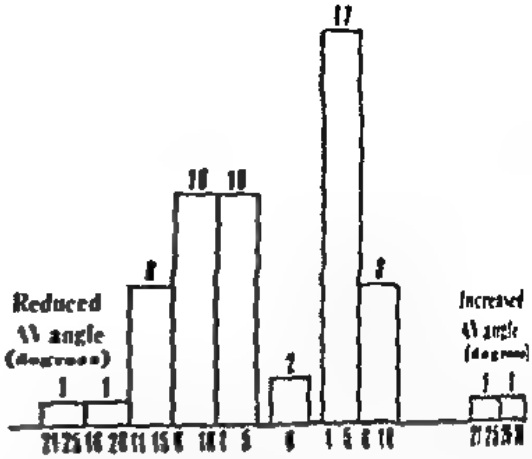

Figure 1 Difference in the anteversion angle (AV-angles) of the fractured and the contralateral femurs The figures over the columns indicate the number of patients

RESULTS

In 26 of the 55 cases the anteversion angles of the contralateral hips calculated from the X-rays differed more that 5 degrees. The difference exceeded 10 degrees in ten cases and 15 degrees in four (Figure 1). The largest calculated difference was 27 degrees. The *relationship* of the difference in the contralateral angles of anteversion to the age of the patients at injury and to the method of

test, $R_s = -0\ 1044$, $n = 55$, $P > 0\ 5$). In patients treated with adhesive traction the anteversion angles differed more than 10 degrees in 5 of the 15 patients. A corresponding difference was found in only 5 out of the 40 patients treated with wire traction. Thus treatment with adhesive traction tended to give a greater number of rotational deformities than wire traction. However, the difference was not highly significant ($X^2 = 3\ 17$, $0\ 05 < P < 0\ 100$).

The relationship between the difference in the femoral neck anteversion of the contralateral hips and the length of the follow-up period is shown in Figure 3 There was no significant correlation between these two

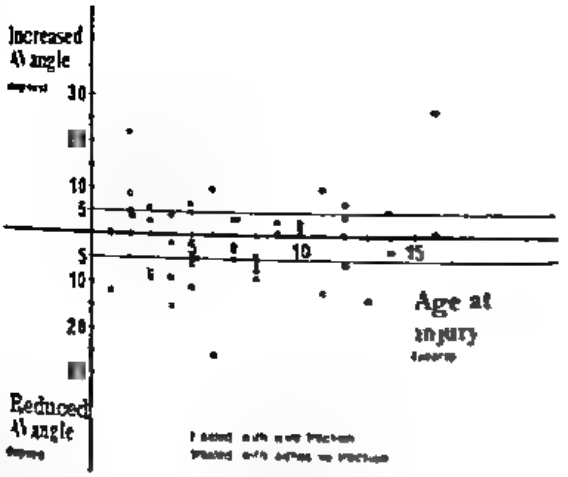

Figure 2 Difference in the AV-angle of the fractured and the contralateral femur related to age at injury

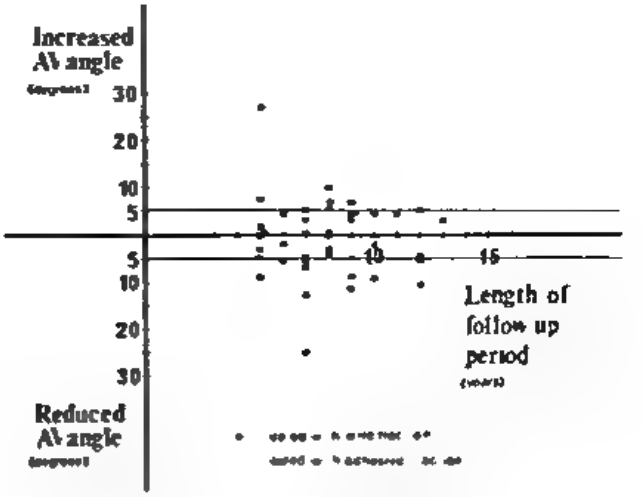

Figure 3 Difference in the AV-angle of the fractured and the contralateral femur related to the length of the follow-up period

actors (Spearman rank test, $R_s = 0.0886$, $n = 55$, $P > 0.10$)

None of the patients had complaints which could be attributed to torsion deformity of the fractured femur. A markedly abnormal foot angle was observed in only one patient. This was in a boy with a decreased anteversion of the femoral neck of 25 degrees. The radiographs of the hips of this patient are shown in Figure 4.

In patients in whom the AV-angle of the contralateral hips differed by more than 10 degrees, the abnormal anteversion of the fractured femur was associated with an expected change in internal or external rotation of at least 10 degrees (Table 2). Smaller abnormalities in anteversion were not consistently accompanied by change in the range of rotational mobility.

DISCUSSION

Radiological measurement of femoral neck anteversion by the Rippstein method is well standardized. However, inadequate position-

Table 2 Difference in rotational mobility in relation to the difference in AV-angles in patients in whom the AV-angle of the fractured femur differed by more than 10 degrees from that on the contralateral side

Case	Difference in AV-angle (degrees)	Difference in internal rotation (degrees)	Difference in external rotation (degrees)
1	−11	−10	0
2	−12	0	+10
3	−12	−10	+10
4	−12	−5	+15
5	−13	−15	+15
6	−15	−10	+10
7	−16	−10	0
8	−25	−20	+10
9	+22	+15	0
10	+27	+20	−15

Figure 4 Radiographs of the hips of a 13 year old boy 7 years after wire traction treatment for fracture of the right femur A AP projection of the hips in neutral position showing the apparent CCD angles B AP projection of neutrally rotated hips in a position of 90 degrees flexion and 20 degrees abduction showing the apparent AV angles

By calculation the AV angle of the right femur was found to be reduced by 25 degrees

ing of the hips may lead to errors in the determination of the AV-angles (Gross & Haike 1970) If the method is used to determine the torsion deformities following fractures, as in the present study a normal biological variation in the torsion axis of the contralateral femurs has to be taken into account The results of our investigation of normal hips indicate that differences between the anteversion angles of the contralateral hips exceeding 5 degrees could indicate torsion abnormalities Accordingly t deformities occurred in approximately cent of the patients. In only 10 of t patients did the deformities excee degrees In 4 patients the deformity greater than 15 degrees These results accordance with those presented by Von et al (1961) and Hupfauer & Balan (1 and with those published by Yano & Sa (1975)

The large number of torsion abnorma among patients treated with unila adhesive overhead traction indicates that difficult to maintain the correct tor axis of the fractured femur by this metl However, the finding of torsion deformitie up to 27 degrees in patients treated with v traction show that even traction on an obl frame may lead to considerable deformity

There was no significant difference c cerning the degree and frequency of tors deformities in relation to the length of t observation period This indicates that significant growth correction of the tors deformities had taken place more than 5 yea after femoral fracture in children Wheth some correction may take place during th very first years after healing of the fractur however, has not been investigated in th present study Nevertheless, the finding support the statement of Vontobel et al (1961) that an abnormal rotational axi following femoral fractures in children n poorly corrected during growth

A poor correlation was found between abnormal femoral neck anteversion of the fractured femur and abnormal rotational mobility of the hip in patients with a femora neck anteversion deformity of less than 10 degrees This might be partly due to an in accurate investigation technique Secondary changes in or around the hip joint of the fractured femur might also be of some im portance It is worth noting however that all cases with torsion deformities exceeding 10 degrees were accompanied by an expected change in either the internal or external rotation of 10 degrees or more This indicates

that measurement of the rotational mobility may be used as a screening test in the diagnosis of marked torsion deformities. Radiological determination of the anteversion angles of the hips has then to be performed if marked differences are found in the rotational mobility of the contralateral hips

Some torsion deformity is usually well tolerated after fracture of the femur However marked deformity may lead to disturbed function and late arthrosis in the hip or in the knee and ankle joint (Weber 1963) According to Muller (1957) retroversion of more than 2 degrees and anteversion of more than 30 degrees may cause degenerative changes in the hip joint Probably the adaption to a torsion deformity is to some extent individual.

Weber (1963) has introduced a special traction table for treatment of femoral fractures in children Bilateral femoral traction is applied with hips and knees flexed 90 degrees and the hips abducted 20 degrees This method should enable a radiological determination of the rotational displacement and a graded correction of the rotational axis Eighteen out of 28 cases treated by this method showed torsion deformities of less than 10 degrees at follow up, while none of the remaining cases showed deformities of more than 18 degrees (Weber 1969) Comparing these results with those of the present study, the Weber method might perhaps appear slightly superior in the prevention of marked torsion deformities. The number of observations of the materials compared are too few to draw any definite conclusions

REFERENCES

Barfod, B & Christensen, J (1958) Fractures of the femoral shaft in children with special reference to subsequent overgrowth *Acta chir scand* **116**, 235–250

Burwell H N (1969) Fractures of the femoral shaft in children *Postgrad med J* **45**, 617–621

Conwell E (1929) Acute fractures of the shaft of the femur in children *J Bone Jt Surg* **11** 593–647

Griffin P P Anderson M & Green W T (1972) Fractures of the shaft of femur in children Treatment and results. *Orthop Clin N Amer* **3**, 213–224

Gross, F & Haike H (1970) Bestimmung der Genauigkeit und der Fehlerquellen des Rippsteinchen Verfahrens zur Messung der Antetorsion des coxalen Femurendes. *Arch orthop Unfall Chir* **67**, 234–243

Hupfauer W & Balan J (1971) Die konservative Behandlung kindlicher Oberschenkelfrakturen und ihre Ergebnisse *Mschr Unfallheilk.* **74**, 441–456

Muller M E (1957) *Die huftnahen Femurosteotomien* Thieme Stuttgart

Neer C S & Cadman E F (1957) Treatment of fractures of the femoral shaft in children *J Amer med Ass* **163**, 634–637

Parvinen, T Viljanto J Paananen M & Vilkki I (1973) Torsion deformity after femoral fracture in children A follow up study *Ann Chir Gynaec Fenn* **62**, 25–29

Rippstein J (1955) Zur Bestimmung der Antetorsion des Schenkelhalses mittels zweier Rontgenaufnahmen *Z Orthop* **86**, 345–360

Stahelı, L T (1967) Femoral and tibial growth following femoral shaft fracture in childhood *Clin Orthop* **55**, 159–163

Stray K (1938) *Kliniske og røntgenologiske efter undersøkelser av femurfrakturer hos barn* Faedrelandsvennen, Kristiansand

Vontobel, V Genton N & Schmid R (1961) Die Spatprognose der kindlichen dislozierten Femurschaftfraktur *Helv chir Acta* **28**, 655–670

Weber B G (1963) Zur Behandlung kindlicher Femurschaftbruche *Arch orthop Unfall Chir* **54**, 713 723

Weber B G (1969) Fractures of the femoral shaft in childhood. *Injury* **1**, 65 68

Yano S & Sawada M (1975) Rotationsfehler nach kindlichen Femurschaftfrakturen *Z Orthop* **113**, 119 129

Correspondence to Pål Benum Orthopaedic Department Trondheim University Hospital 7000 Trondheim, Norway

cta orthop scand 50 93–96 1979

ıN ALTERNATIVE METHOD FOR EXCHANGE)PERATION OF INFECTED ARTHROPLASTY

ENNART HOVELIUS & GÖRAN JOSEFSSON

Orthopaedic Department, Gävle Hospital, Gävle, Sweden

The use of bone cement balls in chains loaded with gentamycin (gentamycin PMMA-ketten) as part of a two-stage exchange operation has proven to be a good method of treatment for infected arthroplasty The procedure is illustrated by three case reports.

Key words exchange operation, gentamycin cement hip surgery infected arthroplasty, knee surgery

Accepted 18 vii 78

Infected joint arthroplasties are a considerable problem to the orthopaedic surgeon Exchange operation with gentamycin-loaded bone cement, described by Buchholz & Gartman (1972) is an accepted method of treatment More than four fifths of the 79 exchange operations at the Orthopaedic Departments in Gavle, Lund and Malmo have been successful (Carlsson et al. 1978)

However, our experience in Gävle is that in certain cases immediate exchange is not suitable In these cases we have first taken out the infected arthroplasty and inserted balls of bone cement loaded with gentamycin (ENID 33040 Merck, Darmstadt), for a period of 3 weeks, before the final exchange operation. This method has been described earlier, particularly in connection with chronic bone infection (Klemm 1976, Jenny et al 1977)

Since 1976 several patients with infected arthroplasties have been operated upon at the Orthopaedic Department in Gävle according to this two-stage procedure with gentamycin-loaded cement balls. Three of the cases are described here.

CASE REPORTS

Case 1 A 67-year-old woman with coxarthrosis was treated with hip arthroplasty in 1970 In 1975, because of infection, an exchange operation with gentamycin loaded bone cement was performed Bacteriological culture yielded *Staphylococcus aureus*

Due to persisting infection in 1976 the latter prosthesis was extracted and replaced with 60 bone cement balls containing gentamycin Culture again gave *S aureus*

The patient was then kept in traction for 3 weeks after which the final operation with a Christiansen prosthesis and with gentamycin-loaded cement (1 5 g gentamycin sulphate/40 g bone cement) was performed

The patient is now quite free of symptoms with a normal X ray and sedimentation rate 18 months after the last surgical procedure

Case 2 A 65-year-old woman was operated on in 1970 and fitted with a Moore prosthesis because of a dislocated fracture of the femoral neck

In 1976 there were signs of deep infection. X-ray showed protrusion of the prosthesis with infection (Figure 1) The patient was operated upon and the prosthesis removed During the operation the femur fractured Because of this and

0001 6470/79 010093–04$02.50/0

© 1979 Munksgaard Copenhagen

Figure 1 (Case 2) Infected Moore prosthesis 6 years after primary operation

Figure 2 (Case 2) Prosthesis extract Gentamycin balls placed in the wound cavity femur was fractured during the operation.

the evident signs of infection no direct exchange was performed Instead 90 balls of bone cement loaded with gentamycin were inserted into the femur and acetabulum. The patient was put into traction (Figure 2)

Culture yielded *Staphylococcus epidermidis* together with anaerobic bacilli sensitive only to ampicillin and gentamycin

Three weeks later the balls were taken out, the fracture stabilized with metallic bands and an arthroplasty using bone cement with gentamycin (0 5 g gentamycin/40 g cement) was performed (Figure 3)

The patient remains free of symptoms after more than 1½ years. X-ray and sedimentation rate are normal.

Case 3 A woman aged 59 years, with rheumatoid arthritis was treated for several years with steroids. In March 1977 both condyles in the right knee were replaced with demi prostheses. months postoperatively there were signs of ... arthritis. Culture showed *S aureus*

At the end of September the prosthesis ... taken out together with much infected tissue possible Thirty gentamycin-loaded balls ... inserted. Primary closure of the wound was ... Four weeks later, when the sedimentation ... had fallen from 80 mm 4 mm, the patient was operated on and fitted with a bicondylar prosthesis. The bone cement was loaded with 1 5 g gentamycin/40 g cement

At the last examination of the patient nine months postoperatively there were still no signs of infection in the knee

igure 3 (Case 2) Total hip arthroplasty with a hristiansen prosthesis The fracture of the femur as been stabilized with two metallic bands

ISCUSSION

Infected arthroplasty usually means further operative procedures. Long-term treatment with antibiotics may alleviate the symptoms without resolving the infection (Lidgren et al 1977)

Since Buchholz & Gartman published their results on exchange operations using gentamycin loaded bone cement (Buchholz & Gartman 1972) this method has been used at the Orthopaedic Departments in Gävle, Lund and Malmo with to date good results (Carlsson et al. 1978)

Exchange operative procedures are often more complicated than primary arthroplasties. Amongst the technical problems encountered are peroperative fracture, perforation of the femoral shaft and difficulty in removing all the bone cement Sometimes the infection is so severe that the surgeon is reluctant to make an immediate exchange

When these circumstances prevail we are convinced that a two-stage operation is preferable At the first intervention the prosthesis, all infected tissue and all bone cement are taken out Adequate bacteriological cultures are made. Chains with gentamycin-loaded cement balls are inserted into the cavity left by the prosthesis During the period in traction before the final arthroplasty, an X-ray is made to confirm that all bone cement is removed, this is important (Buchholz et al 1977, Clegg 1977) The most suitable prosthesis is prepared beforehand and if appropriate, depending on the bacteriological culture, the bone cement may be loaded with antibiotics other than gentamycin (Buchholz et al 1977)

The short period without a prosthesis as in our three cases was a great advantage A longer period may cause technical problems (Carlsson et al 1978)

The final arthroplasty should probably be performed after a period of 3 weeks with the cement balls, after which time most of gentamycin has been released (Sattel & Nabert-Bock 1973)

Summary

We have described an alternative method for exchange operation of infected arthroplasty In certain cases this two-step procedure with gentamycin loaded cement balls offers several advantages.

1 Severe deep infection can be brought under control before the final prosthesis is inserted

2. Adequate bacteriological culture during stage one makes it possible to add the appropriate antibiotic to the cement

3 X-ray makes it possible to confirm that all bone cement is removed.

4 Technical complications, for example femoral fracture, can be handled later when

the correct model of prosthesis has been ordered

REFERENCES

Buchholz, H W & Gartman, H D (1972) Infektionsprophylaxe und operative Behandlung der Schleichenden tiefen Infektion bei der

von über 400 infizierten Huftendoprothesen *Orthop Prax* 12, 1117–1120

Carlsson, Å, Josefsson, G & Lindberg, L (1978) Exchange operations with gentamycin cement for deep infections in total hip arthroplasty *J Bone Jt Surg* (In press)

Clegg, J (1977) The results of the pseudarthrosis after removal of an infected total hip prosthesis *J Bone Jt Surg* 59-B, 298–301

Jenny, G, Kempf, I, Jaeger, J H & Konsbr II (1977) Utilisation de billes de cir acrylique à la gentamycine dans le tra ten de l'infection osseuse *Rev Chir orthop* 491–500

Klemm, K (1976) Die Behandlung chronis Knochen infektionen mit Gentamycin PMMA ketten und — Kugeln Sympo uber Knochen infektionen München, (Merck, Darmstadt)

Lidgren, L, Carlsson, Å & Lindberg L (1 Antibiotikabehandlung bei infizierten to Gelenkplastiken *Orthop Prax* 5/ 344–347

Sattel, W & Nabert-Bock, G (1973) Nach von Antibiotika aus Knochencementen — perimentelle und Klinische Untersuchun *Proceedings First Int Cong on Prosth* Techniques and Functional Rehab, Vienna 94–106 Egermann Druckereigesellschaft H & Co, Wien

Correspondence to Lennart Hovelius Orthopaedic Department, Gavle Hospital 800 07 Gavle, Sw

Acta orthop scand. 50 97–101 1979

ADAMANTINOMA TIBIAE

TOR HIERTON*, KURT KOLSTAD*, ANDERS LINDGREN†
& BO SAHLSTEDT‡

Department of Orthopaedic Surgery*, Department of Clinical Pathology† and
Department of Diagnostic Radiology‡, University Hospital, Uppsala, Sweden

A case with characteristic roentgenographic and microscopic findings of adamantinoma tibiae is reported Knee disarticulation with early ambulation is the treatment of choice and was performed on this patient Limb ablation followed by Unna Paste Bandage to prevent oedema and permit early prosthetic fitting facilitates rehabilitation. The 1 year follow-up showed excellent prosthetic function and no evidence of residual tumour

Key words adamantinoma tibiae, knee disarticulation, early prosthetic fitting, Unna Paste Bandage

Accepted 8 VIII 78

Adamantinoma is a rare primary tumour of long bones It may occur in all regions but the tibia is the most frequent site According to Dahlin (1967) it represents only 0 33 per cent of primary malignant bone tumours in the files of the Mayo Clinic. The present tumour is the first case of adamantinoma tibiae registered in the Swedish Cancer Register since it was started in 1958 There are at present about 1000 malignant skeletal tumours registered, which means an incidence of about 0 1 per cent for adamantinoma tibiae (J Ericsson 1978, personal communication) There are only about 100 cases reported in the literature (Huvos & Marcove 1975) The term adamantinoma tibiae was first used by Fischer (1913) because of the alveolar and tubular arrangement of the cells resembled that of adamantinoma of the jaw bone (ameloblastoma) This pattern of islands and strands of cells forming alveolar or tubular structures is characteristic and pathognomonic (Jaffe 1958, Dahlin 1967, Lichtenstein 1972)

There is considerable controversy regarding the *pathogenesis* Some authors consider this tumour to be a form of synovial sarcoma (Lederer & Sinclair 1954, Hicks 1954) while others believe that the cell clusters are of angioblastic origin (Changus et al 1957) Based on electronmicroscopic studies, Rosai (1969) and also Unni et al (1974), concluded that the palisading cells in the fibrous stroma were of epithelial origin

Adamantinoma tibiae is a slow growing and potentially malignant tumour with a marked tendency to local recurrence and with the possibility of metastasizing through the lymphatics and blood vessels even after very long periods of time (Jaffe 1958, Moon 1965) A multicentric origin of the tumour has been suggested as an explanation for the apparent frequency of recurrence and delayed metastases (Unni et al 1974)

Roentgenograms demonstrate the lesion in its usual tibial location as a well marginated trabeculated rarefaction of the cortex (Jaffe 1958, Radiological atlas of bone tumours) The roentgenologic picture is frequently misinterpreted as fibrous dysplasia

Most authors consider radiotherapy in-

DOI 1-6470 79 010097–05$02 50/0

© 1979 Munksgaard Copenhagen



Figure 1 The lesion is located anteriorly in the diaphysis of the tibia and is fairly well defined with sclerosis at the margin with the normal bone In some parts the tumour has a coarse trabecular structure The cortex is partly destroyed and in places it is only paper thin

effective (Jaffe 1958, Lichtenstein 1972, Unni et al 1974) In 1972, however, Zand et al reported a patient who at the age of seven had been treated with cobalt irradiation and who was free from recurrence or metastasis 9 years later

The following conclusions can be drawn from the reported cases regarding surgical treatment

Local curettage This treatment is followed by recurrence and is inadequate

"En bloc" resection This has been done selected cases with good long term results

Amputation Amputation is the treatment choice when radical "en bloc" resection

produce technically unacceptable results. An active regime of early prosthetic fitting may contribute to the patient's acceptance of limb ablation and leads to optimal rehabilitation.

CASE REPORT

A 32 year-old married woman was first seen in March, 1977, with a 6-month history of a painless swelling below the left knee. There was no history [illegible] past 10 years.

On physical examination there was a slightly tender firm swelling on the anterior aspect of the proximal half of the left [illegible] be left [illegible] tion [illegible] and destroyed a portion of the anterior cortex [illegible] cm below the tibial tubercle. Arteriograms were normal. Cytologic findings after thin-needle biopsy were inconclusive. Tissue from an open biopsy was interpreted as probable adamantinoma tibiae. Radical "en bloc" resection and preservation of knee function was not possible due to the size and site of this neoplasm. After some hesitation the patient agreed to a through knee amputation to be followed by early prosthetic fitting.

The knee disarticulation, *ad modum* Dederich (1970), was performed on May 3 1977. To prevent swelling of the stump and facilitate early ambulation an Unna Paste Bandage was applied. Casting for a temporary prosthesis was made 1 week postoperatively after change of the dressing. The first sockets were given quadrilateral shape for tuberoischial support and relief of the stump end. Six weeks postoperatively (June 16 1977) she was equipped with a total contact thigh socket and a Lyquist prosthetic knee mechanism. This improved her function and it was fully accepted from a cosmetic point of view. The postoperative procedures are summarized in Table 1. They were performed in a stimulating but non irritating atmosphere and were well tolerated (Table 1).

Dissection of the *amputation specimen* demonstrated the anterior portion of the tibia from a level 3 cm below the tibial plateau to 12 cm distally to be involved by a firm grey tumour (Figure 2). The tumour was confined to bone. The antero-medial cortex was infiltrated and very thin, but it was not perforated. As in the pre-operative biopsy specimen, the microscopic picture was dominated by a loose fibrous stroma

Figure 2 Cut surface of the surgical specimen shows a greyish-white, rather sclerotic appearing tumour in the anterior part of the left tibia extending from 3 cm below the tibial plateau distally for 12 cm.

Figure 1 The lesion is located anteriorly in the diaphysis of the tibia and is fairly well defined with sclerosis at the margin with the normal bone In some parts the tumour has a coarse trabecular structure The cortex is partly destroyed and in places it is only paper thin.

effective (Jaffe 1958 Lichtenstein 1972, Unni et al 1974) In 1972 however, Zand et al reported a patient who at the age of seven had been treated with cobalt irradiation and who was free from recurrence or metastasis 9 years later

The following conclusions can be drawn from the reported cases regarding surgical treatment

Local curettage This treatment is followed by recurrence and is inadequate.

"En bloc" resection This has been done selected cases with good long term results.

Amputation Amputation is the treatment choice when radical en bloc" resection

Figure 5 Other areas consist of elongated or cuboid cells in tubular arrangements that are characteristic of adamantinoma. Palisading of cells can also be seen.

without cellular atypia (Figure 3) in which were islands and strands of cells. These cells were elongated or cuboidal and occurred in nests that gave the impression of a vascular tumour (Figure 4). In other areas strands and islands of cuboid epithelial cells were present which had a tubular arrangement and demonstrated palisading (Figure 5) These were characteristic of adamantinoma tibiae

The 1 5 year follow-up has shown the patient to be well and to have good prosthetic function There is no evidence of recurrence of the tumour

ACKNOWLEDGEMENT

The authors express their gratitude to G Sloberger, M.D, and G Soderberg M D Tumorbiologiska Institutionen, Karolinska sjukhuset, Stockholm, for help in the histopathological analysis and to B Stener M D, Gothenburg, and U Nilsonne, M D, Stockholm for advice

REFERENCES

Changus, G W, Speed, J S & Stewart, F W (1957) Malignant angioblastoma of bone *Cancer* 10, 540–559

Dahlin, D (1967) *Bone tumors*, pp 204–211 Charles C Thomas, Ill

Dederich, R (1970) *Amputationen der unteren Extremität* pp 85–88 Georg Thieme Verlag, Stuttgart

Fischer, H (1913) Uber ein primares Adamantinom der Tibia *Frankfurt Z Path* 12, 422–441

Hicks, J D (1954) Synovial sarcoma of the tibia *J Path Bact* LXVII, 151–161

Huvos, A G & Marcove, R C (1975) Adamantinoma of long bones *J Bone Jt Surg* 57 A, 148–154

Jaffe, H L (1958) Adamantinoma of limb bones. *Tumors and tumorous conditions of the bones and joints*, pp 213–223 Lea & Febiger, Philadelphia

Lederer, H & Sinclair, A J (1954) Malignant synovioma simulating "adamantinoma of the tibia" *J Path Bact* LXVII, 163–168

Lichtenstein, L (1972) Dermal inclusion tumors in bone (so-called adamantinoma of limb bones) *Bone tumors*, 4th ed, pp 343–348 The C V Mosby Co, St Louis

Moon, N (1965) Adamantinoma of the appendicular skeleton. *Clin Orthop* 43, 189 213

Radiological atlas of bone tumours (1966) *Adamantinoma of the limb bones* Vol 1 pp 213–214 The Williams & Wilkins Co

Rosai, J (1969) Adamantinoma of the tibia. *Amer J clin Path* 51, 786–792.

Unni, K. K., Dahlin, D C, Beabout, J W & Ivins, J C (1974) Adamantinomas of long bones. *Cancer* 34, 1796–1805

Zand, A., Chambers, G H & Street, D M (1972) So-called "adamantinoma of long bones" *Clin Orthop* 86, 178–182.

Correspondence to Kurt Kolstad, M D Department of Orthopaedic Surgery, University Hospital, S-750 14 Uppsala, Sweden.

Dr. P
LIBRARY
Lege
JAIPUR
18760

Acta orthop. scand. 50, 103–107, 1979

PROCEEDINGS OF THE DANISH ORTHOPAEDIC SOCIETY

EDITOR N J HOLM

Copenhagen, 28–29 October 1977

RESULTS OF OPERATIVE TREATMENT OF LESIONS OF CRUCIATE LIGAMENTS A FOLLOW-UP STUDY

B Barfod & S Boe

In 32 knee injuries 28 ruptures of the anterior and 10 lesions of the posterior cruciate ligaments were found. Only four ruptures of the anterior and one of the posterior ligaments were isolated lesions.

A follow-up study of 26 of the 32 knees showed poor results in nine cases, four due to arthrosis, the rest were due to instability, mostly combined with pain. One anterior and four posterior drawer signs of more than 1 cm were found, all in knees with poor results. Five patients had lateral instability, four with poor results.

Conclusion. Evaluation of the consequences of primary repair of the cruciate ligaments is difficult if not impossible due to the presence of other lesions. Meticulous repair of all injured structures is mandatory.

A STRESS [illegible]

[illegible]

Jacobsen

This operation was carried out on very unstable knees with absent anterior cruciate ligaments. It was shown at stress-radiographical follow-up investigation that it was just as satisfactory to use the difference in anterior displacement between the uninjured and the operated leg as a parameter as it was to compare the values of the injured knee preoperatively and at follow-up. A good result was found in 80 per cent of the measurements. Seventy-two per cent of the patients were very satisfied. It was also shown that clinical quadriceps measurements have to be carried out on both legs both prior to operation and at follow-up before an assessment of postoperative atrophy can be made. Despite a persisting difference a marked bilateral hypertrophy had taken place in many cases at follow-up.

[illegible]

Klaus Jacobsen
Acta orthop. scand. 48, 520–526

Halbaek, 28–29 April 1978

KINETICS OF GAIT

Knud Jansen, Erik Jansen & Robert Larsen

An instrumented treadmill has been used to record the force pattern of gait in patients with gait handicaps. The patient walks on a moving pavement consisting of two parallel conveyor belts. The belts are driven by hydraulic motors and the suspension forces monitored using strain gauges. The signals obtained are the vertical, the transversal and the sagittal force of each foot.

The force curves are recorded on tape for later computer processing. Thus a means of gait analysis under standard conditions has been established. The exact measurements provide information of the kinesiology of gait.

(A movie film illustrated the gait analysis.)

EXTERNAL WORK OF GAIT

Erik Jansen, Robert Larsen & Jens Erik Pedersen

The external work, produced when walking is considered to be a major expression of gait function, especially in the presence of a gait handicap. Using an instrumented treadmill, the vectors of each foot are recorded and the following calculations are made by a computer. Applying Newton's second law the velocities of the three

0001-6470/79/010103-05$02.50/0

© 1979 Munksgaard Copenhagen

directions of movement are obtained By integration and multiplication of the forces from each foot by the velocities the external work produced by each foot is determined. By this method it is possible to relate the patient's gait handicap to his cardio-pulmonary capacity thus facilitating the choice of treatment

LATERAL DISCOID MENISCUS COMBINED WITH HYPOPLASIA OF THE LATERAL FEMORAL CONDYLE

Ivan Hvid, Lars Ib Andersen & Henrik Schmidt

Two cases of hypoplasia of the lateral femoral condyle in conjunction with large, primitive discoid menisci are described Both patients were girls, 9 and 10 years of age at the time of operation One case showed slight and the other pronounced hypoplasia of the lateral femoral condyle

It is postulated that this osseous abnormality is secondary to the mechanical impact of the thick discoid meniscus

IS EARLY WEIGHT-BEARING PERMISSIBLE AFTER INTERTROCHANTERIC FRACTURE TREATED *AD MODUM* McLAUGHLIN?

T Scherff Sørensen og K Hougaard

A retrospective study of 176 intertrochanteric fractures treated by fixation with vitallium nail-plate *ad modum* McLaughlin is presented Seventy-five patients were treated postoperatively without weight-bearing for 12 weeks, and 101 patients were allowed as much weight-bearing as possible from the second postoperative day The frequency of thromboembolic complications was significantly decreased in the group with early weight-bearing No differences in the frequency of disruption of the nail-plate junction nor in other complications were found.

FEMORAL SHAFT FRACTURES TREATED WITH CLOSED INTRAMEDULLARY NAILING

O Fedders

Out of 274 femoral shaft fractures 190 were treated with intramedullary nailing and of these 172 were treated with closed reduction and nailing One fracture developed pseudarthrosis and three osteitis (two of these after secondary surgery) None of these complications occurred in the group receiving closed treatment.

THE TREATMENT OF PER- AND SUBTROCHANTERIC FRACTURES *AD MODUM* ENDER

P Ramsing & I Tovborg Jensen

The Ender method of intramedullary fixation [illegible] per- and subtrochanteric fractures was used in [illegible] patients. The average age was 75 years and th[illegible] mortality rate was 15 per cent In two cas[illegible] infection occurred and in one case there was no[illegible] union 8 months after the operation.

The results were particularly favourable [illegible] patients who were able to walk without canes [illegible] the time of injury In 25 per cent a shortening [illegible] more than 1 cm or a malrotation of more than 20[illegible] was observed.

The advantage of the Ender method is [illegible] reduction in the length and severity of th[illegible] operation and the possibility of early weig[illegible] bearing

[illegible]

A total of 143 patients were operated on f[illegible] lesions of the lateral ligaments of the ankle and [illegible] further 59 patients were treated, in the followin[illegible] period, with plaster of Paris, 138 and [illegible] respectively were re-examined. At operation th[illegible] ligaments were found in be totally ruptured in [illegible] per cent of cases and partially in 4 per cent.

At follow-up two thirds of the patients in ea[illegible] group were symptom-free Nineteen per cent [illegible] the operated group and 10 per cent in the grou[illegible] treated with a cast had feelings of instability th[illegible] former group showing the more stable ankles [illegible] secondary stress inversion X ray examination. [illegible] is concluded that the operative treatment did n[illegible] give better results than the treatment with a cast.

RADIONUCLIDE UPTAKE OF ^{99m}Tc-[illegible]

[illegible]

STUDIES

Steen Bach Christensen

Autoradiography was performed on macro[illegible] scopic specimens from osteoarthritic femor[illegible] heads of patients who had received 10 mC[illegible] ^{99m}Tc-polyphosphate or ^{99m}Tc-methylene[illegible] phosphonate before replacement surgery Th[illegible]

radionuclide accumulated mainly in the walls of cysts in the weight-bearing area and at the osteochondral junction in the osteophytes. Impulse counting corroborated the auto-radiographical findings. Morphological studies revealed the areas of accumulation of radionuclide to be areas of bone formation, particularly enchondral ossification. This was found in the osteophytes and in cysts with cartilage metaplasia in the cyst wall. High alkaline phosphatase activity was correlated with an increased uptake of ^{99m}Tc phosphate compounds, but this was not located in the cells with high enzyme activity, but rather in the cell product, the immature, newly formed bone.

HEAD AND NECK

Vilhelm Møller Pedersen

During a period of 45 months in 1972–1976, 1112 patients with injuries to the head and neck were admitted to the Department of Surgery, Holbæk Hospital. All of these patients were submitted to X-ray examination for possible lesions of the cervical spine. Five cases with lesions of this type were revealed by radiographic examination, there had not been any preliminary clinical suspicion of lesion of the cervical spine. It is concluded from this survey that it is not reasonable to require routine X-ray investigation of the cervical spine in all cases of trauma to the head and neck admitted to hospital.

CONGENITAL PSEUDARTHROSIS OF THE ANTEBRACHIUM

R. Jelnes

A case of congenital pseudarthrosis of both bones of the forearm, with fibrous dysplasia at biopsy is presented.

The patient is a 6-year-old girl. Two years previously an operation with homograft was undertaken. The graft resolved. Due to complaints and signs of irritation of the median nerve, another osteoplastic operation was attempted. The graft was taken from the body of the fibula. The result is still uncertain.

Six of the 10 cases with congenital pseudarthrosis of one or both bones of the forearm, reported in the literature were operatively treated. In four cases the lesions healed, with an average of three operations per patient. There was only a slight decrease in the function of the forearm and none of the hands and fingers.

FRACTURES OF THE PHALANGES OF THE HAND

A. P. Højlund & P. Riegels Nielsen

A review of 90 patients with 94 uncomplicated fractures of the proximal and middle phalanges of the fingers, treated at the Hospital of Orthopaedic Surgery in Sorø, Denmark, showed that one third of the patients had residual complaints such as a feeling of coldness or pain on strenuous use of the hand. Fourteen patients had unsatisfactory function of the hand, and 12 fractures healed with residual deformity. Splintage should not be used for more than 3 weeks as no fracture showed secondary dislocation after this period. The finger should be splinted in the "safe position". Accurate reduction also with regard to rotation is mandatory for a good result.

TREATMENT BY TRACTION *AD MODUM* COTREL IN IDIOPATHIC SCOLIOSIS

Claus Kromann-Andersen

Cotrel traction has two components, an active autoextension and a passive night traction. This system has been used at Department O, Odense Hospital, since September 1976, to treat idiopathic scoliosis. Having been examined clinically and radiologically the patients are instructed in the techniques of a special training programme and in the traction method itself. It has been possible to carry out the treatment at home with outpatient visits every 3 months. Apart from the daily treatment sessions we have not suggested any restrictions in the patient's personal activities.

Twelve patients are under treatment and are being regularly examined. The short observation time does not allow any conclusions to be drawn as yet.

[illegible] OF ALKALINE [illegible]TY IN [illegible]

Inge Reiman

Frozen sections from 24 osteoarthrotic femoral heads were prepared for study of alkaline and acid phosphatase activity using the enzyme-histochemical methods described by Burstone, and by Barka & Anderson. Different areas of the subchondral bone, viz. weight-bearing, non-weight-

bearing and osteophytes, as well as central regions, were investigated The cartilaginous changes were determined by histological-histochemical grading

The data obtained showed wide variation within the same femoral head with significantly greater activity of alkaline as well as of acid phosphatase in weight-bearing than in non-weight-bearing areas and in subchondral than in central regions The activity correlated with the degree of cartilage changes

MIGRATION OF THE FEMORAL HEAD IN LEG[illegible]
SI[illegible]
J [illegible]

The treatment of Legg-Calvé-Perthes' disease *(LCPD) employs to an increasing degree the con*tainment principle in the form of femoral osteotomy, based on the hypothesis that the *decisive factor for the prognosis is centralization* of the femoral head, and not relief of weight-bearing by the hip

A follow-up examination of 48 unilateral LCPD hips treated by strict bed rest showed a poor correlation (best value $r=-0.385$) between the degree of lateralization of the femoral head (the migration percentage) during the course of the disease and the sphericity quotient at follow-up The hypothesis therefore must be rejected

The lateralization increased during the first 1 8 years and then decreased This phenomenon is explained mainly by changes in the balance between the abductors and adductors of the hip

LATERAL RELEASE IN THE TREATMENT OF DISLOCATION OF THE PATELLA AND OTHER DISORDERS OF THE KNEE
N O Christensen

Twenty-six patients with recurrent dislocation of the patella were treated by section of the lateral fibrous capsule and medial tightening In only three cases was the tibial tuberosity advanced

In the present series three patients had recurrence of the dislocation Two of them had significant patella alta (one was spastic) and stability was achieved after additional advancement of the tuberosity The third patient had a remarkably shallow patellar sulcus and reoperation has not yet been carried out The rest of the patients have stable patellae and no complaints or only trivial ones.

Few dislocated patellae have such a high *position that* advancement of the tuberosity is necessary or even justified Undoubtedly severe chondromalacia may follow advancement in patients who do not need it

In another 14 patients a lateral release was performed for patellar arthrosis and chondromalacia, in an attempt to follow the indications of Ficat About half of the patients were relieved of pain As there is no satisfactory alternative treatment for these patients 50 per cent success is perhaps acceptable

ON THE SKELETAL AGE IN COXA PLANA
Hans Bohr

In 154 cases of Coxa Plana (CP) from Denmark the skeletal age, determined according to Greulich & Pyle, was de[illegible] 15 7 months in [illegible] cant compared [illegible] children in the same age group In boys younger than 5 years the delay in skeletal age increases in the following 5 years while it decreases in boys over the age of 8 years There was no correlation between the delay in skeletal age and the duration of the disease Height, weight and growth rate were normal

[illegible]

TILT
E Larsen

Forty-nine patients with acute lateral ankle *injuries* have been investigated radiologically for anterior subluxation of the talus and for talar tilt

A better correlation was found between the results of the examination for anterior subluxation and the operative findings, than between talar tilt and the operative findings.

In addition the examination for anterior subluxation was significantly *less painful* than the examination for talar tilt

[illegible] OF [illegible]

J Grieff

A 70-year-old male sustained a medial fracture of the femoral neck which was treated with an osteosynthesis *ad modum* MacLaughlin Two years later the implant was removed due to persi-

ent pain, and shortly afterwards a femoral neck pseudarthrosis was diagnosed Bone-grafting was performed unsuccessfully Eight years after the injury a scintigram showed no uptake in the femoral head and necrosis of the femoral head was anticipated A replacement of the femoral head was performed, and the histological examination verified the scintigraphic diagnosis. Neither radiological or macroscopic examination revealed collapse of the femoral head

Conclusion The diagnosis "necrosis of the femoral head" has to be based on either scintigraphic or histological examination, while the diagnosis "collapse of the femoral head" can be based on radiological or macroscopic examination

LESIONS OF THE CRUCIATE LIGAMENTS OF THE KNEE JOINT

Poul Otto Liljedahl

Injuries of the ligaments of the knee are mostly multiple, isolated ruptures are unusual Examination under anaesthesia and arthroscopy gives the required accuracy of diagnosis Especially in older injuries arthroscopy can be helpful

In anteromedial rotatory instability the medial collateral and posterior capsular ligaments are ruptured, supplemented with a pes anserinus plasty Anterolateral rotatory instability is treated by transfer of the medial one third of the patellar tendon or by an extraarticular plasty *ad modum* Ellison. The posterior cruciate ligament is reconstructed sometimes using the medial meniscus or the popliteus tendon The late results are good except in cases with pan-compartmental osteoarthrosis where a pronounced scarring of the ligaments was often found

CLASSIFICATION AND TREATMENT OF OSTEITIS

William Damholt

The incidence, morbidity and mortality of osteitis are increasing For relevant prophylaxis differentiation between hematogenous and

or intermittent chronic suppurative infection

In the treatment cooperation between a specially trained nursing staff, the microbiologists and the orthopaedic surgeons is emphasized The treatment of chronic osteitis is discussed according to the principles

1) Preliminary systemic treatment of the patient
2) Topographic and microbiological diagnosis
3) Radical operation, primary closure, suction drainage
4) Postoperative treatment, mobilization

Nineteen patients were operated on, primary healing was obtained in 17 cases, secondary healing in one, and there was a recurrence in one patient

cta orthop scand. 50 109–121, 1979

'ROCEEDINGS OF THE SWEDISH ORTHOPAEDIC ASSOCIATION

'tockholm, May 25–26, 1978

DITOR PETER HERBERTS

UEST LECTURE

HE ROLE OF THE RESURFACING RTHROPLASTY IN THE TREATMENT OF STEOARTHROSIS OF THE HIP

David Stulberg

epartment of Surgery (Orthopedics), hicago, Ill., USA

The Resurfacing Arthroplasty was developed to oid the femoral stem problems of the con ntional THR — loosening and breakage atients most suitable for a Resurfacing rthroplasty are those "at risk" as regards oosening or breakage of the stem of a con ntional femoral component or with a greater an usual risk of developing an infection

Absolute contraindications are active infection marked loss of bone stock from the femoral ead and/or neck Relative contraindications are tensive avascular necrosis, open femoral ophysis, severe leg length discrepancy, neuro-uscular abnormality or acetabular protrusion

Advantages are elimination of femoral stem oblems, not having to invade the medullary anal, and the opportunity to perform salvage pro-edures.

Results are equal to those with the conventional THR.

Disadvantages are the need to vigorously ream he acetabulum, possibly increased heterotopic one formation, the need for more postoperative hysical therapy, the potential risk of component oosening and femoral neck fractures, and a omewhat more demanding surgical technique

AUTO-TRACTION* IN THE TREATMENT OF LOW BACK PAIN AND SCIATICA A MULTICENTRE, CONTROLLED STUDY OF 82 PATIENTS

U Larsson, U Choler, A Lidström, G Lind, A Nachemson, B Nilsson & J Roslund

Departments of Orthopaedic Surgery at Malmo Gothenburg, Skovde, Danderyd and Nacka Hospitals, and at Karolinska Hospital, Stockholm

Patients with low back pain and sciatica were randomly allocated to two equal treatment groups 1) Auto-traction with Lind's multiplane table, and 2) Brace Treatment was given by six orthopaedic surgeons who had received 5 days training in Auto-traction Each patient received up to three treatments, all within 5 days After 1 week, 15 per cent of the Auto-traction group had recovered completely, a further 27 per cent were rid of either low-back pain or sciatica Thus, a total of 42 per cent of the group benefited greatly from the Auto-traction These results are significantly better than for the brace method (only one patient was rid of back pain and one of sciatica) Two weeks later the difference between the two groups had decreased but was still statistically significant After 3 months there was no difference between the groups with regard to the number of patients with residual symptoms.

Comment (G Lind) The 1 week available for the treatment may not have been long enough to obtain a cure in some cases. The orthopaedic surgeons applying the Auto-traction had not received the full course of treatment, and lacked experience

001 6470/79 010109–13$02.50/0

© 1979 Munksgaard, Copenhagen

AUTO-TRACTION* IN THE TREATMENT OF CHRONIC LOW BACK PAIN AND SCIATICA

Gertrud A M Lind & Gert G Walheim
Department of Orthopaedic Surgery, Karolinska Hospital, Stockholm

Ninety consecutive patients received Auto-traction by Lind on her multiplane table during a hospital stay of about 15 days Clinical symptoms and signs were evaluated by Walheim

A 1 *Low back pain and sciatica of 1–30 years standing (69 patients)*

Physician's evaluation	On discharge	No symptoms 63%	Improvement 21%	Total 84%
	Six months later	No symptoms 75%	Improvement 12%	Total 87%

Patient's evaluation Total on discharge 89%, 6 months later 86%

2 *Low back pain only (7 patients)* Roughly the same results as above

3 *Low back pain and sciatica, previously operated upon (7 patients)*

Physician's evaluation	On discharge	No symptoms 4 patients	Improvement 1 patient	Total 5 patients
	Six months later	No symptoms 3 patients	Improvement 1 patient	Total 4 patients

B *First-time low back pain and sciatica, onset within 2–12 months (selected group — 14 patients)*

Physician's evaluation	On discharge	No symptoms 12 patients	Improvement 1 patient	Total 93%
	Six months later	No symptoms 14 patients		Total 100%

The patients were instructed as regards "spinal hygiene" 54% showed no decrease in activity level at work, 35% were "back conscious", 6% showed moderate and 5% severe decrease in activity level at [illegible]

[illegible] sing Lind's multiplane traction

AUTO-TRACTION* IN THE TREATMENT OF CHRONIC LOW BACK PAIN AND SCIATICA EFFECT ON NEUROLOGICAL SYMPTOMS

Gertrud A M Lind

Department of Orthopaedic Surgery, Karolinska Hospital Stockholm

Ninety consecutive patients with chronic low back pain and sciatica were given Auto-traction treatment on the multiplane table during a hospital stay of about 15 days Seventy-eight patients had neurological signs (severe in 73 per cent), four others had L5/S1 syndromes, two with total foot paresis Myelography was positive in 1 out of 47 cases. In 73 per cent of cases *neurological symptoms* had regressed completely on discharge or at the 6-month follow up In 7 per cent slight and in 10 per cent marked neurological impairment persisted

Recovery of sensation presented the same pattern

Conclusion Auto-traction produced complete or partial regression of symptoms in a great proportion of cases and more rapidly than reported for surgery or other forms of treatment for low-back pain and sciatica

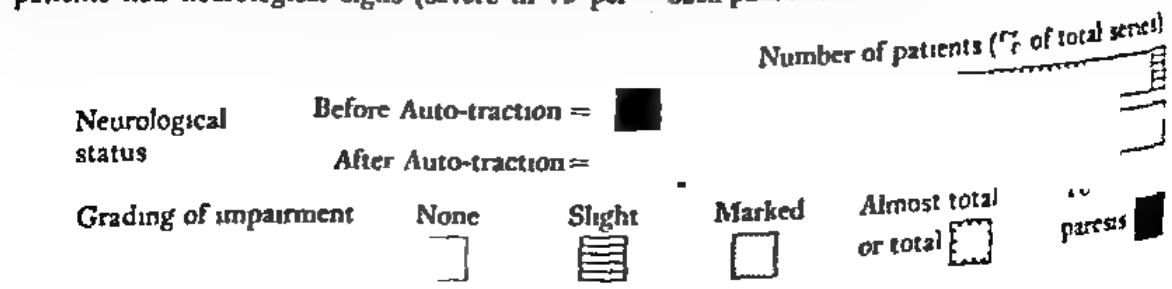

CUTE LOW BACK PAIN IN INDUSTRY · A ONTROLLED PROSPECTIVE STUDY ITH SPECIAL REFERENCE TO THERAPY

I Bergquist Ullman, U Larsson & Nachemson

A controlled study of 217 patients with low ick pain was carried out at a large industrial ant. The effect of a Back School was evaluated d compared with physical therapy and a acebo The effect of the various therapies was aluated by comparing 1) the duration of mptoms following the first treatment, 2) the ck leave period during the current episode of un and 3) the number and duration of symptoms d the total number of days absent from work

first
Back
rapy
cebo

roup (28 7 days) Significantly more patients with shorter duration of sick-leave were observed in e Back School group The number and duration symptoms and absences from work owing to lapses of pain did not differ in any of the erapy groups. Patients given the Back School or ysiotherapy have a shorter period of pain than tients given 'placebo" therapy The Back hool also reduces the average sick leave during e corresponding pain period

ENERVATION OF THE TERVERTEBRAL JOINTS REATMENT FOR LUMBAGO AND CIATICA

Ioe Lindahl
epartment of Orthopaedic Surgery, Regional ospital Linkoping

The actual source of the pain in lumbago and atica remains largely obscure the herniated sc has not provided the explanation that was pected of it. Rees in Australia considers that the use usually lies in pathological alterations in the tervertebral joints. He reports that all but 2 out 1000 consecutive cases of sciatica were cured ter resection of branches of the posterior ramus erve innervating the intervertebral joints. In the maining two cases relief was obtained after ex- pation of the sequestered fragments of a ermiated disc.

This method has been adopted at the Linkoping niversity Hospital but with Shealy's modifica on, in which an electrode is used first for ocation and then for denervation by coagulation

The cure rate in 90 patients with long standing severe postoperative lumbago and sciatica was just under 20 per cent While this figure is by no means as impressive as that reported by Rees it does represent a promising result The surgical method provides interesting information on the route followed by the pain it seems that it need not be an anatomic one

PHALEN & DICKSON S SYNDROME — A FOLLOW-UP

E Spangfort, J Sevastikoglou & S Aaro
Department of Orthopaedic Surgery, Huddinge University Hospital Karolinska Institutet Stockholm

The disabling condition caused by simultaneous contracture of the lumbar and hamstring muscles — lumbo-ischio-crural contracture (LIC contracture) — was described in German literature as "Huft Lenden-Streck-Steife", and primarily associated with tumours, inflammation and disk herniations in the lower back In 1961 Phalen & Dickson published a series of cases in which the LIC-contracture was caused by spondylolisthesis in adolescence A number of reports of this syndrome is now available, but experience with surgical treatment is still limited

At this department ten patients with Phalen & Dickson's syndrome were examined 1 5 to 14 years after operation — 8 girls and 2 boys mean age at operation 14 years (12–17 years) The operations were anterior fusion (8) laminectomy and posterior fusion (1), and in one case laminectomy without any relief, and after 4 months anterior fusion followed by complete recovery There were no surgical complications in this series The result of operation was satisfactory in all cases.

Stockholm

The vertebral rotation has been evaluated in scoliotic patients by a whole body C. T scanner, using a Δ-Scan 50 FS system (Ohio-Nuclear, Inc) The operating factors were 140 kV and 20 mA and the slice thickness was 13 mm. Mean absorbed dose 10 mGy per slice

Measurements were made on the vertex vertebra. The vertebral rotation in the transversal plane was defined as the angle between the line from the posterior central point of the vertebral foramen to the front midpoint of the body and the line from the same point of the vertebral foramen to the midpoint of the vertebral body

After a short course of instruction, measurements were performed by ten radiologists on five different patients. The variance of the 50 estimations was 1 55°

The derotatory effect of the Boston brace and the Harrington procedure have been studied by this method in two small series of cases.

SCINTIGRAPHIC AND THERMOGRAPHIC STUDIES OF THE THORAX IN IDIOPATHIC THORACIC SCOLIOSIS

J A Sevastikoglou, M Dahlborn, E Elmstedt, S Aaro & R Levander
Departments of Orthopaedic Surgery and Diagnostic Radiology, Huddinge University Hospital, Karolinska Institutet, Stockholm

T [illegible]
in [illegible]
scin [illegible]
was performed in five girls with thoracic scoliosis. No difference in the isotope uptake was observed between the spinal segments, suggesting that there may be no vertebral growth disturbance A difference in isotope uptake between left and right sided costosternal junctions of the ribs was found in every case in four of the girls the higher activity was located in the ribs of the concavity The small number of observations allows no statistical conclusions

In seven girls with scoliosis the colour-isothermogram of the body was asymmetric both from the front and from the back No correlation was found however between the thermographic image and the characteristics of the scoliosis.

CHOICE OF TREATMENT IN SUBCUTANEOUS ACHILLES TENDON RUPTURE

Lars Nistor
Department of Orthopaedic Surgery Sahlgren Hospital Gothenburg

A total of 103 patients with total subcutaneous Achilles tendon rupture were randomly allocated to treatment with either equinus plaster or surgery Five patients out of 60 non-surgically treated sustained re-ruptures whereas two out of 43 operated tendons re-ruptured In this second group two patients had deep infections The rate of complications in both groups was thus equal

So far 80 patients have been followed up. There is no difference regarding complaints of weakness or stiffness, sick-leave period, return to sports activities, calf circumference, breadth of tendon or range of motion.

Static and dynamic plantar flexion forces were [illegible]
surgically treated were not significant.

The study will be completed with electromyography and muscle biopsies, but so far the conclusion is that non surgical treatment is adequate and gives a functionally good result.

REOPERATION OF TOTAL HIP REPLACEMENTS IN SWEDEN DURING THE PERIOD 1/1/1976–31/8/1977

L Ahnfelt, G B J Andersson & P Herbert

A multicenter study was performed with the aid of a questionnaire to assess reoperations after total hip replacements The investigation was performed on a basis for a prospective multicenter study Information from 36 out of 41 Swedish departments of orthopaedic surgery revealed that 5073 hip arthroplasties were performed from 1/1/1976 to 31/8/1977, of which 485 were reoperations The reason for reoperation was infection in 33 per cent and in another 33 per cent "aseptic" loosening Both prosthetic components were changed in about 50 per cent the femoral part in 16 per cent, and the cup in 5 per cent. The diagnosis was primary osteoarthritis in 75 per cent, complications after femoral neck fracture in 13 5 per cent, secondary osteoarthrosis in 5 per cent and rheumatoid arthritis in 3 5 per cent.

[illegible]

Out of 366 total hip replacements performed in the Department of Orthopaedic Surgery between 1973 and 1977, 53 were a change from one prosthesis to another Between 1 and 4 years after surgery 43 of these patients were re-examined radiologically and clinically Ratings were obtained for pain, range of motion gait, activities of daily life, postoperative complications, radiological signs of loosening and the patient's own opinion of the result The patients were divided into four groups 1) change from a McKee/Farrar or Ring prosthesis

hesis in a Charnley or Muller prosthesis, 2) hange from one Charnley or Muller to another of e same kind, 3) change from a Moore or hompson prosthesis or Smith-Petersen cup to a harnley or Muller prosthesis. Group 4) is omposed of 19 patients who had had three or ur changes of prosthesis. The indications for hange of the prosthesis were loosening together ith pain, infection recurrent dislocation or iffness in the hip joint The results can be immarized in follows 1/2 of the patients had a ain-free joint after surgery, 2/3 had an acceptable nge of motion and gait 2/3 of the patients also nsidered themselves improved by the operation he worst results were found in group 4, the best group 3

ATE RESULTS OF REVISION RTHROPLASTY USING A TOTAL HIP ROSTHESIS

nkel Welin Berger
partment of Orthopaedic Surgery, St Goran's ospital, Stockholm

Results of re-operations of 46 hips, where ious surgical interventions were replaced with throplasty *ad modum* Charnley or Muller, were esented There were no contra-indications xept for a poor general condition of the patient here were six cases of infections (13 per cent) ollow up time was 18–48 months. According to e modified system of Merle D'Aubigné excellent good results were achieved in 61, fair in 24 and or in 15 per cent It was concluded that re-throplasty in an unselected material has a high centage of failures Preclusion of hips with ep infections in connection with previous major P surgery and of patients with a sedimentation te above 40 mm and of hips with X-ray signs of fection would have improved the results con-derably, but would also have excluded some hips at turned out to be among those with good sults.

ROPHYLACTIC ANTIBIOTICS AGAINST EEP INFECTIONS AFTER TOTAL HIP EPLACEMENTS

the Jernberger Sven S Olsson & ngny Tryggo
epartment of Orthopaedic Surgery Norrkoping

Since 1969 400 total hip replacements have een performed without the occurrence of any own primary deep infection. The operations ave been done with antibiotic prophylaxis con-sting of continuous infusion of 20×10^6 I U of penicillin/d for 3 days and dicloxacillin 0 5 g × 4 for the following 11 days 216 out of 238 operations with more than [illegible] years' follow-up time have been examined with regard to complications and functional results No definite or suspected deep infection was discovered Fourteen hips have been reoperated on with exchange of a loose femoral component All loosenings have taken place between bone cement and metal We have not been able to demonstrate bacterial growth in the tissues surrounding the loosened implants Varus position and insufficient medial cement support of the proximal part of the stem were constant findings in prostheses, where the femoral component later loosened

PRELIMINARY RESULTS OF A TRUNNION

Ole Roos
Department of Orthopaedic Surgery, Sahlgren Hospital, Goteborg

The Christiansen prosthesis is based on a trunnion bearing principle which considerably diminishes friction The prosthetic head is designed according to a bushing principle A cylindrical sleeve is slipped onto the trunnion. This is covered by a metallic casing in the shape of a sphere With this system the head remains stationary in the cup on loaded flexion and exten sion

Fifty six patients (representing 61 hips) have been operated on Forty nine had osteoarthrosis,

pain [illegible] Fifteen patients used a cane for long walks. There was one deep infection, one early and one late dis-location, two femoral stem loosenings and ectopic bone formation in 11 hips (no clinical symptoms)

[illegible] STUDY OF

Lund University Hospital, Lund

Thirty five departments of orthopaedic surgery are participating in a prospective study of knee arthroplasties Data are computerized and

presented twice yearly 1774 arthroplasties have been registered from October 1975 through March 1978 The incidence of deep infection loosening wear and fracture of the endoprosthesis in patients followed up at least 1 year is shown here

One third of the complications were due to deep infection and two thirds to endoprosthesis problems. Patients and surgeon were satisfied with the 1 year result in 78 per cent of the cases.

Diagnosis	Prosthesis	No	No of complications	Prosthesis	
				Reinsertion	Removed
Osteoarthrosis	Hinged	29	7	4	2
	Non-hinged	23	3	1	—
	Double unicondylar	18	1	1	—
	Unicondylar	133	9	5	2
Rheumatoid arthritis	Hinged	56	8	2	2
	Non-hinged	58	4	1	1
	Double unicondylar	82	6	2	2
	Unicondylar	21	2	2	—
Total		420	40 (10%)	18 (=4%)	9 ([illegible])

HEMATOGENOUS INFECTION AFTER ARTHROPLASTY AN EXPERIMENTAL STUDY IN THE RABBIT

Gudmund Blomgren & Urban Lindgren
Department of Orthopaedic Surgery Huddinge University Hospital, Karolinska Institutet, Stockholm

An experimental model with conditions similar to the clinical ones was designed by using human finger joint endoprostheses as knee joint replacement arthroplasties in the right knees of rabbits. The left knees were used for control operations. Bacteriaemia was achieved by repeated intravenous injections of a phage-typed strain of Staphylococcus Aureus (S A).

Four rabbits died in connection with the bacterial injections and all showed growth of the S A strain in the arthroplastic knee joint as well as in the control operated left knees. Ten rabbits were killed 3 weeks after the bacterial injections. Seven showed growth of the S A strain in their arthroplastic knee joints but the control operated left knees in these 10 rabbits were sterile.

ARTHROSCOPY — CLINICAL AND TECHNICAL CONSIDERATIONS

Evald Johansson
Department of Orthopaedic Surgery Karolinska Hospital, Stockholm

A consecutive series of 100 arthroscopies of the knee joint performed by one surgeon has been reviewed. The main indication for arthroscopy was "the problem knee" or acute injuries. The main arthroscopic diagnoses were meniscal, cruciate and/or capsular lesions. The only therapeutic arthroscopies were three percutaneous removals of loose bodies. In 39 patients arthrogram, arthroscopy and arthrotomy were performed. In these cases the radiological assessment was correct in 22, and incorrect in 1. In altogether 64 patients arthrotomy was performed after arthroscopy In 55 there was a complete correlation, three were given an incorrect arthroscopic diagnosis, and six arthroscopic investigations were incomplete, all compartments of the knee had not been assessed. The arthroscopic diagnosis has not been checked by arthrotomy in 36 patients. The reason for the failure is discussed and a standardized method of performing arthroscopy is presented.

AN ULTRALIGHT BELOW KNEE PROSTHESIS

Peter Herberts & Åke Magnusson
Departments of Orthopaedic Surgery Östra and Sahlgren Hospitals, Goteborg

A new technique for the fabrication of a Eden below knee prosthesis has been developed. The final prosthesis consists of a keel, shank and socket of polypropylene and an external SACH foot which is glued to the plastic keel. The prosthesis is about two and half times lighter than standard prostheses.

Four patients have been fitted and followed for 1 year They stated that they use the prosthesis [illegible]

ay long and are able to look after themselves he patients comments indicate that the prosthesis is very comfortable and it was obvious that he lighter the prosthesis, the easier it is to spend it on the limb The decreased pistoning tion with a lighter prosthesis accounts for the ood control these very old patients (85–90 years) are over the prosthesis. The impression was ained that the ultralight prosthesis conserved nergy when the patient walked in contrast to andard prostheses.

The preliminary results indicate that this prosthesis provides better comfort and at least as good unction at a lower cost than conventional prostheses.

DIAPHYSEAL BONE STRENGTH

[illegible]

[illegible] Karolinska Hospital, and Department f Experimental Surgery, Karolinska Institute, tockholm

The development of the adverse effects of a ged internal fixation plate on the strength measured as maximum torque capacity) of iaphyseal bone, as well as the recovery of bone trength after the removal of the plate, has been tudied on rabbits. Due attention had been paid to he effect of the screw holes. On removal of the late which had been applied for 12 weeks ithout previous osteotomy, the bone had ecreased in strength by 50 per cent.

After removal of the plate the bone regained its ormal strength after only 6 weeks. Furthermore, ontrary to the linearly developed weakening, egaining of strength developed non-linearly

DIAPHYSEAL BONE AT ULTIMATE FAILURE

Pelle Netz, Kjell Eriksson [illegible]

Department of C[illegible]
nent of C[illegible]
Department
Mechanic[illegible]
and Depa[illegible]
Karolinsk[illegible]tute, Stockholm

Using a high speed film technique it has been possible to calculate the propagation speed of fractures in fresh diaphyseal canine bones. The film speed used was 5,000 pictures per second The fractures were found to propagate with a speed exceeding 300 meters per second The calculated speed is not in accordance with deformation in canine diaphyseal bone

MEDULLARY COMPARTMENT OF DIAPHYSEAL BONE AT TORSION

Pelle Netz, Kjell Eriksson & Lennart Strom [illegible]

Mechanics, The Royal Institute of Technology and Department of Experimental Surgery Karolinska Institute Stockholm

Entire diaphyseal bones, including the medullary cavity, have so far not been the subject of intensive research, and pressure measurements from the closed compartment of the medullary cavity are only made statically, i.e measurements of the dynamic process when twisting the bone to final fracture have previously not been performed. Deformation of a diaphyseal bone must be followed by a change in the geometry of the medullary cavity and studies of post traumatic fat embolism have assumed high pressures either in the medullary compartment or in the muscle compartment outside the diaphyseal bone

Our studies have shown that there is only a limited pressure rise as the bone is twisted to fracture, but before final fracture when the load-deformation curve turns into a non linear phase, the medullary pressure decreases to a level considerably lower than that of the intact bone

HOFFMAN INSTRUMENTATION FOR UNSTABLE PELVIC RING FRACTURE — DISCUSSION

Gert Walheim
Department of Orthopaedic Surgery Karolinska Hospital, Stockholm

In our department we have studied the special form of pelvic instability after parturition. We have developed a method to measure this instability electro-mechanically One metal pin is put into the os pubis on each side of the symphysis and the movements between the pelvic halves are registered with two transducers connected to a three-channel XY-writer The measuring is done in three different planes. Curves are produced representing movements within the symphysis with force abduction of flexed hips, with standing on one leg and with walking One case of severe symptoms from pelvic instability postpartum is presented. After external fixation with a Hoffman instrument the pains

vanished but recurred immediately after extraction of the instrumentation some days later

HOFFMANN INSTRUMENTATION IN THE TREATMENT OF UNSTABLE PELVIC RING INJURY A CASE REPORT

Tage Sahlstrand
Department of Orthopaedic Surgery,
Östra Hospital, Göteborg

A case with total disruption of the pelvic ring including rupture of the symphysis and both of the sacro-iliac joints is reported A complete reduction and effective stabilization was accomplished by means of Hoffmann's external skeletal fixation using the Hoffmann instrumentation The load-carrying stability was restored after treatment for 6 weeks. This technique seems to offer some definite advantages compared with other methods. The rigid fixation facilitates easy nursing and is convenient for the patient The sliding bar allows adjustment of the compression Distraction with the sliding bar during X-ray

THE HALO IN [illegible]

Department of Orthopedics, Danderyd Hospital, Danderyd

Since 1976 Halo-vests have been used in the treatment of unstable cervical spine lesions at the Orthopedic Clinic, Danderyd Hospital. We have treated [illegible] cases — 7 with dens fractures and 11 with presumptive unstable traumatic cervical spine lesions The treatment technique has been 12 weeks in a Halo-vest and a further 12 weeks with a soft collar Thirteen cases have completed the treatment and have [illegible] healed radiologically, including the seven cases with dens fractures. No serious complications have occurred during treatment It has been possible for the most part to carry out the treatment in the out patient department, which means an important gain in medical rationalization

FRACTURES OF THE FEMORAL NECK IN YOUNG ADULTS BETWEEN 17 AND 50 YEARS OF AGE

C Zetterberg, L Irstam & G B J Andersson
Department of Orthopaedic Surgery I Sahlgren Hospital, Goteborg

Fifty-five fractures [illegible] 54 subjects (28 women and 26 men) occurring in the years 1960 through 1975, were studied Forty were caused by falls [illegible] by traffic accidents and two were stress fractures Fifty per cent of the patients suffered from disease or injury at the time of trauma 11 per cent had premature old-age pensions and 13 per cent serious alcohol problems Late segmental collapse occurred in 42 per cent and reoperation was necessary in 30 cases, among these, [illegible] arthroplasties Thirty-nine per cent of the patients were pain free Only 18 per cent had [illegible] impaired ability to work.

COMPUTERIZED TOMOGRAPHY OF THE ANKLE

[illegible] *Bo Sahlstedt*
[illegible] radiology

Images of transverse frontal and sagittal sections of the ankle were obtained with an Ohio Nuclear Delta 50 FS The axial computerized tomograms have several advantages over conventional tomograms. Incongruency due to fractures, arthrosis and synostosis can be visualized with good diagnostic accuracy

Studies of the talus position in dorsal extension and plantar flexion support Inman's statement that the trochlea being a section of a frustum of a cone, is always in close contact with both malleolar facets. Metal implants give disturbing shadows

CT scanning of the ankle can in certain cases give more clinical information than conventional radiologic methods. Close cooperation between the radiologist and the orthopaedic surgeon is necessary The latter should learn how to operate the display terminal. The images on the screen give much more information than photographs do

RIPLANE EPIPHYSEAL ANKLE RACTURES

aniel R Cooperman, Philip G Spiegel & erald S Laros
ection of Orthopedic Surgery, University of hicago Hospitals and Clinics, USA

Fifteen patients (average age 13 years 5 onths) with triplane fractures are reviewed This oup constitutes 6 per cent of 237 consecutive iphyseal ankle fractures. Fourteen patients were llowed radiologically and 12 clinically for an erage of 26 months post-injury Three patients id premature symmetrical physeal closure thout angular deformity and with less than 0 5 a shortening Three patients had a 5°–10° ternal rotation deformity One of these three tients also had an articular incongruity

In the five cases where tomograms were used to termine the three dimensional configuration of e fracture, a consistent two part fracture pattern as found. The medial part included the tibial aft — medial malleolus — anteromedial iphysis. The lateral part included the remainder of e epiphysis — posterior metaphysis and fibula

TRENCTH[illegible] AL [illegible]

[illegible] CASES
[illegible]rt Walheim & Håkan Lugnegård
[illegible]epartment of Orthopaedic Surgery, St Goran's [illegible]osp tal, Stockholm

There were 22 females and 6 males. All had aput/collum radii fractures In addition 12 had companying fractures (ten in the proximal ulna id two in the capitulum humeri) Elbow strength ts range of motion and grip strength were asured. Four patients had flexion and/or dension defects exceeding 30° and three patients id pronation-supination defects of 30°–115°, t all seven had accompanying fractures of the oximal ulna. Nine patients had valgus deformity d/or valgus instability — valgus deformity °–30° in seven cases and instability of °–20° in six. Only one patient had definite mplaints.

None of the patients had a marked reduction in rength of extension and flexion Strength duction of more than 33 per cent was seen in ronation in seven patients, in supination in five atients and in grip strength in nine patients.

Conclusions After resection of caput radii we ldom encountered complaints of pain or a stricted range of motion. We frequently countered valgus deformity and/or instability, nd reduction of grip and rotational strength.

EFFECT OF HUMAN GROWTH HORMONE IN THE TREATMENT OF PSEUDARTHROSIS

Ragnar Kalén & Torbjörn Ahl
Orthopaedic Clinic, Danderyd Hospital, Danderyd

To investigate the possibility of influencing he healing of pseudarthrosis by administration of Human Growth Hormone (HGH) we have studied 13 patients, aged 42–70, with clinical and radiological evidence of pseudarthrosis. The patients received, at the earliest 6 months after the fracture, 8 IU of HGH daily during a 1 week period and then 8 IU every second day for another 5 weeks, except for the first three cases who were given half that dosage In nine cases healing was obtained within 6 months, while in four cases treatment was unsuccessful. No side effects were observed

Extended trials are now being performed to elucidate whether HGH treatment might be of value as a complement to accepted surgical therapy

HUMAN LEUKOCYTE INTERFERON

Hans Strander
Radiumhemmet, Karolinska Hospital, Stockholm

Interferon is a protein produced by all cells in the organism exposed to viruses. The molecular weight of the active molecule is approximately 21,000 The amino acid sequence is being elucidated at present Interferon is known to affect several body functions, the most important effects being anti-viral, growth-inhibitory and immunological Interferon has been shown to inhibit tumor-growth in experimental animals.

Human leukocyte interferon is produced by exposing white blood cells from blood donors to parainfluensa 1 virus. The cells produce interferon within 24 h and the interferon is then concentrated and purified. The standard preparation employed at the clinic, P–IF, contains $5–20 \times 10^6$ interferon units per ml and $4–20 \times 10^5$ interferon units per mg of protein. This preparation has been available for clinical use since 1973 A summary of the various properties of human leukocyte interferon is given.

SIDE EFFECTS OF HUMAN LEUKOCYTE INTERFERON THERAPY

Snorri Ingimarsson & Hans Strander
Radiumhemmet, Karolinska Hospital, Stockholm

Human leukocyte interferon is given by intramuscular injection daily or three times a week

the dose is $2-3 \times 10^6$ standard units. Twelve distinct signs and symptoms have been recognized as possible side effects of the drug The three most frequent are fever, local pain and shivering Partial purification of the interferon eliminated some but not all of the symptoms. So far all the patients have been treated on an ambulatory basis and none has had to discontinue the interferon therapy

The peripheral blood count has not changed A slight rise in sedimentation rate was noticed during interferon treatment It is concluded that long term therapy with exogenous human leukocyte interferon has so far caused no dangerous nor irreversible side effects in the treated patients

INTERFERON AS ADJUVANT THERAPY IN OSTEOSARCOMA — 3-YEAR FOLLOW-UP STUDY

Lars Ake Brostrom
Department of Orthopaedic Surgery, Karolinska Hospital, Stockholm

Exogenous interferon therapy has been given to a consecutive series of osteosarcoma patients presenting no signs of metastases on admission The series now includes 34 patients with classical osteosarcoma It was compared with a "historical" control group of 35 patients and recently with a [illegible]" group of 23 patients who together [illegible]th the interferon group comprise all osteosarcoma cases in Sweden during the years 1972–75 Neither control group initially showed evidence of metastases or received adjuvant therapy At the 3-year follow up the outcome for the concurrent group was twice as good as for the historical group, but analysis of different variables of possible prognostic importance disclosed differences which might contribute to this result Larger and more malignant tumours were found in the historical group and the concurrent group received more active treatment of pulmonary metastases with surgery and high-dose chemotherapy The 3-year follow-up is perhaps too short to permit any definitive inferences but there are clear numerical differences between the interferon treated and the concurrent control group with regard to absence of metastases (6[illegible] per cent as against 35 per cent) and survival rate [illegible]0 per cent as against 40 per cent) The study c[illegible]nues and the groups are constantly be ng added

ENDOCRINOLOGICAL ASPECTS IN OSTEOSARCOMA

Lars Åke Broström
Department of Orthopaedic Surgery, Karolinska Hospital, Stockholm

It has been suggested that hormo[illegible] mechanisms may be a factor in the pathogen[illegible] of osteosarcoma and might have a bearing on t[illegible] course of the disease The peak inciden[illegible] coincides with the puberty growth spurt and t[illegible] tumour is usually located in the metaphy[illegible] region of long bones in the vicinity of the gro[illegible] zones A preponderance of tall individuals with [illegible]teosarcoma has been reported Forty four pati[illegible] [illegible] 1973–19[illegible]

[illegible] difference from expected growth curves at [illegible] time of diagnosis These findings could [illegible] confirmed from teeth eruption curves, which sh[illegible] a high correlation with somatic development

[illegible]MICAL

Tomas Aparisi
Department of Orthopaedic Surgery, Karolinska Hospital Stockholm

The fine structure of the different cell type[illegible] been studied in six human osteosarcomas and [illegible] localization of acid and alkaline phosphata[illegible] relation to the subcellular organelles demonstr[illegible] Biochemical studies have been carried ou[illegible] compare the enzyme activity of acid phosph[illegible] and non-specific alkaline phosphatase betwe[illegible] teosarcomas and other, non-malignant [illegible] tumours i.e giant cell tumour and aneur[illegible] bone cysts. The results show that a predom[illegible] cell type, osteoblast like, occurs in all the [illegible] teosarcomas studied These cells have a [illegible] alkaline phosphatase activity on the p[illegible] membrane Acid phosphatase activity is [illegible] present in lysosome-like structures of some o[illegible] cells constituting the tumours. The quan[illegible] acid phosphatase in relation to non-sp[illegible] alkaline phosphatase seems to be related to [illegible] tumour's neoplastic activity

)CAL RESECTION OF OSTEOSARCOMA STEAD OF AMPUTATION

f Nilsonne
partment of Orthopaedic Surgery, Karolinska osp tal, Stockholm

In view of the promising results with interferon adjuvant therapy for osteosarcoma it was ght possible to avoid amputation Instead, al resection was resorted to as soon the eraphy of the tumour permitted local surgery h a safe margin to the tumour area Local ection was performed for osteosarcoma mainly the h p and knee region, but also in some cases r osteosarcomas of the pelvic ring The defect ted by the resection was reconstructed either r different kinds of autogenous bone grafting or th ruficial implants some of them being ally designed to fit into rather big defects. In tal of 15 cases of osteosarcoma, locally ted five local recurrences have occurred, ntitating subsequent amputation

[illegible]

-Erik Larsson
rtment of Orthopaedic Surgery, Umeå

tal spondylectomy has been described for (Lievre et al. 1968) ThXI LI (Stener & en 1971) and ThVII (Stener 1971) ularization of the medulla is most critical at evel of ThIII A 22 year-old female received ectomy in February 1975 and high-voltage therapy and in December 1975 decompres- of the medulla because of recurrent plegia. Progression and vertebral collapse l necessitated in January 1977 posterior and thoracic radical extirpation of the tumour n protruded from the dorsum through the astinum infiltrating the lung and completely unding the medulla. The third thoracic ora was completely removed and parts of the d and fourth vertebrae Iliac bone blocks structed the body of ThIII stabilized by plates dorsally The patient was mobilized 3 months in a plaster bed She is walking well 1½ years after operation and shows plete neurological restitution. She has a stable with the plates removed and full working ly There are no signs of tumour recurrence or stasis.

SURGERY OF CHONDROSARCOMA OF THE PELVIS

Sven Erik Larsson
Department of Orthopaedic Surgery, Umeå

A thorough review of all 163 unequivocal chondrosarcoma cases, recorded in the Swedish Cancer Registry 1958–68, showed that 48 lesions were located in the pelvic bones Out of the 29 inoperable cases none survived 5 years. Hemipelvectomy performed in 10 cases resulted in a survival rate of 60 per cent, 7 cases having local extirpation or curettage survived in less than 33 per cent

The pelvic chondrosarcomas were pre-

Therefore, advanced pelvic resections were performed in the present material. Two patients with more than 10 cm large tumours of the pubic bone had extensive anterior pelvic resection with good radicality and undisturbed walking ability One patient with a large tumour of the whole right ilium had a resection through the right sacrum, the pubic bone and the ischium. An endoprosthesis was fixed to the latter bones which made it possible to save the leg with intact neurological and circulatory function She was able to walk with two crutches. Another patient with a large tumour of the right ilium had a radical resection of the ilium ischium and pubic bones. His leg was saved with a specially constructed pelvic-hip prosthesis He could walk on crutches with satisfactory function of the preserved extremity

Improvement of radical pelvic resection techniques, in some cases with primary prosthetic reconstruction, may thus afford radical tumour removal good palliation and also improved quality of life for this category of patient

FURTHER EXPERIENCES WITH ACRYLIC CEMENTATION OF GIANT CELL TUMOURS OF BONE

Bjorn M Persson & Anders Rydholm
Department of Orthopaedic Surgery University Hospital Lund

After thorough curettage nine cases of giant cell tumour of bone have now been cemented and observed for a period of from 1 to 6 years as presented below In the beginning this method was supposed to be a salvage procedure but now

Case	Age	Sex	Localization	PAD	Obs time (years)	Recurrence	Meta
1	66	F	P Tib	Rec GCT	[illegible]	—	—
2	31	F	I Sch	Px GCT	5	—	—
3	45	F	P Tib	Sn GCT	5	—	—
4	28	F	D Fem	Sn GCT	5	—	—
5	29	M	P Hum	— GCT	2	—	—
[illegible]	25	F	P Fem	— CYS	2	—	—
7	40	F	[illegible] Fem	— GCT	1	—	—
8	36	F	D Rad	— GCT	1	—	—
9	30	M	D Fem	Rec GCT	1/2	—	—

it seems to be the method of choice for every giant cell tumour of significant magnitude If recurrences should appear later all the original possibilities for surgical intervention can still be employed

TECHNETIUM DIPHOSPHONATE SCINTIGRAPHY FOR LOCALIZATION OF A CONCEALED OSTEOID OSTEOMA

[illegible]

An osteoid osteoma in the tibial shaft in a 14-year-old boy was located by technetium diphosphonate scintigraphy The tumour was masked by extensive osteosclerosis. Neither conventional radiography nor linear tomography revealed it Several previous operations made the radiographs difficult to interpret At scintigraphy a high uptake of radioactivity was noted within a defined area of the sclerotic bone At operation an osteoid osteoma was found in the indicated area The diagnosis was confirmed histologically Following surgery the symptoms disappeared Six months later further symptoms occurred and neither conventional radiography nor computer tomography revealed an osteoid osteoma Scintigraphy now showed a small area with heavy radioactive uptake 2 cm cranial to that observed at the previous scintigraphy Tomography with hypocycloid movement in the indicated area then revealed an osteoid osteoma The nidus was excised and the diagnosis confirmed histologically Thus in this case the uptake of radioactive technetium by the osteoid osteoma indicated its level exactly within the large area of sclerotic bone, and with a refined tomogr[illegible] technique the tumour could then be demonst[illegible]

FINE NEEDLE ASPIRATION CYTOLOG[illegible] THE DIAGNOSIS OF TUMOURS OF SO[illegible] TISSUE

Anders Rydholm, Ingrid Idvall, Bjorn M P[illegible] & Måns Åkerman
Department of Orthopaedic Surgery and Cytodiagnostic Department, University Hosp[illegible] Lund

A consecutive series of 171 fine needle a[illegible] tion biopsies in patients referred to [illegible] Orthopaedic tumour group, University Hosp[illegible] Lund during the years 1973–1977 was analy[illegible] regards the reliability of the method.

Final diagnosis	Cytological diagnosis		
	Malignant	Benign	Insufficient material
malignant	35	4	4
benign	6	109	13

Final diagnosis was verified by histolog[illegible] cases) or 2 years of clinical observation (42 [illegible] Sufficient material for cytological diagnosis obtained in 90 per cent of which 93 per cent [illegible] correct. Thus fine needle aspiration biopsy [illegible] considerable value in the planning of sur[illegible] Only when amputation is being consider[illegible] cytology supplanted by histology

med Lazer & Ake Kjellquist
Orthopaedic Department Angelholm Hospital and
Department of Neurosurgery Lund University
Hospital

1 A 75 year-old healthy woman with a 3 year history of typical symptoms of a carpal tunnel syndrome in her right hand At exploration multiple tumours up to the size of small birds eggs were found in the nerve and were extirpated Histoscopy showed neurofibromatosis Three months later she was free from symptoms

2. A 38 year-old woman with pain for 11 years in her left thigh Seven years previously Mb Recklinghausen was diagnosed Slight paresis muscle atrophy and hypaesthesia Four neurofibromatous tumours of up to hazelnut size were extirpated followed by definite improvement

The incidence of Mb Recklinghausen is 1 3000 5–10 per cent arising specifically in peripheral nerves.

Discussion Severe pain is an indication for operation which should be done by microsurgical technique, minimizing the risk of functional dis

[illegible] has

Acta orthop scand. 50, 123–126, 1979

PROCEEDINGS OF THE FINNISH ORTHOPAEDIC ASSOCIATION

Helsinki, Finland, March 11, 1978

EDITOR A ALHO

EXPERIMENTAL TOURNIQUET ISCHAEMIA

S Santavirta, A Aritila, K Höckerstedt & I Ainikoski
Division of Orthopaedic Surgery and Traumatology, Surgical Hospital, Helsinki University Central Hospital, Department of Surgery, Turku University Central Hospital, and Department of Cell Biology, Jyvaskyla University

The effect of experimental tourniquet ischaemia (1 to 3 hours) on the circulation, muscle oxygen tension and fine structure of striated muscle of rabbit hind limb was studied

Muscle blood flow was investigated using the xenon clearance method The results obtained suggest that even when the tourniquet time is extended to 3 hours, no blood flow occurs in the limb distal to the tourniquet when the cuff is inflated to 300 mmHg A hyperaemic reaction followed release of the tourniquet and the magnitude of reactive hyperaemia was independent of the length of the tourniquet time The hyperaemia was regularly of short duration and peak flow values were reached in 1 minute, with the flow returning to normal or subnormal values after 5 minutes.

Tissue oxygen tonometry with implanted plastic tubes was employed to register the effect of tourniquet blockade on the muscle PO_2 The muscle microclimate never reached fully anoxic conditions. The rapid response of muscle PO_2 to oxygen breathing suggests expedient recovery of tissue oxygenation after tourniquet occlusion

Ultrastructural changes were noticed primarily in the energy producing organelles Ischaemia (extended up to 3 hours) caused only reversible, sublethal damage to the muscle cells.

HISTOQUANTITATIVE ANALYSIS OF BONE TISSUE

Hannu Pätiälä
Institute of Clinical Sciences, University of Tampere, and Tampere Central Hospital

In many diseases of bone there is reason to subject the areas of resorption and bone formation to histoquantitative analysis by examination of microtome sections which are not demineralized A useful aid in these studies is the test field for calculating points and intersections of the surface with the test line, as developed by Merz (*Mikroskopie* 22: 132, 1968) This makes it possible to quantify the different structures and to assess the intensity of bone resorption and formation

Schenk's method is applied to pieces of bone stained with fuchsin and embedded in methacrylate Sections are ground from the block for fluorescence and microradiographic examinations. After the end of the block has been moulded, microtome sections are obtained for the investigations mentioned above (10 µm) and for Goldner, van Kossa and modified Movat staining (5 µm)

Cells, osteoid and mineralized bone are clearly distinguished in Goldner staining Using modified Movat staining, the different fractions are so clearly distinguished that the specimens can be used for computer-assisted image analysis in addition to ordinary analysis performed using the test field Matrix and mineralized bone are properly identified with van Kossa's staining More quantitative results are required in basic research on bone and in clinical investigations Subjective evaluation can be replaced by the use of measurable quantities.

EXPERIENCE WITH THE TREATMENT OF PERTHES' DISEASE

M Pousa & L -E Laurent
Orthopaedic Hospital of the Invalid Foundation, Helsinki

The management of Perthes' disease at the Orthopaedic Hospital of the Invalid Foundation was by conservative means until 1969 These methods achieved a good result in about 50 per cent of cases (Edgren *Acta orthop scand* Suppl 84, 1965).

In this study the results were related to Catterall's groups During the period 1969–1974, 52 patients were treated conservatively and 66

0001–6470/79/010123–04$02.50/0

© 1979 Munksgaard Copenhagen

patients were treated using intertrochanteric varus osteotomy. Seventeen cases in group I were treated conservatively, the results were good in all of them. Eleven belonged to group IV, and in only one of them was the result assessed as good after treatment. On the other hand, 30 of the patients treated using intertrochanteric osteotomy were in group IV, the results in 8 of them were assessed as good after treatment. Some patients dropped into a lower group during the course of the disease. The following accessory operations were performed: two Chiari pelvic osteotomies, one shelf operation, one partial resection of the caput, and one epiphyseodesis of the contralateral femur.

POSTERIOR DISLOCATION AND POSTERIOR FRACTURE-DISLOCATION OF THE SHOULDER

M. Vastamäki & K. Solonen
Orthopaedic Hospital of the Invalid Foundation, Helsinki

Posterior dislocation (PD) and posterior fracture-dislocation (PFD) of the shoulder are rare injuries but should not be missed at the first examination. Both types of joint derangement may result from trauma or convulsive seizure. The diagnosis may be made when the shoulder locks in adduction and internal rotation. The most important single reason for missing the diagnosis is taking only an A–P X-ray. An axillary roentgenogram is essential. Three patients (32 to 69 years of age) had delayed diagnosis and treatment: one bilateral PFD due to an electric shock, one bilateral PD occurring during a convulsive seizure, and one PFD during an epileptic [illegible]. The treatment was given from 3 months to 2 years after injury. The fractures healed uneventfully. In one of the bilateral cases one side was operated on with a temporary Kirschner wire fixation. The results in both cases were good. The other dislocations were treated with physiotherapy with fair results. A recent dislocation should be treated with closed reduction. Failure to make an early diagnosis may necessitate operative intervention. Late operative treatment can give reasonably good results.

RECOVERY AFTER PRIMARY DISLOCATION OF THE SHOULDER

H. Jaroma, O. Kivisuoto, M. Pasila & A. Sundholm
Department of Orthopaedics and Traumatology, Helsinki University Central Hospital

A total of 227 out of 239 primary shoulder dislocations, treated at the Emergency Department and the Physiotherapy Department during the years 1973–1976, were followed up for 1 year [illegible] mobilized with a mitella for 1 week, while in the second group the affected upper extremity was maintained at the patient's side for 3 weeks. The third group comprised 130 patients over 50 years of age; they were treated in the same way as the patients in the first group.

Redislocation occurred in 30 cases within [illegible] year. It was significantly more frequent ($P < 0.0$[illegible]) in the first and second groups than in the third group. The duration of immobilization had no effect on the frequency of redislocation. Normal active mobility was recovered first in the first group and last in the third group (the median times were 22 and 52 days, $P < 0.001$). The time taken for normal active mobility of the shoulder to be regained was significantly longer in the subgroup of 63 patients with rotator cuff or nerve lesions and similarly in the subgroup of patients whose dislocation was not reduced within [illegible] hours.

Fourteen out of 38 cases with axillary or brachial plexus nerve lesions failed to regain good function within 1 year.

[illegible] OF

Department of Orthopaedics and Traumatology, Helsinki University Central Hospital

Seventy patients (53 men and 17 women) with subcutaneous rupture of the Achilles tendon during the period 1969–1974 were followed up until 1977. Most injuries occurred in persons between 30 and 50 years of age. Seventy per cent of the injuries were sports injuries.

All patients were operated on using Lindholm's technique in 42 cases, suturing in 15, Visser's technique in 5, Silverskiold's in 4, Bosworth's in 2, duplication in one and reinsertion to the calcaneal bone in one case. A plaster cast was applied for 6–8 weeks. Fifteen wound infections (9 superficial and 6 deep infections) and one deep thrombosis occurred. There were two ruptures, but the cause was a distinct new trauma in both cases.

According to the patients the result was excellent or good in 97 per cent and fair in 3 per cent. The Achilles tendon was thicker and the calf thinner on the operated side ($P < 0.001$). There was not a significant loss of power of plantar

flexion, nor any notable change in the range of motion. The results were better with an early operation (within 3 days) than with later ($P<0.05$) Infection had a detrimental on the result ($P<0.001$)

RUPTURE OF THE THORACIC AORTA DUE TO BLUNT TRAUMA DIAGNOSTIC ASPECTS

[illegible] umatology,

Twelve cases of rupture of the thoracic aorta due to blunt trauma were detected among patients treated in the period 1970–1977 Five pedestrians, one cyclist and one motorcyclist were struck by cars the other five patients were drivers or passengers involved in car accidents The clinical signs do not have much diagnostic value, weak or absent pulsations of the femoral artery were seen in two cases, one patient was paraplegic Seven patients had elevated central venous pressure The chest X ray showed blurring of the normally sharp outline of the aorta and a widened mediastinum in all cases, and a left apical extrapleural cap in nine cases The X ray signs were most obvious 6 hours after the trauma, and later diminished The haematomas seen in an X-ray may not be due to the aortic intimal rupture itself but instead may be caused by tears in small arteries and veins The diagnosis was made using aortography in seven cases clinically in one case, at operation in one case and during autopsy in three cases All the ruptures were situated at the proximal descending aorta Five patients were operated on between 6 hours and 2 months after the trauma All the operations were successfully performed at the Department of Thoracic Surgery The aortic rupture was the cause of death in four cases, two patients died from brain injury and one patient from an uncontrollable retroperitoneal haemorrhage

Aortography should be performed on the basis of the trauma mechanism, elevated CVP and chest X ray findings.

PROCESS[illegible]

[illegible]

Jussila & L. Saloranta
Department of Surgery Kotka Central Hospital

Compression of the median nerve due to the anatomical anomaly called processus supracondyloidea humeri is a rare condition. One case was described EMG aided in the diagnosis. The treatment was subperiosteal resection of the process together with the origin of the pronator teres muscle

PRIMARY MALIGNANT BONE TUMOURS 874 CASES

P. Jussila
Department of Surgery, Kotka Central Hospital

A total of 874 primary malignant bone tumours were registered in Finland during the years 1962–68 All cases were verified by histopathological methods 124 osteosarcomas, 4 parosteal osteosarcomas, 71 chondrosarcomas, 25 giant cell tumours, 18 Ewing's sarcomas, 13 reticulosarcomas, 6 lymphomas, 545 myelomas, 10 extramedullary plasmocytomas, 4 angiosarcomas, 2 haemangiopericytoma-sarcomas, 14 fibrosarcomas, 4 chordomas, 2 postradiation sarcomas, 1 neurosarcoma, 9 primary malignant fibrous histiocytomas, 19 sarcomas NUD, 1 fibrolipomyxoma malignum, 1 chondromyxoma malignum and 1 fibromyxoma malignum.

50 9 per cent of the patients were males. The mean age of the males was 52.5 years, and that of females 57 0 years. The mean age in cases of osteosarcoma was 31 6, primary chondrosarcoma 42.6, giant cell tumour 36 0, Ewing's sarcoma 19 1, fibrosarcoma 47 0, and myeloma 63 0 years.

Five-year survival rates were osteosarcoma 28 2 per cent, parosteal osteosarcoma 50 0 per cent, primary chondrosarcoma 35 9 per cent, secondary chondrosarcoma 61 1 per cent, malignant giant cell tumour 60 [illegible] per cent, Ewing's sarcoma 16 7 per cent, reticulosarcoma 15 4 per cent, lymphoma 0/6, solitary myeloma 41 7 per cent, myeloma multiplex 10 8 per cent, extramedullary plasmocytoma 50 0 per cent, angiosarcoma 25 per cent, fibrosarcoma 21 4 per cent, primary malignant fibrous histiocytoma 22 3 per cent

Institute of Clinical Sciences, University of Tampere, and Tampere Central Hospital

Ninety-eight patients with fractures of the thoracic spine, treated during the years 1968–1975, were examined (21 per cent of all vertebral fractures) The mean age of the patients was 42 years range 4–84 years. The duration of hospital treatment was approximately 18 days. Nearly one half of the patients were injured in

traffic accidents Sixty patients had only one fractured vertebra, three patients had five fractured thoracic vertebrae Anterior wedge fracture was the most common type of injury, 87 fractures were stable Only seven patients showed a dislocated corpus fracture Neurological lesions were noticed in eight patients paraplegia in five and incomplete medullary and nerve root lesions in three, one patient with paraplegia was treated using operative reduction and plate fixation

Most often treatment consisted of bed rest until the patient experienced no pain Muscle exercises were started immediately The average duration of bed rest was 18 days.

A follow-up examination was performed in 78 cases, on average 5 3 years after the injury The movements of the back were considered normal in 55 cases The neurological findings were unchanged in 75 and worse in three patients Nine patients were unable to work owing to the injury The mean duration of work disability was 95 days, range 10–261 days

REPLANTATION OF AMPUTATED FINGERS AND HANDS

S K Vilkki

Institute of Clinical Sciences Univers ty Tampere, Tampere Central Hospital

With the development of microsurgical te ques, replantation has become an alternative of treatment of amputative injuries in centres Case selection is most important in to obtain acceptable results. Indications and traindications should be carefully weighed

the amputated part, (4) level of amputatio time factor, (6) age of the patient, (7) asso injuries and illnesses These lengthy emer operations require special arrangements regard to the operating team, anaesthesia postoperative care In finger replantation a phase system was presented (a) preparator bone stabilizing procedures, (b) volar recon tion, (c) dorsal reconstruction Skin c temperature, capillary filling Doppler sound blood haematocrit are monitored postoperat Complications may arise mainly during the week and the main causative factor seems venous thrombosis in the microanastomosis the injured vessels in the replanted part

Letter to the Editor

Dear Sir,

In the paper by O J Fasting et al, "Bone cintigraphy in early diagnosis of Perthes' lisease" which appeared in *Acta orthop cand* 1978, 49, 169–174, the authors refer o my paper "Densitometry and 18-F scintiraphy in the study of revascularization of he femoral head in Coxa Plana" from *Acta rthop scand* 1973, 44, 417–425 The eference reads follows "In an investigaon using F^{18} scintigraphy, Bohr (1973) ound increased uptake in the initial stage nd supported the opinion that the increased ensity was due to appositional bone formation" This is not correct as it was clearly shown in my paper that during the early stage of Coxa Plana (C.P) the uptake of F^{18} in the lateral part of the femoral head was reduced compared with the normal side, and it was pointed out that the reduced uptake was an indication of necrosis The findings of O J Fasting et al, showing a reduced uptake in the early stage of C P, are thus in agreement with the results of my previous investigation and the above-mentioned authors ought to have given me the credit of priority

Hans Bohr, M D

ANNOUNCEMENT

The XIII International Congress of the World Federation of Hemophilia will be held in Tel Aviv, July 8–13, 1979 The program will include the following five invited symposia

The Mechanisms of Blood Coagulation Current Understanding, Chairperson S I Rapaport, M D

Molecular and Genetic Aspects of Factor IX, Chairperson H Roberts, M D

Hemophilic Arthropathy, Chairperson M Gilbert, M D

The Hepatitis Problem in Hemophilic Patients, Chairperson P Jones, M D

Factor VIII and Factor IX Inhibitors, Chairperson S S Shapiro M D

In addition there will be workshops and panel discussions

For further information please contact the Secretariat, the XIII International Congress of the World Federation of Hemophilia P O Box 16271, Tel Aviv, Israel.

Acta orthop scand 50, 129–138, 1979

ALLOGENEIC TRANSPLANTATION IN LOW-GRADE MALIGNANT BONE TUMOURS

I New Operative Technique to Avoid Amputation

ARKEI V S KOSKINEN, PENTTI SALENIUS & ANTTI ALHO

Department of Orthopaedics and Traumatology, University Central Hospital, Helsinki, Finland

A massive allografting of deep-frozen cadaver bone or hemi-joint was performed in 11 patients with tumours which were diagnosed as aggressive, low-grade malignancies. One patient died from a pre-existing hepatic insufficiency The other 10 patients have been followed up from 1 to 8 years. These patients received two bone grafts and eight hemi-joint grafts around the knee joint The operative procedure consisted of fixation of the graft by stable osteosynthesis, surrounding the graft-host junction with an autogeneic iliac chips cuff and, in cases of hemi-joint grafts, reconstruction of [illegible]

operations.

A full restitution of function was achieved in the bone graft cases. The patients with hemi-joint grafts were also able to retain their limb with a good or satisfactory function No metastases or recurrences were experi- [illegible]

Key words: bone neoplasms, bone neoplasms, surgery, chondroblastoma, surgery, giant cell tumours, surgery, parosteal osteosarcoma, surgery, bone transplantation, allogeneic

Accepted 1 x.78

Clinical experience in using allogeneic bone-cartilage transplants dates back to the beginning of this century (Lexer 1908) However, it was only in the 60's, after asepsis and osteosynthesis techniques had been improved, that this method gained a broader clinical use (Parrish 1966, Nilsonne 1969, Volkov 1970, Ottolenghi 1972) One of the cornerstones in the development was deep-freezing of the graft as a means of preservation (Imamaliev 1969)

The indication for allograft replacement has been a locally aggressive bone tumour, where the tendency to metastasis formation is minor and where the therapeutic alternative is in most cases a mutilating amputation (Mankin et al 1976) The present report relates the experiences gained in the treatment of 11 low grade malignant bone tumours using a technique (Koskinen 1978) in which cadaver grafts of bone and bone-cartilage are combined with fresh autogeneic cancellous bone grafts

PATIENTS AND METHODS

During 1970–1977 eleven patients received an osseous or osteoarticular allograft as replacement

0001-6470/79 020129-10$02.50/0

© 1979 Munksgaard, Copenhagen

Table 1 Eleven cases of bone and hemi joint allotransplantation

Case	Sex	Age	Tumour	Type of replacement (1)	Duration of plaster immobilization (months)	Period of non-weight-bearing (months)	Complications	Radiological joint degeneration	Functional result and working ability (2)	Follow up period (years + months
1	M	34	Giant cell tumour	DFHJ	3	9	Progressive deterioration of the joint	+++	Stable 10°–120°, disabled	8 + 2
2	F	20	Fibrosacroma	TMD	6	12	Fatigue fracture, united		Normal at work	7 + 7
3	M	24	Osteosarcoma	HMD			Died from polycystic hepatic degeneration (see text)			
4	F	37	Fibrosarcoma	TMD	7	14	None		Normal at work	4 + 3
5	M	32	Giant cell tumour	DFHJ	6	9	Collateral ligament insufficiency	+	5° varus, stable 0°–85° undergoing re-education	3 + 6
6	M	34	Giant cell tumour	DFHJ	5	10	None	++	Stable 0°–50°; undergoing re-education	3 + 2
[illegible]	[illegible]	[illegible]	[illegible]	[illegible]	[illegible]	[illegible]	[illegible]	[illegible]	[illegible]	[illegible]
9	M	42	Parosteal osteosarcoma	DFHJ	9	9	None	—	[illegible]	[illegible]
[illegible]	[illegible]	[illegible]	[illegible]	[illegible]	2	9	None	++	Stable 0°–70° [illegible]	1 + 9

7	F	17	Chondroblastoma	DFHJ	8	8	None		[illegible] at work	[illegible]
8	M	23	Giant cell tumour	PTHJ	6 (3)	12	Fatigue fracture at 5 months, united	+	Stable 0°–70°, undergoing re-education	2 + 3
9	M	42	Parosteal osteosarcoma	DFHJ	3	9	None	–	Stable, 0°–70°,	1 + 9
10	M	26	Giant cell tumour	DFHJ	2	9	None	++	Stable, 0°–70°, undergoing re-education	1 + 9
11	M	23	Parosteal osteosarcoma	DFHJ	4	6	Fracture at the graft-host junction, united	–	Mobilized, gradual weight-bearing	1 + 3

(1) DFHJ – Distal femoral hemi-joint graft
TMD – Tibial metaphysial-diaphysial graft
HMD – Humeral metaphysial-diaphysial graft
PTHJ – Proximal tibial hemi-joint graft

(2) Joint stability, degree of extension-flexion
(3) Primary immobilization for 2 months, immobilization was reinstated after the fatigue fracture

for a radically removed bone tumour The tumours were giant cell tumour – 5, fibrosarcoma – 2 parosteal osteosarcoma – 2, chondroblastoma – 1, and osteosarcoma – 1 (Table 1) The osteosarcoma had arisen from a giant cell tumour Two of the giant cell tumours had shown their aggressiveness by a local recurrence after earlier surgery Three tumours presented themselves clinically as pathological fractures. The diagnosis was verified by open biopsy and the extent determined by angiography and ^{99m} technetium diphosphonate scanning Metastases were excluded by chest films supplemented by planigraphy and lymphography

In seven cases the operation consisted of a distal femoral hemi joint replacement and in one case of a proximal tibial hemi-joint replacement Metaphysial-diaphysial grafting was performed on the humerus in one patient and on the tibia in two The donors were patients who had died suddenly from subarachnoidal haemorrhage or accident. Their ages varied from 16 to 50 years. Their histories were checked for chronic diseases, malignancies, infections and medication The size of the graft bone was taken into consideration but not the sex, blood group or tissue typing of the donor The grafts were removed within [illegible] hours of death, and in accordance with Finnish law The removal was performed in the operating room All soft parts, muscles, ligaments and periosteum were removed and the bone marrow curetted Bacterial cultures were taken from the transplant surfaces after the removal and immediately before the transplantation In one case a positive saprophyte culture (*Aspergillus nigra*) was obtained before the planned operation. This did not affect the postoperative course under antibiotic coverage. The graft was preserved in a sterile plastic bag at a temperature of −70°C for 48 hours and at −20°C for 30–180 days. Before the transplantation the graft was thawed for 12 hours at +8°C and rinsed with antibiotic solution (Koskinen 1973)

The removal of the tumour was performed as a radical *en bloc* resection including the scar after the previous biopsy and the diseased bone with a large bone and soft tissue margin The knee ligaments could be saved except in one case with involvement of the medial collateral ligament, which was reconstructed In no case was the main vessel nerve bundle affected

In eight hemi-joint replacements the graft was cut to match the resection level and a stable AO/ASIF osteosynthesis (Müller et al 1970) was performed (Figure 1) A cuff of autogeneic iliac bone was invariably built-up around the host-graft contact plane This was done in order to stimulate the process of bony union and promote bone regeneration in the graft itself (Koskinen 1973) The host ligaments were connected with the graft using nonresorbable sutures in bone tunnels The posterior tendon-capsule envelope was specially attached Suction drainage, antibiotics and plaster immobilization were in the aftertreatment.

In cases of massive metaphysial-diaphysial resection a corresponding technique was used extending the osteosynthesis plate over the graft and grafting iliac bone chips around both junctions (Figure 2)

At the time of reporting (May 1978), the follow-up times varied from 8 years 2 months to 15 months (median 2 years 10 months). During the first year the patients were examined [illegible] month intervals and thereafter usually at intervals. To check the incorporation of the X rays were taken regularly, and biopsies in seven cases between 3 months and 7 years (H et al 1978) Furthermore, chest films haematological studies were done at regular tervals.

The postoperative plaster immobilization varied from 3 to 8 months. Full weight was allowed between 6 and 14 months.

RESULTS

Primary operative results All transplantations were technically successful and resulted in stable osteosyntheses where infections were not experienced One early positive death from previous liver disease will be discussed later under complications (Case [illegible] Thus the follow-up study consists of 10 with tumours in the vicinity of the knee or in the diaphysis of the tibia

The total number of operative procedures in the series was 20, five of these being separate biopsies In two cases the osteosynthesis implant has been removed.

Immobilization and weight bearing The length of the plaster immobilization always exceeded the time expected for healing of the soft tissues and even with the shortest immobilization time no adverse effects were observed. In all but one case (Case [illegible]) weight-bearing was gradually increased to full load between 8 and 14 months. The criteria for increasing loading was radiological consolidation at the autogeneous sleeve area



Figure 1 Case 7 Distal femoral chondroblastoma in a 17 year-old girl (a) Distal femoral allograft 6 months postoperatively Fusion is progressing tween the cadaver graft and femur with a callus sleeve from autogenic bone around the junction (b) Solid union 1 5 years after the operation (c)

between host and graft In Case 11 weight-bearing was obviously allowed too early At 6 months the plate and bone fractured at the host-graft junction, which shows the importance of bone consolidation in this area In Case 8, where the progress of healing was very rapid, partial weight-bearing was attempted 2 months after the transplantation A fracture of the graft, considered a fatigue fracture, occurred 3 months later With reosteosynthesis and plaster immobilization for a further 4 months, and non-weight bearing for a total of 1 year, consolidation was finally achieved

Incorporation of the graft As judged radiologically, a reliable bridge formation over the host-graft junction was obtained between 8 and 14 months At that time full weight-bearing was usually allowed Concerning the organic incorporation of the graft as a whole, no conclusive information could be obtained by X-ray studies.

In the scintigraphic studies using ^{99m}Tc diphosphonate, increased activity at the host-graft contact plane could be observed as h as 2 5 years after operation In one pa (Case 7) a large isolated patch of incre activity was observed in the distal fem graft metaphysis as early 3 months po grafting From 5 months (Figure 3) to years a diffusely increased uptake observed on the host side adjacent to t junction Seven years after the grafting Case 1, no elevation of isotope uptake co be observed, indicating a stabilized sta no time were any large areas of incre activity observed in the graft nor could time sequence be demonstrated indicating incorporation of the graft by creeping s stitution. Evidence of slow but ste progress in new bone formation and remo ling of the graft is given by the radiolog disappearance of the drill holes made ligament reconstruction in the fem condyles.

In connection with a secondary grafting after fatigue fracture of

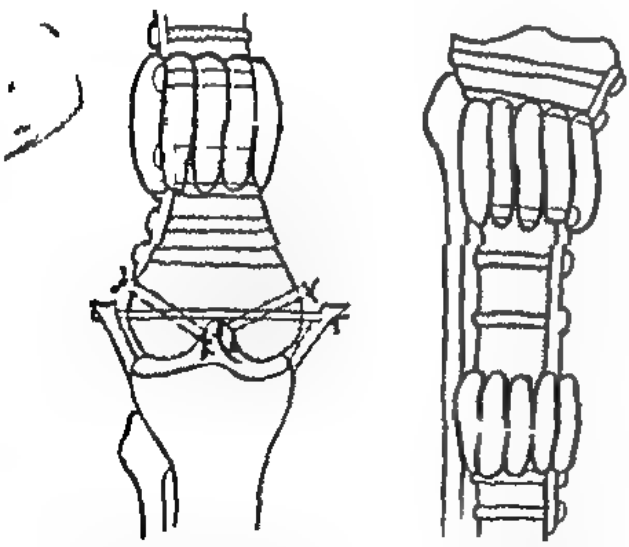

Figure 2 Schematic presentat n f the operative techniques Distal femoral m oint replacement and tibial metaphysial diaf grafting The junctions of allograft and ne were sur rounded by autogeneic iliac ps rigid AO osteosynthesis was used and e l gaments were fixed by sutures through c als

Figure 3 ^{99m}Tc diphosphonate scintigraphy of transplant shows increased activity 5 months p operatively as a sign of early creeping sub tion in the right distal femur (Case 9).

nsplant in Case 2, a biopsy was taken from middle of the graft It revealed well-ed lamellar bone with regular osteones d living osteocytes and osteoblasts 5 years er the allogeneic grafting These findings re also noted in an arthroscopic biopsy at years.

anges in the cartilage Varying stages of tilage degeneration were seen on X-ray amination at follow-up These changes re not distinctly time-dependent (Table 1) wever, the most noticeable changes were and in the earliest case, and even this tient did not experience any pain in the ee Moderate changes were observed in two ses and slight changes in a further two ses between 1 5 and 3 years Three patients owed no cartilage deterioration, the longest llow up being 2 years and 5 months

Figure 4 Biopsy specimen (Case 1) shows new viable bone with large vascular spaces and osteoblast activity A few nests of unreplaced graft bone can also be seen The cartilage is degenerated, but new, viable mature hyaline cartilage can also be seen in the midst of fibrous cartilage The follow-up period was 7 years

In the biopsies, varying degrees of cartilage death and degeneration were observed but there were also changes indicative of regenerative activity in the grafted cartilage (Figure 4)

Functional results In ten cases a useful extremity was obtained and in six cases the patients returned fully to their pre-treatment activities One patient continued working for 4 years and then retired due to low back problems Another patient applied for re-education after a 2 year period in his previous occupation In three cases re-education was started immediately One patient is still in the process of mobilization and gradual weight-bearing

Histocompatibility No efforts were made to match the grafts Many patients had an unexplained fever shortly after the operation In some cases a transient eosinophilia was recorded A biopsy at 18 months in Case 6 revealed a slight lymphocyte infiltration in the subchondral bone This case also showed distinct radiological signs of cartilage degeneration 3 years after the transplantation No manifest rejection reactions were observed

Complications Two fatigue fractures of tibial grafts were experienced, one at 5 months and the other at 5 years One insufficient medial collateral ligament was reconstructed 3 years after the primary operation, the degenerated medial meniscus being removed In the first case a distinct femoral cartilage deterioration was observed However, 8 years after the grafting the knee was painless and had an extension flexion range of 10°–120°

No local recurrences or metastases occurred in the series. No infections were experienced.

One patient (Case 3) developed a parenchymatous type of icterus. He had negative blood cultures for bacteria and did not have hepatitis antigens In controlled studies no blood transfusion dyscrasias were found The

patient had in his history a period of hepatic insufficiency at the age of 14 He died from hepatic coma 5 weeks postoperatively and the necropsy revealed a polycystic cirrhotic liver

DISCUSSION

Bone tumours with a low grade of malignancy and signs of local aggressiveness can be treated by a radical *en bloc* resection with a safe margin of healthy bone An autogeneic grafting is possible in most cases, but in a large resection special reconstruction problems arise, especially in cases where the tumour is located close to a joint (Koskinen 1973) Reconstruction of the joint with artificial materials can seldom be recommended because most of these patients are relatively young Therefore, biological material appears to be preferable The knee region, which is a site of predilection for aggressive tumours, presents a most complicated replacement problem. Arthrodesis using split femoral and tibial grafts (Merle d'Aubigné & Dejouany 1958) is a major and not completely attractive operation Allogeneic hemi-joint transplantation has been reported from several centres as a solution to this difficult problem (Parrish 1966, Nilsonne 1969, Volkov 1970, Ottolenghi 72, Mankin 1976)

In the present study, a deep-freezing procedure recommended by Imamaliev (1969) was used for the preservation of the grafts. The experimental evidence of the need for deep-freezing to reduce the antigenicity of allogeneic bone is intriguing (Langer et al. 1975), while the clinical experience speaks for a minimum freezing time of 3 weeks (Parrish et al 1973) We experienced no distinct rejection reactions However, sporadic eosinophilia, subchondral lymphocyte infiltration and early cartilage degeneration may be signs of incompatibility

Apparently, the draw-back of deep-freezing is the death of cartilage cells. In three out of eight hemi-joint transplantations clear degenerative changes were seen on the X-ray films. In agreement with the report of Parrish et al (1973), this problem was not clear time-dependent No changes, or only slig changes, were seen in the other five cas during an observation time extending to ov 3 years However, in the earliest case th deterioration was marked Pain was not feature of this degenerative process, a dicating a denervated state in the joint. O the basis of experimental studies, Mankin al (1976) tried to improve the chondrocy survival by impregnating the graft cartila with glycerol prior to freezing

The fate of the cartilage need not be total predetermined by the death of the chondr cytes The matrix receives its nutrients fro the synovial fluid Contrary to some earl findings living chondrocytes could be fou in some biopsy specimens (Holmström et a 1978) The importance of this phenomenon conjunction with progressing degeneration the other parts of the cartilage is not clear the present time Thus, the preservation the cartilage, in particular, needs furth study

The union of the graft was enhanced by a autogeneic bone chip sleeve taken from th iliac crest (Figure 5) It seems evident th this procedure accelerates the incorporatio of the allogeneic graft itself Radiologicall solid union ensued in 8 to 12 months and fu weight-bearing could be allowed at that tim Using stable osteosynthesis, the necessa plaster immobilization period was gradual reduced as experience was gained During trial of partial weight-bearing, a fatig fracture occurred in the presumably dea graft Even total incorporation was no guarantee against this problem, as indicate by another case, where a viable gra fractured 5 years after transplantation.

At no time was any distinctly in creased ^{99m}technetium diphosphonate uptak observed, but patches of augmented activit deep in the graft were seen as early as at months and as late as at 2 5 years. *In* arthro scopic biopsies no living subchondral bone was seen before 2.5 years. This may there fore be the time required for total incorpora tion of the graft

Figure 5 Case 6 Early stage of incorporation 6 months postoperatively (a) Angiography shows small calibre vessels in the area of autologous chips and allografts (b).

The allotransplantation method of replacing large bone and joint defects seems to be the only choice in selected cases of aggressive, low-grade malignant bone tumours. The patient has to be prepared to face a considerable morbidity with a long non-weight bearing period the possibility of further operations and later cartilage degeneration However, the method appears to be justifiable, since the alternative is often an amputation No major risks are involved The death of one patient in the series was obviously a result of a pre-existing condition and not of the allografting itself So far, there

have been no subsequent amputations and no metastases have been experienced All patients have retained the limb with a good or satisfactory function In the cases with bone grafting alone the result was full restoration.

REFERENCES

Holmstrom, T, Koskinen, E V S, Salenius, P & Alho, A (1978) Histological changes in hemi-joint allograft. *Europ Soc Surg Res, Abstracts*, Ed Lempinen, M & Kalima, T p 83, Helsinki.

Imamaliev, A. S (1969) The preparation, preservation and transplantation of articular bone ends. *Recent advances in orthopaedics*, Ed Apley, A G, J & A. Churchill Ltd., London

Koskinen, E V S (1973) Local resection of bone tumours. *Orthopaedic surgery and traumatology*, Ed. Delchef, J, deMarneffe, R & Vander Elst, E., pp 381–383 Excerpta Medica, Amsterdam.

Koskinen, E V S (1978) Wide resection of primary tumours of bone and replacement with massive bone grafts. *Clin Orthop* 134, 302–319

Langer, F, Czitrom, A, Pritzker, K. P & Gross, A E. (1975) The immunogenicity of fresh and frozen allogeneic bone *J Bone Jt Surg* 57-A, 215–220

Lexer, E (1908) Die Verwendung der freien Knochenplastik nebst Versuchen über Gelenkversteifung und Gelenktransplantation. *Arch klin Chir* 86, 939–954

Mankin, H J, Fogelson, F S, Thrasher A Z & Jaffer, F (1976) Massive resection and allograft transplantation in the treatment of malignant bone tumours. *New Engl J Med* 294, 1247–1253

Merle d'Aubigne, R. & Dejouany J P (1[illegible]) Diaphysoepiphyseal resection for bone tumours at the knee *J Bone Jt Surg* 40-B 3[illegible]–7[illegible]

Muller, M E, Allgower M & Willenegger R (1970) *Manual of internal fixation Technique recommended by the AO group* Springer, Berlin Heidelberg New York.

Nilsonne U (1969) Homologous joint-transplantation in man. *Acta orthop scand* 4[illegible] 429–447

Ottolenghi, C E (1972) Massive osteo and osteoarticular bone grafts. Technic and results of [illegible] cases. *Clin Orthop* 87, 156–164

Parrish, F F (1966) Treatment of bone tumors by total excision and replacement with massive autologous and homologous grafts. *J Bone Jt Surg* 48 A, 968–990

Parrish F F (1973) Allograft replacement of all or part of the end of a long bone following excision of a tumor Report of twenty-one cases. *J Bone Jt Surg* 55 A 1–22.

Volkov, M (1970) Allotransplantation of joints. *Bone Jt Surg* 52 B 49–53

Correspondence to Prof E V S Koskinen, M D., Annas Lindgreninlie 15D, SF–00570 Helsinki 7 Finland.

acta orthop scand. 50 139–143 1979

NON-LINEAR PROPERTIES OF DIAPHYSEAL BONE

An Experimental Study on Dogs

J. NETZ, K. ERIKSSON & L. STRÖMBERG

Department of Orthopaedic Surgery, Karolinska Hospital, Department of Strength of Materials and Solid Mechanics, The Royal Institute of Technology, Department of Experimental Surgery, Karolinska Institute, and Department of Surgery, Karolinska Hospital, Stockholm, Sweden

The deformation of entire long bones from dogs has been studied in torsion. The load-deformation relationship is non-linear prior to ultimate failure and repeated successively increased loading and unloading in the non-linear range is found to reduce the stiffness of the bone. The non-linearity of the curve is assumed to be due to a change in the geometry of the bone originating from formation of small cracks in the cortex.

The bone material of entire long bones from dogs seems to be linearly elastic for all torques.

Key words: diaphyseal bone, elastic properties of bones, experimental surgery, stiffness of bone, torsional testing.

Accepted 3 x 78

If you twist a diaphyseal bone to fracture you will find, when examining the broken parts, that they fit together and that no residual deformation of the parts can be detected.

These observations are in accordance with the opinion of surgeons experienced in open reduction of spiral fractures, i.e., that exact reduction of fractured ends is possible clinically and that no adjustment of their shape is required to reproduce the original bone geometry after healing (Muller et al. 1970). Thus the deformation and fracture behaviour of diaphyseal bone is typical of an elastic-brittle material.

Diaphyseal bones tested in torsion show however a non-linear torque-twist relationship prior to fracture. Many investigators have assumed the non-linearity to correspond basically to plastic deformation of the bone (Burstein et al. 1972, Pierkarski 1970, Chamay 1970, Pope & Outwater 1972).

The discrepancy between the clinical observations and the experimental results encouraged us to study the deformation of diaphyseal bone especially in the non-linear range. To gain insight into the nature of the non-linearity, repeated loading and unloading torsional experiments have been performed on diaphyseal bones.

MATERIAL AND METHODS

The test material chosen was seven related pairs of fresh canine diaphyseal bones, with closed

Financial support was obtained from the Swedish Medical Research Council (project no. B 77-17X-04788-02) and from the Trygg-Hansa Research Fund for Bodily Injury in Personal Accident Insurance, Stockholm, Sweden.

0001-6470/79/020139-05$02.50/0

© 1979 Mun

epiphyseal lines, from long legged dogs of varying breeds and of both sexes One bone of each related pair was selected as a control bone and the other was used as a test bone

Preparation

The animals were sacrificed with lethal doses of mebumal sodium (Nembutal®, Abbott lab, USA) administered i v Immediately after sacrifice all soft tissues were removed, but the periosteum was kept intact, and the bones were immersed in a +37°C saline solution Both bones of a related pair were tested within 30 minutes after sacrifice of the corresponding animal At most, 10 minutes elapsed between the tests of the two bones of a related pair All related pairs of bones were treated in the same manner

Equipment

The test equipment and method has been described by Stromberg & Dalen (1976a) To permit reversal of the direction of twist at a predetermined torque, the equipment was provided with an additional device In short, across the display of the time base recorder, on which the torque-twist curve is plotted, a light beam runs parallel to the twist axis at the predetermined torque The light beam is connected to the twist machine over a switch When the recorder pen breaks the light beam, reversion of the rotation direction is triggered by the switch During a test the torque was determined as a function of the applied twist for the diaphyseal bone

It has been shown that the maximum torque capacity of diaphyseal bone is independent of the ngular velocity in the range 3–12 degrees per nd (Stromberg & Dalen 1976a). In view of this the angular velocity in the present work was chosen to be 6 degrees per second The angular velocity of the twist machine is constant and independent of torque within the test range

Test procedure

The recorded torque-twist curve of torsionally tested diaphyseal bones comprises two characteristic parts (Figure 1), one linear starting from zero load, which at a critical torque (here called M_c) changes to a non-linear part prior to the ultimate fracture of the bone (at the torque M_f).

To study the properties of the bone material and especially the nature of the non-linear behaviour the procedure was as follows The torque-twist master curve for a related pair was obtained by twisting one of the bones to ultimate

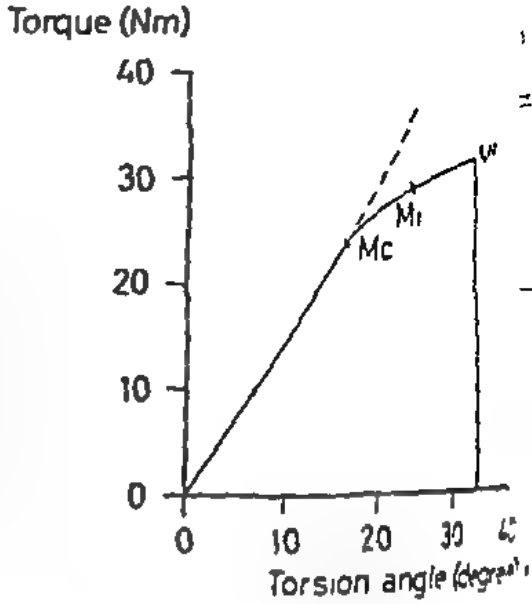

Figure 1 Example of a torque-twist curve for an entire long bone of a dog Load is expressed a randomly chosen point on the curve in the linear range M_f is the point on the curve when the ultimate failure occurs

fracture On this curve the points corresponding to M_c and M_f were marked The other bone, the test bone, was repeatedly loaded and unloaded in torsion In the first load cycle the bone was loaded to a torque M_1 slightly greater than M_c and subsequently unloaded Loading to a torque M_1 and unloading from M_1 to zero torque, where M_1 was increased slightly in every load cycle, was repeated until the bone finally fractured Loading and unloading torque twist curves were registered for all load cycles.

Calculation

The interesting feature of the load cycles is the slope of the linear part of the loading phases or the stiffness of the bone The stiffness is expressed as torque per unit twist (newtonmeters (Nm) per degree)

Conventional statistical methods were used to determine the significance of differences and correlations between the recorded parameters $P < 0.05$ was chosen to indicate significant correlation and difference

le 1 The stiffness of paired long bones from n dogs Stiffness is expressed in torque per unit twist (newtonmeters per degree)

Dog no	Stiffness of paired bones Nm/degree Left	Right	Percentage deviation
1	2 19	2 21	−0 9
2	1 00	1 01	−1 0
3	1 94	1 92	+1 0
4	1 20	1 18	+1 7
5	1 55	1 54	+0 6
6	2.01	2 06	−2 5
7	1 39	1 36	+2 2

* two bones of a pair were twisted in the same ection with respect to the geometry One of the ies was twisted to ultimate failure and the er of the pair to a point M_1 in the non-linear ge of the recorded curve (see Figure 1) The pe of the linear phases was calculated and the centage deviation from the mean value of the ated pair is given All tested bones had the me stiffness as their respective controls ean = +0 2 per cent, s d −1 7 per cent, >0 05)

Table 2 The stiffness after varying numbers of load cycles for one bone of a pair of long bones from seven dogs Stiffness is expressed in torque per unit twist (newtonmeters per degree)

Dog no	Stiffness (Nm/degree) Load cycle no I	II	III	IV	Percentage deviation
1	2 19	1 96	1 65		−24 7
2	1 00	0 92	0 83		−17 0
3	1 94	1 82			− 6 2
4	1 18	1 13	1 04		−11 9
5	1 54	1 40			− 9 1
6	2 06	1 86	1 71	1 67	−18 9
7	1 36	1 24	1 20		−11 8

The deviation of the stiffness from the first loading and the last (where the ultimate fracture occurs) is given in per cent of the value of the first loading In all cases the stiffness was smaller in the last loading compared with that of the first one (mean = −14 2 per cent, s d −6 3 per cent $P < 0\ 01$)

ESULTS

) The slope of the linear part of the first loading curve was equal to that of the master curve for any related pair of bones (Table 1) ($P > 0\ 05$)

) The slope of the linear part of the loading curves decreases as the load cycle number increases (Table 2) ($P < 0\ 01$)

ISCUSSION

It is known that drying or freezing affects the echanical properties of biological materials Smith & Walmsley 1957, Hirsch & Sedlin 966 Stromberg & Dalen 1976b) This fact mits the scope of the present study to fresh aterial only With the method used it is ossible to perform testing within a few inutes after detaching the material from the onor (Strömberg & Dalén 1976a)

A previous study has shown that the torque-twist curves for both bones of a related pair of diaphyseal bones are almost equal and independent of the combination of directions of twist for the two bones (Netz et al 1978) This means that for example, stiffness and maximum torque capacity of both bones are the same and this permits the use of one bone of a related pair as a control bone to determine the torque-twist curve for the pair

Stress-strain relationships for materials are in practice obtained by inference from a load-deformation relationship for a body of the material considered The two relationships are however identical (in normalized units) only if continuity of the body is preserved during the deformation cycle Cracking, cavity formation and other phenomena by which new surfaces are formed, affect the load-deformation relationship of a body but not the properties of the [illegible]

1974). The stress-strain relationship for a material susceptible to cracking can therefore not be uncritically inferred from a load-deformation relationship

Cracking, or localized fractures in combination with deformation implies a restriction upon the choice of specimen. Specimens containing only some part of the entire bone will suffer both from a different geometry and different test boundary conditions, quite apart from effects of specimen preparation upon mechanical properties (Hirsch & Sedlin 1966). As the load-deformation relationship is dependent upon the geometry of the body, in particular the non-linear part of the load-deformation curve is characteristic of the behaviour of the particular specimen only

As regards deformation in combination with localized fracture the effect of size and shape of the specimen upon its non-linear properties cannot be excluded. It is our opinion that the deformation and fracture process of diaphyseal bone can be adequately studied only by using entire bones as specimens.

Bone material is known to be viscoelastic, i.e its mechanical properties are time-dependent (Burstein & Frankel 1968, Currey 1970 McElhaney & Byars 1965) A preparatory test comprising loading and unloading of a test bone within the linear range of the corresponding master curve revealed however, that the width of the hysteresis loop along the twist axis is insignificant compared to the elastic twist range In fact, for the actual loading rate viscous effects can hardly be detected on a twist axis scale suitable for plotting the non-linear behaviour of the entire bone This means that viscous effects within the linear range are insignificant compared to the effects discussed in the following

The slope of the loading curves decreases as the load cycle numbers increase with a concomitant gradually increased load (Figure 2) The same result is also obtained if a complete loading and unloading cycle is considered a hysteresis loop the mean slope of the loop decreases as the load cycle number

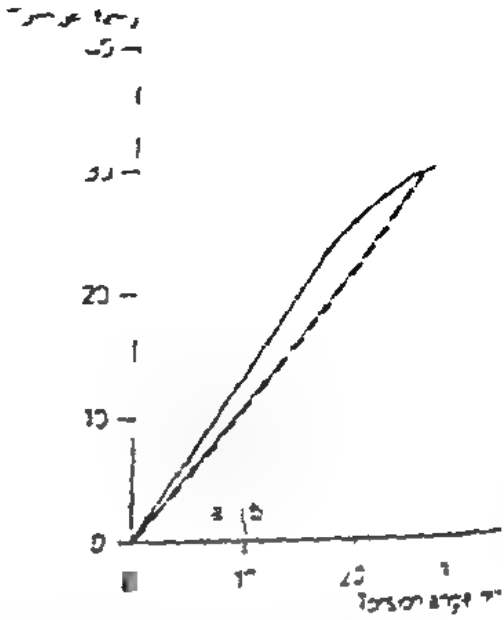

Figure 2 A schematic torque-twist curve repeated and successively increased load showing the decrease of the slope of the linear phase - stiffness Stiffness is expressed in torque unit twist (newtonmeters per degree).

The first loading is represented by the continuous black line The second loading which to ultimate failure is represented by the broken line and the linear phase of this loading forms angle b In the present experiments the angle was greater than the angle b

increases This means that the stiffness of bone must have been affected. The reduction of the stiffness is to such an extent that non-linear behaviour of the bone can explained essentially by this effect.

The change in the stiffness requires a corresponding change in the bone geometry change in the geometry of the bone can explained by assuming that small cracks have been formed in the bone material as a result of the deformation in the non-linear range.

Considering the structure of the bone material and the stress distribution in uncracked bone it is reasonable to assume that the crack plane is perpendicular to the bone surface and parallel to its longitudinal axis (similar to those described by Frost 196 From theoretical considerations it is easy concluded that cracks with the proper

nentation reduce the twist stiffness of the one A quantitative calculation is however a engthy task. In order to approximately lustrate the effect of axial cracks upon the wist stiffness of a cylinder qualitatively, thin-valled cylinders of an elastic material with axial lots through the wall were twisted in torsion ffectively the twist stiffness decreased as the umber and length of the slots increased We onsider this effect as an additional indication f the formation of microcracks in tested iaphyseal bones, during the non linear range torsion.

We are therefore tempted to suggest that one material is linearly elastic for all rques, that is, even in the non linear range nd that the non linearity of the torque-twist urve prior to fracture of the bone is due to e formation and growth of a number of mall cracks in the bone material licroscopic inelastic effects, e g as observed y Chamey (1970) in the immediate eighbourhood of a fracture surface, are not xcluded by this suggestion.

We assume that the torsional fracture rocess of diaphyseal bone is a two-stage rocess. In the first stage, occurring during the non linear phase an increasing number of mall cracks in the cortical layer are rmed The bone still bears the applied rque but its capacity to withstand an in reasing torque is reduced In the second tage, at the maximum torque ultimate ailure of the bone is brought about by udden propagation of small cracks forming he spiral type of fracture

REFERENCES

Burstein, A. H. & Frankel, V H (1968) The viscoelastic properties of some biological materials. *N Y Acad Sci (Wash)* 146, 158–165

Burstein A H Currey J D Frankel V H & Reilly D T (1972) The ultimate propert es of bone tissue the effect of yielding *J Biomech* 5, 35–44

Broek D (1974) *Elementary engineering fracture mechanics* Noordhoff Int Publ., Leyden Netherlands.

Chamey A (1970) Mechanical and morpholog cal aspects of experimental overload and fatigue in bone *J Biomech* 3, 263 270

Currey J D (1970) The mechanical properties of bone *Clin Orthop* 73, 210–231

Frost H M (1960) Presence of microscopic cracks in vivo in bone *Henry Ford Hosp Bull.* 8, 25–35

Frost H M Roth, H & Villanueva A R (1961) Physical characteristics of bone *Henry Ford Hosp Bull* 9 163–170

29 48

McElhaney J H. & Byars. F (1965) Dynamic response of biological materials. ASME paper 65 WA/HUF 9

Muller M E Allgover M & Willenegger H (1970) *Manual of internal fixation.* Springer Verlag Berlin Heidelberg New York

Netz P Eriksson K. & Stromberg L. (1978) Torsional strength and geometry of diaphyseal bone *Acta orthop scand* 49, 430–434

Pekarski K. (1970) Fracture of bone *J appl Physiol* 41, 215–223

Pope M H & Outwater J O (1972) The fracture characteristics of bone substance. *J Biomech* 5, 457–465

Sammarco J G Burstein A H Davies, W L & Frankel V H (1971) The biomechanics of torsional fractures. The effect of loading on ultimate properties. *J Biomech* 4, 113–117

Smith J W & Walmsley R. (1957) Factors affecting the elasticity of bones. *J Anat (Lond)* 93, 503 523

Stromberg L. & Dalen N (1976a) Experimental measurement of maximum torque capacity of long bones. *Acta orthop scand* 47, 257–263

Stromberg L. & Dalen N (1976b) The influence of freezing on the maximum torque capacity of long bones. An experimental study *Acta orthop scand* 47, 254–256

Correspondence to Pelle Netz Department of Orthopaedic Surgery Karolinska Institute, S-10401 Stockholm 60 Sweden.

TREATMENT OF CHRONIC OSTEOMYELITIS BY FREE GRAFTS OF CANCELLOUS AUTOLOGOUS BONE TISSUE

A Preliminary Report

EINAR SUDMANN

Department of Orthopaedic Surgery, University of Tromsø, Tromsø, Norway

Chronic osteomyelitis was treated by free grafts of autologous bone tissue in 13 consecutive patients aged 18 to 81 years. In all patients the osteomyelitis was located in the leg, and *Staphylococcus aureus* was the causative organism. Seven had an infected non-union. The duration of the osteomyelitis varied from less than 1 year to 75 years. Surgical debridement and grafting of cancellous and cortical cancellous bone were performed at the one operation. The osteomyelitis healed after a single operation in all patients but one, who needed three operations before the infection was [illegible] and b[illegible] grafting operation was necessary [illegible] nts is [illegible] afting of autologous bone tissue seems to be a very valuable method of treatment for chronic osteomyelitis.

Key words autologous transplantation, bone and bones, methods, osteomyelitis

Accepted 17 vii 78

Surgical debridement combined with long-term medication with antibiotics has changed the previously gloomy outlook of chronic osteomyelitis. Nevertheless in a recent Norwegian study of postoperative osteomyelitis an amputation rate of 14 per cent was reported (Hagen 1974).

Surgical debridement invariably entails bone loss and to avoid reinfection it seems to be essential to refill the defect (Burri 1975). Several methods have been used, from very crude ones such as refilling it with sand (Uebelhör 1971) to elaborate techniques such as free autografts of omentum secured with microvascular anastomoses (Azuma et al 1976).

Bone defects are best refilled with grafts of bone tissue, but free bone grafts in an infected environment may create new sequestra and so propagate the infection. However, favourable results using the apparently paradoxical technique of grafting free autologous grafts of cancellous bone have recently been reported (Papineau 1973, Burri 1975). The purpose of this study is to present the preliminary findings after using this method to treat 13 consecutive patients with chronic osteomyelitis.

PATIENTS AND METHODS

Patients The investigation comprised 13 patients admitted to the Orthopaedic Department in the period April 1975 to May 1977, 12 men and 1 woman, aged 18 to 81 years (median 52 years). Twelve had chronic post-traumatic osteomyelitis

0001-6470/79/020145-06$02.50/0

© 1979 Munksgaard, Copenhagen

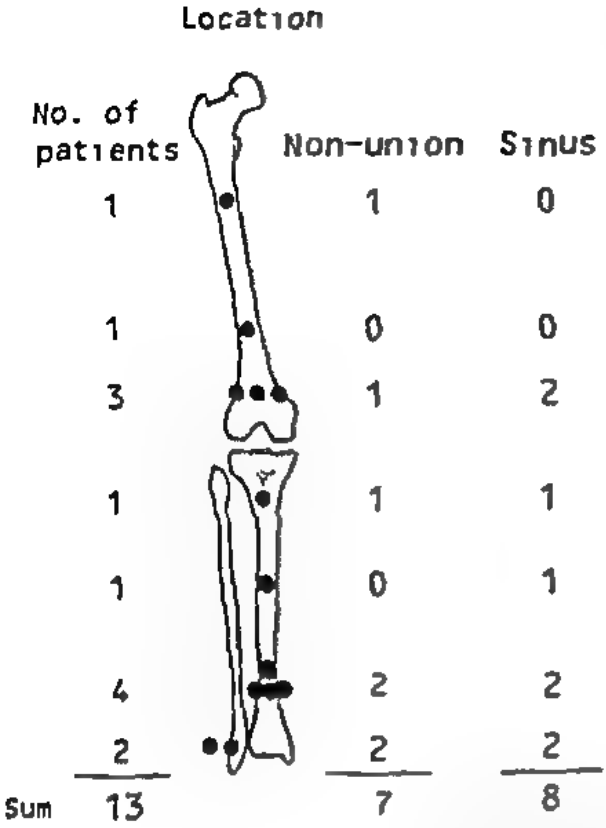

Figure 1 Scatter diagram Location of infection, non-union and sinuses on right and left legs in 13 consecutive patients

and one had osteomyelitis of haematogenous origin Each patient had only one diagnosed infected focus situated in one of the long bones of the leg (Figure 1)

Post traumatic osteomyelitis Five out of 12 fractures were open. One fracture had been treated conservatively by traction, the others by one or more other methods external skeletal fixation (2) cerclage (2) plate and screws (6) and pins (2) The subsequent infection had been treated by systemic antibiotics and various forms of surgery debridement including removal of sequestra and osteosynthesis material, local irrigation of the wound, skin grafting and plaster of Paris. Following this treatment 5 out of 12 fractures had healed despite persisting infection (Figure 1).

Nontraumatic osteomyelitis The oldest patient in this material (81 years) had contracted a haematogenous osteomyelitis as a child For 75 years he had suffered from a chronic exudative femoral osteomyelitis which had resisted repeated surgical interventions comb ed with systemic antibiotics.

The duration of the osteomyelitis prior to fi treatment with bone grafts varied from 1 mo to 75 years (median 1 year) The durat previous hospitalization varied from 1 month to years Nine patients had been treated at oth hospitals before being admitted here

Microorganism and sinus *Staphylococci* wer had been cultured from the infected area in patients The staphylococci were insensitive penicillin in 11 of the 13 patients, but sensitive to lincomycin in all of them. Eig patients had a sinus (Figure 1)

Methods Surgical debridement and bone graft were performed on all patients in a one-st operation by different surgeons.

Operative procedure Bone autografts were tak prior to surgery of the infected area and kept in bandage soaked in isotonic Ringer's solution Cancellous grafts were taken from the super posterior iliac spine (12 times) and cort cancelleous grafts from the anterior iliac crest times)

The infected bone focus was widely opened obviously diseased soft and hard tissue w removed before the bone defect was refilled w bone grafts The wound edges were then possible, loosely sutured in one layer with nylon stitches, otherwise the wound was left o and the bone grafts covered by a loose band soaked in isotonic Ringer's solution Non-un were immobilized either in plaster of Paris patients) or by external skeletal fixa (Hoffmann 1952, Adrey 1971) (5 patients).

Antibiotic treatment and follow-up All pa received systemic antibiotics postoperat usually lincomycin 0 5 g three to four times d until the clinical signs of the infection subsided (3–12 months) One patient recei sulphonamide in addition, another patient treated with cloxacillin alone for less than month The length of follow-up after osteomyelitis healed was from 9 months to 3 ye

RESULTS

All the patients tolerated the operations and we observed no complications from donor sites. The osteomyelitis healed in but one patient after a single operation. T particular patient needed three operations eradicate the infection. In one patient

second bone grafting operation was necessary before allowing weight-bearing (see case report)

In the patients with an open wound the visible uncovered bone chips were gradually covered by granulation tissue as described by Burri (1975) The wounds gradually closed and skin grafting was not necessary In the radiographs the bone grafts were seen to initiate new bone formation, which gradually refilled the defect

Hospital stay and duration of incapacity In 2 patients the hospital stay after the first bone grafting operation varied from 21 to 58 days (median 30 days) In all these patients the lesions were completely healed and they had resumed full activity 3–18 months after the operation (median 7 months) One patient stayed in hospital for 4 months after the first operation, which failed After two further operations the infected non-union of the leg healed, about 2 years after his first operation

CASE REPORT

Male aged 45 He sustained a closed femoral fracture in a traffic accident and was treated by plating (AO plate) Osteomyelitis caused by penicillin resistant staphylococci developed After 3 years radical surgical debridement was carried out including removal of plate and screws. The fracture healed, but a large lateral cortical defect did not refill with bone and the femur refractured When the patient was admitted to this hospital (Figure 2 a,b) the fracture was immobilized with a double frame external fixation device Radiographs showed no callus after 3 months there fore without further delay a bone graft was performed. First 40 ml of pus was removed this gave a pure culture of penicillin resistant staphylococci, and then the cancellous bone grafts were inserted Since the bone grafts only filled a small part of the large defect in the lateral cortex (both fragments) and of the small one in the medial cortex (proximal fragment only) a larger quantity of grafts would have been desirable In less than 6 months the fracture and the osteomyelitis had healed, but at this time the large bone defects – created by previous operations – had not refilled enough to withstand weight bearing (Figure 2 c,d) Regrafting was therefore performed At reoperation no infection was observed Uneventful postoperative healing followed rebuilding of the lateral cortex with cortical cancellous bone chips and the fixation device was removed [illegible] months later

DISCUSSION

Biological refilling of a bone defect, whether it is a fracture or a chronic osteomyelitic defect, depends on osteoclastic and above all on osteoblastic activity As outlined by Frost (1963) and Sudmann & Marton (1975), osteoblastic activity – and likewise bone formation – can be classified in terms of primitive, disordered or differentiated, ordered activity

Primitive, disordered osteoblasts form large amounts of new woven fibred bone, whereas differentiated, ordered osteoblasts form much smaller amounts of parallel-fibred bone during the same period (Frost 1963, Sudmann 1976) Accordingly, a bone defect is most readily refilled if primitive, disordered osteoblastic activity is initiated in it In a non-infected environment such activity is best initiated by refilling the defect with free cancellous and cortical cancellous autologous bone grafts Such grafts provide (1) a supply of living osteogenetic cells which may survive, differentiate and form (primary) primitive bone tissue, (2) a biological scaffold for the granulation tissue to grow on and (3) by means of bone induction this bony scaffold later causes osteogenetic cells within the granulation tissue to form (secondary) primitive bone tissue The question is whether the granulation tissue will revascularize the grafts in the presence of infection As indicated by the results of this study these grafts do not seem to form sequestra of any clinical significance

Infection is the main adverse biological factor to be eliminated In addition to surgical debridement and bone grafting of the osteomyelitic focus we treated most of the patients with lincomycin orally both pre- and postoperatively However, this study gives no definite answer as to whether or not anti-

a

Figure 2 (a d) Radiographs of left femur (case report) (a b) Refractured femur upon admission After the first bone grafting operation the fracture and the osteomyelitis healed in 3 months but defects in the medial and lateral cortex did not refill with bone White arrowheads indicate defects medial cortex black ones proximal part of defect in lateral cortex

c
d

biotics are absolutely necessary for optimum results. Since surgical debridement in combination with long-term antibiotic medication alone may fail (Hagen 1974), we consider bone grafting an essential addition.

Instability and diastasis are the main mechanical and physical adverse factors to be eliminated. Differentiated, ordered bone formation, i.e., longitudinal Haversian remodelling across the fracture line, is possible even in an infected environment provided the fracture is immobilized by rigid plate osteosynthesis (Rittmann & Perren 1974). However, a bone defect is most rapidly refilled by primitive, disordered bone formation. In contrast to differentiated bone formation, primitive bone formation does not require rigid fixation. Thus, the foreign body effect of a plate may outweigh the advantages of its stabilizing effect. Accordingly we avoid plate fixation whenever possible and find rigid double frame external fixation, as outlined by Adrey (1971), sufficient.

Although the number of patients with chronic osteomyelitis studied here is small, our short-term results agree well with larger series published recently (Papineau 1973, Burri 1975, Roy-Camille et al. 1976). We therefore consider autologous bone grafting a very useful method in the treatment of chronic osteomyelitis.

REFERENCES

Adrey, J. (1971) *Hoffmann's external osteosynthesis coupled in frame arrangement. Biomechanical survey of leg fractures.* 2nd ed., Gead, Paris.

Azuma, H., Kondo, T., Mikami, M. & Hara, K. (1976) Treatment of chronic osteomyelitis by transplantation of autogenous omentum with microvascular anastomosis. A preliminary report. *Acta orthop. scand.* 47, 271–275.

Burri, C. (1975) *Post traumatic osteomyelitis.* Huber, Bern.

Frost, H. M. (1963) *Bone remodelling dynamics.* Thomas, Springfield, Ill.

Hagen, R. (1974) Osteomyelitis after operative fracture treatment (Abstract). *Acta orthop. scand.* 45, 996.

Hoffmann, R. (1952) Osteotaxis, en form av perkutan frakturbehandling. *Nord. Med.* 48, 1640–1644.

Papineau, L.-J. (1973) L'excision-greffe avec fermeture retardée délibérée dans l'ostéomyélite chronique. *Nouv. Presse méd.* 2, 2753–2755.

Rittmann, W. W. & Perren, S. M. (1974) *Cortical bone healing after internal fixation and infection. Biomechanics and biology.* Springer, Berlin.

Roy-Camille, R., Reignier, B., Saillant, G. & Berteaux, D. (1976) Résultats de l'intervention de Papineau. A propos de 46 cas. *Rev. Chir. orthop.* 62, 347–362.

Sudmann, E. & Marton, P. F. (1975) Bone remodelling in rabbit ear chambers. A microscopical and histological study. *Acta orthop. scand.*, Suppl. 160, 65–90.

Sudmann, E. (1976) Frakturtilheling og frakturbehandling av diafysefrakturar. *Tidsskr. Lægeforen.* 96, 415–419.

Uebelhor, A. (1971) Hat die Behandlung infizierter Knochen mit Sand noch eine Berechtigung? *Med. Welt (Stuttg.)* 22, 457–459.

Correspondence to: Einar Sudmann, M.D., Department of Orthopaedic Surgery, University of Tromsø, Tromsø, Norway.

EFFECT OF CHLORPROMAZINE ON SKELETOGENESIS

The Result of Maternal Administration of the Drug in Experimental Rats

HAMER SINGH & R. PADMANABHAN

Department of Anatomy, Institute of Medical Sciences, Banaras Hindu University, Varanasi, India

Chlorpromazine hydrochloride (CPZ) is known to induce intrauterine and extrauterine growth retardation. A single dose of CPZ (100 mg/kg) was administered to pregnant CF rats on the 14th day of gestation (sperm positive—day 0) Fetuses were collected from the 16th to the 20th day of gestation and processed for alizarin red S stain. Ossification was delayed by 1 to 3 days in the long bones of the extremities, by 1 day in the scapulae and by 2 to 3 days in the ilium Ischium and pubis remained unossified until the 20th day of gestation Ossification of the skull bones was also delayed as manifested by the presence of wide sutures in the treated cases. The number and range of ossified vertebral bodies and arches in the treated group were always less than those in the control group The sternebrae were most affected The ribs also showed a significant delay in maturity

Key words chlorpromazine, pregnant rats, fetal skeleton, alizarin red-S skeletogenesis inhibition

Accepted 24 v 78

Phenothiazine derivatives are classified (Rumeau Rouquette et al 1977) into four groups depending on their chemical structure

1 3-carbon aliphatic side chain, e g, chlorpromazine,
2 2-carbon aliphatic side chain, e g, promethazine,
3 piperazine side chain, e g, fluphenazine, prochlorperazine,
4 piperidine side chain, e g, thioridazine

Rumeau Rouquette et al. (1977) found a significant increase in the malformation rate in the human with the intake of phenothiazines with a 3-carbon aliphatic side chain. Horvath et al (1976) found the teratogenicity to be increased in experimental animals with the length of the N-alkyl side chain especially with the substituted piperazine ring Previous reports of phenothiazine effects on embryonic development have often been contradictory (Chambon 1955, 1956, Courvoisier & Ducrot 1954, Eyal-Giladi et al 1962, 1963, 1964, Fratta et al 1964) It has been shown that chlorpromazine (CPZ) a phenothiazine derivative, prolongs gestation, reduces litter size and birth weight, increases postnatal mortality and causes intrauterine and extrauterine growth retardation (Ordy et al 1963, Horvath & Druga 1975, Horvath et al. 1976, Singh & Padmanabhan 1978a, 1978b)

In some studies it was also found to be teratogenic (Walker 1969, Horvath & Druga 1975, Horvath et al. 1976, Singh & Padmanabhan 1978c) However, fetal growth retardation was an observation common to most of these investigations. There seems to be no report of the effect of chlorpromazine

01 6470/79/020151-09$02.50/0

© 1979 Munksgaard, Copenhagen

on fetal skeletogenesis, the disturbance of which could be a major cause of such growth retardation The present investigation was therefore undertaken to study the prenatal development of the skeleton in rat fetuses after maternal administration of CPZ

MATERIALS AND METHODS

CF female rats of about 200 g body weight were mated with males of the same strain in the evening and pregnancy was confirmed by the presence of sperm in the vaginal smear examined on the following morning which was designated as day 0 of gestation A single dose (100 mg/kg body weight) of chlorpromazine (Largactil—May & Baker) was given to the pregnant rats intraperitoneally (i p) on the 14th day of gestation and they were caged separately The controls were injected with a corresponding volume of physiological saline Food (Hind Lever diet) and water were provided *ad libitum* 0 5 ml saline injection was given to the controls as well as the treated animals when dehydration was anticipated in the latter (Walker & Patterson 1974) The fetuses were collected from the 16th to the 20th day of gestation by uterotomy following ether anaesthesia They were blotted dry weighed individually and fixed in 95 per cent ethyl alcohol and subsequently processed for alizarin red S stain The younger fetuses were processed by the technique of Hurley (1965) and the older ones by that of Staples & Schnell (1964) and stored in 100 r cent glycerine The specimens were examined der a dissection microscope Five to eight mals (30–50 fetuses) made up both the control and treated groups on each collection day Only living fetuses and intact preparations were used for this study

Figures 1–5 show the effect of maternal ad- tion of CPZ (100 mg/kg) on the fetal sk (cleared in KOH and stained with alizarin C-control, T treated



Figure 1 Forelimb skeletons of 17 to 20-d rat fetuses Note the absence of the metac and the reduced size of other bones in 17 day-old treated fetuses The centres fo metacarpals have appeared in the 20-d treated fetuses but the ossification centres phalanges are absent (cf corresponding co

RESULTS

There were cases of scanty ossification ossification in the treated groups o various days of gestation The term in a treated specimen is used only wh degree of ossification in such a specime comparable to that of the correspo control

Table 1 Effect of maternal i p injection of CPZ (100 mg/kg on the 14th day of gestation) on t fetal skeleton—Bones of the upper limb

	Control—Percentage ossified					Treated—Percentage ossified				
Day	16	17	18	19	20	16	17	18	19	20
Clavicle	100 0	—	—	—	—	46 3	50 0	90 9	100.0	—
Scapula	35 7	100 0	—	—	—	—	6 3	100 0	—	—
Humerus	71 4	100 0	—	—	—	—	53 0	84 8	100 0	—
Radius	21 4	100 0	—	—	—	—	25 0	75 6	100.0	—
Ulna	21 4	100 0	—	—	—	—	21 8	78 8	100 0	—
Carpals	—	—	—	—	—	—	—	—	—	—
Metacarpals	—	—	16 3	100 0	—	—	—	—	70.6	94.5
Phalanges	—	—	—	—	60 0	—	—	—	—	—

Bones of the upper limb (Table 1, Figures 1, 3). Among the bones of the upper limb, the clavicle was the first to ossify in both the control and the treated groups. Ossification was seen in 100 per cent of the clavicles in the control group on the 16th day whereas in the treated groups not all of the clavicles were ossified until the 19th day In 93 7 per cent of the scapulae of the treated group, ossification was delayed by 1 day The humerus, radius and ulna of the control group showed ossification in 100 per cent of cases by the 17th day while in the drug treated group this could not be observed until the 19th day Metacarpals 2, 3 and 4 had appeared in all cases in the control group by the 19th day, and by the 20th day 32.5 per cent of the cases showed ossification centres for the 5th metacarpal also However, in the treated group even on the 19th day, only 70 6 per cent of the cases showed ossification of metacarpals 2, 3 and 4 The ossification centre for metacarpal 5 was not seen in any case The ossification centres for the phalanges were inconsistent in the controls and none could be observed in the treated group

Bones of the lower limb (Table 2, Figure 2) In the control group, the ilium, femur, tibia and fibula were ossified in 100 per cent of cases on the 17th day and the ischium and pubis on the 19th day The ossification was initially inhibited in the treated group and was complete in a comparable percentage of cases after a delay of 3 days in the case of the ilium and 2 days in the case of the other bones. The ischium and pubis in the treated group did not show ossification in all cases even on the 20th day In the drug treated group, the metatarsals were ossified in only 67 7 per cent of cases by the 20th day whereas in the controls all were ossified on the 19th day There were a greater number of metatarsals with retarded ossification in the treated group Ossification centres for the phalanges were not seen in any of the controls or in the treated group



Figure 2 Hindlimb skeletons of 17 to 20-day-old rat fetuses Note the marked reduction in the length of the long bones and the delayed appearance of the ossification centres for the metatarsals in the treated groups

Table 2 Effect of maternal i p injection of CPZ (100 mg/kg on the 14th day of gestation) on the fetal skeleton—Bones of the lower limb

	Control—Percentage ossified					Treated—Percentage ossified				
Day	16	17	18	19	20	16	17	18	19	20
Ilium	—	100.0	—	—	—	—	9 4	78 8	91 2	100 0
Ischium	—	—	—	100 0	—	—	—	—	67 6	96.8
Pubis	—	—	—	100 0	—	—	—	—	35 3	96 8
Femur	—	100 0	—	—	—	—	15 6	57 6	100 0	—
Tibia	—	100 0	—	—	—	—	15 6	54 4	100 0	—
Fibula	—	100 0	—	—	—	—	15 6	54 4	100 0	—
Tarsals	—	—	—	—	—	—	—	—	—	—
Metatarsals	—	—	2.3	100 0	—	—	—	—	35 3	67 7
Phalanges	—	—	—	—	—	—	—	—	—	—

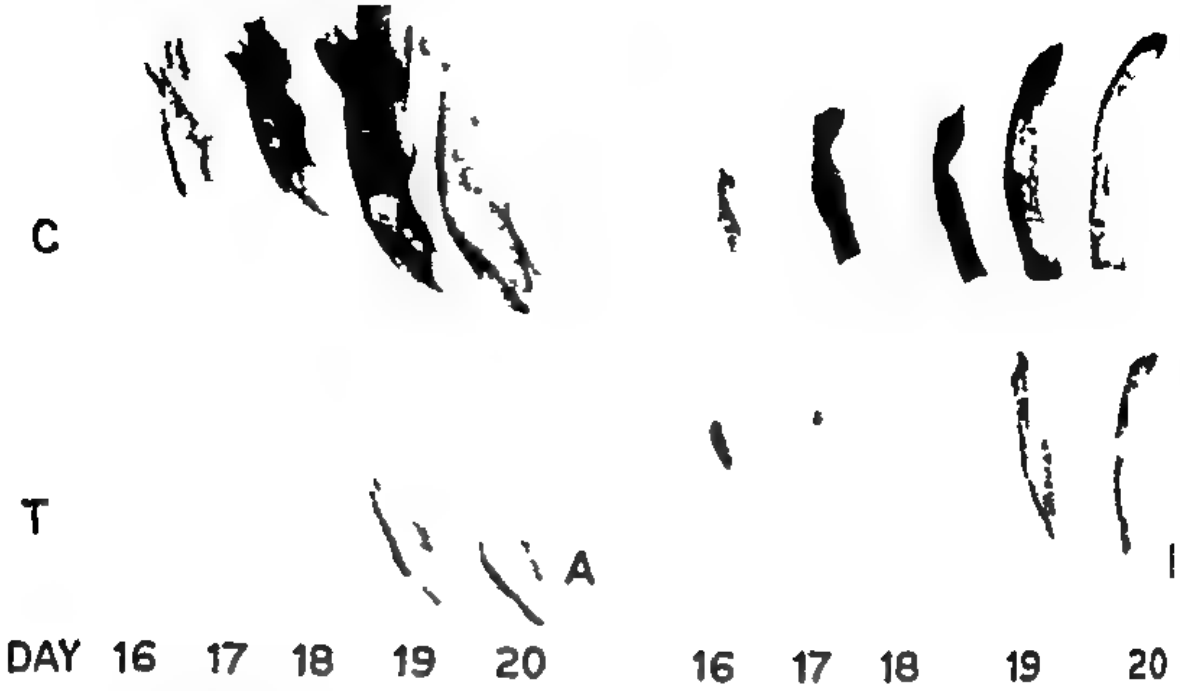

Figure 3 Mandibles (A) and clavicles (B) of 16 to 20 day old rat fetuses Note the scanty and del ossification in the treated group in contrast to the control group

Axial skeleton (Tables 3 and 4, Figure 3) Of the skull bones, the mandible was the first to ossify both in the control and the treated groups and on the 16th day ossification was seen in 100 per cent and 63 per cent of cases, respectively In the treated group, 100 per cent of the mandibles were not ossified until the 18th day The premaxilla maxilla, fro squamosal palatine, basioccipital and occipital bones were ossified in 100 per of cases in the control group on the 17th whereas in the treated group a compar percentage of bones was not ossified untI 19th day, i e, there was a delay of 2 d

le 3 Effect of maternal i p injection of CPZ (100 mg/kg on the 14th day of gestation) on the skeleton—Skull bones

Day	Controls—Percentage ossified					Treated—Percentage ossified				
	16	17	18	19	20	16	17	18	19	20
Mandible	100 0	—	—	—	—	63 0	64 5	100 0	—	—
Maxilla	42.9	100 0	—	—	—	—	9 4	90 9	100 0	—
Premaxilla	—	100 0	—	—	—	—	—	75 6	100 0	—
Nasal	—	85 3	100 0	—	—	—	15 6	57 6	100 0	—
Frontal	21 4	100 0	—	—	—	—	13 5	78 8	100 0	—
Parietal	—	91 2	100 0	—	—	—	—	21 2	94 0	10[illegible]
Squamosal	—	100 0	—	—	—	—	—	15 2	100 0	—
Palatine	—	100 0	—	—	—	—	—	78 2	100 0	—
Basioccipital	—	100 0	—	—	—	—	6 3	75 6	100 0	—
Exoccipital	—	100 0	—	—	—	—	9 4	87 9	100 0	—
Supraoccipital	—	—	—	100 0	—	—	—	—	59 2	74 2
Basisphenoid	—	91 2	100 0	—	—	—	—	75 6	100 0	—
Hyoid	—	—	—	96 8	100 0	—	—	—	56 0 (Rudi.)	[illegible] (Rudi.)

Table 4 Effect of maternal i.p. injection of CPZ (100 mg/kg on the 14th day of gestation) on the fetal skeleton—Vertebrae, ribs and sternebrae

	Controls—Percentage ossified					Treated—Percentage ossified				
Day	16	17	18	19	[illegible]	16	17	18	19	20
1 Vertebrae										
Arches[a]	21.4	100.0	—	—	—	—	78.1	100.0	—	—
	(C_1–C_3)	52.9	39.5	41.9	45.0	—	50.0	21.2	29.4	38.7
		(C_1–L_3)	(C_1–L_4)	(C_1–S_3)	(C_1–CO_1)		(C_1)	(C_1–C_3)	(C_1–S_3)	(C_1–S_3)
Bodies[b]	—	—	—	100.0	—	—	—	—	100.0	—
				41.9	72.5				11.8	22.3
				(T_1–S_3)	(T_1–CO_3)				(T_1–S_3)	(T_1–CO_3)
									(T_3–S_2)	
2 Ribs[c]	92.9	100.0	—	—	—	17.1	100.0	—	—	—
	21.4	55.9	100.0	—	—	17.1	18.8	57.6	100.0	—
	(10)	(13)	(13)			(3–6)	(9)	(12)	(13)	
3 Sternum[d]	—	—	—	96.8	100.0	—	—	—	29.4	100.0
				38.7	97.5	—	—	—	17.6	6.3
				(5)	(6)				(2)	(6)

a & b—parenthesis indicates the ranges of ossified vertebral arches and bodies respectively
c—parenthesis indicates the number of ossified ribs
d—parenthesis indicates the maximum number of ossified sternebrae

In the nasal and basisphenoid bones the ossification was delayed by 1 day in the treated group while in the parietal bones it was delayed by 2 days The hyoid bone in the treated group showed ossification in 87 1 per cent of cases of which 54 8 per cent were rudimentary as compared with 100 per cent with prominent ossification in the controls, when examined on the 20th day Ribs were ossified in 92 9 per cent of the control cases on the 16th day as compared with 17 1 per cent in treated rats while on the 17th day ossification of the ribs was seen in 100 per cent in both groups However, by then 13 ribs could be observed in 55 9 per cent of the controls as compared with only 9 ribs in 18 8 per cent of the treated cases. By the 19th day the ossification of the ribs was comparable in the treated group, i e, 1 day later than the control group The sternebrae were the worst affected On the 20th day only 6 5 per cent of cases in the drug group had six sternebrae as against 97 5 per cent in the control group

All fetuses showed ossification centres for some vertebral arches on the 17th day in the control and on the 18th day in the treated groups, the ossification proceeding in a cephalocaudal direction However, the number of vertebrae with ossification centres the arches was always less in the drug-treated group when compared with the corresponding controls Though 100 per cent of cases in both the control and treated groups showed ossification centres for the vertebral bodies on the 19th day, the number of bodies ossified was never comparable

DISCUSSION

Skeletal ossification in the rat begins with the mandible on the 16th to 17th day of gestation (sperm positive=day 0) (Strong 1926, Walker & Wirtschafter 1957, Wright et al 1958, Witschi 1962, Brock & Kreybig 1964) Fritz & Hess (1970) suggested that in teratological studies ossification of the al skeleton could be considered as an indi on of maturity which could be studied by designing chronological investigation and recording ossified and nonossified parts of the skele and distinguishing the incomplete ossifica from the pathological or the abnormal

The present chronological study of effect of a single dose (100 mg kg) chlorpromazine administered on the 14th of gestation has demonstrated that rat f skeletogenesis can be remarkably retarded this drug (Figures 4 and 5) The appeara of ossification centres for the long bones the upper limb was delayed by 1 to 3 day most of the cases Even in the few cases which the centres appeared a bit earlier degree of ossification was inhibited By 20th day of gestation, the 5th metacarpal not appeared in the drug-treated group an only 70 6 per cent of cases were metacarpals 2, 3, 4 ossified as against per cent in the control group The phalan ossification was totally inhibited in treated group Femur, tibia and fibula w ossified in 100 per cent of control fetuses the 17th day as compared with the 19th in the drug treated group, i e, a delay o days In the case of the ilium the delay even greater The metatarsals 2, 3, 4, 5 w ossified by the 20th day in 98 per cent of control fetuses as compared with only 31 cent of the treated fetuses, the suppres of ossification being highly signifi ($P<0.001$) In the skulls of the drug-tre fetuses, besides there being a significant de in the appearance of the ossification cen for the various bones, the rate of ossifica was also found to be slower as evide from the wide sutures persisting until late the period of gestation, a sign of incomp ossification (Murphy 1962, McColl et 1963, 1965) In most of the treated ra (54 8 per cent) the hyoid bone w represented only by a rudimentary cen ossification Both in the control and tre groups, the ossification of vertebral arc progressed cephalocaudally, but in the d group, the ossification was always restric to a lesser number of vertebrae Little

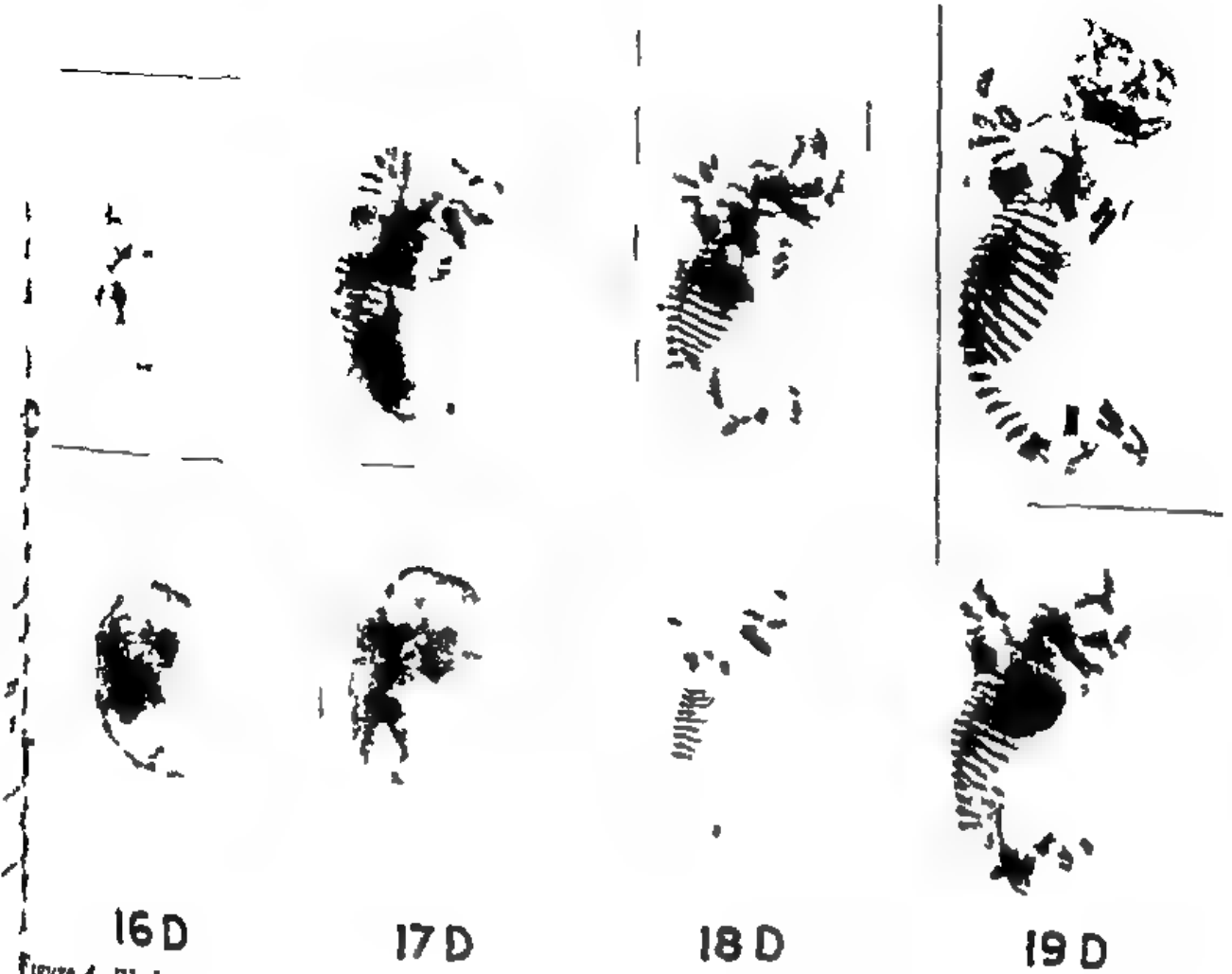

Figure 4 Skeletons of 16 to 19 day old rat fetuses showing a general inhibition of skeletogenesis i e late appearance of the various ossification centres and reduced size of the bones in the treated cases

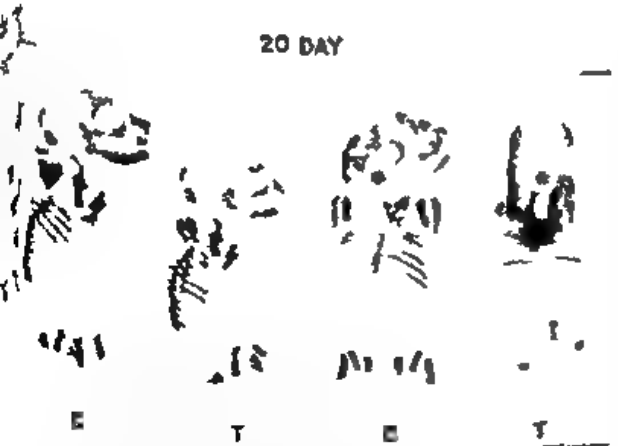

Figure 5 Skeletons of 20-day-old rat fetuses showing markedly stunted size and delayed ossification in the treated cases especially in the skull vertebrae and d gital bones

earlier reports (Horvath & Druga 1975 Horvath et al 1976) the full term fetuses of the drug treated group showed no defects but only a very low percentage (22 per cent) showed the first thoracic to the third coccygeal vertebral bodies as against 72.5 per cent in the control group There were no supernumerary ribs either in the control or in the treated fetuses though a significantly large number of ribs were rudimentary in the latter group In only 6 5 per cent of the drug treated fetuses could all six sternebrae be observed as compared with 98 per cent in the controls, though there was no abnormal ossification in any group. If missing vertebral

bodies and sternebrae are considered malformations (Kimmel & Wilson 1973, Raju et al 1976), the rudimentary ribs and smaller long bones must be considered a retardation of growth (Kimmel & Wilson 1973) Though not well established to be teratogenic, tranquilizers are suspect because of their categorical association with thalidomide—a known teratogen (Wilson 1973) Recent experimental works (Horvath & Druga 1975, Horvath et al 1976, Singh & Padmanabhan 1978c) and prospective studies in humans (Rumeau-Rouquette et al 1977) support the fact that chlorpromazine is teratogenic Its marked growth retarding effect is one common observation in all experimental studies (Ordy et al 1963, Walker & Patterson 1973, Horvath & Druga 1975, Horvath et al 1975, 1976, Singh & Padmanabhan 1978b, 1978c) The present chronological observation of rat fetal skeletogenesis adds further evidence and provides an explanation for this effect In a species (rats) with 21 days of gestation, a delay of 1–3 days, caused by CPZ, in the appearance of the ossification centres and the slow progress of ossification also explains the reduced birth weight and retarded postnatal growth in rats reported by Singh & Padmanabhan (1978b, 1978c)

REFERENCES

Brock, N & Krebig, T von (1964) Teratogenese als pharmakologisch—toxikologisches problem I Allgemeine Grundlagen Normale Embryonalentwicklung von Ratte und Meerschweinchen *Arzneimittel-Forsch* 14, 655–664

Chambon, Y (1955) Action de la chlorpromazine [illegible]

Ch [illegible] chlorpromazine chez l animal *Bull Fed Soc Gynéc Obstét franç* 8, 447

Courvoisier, S & Ducrot, R (1954) Recherche des effets de la chlorpromazine (4560) sur la sphère génitale et la croissance *C R Soc Biol. (Paris)* 148, 462–466.

Eyal, [illegible] & Eyal-Giladi, H (1963) Growth retarding and growth pro[illegible]ting effect of chlorpromazine on developing Ambystoma mexicanum (axolotl) embryos. *Exp Cell Res* 29, 394–399

Eyal-Giladi, H & Eyal, Z (1962) The effect of chlorpromazine on the embryonic development of the axolotl (Ambystoma mexicanum) *J Embryol exp Morph* 10, 357–372

Eyal-Giladi, H, Eyal, Z & Eshel, S (1964) A microscopic study of chlorpromazine (Largactil) treated axolotl larvae *J Embryol exp Morph* 12, 447–456

Fratta, I, Zak, S B, Greengard P. & Sig E B (1964) Fetal death from nicotinamide-deficient diet and its prevention by chlorpromazine and imipramine *Science* 145, 1429–1430

Fritz, H I & Hess, R (1970) Ossification of the rat and mouse skeleton in the perinatal period *Teratology* 3, 331–338

Horvath, C. & Druga, A (1975) Action of the phenothiazine derivative methophenazine on prenatal development in rats. *Teratology* 11 325–330

Horvath, C, Szonyi, L. & Mold, K (1975) Preventive effect of riboflavin and ATP on the teratogenic effects of the phenothiazine derivative T-82 *Teratology* 14, 167–170.

Hurley, L S (1965) Demonstration "A"-Alizarin staining of bone *Supplement to Teratology Workshop Manual Series Workshop in Teratology* pp 121–122, Berkeley California

Kimmel, A C & Wilson, J G (1973) Skeletal deviations in rats Malformations or variations? *Teratology* 8, 309–316.

McColl, J D, Globus, M & Robinson, S (1967) Drug induced skeletal malformations in the rat *Experientia (Basel)* 19, 183–184

McColl, J D, Globus, M & Robinson, S (1967) Effect of some therapeutic agents on the developing rat fetus. *Toxicol. appl. Pharmacol* 7, 409–417

Murphy, M L (1962) Teratogenic effects and of growth inhibiting chemicals, including studies on thalidomide *Clin Proc Children's Hosp (Wash)* 18, 307–322.

Ordy, J M, Latanick, A., Johnson, R J Massopust, L C. (1963) Chlorpromazine effects on pregnancy and offspring in rats *Proc Soc exp Biol Med* 113, 831–836.

Raju, P B, Singh, S & Sanyal, A. K. (1976) Ossification patterns of sternum in rat fetuses after maternal administration of cyclophosphamide *Cong Anom.* 15, 99–106.

Rumeau-Rouquette, C., Goujard, J & Huel, G (1977) Possible teratogenic effect of phenothiazines in human beings. *Teratology* 15, 57–64

Singh, S & Padmanabhan, R. (1975a) Growth

- retardation in rat fetuses induced by chlorpromazine hydrochloride (CPZ) *Anat Anz* (In press)

ngh, [illegible] Padmanabhan, R (1978b) Prolongation of gestation and retarded postnatal growth and mortality induced by chlorpromazine in rats. *Indian J Exp Biol* **16**, 542–545

ngh S & [illegible] enic rat

tapes, R E & Schnell V L (1964) Refinements in rapid clearing technic in the KOH Alizarin red S method for fetal bone *Stain Technol* **39**, 61 63

trong R M (1926) The order, time and rate of ossification of the albino rat *(Mus norvegicus albinus)* skeleton *Amer J Anat* **36**, 313–355

alker D G & Wirtschafter, Z T (1957) *The genesis of the rat skeleton A laboratory atlas*, Charles C Thomas, Springfield Ill

Walker, B E (1969) Relation of embryonic movements to formation of cleft palate *Teratology* **2**, 272 (abstract)

Walker, B [illegible] & Patterson A (1974) Induction of cleft palate in mice by tranquilizers and barbiturates *Teratology* **10**, 159–164

Wilson, J G (1973) *Environment and birth defects* Academic Press, New York

Witschi, E (1962) *Growth, including reproduction and morphological development* Ed Altman, P L & Dittmer, D S, Federation of American Societies for Experimental Biology, pp 304–314, Washington, D C

Wright, H V, Asling, C W, Dougherty, H L, Nelson, M M [illegible] Evans, H M (1958) Prenatal development of the skeleton in Long-Evans rat *Anat Rec.* **130**, 659–672

orrespondence to Dr Shamer Singh, B Sc, M B B S, M S, F A M S, Professor & Head of the Department of Anatomy, Institute of Medical Sciences Banaras Hindu University, Varanasi 221005, India

MORTALITY AFTER HIP FRACTURES

STEEN JENSEN & E TØNDEVOLD

Departments of Orthopaedic Surgery, T-2 & T-3,
Gentofte Hospital Hellerup, Denmark

A survey was made of 1592 patients, over the age of 50 years, who had sustained a fracture of the hip

The mean age was found to be 77 years, and 76 9 per cent (1224/1592) of the patients were women Trochanteric fractures accounted for 52.5 per cent (836/1592) of the cases and these patients had a higher mean age than those with femoral neck fractures.

The average hospitalization time was 24 days and the mortality during the hospital stay was 8 6 per cent (137/1592) Statistical analysis revealed that the hospital mortality rate was related exclusively to the age and the sex

The mortality after 3 months was 17 per cent and that after 6 months 21 5 per cent The survival rates paralleled the expected rate after 1 6 years but were found to be higher than expected after 2 8 years. The mortality after 1 year was 27 per cent, after 3 years 43 per cent and after 5 years 56 per cent.

Key words fractures, mortality, femoral neck fractures mortality

Accepted 5.x 78

A considerable number of studies on the mortality after hip fracture were published in the middle of the 1960's (Alffram 1964, Clark & Wainwright 1966, Cleveland et al 1951, Fitts et al 1959, Manpel et al 1961, McGoey & Evans 1960, Mikkelsen & Langholm 1964, Reno & Burlington 1958, Schenk et al 1956, Sweet et al 1967, Weeden et al 1957). These studies however were based on case materials including a large number of patients treated non-operatively Furthermore, operative fracture fixation was generally followed by late mobilization of the patients.

During the past 15 years the incidence of hip fractures has increased mainly due to an increase in the number of persons in the older age groups. Today most orthopaedic surgeons consider operation with early weight-bearing mobilization to be the treatment of choice (Abrami & Stevens 1964, Ainsworth 1971, Graham 1968, Haggquist 1969, Lindholm et al 1971, Parker & Reitman 1976) We have examined whether this change in treatment has affected the mortality after hip fracture

PATIENTS AND METHODS

The present series consists of 1592 patients, over 50 years of age, with hip fractures. The patients were admitted during the period April 1st 1971 to March 31st 1977

The age distribution and the type of fracture are shown in Figure 1 76 9 per cent were females (1224/1592) with a mean age of 78 years (range 51–99) whereas the mean age for males was 74

0001-6470/79/020161-07$02.50/0

© 1979 Munksgaard, Copenhagen

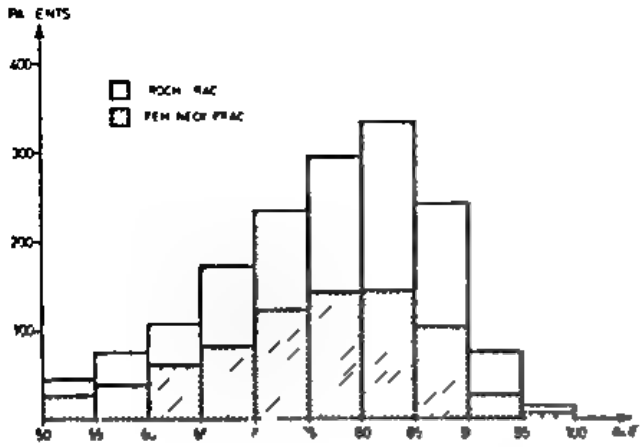

Figure 1 Age distribution of 1592 patients with hip fractures

years (range 51–98) The age and sex distribution related to fracture type are shown in Table 1

Trochanteric fractures were internally fixed using the Jewett, McLaughlin or sliding screw-

(333/756) of the cases were treated by primary hemiarthroplasty and 29 2 per cent (221/756) by internal fixation with a sliding nail The remaining 26 7 per cent (202/756) were treated non-operatively with early weight-bearing mobilization because these fractures were considered to be impacted

The records of the patients were examined trospectively considering the following in- ation the date of admission, the duration of italization, the occurrence of severe somatic complications (i e mainly cardiopulmonary and cerebrovascular diseases or deep infections) and whether the patient died during hospitalization.

All Danish citizens are registered at the Central Bureau of Personal Registration and have an identification number By means of this central computing system the patients who had died before February 1st 1978 were identified and the survival time calculated From these data, life tables were calculated by decrement analysis and compared using Gehan's modified Wilcoxon test.

Survival rates for a comparable number of patients with a similar age and sex distribution were calculated from data obtained from the Danish Central Bureau of Statistics.

RESULTS

The average hospitalization time for the present series was 24 days, ranging from 20 to 28 days for each year of the entire period. There was no significant difference in hospitalization time for trochanteric and femoral neck fractures

The overall *mortality during hospitalization* was found to be 8 6 per cent (137/1592). The hospital mortality after trochanteric fracture was 9 8 per cent (82/836) whereas it was 7.3 per cent (55/756) following femoral neck fracture This difference is significant ($P < 0.05$) applying the χ^2-test These mortality rates were however related to the

Table 1 Age and sex distribution related to fracture type in 1592 patients with hip fractures

		Trochanteric fractures	Femoral neck fractures
Total series			
Number		836/1592 (52.3 %)	756/1592 (47.5 %)
Age	mean	78 years	76 years
	range	51–98	51–99
Females			
Number		631/836 (75 5 %)	593/756 (78 4 %)
Age	mean	79 years	76 years
	Range	52–98	51–97
Males			
Number		205/836 (24 5 %)	163/756 (21 6 %)
Age	mean	73 years	75 years
	range	51–95	51–99

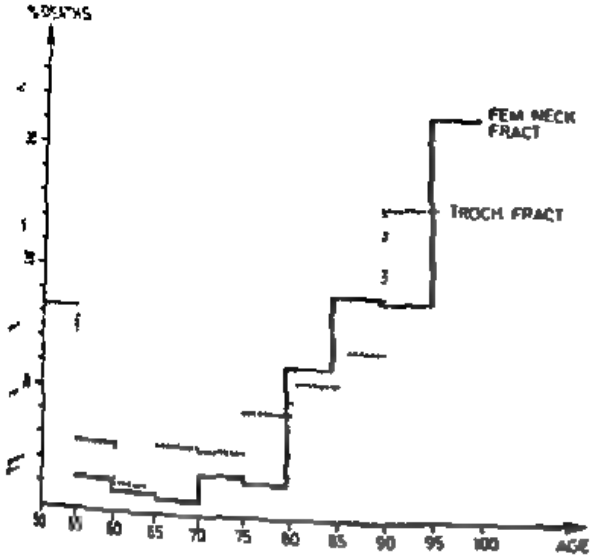

Figure 2 Hospital mortality after hip fracture in 592 patients related to fracture type and age of the patients

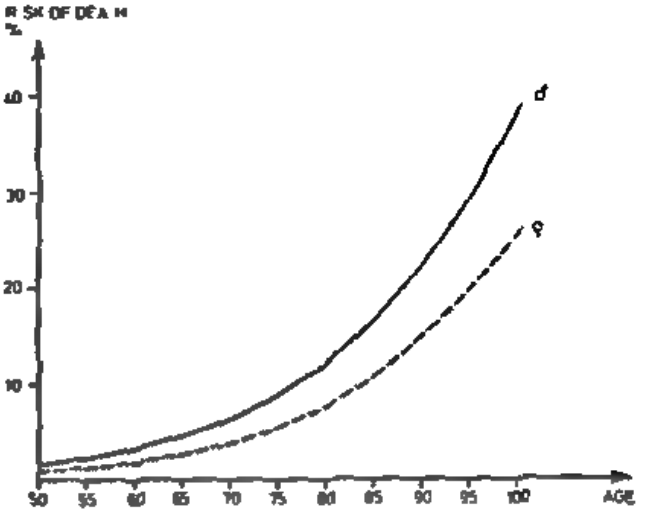

Figure 4 The estimated probability of death, during hospitalization after hip fracture, related to age

age and the fracture type as shown in Figure 2. A multivariate logistic analysis was applied, revealing that age alone was responsible for the difference ($P < 0.02$), the fracture type being of minor importance. In relation to age and sex (Figure 3) the mortality was demonstrated to be higher for

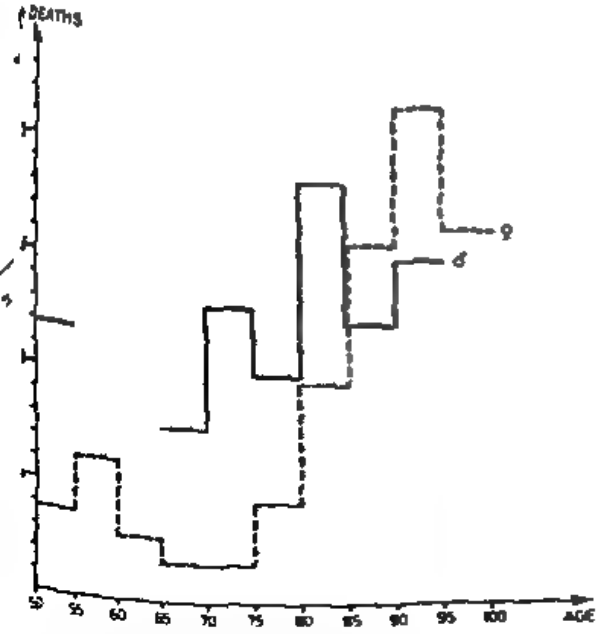

Figure 3 Hospital mortality after hip fracture in 592 patients related to age and sex. The hospital mortality was 8.6 per cent (137/1592)

males in the younger age groups, comparable figures for females were encountered beyond the age of 85 years. The probability of death after hip fracture could be estimated according to age and sex by means of a multivariate logistic analysis. Figure 4 shows that the probability of death increaes exponentially with increasing age. In any age group the risk is higher for males. A male at the age of 88 years is thus running a risk of death during hospitalization of 20 per cent, while a female with an equivalent risk is 94 years of age.

It was also investigated to what extent severe *somatic complications* affected the mortality rates in the various age groups. Figure 5 demonstrates that the oldest age groups are particularly vulnerable to somatic complications such as cardiopulmonary or cerebrovascular diseases. The overall hospital mortality in patients with severe somatic complications was 62.9 per cent (122/194).

The short term survival curves in Figure [illegible] illustrate that there is an initial high mortality rate within the first 3–4 weeks after the fracture. After this the mortality rate decreases slowly with a small temporary increase however between the fourth and the fifth month following the fracture.

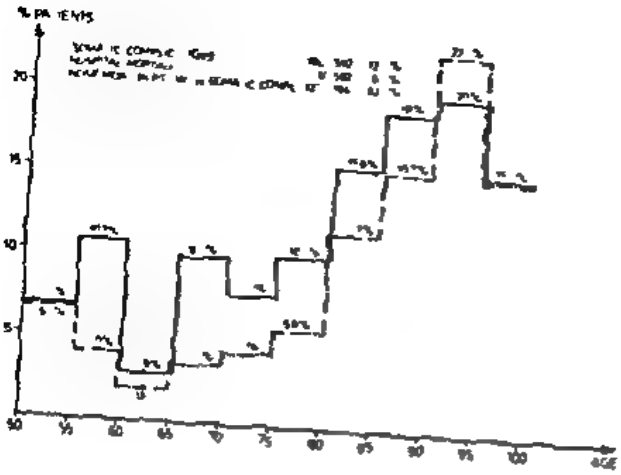

Figure 5 Somatic complications in patients with hip fracture related to age The continuous line illustrates the percentage of patients suffering from somatic complications, 12 2 per cent (194/1592) The dotted line illustrates the percentage of patients dying, 8 6 per cent (137/1592) The hospital mortality in patients with somatic complications was 62 9 per cent (122/194)

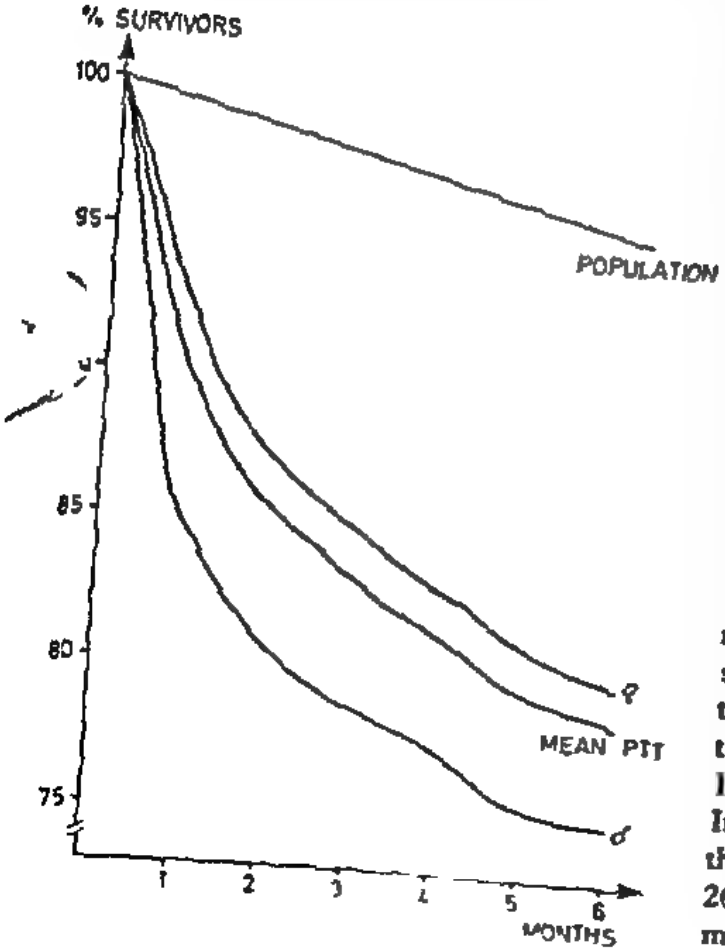

Figure 6 Short term life tables for 1592 patients with hip fractures

During the whole period the morta is considerably higher for males females. At 3 months after the hip f the mortality rate is 21 5 per cent for and 15 2 per cent for females with a mortality rate of 17 0 per cent At 6 m after the fracture 25 0 per cent of the have died, compared with 20 0 per cent females The mean mortality rate months was 21 5 per cent

The long term survival after hip frac shown in the life tables in Figure 7 uppermost three curves demonstrate expected survival rates for populations of same age as the present series de from data obtained from the Danish Ce Bureau of Statistics. As the male patients the present series were younger than females their survival rate was slightly h The lowermost three curves were calcul from the data from the present series.

It was thus found that there was a higher mortality among male patients with hip fractures than for females during the whole period The survival rate for males was considerably lower than expected for men of the same age group The curves for males become parallel 1 8 years after the fracture with an increment of 23 2 per cent, and 3 6 years after the fracture male patients have a slightly higher survival rate than expected. In comparison, female patients obtain the expected survival rate 1 6 years after the fracture with an increment between the curves of 15.3 per cent After 2 6 years the survival rate after hip fracture in females becomes higher than expected and is considerably higher for the rest of the observation period. The survival curve for this series parallels that of the population with the same age and sex distribution after 1 6 years with an increment of 18 0 per cent and converges after 2.5 years In this series the mortality rate 1 year after the hip fracture can thus be calculated to be 26 8 per cent compared with an expected mortality rate of 9 0 per cent, while the mortality rate after 3 years is 43 0 per cent (expected 26 5 per cent) and 56 0 per cent after 5 years (expected 43 0 per cent)

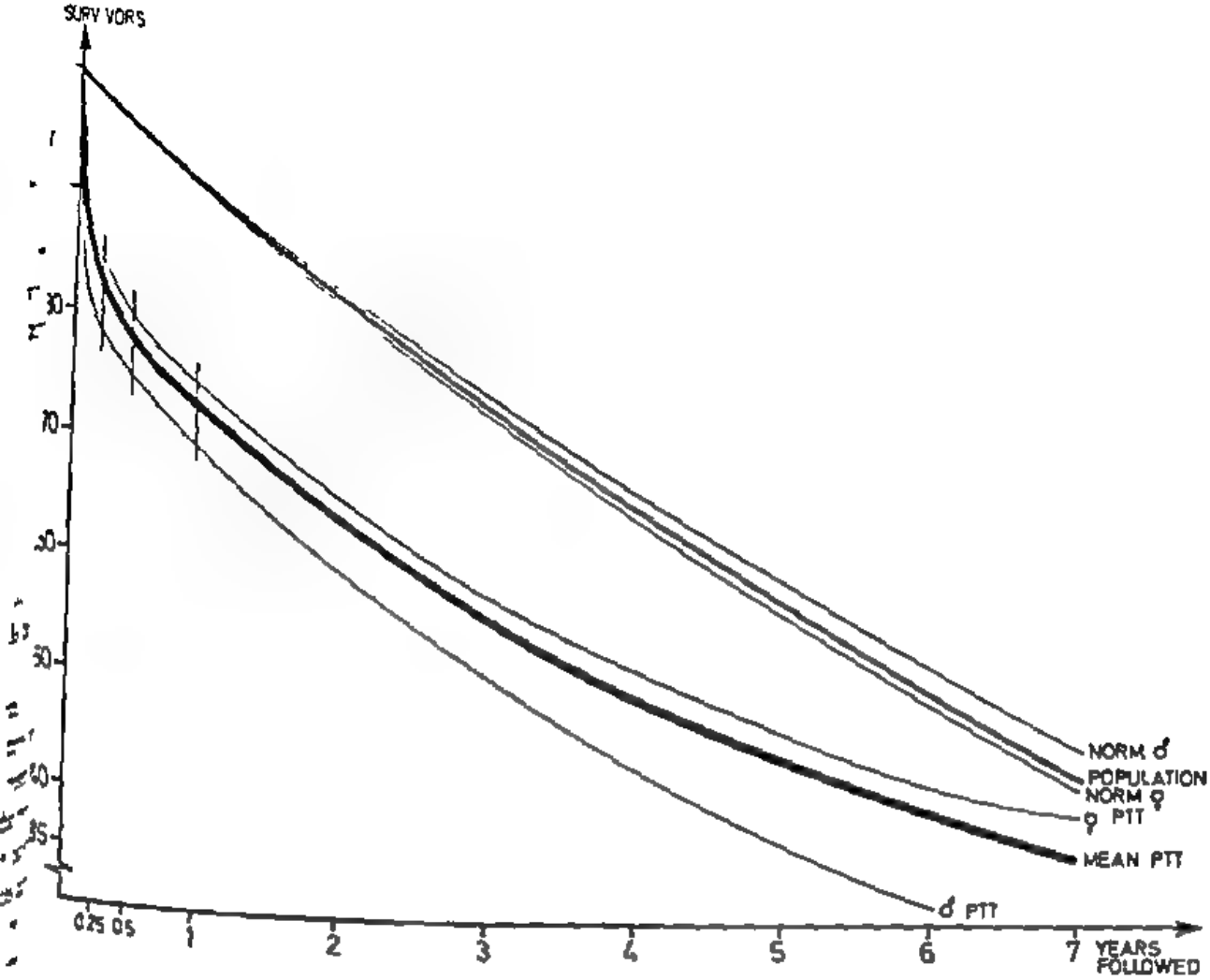

Figure 7 Life tables for 1592 patients with hip fractures

DISCUSSION

The present series confirms some obvious changes in the pattern of hip fractures during the recent years The mean age, 77 years, for patients with hip fracture has thus increased by about 3 to 5 years compared with figures given in earlier papers (Alffram 1964, Fitts et al. 1959, Sweet et al 1967, Öhman et al 1968), but it is consistent with figures in recently published records (Beals 1972, Gordon 1972, Riska 1970). The percentage of female patients, however, is largely unchanged, approximately 75 per cent (Alffram 1964, Gordon 1972, Manpel et al 1961, McNeill 1975, Weeden et al 1957) The mean age of the patients with trochanteric fractures is higher than those with femoral neck fractures and the female patients have a higher mean age than males as mentioned before (Alffram 1964, Beals 1972, Gordon 1972)

The hospital mortality after hip fracture has often been studied and a great variety of mortality rates have been claimed, ranging from 4 per cent (Häggquist 1968, Mikkelsen & Langholm 1964) to about 30 per cent (Manpel et al. 1961, Reno & Burlington 1958, Schenk et al. 1956). In our opinion, however, it is mandatory to know the length of the hospital stay when dealing with hospital mortality rates. It thus makes no sense to compare hospital mortality rates of 31 per cent (Manpel et al 1961) and 36.7 per cent (Schenk et al. 1956) where the period of

hospitalization was 40 and 62 days, respectively, with the hospital mortality of 8 6 per cent in this series where the hospitalization period was 24 days. In two papers taking into account this factor the mortality rate during hospitalization was 7 6 per cent after 16 days (McCown & Miller 1976) and 18 5 per cent after 30 days (Riska 1970)

It has been claimed that the mortality rate is higher in trochanteric fractures than in femoral neck fractures (Colbert & O'Muircheartaign 1976, Cleveland et al 1951, Dolk & Westerborn 1977, McGoey & Evans 1960, Mikkelsen & Langholm 1964, Riska 1970, Weeden et al 1957) The present series, in accordance with others (Alffram 1964, Menpel et al 1961), proves however that it bears no relationship to the fracture type as such The age and the sex of the patients exclusively determine the hospital mortality rates (Alffram 1964, Beals 1972, Clark & Wainwright 1966, Eddy 1972, Fitts et al 1959, Gordon 1972, Manpel et al 1961, Mikkelsen & Langholm 1964, Reno & Burlington 1958, Schenk et al 1956) Severe somatic complications postoperatively lead to a higher mortality within the age groups, which has been established previously (Reno & Burlington 1958) In the present series, ever, 63 per cent of the patients sustain- somatic complications died, whereas Schenk et al (1956) stated 85 per cent

The short term survival in this series, as in most others, was determined by a high initial *mortality rate In our series, however,* a delayed increase in mortality rates was observed 3–4 months after discharge from hospital Beals (1972) noted a similar increase 2 months after discharge from hospital The causes of this secondary rise can not be explained by either of these studies

The mortality 3 months after hip fracture amounted in our series to 17 0 per cent and that at 6 months to 21 5 per cent, which is consistent with figures given in other papers (Alffram 1964, Fitts et al 1959, McCown & Miller 1976, Sweet et al. 1967). These rates have obviously not changed during the past 15 years although the mean age of t patients has increased

In discussing the long term survival af hip fracture it is of interest to identify t time when the survival rate parallels t expected survival rate Alffram (1964) fo this to occur 3 months after the fra while Fitts et al (1959) and Colbert O'Muircheartaign (1976) claimed 6 months the present series the survival rate paralleled expected after 1 6 years, but was fo to be higher than expected after 2.8 years our series the 1 year mortality rate was 2 per cent, in agreement with the rates given Colbert & O'Muircheartaign (1976) Öhman et al (1968) who also encou mortality rates of about 43 per cent af years and about 56 per cent after 5 ye Beals (1972), however, stated an 83 per c mortality rate after 5 years

In conclusion we found, in compa with papers from the past 15 years, that mean age of patients with hip fractures h increased In spite of this and in spite of greater emphasis on operative treatment, t hospital mortality seems to be lar unchanged and related exclusively to age sex The mortality after 3 months is also changed The survival rate, however, does parallel the expected rate until 1 6 years af the fracture

ACKNOWLEDGEMENT

This study was kindly supported by Nor Gjenforsikrings Jubilaeumsfond and the Den Medical Research Council (Grant No Gratitude is expressed to Sv (cand stat) for statistical aid.

REFERENCES

Abrami, G & Stevens, J (1964) Early weight ing after internal fixation of transverse fracture of the femur *J Bone Jt Surg* 46 204–205

Ainsworth, T H (1971) Immediate full weight bearing in the treatment of hip fractures *Trauma* 11, 1031–1040

Alffram, P A. (1964) An epidemiologic study of

cervical and trochanteric fractures of the femur in an urban population *Acta orthop scand*, Suppl 65

Beals, R K (1972) Survival following hip fracture – long follow-up of 607 patients *J chron Dis* 25, 235–244

Colbert D [illegible] O'Muircheartaigh, I (1976) Mortality after hip fracture and assessment of some contributory factors. *Irish J med Sci* 145, 44–50

Clark A N G & Wainwright, D (1966) Management of the fractured neck of femur in the elderly female *Geront clin (Basel)* 8, 321–326

Cleveland, M, Pietra, A D & Friesen, C (1951) An analysis of deaths on an orthopaedic service *J Bone Jt Surg* 33 A, 1009–1011

Delk T & Westerborn, O (1977) Komplikationer och mortalitet i ett höftfrakturmaterial. *Lakartidn* 74, 3554–3558

Eddy, T P (1972) Deaths from domestic falls and fractures *Brit J prev soc Med* 26, 173–179

Fitts, W T, Lehr, H B, Schor, S & Roberts, H (1959) Life expectancy after fracture of the hip *Surg Gynec Obstet* 108, 7–12

Gordon, P C (1972) The probability of death following fracture of the hip *Canad med Ass J* 105, 47–51

Graham, J (1968) Early or delayed weight-bearing after [illegible]

[illegible]

[illegible] bearing in cases of operated subcapital femoral neck fractures. *Acta orthop scand* 40, 684–685

Lindholm, T S, Puronvarsi, U & Lindholm R V (1971) Fractures of the proximal end of the femur with fatal outcome in geriatric patients *Acta chir scand* 137, 778–781

Manpel, J, Marzulli V & Boley, S J (1961) The fractured hip, a complication of ageing *Arch Surg* 82, 474–477

McCown, P L & Miller, W A (1976) Long-term follow-up of hip fractures *South med J (Bgham, Ala)* 69, 1540–1542

McGoey, P F & Evans, J (1960) Fractures of the hip Immediate versus delayed treatment *Canad med Ass J* 83, 260–263

McNeill D H (1975) Hip fractures – influence of delay in surgery on mortality *Wis med J* 74, 129–130

Mikkelsen, O A & Langholm, O (1964) Life expectancy after hip fractures in the aged *Acta chir scand* 127, 46–56

Ohman, U, Bjorkegren N Å & Fahlstrom, G (1968) Trochanteric fractures of the femur *Acta chir scand* 134, 543–548

Parker, H G & Reitman, H K (1976) Changing patterns in fracture management emphasizing early motion and function *Surg Clin N Amer* 56, 667–672

Reno, J H & Burlington, H (1958) Fractures of the hip – mortality survey *Amer J Surg* 95, 581–592.

Risks, E B (1970) Factors influencing the primary mortality in the treatment of hip fractures *Injury* 2, 107–115

Schenk, W G, Smith, R G & Stevens J G (1956) The fractured hip – a major surgical and sociologic problem *Amer J Surg* 91, 618–620

Sweet, M B E, Zwi, S, Mendelow, A, Kotler, M N & Graham, W D (1967) Fractured neck of femur, associated morbidity and mortality *S Afr J Surg* 5, 57–64

Weeden R, Rosenthal H & Miller, P (1957) Mortality statistics on fractured hips *J Bone Jt Surg* 39-A 1218

Correspondence to J Steen Jensen, M D, Dept. Orthop Surg T-2, Gentofte Hospital, DK-2900 Hellerup, Denmark.

hospitalization was 40 and 62 days respectively, with the hospital mortality of 8 6 per cent in this series where the hospitalization period was 24 days In two papers taking into account this factor the mortality rate during hospitalization was 7 6 per cent after 16 days (McCown & Miller 1976) and 18 5 per cent after 30 days (Riska 1970)

It has been claimed that the mortality rate is higher in trochanteric fractures than in femoral neck fractures (Colbert & O'Muircheartaign 1976, Cleveland et al 1951, Dolk & Westerborn 1977, McGoey & Evans 1960, Mikkelsen & Langholm 1964, Riska 1970, Weeden et al 1957) The present series, in accordance with others (Alffram 1964, Menpel et al 1961), proves however that it bears no relationship to the fracture type as such The age and the sex of the patients exclusively determine the hospital mortality rates (Alffram 1964, Beals 1972, Clark & Wainwright 1966, Eddy 1972, Fitts et al 1959, Gordon 1972, Manpel et al 1961, Mikkelsen & Langholm 1964, Reno & Burlington 1958, Schenk et al 1956) Severe somatic complications postoperatively lead to a higher mortality within the age groups, which has been established previously (Reno Burlington 1958) In the present series, ver, 63 per cent of the patients sustain- somatic complications died, whereas t al (1956) stated 85 per cent

The short term survival in this series, as in most others was determined by a high initial mortality rate In our series, however, a delayed increase in mortality rates was observed 3–4 months after discharge from hospital Beals (1972) noted a similar increase 2 months after discharge from hospital. The causes of this secondary rise can not be explained by either of these studies

The mortality 3 months after hip fracture amounted in our series to 17 0 per cent and that at 6 months to 21 5 per cent, which is consistent with figures given in other papers (Alffram 1964, Fitts et al. 1959 McCown & Miller 1976, Sweet et al. 1967) These rates have obviously not changed during the past 15 years although the mean age of the patients has increased

In discussing the long term survival after hip fracture it is of interest to identify the time when the survival rate parallels the expected survival rate Alffram (1964) found this to occur 3 months after the fracture while Fitts et al (1959) and Colbert & O'Muircheartaign (1976) claimed 6 months In the present series the survival rate paralleled the expected after 1 6 years, but was found to be higher than expected after 2.8 years In our series the 1 year mortality rate was 24 per cent, in agreement with the rates given by Colbert & O'Muircheartaign (1976) and Öhman et al (1968), who also encountered mortality rates of about 43 per cent after 1 years and about 56 per cent after 5 years Beals (1972) however, stated an 83 per cent mortality rate after 5 years

In conclusion we found in comparison with papers from the past 15 years, that the mean age of patients with hip fractures has increased In spite of this and in spite of a greater emphasis on operative treatment, the hospital mortality seems to be largely unchanged and related exclusively to age and sex The mortality after 3 months is also unchanged The survival rate, however does not parallel the expected rate until 1 6 years after the fracture

ACKNOWLEDGEMENT

This study was kindly supported by Nordisk Gjenforsikrings Jubilaeumsfond and the Danish Medical Research Council (Grant No. [illegible]) Gratitude is expressed to Sv [illegible] (cand.stat) for statistical aid.

REFERENCES

Abrami G & Stevens, J (1964) Early weight-bearing after internal fixation of transcervical fracture of the femur *J Bone J Surg* 46 204–205

Ainsworth T H (1971) Immediate full weight-bearing in the treatment of hip fracture *Trauma* 11, 1031–1040.

Alffram, P A (1964) An epidemiologic study of

cervical and trochanteric fractures of the femur in an urban population *Acta orthop scand*, Suppl. 65

Beals, R K. (1972) Survival following hip fracture – long follow up of 607 patients. *J chron Dis* 25, 235–244

Colbert, D S & O'Murcheartaigh I (1976) Mortality after hip fracture and assessment of some contributory factors. *Irish J med Sci* 145, 44–50

Clark, A. N G & Wainwright, D (1966) Management of the fractured neck of femur in the elderly female *Geront clin (Basel)* 8, 321–326.

Cleveland M, Pietra A. D & Friesen, C. (1951) An analysis of deaths on an orthopaedic service *J Bone Jt Surg* 33-A, 1009–1011

Dolk, T & Westerborn, O (1977) Komplikationer och mortalitet i ett höftfrakturmaterial. *Lakartidn.* 74, 3554–3558

Eddy T P (1972) Deaths from domestic falls and fractures. *Brit J prev soc Med* 26, 173–179

Fitts, W T, Lehr H B., Schor, S & Roberts, B (1959) Life expectancy after fracture of the hip *Surg Gynec Obstet* 108, 7–12.

Gordon, P C (1972) The probability of death following fracture of the hip *Canad med Ass J* 105, 47–51

Graham, J (1968) Early or delayed weight bearing after internal fixation of transcervical fractures of the femur *J Bone Jt Surg* 50-B 562–569

Haggquist, S O (1969) Results of early weight-bearing in cases of operated subcapital femoral neck fractures. *Acta orthop scand* 40, 684–685

Lindholm, T S, Puronvarsi, U & Lindholm, B V (1971) Fractures of the proximal end of the femur with fatal outcome in geriatric patients *Acta chir scand* 137, 778–781

Manpel, J, Marzulli V & Boley S J (196) fractured hip, a complication of ageing *Surg* 82, 474–477

McCown, P L. & Miller, W A (1976) Long term follow-up of hip fractures *South med J (Bgham Ala)* 69, 1540–1542

McGoey, P F & Evans, J (1960) Fractures he hip Immediate versus delayed treatment *Canad med Ass J* 83, 260–263

McNeill, D H (1975) Hip fractures – influence of delay in surgery on mortality *Wis med J* 74, 129–130

Mikkelsen O A & Langholm O (1964) Life expectancy after hip fractures in the aged *Acta chir scand* 127, 46–56

Öhman U, Bjorkegren N Å & Fahlstrom G (1968) Trochanteric fractures of the femur *Acta chir scand* 134, 543–548

Parker, H G & Reitman H K (1976) Changing patterns in fracture management emphasizing early motion and function *Surg Clin N Amer* 56, 667–672.

Reno J H & Burlington H (1958) Fractures of the hip – mortality survey *Amer J Surg* 95, 581 592.

Riska, E B (1970) Factors influencing the primary mortality in the treatment of hip fractures. *Injury* 2, 107–115

Schenk, W G, Smith R G & Stevens, J G (1956) The fractured hip – a major surgical and sociologic problem *Amer J Surg* 91, 618 620

Sweet, M B E Zwi, S, Mendelow, A, Kotler, M N & Graham, W D (1967) Fractured neck of femur, associated morbidity and mortality *S Afr J Surg* 5, 57–64

Weeden, R. Rosenthal, H & Miller, P (1957) Mortality statistics on fractured hips. *J Bone Jt Surg* 39 A 1218

Correspondence to J Steen Jensen, M D, Dept. Orthop Surg T-2, Gentofte Hospital, DK-2900 Hellerup, Denmark.

a orthop scand 50 169–174 1979

\DOMETHACIN TREATMENT IN OSTEOARTHRITIS F THE HIP JOINT

oes the Treatment Interfere with the atural Course of the Disease?

ELGE RØNNINGEN & NORVALD LANGELAND

phies Minde Orthopaedic Hospital, University of Oslo Oslo Norway

The course of osteoarthritis in 294 hips of 186 patients was evaluated by [illegible] of the disease in patients [illegible] parameter the progress was more severe [illegible] reports indicating that indomethacin might have a deleterious effect on osteoarthritic hip joints. Some possible explanations for this adverse effect of indomethacin treatment are discussed

Key words hip joint, indomethacin, osteoarthritis

Accepted 19 vii 78

I most patients osteoarthritis of the hip ints is a chronic disease, lasting for decades ithout dramatic changes. Rapid disintegra- on of the joint such as collapse of the emoral head occurs, but has been considered be rare (Murray 1976, Storey 1968) In the st 10 years this phenomenon has been bserved in a number of patients Many of hem had been treated with indomethacin, nd this left the impression that there might e a relationship between treatment with ndomethacin and a rapid disintegration of steoarthritic hip joints (Foss Hauge 1975)

The present paper deals with a review of the radiographs of patients treated as in- patients in Sophies Minde Orthopaedic Hospital during 1970 In order to investigate a possible relationship between indomethacin treatment and a rapid deterioration of os- teoarthritic hip joints, the progress in a group treated with indomethacin was compared with that in a control group

MATERIAL AND METHODS

Radiographs of all patients admitted to the hospital because of osteoarthritis of the hip joint in 1970 were reviewed The radiographs anteroposterior projections had been taken with the patient lying supine with his patellae in the frontal plane The patients had been admitted for a radiographic examination of their [illegible] the hospital [illegible] 1965 and [illegible] most recent radiographs taken between these time limits were used for the assessment of the severity and progress of the radiographic changes. The radiographic changes were assessed by an orthopedic surgeon without knowledge of the treatment given to the patient

A modification of the method of Danielsson (1964) was used to quantify the radiographic changes. In Danielsson's method the term "structure" includes hyperdensity (sclerosis) cystic changes and destruction of the joint. These parameters were assessed separately in the present study Changes in the trabecular structure of the femoral head and neck were assessed by the

0001-6470/79 020169 06$02.50/0

© 1979 Munksgaard, Copenhagen

Table 5 Progress of cysts, altered bone structure and destruction during the observation period

	Cysts		Altered bone structure		Destruction	
	Per cent with progress	Mean progress	Per cent with progress	Mean progress	Per cent with progress	Mean progress
Indomethacin group	40*	1 3±0 6	30*	1 2±0 4	31*	1.5±0.4
Control group	26	1 3±0 6	8	1 1±0 3	6	1.0±0.3

* Significantly different from control group ($2\alpha < 0.05$)

Table 6 Hips with progression in cystic changes altered bone structure or destruction during the observation period Observation time, mean age and score at the first examination are indicated

	Number	Mean age Years±s.d	Mean score ±s.d	Mean observation time Years±s.d
Indomethacin group	59	61 9±6 8	7 6±3 1	3 1±2.1
Control group	64	58 3±12.2	5 3±3 8	3 8±2.2

Table 5 shows the percentage of the hips with progression in the above parameters during the observation period Progression was significantly more frequent in the indomethacin group than in the control group ($2\alpha < 0.05$) Furthermore, in the indomethacin treated hips that progressed, a more severe destruction was found ($2\alpha < 0.05$) Progression was equally frequent in females and males.

Table 6 refers to the hips that progressed during the observation time Mean score at the first examination was insignificantly lower in the controls showing progression than in the indomethacin treated hips. Mean observation time and age of the patients correspond to these factors in the groups as a whole

DISCUSSION

Evaluated according to the method described deterioration of osteoarthritic hip joints occurred more frequently among indomethacin treated patients than in the control group In one parameter destruction the deterioration was also more severe. No significant difference in the severity of the osteoarthritis at the first examination could be detected (Table 3). In addition, the patients' ages, sex distribution and observation time were only insignificantly different in the two groups, thus the groups should be statistically comparable

As indomethacin was first introduced in Norway in 1964, none of the patients in the

ndomethacin group had received in-lomethacin for a long period of time at the irst examination Unfortunately exact in-ormation about dosages of indomethacin was ot available in all cases, but none of the atients, where the dosage was known, had eceived doses exceeding those recommended y the producer

As indomethacin treatment was the only nown variable between the two groups, the vestigation supports the theory of a lationship between indomethacin treatment d a rapid deterioration of osteoarthritic hip ints.

Coke (1967), Arora (1968), Allen & urray (1971), Murray (1976), Milner (1973) d Foss Hauge (1975) have reported several ses which have been interpreted as xamples of a relationship between in-omethacin treatment and a rapid progres-on of osteoarthritis

Solomon (1973) reported similar destruc-on in osteoarthritic hip joints as "new vents" during treatment with non-steroid ti-inflammatory drugs, though he paid no ecial attention to indomethacin He rformed further investigations on the ex-pated femoral heads with examination of t surface, slab radiographs and histology lany of the heads, and especially those with anges attributable to non-steriod anti-flammatory drugs, were found to have icroscopic fragmentation of the bony abeculae giving the appearance of a jammed arrow space In the present study loss of abecular structure in the subchondral bone ems to be a characteristic feature in ndomethacin joint destruction" as well as sappearance of normal joint contours and ultiple small cysts. Hyperdensity is com-aratively rare The loss of trabecular ructure could be a parallel to the "jammed arrow spaces" described by Solomon 1973) According to him the drug-induced rthropathy presented features consistent nth necrosis of the femoral head Storey 1968) reporting 14 cases with collapsing steoarthritic hip joints, concluded that the collapse had been a complication of degenerative joint disease, caused either by an avascular necrosis or an osteoporosis predisposing to microfractures in the femoral heads Watson (1976) proposed that osteoporosis leading to microfractures contributes to a rapid disintegration of the hips in these elderly patients The radiographs examined in the present study exhibited features commonly seen in femoral head necrosis, but histological examination has not been carried out As the hips presented well established degenerative disease at the first examination, necrosis could not in any way be the primary event If the theory of osteoporosis as a predisposing factor is the correct one, predominance of females would be expected among the patients showing progression. This could not be detected in the present study

Why indomethacin in some cases may produce a rapid joint destruction remains unknown Two theories have been put forward, the one that indomethacin as an anti-inflammatory agent produces disturbances in bone metabolism and the other that the pain relieving effect makes the patient "overuse" his joint and by increased wear the joint is destroyed The first theory seems to be the more reliable Minor necrosis of bone may be a pathogenetic feature of osteoarthritis, either as a primary event or secondary to microfractures. Normally this necrosis or these fractures are followed by bone repair Bone repair starts with an inflammation. Indomethacin inhibits this inflammation, probably through inhibition of prostaglandin synthetase (Vane 1971, Floman et al. 1977) Because of this inhibition bone repair will be inhibited or delayed as well Repair of necrotic areas or microfractures will thus be affected and severe joint destruction may be the outcome If this theory is correct, a similar effect is to be expected from treatment with other anti-inflammatory agents, although at present indomethacin seems to be the most potent of these agents.

Recently Ro et al. (1976) found that in-

domethacin delayed fracture healing in rats, and Sudmann (1975) reported an inhibition by indomethacin of new bone formation in the rabbit ear chamber An experimental investigation in rats concluded that indomethacin delayed formation of new bone in the extraction cavity following tooth extraction (Huusko et al 1975) The doses used in these animal studies may have been too high to be clinically relevant, but their results support the theory that indomethacin interferes with bone metabolism, leading to delayed bone repair

REFERENCES

Allen E. H & Murray, O (1971) Iatrogenic arthropathies. *European Association of Radiology, Proceedings Exerpta Medica* (International Congress Series) 249, 204–210

Arora, J S (1968) Indomethacin arthropathy of hips. *Proc. roy Soc Med* 61, 669

Coke, H (1967) Long term indomethacin therapy of coxarthrosis. *Ann. rheum Dis* 26, 346–347

Danielsson L. G (1964) Incidence and prognosis of coxarthrosis. *Acta orthop scand*, Suppl. 66, 9–114

Floman F., Okon, E. & Zor, U (1977) The role of prostaglandins in experimental arthritis in the rat *Clin Orthop* 125, 214–220

Hauge, M Foss (1975) Hofteleddartrose - indomethacin *T norske Lægeforen* 95, 1594–1596

Huusko, P J Nieminen, Leena, H L & Nieminen, L S (1975) The effect of indomethacin on tooth extraction wound healing in rats. *Experientia (Basel)* 3, 1056–1057

Milner, J C (1973) Osteoarthritis of the hip and indomethacin. *J Bone Jt Surg* 54-B 702

Murray, R. O (1976) Iatrogenic lesions of the skeleton. *Caldwell Lecture* Vol. 125, No 1 p 19, Charles C Thomas, Springfield, Ill.

Rø, J., Sudmann E & Marton, P F (1976) Effect of indomethacin on fracture healing in rats *Acta orthop scand* 47, 588–599

Solomon, L. (1973) Drug induced arthropathy and necrosis of the femoral head. *J Bone J Surg* 55-B 246–261

Storey, G O (1968) Bone necrosis in gout disease *Proc. roy Soc. Med* 61, 17–25

Sudmann, E (1975) Effect of indomethacin on bone remodelling in rabbit ear chamber *Acta orthop scand*, Suppl. 160 91–115

Vane J R (1971) Inhibition of prostaglandin synthesis as a mechanism of action for aspirin like drugs. *Nature New Biol* 231, 232–235

Watson M (1976) Femoral head height low: a study of the relative significance of sex and its determinants in hip degeneration *Rheumatology and Rehabilitation* 15, 264–269

to Helge Rønningen, Sophies Minde Ortopedisk Hospital, Trondheimsveien 132, Oslo

acta orthop scand 50 175–178 1979

THROMBOEMBOLIC COMPLICATIONS FOLLOWING SCOLIOSIS SURGERY IN SCANDINAVIA

ULF LÖDEN

Department of Orthopaedic Surgery, Malmö General Hospital (University of Lund), Malmö Sweden

[illegible] operated on according to Harrington there were eight [illegible] or [illegible] ght [illegible] irst symptom [illegible] om plaints. O [illegible] of the left leg Another p [illegible] ed pathological collateral [illegible] ment of a post-thrombotic syndrome

Key words scoliosis, thrombosis, iliac compression syndrome

Accepted 16 IX.78

Thromboembolic complications following scoliosis operations have been considered to be extremely rare To gather experience, a multicentre investigation was proposed at a meeting of the Scandinavian Society for Scoliosis Research in Gothenburg in 1976

MATERIAL AND METHODS

This retrospective study is based on reports from scoliosis centres in Denmark, Finland, Norway and Sweden In all 1229 patients were operated on according to Harrington in 1963–1976 Postoperatively 3–5 weeks of strict bedrest was prescribed Some of the patients were operated on on two occasions. The diagnosis of deep venous thrombosis (DVT) was based on clinical examination and verified by contrast phlebography or autopsy In Malmo, isotope phlebography was carried out simultaneously

The material is presented in Table 1 The mean values of estimated blood loss and duration of operation were calculated for each centre and are used for comparison between patients with and without DVT

RESULTS

DVT was diagnosed in eight cases (Table 1) which implies an incidence of 6 5 per thousand Patients with DVT were significantly older than the average ($P < 0.001$, t-test) (Tables 1 and 2) The operation was in these cases more extensive than average as indicated by the number of vertebrae fused, the duration of the operation ($0.05 < P < 0.10$, t-test) and the estimated blood loss ($P < 0.05$, t-test) (Tables 1 and 2)

The DVT were in all cases localized proximally on the left side The diagnosis was made at about 3 weeks after operation (Table 3) The symptoms were negligible in

Financial support was obtained from the Swedish Medical Research Council (project no B 77-17X-2737-9B).

0001-6470/79 020175-04$02.50.0

© 1979 Munksgaard, Copenhagen

the patients are placed on a modified Realton frame which generates continuous pressure on the inguinal region, possibly reducing the blood flow

Most patients developed symptoms 3 weeks after surgery The long delay may be explained by the strict bedrest, reducing the demands and allowing the thrombus to attain a considerable size before causing symptoms During that time there may be a risk of pulmonary emboli and most pulmonary emboli occur without previous clinical symptoms (Sevitt 1962)

The risk of post-thrombotic syndrome is high in cases with proximal involvement (Cockett et al 1967) Out of our seven patients so far only two have developed a post thrombotic syndrome but the incidence will, most likely, increase with time (Gjöres 1956) The scoliosis patients without clinical signs of thrombosis may also develop a post-thrombotic syndrome since such symptoms are preceded by an episode of clinically apparent thrombosis in only one third of the cases (Antal & Reiss 1976)

REFERENCES

Antal, [illegible] C & Reiss R (1976) Post-thrombotic leg ulcer and its surgical treatment. *Amer J Surg* 131, 710–713

Cockett F B Lea Thomas, M [illegible] Negus D (1967) Iliac vein compression, its relation to iliofemoral thrombosis and the post-thrombotic syndrome *Brit med J* 2, 14 19

Cockett, F B & Lea Thomas, M (1965) The iliac compression syndrome *Brit J Surg* 52 816–821

Gjores J E. (1956) Post thrombotic sequelae *Acta chir scand*, Suppl 206

Kakkar V V Howe C T, Flanc, C [illegible] Clark M B (1969) Natural history of post-operative deep vein thrombosis. *Lancet* ii, 230–232

Sevitt S (1962) Venous thrombosis and pulmonary embolism. *Amer J Med.* 33, 703–716

Correspondence to Alf Udén Department of Orthopedic Surgery, Malmo General Hospital (University of Lund) Malmo Sweden

Acta orthop scand. 50, 179–185, 1979

LOCALIZED REGRESSIVE ARTICULAR CARTILAGE CHANGES IN THE HIP JOINT OF THE RABBIT FOLLOWING AN INDUCED SYNOVITIS

DAVID H GERSHUNI ANATOL AXER & BARRY SIEGEL

The Department of Orthopaedics Research Laboratory, Asaf Harofe Hospital, Zerifin, Israel

A talcum induced synovitis in the hip joint of the rabbit, which is known to cause articular cartilage hyperplasia followed by femoral head protrusion and joint incongruency, has in the present experiment also been shown to lead to localized regressive articular cartilage changes. The articular cartilage of the hip joints in 40 rabbits was examined histologically, at intervals, following induction of such a talcum synovitis. Regressive changes in the form of loss of surface chondrocytes and glycosaminoglycans sometimes accompanied by fibrillation, were found in the area of the femoral h
head pr
repair T
synovitis
considere
Perthes'

Key words: cartilage degeneration, Perthes' disease, synovitis

Accepted 1 x.78

In a previous study (Gershuni-Gordon & Axer 1974) we have shown that a synovitis induced in the rabbit's hip joint by the intra-articular injection of a surgical talc suspension stimulated thickening of articular cartilage which decreased the acetabular capacity vis-a-vis the increased head size thus the femoral head protruded from the joint as demonstrated radiologically, and due to abnormal pressure effects the femoral head developed a flattening superiorly It was decided to investigate further these induced effects on the joint cartilage by histological examination using special stains so as to relate the biochemical changes to changing morphology, the final objective being to advance the understanding of the aetiology of Legg-Calvé-Perthes' Syndrome (L C P S) in children.

MATERIAL AND METHODS

Forty immature female rabbits, 21 to 28 days old, were anaesthetized with open ether and after exposing the right hip joint capsule an intra-articular injection of surgical talc (magnesium tetrasilicate) suspension was performed, the left hip served as the control (Gershuni-Gordon & Axer 1974) The animals were allowed to ambulate normally The hip joints were X-rayed at 2 weeks postoperatively and just prior to killing The radiological Medial Joint Space (M J S) was measured from the medial edge of the capital epiphysis to the acetabular "tear-drop" to check whether the joint cartilage thickened in response to the induced synovitis and had caused joint incongruency (Gershuni-Gordon & Axer 1974).

The majority of animals were killed in groups at weekly intervals from 2 to 6 weeks, since the previous study had shown this period to be the most significant for witnessing the effects of an

0001-6470/79/020179-07$02.50 0

© 1979 Munksgaard, Copenhagen

induced synovitis however a smaller number of animals were followed from 7 to 11 weeks. The hip joint capsules were carefully opened and the articular surfaces, after rinsing with physiological saline solution were painted with Indian ink and rinsed again with saline (Meachim 1972) any areas retaining the ink particles were recorded To obviate the discrepancies known to occur in the histochemical techniques used in staining cartilage matrix and especially glycosaminoglycans the specimens from the experimental and control hips were treated in an exactly similar fashion from fixation to staining Thus the hip joints were fixed in formalin and then decalcified in a formic acid buffer solution. The femora were sectioned in the coronal plane and the acetabula in the plane passing vertically through the centre of the acetabular notch. After paraffin wax embedding of complementary right and left hemi sections in the same block sections at 7 μ were cut on the microtome Simultaneously right and left sections were stained on the same slide with haematoxylin and eosin or safranin O and fast green Safranin O selectively stains glycosaminoglycans to an intensity of colour which is proportional to the content of the glycosaminoglycans in the cartilage (Rosenberg 1971).

The sections were examined grossly and microscopically always comparing the right operated side with the left control side Measurement was made of the following features

1 Articular cartilage thickening
2 Femoral head cartilage flattening
3 Loss of glycosaminoglycans as evidenced by decreased safranin O and increased fast green counter staining
4 Loss or death of chondrocytes
5 Cloning of chondrocytes
6 Articular cartilage fibrillation

Indian ink painting

No significant localized patterns of retention of the Indian ink particles were seen on the surface of the articular cartilage on gross inspection but the painting proved useful from another point of view as will be described later

Histological sections

Cartilage thickening and flattening was a prominent feature from 2 weeks until 8 weeks postoperatively After that period cartilage thickening was not found, but in three out of six animals flattening of the head cartilage persisted The flattening occurred on the superior aspect of the head sometimes more anteriorly sometimes more posteriorly (Table 1)

In normal articular cartilage there are chondrocytes dispersed throughout the matrix right up to the surface (Figure 1). On the experimental side death and loss of the superficial layer of the articular chondrocytes was seen starting in some cases at 2 weeks and becoming almost invariably present between 4 and 5 weeks postoperatively (Figure 2) In some cases the deeper layers of chondrocytes were similarly affected, but the changes were never present exclusively in the deeper layers In the area of chondrocyte death there were parallel changes in the

RESULTS

Radiographic Medial Joint Space (M J S)

Enlargement of the M J S was previously shown to correlate with thickening of the joint cartilage (Gershuni Gordon & Axer 1974) Thirty five out of 40 animals had a significant enlargement of the M J S i e, 0 3 mm or more (Gershuni-Gordon & Axer 1974) on the operated side at weeks After 7 weeks the M J S difference between the two hips had decreased (Table 1)

Figure 1 Normal articular cartilage from the femoral head of an 11-week-old rabbit showing regular dispersal of chondrocytes up to the surface (Haematoxylin and eosin x 1[illegible]

Table 1 Results of radiological and histological examinations

Time after operation (weeks)	Number of animals	Average difference in M J S* at 2 weeks (mm)	Average difference in M J S* at sacrifice (mm)	Number with cartilage thickening	Number with cartilage flattening	Number with death and loss of cells	Number with loss of G A G s†	Number with cell cloning	Number with fibrillation
2	5	0 9	0.9	4	3	2	1	1	0
3	4	0 9	0 8	3	3	3	3	3	1
4	6	1 1	1 1	5	6	6	6	5	3
5	6	0 7	0 8	5	5	5	3	3	0
6	10	1 0	0 9	7	7	7	6	5	1
7	1	0 5	1 2	1	1	1	1	1	0
8	2	0 9	0 6	1	2	2	2	2	1
9	3	0 9	0 2	0	3	2	0	2	0
10	1	0 5	0	0	0	0	0	0	0
11	2	0 8	0	0	0	1	1	1	0

* M J S —refers to the radiologically measured Medial Joint Space
† G A G s—Glycosaminoglycans



Figure 2 Femoral head articular cartilage 6 weeks after induction of synovitis There is a decreased cellularity, especially of the superficial cartilage, accompanied by clone formation and decreased metachromasia in the central region of the cartilage (Safranin 0 and fast green, × 100)

3 Femoral head articular cartilage 6 weeks induction of synovitis The "ghosts" of dead can be seen together with clone formation (Haematoxylin and eosin, × 400)

(a)

(b)

Figure 4 Femoral head articular cartilage weeks after induction of synovitis (a) There are focal regressive changes with surface fibrillation (Haematoxylin and eosin × 40). (b) A higher magnification of the fibrillated region showing Indian ink particles on the underside of some collagen fibres Loss of surface chondrocytes and marked cloning are also well shown (Haematoxylin and eosin × 100)

topographically and temporally of glycosaminoglycan loss, as evidenced by decreased safranin 0 staining, and of chondrocyte multiplication as shown by clone formation (Figures 2 and 3)

In six cases, three of them at the fourth postoperative week, the surface layers split in a tangential manner denoting early fibrillation. In these cases the Indian ink particles could often be seen on the inferior aspect of the fibrillations confirming that the changes were not artefacts (Figures 4A and 4B). Many of the above changes were still present after 7 weeks, but the tendency was for them to be much less common with increasing time following operation.

The articular cartilage changes occurred in the whole or part of the extent of the flattened area on the superior aspect of the head In one rabbit killed 6 weeks postoperatively the flattened area of the head showed marked chondrocyte and glycosaminoglycan loss, surface fibrillation and partial collapse of the cartilage on the underlying trabeculae of the bone (Figure 5).

The acetabular articular cartilage showed thickening *pari passu* with that of the femoral

Figure 5 Femoral head articular cartilage 6 weeks after induction of synovitis There is fibrillation of the superficial layer with Indian ink particles outlining the disrupted fibres and the underlying cartilage has collapsed into the bony epiphysis Note also loss of chondrocytes and of uniform metachromasia (Safranin O and fast green x 100)

head did not show such florid changes as just described. Occasionally there were areas of superficial cell loss in a more diffuse manner in the dome region.

None of the above pathological changes were ever seen on the control side

Radiographic Medial Joint Space (M J S) —Histological correlations

There were 35 animals which maintained an enlarged M J S on the operated side until sacrifice and their femoral head articular cartilage showed marked histological changes as described above In five animals that at sacrifice did not show a significant enlargement of the M J S, i.e. of 0 3 mm or more (Gershuni-Gordon & Axer 1974), there were no histological changes in three operated hip joints, and in the remaining two cases only slight cartilage thickening and minimal superficial chondrocyte damage were noted

DISCUSSION

In the human and rabbit hip it has been shown that a very slight natural incongruency allows, on weight bearing, a better distribution of forces between the two articular cartilages (Bullough et al 1968, 1973) As soon as this physiological incongruency is disturbed, weight-bearing forces are concentrated over a reduced area, thus increasing the contact stresses

The present experiment showed that an induced talcum synovitis causes a rapid articular growth response resulting in joint incongruency, in the enlarged femoral head cannot be contained in the less capacious acetabulum Thus the osteocartilaginous head "grows out" of the acetabulum.

A permanent flattening of the superior aspect of the femoral head cartilage, through which the joint action force passes, was found in most animals. This is explained by the cyclical loading of the decreased area of contact causing the expression of a small, although finite, quantity of water from the underlying matrix (Linn & Sokoloff 1965) If the cyclical loading continues and in addition the area is never completely unloaded, a permanent deformation ensues (Linn 1967) and cartilage nutrition at this spot is interfered with (Gritzka et al 1973, Maroudas et al 1968) This results in damage and death of superficial chondrocytes which inhibits repletion of glycosaminoglycans lost in their normal physiological turnover (Mankin & Lippiello 1969) Alternatively, trauma to the chondrocytes releases proteolytic enzymes capable of degrading proteoglycans (Ali 1964, Woessner & Sapolsky 1975) Whichever process is responsible, there is definite histochemical evidence in the present experiment, i e., the localized loss of safranin O uptake (Rosenberg 1971), that the concentration of glycosaminoglycans is diminished in the superficial zone of the articular cartilage of the overstressed area.

Following weakening of the underlying glycosaminoglycan depleted matrix, the increased, mainly radially disposed, cyclical loads caused failure of the horizontal superficial collagen fibres in the articular cartilage (Kempson 1972) Superficial regressive changes with fibrillation occurred only in those cases showing pathological

changes in the deeper layer of the cartilage In most instances the latter changes were present without accompanying fibrillation, implying that superficial collagen fibre rupture was secondary to glycosaminoglycan loss.

In the area of the femoral head showing regressive cartilage changes there was accompanying chondrocyte multiplication which facilitated reconstitution of the articular cartilage (Mankin & Lippiello 1970) Thus in many of the animals examined at 9 or more weeks after the synovitis insult, the cartilage was nearly normal having presumably repaired itself where remodelling had neutralized the previous incongruency (Gershuni-Gordon & Axer 1974)

An important correlation exists between the degree of enlargement of the radiological M J S, which denotes cartilage thickening (Gershuni-Gordon & Axer 1974), and the presence of regressive cartilage changes. This fact connects the severity of cartilage damage directly to the degree of mechanical disturbance developing within the joint

The findings of the present experimental study may be compared with certain known features of transient synovitis and Legg-Calvé-Perthes' Syndrome (L.C P S) in ildren's hips. Firstly, there is considerable dence that L C P S may be preceded by an episode of synovitis (Fox & Griffin 1956, Jacobs 1960 1971, Kemp & Boldero 1966 and Spock 1959) The absolute enlargement of the osteochondral elements of the human hip in transient synovitis and L.C.P S, with the femoral head "growing out" of the acetabulum, has been demonstrated arthrographically (Axer & Schiller 1972, Gershuni et al. 1978) It was also shown that a lateral protrusion of the head and flattening of cartilage in the superior head region occurred in the *early* phase of L.C.P S (Gershuni et al 1978). Larsen & Reimann (1973) and McKibbin & Ralis (1974) noted hyperplasia of the articular cartilage in children with L.C.P S, the former authors also described accompanying clone formation and the latter a large macroscopic indentation of the superior femoral head cartilage. One might speculate that if following transient synovitis the same series of changes and damage occurred in the cartilage of the superior aspect of a child's femoral head as was seen in one rabbit's hip (Figure 9) the result of continuing joint action force passing through this decreased weight-bearing area might be to embarrass that component of the capital epiphyseal vasculature traversing the underlying region, a varying degree of bone necrosis could then ensue

REFERENCES

Ali, S Y (1964) The degradation of cartilage matrix by an intracellular protease. *Biochem J* 93, 611–618

Axer, A & Schiller M G (1972) The pathogenesis of the early deformity of the capital femoral epiphysis in Legg-Calvé-Perthes' syndrome (L.C.P S)—An arthrographic study *Clin. Orthop* 84, 106 1[illegible]

Bullough P, Goodfellow, J Greenwald, H S & O'Connor, J (1968) Incongruent surfaces in the human hip joint *Nature (Lond.)* 217, 1290

Bullough, P, Goodfellow, J & O Connor J (1[illegible]) The relationship between degenerative changes and load bearing in the human hip *J Bone Jt Surg* 55-B 746–758

Fox, K W & Griffin, L. C. (1956) Transient synovitis of the hip joint in children. *Tex. S J Med* 52, 15 20

Gershuni-Gordon D H & Axer A (1[illegible]) Synovitis in the hip joint An experimental model in rabbits. *J Bone Jt Surg* 56 69–77

Gershuni, D. H., Axer, A & Hendel, D (1[illegible]) Arthrographic findings in Legg-Calvé-Perthes syndrome and transient synovitis of the hip *J Bone Jt Surg* 60-A 457–464

Gritzka, T L., Fry L. H., Cheesman, R. L. & Di Vigne, A (1973) Deterioration of articular cartilage caused by continuous compression in moving rabbit joint *J Bone Jt Surg* 55 A 1698–1720

Jacobs, B W (1960) Early recognition of osteochondrosis of capital epiphysis of femur *J Amer med Ass* 172, 527–531

Jacobs, B W (1971) Synovitis of the hip in children and its significance. *Pediatrics* 47 558–566.

Kemp, H S & Boldero, J L (1[illegible]) changes in Perthes' disease *Pr[illegible]* 39, 744–760

Kempson, G E (1972) The tensile properties of articular cartilage and their relevance to the development of osteoarthrosis *Proceedings of the 12th Congress S I C O T* Tel-Aviv, Excerpta Medica

Larsen, E. & Reimann, J (1973) Calvé-Perthes' disease with special reference to histological observations *Acta orthop scand* 44, 426–438

Linn, F C. (1967) Lubrication of animal joints I The arthrotripsometer *J Bone Jt Surg* 49-A, 1079–1098

Linn F C & Sokoloff, L (1965) Movement and composition of interstitial fluid of cartilage *Arthr and Rheum* 4, 481–494

Mankin, H J & Lippiello, L (1969) The turnover of adult rabbit articular cartilage *J Bone Jt Surg* 51 A, 1591–1600

Mankin, H J & Lippiello, L (1970) Biochemical and metabolic abnormalities in articular cartilage from osteo-arthritis hips *J Bone Jt Surg* 52 A, 424–433

Maroudas, A, Bullough, P G, Swanson, S A V & Freeman, M A R (1968) The permeability of articular cartilage *J Bone Jt Surg* 50-B, 166–171

McKibbin, B & Rais, Z (1974) Pathological changes in a case of Perthes' disease *J Bone Jt Surg* 56 B, 438–447

Meachim G (1972) Light microscopy of indian ink preparations of fibrillated cartilage *Ann Rheum Dis* 31: 457–464

Rosenberg, L (1971) Chemical basis for the histological use of safranin O in the study of articular cartilage *J Bone Jt Surg* 53-A, 69–82.

Spock, A (1959) Transient synovitis of the hip joint in children *Pediatrics* 24, 1042–1049

Woessner, J F & Sapolsky, A I (1975) Breakdown of protein-polysaccharide complexes by cartilage proteases. *Ann Rheum Dis* 34, (Suppl 2), 67–68

Correspondence to David H Gershuni, F R C S, F R C S E, Assistant Professor, Division of Orthopaedic Surgery, University Hospital, 225 Dickinson Street, San Diego, California 92103, USA

Acta orthop scand. 50 187–189, 1979

BONE MASS IN PRIMARY COXARTHROSIS

ÅKE CARLSSON, BO E NILSSON & NILS E WESTLIN

Department of Orthopedic Surgery Malmo General Hospital (University of Lund) Malmö, Sweden

The bone mineral content was measured by gamma absorptiometry at two levels on the forearms, proximally on the shafts and distally close to the wrist, in 53 cases of primary coxarthrosis The bone mineral content at the distal measuring site representing trabecular bone was increased in coxarthrosis cases as compared with normal controls, the difference was significant only in women At the proximal measuring site representing cortical bone, there was no significant difference The findings support the concept of impairment of the resilience of the juxta articular trabecular bone as one factor contributing to the pathogenesis of arthrosis

Key words osteoarthritis coxarthrosis, bone mineral

Accepted 25 VIII 78

Radin & Paul (1970) concluded from experimental loading studies on animal joints that only the periarticular soft tissues and the periarticular bone have significant force-attenuating properties and that therefore cartilage degeneration could be caused by alterations in the mechanical properties of the underlying bone Once degenerative joint changes become clinically and roentgenologically apparent there are secondary changes in the periarticular bone However, measurements of bone mass may be obtained from other parts of the body Foss & Byers (1972) measured the cortices of the second metacarpal in patients with coxarthrosis and those with fracture of the upper end of the femur and found that coxarthrosis cases had higher values than the controls whereas fracture cases were below normal Roh et al (1973) found similar changes in the second metacarpal bone of coxarthrosis cases — the dimensions of the bone in the [illegible] increased periosteal apposition rate [illegible] normal endosteal resorption rate, [illegible] the bone remodelling changes in [illegible] Using a method of photon [illegible] measurement of bone mass [illegible] found that not only the [illegible] also the shaft and the distal [illegible] showed an increased bone [illegible] cases with coxarthrosis [illegible] healthy controls The difference was [illegible] pronounced in women [illegible] other hand, Albanese et al (1973) [illegible] demonstrate any difference [illegible] mineral content in the forearm of patients with coxarthrosis [illegible] suggested that differences of results may be due to the selection [illegible]

Financial support was obtained from the Swedish Medical Research Council (project no B78-17X-2737 10C), the Greta and Johan Kock and the Alfred Österlund Foundations

0001-6470/79/020187-03$02.50 0

MATERIAL [illegible]

Coxarthrosis

Included in the [illegible] were altogether 53 [illegible] primary coxarthrosis [illegible] 21 [illegible]

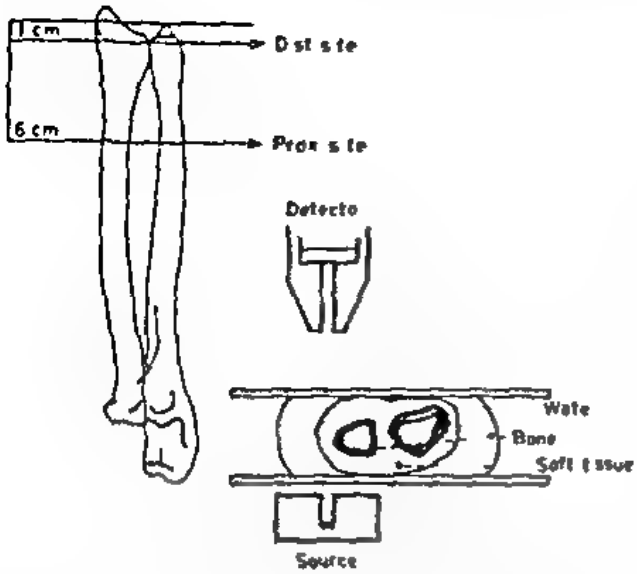

Figure 1 Schematic representation of the measuring device The forearm is enclosed in a water filled latex cuff and compressed between two parallel perspex slabs A rectolinear scan is performed across the two forearm bones and the attenuation of the radiation from the radionuclide source used for calculation of the bone mineral content in the pathway of the beam Measuring sites indicated on the left

an age range of 43–85 They were all classified as primary since there were no signs and no history indicating rheumatoid arthritis traumatic origin or pre-existing deformity All the patients had severe symptoms of coxarthrosis that they were scheduled for total hip replacement In most instances the measurement was carried out when the patients were admitted for surgery

Controls

The controls, 155 women and 140 men were all drawn from previously collected normative data on the bone mineral content of the forearm (Westlin 1974) These subjects were hospital employees, randomly selected visitors to admitted patients and healthy men from a home for the elderly Also some orthopaedic patients from the outpatient department were included These data have been analysed for homogeneity between the various groups sampled. Also, it has been established that individuals with clinical signs of reduced bone mass such as vertebral compression fracture femoral neck fracture and fractures of the proximal humerus and the distal end of the forearm were not more often represented than in the base population. Using these data only those subjects who belonged to age groups corresponding to the coxarthrosis cases were selected for comparison, altogether 99 men and 11 women

Bone mineral measurement

The bone mineral content (BMC) was measured at two levels on the forearm, 1 cm and 6 cm proximal to the tip of the ulnar styloid process (Figure 1). The measurements were obtained by gamma absorptiometry — a rectolinear scan across the radius and the ulna with simultaneously moving radiation source (Americium–241) and detector (Figure 1) (Nordin et al. 1974) The average thickness of bone mineral (g/cm²) was calculated for the radius and the ulna together The average of the left and the right forearms was used

The BMC of control cases and coxarthrosis cases was compared by analysis of covariance with age as the covariant factor

RESULTS

At the proximal measuring site 6 cm from the ulnar styloid representing mainly cortical bone there was no difference between coxarthrosis cases and controls. At the distal measuring site, however which includes much trabecular bone the BMC was greater in coxarthrosis cases than in controls. The difference was significant only in women ($0.01 < P < 0.01$) (Figure 2). Patients walking with a stick did not deviate from other cases of coxarthrosis nor was there any difference between the arm holding the stick and the contralateral arm

DISCUSSION

Roh et al (1974) and Alhava et al (1976) measured the BMC on the shafts of the radius and/or the ulna representing the cortical bone and at the distal end of the two bones representing trabecular bone However the latter measuring sites were located 2 or 3 cm from the tip of the ulnar styloid process At these levels only 10 25 per cent of the bone is trabecular whereas in the measuring site used in the present study — 1 cm from the

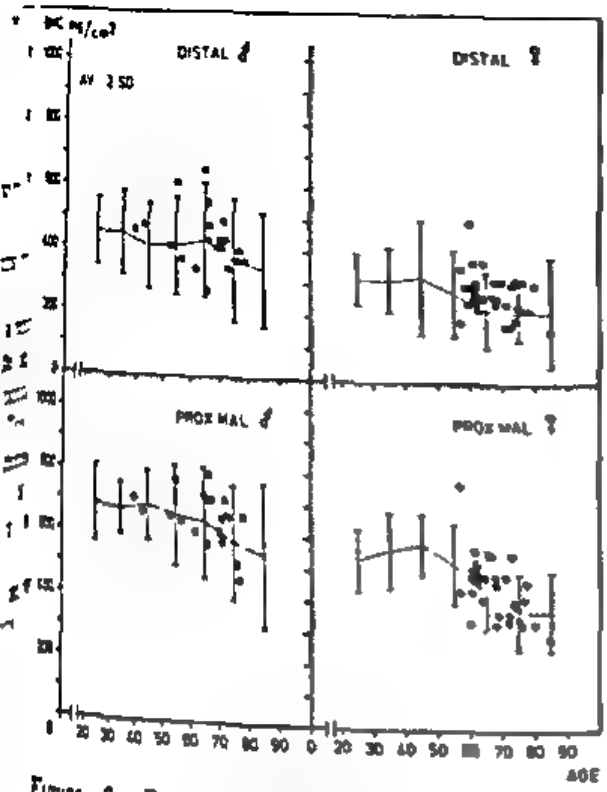

Figure 2 Bone mineral content at the two measuring sites as compared with normative data (interrupted line—average, vertical bars=2 SD) Most values are within the normal range but, in the distal measuring site, women with coxarthrosis deviate significantly from the normative data

ulna styloid tip — 50 per cent of the bone is trabecular (Schlenker 1976) Therefore, previous studies on the relationship between bone mass and arthrosis have dealt mostly with cortical bone whereas the interesting structure is probably the subchondral trabecular bone Our coxarthrosis cases did not deviate from normal with respect to cortical bone, only the juxta-articular cancellous bone of the wrist deviated from normal and, when studied for both sexes separately, the deviation was significant only in women Our data tend to support the hypothesis that the shock-absorbing capacity of the subchondral bone may be impaired in some individuals in whom the bone mineral mass is slightly higher as compared with the average for their age group This may be one of several factors in the pathogenesis of coxarthrosis.

REFERENCES

Alhava, E M, Kettunen, K & Karjalainen, P (1975) Bone mineral in patients with osteoarthrosis of the hip *Acta orthop scand* 46, 709–715

Foss, M. V L & Byers, P D (1972) Bone density, osteoarthrosis of the hip, and fracture of the upper end of the femur *Ann. rheum Dis* 31, 259–264

Nauclér, L O W, Nilsson, B E. & Westlin, N E (1974) An apparatus for gamma absorptiometry of bone — Technical data *Opuscula Medico-Technica Lundensia* 12, I, 1–14

Radin, E. L. & Paul, I L (1970) Does cartilage compliance reduce skeletal impact loads? *Arthr and Rheum.* 13, 139–144

Roh, Y S, Dequeker, J & Muller, J C (1973) Cortical bone remodeling and bone mass in primary osteoarthrosis of the hip *Invest Radiol* 8, 251–254

Roh, Y S, Dequeker, J & Muller, J C. (1974) Bone mass in osteoarthrosis, measured *in vivo* by photon absorption *J Bone Jt Surg* 56-A, 587–591

Schlenker, R A (1976) Percentages of cortical and trabecular bone mineral mass in the radius and ulna *Amer J Roentgenol* 126, 1309–1312.

Westlin N E (1974) An apparatus for gamma absorptiometry of bone — normative data *Opuscula Medico-Technica Lundensia* 12, II, 1–8

Correspondence Bo Nilsson M D, Department of Orthopedic Surgery Malmo General Hospital, S-214 01 Malmo, Sweden

femoral osteotomy alone, with an observation period of up to 6 years, suggest that the fragmentation period is reduced (Axer et al 1973, Puranen & Heikkinen 1976), and that the result is better in the "at risk" group (Catterall 1971) than in untreated patients or in children who have received treatment by means of weight-relieving braces alone (Canale et al 1972, Laurent 1973, Lloyd-Roberts et al 1976)

Two different series of children with LCPD were compared by Brotherton & McKibbin (1977) with a control series of untreated children reported by Catterall (1972) One of the two series received treatment with bed-rest with abducted legs, while the other series was the osteotomy material of Lloyd-Roberts et al (1976) Brotherton & McKibbin found that in Catterall's Group 3, where only a very small portion of the head is not involved, the bed-rest series gave only marginally better results than the osteotomy series, but in Group 4, with total involvement of the femoral head, the benefit obtained in the bed-rest series was considerably better than that obtained in the osteotomy series They also concluded that the benefits of bed-rest in wide abduction could not be ascribed wholly to the application of the containment principle, and it seemed certain that weight relief played some part, at least when the degree of head involvement was total

Varus derotation femoral osteotomy is a relatively simple intervention, which should be taken into consideration if the final result is the same as that after treatment by bed-rest or wheelchair (Lauritzen 1975), so that the children can be spared years of inactivity, possibly away from home

The aim of the present study was therefore to examine the hypothesis of the containment principle in LCPD For the hypothesis to be confirmed, there should be a good correlation between the degree of lateralization of the femoral head during the course of the disease, and the maintenance of the sphericity of the head several years later

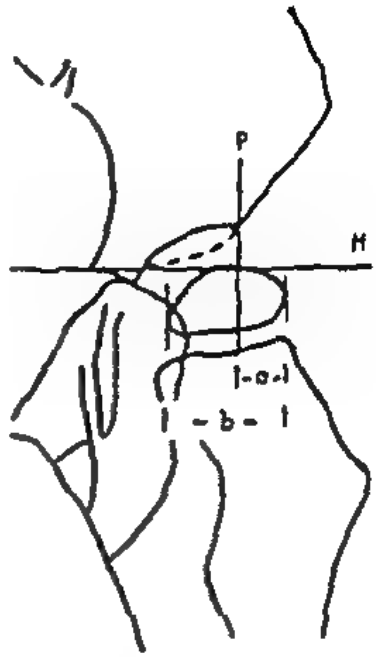

Figure 1 Migration Percentage (MP). P corresponds to Perkins' line perpendicular to the horizontal line H, and passing through the acetabular edge MP is then a/b × 100 per cent

PATIENTS

The material is consecutive and comprises all LCPD children treated at the Seaside Hospital Refsnaes from 1952 to 1957 with strict bed-rest followed by Snyder's sling Excluded from the original material are children with bilateral LCPD children with complicating bone diseases or with other treatment, and those for whom the radiographs were not available

The material then consists of 46 children with a median age of 8 2 years (range 2 10–9 11 years) at the onset of the disease The onset had to be estimated from the anamnesis.

They were treated with bed-rest for a mean period of 1 7 years (range 1 1–2 1 years) up to years after the onset (range 1 6–2 11 years)

Method of assessment

Lateralization of the femoral head The lateralization of the femoral head in relation to the acetabulum is evaluated by measurements on anteroposterior radiographs to give the Migration Percentage (MP) (Figure 1)

The MP indicates how much of the femoral head extends beyond Perkins' line in percent

to the width of the entire head, the measurements being made with the hips in neutral abduction-adduction

To determine whether the MP can be used to indicate the prognosis, the MP was measured on radiographs which were taken at selected intervals from the presumed onset of the disease

Roundness of the femoral head As this investigation includes mature individuals, the often [illegible]

given as the percentage of the height of the head in relation to the maximum width of the head The height is measured at right angles to the width (Figure 2)

The Spherical Quotient (SphQ) indicates the ratio between the SphP of the diseased hip and the SphP of the noninvolved, contralateral femoral head

RESULTS

The data obtained are given in Table 1 The relationship between the MP values at various intervals after the onset of the disease and the corresponding SphQ values at follow-up are shown. At the half-year and 1 year

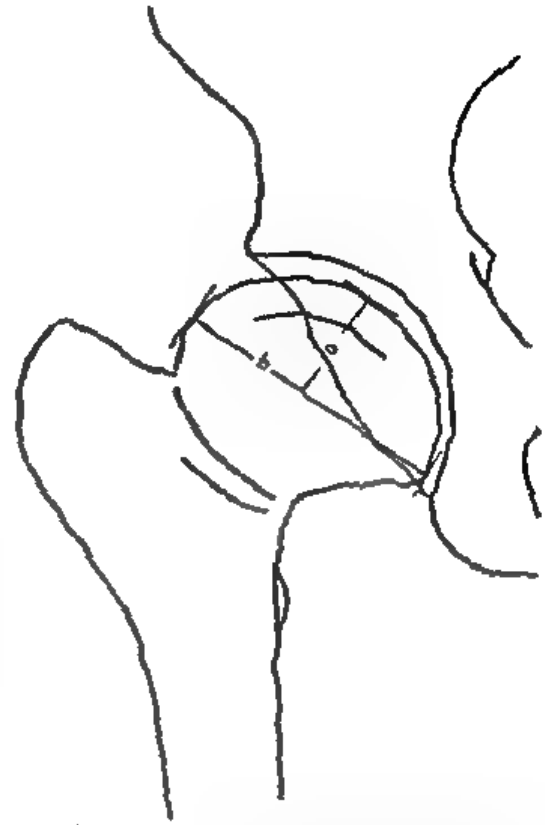

Figure 2 Spherical Percentage (SphP) and Quotient (SphQ) (b) indicates the maximum [illegible] (a) corresponds to the maximum height [illegible] ht angles to [illegible] cent SphQ [illegible] divided by the SphP of [illegible] contralateral femoral head × 100 per cent

Table 1 Data and results obtained at follow-up of 48 children with unilateral LCPD treated with strict bed-rest followed by Snyder's sling Age of onset was a median of 6 2 years

n	X rays		Time from onset (years)	Migration Percentage (MP) (per cent)	Spherical Quotient (SphQ) (per cent)	Correlation coefficient r, between MP and follow up SphQ	
48	primary	median range	0 5 0 1–1 6	12 0–34			
38	half year	median range	0 7 0 5–0 8	13 0–34		0 063	P>0 1
40	one year	median range	1 0 10–1 2	17 0–39		0 052	P>0 1
48	maximum MP	median range	1 8 0 7–4 1	26 5–48		−0 184	P>0 1
48	end of treatment	median range	2.5 1 2–4 1	22 5–43		−0 385	P<0 01
48	follow-up	median range	12 6 5 11–25 2		92 74–135		

examinations, only those hips were included for which a satisfactory radiograph was available around that time The only significant correlation found between the SphQ value at follow-up and the MP value was with the MP value at the end of treatment, $r=-0.385$, with $P<0.01$

DISCUSSION

The main aim of the present study was to examine whether there is a relationship between the MP during the course of the disease, and the SphQ at follow-up several years later. The investigation shows that there is no significant relationship between the MP values ½ year and 1 year after onset of the disease and the SphQ at follow-up, nor is there any relationship between the maximum lateralization of the femoral head and the SphQ at follow-up On the other hand, a slight but significant relationship exists between the MP at the end of treatment, a median period of 2.5 years after onset of the disease, and the SphQ at follow-up, a median period of 10 years later

In the same way, Snyder (1975) found no [illegible]lation between the percentage subluxa[illegible]on and the functional outcome of patients studied over an average period of 10.9 years.

These findings signify that the hypothesis of a containment principle in LCPD is probably in error They also signify that the relationship between the femoral head and the acetabulum, expressed as the MP ½ year and 1 year after onset of the disease, cannot be used as a prognosis, nor can it be taken on its own as an indication for operative reposition of the head.

Suramo et al (1974), by intraosseous venography, found obstruction in the venous flow in the initial and fragmentation stages of LCPD Puranen & Heikkinen (1976) found that an osteotomy, performed in the initial stages, improves venous circulation and accelerates the process of healing even to such an extent that the fragmentation stage possibly does not occur at all The results of the present investigation therefore cannot exclude the possibility that a femoral osteotomy may nevertheless exert a favourable effect, even though the effect is not due to improved containment of the head by the acetabulum

REFERENCES

Axer, A (1965) Subtrochanteric osteotomy in the treatment of Perthes' disease *J Bone J Surg* 47-B, 489–499

Axer, A., Schiller, M G, Segal, D, Rattelay [illegible] Gershuni-Gordon, D H (1973) Subtrochanteric osteotomy in the treatment of Legg-Calvé-Perthes' syndrome. *Acta orthop scand* 44, 31–54

Brotherton, B J & Mehibbin B (1977) Perthes' disease treated by prolonged recumbency and femoral head containment a long term appraisal *J Bone Jt Surg* 59 B 8–14

Canale, S T, D'anca, A F, Cotler, J M & Snedden, H E (1972) Innominate osteotomy in Legg-Calvé-Perthes' disease *J Bone J Surg* 54-A, 25–40

[illegible] of Perthes [illegible] *orthopaedics*, Ed Apley, A G [illegible] 122–147 Butterworths, London.

Fredensborg, N (1976) The results of early treatment of typical congenital dislocation of the hip in Malmo *J Bone Jt Surg* [illegible] 272–278

Larsen, E Hj & Reimann, I (1971) Calvé-Perthes' Disease With special reference to histological observations. *Acta orthop scand* 44, 426–438

Laurent, L E. (1973) Varus-rotation osteotomy in the treatment of Perthes' disease *Acta orthop scand* 44, 104–105

Lauritzen, J (1975) Legg-Calvé-Perthes' disease *Acta orthop scand*, Suppl 159

Lloyd Roberts, G C Catterall, A & Salvine, P B (1976) A controlled study of the indications for and the results of femoral osteotomy in Perthes' disease *J Bone Jt Surg* [illegible] 31–36

Puranen, J & Heikkinen, E. (1976) Intertrochanteric osteotomy in the treatment of Perthes' disease *Acta orthop scand* 47, 79 [illegible]

Salter, R B & Bell M (1968) The pathogenesis of deformity in Legg Perthes' disease experimental investigation. *J Bone Jt Surg* 50-B, 436.

Salter R B, Rang, M, Blackstone, I W, McArthur R C, Weighill, F J, Gygi, A C & Stulberg S D (1977) Perthes' disease the scientific basis of methods of management and their indications. *J Bone Jt Surg* 59-B, 127
der, Ch. R (1975) Legg-Perthes' disease in the young hip – does it necessarily do well *J Bone Jt Surg* 57-A, 751–759
Somerville, E W (1971) Perthes' disease of the hip *J Bone Jt Surg* 53-B, 639–649
Suramo, I, Puranen, J, Heikkinen, E & Vuorinen, P (1974) Disturbed pattern of venous drainage of the femoral neck in Perthes' disease *J Bone Jt Surg* 56-B, 448
Zweymuller, K & Wicke, B (1973) Zur Lateralisation des Oberschenkelkopfes beim M Perthes *Arch orthop Unfall-Chir* 75, 239–248

Correspondence to Jørgen Reimers, Granparken 173, 2800 Lyngby, Denmark

Acta orthop scand. 50 197–203, 1979

TOTAL HIP REPLACEMENT IN JUVENILE RHEUMATOID ARTHRITIS

Analysis of 59 Hips

JAMES COLVILLE & PAULI RAUNIO

Rheumatism Foundation Hospital, Heinola Finland

The results of 59 Charnley low friction arthroplasties in 41 patients with juvenile rheumatoid arthritis are presented Mean follow-up was 30 months and mean age at operation 30 5 years At review 90 per cent had an excellent result and 10 per cent a good result as regards pain relief Mobility was significantly improved in all but two patients. These two patients developed severe ectopic bone formation With few exceptions, the results remained constant after 6 months. Intraoperative complications were the most common. Careful selection of patients, advance planning of surgery and appreciation of the developmental abnormalities in these hips are essential features in avoiding complications and achieving a good result.

Key words arthroplasty, hip juvenile, rheumatoid arthritis

Accepted 16 IX.78

Rheumatoid arthritis affecting children in their growing years can lead to widespread multiple joint involvement. Large joints are most often attacked first in juvenile rheumatoid arthritis. Involvement of the hip joints in the earlier years may be responsible for valgus deformity of the femoral neck, persistent femoral anteversion, subluxation of the hip joint and dysplasia of both the acetabulum and upper femur Protrusio acetabulae may also occur at a later stage

Synovectomy of the hip joint has not been practised to any great extent and intertrochanteric osteotomy can only be expected to postpone for a short while the inevitable time when arthroplasty must be considered.

Various types of arthroplasty of the hip joint have been performed in the past but erratic or poor results have been reported (Aufranc 1964) Nevertheless, many young patients with juvenile rheumatoid arthritis sooner or later reach a clinical state when the severity of the pain combined with a lack of mobility make it difficult for the surgeon to withhold total prosthetic replacement

An additional factor to be considered is the overall prognosis in terms of survival Barkin (1952) reported a mortality of 20 per cent over 10 years and others (Ansell & Bywaters 1959, Ansell 1965 and Edstrom & Gedda 1957) have reported similar mortality rates.

There are very few reports in the literature dealing with total hip arthroplasty in patients with juvenile rheumatoid arthritis and hence we present here our experience of this operation and the follow-up results.

PATIENTS AND METHODS

During the years 1970–1975, 41 patients, diagnosed before the age of 15 years according to the criteria of the American Rheumatism Association (Ropes et al. 1956, 1958), as having definite rheumatoid arthritis, had 59 Charnley low fric-

0001 6470/79/020197–07$02.50/0

© 1979 Munksgaard, Copenhagen

Table 1 Age distribution at the time of surgery

Age in years at time of operation	Number of hips
<20	4
21–25	7
26–30	26
31–40	15
>40	7
Total	59

tion arthroplasties performed at the Rheumatism Foundation Hospital, Heinola, Finland. There were 35 females and 6 males, a female-male ratio of almost six to one. Eighteen patients had bilateral hip replacements. The age distribution at the time of surgery is shown in Table 1, the ages ranged from 18 to 47 years, with a mean of 30.5 years.

Duration of the systemic disease ranged from 11 to 40 years, mean 20.8 years, and the average age at onset of the disease was 9 years, range 2 to 15 years.

Follow-up period was from 1 year to 4.5 years, mean 2.5 years. One patient has not been seen after the 12-month postoperative review but when contacted by telephone she reported that she was mobile and free of pain. Pain, sufficiently severe to disturb the patient, combined with lack of mobility and a willingness on the part of the patient to co-operate fully, were the chief considerations in selecting patients for surgery.

All patients were receiving aspirin at the time of [illegible] and this was continued as part of the prophylactic regime against thromboembolic complications. Seventeen patients (30 per cent) were receiving steroids at time of surgery. Prophylactic antibiotics, beginning preoperatively, were given, penicillin being the drug of choice unless a proven sensitivity existed. All the operations were performed in a standard operating room, built in 1952, with no significant modifications since and no special measures such as ultra violet light or sterile air enclosures were used.

General anaesthetic was not used in 26 cases on account of rheumatoid involvement of the temporo-mandibular joints or cervical [illegible] these cases epidural anaesthesia was used.

Seven hips had been operated upon, one patient having had bilateral [illegible] the age of 9 years.

A standard lateral approach was [illegible] detachment of the greater trochanter. In many cases a psoas and adductor [illegible] were carried out. Re-attachment [illegible] in the earlier part of the series was [illegible] Charnley method and later by the [illegible] Ritter (1972).

In the early postoperative period [illegible] directed towards the prevention of thrombosis, by elevating the end of the bed, [illegible] elastic stockings, and encouraging the patient to move the lower limbs in bed. The drain was removed after 48 hours.

Beginning on the third postoperative day the patients were helped out of bed for a few steps, the length of the walk then being increased daily. Physiotherapy in the swimming pool was started when the wound had healed, usually about [illegible] days after surgery.

During the first 2 weeks, an abduction pillow was strapped between the legs while the patient was in bed.

RESULTS

Using the method of Merle d'Aubigné & Postel (1954) each hip was classified according to pain, mobility and function preoperatively and at each postoperative review, i.e. at 6 months, 1 year, 2 years and 4 years.

Using the above classification 46 hips (78 per cent) were in grades two, three or four and the remaining three hips in grade one preoperatively. Postoperatively 53 hips (90 per cent) were pain-free (grade six) and the remaining six hips (10 per cent) had pain only on beginning to walk (grade five).

Table 2 Range of movement—extension flexion

Movement in degrees	Number of hips (%) preoperatively		Number of hips (%) postoperatively	
<30°	22	37%	[illegible]	[illegible]
30°–60°	22	37%	[illegible]	[illegible]
>60°	15	26%	[illegible]	
Total	[illegible]		Total	[illegible]

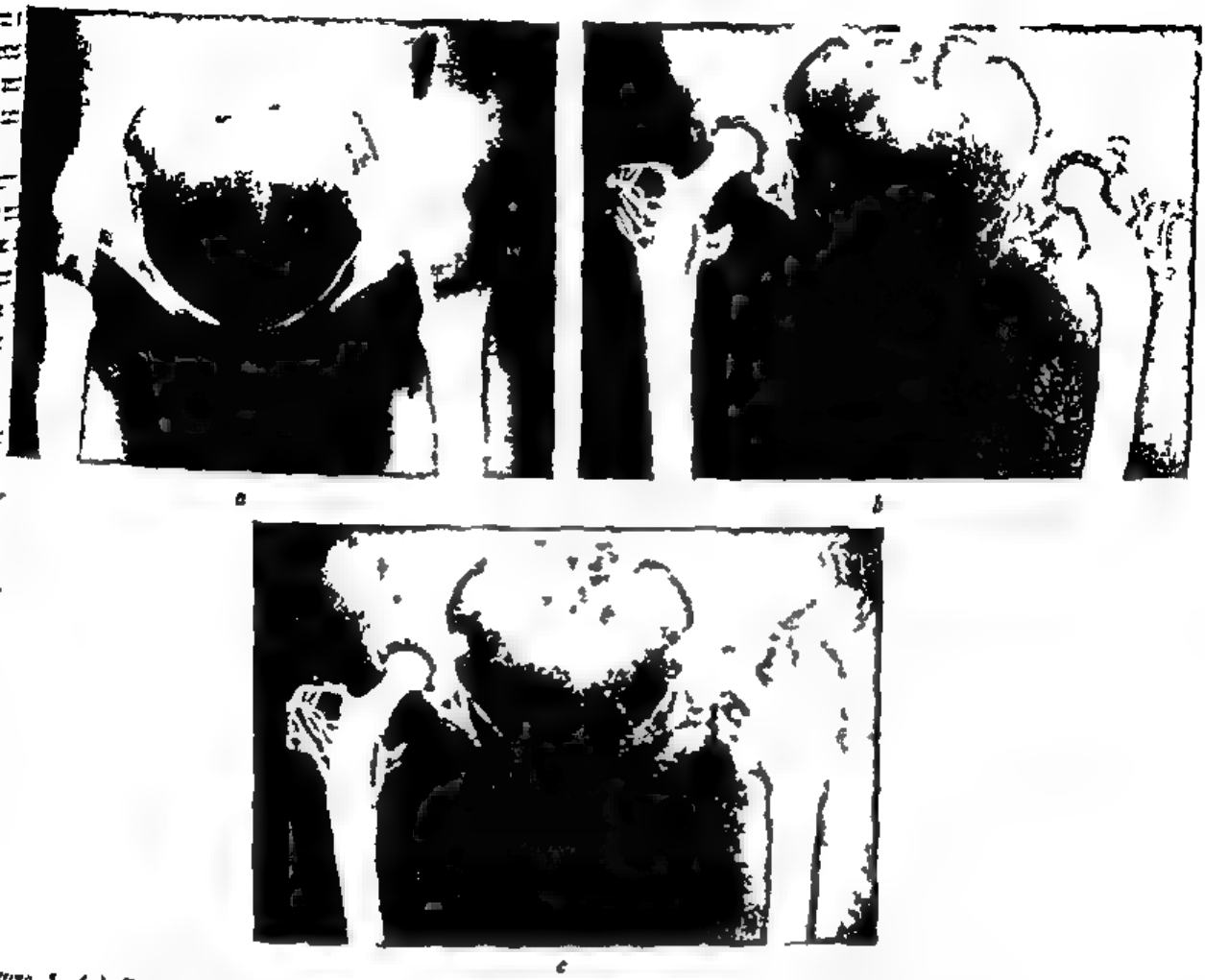

Figure 1 (a) Preoperative radiograph showing ankylosis of the right hip joint (b) Radiograph to show replacement of the right hip joint, 1 year after surgery (c) Radiograph showing severe ectopic bone formation around the right hip joint, 4 years after operation

Mobility, measured numerically as the composite range of three movements, extension flexion, adduction and rotation is graded one to six preoperatively and postoperatively

Preoperatively 15 hips (25 5 per cent) had less than 30 degrees of movement, 16 hips (27 per cent) had between 30 and 60 degrees and 19 hips (32 per cent) between 60 and 100 degrees. The remaining nine hips (15 per cent) had more than 100 degrees of movement. Postoperatively 42 hips (73 per cent) had greater than 160 degrees of movement, 14 (24 per cent) had between 100 and 160 degrees. One hip with ectopic bone formation has 60 degrees of movement and the other hip for the same reason is completely ankylosed and is classified as grade one

Twenty-two hips (37 per cent) had a preoperative range of movement, extension-flexion, less than 30 degrees (Table 2) and the same number of hips had a range of movement, extension flexion, of between 30 and 60 degrees The remaining 15 hips (26 per cent) had more than 60 degrees extension-flexion

Postoperatively only one patient had a range of movement extension-flexion, less than 40 degrees This patient (Figure 1, a,b,c) had a flexion contracture of 75 degrees preoperatively and an ankylosed hip Six months postoperatively 90 degrees of flexion was possible but over the next 2 years the range of flexion steadily decreased due to severe ectopic bone formation and the hip is again ankylosed Six hips (10 per cent) had a range of flexion at review of 60 degrees, but five of

Figure 2 (a) Preoperative radiograph (b) Radiograph, 2 years after bilateral hip replacement showing erforation of the medial femoral cortex bilaterally with new bone formation (c) Radiograph 3 years after bilateral hip replacement shows no significant change

them had less than 30 degrees extension-flexion preoperatively The remaining 52 (88 per cent) had a postoperative range of movement, extension-flexion, of more than 60 degrees. Thus overall only one patient, the one described above (Figure 1, a,b,c), did not obtain any lasting improvement in range of movement, extension-flexion.

In general and with few exceptions, the results obtained at 6 months remained unchanged

Flexion contracture preoperatively (Table 3) greater than 60 degrees was present in eight hips (13 5 per cent) and nine hips (15 per cent) had a flexion contracture between 30 and 60 degrees. The remaining 42 hips (71 per cent) had a flexion contracture between 0 and 30 degrees. Postoperatively a patient had a flexion contracture greater than 30 degrees, the only hip now ankylosed in a position of 20 degrees of flexion.

Complications

One patient, aged 37 years developed deep venous thrombosis requiring anticoagulation There were no wound healing problems or superficial wound infections and all patients had their sutures removed on the 14th postoperative day

There have been no deep infections in this series.

Intraoperative complications occurred, however, on three occasions, the femur

Table 3 Flexion contracture in degrees

Degrees	Number of hips preoperative (%)		Number of hips postoperative (%)	
<30	42	(71)	59	(100)
30–60	9	(15 5)		
>60	8	(13 5)		
Total	59		Total 59	

cortex being perforated by the tip of the prosthesis at time of insertion (Figure 2, a,b,c) Perforation of the acetabular floor occurred on two occasions also and two femoral components were placed in excessive varus

There were no dislocations, subluxations or intraoperative fractures

Postoperative ectopic calcification has developed (Figure 1c) to a severe degree in two patients. One patient, female aged 36 years, has no movement of the hip joint at all and the other, female aged 22 years, has only 60 degrees composite range of movement

DISCUSSION

Few reports deal with total hip replacement in juvenile rheumatoid arthritis Arden (1974), Halley & Charnley (1975) and Bisla et al (1976) have all reported series which include a number of rheumatoid patients less than 30 years old at the time of operation All patients in this series, however, developed rheumatoid arthritis while still in the growing years, resulting in growth deformities which caused problems at surgery

Selection of patients for total hip replacement is very difficult and it is not possible to give anything more than guide lines. The first and most important indication for total hip replacement is motivation on the part of the patient. Fortunately, in this age group, lack of motivation is seldom a problem Secondly, the general condition of the patient with respect to the systemic and local disease in other joints has to be considered, and a plan of treatment worked out. Thirdly, in the case of bilateral hip involvement, occasionally the contralateral hip can be left unoperated, even if stiff, provided it is in a good position. Many patients in this series required surgery of other lower limb joints soon after becoming more mobile on account of the improvement in the hip function following arthroplasty Therefore the possibility of multiple operations has to be considered at the outset

In this series, severe pain was seldom the sole indication for surgery, however, moderately severe pain (41 hips, 69 per cent in this series) combined with lack of mobility (50 hips, 85 per cent in this series) does indicate the need for surgery Those patients with a bed to chair existence or those who can walk only with support (31 hips, 52 per cent in this series) are in need of hip replacement even in the absence of severe pain Halley & Charnley (1975) pointed out that due to the built-in restraints in these patients, they expect 25 to 30 years of use before revision and replacement may be necessary If in doubt about the need to operate, then the pseudarthrosis test advocated by Halley & Charnley (1975) should provide the answer

The results for pain relief, 90 per cent excellent, 10 per cent good, in this series are comparable to the results of Halley & Charnley (1975) and Bisla et al. (1976)

In many cases the patient would consider this benefit alone justified the operation Mobility in our series was significantly improved with the exception of the two patients who developed severe ectopic bone formation.

The correction of flexion contracture is important especially when, as is often the case, other joints will require replacement

Although the overall measured improvement in mobility is not so noticeable as in adult rheumatoid arthritic patients with total hip replacement, it is sufficient to make most patients independent again Although many do not walk far, most are free from all external supports and a few have become employable The maintenance of the overall good results is particularly encouraging

Halley & Charnley (1975) and Bisla et al (1976) each report one case of infection in a comparable sized series, however, the numbers are small as in our series and therefore few conclusions can be drawn

Ectopic bone formation occurred in three hips in two patients in this series resulting in a poor result for one patient and a less than satisfactory result in the other Bisla et al (1976) found 14 cases in a series of 67 hips. We feel that this is more likely to occur in juvenile rather than adult rheumatoid arthritics and to be related to the degree of ankylosis and subsequent surgery

Operative complications proved to be the most troublesome but with experience we have learned to minimize them Depending upon the age at which the disease began, juvenile rheumatoid arthritic patients have a variable degree of hypoplasia of the aceta- [illegible] narrowing of the femoral medullary canal, and anteversion of the femoral neck. It was often difficult to prepare a good socket to suit even the smallest acetabular prosthesis and so custom made, smaller cups should be available

Fracture of the acetabular floor can only be avoided by gentle reaming or in some cases curetting instead of reaming

Failure to appreciate completely the narrowing of the upper femoral medullary canal led to perforation by the prosthesis on three occasions and though these patients are now trouble-free, two of them at 3 years postoperation and one at 2 years postoperation, they are nevertheless a potential source of trouble in the future A custom-made prosthesis should be made prior to surgery if it is doubtful that the straight narrow stem prosthesis will be adequate A Nippon type prosthesis is a suitable alternative. At operation if in doubt about perforation of the femur a lateral radiograph should be taken In all cases, both prosthetic sites should be prepared before fitting the acetabular component

Bisla et al (1976) from their experience with 26 rheumatoid arthritic patients recommend that the femoral prosthesis always be aligned in relation to the plane of the knee joint, which in some cases requires the prosthesis to be placed anteroposteriorly This view fails to appreciate the fact that the muscles acting on the hip joint will over the years, have adapted to the femoral anteversion and so stability is more likely to be achieved and maintained if both parts of the prosthesis are inserted in a position more closely resembling the joint being replaced In this series no attempt was made to correct the anteversion and at 30 months mean follow-up (range 1 to 4 5 years) there have been no dislocations or loosening

Positioning of the femoral component in excessive varus is an additional problem to be anticipated, both our cases were attributed to inadequate reaming of the femoral canal and so insertion of the prosthesis in a normal position was not possible

Conclusions

Hip replacement in juvenile rheumatoid arthritic patients can be rewarding if great care is taken in selection of patients and their enthusiastic co-operation is obtained.

Surgery must be planned well in advance and a full range of prostheses made available In certain cases custom-made prostheses are essential.

At operation, hypoplasia of the femur and excessive anteversion of the femoral neck must be appreciated.

Operative complications are avoidable and general complications in young patients even with rheumatoid arthritis, should be few Hence a good result for pain relief can be mobility and independence can be anticipated.

REFERENCES

sell B M. (1965) Still s disease *Progress in clinical rheumatology*, Ed Dixon, A St. J p 95 J A. Churchill, London

sell, B H & Bywaters, E (1959) Prognosis in Still s disease *Bull Rheum Dis* 9, 189–192

den, G P (1974) Total hip replacement in juvenile chronic polyarthritis and ankylosing spondylitis. *Orthop Digest* Dec., 14–22.

franc, O E (1964) Surgery of the hip in rheumatoid arthritis and osteoarthritis. *Bull Rheum Dis* 14, 335–338

rkin, R E. (1952) Juvenile rheumatoid arthritis, a long term follow up *Ann. Rheum Dis* 2, 316–317

sla, R. S, Inglis A E & Ranawat, C S (1976) Joint replacement surgery in patients under thirty *J Bone Jt Surg* 59-A, 1098–1104

Aubigne R M & Postel, M (1954) Functional results of hip arthroplasty with acrylic prosthesis. *J Bone Jt Surg* 36-A 451–475

Edström, G & Gedda, P O (1957) Clinical prognosis of rheumatoid arthritis in children *Acta rheum scand* 3, 129–153

Ritter, M A (1972) Transposition of the greater trochanter A new method of attachment *J Bone Jt Surg* 54-A, 179–180

Ropes, M W, Bennet, G, Cobb, S., Jacox, R & Jessar, R A. (1956) Proposed diagnostic criteria for rheumatoid arthritis. *Bull Rheum Dis* 7, 121–124

Ropes, M W., Bennet G, Cobb, S, Jacox, R. & [illegible] diagnostic [illegible] *Rheum*

orrespondence to James Colville, Cappagh Orthopaedic Hospital Cappagh, Finglas Dublin 11, eland.

Although the overall measured improvement in mobility is not so noticeable as in adult rheumatoid arthritic patients with total hip replacement, it is sufficient to make most patients independent again Although many do not walk far, most are free from all external supports and a few have become employable. The maintenance of the overall good results is particularly encouraging

Halley & Charnley (1975) and Bisla et al (1976) each report one case of infection in a comparable sized series, however, the numbers are small as in our series and therefore few conclusions can be drawn.

Ectopic bone formation occurred in three hips in two patients in this series resulting in a poor result for one patient and a less than satisfactory result in the other Bisla et al (1976) found 14 cases in a series of 67 hips. We feel that this is more likely to occur in juvenile rather than adult rheumatoid arthritics and to be related to the degree of ankylosis and subsequent surgery

Operative complications proved to be the most troublesome but with experience we have learned to minimize them Depending upon the age at which the disease began juvenile rheumatoid arthritic patients have a variable degree of hypoplasia of the acetabulum, narrowing of the femoral medullary canal, and anteversion of the femoral neck It was often difficult to prepare a good socket to suit even the smallest acetabular prosthesis and so custom made smaller cups should be available

Fracture of the acetabular floor can only be avoided by gentle reaming or in some cases curetting instead of reaming

Failure to appreciate completely the narrowing of the upper femoral medullary canal led to perforation by the prosthesis on three occasions and though these patients are now trouble-free, two of them at 3 years postoperation and one at 2 years postoperation, they are nevertheless a potential source of trouble in the future A custom made prosthesis should be made prior to surgery if it is doubtful that the straight narrow stem prosthesis will be adequate A Nippon type prosthesis is a suitable alternative At operation in doubt about perforation of the femur lateral radiograph should be taken. In cases, both prosthetic sites should be prepared before fitting the acetabular component

Bisla et al (1976) from their experience with 26 rheumatoid arthritic patients recommend that the femoral prosthesis always be aligned in relation to the plane the knee joint, which in some cases requires the prosthesis to be placed anteroposteriorly This view fails to appreciate the fact that muscles acting on the hip joint will, over years, have adapted to the femoral anteversion and so stability is more likely to achieved and maintained if both parts of prosthesis are inserted in a position closely resembling the joint being replaced this series no attempt was made to correct the anteversion and at 30 months mean follow-up (range 1 to 4 5 years) there has been no dislocations or loosening

Positioning of the femoral component excessive varus is an additional problem to anticipated, both our cases were attributed inadequate reaming of the femoral canal so insertion of the prosthesis in a neutral position was not possible

Conclusions

Hip replacement in juvenile rheumatoid arthritic patients can be rewarding if proper care is taken in selection of patients and the enthusiastic co-operation is obtained.

Surgery must be planned well in advance and a full range of prostheses made available In certain cases custom-made prostheses are essential.

At operation, hypoplasia of the proximal femur excessive anteversion of the femoral neck must be appreciated.

Operative complications are avoidable and *general complications* in young patients with rheumatoid arthritis should be few Hence a good result for pain relief, mobility and independence can be anticipated.

TOTAL HIP REPLACEMENT WITH A TRUNNION BEARING PROSTHESIS

Biomechanical Principles and Preliminary Clinical Results

IAN F GOLDIE & CHRISTINA RANER

Department of Orthopaedic Surgery II, Sahlgren Hospital University of Goteborg
Goteborg Sweden

The biomechanics are presented of a bushing principle forming [illegible] for a trunnion bearing prosthesis in total hip replacement The stem is equipped with a trunnion on to which a cylindrical plastic [illegible] applied On top of this a metal casing is placed which forms the femoral head On flexion-extension this remains stationary in the acetabulum and motion occurs between the trunnion and the cylindrical sleeve Friction between head and cup is reduced to a minimum decreasing the risk of loosening

A follow-up study of 61 hips replaced by the trunnion bearing prosthesis was performed 2.5 years postoperatively Eighty-eight per cent were considerably improved. There was one deep infection and two femoral stem loosenings.

Key words bushing principle, diminished friction, loosening, total hip replacement, trunnion bearing prosthesis

Accepted 12.IX.78

At present some 1000 total hip replacements are carried out daily in the Western world (Bloch 1976, personal communication). In Great Britain with 58 million inhabitants about 30 000 hips are replaced per year (Lancet 1976) and in Sweden with 8 million inhabitants there are about 3000 hip replacements annually (Herberts 1978, personal communication).

The results are good and Eftekhar & Stinchfield (1973), reporting a series of 700 operated hips, found that 70 per cent were still completely free of pain 4 years after the operation. Charnley (1970, 1975) reported freedom of pain in 96 per cent in a 5-year study and after 15 years there was a successful result in 79 out of 90 patients who were still alive (Charnley 1978).

In 1976 at the 26th North West German Orthopaedic Congress no less than 36 of the papers presented were about complications after total hip replacement and the most common were dislocation of the prosthesis, infection, loosening, fracture of the prosthesis, the cement or bone, allergic reactions and complications arising from the surrounding soft tissue In all, 10–15 per cent of all total hip replacements are marred by complications (Lancet 1976)

Besides infection, loosening is a dreaded complication and the variety of designs of total hip prostheses available reflects the

0301-4470/79/020205-12$02.50/0

© 1979 Wright, Copyright

Figure 1 A Christiansen's trunnion bearing prosthesis Femoral component Trunnion at proximal end forms an angle of 115° with axis of the stem Inset cylindrical sleeve to be passed on to the trunnion

Figure 1 B Spherical casings in metal to be placed on the trunnion. Varying neck length: top 5 mm, middle 10 mm bottom 15 mm

desire to construct a prosthesis which will be least hampered by complications. In 1969 a new prosthetic system was introduced for total replacement of the diseased hip joint (Christiansen 1969). The system is based on a trunnion bearing principle with the object of diminishing friction between the articulating surfaces. Since its introduction more than 2500 patients operated in Scandinavian hospitals have been fitted with the prosthesis. Christiansen (1977, personal communication) has treated about 250 patients, the longest observation time being 7 years and the shortest 2 years. Using the Love/Charnley class [illegible] for evaluation of results, Christiansen found, in his external [illegible]

re 1 C Acetabular cup made of Delrin
rnal diameter 37 mm External diameters 47
31 mm

r cent excellent and 33 per cent good
sults, in other words satisfactory results in
0 per cent. In all, there were 21 com-
lications, i e. almost 10 per cent There was
nfection in six cases, loosening in seven, dis-
location in two, perforation into the pelvis in
two and heterotopic ossification in four

So far, no further reports of this new device have been published and in this presentation a preliminary clinical follow-up study is reported and the biomechanical principles of the design are described and partly analysed This forms the first of a series of reports which include an analysis of the movements of the various components of the prosthetic system, a strain gauge registration of the forces acting on the trunnion *in vitro* and *in vivo*, and finally—a continuous, long-term registration of a base material, the first presentation of which is published in this

DESIGN

Femoral component

The *prosthetic stem* is slightly curved in varus. In the transverse plane it has a rectangular form, the medial border of which is slightly curved The length of the stem is either 130, 160 or 260 mm. The proximal end of the prosthesis carries a trunnion, the axis of which forms an angle of 115° with the long axis of the stem (Figure 1 A)

Figure 1 D Trunnion bearing prosthesis assembled and ready for insertion into the femoral shaft

The *prosthetic head* is designed according to a bushing principle Thus, a cylindrical sleeve is slipped on to the trunnion The sleeve is made of polyacetal (Delrin) On to this sleeve a casing is passed in the shape of a sphere with a neck of varying length and this completes the prosthetic head The casing is either of stainless steel or vitallium and the neck can vary in length from 5 to 15 mm (Figure 1 B). The diameter of the head is 37 mm.

Acetabular component

The cup is made of polyacetal (Delrin) and has two external sizes 47 and 51 mm, respectively

Figure 1 A Christiansen's trunnion bearing prosthesis Femoral component Trunnion at proximal end forms an angle of 115° with axis of the stem Inset cylindrical sleeve to be passed on to the trunnion

Figure 1 B Spherical casings in metal to b placed on the trunnion. Varying neck lengths to 5 mm, middle 10 mm, bottom 15 mm.

desire to construct a prosthesis which will be least hampered by complications. In 1969 a new prosthetic system was introduced for total replacement of the diseased hip joint (Christiansen 1969) The system is based on a trunnion bearing principle with the object of diminishing friction between the articulating surfaces. Since its introduction more than 2500 patients operated in Scandinavia hospitals have been fitted with this pro thesis. Christiansen (1977, personal com munication) has treated about 250 patient the longest observation time being 7 yea and the shortest 2 years. Using th Love/Charnley classification for evaluation results, Christiansen found, in his material, 5

gure 4 Right hip after total hip replacement with trunnion bearing prosthesis seen from a posterior
Tob
isk mdi
ion of ti
load

The internal diameter for both ■ 37 mm (Figure 1 C).

When assembled the prosthetic system appears ■ Figure 1 D

Delrin

Delrin is produced by the polymerization of formaldehyde It is a polyacetal homopolymer and chemically known as polyoxymethylene or polyformaldehyde It resists organic solvents, weak acids, bases and inorganic salts, e g ■ per cent solution of sodium chloride

Delrin resists elevated temperatures and it has

regarded as a dermatitis hazard

Delrin has higher tensile strength higher yield strength greater hardness and higher resistance than ultrahigh molecular weight polyethylene The hardness of Delrin is equal to that of polymethylmethacrylate The biocompatibility of Delrin is tolerable (Dumbleton 1977 personal communication)

Rationale for trunnion bearing prosthesis

In osteoarthrosis of the hip joint and in avascular necrosis of the femoral head replacement by the Austin-Moore prosthesis can be performed (Sarmiento 1973 Andersson & Moller Nielsen 1972). Migration of the prosthesis may occur with penetration through the acetabulum into the pelvis (Perkins 1961). This is caused by the friction which is generated by repeated movements between the metal head and the bone structures. In total hip replacement there is also friction causing wear of the acetabular cup which may jeopardize the results as the prosthesis may loosen (Charnley & Cupic 1973).

The object of the trunnion bearing prosthesis is to diminish the friction between the metal femoral head and the plastic acetabular cup This is achieved by decreasing the movement between these components during loaded flexion and extension as occurs in for example walking The bushing principle implies that the movements occur in the trunnion bearing system with the plastic sleeve rotating around the trunnion leaving the head stationary in the acetabular cup There will thus be less wear and tear between the head and the acetabuum and the risk of wear in the acetabular cup is reduced to a minimum.

The background for this assumption is the biomechanics which develop in the Pauwels Type III fracture (Pauwels 1976) in which the fracture line is between 70 and 90° i.e almost a vertical fracture line. A stable internal fixation is counteracted by the shear forces which cause locking of the femoral head while the femoral shaft is free to move. With the axis of the trunnion bearing prosthesis designed at 115° the biomechanics simulates those of the Pauwels Type III fracture and thus the prosthetic femoral head should remain stationary in the acetabular cup on loaded flexion and extension

Indications to support the assumption of movements of the cylindrical sleeve in relation to the trunnion

Investigation by cineradiography Difficulties arise in demonstrating the movements actually taking place between the trunnion and the cylindrical sleeve whilst the metal casing (the head) remains stationary in the acetabular cup

In an attempt to analyse the movements between the individual prosthetic components metal markers were inserted in the cylindrical sleeve at the edge bordering on the femoral stem The neck of the metal casing (the head) was shortened so that the markers could be demonstrated at radiography (Figure 2). The specially prepared prosthesis was operated into patient One year following surgery cineradiographic registration of the movements of the prosthetic system was made during loaded flexion and extension as in walking It could then be demonstrated that the metal markers rotate around the trunnion This was interpreted as movement of the cylindrical sleeve around the trunnion but conclusive evidence could not be obtained by this examination that the metal ha

Figure 5 Guide for insertion of femoral stem in trunnion bearing prosthesis Bar to be held parallel with the lower leg which is at 90° to the floor Correct positioning of the femoral component can be expected.

remained stationary in the acetabular cup (Figure 3 A, B and C) The patient into whom this specially prepared prosthesis had been fitted has done very well he has suffered no pain and has had no loss of function

Observations at operation To obtain further information as to whether the metal head remains stationary in the cup on loaded flexion and extension, tests of the prosthesis were carried out at operation. Once the prosthesis was inserted, the hip joint was flexed and extended and it then became evident that on *unloaded* flexion and extension there was movement of the metal head in the acetabular cup On *loaded* flexion and extension the head remained in the same position with the movement taking place between the trunnion and the cylindrical sleeve (Figure 4 A and B).

Load distribution

The diameter of the head is chosen so as to cause a satisfactory balance between friction and loading per unit area of the prosthetic head which will diminish the effects of torque (Christiansen 1977). An increase in this may cause a loosening of the prosthesis With the transfer of movements from the head and acetabulum to the trunnion and surrounding cylinder there is a redistribution of the load This is believed to become linear instead of point limited as is the case in the conventional sphere prosthesis. This is supposed to lead to a longer life span for the trunnion bearing the cylinder, the metal casing and the acetabular cup

We are testing the above theory in practice The results, however, are as yet not finalized for presentation

CLINICAL STUDY

Material

In this particular study the trunnion bearing prosthesis has been used since 1975 (However, other prostheses, such as Brunswick, Charnley and McKee-Arden, have also been used.) In all, 78 patients have been operated on However, as a minimum time for follow-up was set at 6 months, 22 patients (22 hips) who did not fulfil this time requirement were not included in this study Therefore 56 patients (61 hips) remained for the follow-up (Table 1)

Sex and age are presented in Tables 2 and 3 The age distribution corresponds to that which is commonly found in similar series reported in the literature, i e a majority between 60 and 80 years

Table 1 Number of patients/hips and of operation for trunnion bearing total hip replacement

61 hips in 56 patients Year of operation	[illegible]
1975	9/9
1976	20/20
1977	27/29

Table 2 Sex distribution of patients treated with trunnion bearing total hip replacement

	Women	Men
Hips	38	23
Patients	35	21

Table 3 Age at operation of patients treated with trunnion bearing total hip replacement (61 hips)

Age at operation	No of hips	Women	Men
<60	15	9	6
60–69	28	20	8
70–79	17	8	9
>80	1	1	

Operative technique

All patients were operated on by one of the authors (I G) and a posterior approach was used The recommendations of Christiansen were followed (Christiansen 1977, personal communication) One detail worth mentioning is the guide (Figure 5) for the insertion of the femoral prosthesis. The guide is equipped with a bar and passed on to the trunnion The bar is placed parallel to the lower leg which is at 90° to the floor In this way the femoral prosthesis is placed in the correct anteversion position

Follow-up A follow-up was carried out in February 1978 by one of the team not acquainted with the patients pre- or postoperatively (C.R). Of the 56 patients one had died, thus leaving 60 hips

in 55 patients to be followed up Two patients refused to participate but enough information could be obtained by telephone interview to make evaluation of the results possible Thus 58 hips could be evaluated by personal examination The follow-up time varied from 6 months to more than 3 years, for a majority of the patients it was just over 2 years (Table 4).

Table 4 Length of follow-up in 55 patients (60 hips) treated with trunnion bearing total hip replacement

Follow-up time (years)	No of hips
<1	15
1–2	32
2–3	11
>3	2

RESULTS

Pain

The results as rated by the numerical of Merle d'Aubigné & Postel (1954) presented in Tables 5 and 6 For the total material there was complete freedom of pain in 50 per cent and a considerable decrease in pain in 20 per cent, thus giving satisfactory results as regards pain in 70 per cent There were eight patients who suffered some pain only after a certain amount of activity and who became pain free after rest These patients belonged to the osteoarthrosis group and will be discussed below There were two patients who still had severe spontaneous pain, one of whom belonged to the osteoarthrosis group and the other to the rheumatoid arthritis group The reason for the persistent pain could not be explained clinically On objective examination the range of motion was good and radiography did not disclose any abnormalities.

As for the osteoarthrosis group, complete freedom of pain occurred in 53 per cent and a considerable decrease in 22 per cent, thus giving a satisfactory result in 75 per cent In this group there were eight patients who suffered pain only after some activity with disappearance of pain at rest These patients were rated 4 in the rating system as it was difficult to give them a place which corresponded to their condition. They did not complain as much of pain as of a discomfort which they had difficulty in describing Despite this they were all pleased with the result of the operation They all had a positive Trendelenburg's sign and also used a cane when walking for longer distances No cane was used on walking shorter distances and the reason for using a cane was simply a matter of security

As for the rheumatoid arthritis group this was very small but still the results were quite rewarding as no pain was experienced in 75 per cent

The average grade for pain in the total group was 5 1 points, in the OA group 5.2 points and in the RA group 4 7 points.

Walking

Of the total group 10 per cent walked without a cane Fifty-six per cent had limited walking capacity without a cane and 25 per cent could walk long distances with one cane. Looking at the individual groups 8 per cent of the OA group walked normally and this applied to 1 6 per cent of the RA group. Quite a number of patients (total 34) in both groups could walk without a cane but had a limp The general impression was a decided satisfaction with the improvement achieved by the operation (Table 6).

Range of motion

The total motion is registered in Table 7 and the movement is expressed as the sum of degrees of movement in all three standard directions. On the whole the movement reached a total of 165°

Table 5 Registration of pain at follow-up in 60 hips operated with trunnion bearing total hip replacement

Pain	Points	Number of hips total	osteo-arthrosis	rheumatoid arthritis
Severe Spontaneous	1	2	1	1
Severe on attempting to walk, prevents all activity	2	–	–	–
Pain tolerable permitting limited activity	3	5	2	3
Pain only after some activity disappears quickly with rest	4	8	8	–
Slight or intermittent pain on starting to walk, diminishing with normal activity	5	12	11	1
No pain	6	33	26	7
Total		60	48	12

endelenburg's sign

Trendelenburg's sign was positive in 49 n which may explain the high number of ips registered It should be mentioned, wever, that very little pain accompanied limp The reason for limping is difficult to rify but speculations have been made arding preoperative muscle weakness due pain and limited function in the diseased nt, and it has also been suggested that the sterior approach may have some influence

omplications

The complications registered were in ctions (superficial and deep) throm- embolism, dislocations, ectopic bone rmation and loosening The infections are esented in Table 8, there were six perficial infections and one deep

Prophylactic antibiotics were administered during the operation and for 7 days following the operation (day of operation 3 g cloxacillin in 500 ml invertos during 6 hours and a repeated dose during the following 6 hours, 0 5 g dicloxacillin for 7 days postoperatively) As soon as a discharge was noted in the wound, cultures were taken The six hips with superficial infection healed within the period of administration of prophylactic antibiotics and no supplementary treatment was given

The one instance of deep infection probably occurred as a result of metastatic infection, 1 year previously the opposite hip had been operated on for a pertrochanteric fracture and at this time an infection developed The infection in the hip joint replaced with a trunnion bearing prosthesis appeared on the third day after operation The antibiotic treatment was therefore pro-

Table 6 Walking ability at follow up of 55 patients (60 hips) treated with trunnion bearing total hip replacement

Walking	Points	Number of hips total	osteo-arthrosis	rheumatoid arthritis
Bedridden or can walk a few yards. Two sticks or crutches	1	–	–	–
Time and distance very limited with or without sticks	2	3	1	2
Limited with one stick (less than 1 hour) Difficult without stick Able to stand long periods	3	2	2	–
Long distances with one stick Limited without a stick	4	15	13	2
No stick but a limp	5	34	28	6
Normal	6	6	4	2
Total		60	48	12

Table 7 Total range of movement in 58 hips treated with trunnion bearing total hip replacement

Total range of movement	Points	Number of hips
0– 30	1	–
30– 60	2	–
60–100	3	1
100–160	4	25
160–210	5	27
210	6	5
Mean value points	5 1	

longed There was complete healing and 6 months after the operation the patient was completely free of pain (Grade 6) and had no radiologic signs of loosening

In Table 9 the remaining complications are recorded The thromboembolism did not lead to any serious complications. The early dislocation occurred on the 14th day after operation the reason being unknown. A clo reduction could be performed with difficulty and no further complicati occurred. The late dislocation occurred so months after the operation and this pati has dislocated no less than three times.

Ectopic bone formation occurred in 11 hi but without clinical significance as neith pain walking ability or range of motion we influenced by this development.

Loosening occurred in two femoral stem and these patients are candidates for r operation At the time of follow up th loosening did not appear to be infectious origin

There were no further complications suc as penetration of the femur or acetabulum n nerve injuries or allergic reactions

Thus, there were serious complications i four cases, i e 6 5 per cent, and compl cation of a minor significance occurred in 12 hips i e 20 per cent

Table 8 Infections in 61 hips treated with trunnion bearing total hip replacement

Type	Number	Bacteria	Remarks
Superficial	6	Staph. epidermidis *Enterobacts* Proteus Pseudomonas	Healed within period of *administration of* prophylactic antibiotics No supplementary treatment No influence on result
Deep	1	Staph aureus *Pseudomonas*	Complete healing After 6 months rated as Grade 6

Table 9 Further complications in 61 hips treated with trunnion bearing total hip replacement

Type	Number
Thromboembolism	5
Dislocations—early	1
late	1
Ectopic bone formation	11
Loosening—Femoral prosthesis	2

DISCUSSION

The bushing principle as employed in the trunnion bearing prosthesis is an attempt to diminish friction between the articulating surfaces Friction is assumed to have a serious effect on the properties of the articulating surfaces on the bonding of the prosthesis to cement and in turn to bone The small sized femoral head (22 mm) of the Charnley prosthesis was especially designed in this way to diminish friction Even so Charnley claimed that wear of the acetabular cup must be accepted and calculated that 0 1–0 3 mm surface wear per year could be expected in the acetabular cup Furthermore, the results as reported by Charnley (1978) have confirmed that a certain amount of wear of the cup cannot be avoided but clinically this does not appear to have any serious consequences. The loosenings reported were due to a greater extent to faulty operative technique the cup was placed too deeply into cancellous bone and too high instead of more medially

In a series of laboratory tests on cadaver hips Andersson et al (1972) were able to show that the effect of friction on the attachment of the cup to the bone did not exceed that of the loading necessary to break this attachment Their conclusion was that mechanical factors could not be held responsible for loosening but rather it could be attributed to septic, thermal or inflammatory factors

Contrary to this Simon et al (1975) demonstrated that friction in total hip replacement was forty times greater than that of a normal hip On further analysis they found that the friction which is generated on initiating a movement, so called stiction-friction far exceeds that of the dynamic friction which occurs during, for example, walking They therefore concluded that loosening was more an effect of the initiation of movement than of continuous movement.

In view of this the bushing principle appears as an attractive alternative to the conventional ball and socket joint principles. With the femoral head stationary in the acetabular cup on loaded flexion and extension, friction should be reduced to a minimum In the present investigation some indications have been presented to support the concept of the metal head remaining stationary with the movement taking place between the trunnion and the cylindrical sleeve It remains, however, to be proved that this actually occurs in daily walking

It cannot be excluded that mechanical factors such as friction can cause loosening In 1975 Dandy & Theodorou reported 1 042 total hip replacements with the McKee-Farrar prosthesis. After 2 years, loosening occurred in 113 hips (9 2 per cent). In 83 of these mechanical factors were the obvious cause

In other reports loosening has occurred between 2 to 3 years postoperatively in 9–11 per cent but in some of these infection cannot be excluded (Amstutz 1970 Pattersson & Selby Brown 1972, Wilson & Scales 1970 Lazansky 1973, Nolan et al 1975)

In this investigation the mean follow up time has been 2 3 years and two femoral stem loosenings have been recorded (3 3 per cent) So far there have been no signs of cup loosenings. A cautious assumption may be made that the bushing principle causes less friction and thus lessens the risk of loosening

REFERENCES

Amstutz H C (1970) Complications of total hip replacement. *Clin Orthop* 72, 123–137

Anderson G B J., Freeman M A R & Swanson S A V (1972) Loosening of the cemented acetabular cup in total hip replacement. *J Bone Jt Surg* 54 B 590 599

nderson G B J & Müller Nielsen J (1972) J Moore s arthroplasty results after 8 years. *Acta orthop scand* 43, 397 410

Charnley J (1970) *Acrylic cement in orthopaedic surgery* E & S Livingstone Edinburgh and London

Charnley J & Cupic Z (1973) The nine and ten year results of the low friction arthroplasty of the hip *Clin Orthop* 95, 9 22.

Charnley J (1975) Fracture of a femoral prosthesis in total h p replacement *Clin Orthop* 111, 105–120

Charnley J & Weber S (1975) A radiological study of fractures of acrylic cement in rela on to the stem of a femoral head prosthesis *Bone Jt Surg* 57 B 297–301

Charnley J (1978) Late results of total replacement—12 to 15 years. 8th Course Operative Treatment of Osteoarthrit s of Hip Joint. Bern April 3–6, A-O Documentatio

Christiansen, C. H T (1969) A new hip p thesis with trunnion bearing *Acta chir* 135, 43–46

d Aubigné R M & Postal M (1954) Functi results of hip arthroplasty with acrylic p thesis. *J Bone Jt Surg* 36-A, 451–473

Dandy D J & Theodorou B C. (1975) management of local compl cations of total replacement by the McKee-Farrar techni *J Bone Jt Surg* 57 B 30 35

Ffrekhar N S & Stinchfield, E. (1973) T replacement of the hip joint by low fric arthroplasty *Orthop Clin N Amer* 483–501

Lancet (1976) Editorial, 31 1 pp 234–235

Lazansky M G (1973) Complications revis The debit s de of total h p replacement C *Orthop* 95, 96–103

Nolan D R Fitzgerald R., Beckenbaugh, R [illegible]

Pat [illegible] McKee-Farrar total hip replacement. *J B Jt Surg* 54 A 257–273

Pauwels, F (1976) *Biomechanics of the nor* [illegible] Springer Verlag [illegible]

Per [illegible]

Sa [illegible] Washington.

Simon S Paul J Roos, E & Radin, E. (19 Stiction friction of total h p prosthesis and relationship to loosening *J Bone Jt Su* 57 A 226–230

Wilson J A E Scales J T (1970) Loosening the total h p prosthesis w th cement fixatio *Clin Orthop* 72, 145–160

Correspondence to Ian F Goldie Department of Orthopaed c Surgery II Sahlgren Hosp tal Uni sity of Goteborg Goteborg Sweden

Acta orthop scand. 50, 217–223, 1979

217-2

ANATOMICAL BASIS OF VARIABILITY IN INJURIES OF T MEDIAL MALLEOLUS AND THE DELTOID LIGAMENT

I Anatomical Studies

ARSEN M. PANKOVICH & MYSORE S. SHIVARAM

Division of Orthopedic Surgery, Cook County Hospital and Hektoen Institute for Medical Research, Chicago, Illinois, USA

An anatomical study of the medial malleolus and the deltoid ligament of the ankle on fresh and formalin preserved legs of cadavera and amputation specimens has been carried out

The anterior and posterior colliculi, and the intercollicular groove of the medial malleolus were described The deltoid ligament was found to have two layers the superficial, attached primarily to the anterior colliculus, consisted of the naviculotibial, calcaneotibial, and superficial talotibial ligaments, the deep layer consisted of the deep anterior and posterior talotibial ligaments and was attached primarily to the posterior colliculus and the intercollicular groove These findings are at variance with previous descriptions of the deltoid ligament

Key words ankle anatomy, deltoid ligament, medial malleolus

Accepted 5 x 78

; has been established that only section or ıpture of the deep portion of the deltoid gament allows for a significant displacement f the talus (Close 1956, Grath 1960) The ıle, if any, of the superficial portion of the eltoid ligament in a normal ankle or in an ıjury of the ankle is not clear from the terature Furthermore, the morphology of m medial malleolus and its colliculi has not een previously described in detail, and in articular the relationship to the various parts the deltoid ligament Finally, it is generally ssumed that in order for the talus to be ısplaced and rotated laterally, either the eltoid ligament must first rupture, or instead fracture of the medial malleolus must occur h existence of concurrent injuries of the edial malleolus and the deltoid ligament ıus appear impossible, and yet such cases ıve been presented in the literature (Close 1956, Burwell & Charnley 1965, Mendelsohn 1965, Solonen & Lauttamus 1965, Coonrad 1970), although never clearly described nor their mechanism of injury explained

Therefore the aim of this investigation was 1) to make a detailed study of the morphology of the medial malleolus and the deltoid ligament, and their spacial relationship, and 2) to apply the findings of the anatomical studies to actual cases, in order to gain further understanding of variations of injuries of the deltoid ligament and the medial malleolus This latter part of the study will be reported separately

MATERIAL AND METHODS

A total of 16 specimens were available for dissection Each specimen consisted of the entire

01-6470/79/020217-07$02.50.0

© 1979 Mu

amputated just below the knee joint Ten specimens were fresh two were obtained following above-knee amputations for lesions in the femur and eight at autopsy These specimens were kept frozen, and were thawed for 12 hours before dissection Four specimens were preserved in formalin

All specimens were carefully dissected and all structures photographed The relationships of the deltoid ligament and the overlying and surrounding structures were recorded Particular care was exercised in dissecting the tendon sheaths overlying the deltoid ligament In order to demonstrate the articular side of the deep deltoid ligament, all tendons and ligaments along the fibula as well as the joint capsule were sectioned and the tibia and fibula tilted medially Each ligament was carefully dissected and its bony attachments and relations to the adjoining structures were recorded and photographed.

PREVIOUS DESCRIPTIONS OF THE DELTOID LIGAMENT

Essentially five different descriptions were found in the literature

1 Bonnin (1950) and Dziob (1956) considered the deltoid ligament to be a single layer ligament consisting of three parts the anterior and posterior talotibial, and the caneotibial ligaments. Dziob stated that deltoid ligament originates from the entire border of the medial malleolus and inserts into the anterior side of the talus, the sustentaculum tali, and the medial tubercle of the talus.

2. Toldt (1921) and Grath (1960) (citing Rauber-Kopsch's Textbook of Anatomy, 1932 Edition) described two layers of the deltoid ligament the superficial layer composed of the tibionavicular and calcaneotibial ligaments, and the deep portion of the anterior and posterior talotibial ligaments The smaller anterior talotibial ligament originates on the anterior edge of the medial malleolus and is inserted into the neck of the talus (Grath) or into the anterior part of the medial surface of the talus (Toldt) The posterior talotibial ligament originates on the posterior border of the medial malleolus and is inserted into the posterior part of medial surface of the talus

3 In the 29th Edition of Gray's Anato (1973) the deltoid ligament is described having two layers. In the superficial la there are three ligaments tibionavicul calcaneotibial, and posterior talotibial. Tl originate on the medial malleolus and inserted into the navicular, the sustentacul tali, and the medial tubercle of the talus. the deep layer there is only the ante talotibial ligament which is attached to tip of the medial malleolus and the med surface of the talus.

4 Close (1956) described the superfi fibers of the deltoid ligament as taking on on the anterior colliculus of the med malleolus and being inserted into navicular, the neck of the talus, the spr ligament, and the sustentaculum tali T deep portion originates in the groove betw the colliculi and is inserted into the med surface of the talus.

5 Wilson (1975) described superficial a deep fibers of the deltoid ligament T superficial fibers originate at the tip of t medial malleolus and are inserted into t navicular, the sustentaculum tali, and the talu The deep fibers run from the intercollicul notch of the medial malleolus to the medi surface of the talus.

FINDINGS IN THE ANATOMICA STUDIES

The following structures were studied in eac specimen the medial malleolus, the medi surface of the talus, calcaneus, and tars navicular, the deltoid ligament, and th relationship of the medial tendons, the sheaths, and the crural fascia to the deltoi ligament

A Medial malleolus is the medial proces of the distal tibia It has a wide base prox imally, a convex medial surface a slightly concave articular surface which is continuous with the articular surface of the tibial plafond, and an anterior and a posterior

wo views of the medial malleolus and ar colliculi A Anterolateral view of the anterior colliculus showing the articular surface and the anterior ridge The arrow indicates the anteromedial corner of the plafond where a great many fractures of the medial malleolus occur B Posterolateral view of the medial malleolus The intercollicular groove (G) and the distal and posterior surfaces of the posterior colliculus (P) are clearly seen along with the sulcus for the tendons of tibialis posterior and flexor digitorum longus (S) and the anterior colliculus (A)

colliculus which are separated from each other by the intercollicular groove (Figure 1A and B).

The anterior colliculus is the narrower slender, anterior portion of the medial malleolus which extends distally below the level of the posterior colliculus. It forms a ridge anteriorly and inferiorly, and its convex medial surface serves for attachment of the

Figure 2 Medial surfaces of the talus calcaneus and tarsal navicular showing navicular tuberosity (1) sustentaculum tali (2), medial tubercle of the talus (3) and the surface for attachment of the deep posterior talotibial ligament (arrows)

superficial portion of the deltoid ligament The articular surface of the anterior colliculus is easily distinguishable from and is continuous with the articular surface of the posterior colliculus.

The posterior colliculus is the broader, solid posterior portion of the medial malleolus It is convex medially and posteriorly, and contains the smaller posterior portion of the articular surface of the medial malleolus A shallow sulcus on its posterior surface serves for attachment of the tendon sheaths of the tibialis posterior and flexor digitorum longus.

The intercollicular groove extends from the anterior border of the articular surface of the posterior colliculus in an anteromedial direction and ends on the medial surface at the base of the anterior colliculus The entire surface of the intercollicular groove, and the distal surface of the posterior colliculus, serve for attachment of the deep posterior talotibial ligament

B The medial surface of the talus, calcaneus, and tarsal navicular serve for attachments of various parts of the deltoid ligament (Figure 2)

The medial surface of the talus has at its anterior and upper part a triangular articular facet which articulates with the medial malleolus. Below the posterior part of this facet, there is a surface for attachment of the

deep posterior talotibial ligament Anterior to this surface, a number of small perforations serve for entrance of the talar vessels, and anterior to that starts the neck of the talus Posterior and distal to this surface, the medial tubercle overhangs the posterior articular facet of the talus It is located just posterior and proximal to the sustentaculum tali of the calcaneus. It is important to distinguish these two bony prominences when dissecting the superficial portion of the deltoid ligament in order to delimate the calcaneotibial and superficial talotibial ligaments which are in most instances contiguous with each other The concave, medial surface of the calcaneus, below the sustentaculum tali, serves for passage of the tendon of the flexor hallucis longus and plantar vessels and nerves into the foot The plantar calcaneonavicular ("spring") ligament takes origin from the anterior margin of the sustentaculum tali and is inserted into the medial and plantar surfaces of the navicular and its tubercle On the dorsomedial surface of this ligament is attached the naviculotibial ligament

C The deltoid ligament was found to have two portions deep and superficial

eep portion of the deltoid ligament

Two ligaments, the smaller deep anterior id the deep posterior talotibial ligament, were discerned in the deep portion of the deltoid ligament and found to be practically intraarticular structures (Figure 3A and B)

Deep anterior talotibial ligament This is a small and short band which is covered by the calcaneotibial ligament The two ligaments blend with each other and may be confused during dissection for a single calcaneotibial ligament, although each of them has a separate insertion on the talus and the calcaneus The origin of the ligament is on the intercollicular groove and the adjoining anterior colliculus, and is contiguous with the deep posterior talotibial ligament It descends in a distal and slightly anterior direction and is inserted on the medial surface of the talus

Figure 3 The deep portion of the deltoid ligament A Lateral (intraarticular) view of the deep posterior talotibial ligament and its attachments (1) and

view of the deep posterior talotibial ligament and its attachments to the posterior colliculus and talus Superficial deltoid ligaments (2) were detached and reflected in order to show the deep anterior talotibial ligament (3)

near its neck This ligament was found to be of variable size in different specimens, sometimes hardly discernible and in some cases completely absent

Deep posterior talotibial ligament This is a strong and thick ligament which takes origin

Figure 4 The superficial portion of the deltoid ligament takes origin from the anterior colliculus A The naviculotibial ligament (arrows) B Detached from the anterior colliculus are naviculotibial (1) and calcaneotibial (2) ligaments still attached is the superficial talotibial ligament (3) In view is also the deep posterior talotibial ligament (4)

on the area bordered by the articular surface of the posterior colliculus, the posterior sulcus, the medial surface of the posterior colliculus, and the entire anterior margin of the intercollicular groove A few fibers of the ligament take origin also from the adjoining anterior colliculus. The ligament extends in a posterior, lateral, and distal direction and inserts into the medial surface of the talus, in an area extending from the medial tubercle to the edge of the posterior third of the articular surface of the talar trochlea The intraarticular surface of the ligament is covered with a layer of synovium.

Superficial portion of the deltoid ligament

Three ligamentous parts or bands were discerned in the superficial portion of the deltoid ligament which originate on the medial surface and the anterior ridge of the anterior colliculus and partially on the medial surface of the posterior colliculus of the medial malleolus. Their origins are contiguous with each other as are these ligaments in most parts (Figure 4A and B)

Naviculotibial ligament This band originates from the anterior colliculus. It extends in a fan-shaped fashion and forms a triangular ligament which is inserted into the dorsomedial surface of the navicular and along the dorsomedial surface of the plantar calcaneonavicular ("spring") ligament This is the largest and widest, yet the weakest portion of the deltoid ligament It blends with the joint capsule anterolaterally, and with the calcaneotibial ligament posteriorly

Calcaneotibial ligament This is the middle band It originates from the mid portion of the medial surface of the anterior colliculus. It extends distally in an almost perpendicular plane and inserts along the medial border of

the sustentaculum tali of the calcaneus. This is the strongest of the three bands.

Superficial talotibial ligament This band originates from the posterior part of the medial surface of the anterior colliculus and the adjacent small part of the posterior colliculus. It takes a postero-distal course and inserts into the anterior portion of the medial tubercle of the talus In some specimens the ligament was separated from the adjoining calcaneotibial ligament and in others the two structures were contiguous and indistinguishable, in the latter cases their separate insertions into the medial tubercle of the talus and the sustentaculum tali of the calcaneus had to be carefully dissected and differentiated In one specimen, the ligament was absent

It was also observed that the deep anterior talotibial and naviculotibial ligaments, and most fibers of the calcaneotibial ligament, became taut when the foot is plantar flexed Conversely, with the foot in dorsiflexion, the superficial talotibial and the deep posterior talotibial ligaments, and the posterior fibers of the calcaneotibial ligament, are taut

D Relations of the deltoid ligament to the overlying structures.

Superficial portion of the deltoid ligament almost completely covered by the sheaths and tendons of the tibialis posterior and flexor digitorum longus The tendon sheaths are firmly attached to the calcaneotibial and superficial talotibial ligaments, and are quite difficult to dissect The only part of the deltoid ligament which is readily dissectable, on a specimen or exposed at surgery, is the anterior portion of the naviculotibial ligament which lies under the fascia The tendons and the neurovascular bundle are covered by the crural fascia which is reinforced with the laciniate ligament at the level of the ankle joint (Figure 5A and B)

Figure 5A and B The deltoid ligament is almost completely covered by the tendons of the tibialis posterior and flexor digitorum longus (1) crural fascia, and the laciniate ligament (2)

DISCUSSION

Review of the literature revealed differences among descriptions of the deltoid ligament, its component parts, and their attachments to the medial malleolus and the talar bones At least five descriptions varying from each other exist in the literature Some authors consider

ie deltoid ligament to be a single layer ructure and others described two layers perficial and deep Variations also exist in gard to the number of ligaments in each yer and their bony attachments.

Description of the deltoid ligament by lose (1956) is similar to the findings in the esent study, the main difference being his ilure to recognize the superficial talotibial gament and inclusion of the anterior lotibial ligament in the superficial group ath (1960) and Toldt (1921) consider the ep anterior and posterior talotibial aments as the deep portion of the deltoid ament but do not recognize the superficial lotibial ligament The description in Gray's atomy is clearly inaccurate because the terior talotibial ligament does not represent e principal deep portion of the deltoid ament. Finally Wilson (1975) does not cognize the anterior talotibial ligament and relation to the calcaneotibial ligament herwise, his description is very similar to e present one

Since it was found in the present study at the deep anterior talotibial and the perficial talotibial ligaments may be less veloped or even absent in some specimens, is possible that the description by other thors reflected these variations in the eltoid anatomy

Findings in the present study demonstrated at the ligaments of the superficial deltoid yer take origin primarily from the anterior olliculus, and its three bands insert into the avicular and the plantar calcaneonavicular "spring") ligament the sustentaculum tali nd the medial tubercle of the talus The deep leltoid ligaments take origin primarily from he posterior colliculus and the intercollicular groove and are inserted into the medial surface of the talus. Only a very small portion of the deep anterior and posterior talotibial ligaments are attached to the anterior colliculus. These findings of separate attachments of the superficial and the deep portions of the deltoid ligament to the anterior and posterior colliculi respectively, are essential in the understanding and recognition of various singular and concurrent lesions of the medial malleolus and the deltoid ligament. These lesions will be described in a separate communication

REFERENCES

Bonnin J G (1950) *Injuries to the ankle* Heinemann Medical Books, Ltd. London

Burwell H N & Charnley, A D (1965) The treatment of displaced fractures at the ankle by rigid internal fixation and early joint movement *J Bone Jt Surg* 47 B 634–660

Close J R. (1956) Some applications of the functional anatomy of the ankle joint. *J Bone Jt Surg* 38 A 761–781

Coonrad R W (1970) Fracture-dislocation of the ankle joint with impaction injury of the lateral [illegible] *Acta chir scand* Suppl 263

Gray H (1973) *Anatomy of the human body* Ed C. M Moss, 29th ed., Lea and Febiger Philadelphia

Mendelsohn H A (1965) Nonunion of malleolar fractures of the ankle *Clin Orthop* 42, 103–118

Solonen, K A & Lauttamus, L. (1965) Treatment of malleolar fractures *Acta orthop scand* 36, 321–336

Toldt, C (1921) *Anatomischer Atlas* Elfte Auflag Berlin Wien Urban and Schwarzenberg.

Wilson, F (1975) *Fractures and dislocations of the ankle* Ed C Rockwood & D Green Fractures Vol 2 pp 1361–1399 J B Lippincott, Philadelphia.

Correspondence to Arsen M Pankovich, M D Cook County Hospital 1825 West Harrison Street Chicago Illinois 60612, USA

Acta orthop scand. 50, 225–236 1979

ANATOMICAL BASIS OF VARI[illegible] MEDIAL MALLEOLUS AND TH[illegible]

II Clinical Studies

ARSEN M PANKOVICH & MYSORE S SH[illegible]

Division of Orthopedic Surgery, Cook Cou[illegible]
Chicago, Illinois, USA

Figure 1 Correlation of the anatomy of the medial malleolus on the roentgenograms A) anteroposterior view, and B) lateral view Anterior colliculus (1) posterior colliculus (2) and intercollicular groove (3)

will be described on the basis of findings present in the cases in which the lesions were diagnosed preoperatively and then confirmed at surgery In some cases the diagnosis became evident only at surgery

The following material was obtained in all cases 1) data on the presence or absence of tenderness and swelling over the ligaments on the medial and lateral sides of the ankle and the anterior capsule of the ankle joint, 2) a roentgenographic examination which included three views of the ankle and when indicated anteroposterior and lateral views of the proximal parts of the fibula and tibia 3) external rotation and valgus stress roentgenograms when indicated, and 4) the operative findings with special attention to lesions of the deltoid ligament and the medial malleolus. In a few cases where plain roentgenograms did not clearly demonstrate the fracture line of the medial malleolus and its relation to the colliculi, lateral tomograms of the medial malleolus were obtained.

In order to be able to recognize the anatomy of the medial malleolus on plain roentgenograms they were correlated with tomograms and findings at surgery whenever possible The landmarks were recognized on the anteroposterior and lateral roentgenograms which represented the anterior and posterior colliculi and the intercollicular groove (Bonnin 1950) (Figure 1)

RESULTS

Six patterns of injuries of the deltoid ligament and the medial malleolus were observed

1 *Rupture of the deep and superficial portions of the deltoid ligament* The deep posterior talotibial ligament was considered to be ruptured only when widening of the medial mortise greater than 2 to 3 mm was present on the original roentgenograms or on subsequent valgus and external rotation stress roentgenograms (Figure 2) There were 15

Figure 2 Roentgenograms indicate rupture of the deep posterior talotibial ligament in a supination external rotation injury Widening of the medial mortise is greater than 3 mm.

such cases. At surgery in all of these cases there was rupture of the deep posterior talotibial ligament The deep anterior talotibial ligament was also probably ruptured, although in the majority of cases it was not possible at surgery to identify this ligament due to hematoma and damage to the surrounding structures, and its small size While it was easy to demonstrate at surgery rupture of the deep posterior talotibial ligament because of its intraarticular accessibility, this was not the case with the superficial deltoid ligaments which are covered with tendons of the tibialis posterior and flexor hallucis longus and their sheaths, and the crural fascia reinforced with the laciniate ligament If these overlying structures are intact, as it is often the case, it is difficult and impractical to attempt to expose the superficial ligaments at surgery In cases where there were ruptures of fascia and tendon sheaths, the presence of hematoma indicated injury of the superficial ligaments In some cases, clear rupture of the superficial ligaments, usually at their bony attachments, was demonstrated Surgery was never performed if only rupture of the superficial portion of the deltoid ligament was suspected

The site of rupture of the deep posterior talotibial ligament was found most often to be near its insertion into the medial surface of the talus, and only rarely from the posterior colliculus and the intercollicular groove

The deltoid ligament was found to be ruptured in supination-external rotation, pronation-external rotation and pronation-abduction injuries, and in Maisonneuve lesions. Isolated ruptures were not observed For obvious reasons, the ligament was never found to be ruptured in supination adduction and various internal rotation lesions.

2. *Fracture of the anterior colliculus* In these lesions, the fracture line extends obliquely (Figure 3A) or transversely between the anterior edge of the anterior colliculus and its posterior edge or the intercollicular groove On the anterposterior roentgenograms (Figure 3B) the fracture fragment is located just below the intact posterior colliculus and the medial mortise is not widened The deep posterior talotibial ligament remains intact as demonstrated by valgus and external rotation stress roentgenograms (Figure 3C)

Fractures of the anterior colliculus were found in advanced stages of the supination-external rotation injuries, and sometimes as isolated fractures accompanied by tenderness of the distal tibiofibular syndesmosis, indicating that the mechanism of the injury was pronation-external rotation (Pankovich 1978) (Figure 4)

Nine fractures of the anterior colliculus were seen during the period of the study In all cases, valgus and external stress roentgenograms were obtained and failed to demonstrate medial ankle instability Seven of these cases were treated by immobilization in a short walking cast for 6 weeks and two underwent open reduction and internal fixation. Two patients treated by cast im-

Figure 3 F
rotation les
widening of
fragments a

igure 4 A) Anteroposterior and B) lateral roentgenograms of a fracture of the anterior colliculus in a tage 2 pronation external rotation injury The fracture line extends into the intercollicular groove aving the posterior colliculus (arrow) intact The ankle is stable

iobilization developed fibrous union of 'acture of the anterior colliculus, painful in ne patient (Figure 3D) This latter patient ould not undergo open reduction because he leveloped pulmonary embolism while under nticoagulation therapy and continues to ave ankle pain In two patients who nderwent open reduction, the deep posterior alotibial ligament was found to be intact)ne patient treated conservatively removed he cast after 1 week and was bearing full ve ght when seen in the clinic 6 weeks later Roentgenograms at that time revealed healed 'ractures of the anterior colliculus and the fibula in a good position (Figure 5)

3 *Concurrent fracture of the anterior colliculus and rupture of the deep posterior talotibial ligament* There were six such cases. In the two initial cases, rupture of the deep posterior talotibial ligament was recognized only at surgery although the diagnosis was evident on preoperative roentgenograms (Figure 6)

At surgery in three cases attachments of the deep posterior talotibial ligament were found to be separate from the fractured anterior colliculus, the ligament was ruptured in its middle in one case and near talar insertion in two cases. The deep anterior talotibial ligament was not discernible in any of these cases because of local heamtoma and tissue damage which prevented identification of the ligament All three ankle injuries were an advanced supination-external rotation lesion with the fracture of the fibula at the level of the distal tibiofibular syndesmosis. Treatment consisted of approximation of the ends of the ligament with a chromic catgut suture and fixation of the anterior coll culus

Figure 5 A fracture of the anterior colliculus in a supination external rotation injury The patient removed her cast at 1 week post injury At 6 weeks, fractures have healed in a good position

with a navicular screw and usually a wire Stability of the medial side further increased by internal fixation of the fracture of the fibula with a small fragment A0 plate

In another three cases a segmental rupture of the deep posterior talotibial ligament was present One patient was a 22-year-old male who twisted his left ankle in a fight on the day of admission Roentgenograms revealed an advanced supination-external rotation lesion with a fracture of the fibula above the distal tibiofibular syndesmosis, widening of the medial mortise, and a fracture of the anterior colliculus which appeared to involve a small portion of the posterior colliculus (Figure 7A, B) At surgery, it was found that the fracture line did indeed involve a portion of the posterior colliculus which carried along approximately one half of the deep posterior

Figure 6 A concurrent fracture of the anterior colliculus and rupture of the deep posterior talotibial ligament, confirmed at surgery A) Lateral and B) anteroposterior views

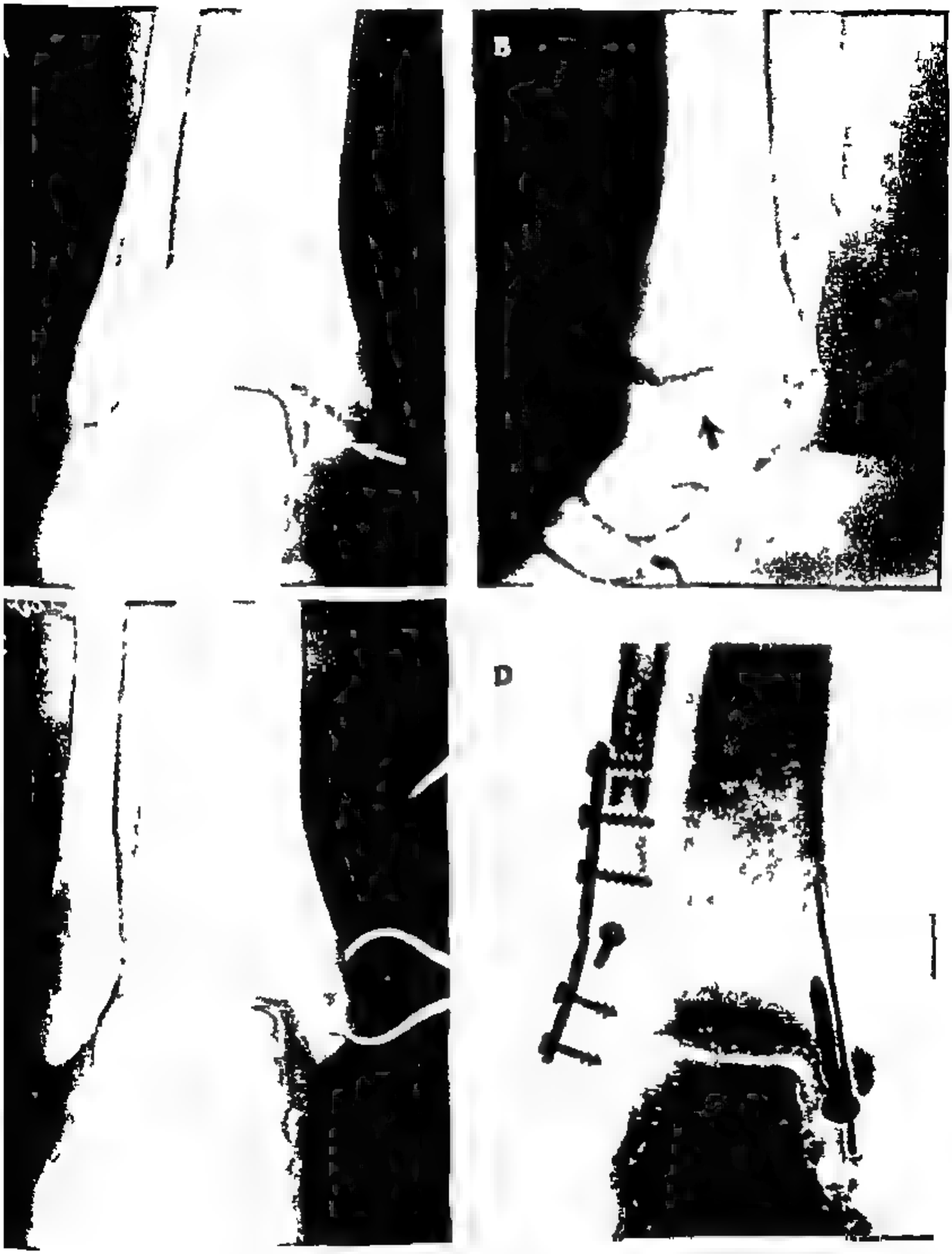

Figure
the

ttability of the ankle are restored.

talotibial ligament, the other half attached to the posterior colliculus, was ruptured in its middle. In order to test the stability of the talus after fixation of only the medial malleolar fragment and leaving the ruptured portion of the deep posterior talotibial ligament unrepaired the fracture fragment was reduced and held in position with an AO malleolar clamp External rotation stress roentgenograms showed a 4 mm increase in width of the medial mortise (Figure 7C) which decreased to 2 mm following repair of the ligament. After fractures of the medial malleolus and the fibula were fixed the medial mortise was only 1 mm wider (Figure 7D).

4 *Fracture of the posterior colliculus* There were four such cases. In two of these cases the anterior colliculus was also fractured In all cases, the posterior fracture fragment consisted of the posterior colliculus and a supracollicular spike of bone from the posteromedial part of the tibia which carried along the posterior tibial tendon (Figure 8) In two cases, there was an undisplaced transverse fracture between the colliculus and the spike. Since the diagnosis of a fracture of the posterior colliculus by plain roentgenograms is often quite difficult lateral of the medial malleolus were preoperatively in the last two cases (Figure 9) Roentgenographic findings were confirmed at surgery

5 *Supracollicular fractures* Most of the fractures of the medial malleolus under study were shown by roentgenograms and at surgery to have the fracture line above the colliculi (Figure 10) Common to all these fractures was presence of the intact deltoid ligament attached to the fracture fragment The three common types of fractures vertical, oblique, and transverse were observed.

6 *Avulsion chip fractures* Four such cases were available for study These were isolated injuries of the ankle. In three cases the chip

Figure 8 A fracture of the posterior colliculus has a supercollicular spike (arrow) which is typical of this lesion

fracture was located in close proximity to the anterior colliculus and was best seen on the lateral roentgenograms (Figure 11). These lesions are considered to be a sprain fracture of the superficial deltoid ligament caused by forceful plantar flexion of the foot. A chip fracture of the posterior colliculus, as described by Bonnin (1950) was also seen in one case

DISCUSSION

In order to recognize various singular and concurrent lesions it is essential to understand the anatomical relations of the medial malleolus and its colliculi, and the various parts of the deltoid ligament (Pankovich & Shivaram 1979) It is also important to know which of these lesions are stable and which unstable. Thus a fracture of the anterior colliculus can be considered a singular stable



Figure 9 Concurrent fractures of the anterior and posterior colliculi in a supination external rotation injury A) The anteroposterior view shows comminution of both colliculi and a supracollicular spike (arrow) B) On the lateral view, there are fractures of the anterior colliculus, the posterior colliculus (lower arrow), the posterior tibial tubercle (upper arrow), and the fibula almost superimposed over each other C) A lateral tomogram of the medial malleolus clearly outlines a fracture of the anterior colliculus and comminution of the fractured posterior colliculus

Figure 10 A, B) The fracture line is supracollicular, indicating an intact deep posterior talotibial ligament

Figure 11 An avulsion chip fracture of the anterior colliculus is best seen on lateral views

lesion if the deep posterior talotibial ligament is shown by external rotation and valgus stress roentgenograms to be intact On the other hand, if the medial mortise widens under these stresses, the lesion is considered concurrent and unstable due to rupture of the deep posterior talotibial ligament. The variety of stable and unstable, singular and concurrent lesions are depicted schematically in Figure 12

Recognition of the various singular and concurrent lesions of the medial malleolus and the deltoid ligament has a definite bearing on the choice of treatment A singular, anterior collicular fracture, when undisplaced or slightly displaced, requires a short period of immobilization in a short cast because it is a stable lesion Existence of this type of fracture, in which the deep posterior talotibial

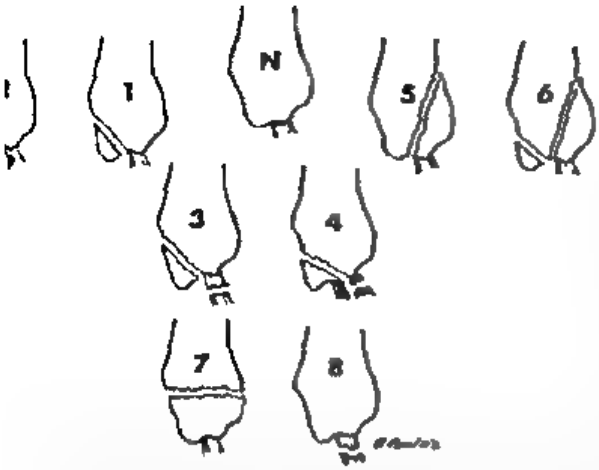

gure 12 Types of lesions of the medial malleolus d the deep posterior talotibial (DPT) ligament normal 1 singular fracture of the anterior lliculus, 2-chip fracture of the anterior lliculus 3-concurrent fracture of the anterior lliculus and rupture of the DPT ligament, 4 mental rupture of the DPT ligament, 5 gular fracture of the posterior colliculus, 6- ncurrent fractures of the anterior and posterior lliculi, 7 supracollicular fracture, and 8- gular rupture of the DPT ligament

gament is intact, explains absence of dis- acement of the talus in supination-external tation injuries in patients who continued to ear weight on the injured ankle However, if e fractured anterior colliculus is displaced, ternal fixation may be preferable because onservative management in our two cases d to a fibrous union Fixation of the lateral alleolus in such cases does not seem ecessary because displacement of the racture is only minimal and is not expected increase since the deep posterior talotibial gament is intact On the other hand a con- urrent fracture of the anterior colliculus and upture of the deep posterior talotibial gament, an unstable lesion, requires repair f both structures, and usually additional tabilization of the talus by fixation of the racture of the fibula, and sometimes fibulotibial transfixion It is quite obvious that fixation of only the anterior colliculus would not prevent talar displacement and consequent widening of the medial mortise The existence of this type of concurrent lesion provides an explanation for the cases found in the literature in which widening of the medial mortise remained after anatomical reduction and fixation of the fracture of the medial malleolus

Variability of the direction of the fracture line is responsible for different lesions of the medial malleolus and the deep posterior talotibial ligament The fracture line usually starts at the anteromedial corner of the ankle mortise Horizontal and only slightly downward oblique fracture lines in the anteroposterior direction are representative of supracollicular fractures In singular fracture of the anterior colliculus, the fracture line is more oblique, and if the injuring force is strong enough it will rupture the deep posterior talotibial ligament as well Although all these lesions are usually easily recognized on the plain and stress roentgenograms, in some cases the fracture line may appear to be supracollicular while in fact it passes above the intercollicular groove, and involves a portion of the posterior colliculus In such cases, a considerable portion of the deep posterior talotibial ligament may be ruptured from the posterior part of the posterior colliculus, and fixation of the fracture fragment alone would still leave medial instability, as seen in three of our cases This points to the importance of the more abundant posterior portion of the deep posterior talotibial ligament to ankle stability and to the need for repair of all injured structures.

Methods of treatment of these lesions were discussed primarily to emphasize the anatomical findings. A long-term follow-up study of a greater number of cases is needed in order to determine the best method of treatment, particularly of singular and concurrent collicular fractures Results of such a study will be reported at a later date.

Credit for the first description of the collicular injuries goes to Bonnin (1950) who mentioned them in his monograph on injuries to the ankle To the best of our knowledge there are no other descriptions of these lesions in the English medical literature

REFERENCES

Bonnin, J G (1950) *Injuries to the ankle* Heinemann Medical Books, Ltd London

Burwell, H N & Charnley, A D (1965) The treatment of displaced fractures at the ankle by rigid internal fixation and early joint movement. *J Bone Jt Surg* 47-B, 634–660

Close, J R (1956) Some applications of the functional anatomy of the ankle joint *J Bone Jt Surg* 38-A, 761–781

Coonrad, R W (1970) Fracture-dislocation of the ankle joint with impaction injury of the lateral weight-bearing surface of the tibia *J Bone Jt Surg* 52-A, 1337–1344

Mendelsohn, H A (1965) Nonunion of malleolar fractures of the ankle *Clin Orthop* 42, 103–118

Pankovich, A M (1978) Fractures of the fibula proximal to the distal tibio-fibular syndesmosis. *J Bone Jt Surg* 60-A, 221–229

Pankovich, A M & Shivaram, M S (1979) Anatomical basis of variability in injuries of the medial malleolus and the deltoid ligament. Anatomical studies. *Acta orthop scand* 50, 217–223

Solonen, K A & Lauttamus, L (1956) Treatment of malleolar fractures. *Acta orthop scand* 36, 321–336

Correspondence to Arsen M Pankovich, M D, Cook County Hospital, 1825 West Harrison Street, Chicago, Illinois 60612, USA

Acta orthop scand 50 237–239, 1979

FRACTURE-SUSPENDING EFFECT OF THE PATELLAR-TENDON-BEARING CAST

H SVEND-HANSEN, V BREMERSKOV & P OSTRI

Department of Orthopaedic Surgery, Copenhagen County Hospital, Glostrup, Denmark

In order to evaluate the fracture-suspending effect of the patellar-tendon-bearing cast, experiments using a load cell under the heel were carried out on four subjects Measurements were made using a conventional below-knee cast, the PTB cast, and an above-knee cast There were no differences between the forces transmitted by the same subject wearing the three types of casts in turn and consequently the choice of cast must be based on other factors.

Key words early weight-bearing, patellar-tendon bearing cast, tibial fractures

Accepted 11 IX.78

The patellar-tendon-bearing cast (PTB cast) is a functional below-knee total contact cast first described by Sarmiento (1967) Experience with the patellar tendon-bearing prosthesis in current use for the below-knee amputee led to the development of the cast and its use in the treatment of tibial fractures. In principle it is a below-knee cast extending to the upper pole of the patella and with a firm moulding over the medial flare of the tibia, the patellar tendon, and the popliteal space, and shaped in a triangular manner at the upper end of the tibia Sarmiento (1967) stated that the PTB cast stabilized the proximal fragment of a tibial fracture, left the knee free to move, and allowed early ambulation as weight-bearing forces should be transmitted from the ground to the proximal end of the tibia, virtually bypassing the fracture site and suspending the fractured bones. To assess whether the latter assertion is correct, the present investigation was carried out A PTB cast was compared with a conventional below-knee cast and an above-knee cast

MATERIAL AND METHODS

Four subjects weighing 50, 65, 80, and 100 kg were used in the experiments A miniature load [illegible] were then applied, incorporating an adjustment [illegible] the cast screw resting on the upper aspect of the cast heel. This screw enabled us to elevate or lower the load cell casing so that it just touched the under surface of the foot with the leg in a non-weight-bearing position. The cast was then extended to just below the tibial tubercle as in a conventional below-knee cast. Figure 1B shows the position of the load cell casing After the cast had dried, the load cell was connected to a pen recorder (Servogor RE 511) and a pressure curve was obtained when the test subject walked without [illegible]

© [illegible]

0001-6470/79/020237 03$02.50/0

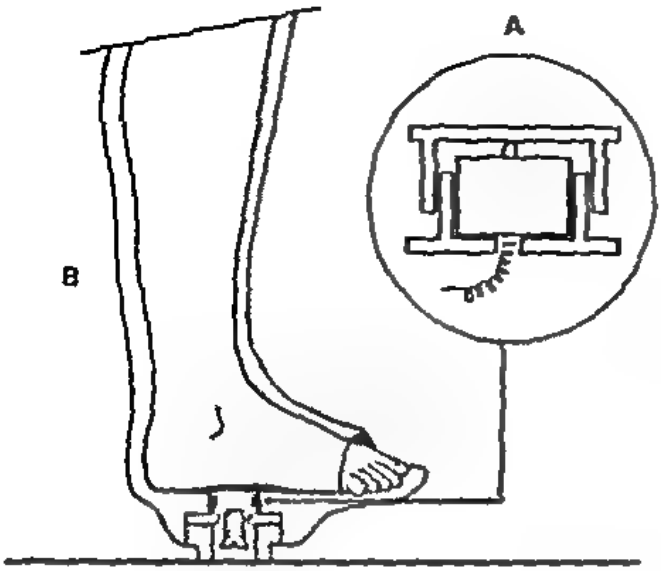

Figure 1 A Transection of the load cell casing B The position of the load cell casing in the cast

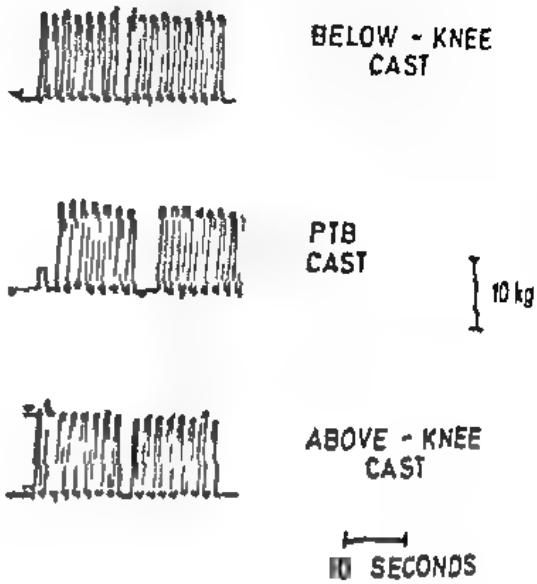

Figure 2 Pressure curves obtained from the subject weighing 65 kg

support The cast was then extended and moulded as a PTB cast and new measurements were taken Finally the cast was cut down until well below the knee and subsequently extended until high on the femur A third set of measurements was obtained

RESULTS

In Table 1 the forces transmitted by the four subjects are recorded The relative forces transmitted are almost the same with the three different types of casts, while the forces vary between test subjects, ranging between 10 6 and 20 0 per cent body weight transmitted In Figure 2 typical curves obtained from the subject weighing 65 kg are shown The forces transmitted from the tibia through the heel into the heel of the plaster cast are of the same magnitude in the three types of cast, and thus no difference was found as regards fracture-suspending effect

DISCUSSION

The principle of early weight-bearing was first described by Gurd (1940) Later Dehne et al (1961) and Brown & Urban (1969) advocated this form of treatment Sarmiento (1967) described the PTB cast and its

Table 1 Forces transmitted by the four subjects using three types of casts

		Below-knee cast		PTB cast		Above-knee cast	
Subject no	Body weight (kg)	Force transmitted (kg)	Force transmitted (per cent)	Force transmitted (kg)	Force transmitted (per cent)	Force transmitted (kg)	Force transmitted (per cent)
1	50	5 7	11 2	5 7	11 2	5 3	10 6
2	65	13 0	20 0	13 0	20 0	12.3	18 9
3	80	11 0	13 8	11 0	13 0	10 5	13 1
4	100	16 5	16 5	16 2	16 2	15 8	15 8

application in 180 patients Many surgeons have later adopted this principle in selected cases (Wiedmer et al 1975, Hackstock 1974, Mølster et al 1976) Dehne (1972) claimed that a small amount of movement at the fracture site stimulates healing of the fracture Sarmiento (Sarmiento 1974, Sarmiento et al 1974) introduced the "hydraulic container theory" He stated that the soft tissues of the lower leg within the rigid tight fitting walls of the cast constitute some sort of hydraulic system, which in combination with the interosseus membrane prevents shortening of the fracture He claimed furthermore that the rhythmic compression of the visco-elastic structures of the calf enhanced blood circulation and osteogenesis In the latter study he conceded that the fracture-suspending effect of the cast may be smaller than originally assumed

In this paper we do not aspire to recommend any specific treatment in tibial fractures We have merely shown that the axial forces transmitted through the bone to the ground are the same in below-knee, PTB, and above-knee casts The choice of treatment must consequently be based on other factors as no difference exists in the fracture-suspending effect

REFERENCES

Brown, P W & Urban, J G (1969) Early weight-bearing treatment of open fractures of the tibia *J Bone Jt Surg* 51-A, 59–75

Dehne, E, Metz, C W, Deffer, P A & Hall R M (1961) Non-operative treatment of the fractured tibia by immediate weight-bearing *J Trauma* 1, 514–535

Dehne, E (1972) The weight-bearing principle in treatment of lower-extremity fractures 1885–1972 *J Trauma* 12, 539–540

Gurd, F D (1940) The ambulatory treatment of fractures of the lower extremity *Surg Gynec Obstet* 70, 385–391

Hackstock, H (1974) Zur konservativen Behandlung von Unterschenkelbrüchen mit dem Sarmiento-Gips *Hefte Unfallheilk* 119, 41–49

Mølster, A, Søreide, O & Stedjeberg, O (1976) *Patellasenebaerende gagips. T norske Laegeforen* 29, 1548–1550

Sarmiento A (1967) A functional below-the-knee cast for tibial fractures *J Bone Jt Surg* 49-A, 855–875

Sarmiento, A, Latta L, Zilioli, A & Sinclair, W (1974) The role of soft tissues in the stabilization of tibial fractures. *Clin. Orthop* 105, 116–129

475 477

Correspondence to Henrik Svend Hansen, Bibliotekvej 10, 2650 Hvidovre, Copenhagen Denmark.

PARATHYROID HORMONE SECRETION AFTER OPERATIVE BONE TRAUMA

ANDERS HULTH & OLOF JOHNELL

Department of Orthopedic Surgery, Malmö General Hospital, University of Lund, Malmö, Sweden

Skeletal trauma in man (operations for scolioses and femoral shortening) results in a significant increase in parathyroid hormone secretion beginning the day after the operation and lasting for more than 1 week. A concurrent decrease in serum calcium, dependent on the postoperative lowering of serum albumin, was also observed

Key words parathyroid, parat hormone, bone trauma, serum calcium, scoliosis

Accepted 25 vii 78

Standardized bleedings in rats result in increased mitosis activity of the bone marrow cells, which might be due to a parathyroid dependent hypercalcemia (Perris & Whitfield 1967a,b) The bone marrow mitosis is proportional to the plasma calcium concentration (Perris & Morgan 1976) Femoral fractures and aspiration of bone marrow in rats also stimulate the mitotic activity of bone marrow cells of the opposite bone and of thymus cells (Hulth & Johnell 1976a,b,) It is possible that this increase in mitotic activity is also dependent on the parathyroids Bleeding and femoral fractures in rats also result in an increased amount of osteoclasts in rib metaphysis (Johnell & Hulth 1977)

The results of these experiments have evoked our interest in the study of parathyroid secretion after operative trauma in man Investigations have shown serum calcium to be unchanged during the early phase after bone trauma (Lal et al 1976, Lyrits et al 1976) In spite of the fact that serum calcium in man is very well regulated, it may be possible to find a change in the parathyroid hormone (PTH) secretion during the early phase after bone trauma

MATERIAL AND METHODS

Analyses were made on 11 patients, 9 patients aged 13–33 years undergoing operations for scoliosis according to Harrington's method and [illegible] patients (aged 19 and 24 years) on whom shortening of one [illegible] performed [illegible] operations [illegible] replaced [illegible] operations. Blood samples were taken the day before, and 1, 3, 6 and 14 days after the operations. All the samples belonging to each patient were kept in the deep freezer and sent in for analysis concurrently to the Medicinsk Laboratorium, Copenhagen Parathyroid hormone was analyzed with a radioimmunoassay method, standardized to Medical Research Council, England No 71/324=1 As standard, bovine PTH was used

Financial support was obtained from the Swedish Medical Research Council (project no B79–17X–05223–02).

0001–6470/79/030241–03$02.50, 0

© 1979 Munksgaard, Copenhagen

The hemoglobin (Hb) and hematocrit (Hct) were measured regularly in all patients and in seven of the scoliosis cases the calcium and albumin in serum were also investigated

RESULTS

The results are shown in Figures 1–3 PTH increased from the day after operation, the increase becoming highly significant ($P < 0.001$) on the third day after operation and then undergoing a slow decline reaching the normal value on the 14th day (Figure 1) In only three cases did the peak values exceed the upper limit of the reference interval (0 50 µg/l)

Ca decreased significantly on the 1st and 3rd days after operation There was, however, at the same time a significant decrease in serum albumin (Figure 2) If the calcium values are recalculated in relation to the decreased albumin values, a significant serum calcium decrease no longer exists (Figure 3) A decrease in serum albumin occurs regularly after trauma, as shown by repeated investigations (Aronsen et al 1972) In the course of the 3rd and 6th days after operation hemoglobin and hematocrit were significantly decreased probably due to incomplete replacement

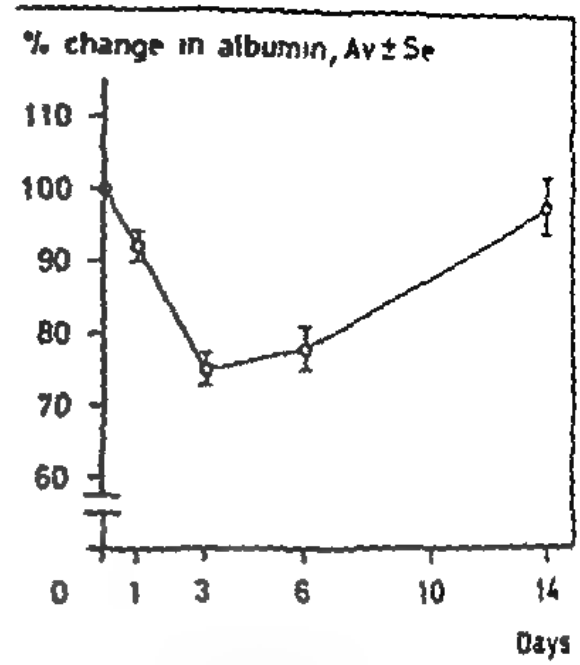

Figure 2 The postoperative decrease in albumin/s in per cent The initial values = 100 per cent

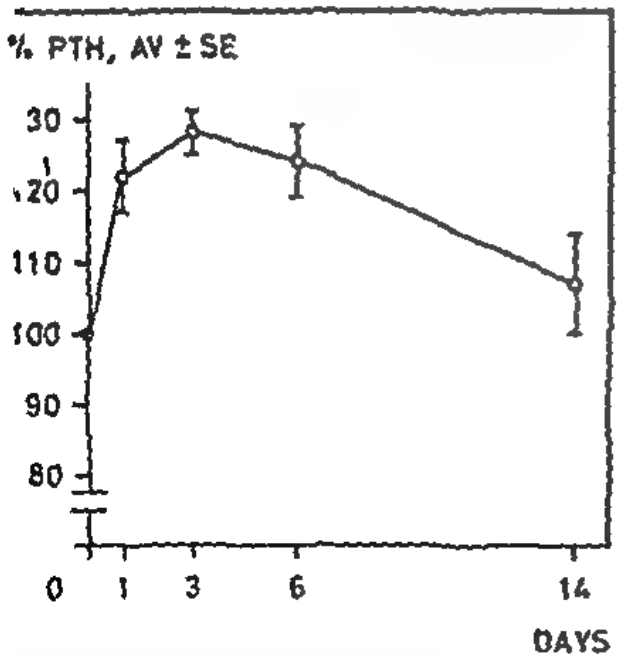

Figure 1 The postoperative increase in PTH secretion after the operations in per cent The initial values = 100 per cent The reference interval of the normal values is 0 22–0 50 µg/l

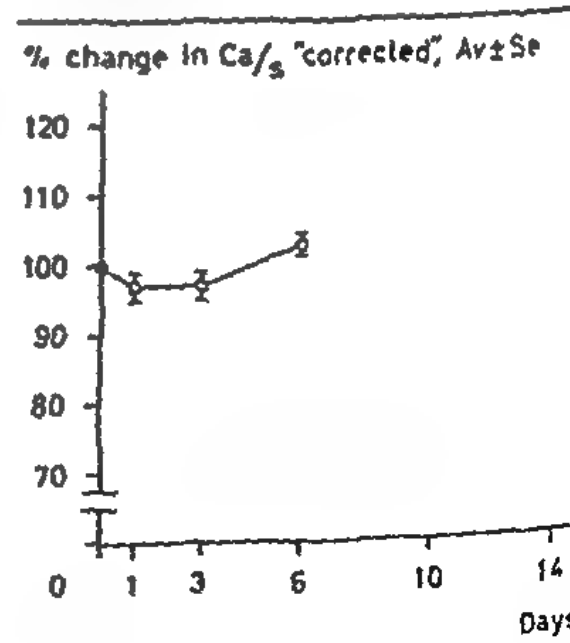

Figure 3 The postoperative change in calcium/s corrected for the concurrent decrease in albumin The initial values = 100 per cent

DISCUSSION

The increase in PTH is of course difficult to evaluate, but nevertheless of interest to report. It is known that fractures in humans and immobilization result in immediate changes in mineral metabolism, demonstrated particularly by the increased urinary excretion of calcium (Howard et al 1945, Klein 1966) Serum calcium in man is, however, always constant, as in our investigation, except in elderly people with femoral neck fractures where a decrease has been found (Nilsson & Westlin 1972) It is improbable that the rise in the PTH level is the only cause of the disturbance in the mineral metabolism The rise is too low and in addition the increased PTH should have given the opposite effect on renal calcium excretion At this moment, therefore, it is not possible to explain the increased PTH secretion after operative trauma, except as an unspecific stimulation.

REFERENCES

Aronsen K. F, Ekelund G., Kindmark, C-O & Laurell, C-B (1972) Sequential changes of plasma proteins after surgical trauma. *Scand J clin. Lab Invest*, Suppl. 124, 29, 127–136

Howard, J E, Parson W & Bingham, R S (1945) Studies on patients convalescent from fracture *Johns Hopk. Hosp Bull* 77, 291–313

Hulth, A & Johnell, O (1976b) Cell proliferation in the bone marrow and thymus following partial bone marrow aspiration *Experientia (Basel)* 32, 1577–1588

Johnell O & Hulth, A. (1977) Proliferation of osteoclasts in rat bone following bleeding and femoral fractures *Calcif Tiss Res* 23, 241–244

Klein, L (1966) The relationship between urinary hydroxyproline calcium and serum alkaline phosphatase during fracture healing and acute disuse osteoporosis. Fourth European Symposium on Calcified Tissues *Excerpta Medica Foundation* 47, 65–66

Lal, S K, Jacob, K. C, Nagi, O N, Annamalai, A L & Nair, C R (1976) Variations of some plasma components after closed fractures. *J Trauma* 16 (3), 206–211

Lyritis, G, Nikiforidis, P, Papadopoulou, Z, Castrisios, E & Hartofilakidis-Garofalidis G (1976) The values of some plasma components during the early phases of fracture healing in man *Acta orthop scand* 47, 264–266

Nilsson, B E & Westlin N E (1972) The plasma concentration of alkaline phosphatase, phosphorus and calcium following femoral neck fracture *Acta orthop scand* 43, 504–510

Perris, A D & Whitfield, J D (1967a) Calcium and the control of mitosis in the mammal *Nature (Lond)* 216, 1350–1351

Perris, A D & Whitfield, J F (1967b) Stimulation of mitosis in bone marrow and thymus of normal and irradiated rats by divalent cations and parathyroid extract *Radiat Res* 32, 550–563

Perris, A. D & Morgan, J I (1976) The interaction of divalent cations hormones and cyclic nucleotides in the control of mitosis. *Calcif Tiss Res*, Suppl 21, 15–20

Correspondence to Prof A. Hulth, Department of Orthopedic Surgery, Malmo General Hospital S-214 01 Malmö, Sweden

)

Acta orthop scand 50, 245–249 1979

EFFECTS OF CLOXACILLIN, DOXYCYCLINE, FUSIDIC ACID AND LINCOMYCIN ON THE MECHANICAL PROPERTIES OF BONE AND SKIN IN YOUNG RATS

LARS B ENGESAETER & ANNE GRETE SKAR*

Institute for Surgical Research, Rikshospitalet, Sophies Minde Orthopedic Hospital and * "Kaptein W Wilhelmsen og Frues Bakteriologiske Institutt", Rikshospitalet, University of Oslo, Norway

The influence of cloxacillin, doxycycline, fusidic acid and lincomycin on the mechanical properties of bone and skin in young rats was examined. The concentrations of the antibiotics in plasma corresponded to therapeutic

or in the mechanical properties of the femur and tibia

Key words bones, cloxacillin, doxycycline, fusidic acid, lincomycin, mechanical properties, skin

Accepted 20 XII 78

Ideally, antibiotics should be toxic to the bacteria and harmless to the host organism Some antibiotics such as the tetracyclines, may, however, also impair mammalian cells (Cohlan et al 1963, Gudmundson 1971, Vazquez 1974) In a previous study we found that oxytetracycline caused reduced bone growth and reduced mechanical strength of both bone and skin in young rats (Engesaeter & Skar 1978)

The purpose of the present investigation was to study the influence of four other antibiotics (cloxacillin, doxycycline, fusidic acid and lincomycin) on Weight gain, longitudinal bone growth, mechanical properties of bone, intact skin and wound healing

MATERIALS AND METHODS

Experimental animals were outbred male Wistar/Af/Han/Mol SPF rats, initially weighing 39–44 g They were kept five in each cage and fed water and Norwegian standard diet for rats *ad libitum* The animals were divided into five weight-matched groups of ten rats. Group 1 received cloxacillin (Ekvacillin* ad inj, Astra), group 2 doxycycline (Vibramycin* ad inj., Pfizer), group 3 fusidic acid (Fucidin* oral susp, Leo), group 4 lincomycin (Lincocin* ad inj, Upjohn) and group 5 (control) isotonic sodium chloride solution The antibiotics were given in 0 5 ml of water as intraperitoneal injections every 12 hours for 14 days. Fusidic acid, however, had to be administered by stomach tube as intraperitoneal injections in a pilot study gave massive abdominal adhesions

The daily amount of antibiotic given was constant throughout the experiment, but as the rats grew rapidly the doses in mg/kg/day were higher initially than at the end The doses in the middle of medication are given in Table 1

The concentrations in plasma of cloxacillin, doxycycline and lincomycin were determined by the paper disc method of AB biodisk (Stockholm, Sweden) (Jalling et al. 1972) Regarding fusidic acid, no commercial standard disc-series was

0001 6470/79/030245 05$02 50.0

© 1979 Munksgaard, Copenh

available However, a method for determination of the concentration of fusidic acid in rat plasma was obtained from Løvens kemiske Fabrik (Copenhagen, Denmark)

On the first day of medication a 3 5 cm long skin incision was made on the left side of the back of the rats. The wound was closed with three interrupted stitches as previously described (Engesæter & Skar 1978). The animals were killed with ether after 14 days of medication Immediately after death the femora and the tibia were dissected free The length of the femur (from the top of the caput to the distal end of the medial condyle) was measured with a sliding callipers (accuracy of ±0 01 mm). Until mechanical testing (less than 2 hours) the femora were kept in isotonic saline solution at room temperature (about 20° C) The left femur diaphysis was tested [illegible]

For practical reasons the tibiae were frozen 20° C) for 5 days before testing of bending [illegible] After thawing (to 20° C), and in a wet [illegible] the proximal half of the right tibia was deflected laterally relative to the [illegible]

from the left side of the back containing the healing wound and intact skin from the corresponding right side were removed and frozen for 10–11 days. After thawing the tensile strength of both sutured and intact skin specimens was measured as previously described (Engesæter & Skar 1978)

In addition to these 50 rats described, 10 animals were killed at the start of the experiment to obtain origin values for femur length, tensile strength of intact skin and bending strength of the tibia diaphysis.

The median with 25- and 75- fractiles was used to express the average and the dispersion of the measured values. Statistical significance was evaluated by the Wilcoxon test for two samples (one-tailed test) and differences were considered significant if $P \leq 0\ 05$ (Diem & Lentner 1975)

RESULTS

In the middle of the experiment plasma concentrations of the antibiotics were measured 1, 2, 6 and 12 hours after medication (Table 1)

All animals grew rapidly during the experiment (Figure 1), but the cloxacillin and the doxycycline treated rats had, at the end of the medication period, significantly lower body weights (2 and 7 per cent, respectively) than the control rats.

The influence of the antibiotics on longitudinal growth of the femur is illustrated in Figure 2 As compared with controls, the femurs of animals receiving doxycycline, fusidic acid or lincomycin were significantly shorter (1–2 per cent)

No significant differences could, however, be detected in the mechanical properties of the bones from any of the antibiotic treated groups when compared with the controls,

Table 1 Doses and plasma concentrations of the antibiotics on the 7th day of medication The concentrations were measured in five rats in each group (Median with 25- and 75 fractiles)

Antibiotic	Dose (mg/kg/12 h)	Plasma concentration (µg/ml) at varying intervals after administration			
		1 h	2 h	6 h	12 h
Cloxacillin	248	13 (10–18 5)	<2.0	<2.0	<2 0
Doxycycline	25 5	5 0 (4 5–5 3)	4 5 (4 0–4 6)	2.0 (1 8–2 1)	1 3 (1 2–1 3)
Fusidic acid	238	2 8 (2.8–3 1)	2 0 (1 9–2 2)	1 2 (1 0–3 8)	0 3 (0 2–0 3)
Lincomycin	95	8 (4–8)	<1 0	<1 0	<1 0

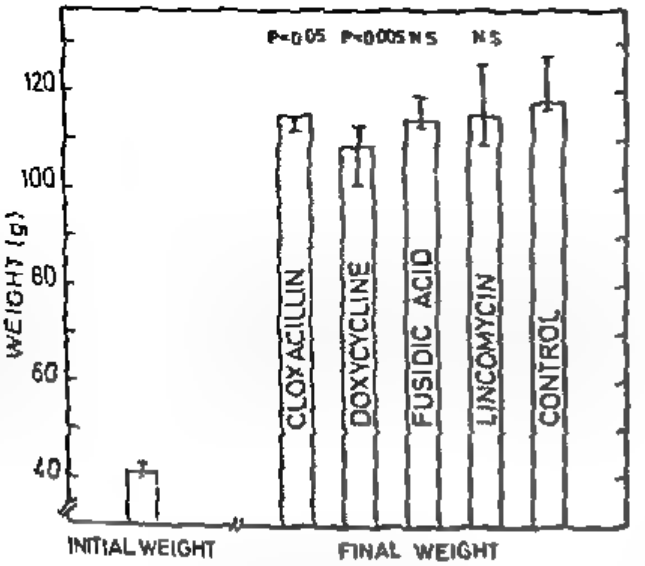

Figure 1 Initial weight and weight after 14 days of medication. (Median with 25- and 75-fractiles)

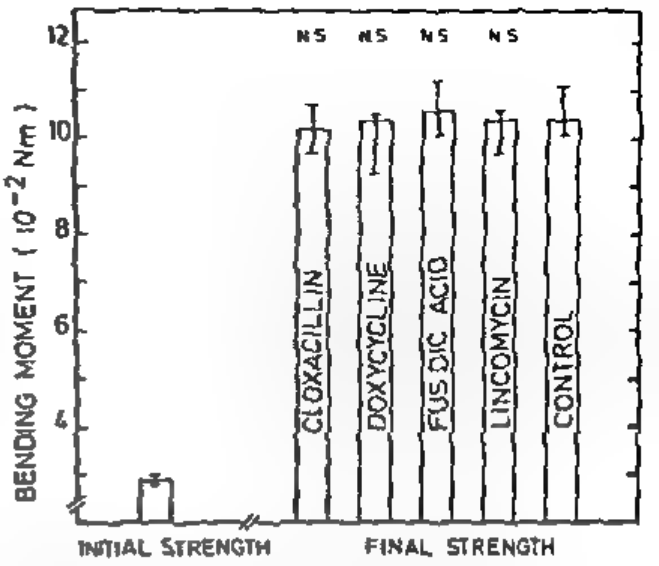

Figure 3 Bending moment necessary to produce fracture in the tibia diaphysis at the beginning of the experiment and after 14 days of medication (Median with 25 and 75-fractiles)

neither in torsion of the left femur diaphysis, nor in bending of the right distal femur diaphysis or of the right tibia diaphysis (Figure 3)

Testing of the skin wounds revealed no significant tensile strength difference between the antibiotic treated rats and the controls Tensile strength of intact skin from the doxycycline, the fusidic acid or the lincomycin rats was, however, significantly reduced compared with skin from controls (22, 23 and 19 per cent, respectively) (Figure 4)

DISCUSSION

The main features of the present study in young rats are that cloxacillin and doxy-

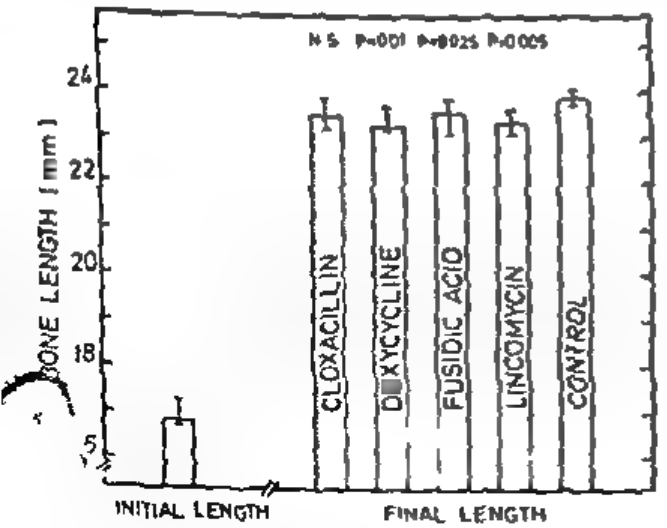

2 Initial length of right femur and length days of medication. (Median with 25- and

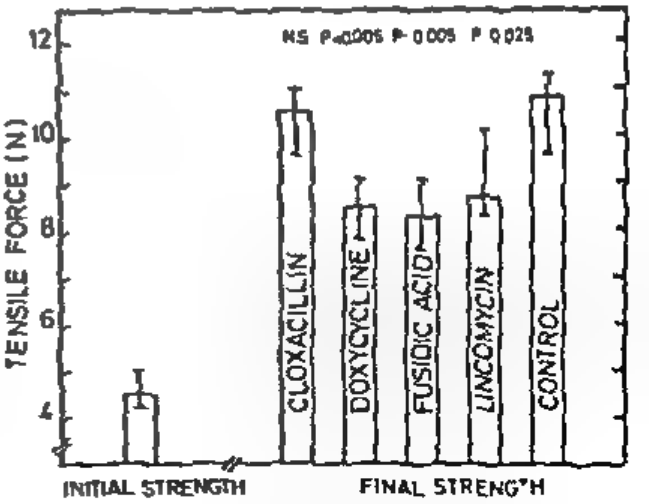

Figure 4 Tensile force necessary to pull apart the intact skin specimens at the beginning of the experiment and after 14 days of medication (Median with 25 and 75 fractiles)

available. However, a method for determination of the concentration of fusidic acid in rat plasma was obtained from Leverne Kemiske Fabrik (Copenhagen, Denmark).

On the first day of medication a 15 mm long skin incision was made on the left side of the back of the rats. The wound was closed with three interrupted stitches as previously described (Engesæter & Ribe 1978). The animals were killed with ether after 14 days of medication. Immediately after death the femora and the tibiae were dissected free. The length of the femur (from the top of the capitulum to the distal end of the medial condyle) was measured with a sliding calliper (accuracy of 0.01 mm). Until the hand of testing (less than 2 hours) the femora were kept in isotonic saline solution at room temperature (at about 20°C). The left femur diaphysis was tested in tension and the right distal femoral metaphysis in bending according to methods described previously (Engesæter et al. 1978).

For practical reasons the tibiae were frozen (−20°C) for 5 days before testing of bending strength. After thawing (to 20°C) and in a wet condition the proximal half of the right tibia diaphysis was divided laterally relative to the distal half.

Skin from the left side of the back containing the healing wound and intact skin from the corresponding right side were removed at intervals of 10–11 days. After thawing the tensile strength of the wounded and intact skin specimens was measured as previously described (Engesæter & Ribe 1978).

In addition to these 60 rats described, 10 animals were killed at the start of the experiment to obtain origin values for femur length, tensile strength of intact skin and bending strength of the tibia diaphysis.

The mean with 25 and 75 percentiles was used to express the average and the dispersion of the measured values. Statistical significance was evaluated by the Wilcoxon test for two samples (Mann–Whitney test) and differences were considered significant at $P < 0.05$ (Bloom & Ericson 1979).

RESULTS

In the middle of the experiment plasma concentrations of the antibiotics were measured 1, 2, 6 and 12 hours after medication (Table 1).

All animals grew rapidly during the experiment (Figure 1) but the clindamycin and the doxycycline treated rats had, at the end of the medication period, slightly lower body weights (2 and 2 g, respectively) than the control rats.

The influence of the antibiotics on longitudinal growth of the femur is illustrated in Figure 2. As compared with controls the femora of animals receiving doxycycline, fusidic acid or lincomycin were slightly shorter (1–2 per cent).

No significant difference, however, is detected in the mechanical properties of the femora from any of the antibiotic treated groups when compared with the controls

Table 1. Dose and plasma concentrations of the antibiotics on the 7th day of medication. The concentrations were measured in five rats in each group (Mann–Whitney 25 and 75 percentiles)

Antibiotic	Dose (mg/kg/12 h)	Plasma concentration (μg/ml) at varying intervals after injection			
		1 h	2 h	6 h	12 h
Clindamycin	240	13 (10–18.5)	>20	>20	>20
Doxycycline	25.5	50 (45–63)	45 (40–47)	20 (18–23)	13 (12–13)
Fusidic acid	238	28 (28–31)	20 (19–22)	12 (10–18)	03 (02–03)
Lincomycin	95	8 (4–8)	>10	>10	>10

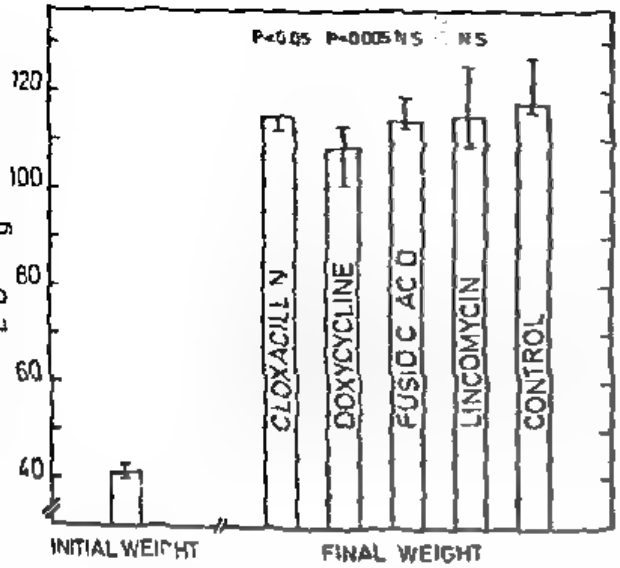

Figure 1 Initial weight and weight after 14 days of medication (Median with 25- and 75 fractiles)

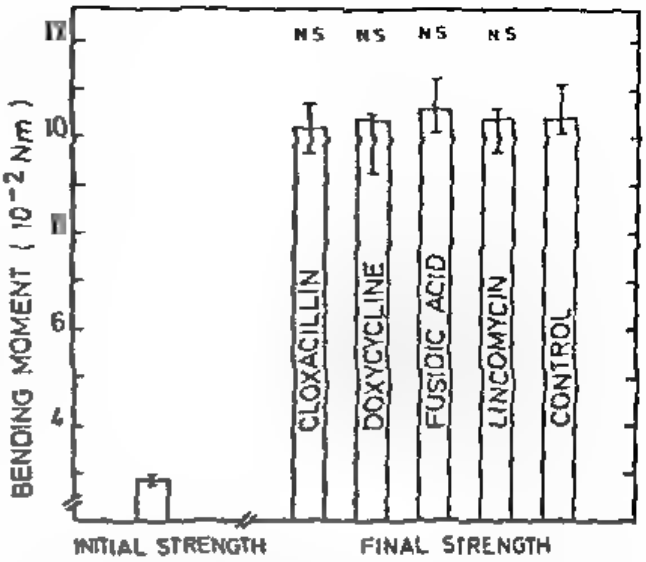

Figure 3 Bending moment necessary to produce fracture in the tibia diaphysis at the beginning of the experiment and after 14 days of medication (Median with 25 and 75 fractiles)

neither in torsion of the left femur diaphysis, nor in bending of the right distal femur diaphysis or of the right tibia diaphysis (Figure 3)

Testing of the skin wounds revealed no significant tensile strength difference between the antibiotic treated rats and the controls Tensile strength of intact skin from the doxycycline, the fusidic acid or the lincomycin rats was, however, significantly reduced compared with skin from controls (22, 23 and 19 per cent, respectively) (Figure 4)

DISCUSSION

The main features of the present study in young rats are that cloxacillin and doxy-

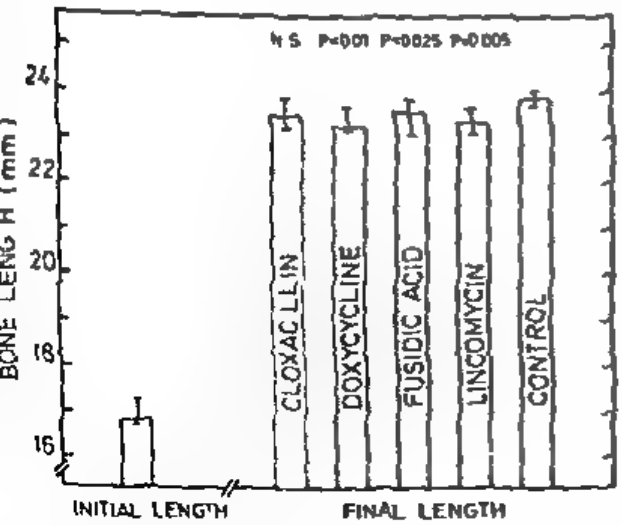

Figure 2 Initial length of right femur and length after 14 days of medication. (Median with 25 and 75 fractiles)

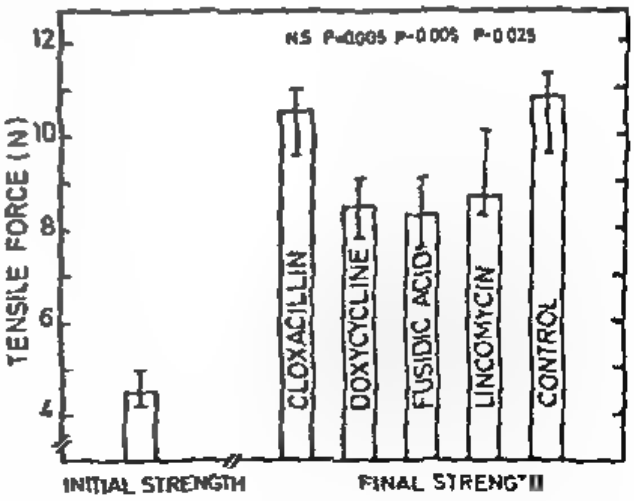

Figure 4 Tensile force necessary to pull apart the intact skin specimens at the beginning of the experiment and after 14 days of medication (Median with 25 and 75 fractiles)

cycline caused reduced weight gain and that doxycycline, fusidic acid and lincomycin caused both a reduced longitudinal growth of the femur and a reduced tensile strength of intact skin. No influence of any of these antibiotics could be detected on the mechanical properties of bones or skin wounds.

The doses of antibiotics given, expressed as mg/kg/day, are 2–12 times higher than the recommended maximal human doses (Goodman & Gilman 1975, Otten et al. 1975). However, the plasma concentrations, which are more important, compared well with therapeutic levels in man (Otten et al. 1975).

The observed reduced weight gain in the rats receiving cloxacillin or doxycycline could be caused by an intestinal dysfunction, due for example, to disturbed intestinal flora or to peritonitis following the intraperitoneal injections. The latter seems, however, less likely as adhesions of the intestines were only found in a few of the doxycycline treated rats.

Rats receiving doxycycline, fusidic acid or lincomycin had shorter femora and a lower tensile strength of intact skin than the controls. These drugs exert their antimicrobial effect through inhibition of the protein synthesis which may indicate a possible explanation for our observations. In accordance with this doxycycline and fusidic [illegible] are known to influence the protein [illegible] in mammalian cells (Morgan & [illegible]ough 1972, Vazquez 1974, Wynn 1965). Lincomycin, however, is supposed to inhibit the protein synthesis only in bacterial ribosomes (Vazquez 1974).

A possible explanation for the mechanical impairments observed in the present study and in the preceding oxytetracycline experiment may be an inhibition of the cross linking of collagen (Bailey et al. 1974). The enzyme lysyl oxidase is essential in the first step of cross link formation and it depends on copper as a co-factor (Siegel et al. 1970). Doxycycline and oxytetracycline are both known to have chelator properties and may inhibit the enzyme by binding copper (Lancet 1978).

In humans it has been proposed that fusidic acid promotes wound healing (Taylor & Bloor 1962). This effect was ascribed to a proposed anabolic effect of the antibiotic. However, in an experiment with rats Calnan & Fry (1962) could not find any effect on wound healing with 90 mg fusidic acid per os/kg/day (plasma concentrations were not measured). This finding is consistent with our results.

The present study and the previous oxytetracycline study indicate that several antibiotics may impair the mechanical properties of bone or skin in rats. The mechanisms responsible for these effects remain unclear. Collagen is, however, the principal protein in both bone and skin and as this protein is responsible for a major part of the strength in both tissues, it seems worthwhile to elucidate further the effects of these antibiotics on collagen.

REFERENCES

Bailey, A. J., Robins, S. P. & Balian, G. (1974) Biological significance of the intermolecular crosslinks of collagen. *Nature (Lond.)* 251: 105–109.

Calnan, J. & Fry, H. J. H. (1962) Wound healing in rats with the antibiotic Fucidin. *Brit. J. Pharmacol.* 19: 321–323.

Cohlan, S. Q., Bevelander, G. & Tismar, T. (1963) Growth inhibition of prematures receiving tetracycline. *Amer. J. Dis. Child.* 105: 453–461.

Diem, K. & Lentner, C. (eds.) (1975) Documenta Geigy. *Scientific tables*. 7th ed. pp. 810. Ciba-Geigy Ltd. Basle.

Engesæter, L. B., Ekeland, A. & Langeland, N. (1978) Methods for testing the mechanical properties of the rat femur. *Acta orthop. scand.* 49: 512–518.

Engesæter, L. B. & Skar, A. G. (1978) Effects of oxytetracycline on the mechanical properties of bone and skin in young rats. *Acta orthop. scand.* 49: 529–534.

Goodman, L. S. & Gilman, A. (eds.) (1975) *The pharmacological basis of therapeutics*. 5th ed. pp. 1704. Macmillan Publ. Co. New York.

Gudmundson, C. (1971) Oxytetracycline-induced fragility of growing bones. An experimental study in rats. *Clin. Orthop.* 77: 284–289.

Jalling, B., Malmborg, A. S., Lindman, A. & [illegible]

Boreus, L O (1972) Evaluation of a micromethod for determination of antibiotic concentrations in plasma *Europ J clin Pharmacol* 4, 150–157

Lancet (1978) Collagen in health and disease *Lancet* 1, 1077–1079

Morgan, T & Ribush N (1972) The effect of oxytetracycline and doxycycline on protein metabolism *Med J Aust* 1, 55–58

Otten, H, Plempel, M & Siegenthaler, W (eds.) (1975) *Antibiotika Fibel* 4th ed pp 1039, Georg Thieme Verlag, Stuttgart.

[illegible] (1970) [illegible] antibiotic fusidic acid *Brit med J* 1, 1400–1404

Correspondence to Lars B Engesæter, Institute for Surgical Research, Rikshospitalet, Oslo 1, Norway

Acta orthop scand. 50 251–253, 1979

A CASE OF ALBRIGHT'S SYNDROME TREATED WITH CALCITONIN

ÅKE HJELMSTEDT & SVERKER LJUNGHALL

Departments of Orthopaedic Surgery and Internal Medicine, University Hospital Uppsala Sweden

A 23 year-old woman with Albright's syndrome (polyostotic fibrous dysplasia of bone, precocious puberty and irregular cutaneous pigmenta-

Key words calcitonin, calcium metabolism fibrous dysplasia side effects

Accepted 13 ix 78

Fibrous dysplasia of bone is a disorder in which an excessive proliferation of fibrous tissue disrupts the normal architecture of bone The disorder sometimes only affects one bone but frequently engages several areas, often symmetrically, throughout the skeleton The pathogenesis is obscure For equally unknown reasons there is an association between the polyostotic form of the disease and various endocrinopathies, among them thyroid, parathyroid and adrenal disorders The triad polyostotic fibrous dysplasia, precocious puberty and hyperpigmentation has become known as Albright's syndrome (Albright et al. 1938)

The progressive replacement of bone by fibrous tissue may result in severe deformities. Limited surgical corrections can be helpful but until recently no medical treatment for the bone disease has been reported

Calcitonin is a polypeptide hormone with potent inhibitory effects on bone resorption (Hirsch & Munson 1969) and therapy with calcitonin has proven to be of considerable value in disorders characterized by an increased bone turnover, e g Paget's disease (Kanis et al 1975) It has also been reported that when calcitonin was given to patients with fibrous dysplasia the serum concentrations of alkaline phosphatase decreased together with the urinary excretion of hydroxyproline (Bell et al 1970, Morii et al 1971) These short-term metabolic effects suggested that the pathological skeletal turnover might be affected and consequently raised the hope of some beneficial clinical value of calcitonin also in this disease As Albright's syndrome is a rare disorder no controlled studies seem to have been performed We have, therefore, considered it worthwhile to report our experience in a case treated with calcitonin for 1 year

0001–6470/79/030251 03$02.50/0

© 1979 Munksgaard, Copenhagen

CASE REPORT

A 3-year-old girl was diagnosed as having Albright's syndrome because of typical cutaneous pigmentations and fibrous dysplasia of both femurs At the age of [illegible] she had her first fracture after a minor trauma Since then and up to the age of 23, when the present study was undertaken, she had experienced at least 15 fractures, primarily of the arms and legs, and had been submitted to 10 corrective osteotomies. She was grossly disabled and confined to a wheel chair Pubertas precox was experienced at the age of 9, at which time laparotomy disclosed normal post-pubertal gynaecological findings as did a biopsy from one ovary Menstruations thereafter have been slightly irregular

At the time of admission examination disclosed marked malformations of the extremities and several irregular pigmentations. Areas of fibrous dysplasia were roentgenologically demonstrated throughout the skeleton. She had a normal routine laboratory profile including blood picture, serum electrolytes, tests of hepatic and renal function and urinalysis Thyroid function was normal, T_4 100 nmol/l, T_3 3 0 nmol/l, TSH 4 mU/l, but there was no significant rise of the TSH levels after i v injection of 200 µg TRH A thyroid scan was normal and she had a normal iodine uptake. The serum cortisol levels displayed a normal circadian rhythm and the urinary excretion of oxogenic steroids were in the lower part of the normal range Both LH and FSH serum concentrations were normal and after injection of LRH a signifi- increase was demonstrated. Growth hormone ons were repeatedly around 3 ng/ml, without significant suppression during an intravenous glucose tolerance test, whereas a marked rise was noted following the injection of insulin The glucose tolerance was normal (T 1/2 = 48 min) as were the serum insulin levels. The serum calcium, phosphate, parathyroid hormone and calcitonin concentrations were all normal but the serum alkaline phosphate activity was greatly increased, exclusively due to an increase in the bone [illegible] severe nausea and vomiting, appearing after a few days, the dose was reduced after 1 month to 8 MRC units, which was maintained during the following 11 months. During treatment no significant metabolic effects could be detected, serum alkaline phosphatases remained high as did the urinary excretion of hydroxyproline (Table 1). Nor was there any clinical response She continued to develop fractures also during therapy and at the end of one year of treatment increasing discomfort with diffuse bone and muscle pain was experienced. When therapy was stopped these complaints disappeared within a week.

DISCUSSION

In this patient all the typical features of Albright's syndrome were present The metabolic evaluation suggested an accelerated bone turnover with constantly raised serum alkaline phosphatases and a marked increase in the urinary hydroxyproline excretion. Therapy with calcitonin, however, although useful in other disorders characterized by increased bone resorption and formation (Gray & Ontjes 1975) was of no apparent clinical benefit in the present case, nor could any significant metabolic changes be detected

Table 1 Laboratory effects of treatment with calcitonin in a case of Albright's syndrome

		Normal range	Months of treatment 0	1	12
Serum	calcium (mmol/l)	2 20–2 60	2.35	2 35	2 25
	phosphate (mmol/l)	0 76–1 44	0 80	0 80	0 80
	alkaline phosphatase (µkat/l)	0 8–4 8	26	26	25
	parathyroid hormone (ng/ml)	1 1–2 5	1 6		
Urinary	calcium (mmol/24 h)	–5	3 5	4 2	3 4
	phosphate (mmol/24 h)	–25	20	25	15
	hydroxyproline (mg/24 h)	6 –22	109	210	167
Daily dose of calcitonin (MRC units)			—	80	8

Several factors might have contributed to this picture

It seems probable that calcitonin is less important for skeletal homeostasis than for calcium homeostasis (Potts 1969) Further, in the present case the biochemical disturbances presented are more likely to have reflected continuous bone repair and remodelling rather than resorption of mineralized bone and hence probably there is inadequate theoretical basis for therapy with calcitonin in fibrous dysplasia

During the major part of the time the dosage of calcitonin was comparatively low, 8 MRC units per day Although we were, in the present study, unable to determine any effects of the drug the dosage was similar to that used by others (Morii et al 1971) Further, no metabolic effects were noted during the first treatment month with a tenfold higher dose Thus, it is unlikely that the lack of response was due to inadequate calcitonin dosage

The original intention to use a higher maintenance dose turned out to be impossible because of various side reactions Nausea and vomiting, which were the initial complaints, are well known and generally temporary, as in the present case The diffuse pain of bone and muscle, on the other hand, which appeared after several months treatment seems to be less frequent. The underlying mechanism is unknown Since the pain persisted for several weeks during calcitonin therapy but subsided within days after cessation of the treatment a relationship with the calcitonin administration seems probable

It has been suggested that the endocrine manifestations of Albright's syndrome are caused by a hypothalamic hypersecretion of releasing hormones (Warrick 1973) However, in the present case the basal levels of the serum pituitary hormone concentrations were not increased as would have been expected in the case of continuous hypothalamic stimulation Furthermore, adequate pituitary responses were obtained after the administration of the corresponding releasing hormones, which also supports a normal hypothalamic-pituitary relationship

REFERENCES

Albright, F, Scoville, B & Sulkowitch, H W (1938) Syndrome characterized by osteitis fibrosa disseminata, areas of pigmentation and a gonadal dysfunction *Endocrinology* **22**, 411–421

Bell, N H, Avery, S & Johnston, Jr C. C (1970) Effects of calcitonin in Paget's disease and polyostotic fibrous dysplasia *J clin Endocr* **31**, 283–290

Gray, T K & Ontjes, D A. (1975) Clinical aspects of thyrocalcitonin *Clin Orthop* **111**, 238–256

Hirsch, P F & Munson, P L (1969) Thyrocalcitonin *Physiol Rev* **49**, 548–622.

Kanis, J A., Fitzpatrick, K. & Strong, J A (1975) Treatment of Paget's disease of bone with porcine calcitonin clinical and metabolic responses *Quart J Med* **175**, 399–413

Morii, H, Tanae, A., Ibayashi, H & Nakao, K. (1971) Effects of calcitonin in metastatic bone carcinoma, osteoporosis, polyostotic fibrous dysplasia and hypercalcemia. *Endocr jap* **18**, 81–90

Potts, Jr, J T (1969) NIH Clinical Staff Conference Polypeptide hormones and calcium metabolism *Ann intern. Med* **70**, 1243–1265

Warrick, C K. (1973) Some aspects of polyostotic fibrous dysplasia. Possible hypothesis to account for the associated endocrinological changes. *Clin Radiol* **24**, 125–138

Correspondence to Sverker Ljunghall, M D., Department of Internal Medicine, University Hospital, S-750 14 Uppsala, Sweden

Acta orthop scand 50, 255–259, 1979

NORMAL GRIP STRENGTH

K.-G THORNGREN & C O WERNER

Department of Orthopaedic Surgery, University Hospital of Lund, Lund, Sweden

The normal grip strength was determined with the Martin Vigorimeter in 450 men and women aged 21–65 years The grip strength decreased steadily with increasing age Men were stronger than women and in both sexes the dominant hand was the strongest The ratio dominant/non dominant hand varied only slightly with age and sex and it could thus be a useful parameter in evaluation of grip strength under pathological conditions

Key words grip, hand, strength

Accepted 19 1 79

A diminished grasping force in the hand is often seen after injury To determine this is one way of establishing the degree of invalidity Determinations can be made preoperatively and postoperatively to assess the results of surgery in the arm and hand Various methods have been developed to determine the grip strength using a number of mechanical and electrical devices (Hunsicker & Donelly 1955, Wright 1959, Funfgeld 1966, Hallén et al 1966, Mannerfelt 1966, Schmidt & Toews 1970, Brewer [illegible] 1975, Heyward et al 1975)

Most previous studies have involved groups isolated according to age, sex or vocation, such as college students or steel workers (Kjerland 1953, Pierson & O'Connell 1962, Anderson & Cowan 1966, Klimt 1969, Schmidt & Toews 1970 Kellor et al 1971, Heyward et al 1975, Nwuga 1975)

The aim of the present investigation was to determine the normal grip strength in an unselected population of adults over a wide age range These determinations may constitute a basis for future comparison with pathologic conditions.

PATIENTS AND METHODS

The investigation included 450 probands (225 men and 225 women) aged 21–65 years For each 5-year interval (21–25, 26–30 etc) 25 men and 25 women were investigated. They were randomly selected from among ambulatory patients, relatives to patients, and personnel at the Orthopaedic Clinic, University Hospital of Lund, without a history of trauma or pain in the upper extremity, and they thus represented various occupations. To determine the variations in grip strength on different occasions 10 men and 13 women were investigated on three different occasions at intervals of some weeks.

The Martin Vigorimeter (Gebruder Martin, Tuttlingen, Germany), which was used, is a dynamometer with a rubber balloon which is compressed in the hand The air-pressure within the balloon is registered in kilopond per square centimetre (1 kp/cm² = 98 1 kPa) on a manometer via a rubber tube connection Three sizes of balloons are available (diameter 4, 5 and [illegible] cm) and in the present study the large balloon was used for men and the medium one for women

Three consecutive determinations were performed alternating the dominant with the non-dominant hand The proband was sitting with the elbow flexed 30° and instructed to exert maximal pressure on the balloon after having applied a comfortable grip around the balloon with the con-

0001 6470/79/030255–05$02.50/0

© 1979 Munksgaard, Copenhagen

nection tube coming out between the thumb and the index finger. The mean of three values for each hand was determined and the ratio dominant/non-dominant hand was calculated.

RESULTS

In general the grip strength decreased with increasing age (Figure 1, Tables 1 and 2). The values were generally higher in the dominant hand. Men were stronger than women for each age interval.

The overall ratio dominant/non-dominant hand was 1.07 ± 0.11 with little variation with age or between sexes (Tables 1 and 2).

The grip strength on different occasions showed highly significant ($P < 0.001$) differences in absolute values both in men and women (Table 3). There was no significant interaction between occasion and hand, i.e. the same hand was the strongest on the different occasions.

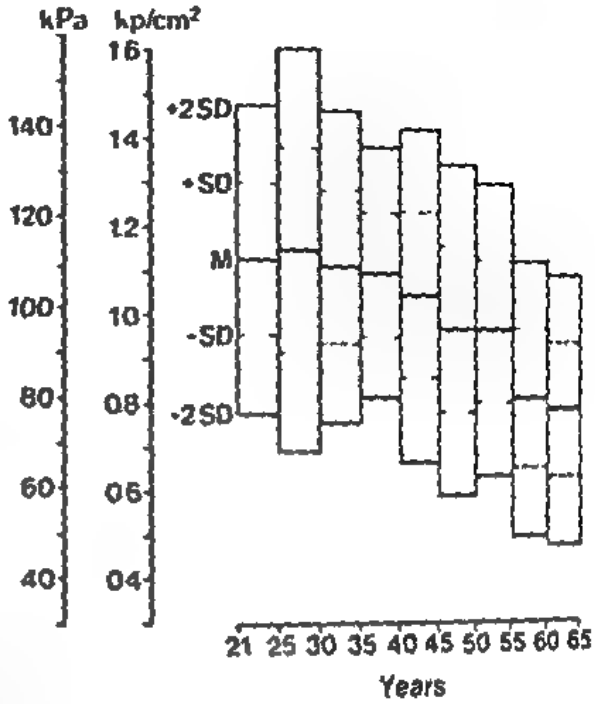

Table 1. Grip strength in normal men and women of various ages for the dominant hand (DH) in kp/cm² and the ratio dominant hand/non-dominant hand (DH/NDH). Each value is based on 25 determinations. Statistical analysis of males vs. females (Student's t-test, one tailed). The mean value for the non-dominant hand (NDH) can be calculated from the values of DH and the ratio. The NDH showed the same sex difference and standard deviation as the DH values.

Age	Men		Women	
	DH	DH/NDH	DH	DH/NDH
21 – 25	1.13 ± 0.18	1.07 ± 0.08	1.03 ± 0.16*	1.10 ± 0.12 NS
26 – 30	1.16 ± 0.23	1.05 ± 0.08	0.96 ± 0.16***	1.10 ± 0.08*
31 – 35	1.12 ± 0.17	1.06 ± 0.08	0.95 ± 0.17***	1.07 ± 0.14 NS
36 – 40	1.10 ± 0.18	1.07 ± 0.10	0.95 ± 0.19**	1.06 ± 0.15 NS
41 – 45	1.06 ± 0.14	1.05 ± 0.10	0.90 ± 0.19***	1.09 ± 0.12 NS
46 – 50	0.97 ± 0.19	1.03 ± 0.08	0.82 ± 0.22**	1.06 ± 0.17 NS
51 – 55	0.97 ± 0.17	1.05 ± 0.10	0.79 ± 0.18***	1.12 ± 0.11*
56 – 60	0.81 ± 0.16	1.09 ± 0.13	0.74 ± 0.17 NS	1.05 ± 0.14 NS
61 – 65	0.79 ± 0.16	1.06 ± 0.16	0.66 ± 0.18**	1.09 ± 0.13 NS

Values = means ± standard deviations
*** $P < 0.001$
** $0.001 < P < 0.01$
* $0.01 < P < 0.05$
NS $P > 0.05$

Table 2 Regression analysis of grip strength in normal men and women Grip strength in kp/cm² (y) for various ages (x) of dominant hand (DH), non-dominant hand (NDH) and ratio DH/NDH Correlation coefficient (r) and its significance

Men	DH	$y = -9.5\ 10^{-3} \times +1.43$	$r = -0.571^{***}$
	NDH	$y = -9.1\ 10^{-3} \times +1.35$	$r = -0.547^{***}$
	DH/NDH	$y = 1.6\ 10^{-4} \times +1.05$	$r = 0.020^{NS}$
Women	DH	$y = -8.9\ 10^{-3} \times +1.25$	$r = -0.549^{***}$
	NDH	$y = -8.0\ 10^{-3} \times +1.16$	$r = -0.507^{***}$
	DH/NDH	$y = -4.5\ 10^{-4} \times +1.10$	$r = -0.045^{NS}$

*** $P < 0.001$
NS $P > 0.05$

Table 3 Analysis of variance for values of grip strength (100 kp/cm²) determined in normal men on different occasions (Similar significance of F was found in the tested women)

Source of variation		Sum of squares	DF	Men square	F
Main effects					
Occasion		690	2	345.4	38.65***
Hand		1126	1	1126.6	126.09***
Proband		6125	9	680.5	76.16***
2-way interactions					
Occasion	hand	5	2	2.9	0.32 NS
Occasion	proband	2792	18	155.1	17.36***
Hand	proband	656	9	72.9	8.16***
Residual		160	18	8.9	
Total		11,558	59	195.9	

*** $P < 0.001$
NS $P > 0.05$

Table 4 Analysis of variance for the ratio of values in per cent (dominant hand/non dominant hand) of grip strength determined in normal men on different occasions (Similar significance of F was found in the tested women)

Source of variation	Sum of squares	DF	Men square	F
Main effects				
Occasion	3	2	1.6	0.10 NS
Proband	1164	9	129.3	8.42***
Residual	276	18	15.3	
Total	1444	29	49.7	

*** $P < 0.001$
NS $P > 0.05$

The ratio dominant/non-dominant hand did not show any significant difference when tested sequentially with an interval of some weeks (Table 4)

DISCUSSION

The data shown here are meant to be used as a reference in evaluation of grip strength disabled because of disease or trauma

It is well known that the grip strength decreases with increasing age (Kjerland 1953, Anderson & Cowan 1966, Schmidt & Toews 1970, Kellor et al 1971) and that it is correlated with body weight and height (Pierson & O'Connell 1962, Anderson & Cowan 1966, Schmidt & Toews 1970, Petrofsky & Lind 1975)

This investigation showed age-correlated values for both men and women drawn from the general population, with the determinations performed as is usual in everyday clinical practice

Since similar testing devices have not been used, a comparison of the absolute values from this investigation with those of others (Kjerland 1953, Wright 1959, Pierson & O'Connell 1962, Anderson & Cowan 1966, Schmidt & Toews 1970, Kellor et al. 1971, Heyward et al 1975, Nwuga 1975) is not possible

Most previous investigators have found a sex difference in grip strength, men have more powerful handgrips than women (Kjerland 1953, Anderson & Cowan 1966, Kellor et al 1971, Nwuga 1975) This was confirmed in the present investigation The difference is actually even greater than registered due to the difference in balloon size used for the two sexes. A small balloon, such as that used in testing women, gives higher values (Fünfgeld 1966)

In agreement with Schmidt & Toews (1970), who tested men, the dominant hand was generally found to be the strongest. They found the dominant hand to be stronger by a factor dominant/non-dominant hand of 1 03, which is in accordance with the ratio 1 07 ± 0 11 observed in the present investigation

Diurnal and day-to-day variations which influence the grip strength have previously been reported by Cousins (1955) Wright (1959), Lee et al (1974), Rikli (1974). Such variations, however, are diminished when the ratio of the value for the two hands is calculated

The ratio value was thus found to be a stable parameter, showing little difference for the various age groups both in men and women Also when tested on various occasions no significant differences were found Thus the ratio of the dominant hand over the non-dominant hand is an accurate means of evaluating grip strength

REFERENCES

Anderson, W F & Cowan N R (1966) Hand grip pressure in older people *Brit J prev soc Med* 20, 141–147

Brewer, K., Guyatt A R & Scott, J T (1975) Comparing grip strength *Physiotherapy* 61 118

Cousins, G F (1955) Effect of trained and untrained testers upon the administration of grip strength tests *Research Quarterly* 26 273–276

Fünfgeld E W (1966) Vigorimeter Zur Kraftmessung der Hand und zur Simulationsprüfung *Dtsch med Wschr* 91 2214–2216

Hallén, L G, Lindahl O & Lindqvist B (1966) Simple means of measuring the power of the hand in rheumatic patients *Nord Med* 75 380–381

Heyward V, McKeown, B & Geeseman, R. (1975) Comparison of the Stoelting hand grip dynamometer and linear voltage differential transformer for measuring maximal grip strength *Research Quarterly* 46 262–266

Hunsicker, P A & Donnelly, R J (1955) Instruments to measure strength. *Research Quarterly* 26 408–420

Kellor, M, Frost, J, Silberberg N Iversen, I & Cummings, R. (1971) Hand strength and dexterity *Amer J occup Ther* 25 77–83

Kjerland, R N (1953) Age and sex differences in performance in motility and strength tests. *Proc Iowa Acad Sci* 60 519–523

Klimt F (1969) Die Handkraft im Kindesalter *Arch Kinderheilk* 179, 1–12

Lee, P, Baxter, A, Dick, W C & Webb, J (1974) An assessment of grip strength measurement in rheumatoid arthritis. *Scand J Rheumat* 3, 17–23

Mannerfelt, L. (1966) Studies on the hand in ulnar nerve paralysis. *Acta orthop scand*, Suppl 87

Nwuga, V C. (1975) Grip strength and grip endurance in physical therapy students. *Arch phys Med* 56 296–300

Petrofsky, J S & Lind, A R (1975) Isometric strength, endurance, and the blood pressure and heart rate responses during isometric exercise in healthy men and women, with special reference to age and body fat content. *Pflügers Arch ges Physiol* 360, 49–61

Pierson, W R. & O'Connell, E R (1962) Age, height, weight and grip strength. *Research Quarterly* 33, 439–443

Rikli, R (1974) Effects of experimenter expectancy set and experimenter sex upon grip strength and hand steadiness scores. *Research Quarterly* 45, 416–423

Schmidt, R T & Toews, J V (1970) Grip strength as measured by the Jamar Dynamometer *Arch phys Med* 51, 321–327

Wright, V (1959) Some observations on diurnal variations of grip *Clin. Sci* 18, 17–23

Correspondence to C O Werner, M D Department of Orthopaedic Surgery, The University Hospital, S-221 85 Lund, Sweden

Acta orthop scand 50, 261–268, 1979

CLAVICULAR FUNCTION*

ANNE ELISABETH LJUNGGREN

Anatomical Institute, Anthropological Department, University of Oslo Oslo, Norway

This is a survey of the functional variation of the clavicle, in particular with regard to its adaptability, the bone being an essential link in the shoulder girdle The presence of a clavicle, and its shape, size and position are discussed from the point of view of stability and mobility, and the role of the bone regarding circulation, pulmonary ventilation and muscular tension is pointed out It is stated that the clavicle contributes significantly to the stability of the shoulder girdle, and that in man the presence of this bone represents an increase in the degree of freedom of the upper extremity mobility pattern, dependent on the transversal shape of the thoracic diameter The precondition for the clavicle to function appropriately is that its curvature fits in with the ligamentous pull

Key words axes, clavicle, function, mobility, stability

Accepted 29 x 78

The human clavicle is the only bone of the shoulder girdle forming a synovial joint with the trunk The bone is connected strongly to a number of muscles, and accordingly to fascies Through the fascies of the neck and the pectoral region the clavicle is functionally joined with the internal and external jugular veins as well as with the subclavian vein By intermittent contraction of the muscles related to the fascies, and by movement of the clavicle, the structures mentioned work jointly as a circulation and ventilation pump for the arm, head and neck

The word "clavicula" is a diminutive of "clavis", key, but its meaning may equally well be door handle Medially the clavicle has a ventrally-directed convexity, laterally a dorsally-directed one The latter shows the greatest curvature and is located in the lateral third of the bone (Figure 1)

In man the clavicle is one of the bones showing the highest variability in shape (Grant 1971) Its curvatures and thickness to a high degree vary according to the attachments of muscles and ligaments Muscular individuals are found to exhibit thick and curved clavicles, and males have thicker and more curved clavicles than females (Cunningham 1931, Martin & Saller 1959) In accordance with the usually greater force and higher activity of the right-side extremity in right-handed people, the right-side clavicle is as a rule thicker and more curved than the left-side one (Martin & Saller 1959, Grant 1971)

Stabilization of the shoulder

The medial two-thirds of the clavicle are approximately circular or triangular in cross section, a shape consistent with axial pressure or pull Its lateral third, corresponding to the acromion, has a relatively flat superior and inferior surface, a shape compatible with pull from muscles and ligaments.

* Lecture delivered as partial fulfilment of the requirements for the Doctor's Degree of Philosophy, University of Oslo 28 x.77

0001 6470/79/030261 08$02.50 0

© 1979 Munksgaard, Copenhagen



specimens The clavicular attachments of the ligaments are indicated by circular areas, their directions by thick, stippled arrows, expressing their location caudal to the bone Regarding the long axis of the clavicle, the costoclavicular ligament has a ventrally directed moment, the coracoclavicular ligament a dorsally directed moment

The clavicle is connected to several ligaments, most of which are essential for the stability of the shoulder girdle In this presentation only the costoclavicular and coracoclavicular ligaments are dealt with (Figure 1) Because of their clavicular attachments (near to the ventral and dorsal convexity, respectively) and because of their orientation, the moments of the forces represented by the two ligaments are oppositely directed as regards the estimated long axis of the clavicle (Figure 1) In this way equilibrium may be maintained in the plane perpendicular to the axis, i e in an approximately sagittal plane Because of their course and attachments the ligaments increase stability in other planes as well

The clavicle slopes mediocaudally (Figure 2) Thus, the mass of the arm is transmitted to the clavicle (to a high degree through the coracoclavicular ligament), and through the clavicle to the sternoclavicular joint and to the sternum The resultant vector W (Figure 2) is resolved into one component in the direction of the long axis of the clavicle (N), giving normal stress on the sternal two-thirds of the bone, and into a second component (T), perpendicular to the first one, tending to move the clavicle laterally and caudally As is shown in Figure 2, the axially running vector N increases when the acromial part of the clavicle is elevated This gives an increased normal stress in the sternal two-thirds of the bone and increased stability of the sternoclavicular joint, owing to the shape and orientation of the clavicular joint surface of the sternum In this way stability increases as the mass of the arms increases.

This theory is in harmony with the results of electromyographic examination Thus, Bearn (1961) did not notice electrical activity in the upper part of the trapezius muscle during static loading The clavicle is predominantly stabilized by passive structures. The unit formed by the sternum and the two attached clavicles has been compared to a yoke, accordingly, the latin word "jugulum" With reference to what is stated above only the sternal two-thirds of the clavicle is

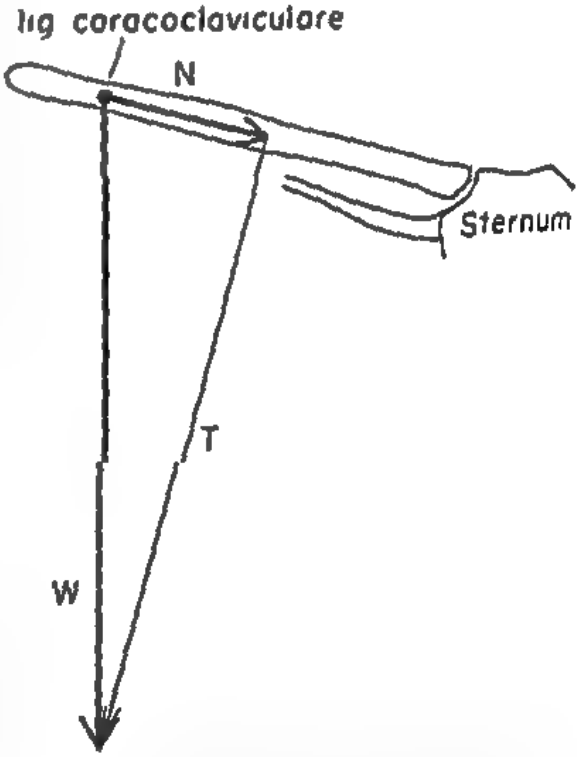

Figure 2 A model showing some stabilizing elements of the clavicle Parts of the right shoulder girdle in centrodorsal view The point of action of the vector W (the mass of the arm) is the clavicular attachment of the coracoclavicular ligament For further explanation see the text.

included in the ventral yoke As the clavicle is craniolaterally as well as craniodorsally directed, the sternal part of the bone is able to lift the acromial part, as well as the acromion and the shoulder joint, up from the thorax, and keep these structures in a lateral position. Accordingly the clavicle acts as a prop This is illustrated by the tendency for an adducted and inwardly rotated position of the shoulder girdle in the rare congenital anomaly cleido-cranial dysostosis, where among other bones, the clavicles are missing, totally or partly However, according to Inman & Saunders (1946), partial or complete resection of the clavicle in adults results in only slight deformation of the shoulder region and negligible dysfunction

According to the authors referred to above, instability and a feeling of weakness during heavy work, especially when pushing above head level, are the only difficulties of importance noted after excision of the clavicle in adults. This is compatible with the notion that the act of carrying, when pushing in a cranial direction, causes pressure in the direction of the long axis of the clavicle On the other hand, the clavicle will be exposed to pull in its longitudinal direction in hanging, when the arms are above the head, as they are in hanging on a bar or on a rope, as well as when supporting oneself on the arms on a table or on crutches

In accordance with function some mammals exhibit a clavicle in regression In the carnivores the bone is reduced, in the ungulates it has vanished (Boas & Thomson 1961) The transmitting of weight from the upper extremity to the trunk, through the coracoclavicular ligament and the sternal part of the clavicle, is a superfluous mechanism in these animals. Because they are quadruped and because of the relatively large anteroposterior diameter of their thorax, the scapula of these animals is almost vertically oriented In this way the reaction force from the ground meets the glenoid cavity directly, the direction of the reaction force hitting the surface of the cavity almost perpendicularly The mass of the body is supported on the scapula. This bone in turn is suspended in the serratus anterior muscle (Grant 1971). This suspensory mechanism, together with the reduction of the clavicle, imply a resilient connection between the forelimb and trunk, and it is in harmony with the lithe and graceful movements of the carnivores and the ability of the ungulates to leap and gallop

Functional asymmetries

Adequate stimuli for growth in length are intermittent pressure and pull (Pauwels 1957, LeGros Clark 1965) In man the clavicle is the bone first starting to ossify (according to Cunningham (1931) in the fifth foetal week) Considering also that its sternal epiphysis is the last of the epiphyses of the long bones to fuse (according to McKern & Stewart (1957) in the third decade), it seems obvious that functional asymmetries have a long period of time to leave their marks on the bone The left shoulder girdle to a great extent is used to support body weight In conformity with the fact that the clavicle is subjected to normal stress in its longitudinal direction in movements and positions where body weight is supported by means of the arms, it is reasonable to find that the left clavicle is often longer than the right one (Martin & Saller 1959, Grant 1971)

Mobility of the shoulder considering the clavicle as a link in the girdle

Excision of the clavicle is accompanied by increased mobility of the shoulder girdle, especially in the sagittal plane This characteristic is also a typical clinical sign in cleido-cranial dysostosis. Moreover, experiments with rats (Jenkins 1974) have shown that the shoulder loses its circular path of movement when the clavicle is exirpated This indicates that the presence of the clavicle allows the upper extremity more degrees of freedom (Hjortsjo 1967) However, one has to consider that since the scapula is gliding on the thorax, the path of movement of the shoulder girdle as well as

Figure 1 The right side human clavicle in craniocaudal view The estimated long axis of the bone as well as two of its most important ligaments, are drawn according to observations from dissected specimens The clavicular attachments of the ligaments are indicated by circular areas, their directions by thick, stippled arrows expressing their location caudal to the bone Regarding the long axis of the clavicle the costoclavicular ligament has a centrally directed moment the coracoclavicular ligament a dorsally directed moment

The clavicle is connected to several ligaments, most of which are essential for the stability of the shoulder girdle In this presentation only the costoclavicular and coracoclavicular ligaments are dealt with (Figure 1) Because of their clavicular attachments (near the ventral and dorsal convexity, respectively) and because of their orientation, the moments of the forces represented by the two ligaments are oppositely directed as regards the estimated long axis of the clavicle (Figure 1) In this way equilibrium may be maintained in the plane perpendicular to the axis, i e in an approximately sagittal plane Because of their course and attachments the ligaments increase stability in other planes as well

The clavicle slopes mediocaudally (Figure 2) Thus, the mass of the arm is transmitted to the clavicle (to a high degree through the coracoclavicular ligament) and through the clavicle to the sternoclavicular joint and to the sternum The resultant vector W (Figure 2) is resolved into one component in the direction of the long axis of the clavicle (N) giving normal stress on the sternal two-thirds of the bone, and into a second component (T) perpendicular to the first one, tending to move the clavicle laterally and caudally As is shown in Figure 2 the axially running vector N increases when the acromial part of the clavicle is elevated This gives an increased normal stress in the sternal two-thirds of the bone and increased stability of the sternoclavicular joint, owing to the shape and orientation of the clavicular joint surface of the sternum In this way stability increases as the mass of the arms increases.

This theory is in harmony with the results of electromyographic examination Thus Bearn (1961) did not notice electrical activity in the upper part of the trapezius muscle during static loading The clavicle is predominantly stabilized by passive structures. The unit formed by the sternum and the two attached clavicles has been compared to a yoke, accordingly, the latin word 'jugulum With reference to what is stated above only the sternal two-thirds of the clavicle is

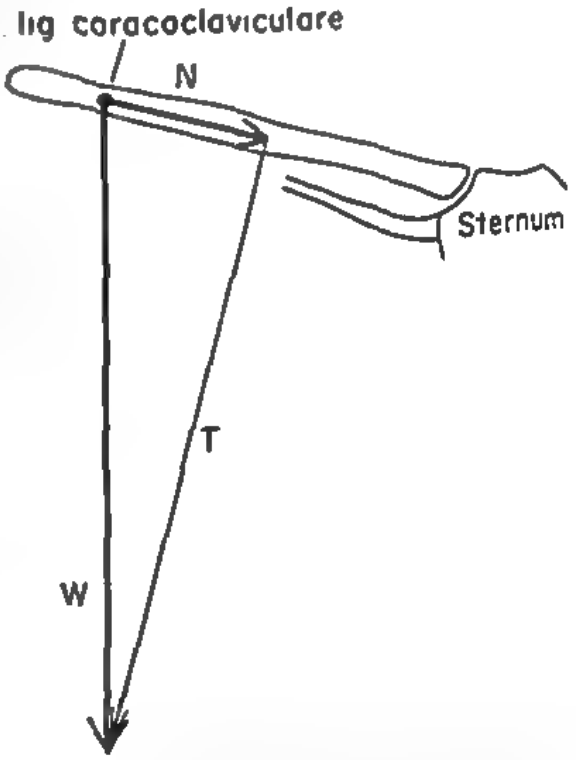

Figure 2 A model showing some stabilizing elements of the clavicle Parts of the right shoulder girdle in ventrodorsal view The point of action of the vector W (the mass of the arm) is the clavicular attachment of the coracoclavicular ligament For further explanation see the text

from a mechanical point of view, are of the spheroidal type, both of them possess three degrees of freedom, i e, ability of rotation about three axes, perpendicular to each other (Hjortsjo 1967)

Concerning the sternoclavicular joint, it is stated that the point of intersection of the three rotational axes is positioned close to the clavicular attachment of the costoclavicular ligament (Abbott & Lucas 1954, Andreasen 1960, Hjortsjo 1967)

In the transversal plane, however, the sternal joint surface exhibits a convexity directed laterally According to this the craniocaudal axis of the sternoclavicular joint is situated in the sternum (Kapandji 1970) This means that in protrusion and retraction of the shoulder girdle the sternal and acromial part of the clavicle move in the same direction True enough, in maximum retraction its sternal end protrudes ventrolaterally This may be associated with a separation between the surfaces of the sternoclavicular joint, a movement which is not perpendicular to the joint surfaces Possibly there is a craniocaudally directed rotational axis situated in the dorsal aspect of the joint space Accordingly, retraction of the shoulder girdle is an example of the way in which axes of rotation shift during movements, impeding kinematical analyses generally

The anteroposteriorly directed axis of rotation of the sternoclavicular joint obviously is situated on the clavicular side of the joint Possibly there may even be two axes (Figure 4) Because the clavicle rotates simultaneously about these two axes, and because of the presence of the disc, the sternoclavicular joint functionally corresponds to the accentuated grinding joint principle (Hjortsjo et al 1977) There is one sliding movement between the sternum and the disc (rotation about axis C_y), and one sliding movement between the disc and the clavicle (rotation about axis C_x), i e, the joint may also be classified as a double *sliding* joint Comparable kinematical problems are met with in the temporomandibular joint (Hjortsjö 1953)

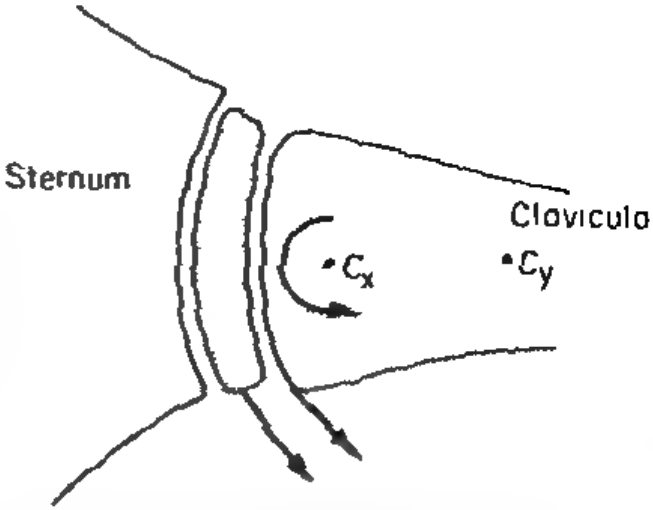

Figure 4 Schematic representation of possible rotation of the clavicle about anteroposteriorly directed axes related to the sternoclavicular joint Frontal view C_x is the centre of the medially directed convexity formed by the sternal joint surface of the clavicle and the disc C_y is the centre of the laterally directed concavity formed by the clavicular joint surface of the sternum

In order to simplify the description of the movements of the shoulder girdle, and to get a more unambiguous reference system, one often regards the axes of rotation of the shoulder girdle as if they were parallel with the three main axes of the body One exception, however, is the mediolaterally directed axis This rotational axis, which is equivalent to the long axis of the clavicle (Figures 1 and 5) is common to the two joints of the shoulder girdle The long axis of the clavicle is shown to form an acute and dorsolaterally directed angle with the transversal plane (Figures 3 and 2) Accordingly, the long axis of the clavicle intersects with the other two main planes as well Thus, concerning the sternoclavicular joint, the anteroposteriorly directed rotational axis is not parallel with the sagittal axis, the craniocaudally directed rotational axis is not parallel with the frontal (vertical) axis, and, as stated above, the mediolateral axis of the shoulder girdle (the long axis of the clavicle) is not parallel with the transversal axis.

Consequently, the effect on the shoulder girdle of rotational movements about axes

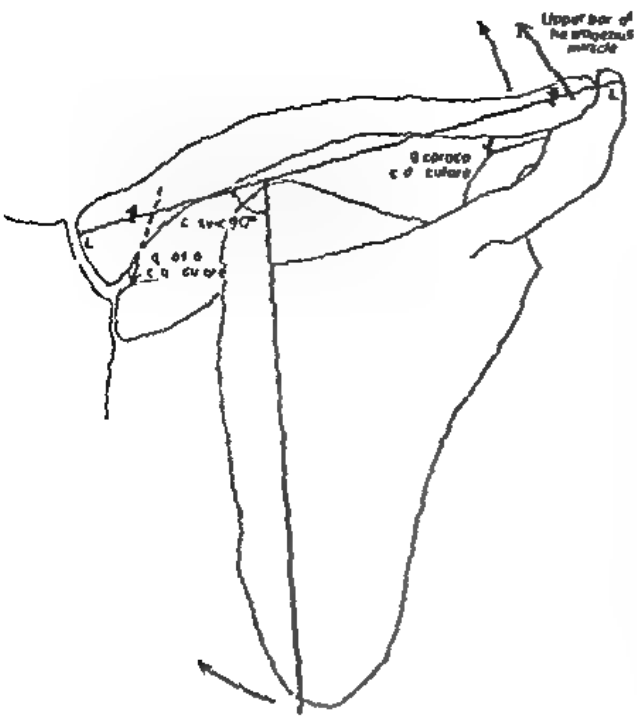

Figure 5 Simplified representation of rotation about the estimated long axis of the clavicle (L L) in separate elevation of the right shoulder girdle Dorsoventral view, the ribs are eliminated Anteroposteriorly directed axes of rotation are not drawn The small curved arrows indicate the direction of the rotational moment about the long axis of the clavicle The two other curved arrows represent the direction of rotation of the two bony components of the shoulder girdle The C-SV-angle is the frontally projected and medially directed angle between the long axis of the clavicle and the vertebral border of the scapula

parallel with the main axes of the body, and of rotation about axes corresponding to the shape of the thorax and the orientation of the bones, will differ

Rotation of the clavicle about its long axis in elevation of the shoulder girdle and the arm

Due to the interposition of the clavicle between the scapula and the sternum, as well as in the connection between the shoulder girdle and the thorax, all movements of the shoulder girdle bring about rotation of the clavicle occurring about more than one of the three axes in the sternoclavicular and the acromioclavicular joints. In the following, the rotation about the long axis of the clavicle will be dealt with

In separate elevation of the shoulder girdle (Figure 5) the clavicle and the scapula rotate in opposite directions about anteroposteriorly directed axes in the sternoclavicular and the acromioclavicular joints, respectively Thus the C-SV-angle, which was introduced by Hjortsjo (1967) decreases The angle is about 90 degrees in the starting position A decreased C-SV-angle is supposed to give a relaxation of the coracoclavicular ligament (Bragstad 1974) However, the costoclavicular ligament is stretched during elevation of the shoulder girdle, and in this way the clavicle acquires a ventrally directed rotational moment about its long axis (Figure 5) In addition because of its direction and insertion on the dorsal convexity of the clavicle the upper part of the trapezius muscle gives the bone a ventrally directed rotational moment (Figure 5) Thus in separate elevation of the shoulder girdle forces which effect ventrally directed rotational moments to the clavicle dominate The movement illustrates a ligamento-muscular synergism (Bragstad 1974)

In elevation of the arm, however, the scapula and the clavicle rotate in the same direction about anteroposteriorly directed axes in the two joints of the clavicle When the inferior angle of the scapula is abducted the C-SV-angle will increase, and the coracoclavicular ligament is stretched Thus the clavicle obtains a dorsally directed rotational moment, *i e*, the opposite of what is shown in Figure 5 When the clavicle rotates dorsally about its longitudinal axis, its acromial joint surface will be more cranially oriented. In this way additional abduction of the inferior angle of the scapula is allowed, resulting in a more cranial orientation of the glenoid cavity, corresponding to the elevation of the arm The abduction of the inferior angle, taking place about an approximately sagittally directed axis in the acromioclavicular joint, is the result of activity of the trapezius muscle and parts of the serratus anterior muscle

Dorsally directed rotation of the clavicle

may as well be caused by pull of other muscles attaching to the clavicle Because of its attachment on the ventral convexity of the bone, the clavicular portion of the pectoralis major muscle rotates the clavicle dorsally when the arm is elevated ventrally above the horizontal plane

According to DePalma (1957) there is an association between the frequency of degenerative changes in the acromioclavicular joint and the shape of the clavicle DePalma found that the majority of acromioclavicular joints causing pain and showing degenerative changes exhibited clavicles with relatively little pronounced acromial curvatures This is interesting, considering the dorsally directed rotational movement of the clavicle when the coracoclavicular ligament is stretched When the acromial curvature is less conspicuous, the clavicle will have to rotate more and earlier during elevation of the arm, giving increased shearing forces at the acromioclavicular joint

The findings and theory are in accordance with the conclusions of Inman & Saunders (1946) and Abbott & Lucas (1954) These authors claim that when a clavicular fracture cannot be reduced so that the shape of the bone fits in with the ligamentous pull, it is more to the patient's advantage to extirpate the clavicle This refers to the acromial as well as the sternal curvature (Inman & Saunders 1946)

The clavicle relative to circulation, ventilation and muscular tone

Making up the roof in the costoclavicular space the clavicle shelters the great nerves and vessels. On the other hand, caudal and dorsal movements of the lateral end of the bone decrease the space and in this way the clavicle may cause neurological and circular deficiencies, as in the claviculocostal syndrome.

Elevation of the lateral part of the clavicle results in increased pull on the costoclavicular ligament and the subclavius muscle, especially if the clavicle rotates dorsally, as it does when the arm is elevated Due to the articular, ligamentous and muscular connections between the clavicle and the first rib and due to the synchondrosis between the latter and the sternum, elevation of the shoulder girdle, and especially of the arm brings about a cranial motion of the thorax, corresponding to a high costal inspiration Accordingly, elevation of the shoulder girdle is synergetic to inspiration This is made use of in indirect breathing exercises and in artificial ventilation

If the shoulders are habitually elevated, however, the thorax will be fixed in inspiration, causing unsatisfactory utilization of real respiratory capacity, deterioration of circulation and increased muscular tone generally, and it often produces weariness and pain in the arm, neck, throat and head

Summing up, it should be stated that the clavicle is essential for stability and movements, for circulation, ventilation and tension, and even for the muscles of expression of the throat, shoulder and thorax In itself the clavicle also contributes greatly to the aesthetic impression of this area

REFERENCES

Abbott L. C & Lucas, D B (1954) The function of the clavicle *Ann Surg* 140, 583–599

Andreasen, [illegible] (1960) *Bevaegeapparatets anatomi* 2nd ed. pp 160–162. Gyldendal Copenhagen

[illegible] (1961) An electromyographic study of

Boas, J E V & Thomson, M (1961) *Zoologi* Vol 3 7th ed pp 324–328 Gyldendal, Copenhagen

Bragstad, A. (1974) Bevegelseslaere In manuscript.

Cunningham, D J (1931) *Text book of anatomy* 6th ed. pp 220–223, 434–443 Oxford University Press, London.

DePalma, A. F (1957) *Degenerative changes in the sternoclavicular and acromioclavicular joints in various decades* Charles C Thomas, Springfield Illinois.

Grant, J C. B (1971) *Method of anatomy* 8th ed. pp. 92–105 Williams & Wilkins, Baltimore

Hjortsjo, C-H (1953) The significance of the articular disc and the "accentuated grinding joint" *Odont Rev* 4, 203–209

Hjortsjo, C-H (1967) *Rörelsesapparaten Speciell del* pp 113–124 CWK Gleerups förlag, Lund

Hjortsjo, C-H, Ljunggren, A E & Sonesson, B (1977) Theoretical comments on grinding joints, rolling joints and accentuated grinding joints Comm Departm Anat, Lund, No 9

Inman V T & Saunders, J B deC M (1946) Observations on the function of the clavicle *Calif west Med* 65, 158–166

Jenkins, F A (1974) The movement of the shoulder in claviculate and aclaviculate mammals *J Morph* 144, 71–84

Kapandji, A (1970) *The physiology of the joints* Vol 1, Upper limb, 2nd ed pp 10–77 Churchill Livingstone, Edinburgh

LeGros Clark, W E (1965) *The tissues of the body* 5th ed pp 71–118 Clarendon Press Oxford

Martin, E & Saller, K (1959) *Lehrbuch der Anthropologie in systematischer Darstellung mit besonderer Berücksichtigung der anthropologischen Methoden* Vol 2, 3rd ed pp 1039–1041 Gustav Fischer Verlag Stuttgart

McKern, T W & Stewart, T D (1957) Cit from Grant, J C B (1971) *Method of anatomy* 8th ed p 103 Williams & Wilkins Baltimore

Oxnard, C (1973) *Form and pattern in human evolution Some mathematical, physical and engineering approaches* pp 26–31 50–67 University of Chicago Press Chicago

Pauwels, F (1957) Funktionelle Anpassung des Knochens durch Langenwachstum *Verh dtsch orthop Ges* 45, 34–56

Correspondence to Dr Anne Elisabeth Ljunggren, Anatomical Institute, University of Oslo Karl Johansgt 47, Oslo 1, Norway

cta orthop scand 50 269–274 1979

SPONTANEOUS DISLOCATION OF THE STERNO-CLAVICULAR JOINT

BAHMAN SADR & MALCOLM SWANN

Heatherwood Hospital Ascot, Berkshire, England

A description is given of 22 patients, with a spontaneous forward subluxation of the sternal end of the clavicle, seen over a 5-year period The majority were middle-aged women presenting with a lump at the root of the neck which was usually associated with little or no discomfort There was no history of injury and no interference with shoulder function The diagnosis was obvious on clinical examination and no treatment was required other than explanation reassurance and simple analgesia

In no case was the correct diagnosis made by the referring physician and many of the patients were unduly concerned by the nature of the swelling

The sterno-clavicular joint is a synovial articulation and consequently it may be involved in rheumatic arthropathy A condition of non infective subacute arthritis of the sterno-clavicular joint has been described and is similar to that reported here but in contrast to the previous report we believe that the changes which occur in the joint are secondary to its subluxation.

Key words middle-aged women root of neck, swelling spontaneous appearance

Accepted 27 x.78

Dislocations of the sterno-clavicular joint are generally considered to be the result of direct or indirect violence In one reported series (Cave 1958) 70 per cent were due to a fall on the point of the shoulder and the remaining 30 per cent were caused by a direct blow to the clavicle

It is known, however, that trauma is not essential for the occurrence of an anterior dislocation and a "strain" alone is sometimes sufficient Stokes (1847) reported "forward and upward displacement of the sternal extremity of each clavicle, the result of powerful inspiratory efforts" in a man dying of cirrhosis. Ducket (1888) described the case of a "strong well-made man of active habits while swimming upon his left side he endeavoured to turn upon his back during which action he felt something give way in his neck" Anterior dislocation of the sterno-clavicular joint was later found and reduced Duggan (1931) performed menisectomy on the sterno-clavicular joint of a 37-year-old female who had developed a painful shoulder while making a bed and was later found to have a dislocated "sterno-clavicular cartilage" In a review of sterno-clavicular dislocations (Salvatore 1968) "reaching" and "lifting" were listed among the causes. Subluxation of the sterno-clavicular joint has been reported in weight-lifters (Korkusuz 1974) and Lusneth et al (1975) has described the case of a 20-year-old student who experienced pain and swelling in the sterno-

© 1

0001–6470/79/030269–06$02.50

Table 1 Summary of the 22 patients with spontaneous dislocation of the sterno-clavicular joint

Patient	Age	Sex	Occupation	Affected side	Dominant side	Presentation	Family history	History of strain or injury	Treatment
1	63	F	Housewife	R	R	Painless swelling 'for weeks'	None	None	None
2	63	F	Housewife	R	R	Painless swelling for 2 months. Ache in right shoulder	None	Fall on rt shoulder 7 years previously	None
3	49	F	Housewife	R	L	Painless swelling for 2 months	None	None	None
4	53	F	Housewife	R	R	Ache in right shoulder	None	None	None
5	77	F	Housewife	R	R	Painless swelling for 5 months	None	None	Local SWD
6	61	F	Home help	R	R	Painless swelling for 1 month	Yes (sister)	None	None
7	54	M	Manager	L	U/K	Painful lump for 1 month	Unknown		Local SWD
8	45	F	Supervisor	R	R	Pain in region of SCJ 7/52	None	None	Physiotherapy
9	52	F	Welfare asst	R&L	R	Aching in SCJ for 4 years	None	None	None
10	41	F	Housewife	R	R	Pain in SCJ for 6/12	Unknown	None	Hydrocortisone injection
11	49	F	Shop asst	R	R	Pain in clavicle for 1 year	None	None	None
12	56	F	Teacher	R	L	Painless swelling 5 years	None	None	Excision of medial end of clavicle
13	58	F	Housewife	R	R	Painless swelling 1 year	None	None	None
14	48	F	Housewife	L	R	Painless swelling 1½ years	None	None	None
15	51	F	Housewife	R	R	Painful swelling 2 months	None	None	None
16	56	F	Housewife	L	R	Vague pain in upper thorax	None	None	None
17	55	M	Fitter	R	R	Ache and swelling 'for months"	None	Pushing heavy wheelbarrow day before	None
18	56	F	Housewife	R	R	Painless lump for 5/52	None	'Heavy washing day before	None
19	42	F	Housewife	R	R	Painless lump for 6/52	None	None	None
20	51	F	Housewife	R	R	Painless swelling for 6/12	None	None	None
21	61	F	Housewife	L	R	Noted swelling while turning in bed 4/12 previously	None	None	None
22	69	F	Housewife	R	U/K	Painless swelling for 5/12	None	None	None

SCJ = Sterno-clavicular joint
SWD = Shortwave Diathermy

clavicular joint while doing "hyperabduction exercises" a year prior to the discovery of sterno-clavicular dislocation

Congenital forward subluxation of the sterno-clavicular joint has been recognized and documented According to Moseley (1969) it appears to run in families and he presents a case, with photographs, of a young woman with habitual dislocation of both sterno-clavicular joints Similarly, Machan (1973) describes the appearance of habitual dislocation in the sterno-clavicular joints of a 17-year-old girl with evidence of generalized joint laxity Nettles & Linscheid (1968), on the other hand, in a review of 60 sterno-clavicular dislocations found two occurring in newborns and three bilateral cases of unknown aetiology occurring in teenagers without evidence of generalized joint laxity In addition they described a further 11 unilateral cases occurring spontaneously "during routine movement (such as during sleep or while combing hair)"

Slow spontaneous displacement of the sterno-clavicular joint due to repetitive manipulation of a heavy lever was reported by Katzenstein (1903) Waskowitz (1961) describing 18 cases of dislocations and subluxations of the sterno-clavicular joint found two in whom no history of trauma or known aetiology could be found

Lamb (1976) has studied four patients with sterno-clavicular joint enlargement following block dissection of the neck for cancer He draws attention to the misleading X-ray appearance of these joints and advocates a conservative management

In this series we present a further 22 cases of apparently spontaneous anterior subluxation of the sterno-clavicular joint

PATIENTS

Details of the 22 patients, 2 men and 20 women with an average age of 56 are summarized in Table 1 The majority were housewives or had sedentary occupations One man worked as a fitter involving moderately heavy manual labour Nine

Figure 1 Clinical appearance The swelling had given the patient considerable anxiety

patients presented with a painless lump in the root of the neck (Figure 1) In a further seven patients the lump was associated with some [illegible]

and never interfered with the function of the affected shoulder girdle which moved freely and fully on clinical examination The commonest reason for referral to the Orthopaedic Clinic was the concern of the patient or the referring physician over the appearance of an unexplained and undiagnosed lump at the root of the neck One patient had a sister similarly affected, all others specifically questioned gave a negative family history The right side was affected in 16 cases the left in four and it was bilateral in one The association between the affected and dominant side was statistically significant ($P > 0.01$ and < 0.05) The length of history ranged from 1 month to 5 years with an average of 8 months

There was no history of injury or precipitating cause in any of the patients We purposely excluded from this series any patient who gave a history of trauma in the year preceding the onset of symptoms even though the connection sometimes seemed fortuitous. One such patient was our own theatre sister, a reliable historian, who was involved in a road accident and sustained bruising of the front of her chest 6 months prior to the development of a lump at the root of her neck. She had no symptoms in the intervening period and it seemed likely that the two events were unconnected She was nevertheless excluded from the survey One patient gave a history of a fall 7 years previously and two others associated the appearance of symptoms with strenuous activity

Figure 2 Radiographs of the same patient as Figure 1 with subluxation of the right sterno-clavicular joint (a) Normal left joint (b) Right joint unremarkable appearance (c) Tomogram of both joints Cystic changes seen at the medial end of the clavicle on the affected side

Figure 3 Erosive change and cyst formation of the right sterno-clavicular joint

the previous day They were all included in the survey

The diagnosis was usually obvious on clinical examination, the sternal end of the clavicle being subluxated anteriorly and irreducible Thirteen patients were X rayed but radiographs were generally not required for diagnosis Irregularity of the sternal end of the clavicle cyst formation and erosive changes were found in three cases (Figures 2a b c) but in the rest the X ray appearance was unremarkable and only confirmed a clinically obvious subluxation In one patient (case 12) we were alarmed by the radiographic appearance of the affected sterno-clavicular joint (Figure 3) which was reported as showing the features of 'caries sicca The patient was therefore subjected to an open biopsy of the medial end of the clavicle the histology of which showed non-specific chronic inflammation In retrospect, it seems likely that these X ray changes were secondary to the subluxation and the consequence of degenerative processes starting in areas of unopposed cartilage (Harrison et al 1951)

The spontaneous subluxation of this joint so as to produce an obvious swelling in a healthy patient is characteristic of the condition. Nevertheless other conditions may produce a swelling which at first glance is similar in appearance, but for the most part they will be associated with other presenting features which will serve to identify the underlying problem.

Rheumatic arthropathy and in particular ankylosing spondylitis not infrequently affect the sterno-clavicular joint In this event the swelling is painful and associated with other features of the disease and the subject a male Disease such as infection or malignancy may, by chance, affect the articulation or the medial end of the clavicle and produce a swelling However, other features of this particular disease will be manifest either at other anatomical sites or by alteration in the blood picture, or by characteristic radiological change The sterno-clavicular joint is located well above the area occupied by breast tissue However, a number of the patients feared that they had a carcinoma of the breast

The majority of patients required no treatment Analgesia and shortwave diathermy were given in a few cases but in general simple reassurance was adequate Pain if present, was mild and usually self limiting within 3 to 4 months.

DISCUSSION

The sternal end of the clavicle articulates with a shallow depression in the manubrium-sterni and the cartilage of the first rib As the articular area of the clavicular extremity is larger than that of the depression, only a small portion of it fits into this groove at any one time The stability of the joint therefore depends entirely on its ligaments (notably the costo-clavicular or rhomboid ligaments) and the intra-articular fibrocartilagenous disc which in addition provides an articulating surface for the disproportionately large sternal extremity It therefore seems surprising that sterno-clavicular dislocations do not occur more often and only represent 1 per cent of all dislocations (Salvatore 1968, Lumeth et al 1975)

Although most of the literature on sterno-clavicular joint dislocations and subluxations is concerned with cases following violent trauma it is well recognized that subluxation or even dislocation can occur without significant injury In this series we present 22 cases of spontaneous forward subluxation of the sterno-clavicular joint which have been seen in our hospitals over a 5-year period

The condition seems to occur in middle age and affects women more frequently than men. There is a significant association between the involved and dominant side although the condition affects the housewife and the sedentary worker rather than the manual labourer Characteristically there is no history of injury

The commonest presenting feature is a lump at the root of the neck with or without an aching discomfort The principal reason for seeking medical opinion and for referral to an Orthopaedic Clinic is to establish the diagnosis There may be a fear of malignancy such as breast cancer The diagnosis is simple to make clinically, and X-rays are generally not required, particularly as these are difficult to interpret, and may be misleading Similarly, open biopsy of joint contents is unhelpful and should be avoided In contrast to a previous report (Bremner 1959) we believe that non-specific inflammatory changes which occur in the joint are secondary to its subluxation

No treatment is needed other than simple analgesia (if at all) and reassurance as symptoms of ache and discomfort (if any) are mild and self limiting

Conclusions

1 Spontaneous sterno-clavicular subluxation is a condition of unknown aetiology that occurs insidiously and affects chiefly middle-aged women.
2 The diagnosis is simple to make clinically and active treatment is normally not required Its recognition, however, is important
3 If X-rays are taken, they must be interpreted with caution Radiographic changes such as erosion and irregularity of the articular surfaces are probably secondary to the subluxation

ACKNOWLEDGEMENTS

The authors wish to thank Dr Barbara Ansell and Mr George Arden for permission to include their cases.

REFERENCES

Bremner, R A (1959) Monoarticular, non-infective subacute arthritis of the sternoclavicular joint *J Bone Jt Surg* 41-B, 749–753

Cave, E D (1958) *Fractures and other injuries* The Year Book Publishers, Philadelphia

Duggan, N (1931) Recurrent dislocation of the sternoclavicular cartilage *J Bone Jt Surg* 13, 365

Ducket, C A (1888) Ante-sternal dislocation of the clavicle *Lancet* i, 667

Harrison, M H M, Schajowicz, F & Trueta, J (1951) Osteoarthritis of the hip a study of the nature and evolution of the disease *J Bone Jt Surg* 35-B, 598–626

Katzenstein, M (1903) Ueber eine durch ein chronisch wirkendes Trauma allmälig entstehende Luxatio sternoclavicularis. *Arch klin Chir* 69, 1049

Korkusuz, Z (1974) Subluxation of the sternoclavicular joint in weight lifters. *Arch orthop Unfall Chir* 74, 224–230

Lamb, C E M (1976) Sternoclavicular enlargement following block dissection *Brit J Surg* 63, 488–492

Lusneth, P A, Chapman K W & Frankel, V H (1975) Surgical treatment of chronic dislocation of the sternoclavicular joint *J Bone Jt Surg* 57-B, 193–196.

Machan, Von F G (1973) Neglected dislocations of the sternoclavicular joint *Beitr Orthop Traum* 20, 219–221

Moseley, H F (1969) *Shoulder lesions* 3rd ed. pp 226–234 E & S Livingstone Co. Edinburgh and London

Nettles, J L & Linscheid, R L (1968) Sternoclavicular dislocations *J Traum* 8, 158–163

Salvatore, J E (1968) Sternoclavicular joint dislocations. *Clin Orthop* 58, 51–53

Stokes, W (1847) Partial displacement of the sternal end of each clavicle *Proc path Soc Dublin 1–2, 273–274*

Waskowitz, W J (1961) Disruptions of the sterr lar joint An analysis and dossier *A* 3, 176–179

Correspondence to Bahman Sadr F R C S , Berkshire, E

Acta orthop scand. 50 275–281 1979

VESTIBULOSPINAL REFLEX ACTIVITY IN PATIENTS WITH ADOLESCENT IDIOPATHIC SCOLIOSIS

Postural Effects During Caloric Labyrinthine Stimulation Recorded by Stabilometry

TAGE SAHLSTRAND BJÖRN PETRUSON & ROLAND ORTENGREN

Departments of Orthopaedic Surgery I, Otorhinolaryngology and Clinical Neurophysiology, S[illegible] Hospital, University of Göteborg, Göteborg Sweden

Postural sway has been quantified with stabilometry during [illegible] labyrinthine stimulation in an erect posture in 49 patients aged [illegible] years, with adolescent idiopathic scoliosis. Thirty-two healthy children of the same age constituted a control group The scoliotic patients tended to have an increased postural sway during labyrinthine stimulation on the convex side compared to the effects on the concave side Significant differences were observed when left and right scoliotic patients were compared with the controls. The results can be explained by an asymmetric sensitivity in the labyrinth or by a dysfunction in the postural control mechanisms at the brain stem level.

Key words aetiology, equilibrium, posture, scoliosis, stabilometry, vestibulospinal reflex, vestibular function test

Accepted 25 XI.78

The vestibular system performs an essential function in the control of posture and movements. The regulation is exerted either by direct efferent projections of the vestibular nuclei in the spinal cord, i.e. the lateral and medial vestibulospinal tract, or by collateral activities of reticulospinal neurons (Gernandt 1959, Pompeiano 1975)

During vestibular imbalance, caused by stimulation or disease, an asymmetric tone in skeletal muscles can be distributed reflexively via these tracts (Torok & Kahn 1960), resulting in a deviation and rotation of the body towards the side with least tone (Wodak & Fischer 1923). When the spine demonstrates an abnormal asymmetric posture under these circumstances, there is a resemblance to the characteristics of scoliotic deformity A functional asymmetry or disturbance at some level in the vestibulospinal reflex arc might therefore be a contributory factor in the development of adolescent idiopathic scoliosis.

Different approaches to the study of the vestibulospinal reflex have been reported. Wodak & Fischer (1923) described "Körperdrehreflex" and "Körperneigungsreflex" in patients exposed to caloric labyrinthine stimulation and estimated the effects qualitatively A stepping test has been used by Fukuda (1959) Hara et al. (1960) made [illegible] recording device for measuring rotary falling tendency after rotatory labyrinthine stimulation. Henriksson et al. (1962) described a method for recording vestibulospinal influence on the head with pneumatic b[illegible] one on each side of the [illegible]

© 1979 M[illegible]

0001-6470/79 030275-07$02.50/0

(1970) published a study using the same method Galvanic stimulation of the vestibular system with recording of the postural effects using a statokinesimeter has been reported by Njiokiktjien & Folkerts (1971)

The purpose of the present investigation was to study, by means of stabilometry, the effects of caloric vestibulospinal stimulation in an erect posture in a group of patients with adolescent idiopathic scoliosis and to compare the reactions with those recorded in a control group

METHODS

The effect of caloric stimulation of the labyrinth on postural sway was recorded using a force platform and a tape recorder The recording equipment and the evaluation procedure have previously been described in detail (Sahlstrand et al 1978) Briefly, the output signals of the force platform were converted to length coordinates which indicate the movements of the projection on the base plane of the body's centre of gravity when the acceleration forces are small compared to the gravitational forces The time series of length coordinates describe the postural sway and were used in the calculation of average values x_m in the lateral direction and y_m in the sagittal direction (Positive directions to the right and forwards respectively) The points x_m and y_m indicate the centre of the sway In addition, the rms-values s_x and s_y of the lateral and sagittal sway amplitudes were estimated regarding the sway as a bivariate normal stochastic process. The area A of the 39 6 per cent confidence ellipse of the bivariate amplitude density function was calculated This area is a statistical measure of the sway area which takes a possible correlation between x and y signals into account The angle a between the major axis of the ellipse and the positive y axis being a measure of the average direction of the sway was also calculated (positive direction counterclockwise)

All data were treated statistically and mean values, standard errors of the means and 95 per cent confidence intervals were calculated for each parameter and test situation To estimate changes in the centre coordinate x_m and the average direction of the sway a, the statistical calculations were also based on the normalized values $x_m - x_{m_1}$ and $a - a_1$ for each subject Here x_{m_1} and a_1 are the values obtained in the reference test position, i e standing relaxed with eyes open

The caloric stimulations in an erect posture constituted the last test in a series of examinations including stabilometry in the standing position and electronystagmography during caloric stimulation in the supine position These studies have been described elsewhere (Sahlstrand et al 1978 Sahlstrand & Petruson 1979a b) The caloric stimulation in a supine position was performed at least 1 hour before the stimulation in an erect position and none of the subjects participating in this study had any remaining vertigo or nausea.

The recordings were performed with the subject standing on the force platform with his head straight forward making the direction of the eye ball axis horizontal i e the horizontal semicircular canal was at an angle of 30 degrees to the horizontal plane The subjects had their eyes closed and the room was dark The positioning of the feet on the platform was always the same with the heels together and with the feet at an angle of 30 degrees The subjects were instructed to stand with their arms hanging freely beside their trunk In the event of a subject experiencing marked instability during the stimulation a surrounding barrier was available for support. The testing started with the left ear and continued 10 minutes later with the right ear The syringing was performed for a period of 30 seconds using 100 ml of cold water (30°)

The recording from the force platform started when the separate syringing was finished i.e after 30 seconds and lasted 180 seconds. The nystagmus was recorded simultaneously using ENG These results are presented in another paper (Sahlstrand & Petruson 1979b) During the tests the subject's subjective reactions, need for support, and visual assessment of rotation of the body were also noted An account of this evaluation is presented in another paper (Sahlstrand & Petruson 1979b)

MATERIAL

This study included 41 children with adolescent idiopathic scoliosis (AIS) all of them with a single major structural curvature The material, originally consisting of 48 patients, has been described in a previous paper (Sahlstrand et al 1978) Seven patients were excluded because they were not able to tolerate continued caloric stimulation in an erect posture due to persisting vertigo or nausea after the previous caloric test in the supine position The patients were subgrouped according to the magnitude and convexity of the curvature (Table 1).

Table 1 Grouping of the scoliotic patients with regard to magnitude and convexity of the curve

	Patients placed under observation	Patients requiring treatment	Total
Right convex single curve	8	15	23
Left convex single curve	9	9	18
Double primary curve		8	8
Total	17	32	49

Eight scoliotics with double primary curvatures were included as a separate group and are analysed separately Also in this group one patient was excluded because of persisting vertigo and nausea after the previous caloric test The control group comprised 32 healthy children of the same age

All the subjects were given a thorough physical investigation with emphasis on neurological status according to a special schedule None of the subjects was taking any drugs or had consumed any tobacco or coffee on the day of the investigation

RESULTS

Comparing the results from right and left labyrinthine stimulation within the different scoliotic groups, there is a tendency towards more pronounced effects when the labyrinth on the convex side was stimulated, whether the right or the left convex patients are analysed (Tables 2 a, b and 3)

Patients placed under observation, in right as well as left convex groups, were noted to have significantly more lateral sway s_x during left labyrinthine stimulation compared to the patients requiring treatment In the right convex group, the patients placed under observation also showed a significantly more pronounced shift of x_m and a significantly increased total sway A during left labyrinthine stimulation.

There were also more pronounced effects in general in the scoliotic patients compared to the controls. The control children had almost completely symmetric vestibulospinal effects from the two separate stimulations.

Right labyrinthine stimulation seemed to distinguish statistically between the groups to a lesser extent compared to left labyrinthine stimulation The shift of the centre of the sway $x_m - x_{m_0}$ and the lateral sway s_x tended to be the most decisive parameters

The double primary scoliotics had an increased lateral sway compared with the controls during vestibular stimulation on the right side They also differ significantly from the left convex patients regarding the change in angle a during left labyrinthine stimulation

DISCUSSION

To our knowledge, effects of vestibular stimulation have not been investigated previously in patients with adolescent idiopathic scoliosis The laterotorsion, i e lateral twist of the head, neck, and body, that follows vestibular stimulation (Henriksson et al 1962) has certain similarities with the characteristics of a lateral rotatory deformity in the idiopathic curvature This observation might be of importance in connection with aetiological factors in idiopathic scoliosis

Irrigation with cold water diminishes the continuous excitatory impulse flow from the labyrinth towards the vestibular nuclear complex in the brain stem (Richter 1943, Wodak & Fischer 1923). At the same time the tone in axial muscles decreases, and the subject develops laterotorsion towards the stimulated side All the subjects in the present investigation showed this effect to a greater

Table 2a Postural sway after caloric stimulation Mean values and standard errors of the means For explanation of the symbols see Figure 1

	s_y cm		s_x cm		s_y/s_x	
	Left lab stim	Right lab stim	Left lab stim	Right lab stim	Left lab stim	Right lab stim
Controls	1 11±0.07	1 14±0 07	0 93±0 08	0 92±0 07	1 30±0 08	1 31±0 06
Right convex scoliotics	1 19±0 08	1 31±0 12	0 99±0 07	1 05±0 09	1 25±0 05	1 28±0 08
placed under observation	1 34±0 18	1 50±0.24	1 21±0 15	1 24±0 21	1 13±0 06	1 26±0.10
requiring treatment	1 12±0 08	1 21±0 13	0 86±0 06	0 94±0 06	1 31±0 07	1 30±0 12
Left convex scoliotics	1 44±0 15	1 26±0 09	1 11±0 09	1 10±0 08	1 31±0 10	1 18±0 07
placed under observation	1 58±0 24	1 26±0 12	1 28±0 14	1 13±0 10	1 21±0 09	1.14±0 08
requiring treatment	1 30±0 16	1 26±0 15	0 95±0 10	1 07±0 13	1 40±0 17	1 22±0 11
Double primary scoliotics	1 16±0 11	1 39±0 15	0 94±0 09	1 28±0 15	1 28±0 16	1 13±0 11

Table 2b Postural sway after caloric stimulation Mean values and standard errors of the means For explanation of the symbols see Figure 1

	A cm^2		α degrees		$\alpha-\alpha_i$* degrees		$x_m - x_{m_i}$* cm	
	Left lab stim	Right lab stim	Left lab stim	Right lab stim	Left lab stim	Right lab stim	Left lab stim	Right lab stim
Controls	3 58±0 62	3 62±0 60	15 8± 5 8**	− 9 1± 4 9	11 2± 8 0	−13 8± 7 0	−0 67±0 14	1 08±0 14
Right convex scoliotics	3 99±0 53	4 75±0 79	11 2± 6 4	− 5 9± 7 0	5 5± 8 6	−11 6± 9 0	−0 93±0 17	0.80±0 18
placed under observation	5 59±1 19	6 67±1 85	18 0±10 5	− 6 6±12 0	− 2 3±18.3	−26 9± 8 2	−1 48±0 26	0 53±0 38
requiring treatment	3 14±0 40	3 73±0 61	7 6± 8 1	− 5 5± 9 0	9 7± 9 2	− 3 4±12 8	−0 63±0 19	0 94±0 19
Left convex scoliotics	5 15±0 87	4 55±0 61	1 3± 9 1	−13 0± 9 4	25 1±13 5	8 9±14 2	−1 29±0 22	1 06±0 19
placed under observation	6 34±1 51	4 49±0 66	3 6±13 8	− 5 1±14 9	19 8±20 2	6 2±21 1	−1 34±0 33	1 25±0 24
requiring treatment	3 97±0 16	4 61±1 03	−1 0±12.8	−20 1±12.0	30 4±18 8	11 2±20 4	−1 23±0 30	0 88±0 30
Double primary scoliotics	3 39±0 56	5 69±1 36	−3 1±11 2	9 5±15 8	−21 1±13 9	− 7 4±18 0	−1 19±0 27	0 70±0 15

* x_{m_i} and α_i are values obtained in a reference test position, i e standing relaxed with eyes open before caloric stimulation
** A positive mean indicates a counter-clockwise direction (α) and a direction to the right (x_m).

Table 3 Summary of statistical analysis Left and right labyrinthine stimulation (significance in right labyrinthine stimulation underlined)*

	s_y	s_x	s_y/s_x	A	α	$\alpha-\alpha_i$	x_m/x_{m_i}
Controls/Right convex scoliotics							
placed under observation				$\underline{P<0.05}$			$P<0.05$
requiring treatment							
Controls/Left convex scoliotics	$P<0.05$						$P<0.05$
placed under observation	$P<0.05$	$P<0.05$					
requiring treatment							
Controls/Double primary scoliotics		$\underline{P<0.05}$					
Right/Left convex scoliotics							
placed under observation							
requiring treatment							
Scoliotics placed under observation / Scoliotics requiring treatment							
right convex		$P<0.05$		$P<0.05$			$P<0.05$
left convex		$P<0.001$					
Right convex scoliotics/Double primary scoliotics							
Left convex scoliotics/Double primary scoliotics							

* Differences between the groups were investigated by means of Student's *t*-test at the 5 per cent level of significance

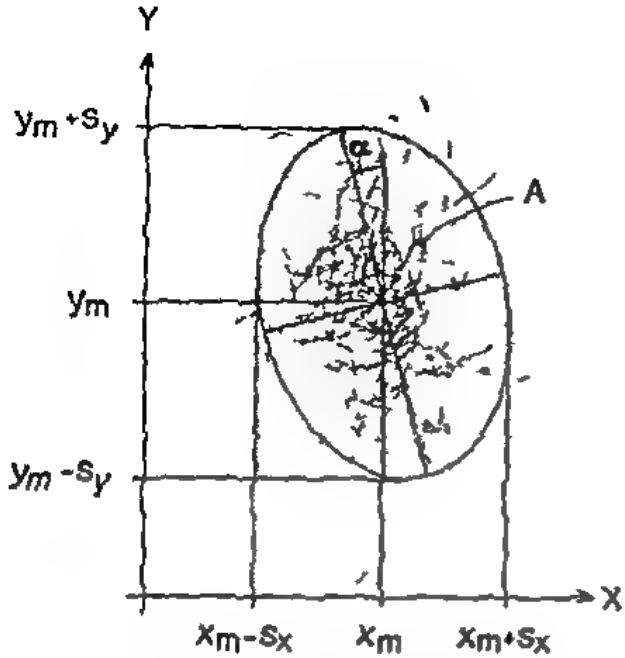

Figure 1 Statistical description of postural sway in the x-y plane The confidence ellipse of area A has its centre in $(x_m y_m)$ The tangents parallel to the coordinate axes yield the standard deviations of the marginal distributions which are equal to the rms values of the sway components s_x and s_y in the lateral and sagittal directions, respectively The scale of the locus trace has been reduced by a factor of two to increase clarity

or lesser extent Visual estimation of the torsion revealed no difference between the scoliotic patients and the controls (Sahlstrand & Petruson 1979b) The force platform provides an objective measure that enables quantitative estimation of lateroversion to be performed

There was a common tendency for the scoliotic patients to have an increased postural sway after stimulation on the convex side compared to the effects on the concave side The differences were not statistically significant, however Significant differences as regards effects on the convex side were obtained when left and right scoliotics were compared to the controls especially for the left convex group The vestibulospinal reflex was activated with the same stimulus on the two labyrinths but the reaction measured from the force platform was different An explanation for this could be an asymmetric processing of input information taking place at some level A previous study in the supine position (Sahlstrand & Petruson 1979a) has shown a functional asymmetry in the labyrinthine function, with a convex side dominance It seems reasonable to assume that the cause of the more pronounced sway during stimulation on the convex side is an effect of a vestibular imbalance in the labyrinthine level, i e differences in labyrinthine sensitivity

In the supine position the imbalance in the labyrinthine function was found to be more pronounced in patients with more severe scoliosis compared to those with smaller curvatures (Sahlstrand & Petruson 1979a) This observation makes it difficult to explain why calorization induced more pronounced postural effects in patients with smaller curvatures in the erect position as seen in this study Obviously the postural sway effects cannot be explained only by an imbalance in the labyrinthine function An EEG study by Petersén et al 1979 has demonstrated EEG pathology in patients with idiopathic scoliosis The type and localization of the abnormalities indicated involvement of brain stem structures, where important centres for postural regulation are located The abnormalities were significantly more frequent in the group with smaller curvatures. The efficiency in processing different afferent impulses might therefore explain the difference in postural control between these groups The observed differences are also in accordance with the results found in a study of postural effects in other test situations (Sahlstrand et al 1978)

The results of this study indicate a dysfunction in the labyrinths or in the efficiency with which the scoliotic patient succeeds in counteracting a vestibular imbalance with his postural control mechanisms. A combination of these factors seems even more probable The observed dysfunction might be of aetiological importance in idiopathic scoliosis.

ACKNOWLEDGEMENTS

This investigation was supported by grants from The Swedish Medical Research Council (Proj B76-29X-04553-02), Norrbacka-Eugeniastiftelsen, Bertha och Felix Neuberghs Valgorenhetsstiftelse, Stiftelsen Sigurd och Elsa Goljes Minne and Stiftelsen Clas Groschinskys Minnesfond

REFERENCES

Fukuda, T (1959) The stepping test (two phases of the labyrinthine reflex) *Acta otolaryng (Stockh)* **50**, 95–108

Gernandt, B E (1959) Vestibular mechanisms. *Neurophysiology* **1**, 549–564

Hara, T, Suzuki, G & Suzuki, J (1960) A study of the vestibulo-spinal reflex Part 1 Electromyographic observations *Yokohama med Bull* **11**, 407–414

Henriksson, N G, Dolowitz, D A & Forssman, B (1962) Studies of cristospinal reflexes (laterotorsion) 1 A method for objective recording of cristospinal reflexes. *Acta otolaryng (Stockh)* **55**, 33–40

Njiokiktjien Ch & Folkerts, J F (1971) Displacement of the body's centre of gravity at galvanic stimulation of the labyrinth *Confin Neurol (Basel)* **33**, 46–54

Petersén, I, Sahlstrand, T & Selldén, U (1979) Electroencephalographic investigation of patients with adolescent idiopathic scoliosis *Acta orthop scand* **50**, 283–293

Pompeiano, O (1972) Spinovestibular relations Anatomical and physiological aspects. Progress in Brain Research, Basic Aspects of Central Vestibular Mechanisms **37**, 263–296

Pompeiano, O (1975) Vestibulo-spinal relationships *The vestibular system* Ed Naunton, R F, pp 147–184, Academic Press, New York

Richter, H R (1973) L'intêret de la nystagmographie en neurologie (L'épreuve thermique et le diagnostic topographique) *Oto-Neuro-Opht* **45**, 347–351

Sahlstrand, T & Petruson, B (1979a) A study of labyrinthine function in patients with adolescent idiopathic scoliosis. *Acta orthop scand* (In press)

Sahlstrand, T & Petruson, B (1979b) A study of postural effects on nystagmus response in caloric labyrinthine stimulation *Acta orthop scand* (In press).

Sahlstrand, T, Örtengren, R & Nachemson, A (1978) Postural equilibrium in patients with idiopathic scoliosis *Acta orthop scand* **49**, 354–365

Spector, M (1970) Pneumatic registration of vestibulospinal reflexes. *Pract oto-rhinolaryng (Basel)* **32**, 11–16

Torok, N & Kahn, A (1960) Vestibular lateropulsion *Ann Otol (St Louis)* **69**, 61–72.

Wodak, E & Fischer, M H (1923) Vestibulare Korperreflexe und Reaktionsbewegungen beim Menschen *Klin Wschr* **2**, 1802–1804

Correspondence to Tage Sahlstrand, M D, Department of Orthopaedic Surgery, Östra sjukhuset, University of Goteborg, S-41685, Goteborg, Sweden

(Robin 1975) Functional and organic involvement of the brain stem has been described in works of Tezuka (1971), Yamada & Yamamoto (1972), Crisfield (1974), Dretakis & Kondoyannis (1974), and Sharpe et al (1975) Martin (1967) and Duvoisin & Marsden (1975) pointed out that diseases in the basal ganglia may be of importance for the aetiology of a lateral curve Martin (1967) quoted previous authors who had found that unilateral lesions of the caudate nucleus in dogs may cause scoliosis concave to the same side

In the present study we have compared the EEG findings in a group of patients suffering from idiopathic scoliosis with those in healthy children In addition, it was thought of interest to investigate if electroencephalographic signs of deficient maturation in the CNS were to be found in these patients, especially in view of the fact that a retarded development of the equilibrium function had been reported by Yamada & Yamamoto (1972) in patients with idiopathic scoliosis.

METHOD

EEG was recorded with a 16-channel electroencephalograph. The 10–20 electrode system of the International Federation was used with longitudinal and transverse bipolar derivations The EEG investigation included resting EEG and activation procedures by means of hyperventilation intermittent photic stimulation and sleep The recordings were classified according to the customary visual technique For definitions of normal and pathological findings reference is made to Sellden (1964) Eeg-Olofsson et al. (1971) and Petersén & Eeg-Olofsson (1971).

The following EEG patterns were distinguished normal EEG, slight or moderate increase of low frequency activity in resting EEG, paroxysmal activity in resting EEG, 14–6 Hz positive spike phenomenon and/or 6 Hz spike and wave activity and paroxysmal activity occurring with any of the activation procedures applied Electroencephalographic findings included in the patterns mentioned above were noted in the total material and in the following subgroups patients requiring treatment (brace or operation) patients placed under observation only and patients meeting criteria of normality according to Petersén & Eeg-Olofsson (1971)

The EEG findings encountered were compared a) between patients requiring treatment and those [illegible] were girls (49 out of 57) and the normal material comprised an equal number of both sexes Comparison by sexes was not considered suitable however because of the fact that further grouping would have resulted in groups too small for adequate statistical treatment

Visual evaluation of the EEG was complemented to a certain extent by automatic frequency analysis. A previously described method for calculation of "EEG age from the frequency spectra (Matousek & Petersén 1973) was applied in order to reveal any electroencephalographic signs of cerebral immaturity This procedure implies a comparison between 'EEG age' measured from maturation of EEG frequency spectra and the biological age of the patient

In the statistical analysis, X^2 test in a fourfold table with Yates correction was employed When the expected frequencies were less than five in any of the cells an exact confidence interval for proportions was also constructed (Scientific Tables Documenta Geigy 1975)

MATERIAL

The study comprised 57 patients with idiopathic scoliosis referred to the Department of Orthopaedic Surgery I at Sahlgren Hospital during 1975–1976 Age and sex ratio are shown in Table 1 The patients were divided into subgroups with regard to the magnitude and convexity of the curve (Table 2) The magnitude of the scoliosis has been classified according to whether the deformity required treatment or not. As a rule, the indication for treatment has been a curve of more than 20° (Cobb 1948) in a patient still skeletally immature In two patients with curves of 17°, however, a brace was applied The two different subgroups requiring treatment have been analysed together and they were investigated with EEG prior to treatment. All patients

Table 1 Material

Range (years)	Mean age ± s.d (years)	Sex ratio ♂/♀
10–16	13 3 ± 1 7	8/49

Table 2 Grouping of scoliotic patients with regard to magnitude and convexity of the curve

	Patients placed under observation	Patients requiring treatment	Total
Right convex single curve	9 (5)*	19 (11)	28 (16)
Left convex single curve	11 (8)	10 (6)	21 (14)
Double primary curve		8 (4)	8 (4)
	20 (13)	37 (21)	57 (34)

* Figures within brackets indicate number of patients meeting criteria of normality in control group.

had a thorough somatic investigation, emphasizing the neurological status according to a special schedule

The EEG findings in the patients were compared with those in the healthy children belonging to a material previously described by Petersén & Eeg-Olofsson (1971) and Eeg-Olofsson (1971)

These children were selected according to well defined criteria of normality This means that children not possessing signs or symptoms which imply a risk of the appearance of certain EEG patterns, looked upon as abnormal in the literature, have been investigated. The selection is based on the following criteria of normality 1) An uneventful prenatal, perinatal and neonatal period, 2) No disorder of consciousness (sporadic syncope however, was accepted), 3) No head injury with cerebral symptoms, 4) No history of central nervous system diseases 5) No obvious somatic disease, 6) No convulsions, 7) No family history of convulsive disorders other than those secondary to acquired cerebral damage 8) No paroxysmal headache or abdominal pain, 9) No enuresis or encopresis after the fourth birthday, 10) No tics, stuttering, pavor nocturnus or excessive nail-biting, 11) No obvious mental diseases, 12) No conduct disorders, 13) No deviation with regard to mental and physical development. For the present investigation all children in the same age-group as the patients with scoliosis were chosen (362 children 194 girls and 168 boys. Sleep recording was done in 275 children 152 girls and 123 boys.)

RESULTS

Out of the 57 cases (49 girls and 8 boys) with scoliosis 34 (29 girls and 5 boys) met the criteria of normality Among the 23 patients not meeting these criteria the majority had had some problem during the perinatal period (e g prematurity, forceps extraction), others moderate head trauma or enuresis. Absence of the earliest history because of adoption constituted the deviation from criteria of normality in three patients. Psychological or cosmetic problems were admitted in six cases only None of the children presented any pathological neurological signs.

Comparison within scoliotic patients after grouping with regard to magnitude and convexity of the curve

Among the different EEG-patterns, "paroxysmal activity at rest" occurred to a greater extent in patients placed under observation than in those requiring treatment ($P<0.05$) (Table 3) Otherwise no difference was present between these two subgroups. The localization of EEG abnormality within the hemispheres tended neither to agree nor to disagree systematically with the direction of the scoliosis.

Comparison between EEG findings in scoliotics and healthy children

A Visual assessment (Table 4)

Increase of low frequency activity

Slight increase of low frequency activity within the theta range occurred in ten cases and

Table 3 Distribution of EEG patterns in patients with scoliosis

EEG pattern		a Patients placed under observation 20 (13)* cases	b Patients requiring treatment 37 (21) cases	Difference a – b	Total 57 (34) cases
I	Increase of low frequency activity	7 (4)	6 (3)	NS (NS)**	13 (7)
II	Paroxysmal activity at rest	6 (5)	2 (1)	$P<0.05$ (NS)	8 (6)
III	14–6 positive spike and/or 6 Hz spike phenomenon with sleep	8 (6)	11 (6)	NS (NS)	19 (12)
IV	Paroxysmal effects with either of the activation procedures (III excluded)	3 (2)	5 (3)	NS (NS)	8 (5)

* Figures within brackets indicate number of patients meeting criteria of normality in control group.
** NS = not statistically significant

Table 4 Distribution of EEG patterns in patients and controls

EEG pattern		A. Total group of scoliotics $n = 57$	B Scoliotics meeting criteria of normality $n = 34$	C Healthy children $n = 362$ (I + II) $n = 275$ (III)	Statistical differences A C	B-C
I	Increase of low frequency activity	13 (23%)	7 (21%)	54 (15%)	NS*	NS
II	Paroxysmal activity in rest	8 (14%)	6 (18%)	9 (3%)	$P<0.01$	$P<0.01$
III	14-6 positive spike and/or 6 Hz spike phenomenon	19 (33%)	11 (32%)	67 (24%)	NS	NS

* Not statistically significant

moderate increase in three cases This implies an EEG by definition referred to as pathological in 23 per cent For the patients fulfilling the normality criteria applied to the healthy children the figure was 21 per cent Neither of these figures showed any statistically significant difference from those in healthy children (15 per cent) Nor did the type of abnormality or localization within the hemispheres differ in any notable way In four cases, however, some kind of paroxysmal activity appeared in addition to the increase of low frequency activity (see below)

Paroxysmal activity at rest

In agreement with Eeg-Olofsson et al. (1971) paroxysmal activity is defined as discharges of spikes (14–6 Hz positive spike phenomenon excluded) or sharp waves and spike-and wave complexes as well as burst of delta and/or theta activity with amplitudes exceeding at least twice that of the background activity

1) Frequency of paroxysmal activity Paroxysmal activity occurred in eight out of 57 cases (14 per cent) in the total material of

scoliotic children and in six out of the 34 cases (18 per cent) which met the normal criteria of the healthy group In the normal series, nine out of 362 children presented some kind of paroxysmal activity (3 per cent) Thus the occurrence of paroxysmal activity was higher in the patients than in the normals This applied to the total group of children with scoliosis as well as to those meeting the criteria of normality The difference was highly statistically significant in both groups ($P < 0.01$)

ii) *Type and lateralization of paroxysmal activity* Focal paroxysmal activity occurred in only one out of eight patients, a 12 year old girl with sharp waves in the left fronto-temporo-central leads. Two cases showed more or less distinct sharp waves fronto-temporal left and fronto-temporal bilaterally respectively The remaining five cases presented bilateral synchronous paroxysmal slow activity (Figure 1) including sharp wave and/or spike potentials in four cases. Slight side dominance to the right was noted in three cases and no side difference in the remaining two Four children presented increase of low frequency activity as well

Paroxysmal activity of the healthy children was mainly focally distributed Only one out of nine in this group showed diffuse bilateral paroxysmal slow activity

iii) *Age of patients with paroxysmal activity* All eight patients were 12 years of age or more one case 12 years, two cases 13 years, three cases 14 years and two 15 years. In the normal series five out of nine were 12 years or below and the remaining cases below 15 years.

Thus the paroxysmal activity was significantly more frequent in children with scoliosis than in normals the type and localization of paroxysmal activity were different – paroxysmal slow activity bilaterally being the most usual pattern with patients, and focal sharp waves occurring in healthy children

14–6 Hz positive spike and/or 6 Hz spike phenomenon

This pattern was clearly age dependent In the age groups concerned the incidence was high in normals, percentages varying between 17 and 38 11 year-old boys presented the

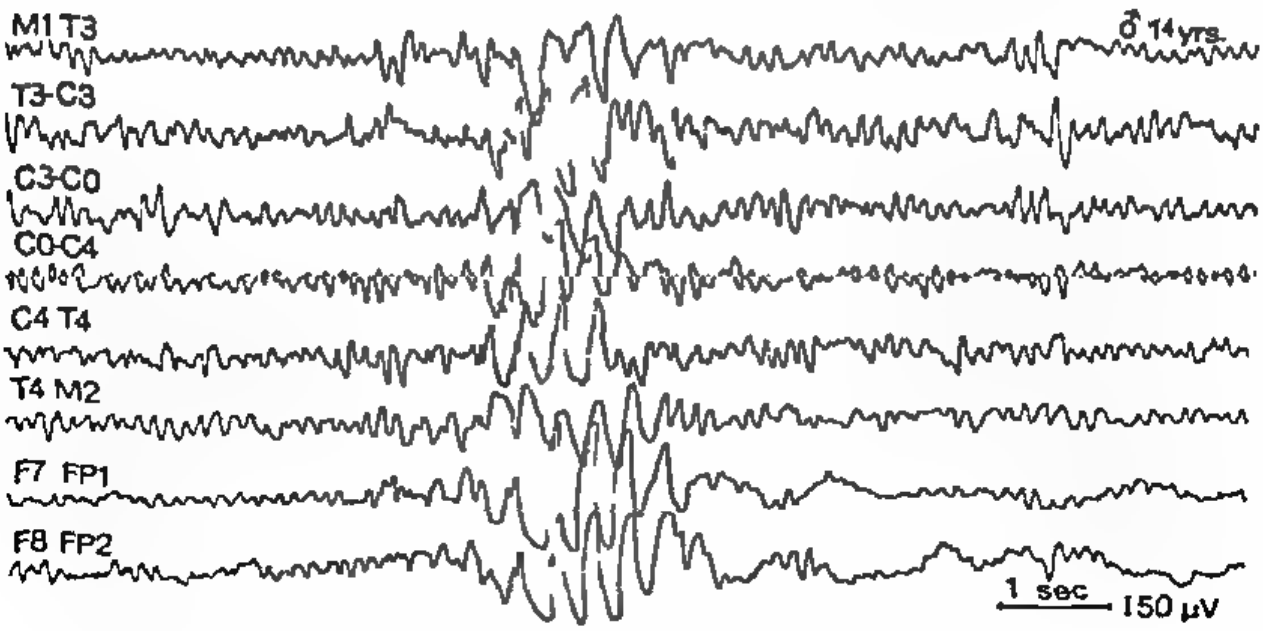

Figure 1 An example of bilaterally synchronous paroxysmal activity in a 14-year-old boy

highest figure and 10-year-old girls the lowest It occurred in 19 out of 57 children with scoliosis (33 per cent) and in 12 out of 34 patients meeting criteria of normality (32 per cent) Of the total of 19 patients showing this pattern, 13 had only 14–6 Hz positive spikes, 4 had 14–6 Hz positive spikes + 6 Hz spike-and-wave activity, and 1 had only 6 Hz *spike-and-wave activity The healthy children* presented this phenomenon in 67 cases out of 275 (24 per cent)

Paroxysmal effects occurring with any of the activation procedures

As described above children with scoliosis showed a large amount of paroxysmal activity in the resting EEG With activations, however, the paroxysmal effects were comparatively few The number of effects encountered was only 13 in the total scoliosis material The corresponding figure found in normals was 38 in 362 cases

In summing up the results, the statistical outcome as to representation of EEG findings was the same in patients meeting criteria of normality as in the total material Only the pattern "paroxysmal activity at rest" was found significantly more often in children with scoliosis than in normals It should be mentioned, however, that there was a marked tendency towards greater EEG pathology in patients This was invariably true, even after subgrouping patients into those who met the normality criteria and those who did not When considering deviation from strictly normal in resting EEG on the whole, 17 out of 57 children with scoliosis (30 per cent) exhibited at least one of the patterns "*increase of low frequency activity*" and "paroxysmal activity" The corresponding figures in the healthy children were 63 out of 362 (17 per cent) The difference was statistically significant ($P<0\ 05$) Moreover the number of cases without any deviation from strictly normal EEG was 15 (44 per cent) in patients and 236 (65 per cent) in healthy controls ($P<0\ 05$)

B Assessment by means of automatic frequency analysis

Frequency analysis was performed in 29 of the 57 cases Age and sex distribution in these cases, as well as the number of patients meeting criteria of normality, were essentially the same in this group as in those not submitted to frequency analysis. Twenty of these cases met the normality criteria The results in the nine cases not meeting these criteria were disregarded – The outcome of the analysis did not support the hypothesis that children with scoliosis might show signs of delayed cerebral maturation Thus all cases exhibited a frequency spectrum within the limits encountered in the healthy group

DISCUSSION

As stated in the introduction, no EEG studies have previously been made of patients with idiopathic scoliosis A number of writers, however, have suggested the possibility of a functional disturbance or organic injury in the CNS as a contributory cause in the development of this disease An EEG study was therefore thought to be justified, partly to ascertain whether there would be pathological findings at all, and partly to investigate the type and localization of any abnormalities To some extent, different EEG patterns stem from different cerebral structures, and the EEG may therefore help us to find out what levels in the CNS could be involved in a pathological process Furthermore, the EEG can give certain information about the degree of cerebral maturity since its frequency development, among other things, is a *function of age*. Normally, this development goes on continuously during the period of growing up, and is virtually completed at puberty The last phase of maturation coincides with an age that is particularly susceptible to the rise and progress of adolescent idiopathic scoliosis A delay in CNS maturation ought therefore to be reflected in these patients' EEGs As shown earlier by

Japanese writers (Yamada & Yamamoto 1972) scoliosis patients are behind in the development of the equilibrium function as compared with normal children of the same age This might perhaps indicate that the scoliosis patients have a deficient CNS maturation in relation to their age

When judging the probability that an EEG abnormality is connected with a particular disease in the patient, possible sources of error must be taken into account Special difficulties in evaluation arise from the fact that similar EEG abnormalities may appear with different diseases and that some deviations from a strictly normal EEG also occur in clinically and anamnestically healthy individuals. The cause of the latter may perhaps be incomplete diagnosis, where it is a question of confirming earlier more or less important injuries. In the evaluation of EEG findings in a clinical material, therefore, the material must be well defined, not merely as regards the disease dealt with by the investigation but also in other respects, particularly where diseases or injuries which may involve the CNS, primarily or secondarily, are concerned. In addition, the same demand must be made of so-called control or normal materials, in order to avoid as far as possible erroneous conclusions about the significance of the EEG findings Unique possibilities for making relevant comparisons are obtained when the clinical material fulfils the same criteria of normality as the comparison material except for the particular disease which is the object of study Any differences which appear in the EEG findings may then, with reasonable probability, be attributed to the factors connected with the disease in question

In the normal material published by Petersén & Eeg-Olofsson (1971) the children selected were children who did not possess any special signs or symptoms which imply a risk of the appearance of certain EEG patterns looked upon as abnormal. The materials compared in our own study were investigated in the same way, both anamnestically and clinically

In our scoliosis material, some patients fulfilled these criteria while others did not. All the scoliosis patients showed normal findings in the clinical neurological examination. As will be seen in the account of the results, 34 patients fulfilled the criteria applied in the selection of the control material This provided a unique opportunity to compare EEG findings in groups of individuals where the disease studied in the patient group constituted the main difference between them

It should be emphasized in this connection that the scoliosis in itself can be thought of as forming a more or less pronounced factor of mental stress for the patients The difference between the normal cases and the scoliosis patients would then also include possible effects secondary to the stress patients were exposed to on account of their disease. Reports on EEG responses to stress, however, are fairly few and mostly concerned with considerable physical strain on the individual, e g gravitation force during flight, and major surgery

With less dramatic strain on the individual discrete EEG changes are described by Kamp et al (1970) These authors found only slight shifts of the peak in the alpha frequency band when submitting experimental persons to minor physical and mental loads. These were mostly psychological tests of different kinds. In our investigation, however, only six cases admitted psychological or cosmetic problems, and only one of these patients showed an EEG finding which deviated from the normal.

Certain other problems connected with our comparison between the EEG findings in the scoliosis cases and those in normal children will be taken up for discussion It is a fact that some EEG patterns show age and sex variations, and therefore the age and sex distribution in the material to be compared ought to be more or less the same Our scoliosis material presents essentially the same age distribution as the control material, and sources of error due to uneven age distribution can thus be disregarded. On the other hand there is a very uneven distribution where sex is concerned. In the normal

material the sex distribution was equal, whereas the scoliosis material contained a clear majority of girls The reason for this is that such a sex distribution is inherent in the nature of the disease, particularly if one considers progressive curves and curves which require treatment

Of the EEG variables discussed, however, only the "14–6 Hz positive spike" pattern and "paroxysmal effect on intermittent photic stimulation" showed a sex difference in the relevant age groups in normal children Boys showed a higher frequency of the first-mentioned activity than girls, and girls a higher frequency of the second than boys (Eeg-Olofsson 1971, Eeg-Olofsson et al 1971) As regards the "14–6 Hz positive spike" pattern, it is pointed out that the small number of boys in the scoliosis material should help to weaken any significant differences, as the comparison was made with a normal material with an even sex distribution As to "paroxysmal effect on intermittent photic stimulation", this occurred in so few scoliosis cases that statistical calculation would be irrelevant

Some findings of special interest emerged in the EEG investigation of the scoliosis patients, in particular with regard to the occurrence of paroxysmal abnormalities in resting EEG These appeared to a statistically very significantly higher degree ($P<0\,01$) in the scoliosis cases than in the normal ones It could be observed, furthermore, that the scoliosis patients presented a strikingly higher percentage of deviations from strictly normal resting EEG on the whole These deviations were of the same magnitude in the group which fulfilled normal criteria as in the total material (32 per cent and 30 per cent, respectively) Consequently, possible cerebral pathology referable to cases excluded by the normal criteria was not likely to represent a source of error when evaluating the statistical outcome

The paroxysmal abnormalities in the scoliosis cases were to a large extent bilaterally synchronous, and as a rule were spread over large areas of both hemispheres. The changes were of a type considered to be generated in subcortical, deep-lying midline structures, thus including the brain stem region (Fortuyn & Jasper 1947, Magoun 1953) An example of an abnormality of this kind will be seen in Figure 1 These findings are of particular interest as they may indicate a lesion or a dysfunction of cerebral structures at the level of the brain stem In the CNS, it is also the brain stem level which is of most interest, from the aetiological point of view, in idiopathic scoliosis first in the light of the reports mentioned in the introduction and second in the light of what we know about its fundamental importance for postural equilibrium

In this connection, the high percentage of occurrence of "14–6 Hz positive spikes and/or 6 Hz spike waves" should also be recalled This activity appeared to the same extent in the whole group of scoliosis cases as in the 34 patients meeting normal criteria (33 per cent and 32 per cent, respectively) It has been said that clinical correlatives to this pattern in children include autonomic dysfunction, behaviour problems and convulsive phenomena (Niedermeyer & Knott 1961, Henry 1963, and Hughes 1965) In no case, however, was the reason why some patients did not fulfil the criteria of normality due to the occurrence of these clinical symptoms

"14–6 Hz positive spikes" and "6 Hz spike wave" activity often occur in the same patient and it is sometimes difficult to distinguish between them, since so-called transitional forms are common (Silverman 1967) Particularly "14–6 Hz positive spike" activity (occurring in 18 of the 19 patients in this pattern group) is regarded as being generated in the hypothalamus region (Gibbs & Gibbs 1951, Little & Bevilacqua 1962, Niedermeyer et al 1967)

The difference in incidence between scoliosis and normal cases was not statistically significant, it is true, but this may be due to the fact that the boys in one of the

age groups of the normal material showed a notably high percentage of this pattern Thus, compared with 11-year-old girls, the percentage among 11-year-old boys was about twice as high It was also twice as high as the figures found in the neighbouring age groups in both sexes This might have induced an error, as the calculation was based on equal numbers of both sexes in the healthy children, while the patients were mainly girls. In spite of this souce of error, the percentage of this pattern was considerably higher in the scoliosis cases than in the normal ones.

Another circumstance that may be interesting to note is the appearance of paroxysmal changes in relation to age among the scoliosis patients From studies of a normal material (Petersén & Eeg-Olofsson 1971, Hagne 1972) it appears that paroxysmal activity shows a pronounced dependence on age From a very high frequency postpartum (about 40 per cent), a marked and thereafter successive decrease in frequency takes place during the first year of life At the time when scoliosis develops the figures stands at about 3 per cent Among the scoliosis cases a greatly increased frequency could be observed without the tendency to a decrease in occurrence in the older children It may be asked, then, whether this is really a reflection of cerebral pathology or perhaps, instead, of cerebral immaturity in these individuals, but the type and localization of the paroxysmal changes rather suggest cerebral pathology than cerebral immaturity The investigation by means of frequency analysis carried out on a part of the material gave no support, either, for the possibility of a lack of cerebral maturity in relation to age in these children.

In the natural history of idiopathic scoliosis there is the interesting tendency, hitherto unexplained, for an affected girl to run a definitely higher risk, as compared to a boy, of her scoliosis progressing during puberty (Rogala et al 1976). The incidence of idiopathic scoliosis, too is higher in girls, especially with more important curves, e g over 10° (Rogala et al 1976 Brooks et al 1975) Unexplained sex differences are also to be found with certain EEG variables. By means of EEG investigation of healthy individuals between the ages of 1 and 60 years (Sellden 1964, Petersén & Eeg-Olofsson 1971) these sex differences have been documented. In particular, women show more frequent and more powerful effects than men with different types of activation These EEG effects often appear with an extension over the hemispheres which points to an involvement of subcortical midline structures. The reason for this increased sensitivity in women to various stimuli, of course, can only be a matter for speculation One wonders whether a lower tolerance for various afferent stimuli can contribute in some way to the higher frequency of scoliosis among the girls.

In healthy children, the pattern "increase of low frequency activity" also shows certain sex differences during the period of growing up (Petersén & Eeg-Olofsson 1971) Thus a higher frequency appeared among the boys than among the girls up to the age of 8 years, while the reverse was the case after 14 years. It is possible that this reflects a sex difference in the maturity profile of the EEG and is not exclusively a sign of cerebral pathology of some kind In this connection it may be mentioned that the incidence of "increase of low frequency activity" in boys and girls at different ages showed the same profile as the incidence of idiopathic scoliosis. James (1970) has shown that there is a majority of boys among the cases of infantile idiopathic scoliosis (≤ 3 years), after which the proportions alter successively until the relation is the opposite during adolescence (≥ 10 years).

Finally, one wonders if the result of an EEG investigation can be used in some way to assess the probable development of scoliosis in the individual case It is still not clear what factors cause the scoliosis in some patients to progress so that some form of treatment becomes necessary, while in others it remains unchanged or even regresses.

The number of EEG findings deviating from the strictly normal was not larger in

patients with scoliosis of greater magnitude than in other scoliosis patients On the other hand, for the variable "paroxysmal activity at rest" the opposite could be observed This tendency towards a higher frequency of paroxysmal activity in patients with smaller curves cannot be explained by difference of age, since the age distribution was the same in both groups No tendency to accumulation of particular EEG patterns was found in the cases requiring treatment, but the present material was too small to throw light on this problem In order to do this, a longitudinal study of a larger group of scoliosis cases would be needed

To conclude, it should be pointed out, however, that the number of pathological EEG findings in the scoliosis group as a whole was remarkably large In addition, the type and localization of the various abnormalities gave support for the hypothesis that centrally situated subcortical structures are involved in the pathological process in idiopathic scoliosis

REFERENCES

Brooks, H L, Azen, S P, Gerberg, E, Brooks, R & Chan, L (1975) Scoliosis A prospective epidemiological study *J Bone Jt Surg* 57-A, 968–972

Cobb, J R (1948) Outline for the study of scoliosis Instructional Course Lectures, the American Academy of Orthopaedic Surgeons 5, 261, J W Edwards, Ann Arbor

Crisfield, R J (1974) Scoliosis with progressive external ophthalmoplegia in four siblings *J Bone Jt Surg* 56-B, 484–489

Dretakis, E K & Kondoyannis, P N (1974) Congenital scoliosis associated with encephalopathy in five children of two families *J Bone Jt Surg* 56-A, 1747–1750

Duvoisin, R S & Marsden C D (1975) Note on the scoliosis of Parkinsonism *J Neurol Neurosurg Psychiat* 38 787–793

Eeg-Olofsson, O (1971) The development of the electroencephalogram in normal children from the age of 1 through 15 years 14 and 6 Hz positive spike phenomenon *Neuropädiatrie* 2, 405–426

Eeg-Olofsson, O, Petersén, I & Selldén, U (1971) The development of the electroencephalogram in normal children aged 1 through 15 years. Paroxysmal activity *Neuropadiatrie* 2, 375–404

Fortuyn, J D & Jasper, H H (1947) Thalamic centres controlling rhythmic electrical activity of the cortex Proc XVII Internat Physiol. Congress, Oxford, Abstracts, 368

Gibbs, E L & Gibbs, F A (1951) Electro-*encephalographic evidence of thalamic and* [illegible]

the EEG and behaviour abnormality *EEG and behaviour* Ed Glaser, G H 406 p Basic books, Publ, New York

Hughes, J R (1965) A review of the positive spike phenomenon *Applications of electro-encephalography in psychiatry* A symposium Ed Wilson, W P 268 p Durham, N C

James, J I P (1970) The etiology of scoliosis *J Bone Jt Surg* 52-B, 410–419

Kamp, A, Troost, J & van Rijn, A J (1970) [illegible] of mental and physical stress on the [illegible]

associated with proved hypothalamic disease Fourteen- and six-per-second dysrhythmia *Arch Neurol (Chic)* 6, 324–330

Magoun, H W (1953) Physiological interrelationships between cortex and subcortical structures *Electroenceph clin Neurophysiol*, Suppl 4, 163

Martin, J P (1967) *The basal ganglia and posture* pp 100–145, 30–35 Pitman Medical Publishing, London

Matousek, M & Petersén, I (1973) Frequency analysis of the EEG in normal children and adolescents *Automation of clinical electro-encephalography* Ed Kellaway, P & Petersén, I pp 75–102. Raven Press New York

Niedermeyer, E & Knott, J R (1961) Uber die Bedeutung der 14 und 6/sec.-positiven Spitzen im EEG *Arch Psychiat Nervenkr* 202, 266–280

Niedermeyer, E, Ray, C D & Walker, A E (1967) Depth EEG studies in a patient with fourteen and six per second positive spikes *Electroenceph clin Neurophysiol* 22, 86–89

Nordwall, A (1973) Studies in idiopathic scoliosis relevant to etiology, conservative and operative treatment *Acta orthop scand*, Suppl. 150

Petersén, I & Eeg-Olofsson O (1971) The development of the electroencephalogram in

normal children aged 1 through 15 years. Non paroxysmal activity *Neuropädiatrie* 3, 247–304

Robin G C (1975) *Scoliosis and neurological disease* A Halsted Press book

Rogala, E. J., Drummond, D S & Gurr, J F (1976) Scoliosis Incidence and natural history A prospective epidemiological study of 22,584 school children Presented at the Annual Meeting of Scoliosis Research Society, Ottawa, September

Scientific Tables, Documenta Geigy (1975), Ciba-Geigy Limited, Basel, Switzerland, 186–187

Selldén, U (1964) Electroencephalographic activation with Megimide in normal subjects. *Acta neurol scand*, Suppl. 12, 40, 1–69

Sharpe, J A, Silversides, J L. & Blair, R D G (1975) Familial paralysis of horizontal gaze *Neurology* 25, 1035–1040

Silverman, D (1967) Phantom spike-waves and the fourteen and six per second positive spike pattern A consideration of their relationship *Electroenceph clin Neurophysiol* 23, 207–213

Tezuka, A (1971) Development of scoliosis in cases with congenital organic abnormalities of the brainstem. *Tokushima J exp Med* 18, 49–62.

Yamada, K & Yamamoto, H (1972) Equilibrium function in scoliosis and active corrective plaster jacket for treatment The American Digest of Foreign Orthopaedic Literature, Third Quarter, 182–185

Correspondence to Tage Sahlstrand, M D, Department of Orthopaedic Surgery, Östra Sjukhuset, University of Goteborg, S 41685, Goteborg, Sweden

Acta orthop scand 50 295–302, 1979

MOIRE TOPOGRAPHY FOR THE DIAGNOSIS AND DOCUMENTATION OF SCOLIOSIS

STIG WILLNER

Department of Orthopedic Surgery Malmo General Hospital University of Lund Malmo Sweden

Moire topography is a biostereometric method which produces a three-dimensional image of the shape of the trunk In structural scoliosis an asymmetry of the two halves of the back is seen

This method has been studied and the range of the asymmetry of the moire pattern has been compared with clinical observations and X ray findings in 216 cases with structural scoliosis. A statistically significant correlation between these three ways of describing a structural scoliosis was found

Because of the sensitivity of the moiré method an asymmetry of at least one fringe interval could be regarded as a positive result All the observed asymmetries less than one fringe interval had a lateral deviation of the spine of less than 10 degrees according to Cobb when X ray examined The moiré method seems to be very suitable for the screening of structural scoliosis, owing to its ability to detect and document even small deformities by photography and the simplicity of the technique which can be carried out even by staff without medical training

Key words scoliosis moiré topography, screening rotation hump

Accepted 27 x.78

The results of both the conservative and the surgical treatment of scoliosis have improved considerably during recent years. This is partly due to the introduction of more efficient methods of treatment but also to a greater knowledge of scoliosis. It has also been found that the results of treatment improve if the treatment is started early during the course of the condition Therefore the interest in an early diagnosis of these deformities of the spine has now grown rapidly (Kane & Moe 1970, Asher et al. 1975 Winter 1975, Lonstein et al 1976, Gaines et al 1977, Adair et al. 1978)

Financial support was obtained from the Swedish Medical Research Council (project No B 78-17X-04780-03).

Screening for scoliosis is usually carried out at the school health examinations The investigation of the spine is here based entirely upon clinical observations. The diagnosis of more severe curves is not particularly difficult Smaller deformities, however, may easily be overlooked especially by an inexperienced investigator One weakness of clinical investigation is that the condition of the scoliosis cannot be compared between two examinations. Without an X-ray it is not possible to see if there is an increase in the deformity of the spine.

With the introduction of the moiré topography method a new means of describing and documenting the state of the spine has been made available This method which is able to diagnose even very small asymmetries

0001–6470/79 030295–08$02.50/0

© 1979 Munksgaard, Copenhagen

of the spine has been tested at the Orthopedic Department of Malmo General Hospital and the results are given later in this study

THE MOIRE TECHNIQUE

The physical meaning of the term moire is the pattern of shadows which are produced by interference when periodic or quasi periodic grids are placed one on top of the other The width of the lines of the grid should be equal to the space between them.

The moire effect can also arise through interference between a screen and its shadow which falls upon an object behind. The appearance of the fringe pattern is determined by the shape of the illuminated surface In this case the various shadow lines the contour lines – appear on the surface of the object at regular distances from the grid These lines can be compared with the contour lines on a topographical map The distance between the moire screen and the contour lines is determined by

1 The distance between the light source and the screen – l
2 The distance between the light source and the eye/camera – d
3 The screen intervals (the diameter of a screen wire plus the space between them – s.

Knowing these distances the distance to the first contour line – h – is calculated according to the following formula

$$h = \frac{s \quad l}{d - s}$$

Each point on the same contour line is at the same distance from the screen The difference in distance (to the moire screen) of two adjacent fringes is approximately equal for all the contour lines seen on the object

With this method asymmetries between the two halves of a back can be studied and recorded by comparing the moire patterns If the spine is erect and without rotation these fringe patterns will be symmetric If on the other hand, there is a structural scoliosis characteristic differences between the shadow patterns of the two halves will be observed (Figure 1) The degree of asymmetry of the shadow patterns is here

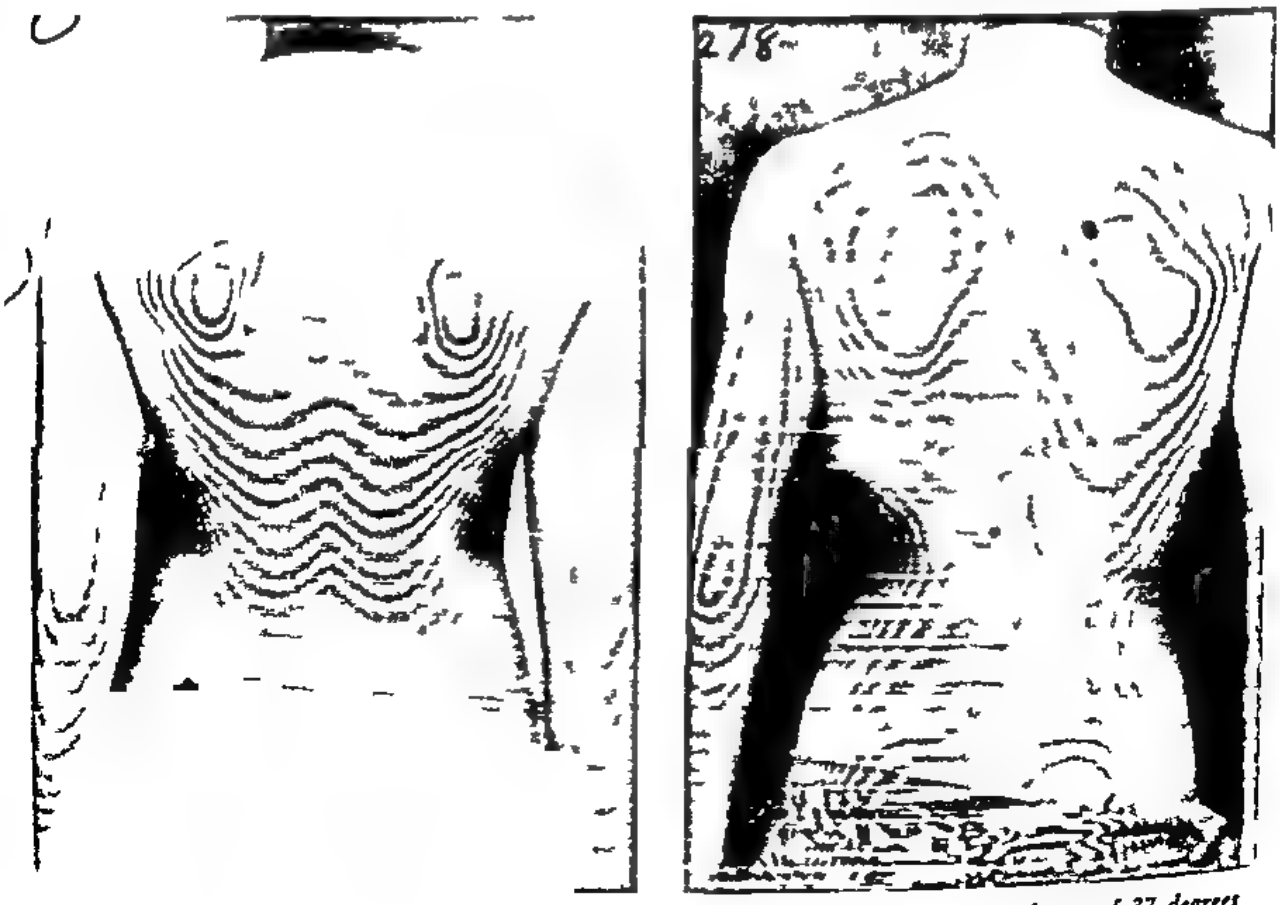

Figure 1 The moire photographs of a normal back (left) and a thoracolumbar scoliosis of 37 degrees (right)

Figure 2 The moire equipment

determined by the rotation of the scoliosis rather than by its lateral deviation

The moiré apparatus

The apparatus consists of the following components (Figure 2) The moiré frame (with an opening of 75 × 50 cm) is equipped with nylon wires which extend horizontally between the vertical sides of the frame The diameter of the wires and the space between them are both 1 mm The frame is fixed to a tripod which can be raised or lowered in order to facilitate the investigation of children of various heights. The light source consists of a studio light with an intensity of 1000 watt It is fixed to the same tripod as the camera which is on a level with the central point of the moiré frame A single-lens reflex camera (Canon AE with 81 mm focal length lens) is used. Generally, black and white film is used (Tri-X pan 400 ASA) The exposure time is 1/125 second and the aperture size 5 6–8

In this study the following distances between the [illegible]

[illegible] these circumstances the difference in distance to the frame between adjacent contour lines will be 0 7 cm In order to compare the moiré photos from examination to examination the patient must be accurately repositioned against the moiré screen with the back just touching the screen at the shoulders and buttocks. It is also necessary to make the children stand erect, relaxed and with equal load on both legs.

The interpretation of the moiré pictures

The pictures are easily obtained and do not require trained medical personnel The evaluation of the photograms, however should be performed by members of the school health staff

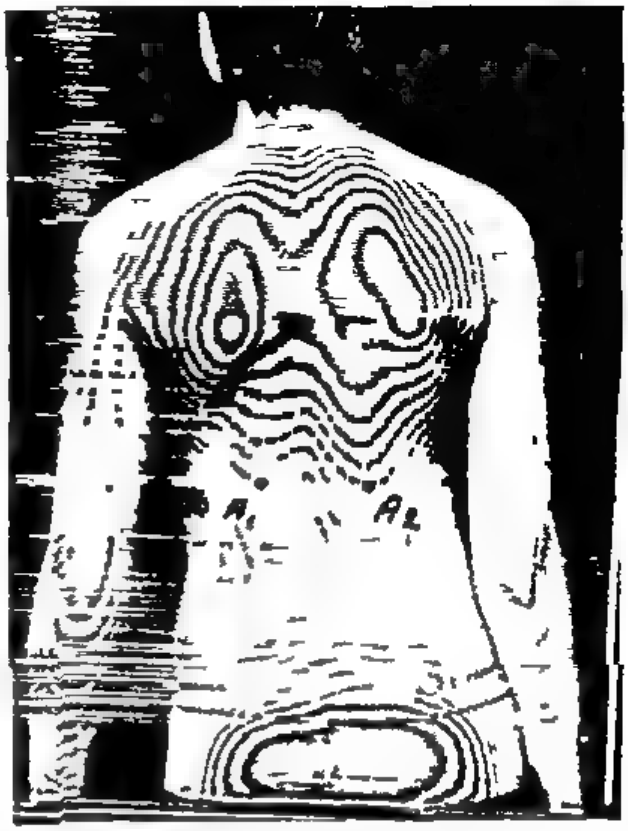

Figure 3 A 10-year-old girl with a right convex thoracic scoliosis (24 degrees and apex T 9) A deviation of two moire fringes is seen between the two symmetric points A_1 and A_2 indicating a right convexity A deviation of the number of contour lines is also seen laterally to the scapular contact surfaces

The asymmetry between the moiré pattern of the convex half and that of the concave one can be deduced from the following observations

1 Contact surfaces of varying size between the scapulae and the wires of the screen occur in the case of thoracic and thoracolumbar scolioses (Figure 3) If the curve is located distally in the lumbar spine an asymmetry of the contact surfaces of the buttocks will also be visible

2. A difference in level of the contour lines between the convex and concave halves is most noticeable at the level of the vertex of the scoliosis. If there are curves in the proximal thoracic spine this difference in level is seen proximally to the contact surfaces of the scapulae If, on the other hand the scoliosis is located in the lower half of the thoracic spine and in the lumbar spine the difference in the level of the contour lines will be seen distally to the contact surfaces of the scapulae (Figure 3) If two symmetrical points are marked one on each side of the body the relationship of these to the fringe pattern will be evident. The more fringes that separate the two,

Figure 4 A 16 year old girl with a right convex thoracic curve (20 degrees and apex T 4) and a left convex thoracolumbar curve (18 degrees and apex T 12) The symmetric points A_1 and A_2 are located on different contour lines with a deviation of two moiré fringes The symmetric points B_1 and B_2 are also seen to be on separate contour lines with a deviation of one moire fringe

the larger in the rotational deformity The shapes of the contour lines also differ to a greater extent with increasing deformity of the back The contour lines on the concave half become more and more vertical and lose their rounded shape across the paravertebral muscles On the convex half the rounded form of the contour lines will be more and more noticeable (Figure 3)

3 In scolioses located in the mid thoracic spine the asymmetry of the moiré pattern is most visible laterally to the contact surfaces of the scapulae (Figure 4) On the convex half an increasing number is found due to the hump By studying the difference in the contour lines at 1 cm lateral to the scapulae plateau an estimation of the asymmetry of the chest can be obtained

Because of the sensitivity of the method to record asymmetries of the shadow pattern even in very small rotational deformities of the spine a difference less than one fringe interval has been accepted as a normal spine



Figure 5 Clinical evaluation of rotation in a forward bending position

PATIENTS AND METHOD

The study included 216 children with a structural scoliosis with a varying range of severity (5 degrees to 65 degrees according to Cobb 1948) Five cases were congenital scolioses, three paralytic scolioses and 208 children had a scoliosis of the idiopathic type One hundred and thirty seven cases were single primary curves and 79 were double primary curves In the latter group both curves were studied with the moire method One hundred and forty seven curves were located in the thoracic spine (Th 1 to Th 11) and 160 were thoracolumbar and lumbar curves (Th 12 to L 5)

All the children were investigated clinically (forward bending test) roentgenographically (Standing AP X ray) and with the moiré method on the same occasion The range of the rotation was determined according to Figure 5

RESULTS

All cases were first diagnosed clinically with positive forward bending test which showed a visible asymmetry of the trunk caused by a rotation of the spine

When comparing the range of the curve according to Cobb and the range of the deviation of the contour lines on both halves of the back a significant correlation was seen (Figure 6) All the 11 cases with a lateral deviation of less than 10 degrees had a deviation of less than one fringe interval which in our study had been designated as the lower limit for a positive result With a deviation of more than one fringe interval practically all of the scolioses exceeded 10 degrees. When the deviation was three fringe intervals or more all cases had a curve of

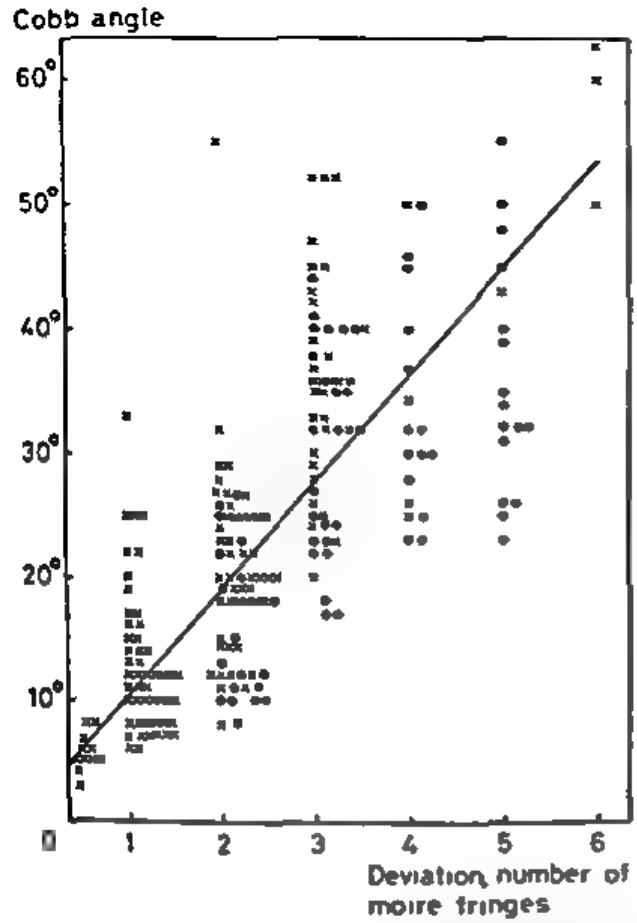

Figure 6 Correlations between lateral deviations and asymmetries of moire fringes in structural scoliosis (only the maximal curves are included) ● = maximal deviation of the moiré fringes laterally to the contact surface of the scapulae x = proximally or distally to the scapulae y = 8 x + 4 8, r_{216} = 0 77

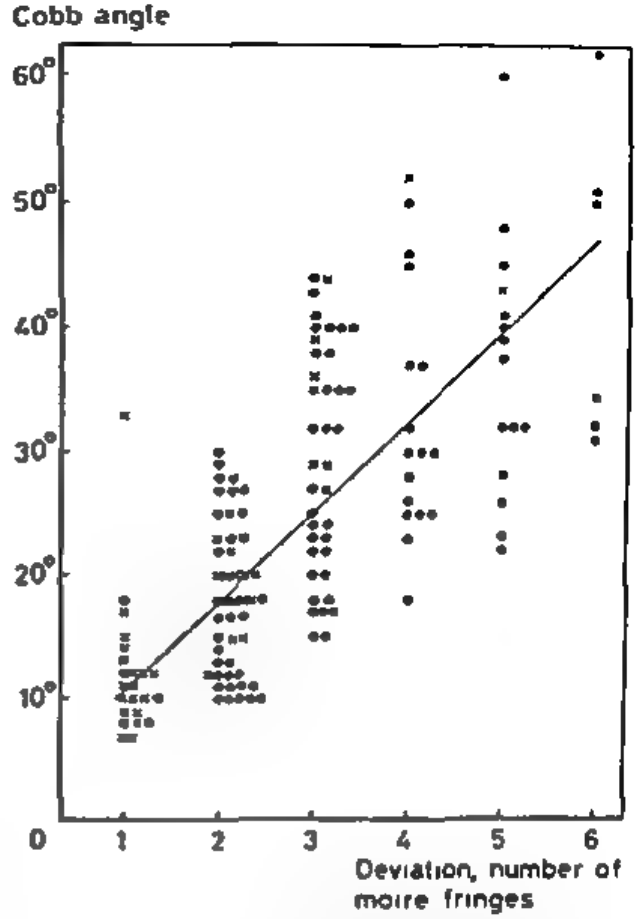

Figure 7 Correlations between lateral deviations and asymmetries of moiré fringes in thoracic curves (Th 1–Th 11) ● = maximal deviation of the moiré fringes laterally to the contact surface of scapulae x = proximally or distally to the scapulae y = 6 7 x + 6 1, r_{146} = 0 73

more than 20 degrees, which was the borderline for active treatment of a growing child A wide range of lateral deviation was seen in all the various groups of deviations of fringe intervals. However, it must be remembered that the moiré method registered the rotation and the X-ray examination the lateral deviation of the scoliosis.

When comparing the moiré pattern with the X-ray findings in scoliosis partly located in the thoracic region (Figure 7) and partly in the thoracolumbar and lumbar spine (Figure 8) a closer correlation was found in the lumbar region In Figure 6 a deviation of two fringe intervals or more was associated with a scoliosis of more than 20 degrees

Another significant correlation was found when comparing the deviation of the contour intervals with the range of asymmetry of the hump (Figure 9)

Finally, a comparative study of the X-ray observed lateral deviation and the clinically estimated size of the hump was performed (Figure 10).

DISCUSSION

During the last few years the importance of early diagnosis of the structural scoliosis in progress in the growing child has become

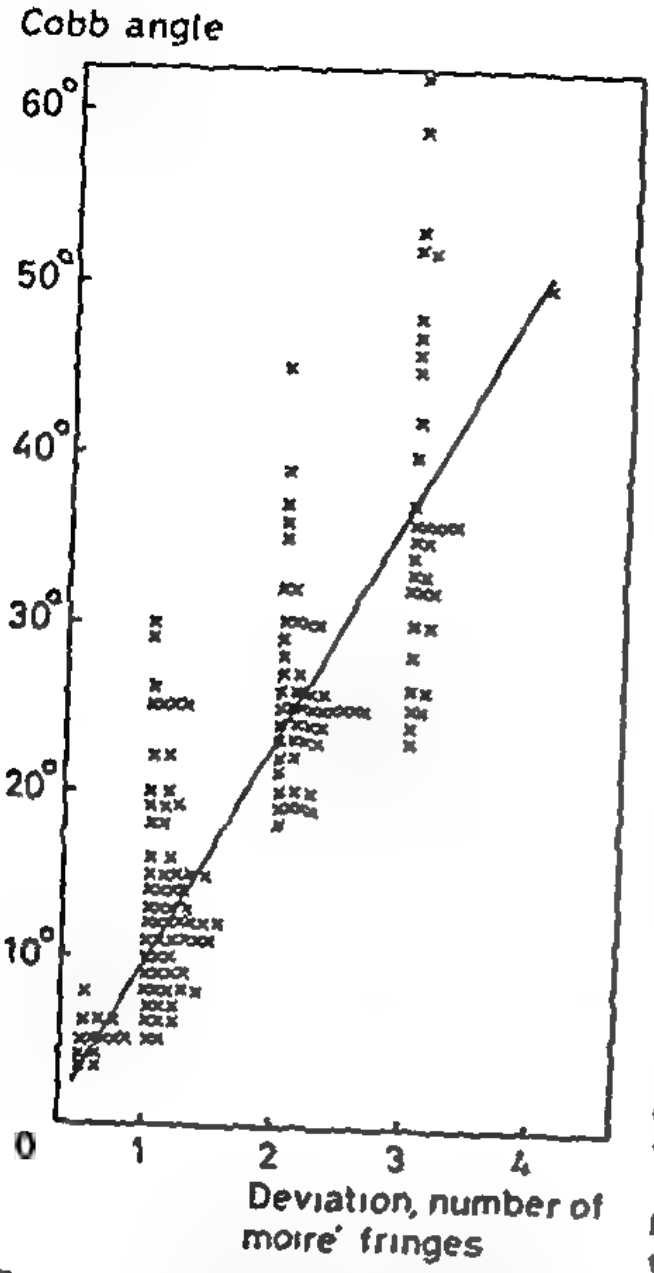

Figure 8 Correlations between lateral deviations and asymmetries of moiré fringes ■ thoracolumbar and lumbar curves (Th 12–L 5) Maximal deviations are only seen distally to the contact surface of the scapulae y = 12 4 x + 1 1, r_{189} = 0 84

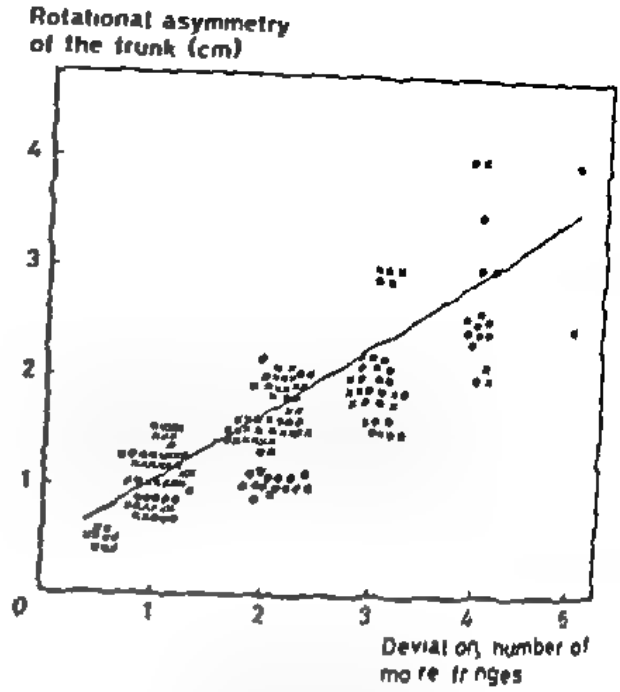

Figure 9 Correlations between the clinically estimated size of the humps (cm) and the asymmetries of the moiré fringes in the structural scoliosis x = located in the thoracic spine (Th 1–Th 11) ● = in the thoracolumbar or lumbar spine (Th 12–L 5) y = 0 55 x + 0 45, r_{166} = 0 83

evident Therefore interest in the various screening methods has also increased

The criteria for an acceptable screening method are

1 The possibility of diagnosing very slight deformities of the spine,

2 A minimal number of false positive and negative results,

3 A simple technique with a minimal risk of personal error and which allows the investigation of many children in a short time,

4 The possibility to document the findings for comparison with subsequent examinations

Most screening methods used nowadays to detect scoliosis are exclusively clinical studies. Roentgenological screening is neither ethically nor economically justifiable With moire topography a new optical biostereometric method has been introduced for school screening of scoliosis

This method was first described by Takasaki (1970, 1973) An evaluation of the moiré method has been published by Drerup (1977)

The interest in the use of the moiré technique in school screening has increased during the last few years Recently a moiré screening program was published by Adair et al (1978) They found that the moiré method

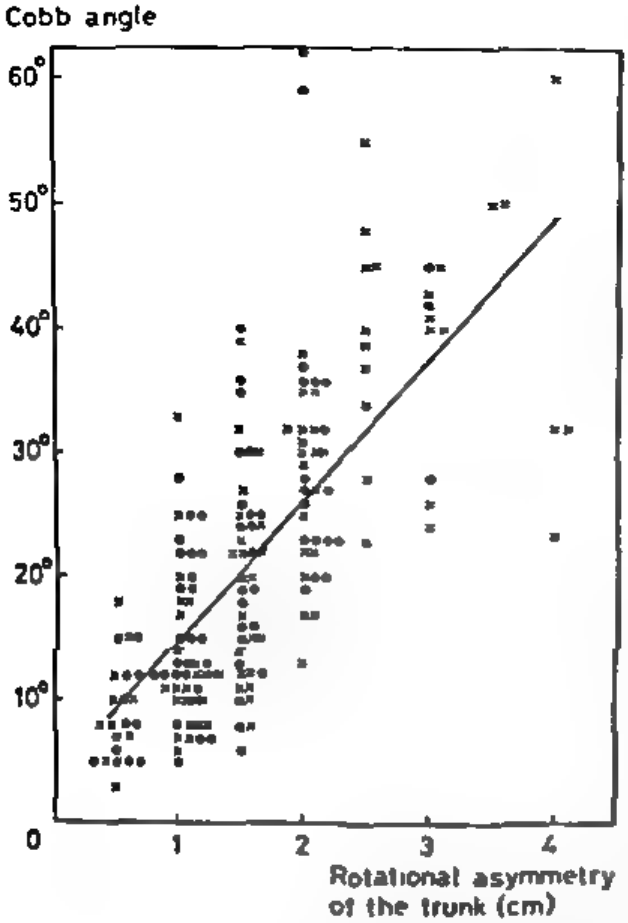

Figure 10 Correlations between lateral deviations and sizes of the humps in structural scoliosis x = located in the thoracic spine (Th 1–Th 11) ● = in the thoracolumbar or lumbar spine (Th 12 L 5) y = 11 6 x + 3 7, r_{100} = 0 73

registered X-ray diagnosed scoliosis with greater accuracy than clinical observation (forward bending test), 94 per cent and 46 per cent, respectively

In the straight trunk the moire patterns are equal in both halves of the back (Figure 1) On the other hand, with an increasing asymmetry of the trunk the two moiré patterns deviate more and more from each other However, it is important to remember that the deviations of the moiré pattern are mainly caused by a rotation and not by a lateral bending The latter is measured and discussed roentgenographically when describing the spinal deformity This means that the moiré technique and the X-ray examination describe two separate properties of structural scoliosis

As the moire method has been shown to be very sensitive and to register even very insignificant asymmetries of the trunk we decided to accept as "normal spines" all those whose asymmetries are characterized by a deviation of less than one fringe interval (with the equipment we used) In no case in this study was a deviation of less than one fringe interval found to accompany a lateral deviation of more than 10 degrees according to Cobb This means that the risk of getting a false negative result or missing a case requiring active treatment would appear to be small

On the other hand, defining all types of asymmetries as positive results, the moiré method will be burdened with a large number of false positive results without any clinical value

Even if this study as a whole shows a statistically significant correlation between the deviation of the contour intervals and the range of the X-ray examined lateral deviation according to Cobb a wide spread of lateral deviation is seen in all the groups of deviations of fringe intervals. In the thoracolumbar and lumbar scoliosis a deviation of two contour intervals or more is indicative of curves of more than 20 degrees. In thoracic scoliosis most of the midthoracic curves are mainly detected by the deviation of fringe intervals lateral to the shoulders. Here there seems to be a wider distribution of lateral deviations in the groups of deviations of fringe intervals than in the groups with maximal deviation below the shoulders.

As expected, a significant correlation was observed between the range of the hump and the moiré asymmetry In reality both these observations describe the same component of the scoliosis, viz the rotation.

A significant correlation was also seen between the range of the hump deformity measured clinically and the lateral deviation as measured by X-ray examination as formerly discussed by, among others, Gotze (1973). However, this correlation was not so evident as that between the moiré asymmetry and the X-ray observation

The moire method, however, demands that the children stand in a correct position in relation to the grid This means that there should be slight contact between both the shoulders and buttocks and the screen An incorrect position, however, can easily be observed by the photographer if he studies and counts the number of contour lines on either side of the midline between the shoulders, which should be equal

The advantage of this method in comparison with clinical ones is the possibility to document the condition of the back. Furthermore the moiré method is easy to apply and can be managed by paramedical staff The investigation can be performed rapidly by two persons, one photographs and the other helps the children to stand in a correct position About 40 children can be investigated per hour

When studying the moire photos it is important to look for the maximal deviation of the fringe intervals between the two halves of the trunk laterally as well as above or below the contact surfaces of the shoulder Also the difference in size and level of these contact surfaces must be studied

CONCLUSION

Our observations show that the moire technique is suitable for the screening of structural scoliosis because of

1 Its sensitivity to even small deformities,
2 The simplicity of the technique,
3 The possibility of documenting the condition of the back for comparison with subsequent examinations

REFERENCES

Adair, I V, van Wijk, M C & Armstrong G W D (1978) Moire topography in scoliosis screening *Clin Orthop* 129, 165–171

Asher, M A, Adler, F & Jacobs R R (1975) Idiopathic adolescent scoliosis. Rationale and techniques of early detection *J Kans med Soc* 76, 285–292

Cobb, J R (1948) Outline for the study of scoliosis Instruct Course Lectures Amer Academy of Orthopaedics p 261

Drerup, B (1977) *Eine Apparatur zur Dokumentation von Erkrankungen des Haltungs und Bewegungsapparates durch Moiré Topografie* Sonderforschungsbereich 88 Westfälische Wilhelms-Universitat, Munster

Gaines R W, McKinley, L M & Leatherman K D (1977) Scoliosis must be diagnosed early *Kentucky med J* 75, 231–234

Gotze H-G (1973) Der Rotationsindex bei idiopathischen Thorakalskoliosen *Z Orthop* 111, 737–743

Kane, W J & Moe, J H (1970) Scoliosis prevalence survey in Minnesota *Clin Orthop* 69, 216

Lonstein J E, Winter R B, Moe, J H Bianco A J, Campebell, R G & Norval, M A (1976) School screening for the early detection of spine deformities *Minn Med* 59, 51–57

Takasaki, H (1970) Moiré topography *Appl Optics* 9, 1467–1472.

Takasaki, H (1973) Moire topography *Appl Optics* 12, 845–850

Winter, R B (1975) Scoliosis and other spinal deformities. *Acta orthop scand* 46, 400–424

Correspondence to Stig Willner Department of Orthopedic Surgery Malmo General Hospital, University of Lund, Malmo, Sweden

Acta Orthopaedica 50, 303–309, 1979

THE EFFECT OF PHYSICAL TRAINING ON EXERCISE ABILITY IN ADOLESCENT IDIOPATHIC SCOLIOSIS

J. M. SHNEERSON & R. MADGWICK

Department of Respiratory Physiology, Cardiothoracic Institute, Brompton Hospital, London, England

Twenty subjects with adolescent idiopathic scoliosis, aged 11–17 years, were studied before spinal fusion. Half the patients underwent a programme of daily physical exercises for 6–10 weeks. Before and after this period all the patients carried out a range of lung function tests and a progressive exercise test. There were no significant differences in any of the results between the control group and the training group. The cardiac and respiratory complications of spinal fusion are therefore unlikely to be lessened by preoperative physical training except in selected subjects.

Key words: exercise testing, physical training, scoliosis, spinal fusion

Accepted 9.1.79

Although physical exercises have been used in an attempt to correct spinal curvatures there have been no reports of their use to improve cardiac and respiratory performance preoperatively. This is surprising in view of the well-established diminution in lung volumes (Schaub et al. 1954) and the hyperventilation, and reduced maximal ventilation and maximal oxygen uptake during exercise in adult scoliotics (Shneerson 1978a). In this study half the patients carried out a programme of daily exercises to see whether their cardiorespiratory function could be improved preoperatively and the complications of surgery thereby minimized.

PATIENTS AND METHODS

Twenty successive subjects with adolescent idiopathic scoliosis in which the primary curve affected the thoracic spine were studied. None of the subjects had any cardiac or respiratory disease complicating the scoliosis. All the patients performed a range of lung function tests and an exercise test and were then randomly allocated to the control or the training groups. The latter were instructed to carry out a daily regime of physical exercises including repeated step-ups, hopping, jumping and reaching up above their head. The exercises were performed initially in the presence of the authors and in each patient the heart rate rose above 160/minute. The exercises were supervised by their parents and records kept of their performance. After 6–10 weeks both the control [illegible]

method of Cobb (1948). The vital capacity (VC) was measured with a dry spirometer (Vitalograph) and the maximum voluntary ventilation [illegible] Morgan [illegible]

resista[illegible] Morgan 71522) with a dead space of 60 ml. The expired gas passed to a mixing chamber containing a fan. A sample of the mixed expired gas was dried with magnesium perchlorate and passed [illegible]

The patients rested on the ergometer until their [illegible]

© 1979 Munksgaard, Copenhagen

0001-6470/79/030303-04$02.50/0

The moiré method, however, demands that the children stand in a correct position in relation to the grid This means that there should be slight contact between both the shoulders and buttocks and the screen An incorrect position, however, can easily be observed by the photographer if he studies and counts the number of contour lines on either side of the midline between the shoulders, which should be equal

The advantage of this method in comparison with clinical ones is the possibility to document the condition of the back. Furthermore the moiré method is easy to apply and can be managed by paramedical staff The investigation can be performed rapidly by two persons, one photographs and the other helps the children to stand in a correct position About 40 children can be investigated per hour

When studying the moire photos it is important to look for the maximal deviation of the fringe intervals between the two halves of the trunk laterally as well as above or below the contact surfaces of the shoulder Also the difference in size and level of these contact surfaces must be studied

CONCLUSION

Our observations show that the moire technique is suitable for the screening of structural scoliosis because of

1 Its sensitivity to even small deformities,
2 The simplicity of the technique,
3 The possibility of documenting the condition of the back for comparison with subsequent examinations

REFERENCES

Adair, I V, van Wijk, M C & Armstrong [illegible]

As[illegible] Idiopathic adolescent scoliosis. Rationale and techniques of early detection *J Kans med Soc* 76, 285–292

Cobb, J R (1948) Outline for the study of scoliosis Instruct Course Lectures Amer Academy of Orthopaedics p 261

Drerup, B (1977) *Eine Apparatur zu Dokumentation von Erkrankungen de Haltungs- und Bewegungsapparates durc Moiré Topografie* Sonderforschungsbereich [illegible] Westfalische Wilhelms-Universitat, Munster

Gaines, R W, McKinley, L M & Leatherman K. D (1977) Scoliosis must be diagnose early *Kentucky med J* 75, 231–234

Gotze, H -G (1973) Der Rotationsindex bei idiopathischen Thorakalskoliosen *Z Orthop* 111 737–743

Kane, W J & Moe, J H (1970) Scoliosis prevalence survey in Minnesota *Clin Orthop* [illegible] 216

Lonstein, J E, Winter, R B, Moe, J H, Bianco A J, Campebell R G & Norval, M A (1976) School screening for the early detection o spine deformities *Minn Med* 59, 51–57

Takasaki H (1970) Moiré topography *Appl Optics* 9, 1467–1472

Takasaki, H (1973) Moiré topography *Appl Optics* 12, 845–850

Winter, R B (1975) Scoliosis and other spinal deformities. *Acta orthop scand* 46, 400–424

Correspondence to Stig Willner, Department of Orthopedic Surgery, Malmö General Hospital University of Lund, Malmo, Sweden.

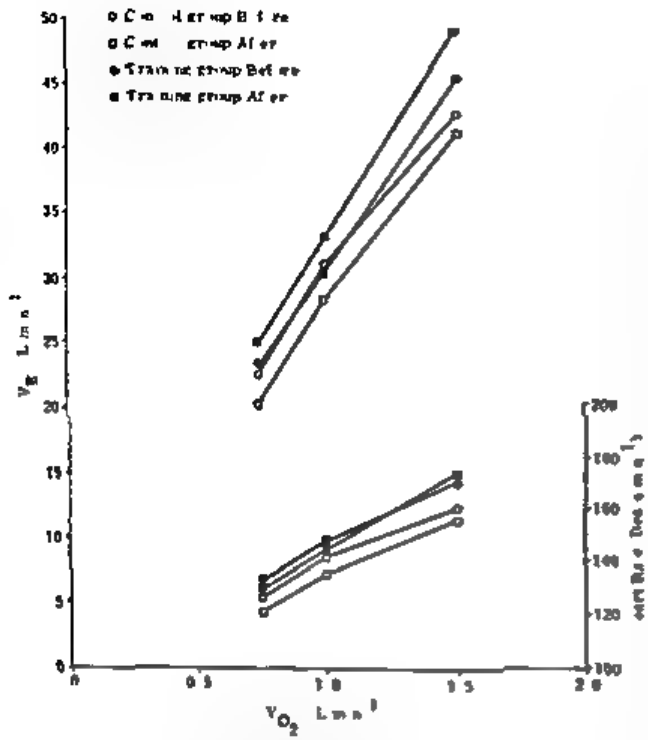

Figure 1 Minute ventilation and heart rate responses during exercise tests

DISCUSSION

This study was carried out to determine whether the exercise capacity of patients with adolescent idiopathic scoliosis could be improved by a course of physical training Scoliotics develop a variety of cardiac and respiratory abnormalities (Bergofsky et al 1959) and it is therefore important that they are as fit as possible, especially prior to surgery such as spinal fusion The exercises chosen were simple and practicable and utilized all the main muscle groups. More intensive and supervised exercises could have been designed if the subjects had been admitted to hospital for the period of training However, hospitalization for several weeks is undesirable and unacceptable to many patients and it was thought preferable to use a simple regime The effectiveness of a training programme depends on the severity of the physiological stress it presents. Exercise which induces a rise in heart rate above 150 beats/minute is sufficient to produce measurable improvement (Saltin et al 1969) The heart rate rose above 160 beats/minute in all the subjects of this study A significant increase in V_{O_2} max can be produced by an exercise course of 8 weeks (Saltin et al 1968), which was the approximate duration of this training course

The group of control patients who did not undergo physical training was comparable with the training group in age, sex, weight, and angle and level of scoliosis. The previous studies of the effects of exercise in scoliotics (Bjure et al 1969, Götze et al. 1974, Stoboy & Spetzerer, 1975) have not included a control group, but instead have studied the same patients on two or more occasions. The improvements they have observed could therefore be due to lessening of anxiety on the later occasions, familiarity with the apparatus (McHardy 1978), or to the physiological consequences of growth of the subjects For instance, the FEV_1 and VC are related to height and arm span (Godfrey et al 1970), the heart rate response during exercise is inversely proportional to lean body mass (Cotes et al 1973), and V_{O_2} max varies with body weight (Davies et al 1972)

An improvement in physical fitness due to the exercise course should result in a higher dyspnoeic index with an unchanged MVV, a slower heart rate at any given V_{O_2}, and a greater V_{O_2} max. Both the trained and untrained subjects improved slightly at their second attendance in several ways, but the trained group did not show any significant benefit compared with the control group There was no difference in response between the milder and more severe subjects within the trained group Even a slight improvement in the most severely affected subjects might be of symptomatic benefit, but Shneerson (1978b) has shown that severe pulmonary hypertension can develop during and after exercise in scoliotics with a vital capacity less than 1 0–1 5 litres. Physical training should, therefore, not be advised for these subjects. The best results from a course of training would probably be achieved by selecting those who are habitually the least

active A high proportion of active subjects in the present study may have obscured the benefit that more sedentary adolescents would achieve from a course of training similar to the present one

ACKNOWLEDGEMENTS

We would like to thank Dr F J Prime for his help and advice, Mr M Edgar for allowing us to study patients under his care, and Mrs J MacGuigan for preparing the manuscript. J M S held the appointment of Clinical Lecturer in the Department of Respiratory Physiology, Cardiothoracic Institute, Brompton Hospital, London, and was supported by grants from the Research Committee of the Brompton Hospital and by Boehringer Ingelheim Ltd

REFERENCES

Bergofsky, E H, Turino, G M & Fishman, A P (1959) Cardio-respiratory failure in kyphoscoliosis. *Medicine* **38**, 263–317

Bjure, J, Grimby, G, Nachemson, A & Lindh, M (1969) The effect of physical training in girls with idiopathic scoliosis *Acta orthop scand* **40** 325–333

Cobb, J R (1948) Outline for the study of scoliosis. Instructional Course Lectures *Amer Acad Orthop Surg* **5**, 261–275

Cotes, J E (1969) Relationships of oxygen consumption, ventilation, and cardiac frequency to body weight during standardized submaximal exercise in normal subjects *Ergonomics* **12**, 415–427

Cotes, J E, Berry, G, Burkinshaw, L, Davies, C T M, Hall, A M., Jones, P R M & Knibbs, A V (1973) Cardiac frequency during submaximal exercise in young adults relation to lean body mass, total body potassium and amount of leg muscle *Quart. J exp Physiol* **58**, 239–250

Davies, C T M, Barnes, C. & Godfrey, S (1972) Body composition and maximal exercise performance in children *Hum Biol* **44**, 195–214

Godfrey, S, Kamburoff, P L & Nairn J R (1970) Spirometry, lung volumes and airway resistance in normal children aged 5–18 years. *Brit J Dis Chest* **64**, 15–24

Gotze, H G, Sünram, F, Scheele, K & Klisa B (1974) Der Einfluss eines vierwochigen Konditionstrainings auf die organische Leistungsfähigkeit jugendlicher Skoliose Patienten *Dtsch med Wschr* **99**, 1761–1769

McHardy, G J R (1978) Assessment of exercise therapy *J Roy Soc Med* **71**, 63–64

Saltin, B, Blomqvist, G, Mitchell, J H, Johnson R L, Wildenthal, K & Chapman C B (1968) Response to exercise after bed rest and after training *Circulation* **38** Suppl 5

Saltin, B, Hartley, L H, Kilbom, A & Åstrand I (1969) II Oxygen uptake, heart rate and blood lactate concentration at submaximal and maximal exercise *Scand J clin Lab Invest* **24**, 323–334

Schaub, F, Buhlmann, A & Kalin R (1954) Das "Kyphoskolioseherz" und seine Pathogenese *Cardiologia* **25**, 147–152

Shneerson, J M (1978a) The cardio respiratory response to exercise in thoracic scoliosis. *Thorax* **33**, 457–463

Shneerson, J M (1978b) Pulmonary artery pressure in thoracic scoliosis during and after exercise while breathing air and pure oxygen. *Thorax* **33**, 747–754

Spiro, S G, Juniper, E, Bowman P & Edwards, R H T (1974) An increasing work rate test for assessing the physiological strain of submaximal exercise *Clin Sci Mol Med* **46**, 191–206

Stoboy, H Spencer, R (1975) Lungenfunktionswerte und spiroergometrische Parameter wahrend der Rehabilitation von Patienten mit idiopathischer Skoliose (Fusionsoperation der WS nach Harrington und Training) *Arch orthop Unfall Chir* **81** 247–254

Correspondence to J M Shneerson, D M, Westminster Hospital, Horseferry Road, London, SW1 England

Acta orthop scand 50, 307–313 1979

THE PROGNOSIS IN CONGENITAL LOWER LIMB HYPERTROPHY

C J McCullough & J Kenwright

Nuffield Orthopaedic Centre, Headington Oxford England

Twenty-eig[illegible]
with lower [illegible]
reviewed. [illegible]
and its in[illegible]
features of the affected limbs are described In congenital total hypertrophy the maximal increase in leg length discrepancy occurs before the age of 10 [illegible] leg length discrepancy of more than 2 5 cm at [illegible]
outcome for the limb was determined by the nature of the vascular anomaly which should be accurately defined by angiography

Key words angiomatosis, hypertrophy, leg length inequality

Accepted 27 x.78

There are two main clinical problems in the assessment of children with lower limb hypertrophy The first is to predict at an early age the expected leg length discrepancy at skeletal maturity and the second is to give a prognosis for function and cosmetic appearance of the limb Although the general features of patients with congenital total hypertrophy (Ward & Lerner 1947, Schwartzman et al 1942, Bryan et al 1958) and those with hypertrophy associated with vascular abnormalities (Goldanich & Campanacci 1962, Lindenauer 1971) have been well reviewed, little attention has been paid to the prognostic factors that govern the outcome for the affected limb Since one of these factors may be the rate of increase of leg length discrepancy during growth we have studied patients with lower limb hypertrophy particularly from this point of view

PATIENTS

Two groups of patients with generalised lower limb hypertrophy and leg length discrepancy were studied

Congenital total hypertrophy

Twenty-eight patients were studied and classified according to Ward & Lerner (1947)

(a) *Segmental* – 17 patients
Involvement of the whole lower limb without involvement of other structures on that side of the body (Figure 1)

(b) *Crossed* – 1 patient
Overgrowth of one half of the body and segmental hypertrophy of the other side

(c) *Hemihypertrophy* – 10 patients
Overgrowth of the entire one half of the body (Figure 2)

In these groups there was hypertrophy of all tissues of the involved limb There is often difficulty in deciding whether one limb or side of the body is hypertrophied or the other atrophied

0001–6470/79 03030[illegible] 07$02.50/0

© 1979 Munksgaard, Copenhagen

active A high proportion of active subjects in the present study may have obscured the benefit that more sedentary adolescents would achieve from a course of training similar to the present one

ACKNOWLEDGEMENTS

We would like [redacted] thank Dr F J Prime for his help and advice, Mr M Edgar for allowing us to study patients under his care, and Mrs. J MacGuigan for preparing the manuscript. J M S held the appointment of Clinical Lecturer in the Department of Respiratory Physiology, Cardiothoracic Institute, Brompton Hospital, London, and was supported by grants from the Research Committee of the Brompton Hospital and by Boehringer Ingelheim Ltd.

REFERENCES

Bergofsky, E H, Turino, G M. & Fishman, A P (1959) Cardio-respiratory failure in kyphoscoliosis *Medicine* **38**, 263–317

Bjure, J, Grimby, G, Nachemson, A & Lindh, M (1969) The effect of physical training in girls with idiopathic scoliosis. *Acta orthop scand* 40, 325–333

Cobb, J R. (1948) Outline for the study of scoliosis. Instructional Course Lectures. *Amer Acad Orthop Surg* **5**, 261–275

Cotes, J E. (1969) Relationships of oxygen consumption, ventilation, and cardiac frequency to body weight during standardized submaximal exercise in normal subjects. *Ergonomics* **12**, 415–427

Cotes, J E, Berry, G, Burkinshaw, L, Davies, C T M, Hall, A M, Jones, P R M & Knibbs, A V (1973) Cardiac frequency during submaximal exercise in young adults relation to lean body mass, total body potassium and amount of leg muscle *Quart J exp Physiol.* **58**, 239–250

Davies, C T M, Barnes, C & Godfrey, S (1972) Body composition and maximal exercise performance in children *Hum Biol* **44**, 195–214

Godfrey, S, Kamburoff, P L [redacted] Nairn, J R. (1970) Spirometry, lung volumes and airway resistance in normal children aged 5–18 years. *Brit J Dis Chest* **64**, 15–24

Götze, H G, Sünram F, Scheele, K [redacted] Klisa B (1974) Der Einfluss eines vierwöchigen Konditionstrainings auf die organische Leistungsfähigkeit jugendlicher Skoliose-Patienten *Dtsch med Wschr* **99**, 1761–1769

McHardy, G J R (1978) Assessment of exercise therapy *J Roy Soc Med* **71**, 63–64

Saltin, B, Blomqvist, G, Mitchell J H, Johnson R L, Wildenthal, K & Chapman, C B (1968) Response to exercise after bed rest and after training *Circulation* **38** Suppl 5

Saltin, B, Hartley, L H, Kilbom, A & Åstrand I (1969) II Oxygen uptake heart rate, and blood lactate concentration at submaximal and maximal exercise *Scand J clin Lab Invest* **24**, 323–334

[redacted] (1954) Da[redacted]

[redacted] response to exercise in thoracic scoliosis *Thorax* **33**, 457–463

Shneerson, J M (1978b) Pulmonary artery pressure in thoracic scoliosis during and after exercise while breathing air and pure oxygen. *Thorax* **33**, 747–754

Spiro, S. G, Juniper E, Bowman [redacted] & Edwards, R H T (1974) An increasing work rate test for assessing the physiological strain of submaximal exercise *Clin Sci Mol Med* **46**, 191–206

Stoboy, H Speierer B (1975) Lungenfunktionswerte und spiroergometrische Parameter während der Rehabilitation von Patienten mit idiopathischer Skoliose (Fusionsoperation der WS nach Harrington und Training) *Arch orthop Unfall Chir* **81** 247–254

Correspondence to J M Shneerson, D.M, Westminster Hospital, Horseferry Road, London, SW1 England

RESULTS

Congenital total hypertrophy

General quality of the limb Hypertrophy produced no functional disability in our patients and all had muscles of normal power Nine patients had cutaneous haemangiomata and one exhibited gigantism of the toes

Leg length discrepancy The average discrepancy for those patients who did not undergo surgical correction was at 4 years, 1 6 cm (range 0 3 to 2 4 cm), at 10 years 2 3 cm (range 0 9 to 3 3 cm) and at the end of growth 2 6 cm (range 1 1 to 3 7 cm) For six non-operated patients with congenital total hypertrophy who have been assessed regularly from the age of 2 to 14 years, the maximal increase in leg length discrepancy occurred before the age of 10 years If the average increase in discrepancy per 2 years of growth is plotted against age, the resultant growth velocity curve (Figure 3) confirms the initial *rapid increase in discrepancy In this*, admittedly small, group of patients the mean leg length discrepancy at 4 years, 10 years and 14 years (Figure 3) is very similar to that of all patients with the diagnosis of congenital total hypertrophy Five of the twenty-eight patients underwent procedures to correct leg length discrepancy, and epiphysiodesis is contemplated for a further patient who has leg overgrowth of 4 9 cm at the age of 4 years All of these patients except one had a discrepancy of more than 2 5 cm (average 2.9 cm) at 4 years of age The most severe discrepancy was 7 6 cm in a boy aged 11 years who had a lower femoral and proximal tibial epiphysiodesis with an eventual descrepancy of 1 9 cm The femoral arteriogram in this patient was normal

Bone structure abnormalities The overall width of both femur and tibia was greater as measured on the X-ray at the points (a) distal femoral epiphysis (b) proximal tibial epiphysis and (c) at the mid-point of each bone No other structural abnormality of the bones was noted

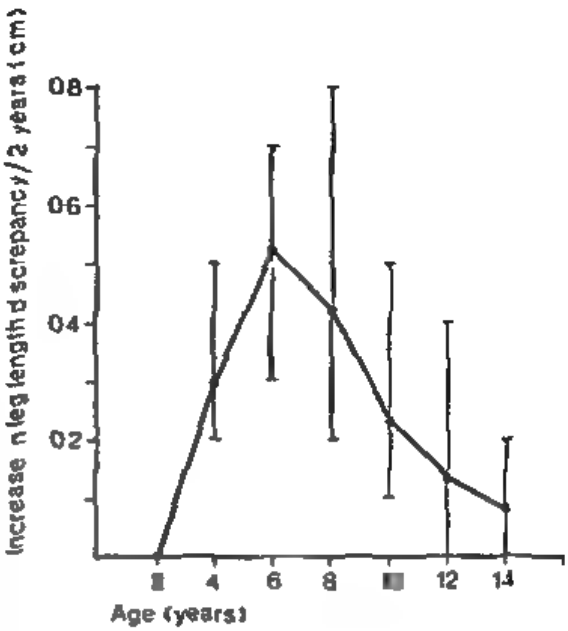

Mean growth velocity curve ■ patients with congenital total hypertrophy

Mean total leg length discrepancy

at age	4 years	1 73 cm	(range 1 2 2 2)
	10	2 72	(1 8 3 3)
	14	2 98	(1 9 3 7)

Figure 3 The mean growth velocity curve is shown for six patients with congenital total hypertrophy regularly assessed from 2 to 14 years of age The range of increase *in leg length discrepancy per 2 years is shown for this group of patients for each age point The mean total leg length discrepancy is also shown for this group of patients at 4 years, 10 years and 14 years of age*

Lower limb hypertrophy with congenital vascular abnormality

The clinical features of these patients are summarised in Tables 1 and 2

General quality of the limb Venographic assessment enabled the patients with Klippel-Trénaunay syndrome to be classified into two categories (Lea Thomas & Andress 1971) In the first category, five patients (A – E) exhibited superficial varicosities associated with normal or dilated valveless deep veins

Table 1 Clinical features of 6 patients with Klippel-Trénaunay syndrome

Patients	Age years	Leg length discrepancy cm Tib	Fem	Total	Arteriogram	Venogram
A	6 8 9	+1 6 +1 2 +1 2	+0 6 +0 7 +0 3	+2 2 +1 9 +1 5	No	Dilated valveless sciatic vein Superficial femoral vein normal
B	26	+2 6	+0 5	+2.9	No	Dilated valveless deep and superficial veins
C	17	Bilateral R	L	+0 5	Normal	Normal deep veins Dilated superficial veins
D	8	+2.4	+3 1	+5 4	Normal	Normal deep veins Dilated superficial veins
E	7 15	−0 1 −0 3	−0 1 −0 3	−0 2 −0 6	Sciatic artery	Dilated valveless deep veins Dilated superficial veins
F	2 4 8	0 0 −0 1	+0 8 +2.4 +1 9	+0 8 +2 4 +1 8	No	Diffuse cavernous angiomata

− = Affected limb shorter
+ = Affected limb longer

Table 2 Clinical features of 4 patients with diffuse congenital arteriovenous fistulae

Patient	Age years	Clinical	Arteriogram	Leg length discrepancy cm	Progress
1	16	Limb hypertrophy A-V bruit	Diffuse A-V fistula	1 9	Below-knee amputation for ulceration and pain
2	20	Limb hypertrophy A-V bruit Branham's test +ve Pulsating veins	No	2 2	Above-knee amputation for leg ulcer haemorrhage
3	24	Limb hypertrophy A-V bruit Pulsating veins	Diffuse A-V fistula	3 7	Recurrent ulceration of foot
4	19	Limb hypertrophy Varicose veins Increased foot pulses	Normal	4	No foot ischaemia or ulceration

whereas in the second category, patient F had a limb extensively involved with cavernous angiomata (Figure 4) In the former, the function of the limb was good although the superficial varicosities resulted in problems of venous stasis and were cosmetically undesirable (Figure 5) The cutaneous angiomata (port wine stain) produced significant cosmetic disability in two of our patients One patient had gigantism of the toes In contrast, patient F (Figure 6) had a poor quality limb massively hypertrophied, with knee flexion and ankle equinus contractures She subsequently developed disseminated intravascular coagulation secondary to clotting within her extensive venous malformation

Three patients with diffuse arteriovenous fistulae developed distal ischaemic ulceration for which two required amputation Patient 4 was spared this complication and a clinical diagnosis of multiple hypo-active fistulae was made in the presence of a normal arteriogram.

Figure 4 Venogram of patient (F) showing diffuse involvement of lower leg with cavernous angiomata

Figure 5 Bilateral Klippel Trénaunay syndrome (patient C) Normal deep veins on venogram Good quality limbs although with extensive cutaneous haemangiomata

Leg length discrepancy In patients with Klippel-Trenaunay syndrome there was a wide variation in leg length discrepancy even in patients with similar venous anomalies. The maximum discrepancy was 5 4 cm at the age of 8 years (patient D) Patients A and F exhibited a decreasing discrepancy with growth.

Bone structural abnormalities The bones were not thicker and in patient F the affected bones were thinner In this patient the increase in length was all due to femoral

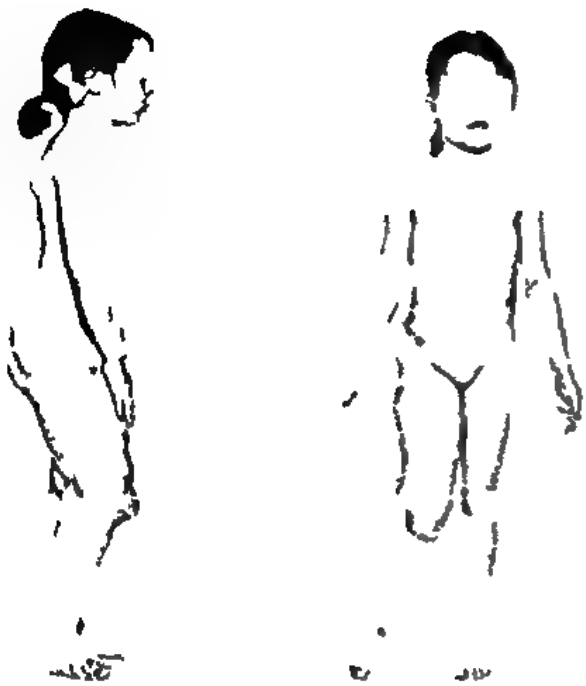

Figure 6 Massive hypertrophy of right leg associated with diffuse intra muscular cavernous angiomata

overgrowth and irregularity of both lower femoral and upper tibial epiphyses was noted radiographically

DISCUSSION

Dean MacEwen & Case (1967) in a review of 32 patients with congenital hemihypertrophy, 26 of whom had leg length discrepancy, stated that 65 per cent of their patients have had or will require epiphysiodesis Figure 3 shows that in six patients followed from 2 to 14 years the rate of increase in discrepancy slows markedly after 10 years of age This indicates that the eventual discrepancy at the end of growth was less than would have been predicted at the age of 10 years We would thus delay operative correction of leg length discrepancy until skeletal maturity and then consider surgery only for those patients with a discrepancy of more than 3 8 cm thus avoiding unnecessary epiphysiodesis We would favour subtrochanteric femoral shortening at the end of growth which allows accurate correction of discrepancy without the development of growth abnormality which not uncommonly follows epiphysiodesis (Hostrup & Pilgaard 1969) Epiphysiodesis should be reserved for those patients who have a major incapacitating discrepancy (i e more than 4 5 cm) some years prior to natural epiphyseal closure when femoral shortening would normally be undertaken The exact timing of epiphysiodesis and the number of epiphyses to be fused should be determined by reference to a growth prediction chart (Anderson et al 1963) Accurate correction should be possible as our findings suggest that for patients with congenital total hypertrophy there is little increase in discrepancy after the age of 10 years

In the patients with Klippel Trénaunay syndrome a variation in leg length discrepancy was noted even in those with similar venous anomalies The rate of increase in discrepancy was unpredictable and two patients exhibited a decreasing discrepancy as growth continued In two of the patients the limb overgrowth was due to an increase in the length of the femur or the tibia alone

In those patients with congenital vascular abnormalities it is the nature of the vascular lesion that governs the outcome for the affected limb Angiography allows an accurate differentiation to be made between those patients with normal or diffusely dilated deep veins those with extensive intramuscular cavernous angiomata and those with diffuse arteriovenous fistulae (Lindenauer 1971) We have described the different clinical features associated with these three types of vascular abnormality In patients with Klippel Trénaunay syndrome with normal or diffusely dilated deep veins the limb quality was good and we would not agree that limb overgrowth is a major problem in management (Letts 1977) Varicose veins may successfully be

excised in the presence of competent deep veins. In contrast, the patient with extensive intramuscular cavernous angiomata exhibited gross limb hypertrophy and developed a life-threatening complication In congenital diffuse arteriovenous fistulae, the outcome for the limb depends almost entirely on the size and activity of the fistulous communications and their amenability to surgical correction (Cotton & Sykes 1969)

ACKNOWLEDGEMENTS

We would like to thank Mr D J Tibbs, Professor R B Duthie and Mr J Scott Ferguson for permission to study their patients We would like to thank the Hospital for Sick Children, Great Ormond Street, for permission to use Figure 6 Thanks are also due to Dr R Smith for his helpful criticism, and Mr R Emanuel for the photography and Mrs. J Malphant for preparing the manuscript

REFERENCES

Anderson, M, Green, W T & Messner, M B (1963) Growth and prediction of growth in the lower extremities. *J Bone Jt Surg* **45**, 1–14

Bryan, R A, Lipscomb, P R & Chatterton, C C (1958) Orthopaedic aspects of congenital hypertrophy *Amer J Surg* **96**, 654–659

Cotton, L T & Sykes, B J (1969) The treatment of diffuse congenital arteriovenous fistulae of the leg *Proc roy Soc Med* **62**, 245 247

Dean MacEwen, G & Case, J L (1967) Congenital hemihypertrophy *Clin Orthop* **50**, 147–150

Goldanich, I F & Campanacci, M (1962) Vascular hamartomata and infantile angioectatic osteohyperplasia of the extremities *J Bone Jt Surg* **44-A**, 815–842

Hostrup, H & Pilgaard, S (1969) Epiphysiodesis and epiphyseal stapling of the lower limbs. *Acta orthop scand* **40**, 130–136

Klippel, M & Trénaunay, P (1900) Du noevus varicqueux ostéo-hypertrophique *Arch gén Méd* Paris **185** (Series 9) 641–672

Lea Thomas, M & Andress, M R (1971) Angiography in venous dysplasia of the limbs *Amer J Roentgenol* **113**, 722–731

Letts, R. M (1977) Orthopaedic treatment of hemangiomatous hypertrophy of the lower extremity *J Bone Jt Surg* **59-A**, 777–783

Lindenauer, S M (1971) Congenital arteriovenous fistula and the Klippel-Trenaunay syndrome *Ann Surg* **174**, 248–263

Penfield, W & Robertson, J S M (1943) Growth asymmetry due to lesions of the post-central cerebral cortex *Arch Neurol Psychiat* **50**, 405–430

Schwartzman, J, Grossman, L & Dragutsky, D (1942) True total hemihypertrophy *Arch Paediat* **59**, 637–645

Ward, J & Lerner, H H (1947) A review of the subject of congenital hemihypertrophy and a complete case report *J Paediat* **31**, 403–413

Correspondence to C J McCullough, M B, B Chir, F R C S, Senior Registrar, Nuffield Orthopaedic Centre, Headington, Oxford, OX3 7LD, England

Table 1 Nine children with neonatal hip instability Heredity and observations during pregnancy and delivery

No	Initials and year of birth	Sex	Hip disorder in family	Pregnancy			Delivery	
				Mother's age	Order of pregnancy	Comments	Position/Presentation	Comments
1	KJ -73	M	Twin (girl) unstable left hip	34	4	Oedema of pregnancy	Vertex	Duplex
2	VL -73	F	—	26	1	Normal	Breech	—
3	JN 74	F	—	26	3	Bleeding during 1st trimester Progesterone treatment	Vertex	Rupture of uterine cervix
4	LL -74	F	—	23	1	Normal	Breech/Caesarean section	
5	VR -74	F	Older sister with unstable hips	39	4	Normal	Breech	—
6	SR -75	F	—	20	1	Normal	Vertex	—
7	AO -76	M	—	23	1	Normal	Vertex	—
8	VV 72	F	—	33	1	Goitre Levaxin 0 1 g/di	Breech/Caesarean section	—
9	AH -74	F	—	29	2	Normal	Breech	Intrauterine asphyxia

(b) redislocation occurring during or after treatment due to inadequate immobilization or too short an immobilization time

The aim of this study was to shed light on these questions on the basis of clinical and arthrographic findings, and also with the aid of patho-anatomical observations made at open reduction Furthermore, a comparison is made between preoperative arthrograms and anatomical findings at operation The findings in idiopathic and arthrogrypotic hip dislocations are also compared

Definitions

Unstable hip joint A hip joint in which the femoral head is or can be moved out of the acetabulum partially or completely

Acetabular dysplasia Abnormal ossification of the iliac bone (roof of the acetabulum) observed on plain radiographs of the hip The chondral part of the acetabulum may show a normal or abnormal shape at arthrography

Neonatal period The first month of life.

can be made from this film

The child was born with a breech presentation. On clinical examination on the second day of life bilateral hip instability was observed

PATIENTS AND METHODS

The material consisted of seven children with bilateral idiopathic instability of the hip joint and two children with hip dislocation associated with arthrogryposis, one of them bilateral. The children were born in the period 1972–1976 within a region with a population of about 1 5 million. During this time about 90 000 children were born within the region

Data concerning the heredity pregnancies and deliveries are given in Table 1

Of the seven children with idiopathic instability, two were breech deliveries and one was delivered by Caesarean section because of breech position In two of these cases radiographs, taken 24 and 16 days, respectively before birth, were available On these it was seen that the foetuses lay with greatly flexed hips with the legs pointing upwards and the knees almost fully extended (Figure 1)

All patients were examined clinically and many of them also radiographically with respect to hip instability within the first week of life The findings at these examinations are presented in Table 2.

Since 1972 arthrography has been performed routinely in our hospital in all cases of hip instability persisting after the neonatal period.

The treatment of the children after diagnosis at their respective hospitals and before referral to this hospital is given in Table 3 In only one of the seven cases with idiopathic instability (No 4) was interposition suspected primarily, and this was confirmed by arthrography in an early stage (Figure 2 a and b). In two other cases (Nos. 6 and 7) interposition was suspected as the hip instability persisted after 1 to [illegible] months of abduction. In the other four cases hip instability still persisted after 1 5 to 3 months of treatment with an abduction pillow or splint, but an obstacle to reduction was not suspected and therefore closed reduction was again performed and the hip was immobilized in plaster

One of the two children (case 8) with arthrogryposis was treated with a von Rosen splint and hip spica for a total of 4 months,

Table 2 Nine children with neonatal hip instability Clinical and radiological findings during first of life

	ar	Sex	Findings at clinical examination General	Hips	Retrospective evaluation of the radiograms
		M	—	Bilat instability	No examination
		F	—	Bilat instability	No examination
		F	—	Bilat instability	Bilat. displacement
		F	Overstretched knees	Bilat restricted abd	Bilat. displacement
		F	—	Left instability	No examination
		F	—	Bilat instability	Bilat displacemen
		M	VOC (ASD) Aplasia 4th dig left hand	Bilat instability	No examination
		F	Arthrogryposis. Pes equinovarus. Fract of left femur	Bilat instability	Bilat displacement Fract of left femur
7	AH 74	F	Arthrogryposis	Bilat fixed flexion	Right D splacem Left Normal

followed by another reduction with immobilization in plaster for a long period. [illegible]

Results of the primary treatment The child with a primarily suspected reduction impediment (case 4) was referred for investigation and operation after an unsuccessful attempt at reduction.

In five cases (Nos 1 2, 3 6 and 7) abduction treatment resulted in stability in one hip but not in the other In one case (No. 9) treatment failed in both hips (Table 3).

Thus in seven children with idiopathic [illegible] the period in question

Figure 2 (a) Radiograph of a 3-day-old girl (No 4) delivered by Caesarian section because of breech position which had been confirmed at [illegible] X ray 16 days before delivery Marked [illegible] and lateral displacement of the femur [illegible] bilaterally indicating hip dislocation. On clinical examination at the same time b lateral restriction of hip abduction and extension contracture of knee joints were noted

(b) Bilateral hip joint arthrography on the girl at 1 month of age No treatment had been given before the arthrography apart from an unsuccessful attempt at closed reduction and bilateral adductor tenotomy The [illegible] shows bilateral dislocation [illegible] narrowing of the joint capsule A [illegible] clearly seen especially on the right side findings were apparent in all projections

Table 3 Nine children with neonatal hip instability Treatment, clinical and radiological findings up to the time of referral

No	Initials and year of birth	Sex	Treatment until first X-ray check-up		Retrospective evaluation of first X-ray check up	Continued treatment before referral		Findings at time of referral
1	KJ -73	M	Pillow	1 5 months	Displacement right	Reduction + plaster	2.5 months	Unstable right
2	VL -73	F	Pillow	3 months	Displacement bilat	Reduction + plaster (left open reduction)	27 months	Unstable right
3	JN -74	F	Pillow + splint	1 5 months	Displacement right	Reduction + plaster	7 5 months	Unstable right
4	LL -74	F	Failure of reduction after adductor tenotomy		Displacement bilat	Referred		Unstable bilat
5	VR -74	F	Pillow	3 months	Displacement bilat	Reduction + plaster	6 months	Unstable bilat
6	SR -75	F	Splint	1 month	Displacement right	Reduction + plaster	1 month	Unstable right
7	AO -76	M	Splint	1 5 months	Displacement right	Referred		Unstable right
8	VV -72	F	Plaster	1 month	Displacement left (not diagnosed primarily)	Splint Reduction + plaster	3 months 23 months	Unstable left
9	ÅH -74	F	No treatment	1 5 months	Displacement right	Referred		Unstable right

Figure 4 A girl (case 3)

acetabular dysplasia The left femur is correctly oriented

(b) Arthrography at the age of 10 months after 7 months of conservative treatment The same projection as in Figure 4a The right femoral head is still dislocated and deformed The capsule is narrowed, which will impede reduction The size and shape of the chondral part of the acetabulum cannot be judged satisfactorily

The left hip joint appears normal (Metal indicators as in Figure 3)

Figure 3 Arthrograms of a 2 month-old boy (case 7) Bilateral hip instability was noted at delivery After abduction treatment for 1 5 months, the

(c) the right hip abducted 45° and rotated outwards

In the right hip the femoral head is deformed and is constantly dislocated The capsule is narrowed between the femoral head and the acetabulum (hour glass shaped) which is apparent in all projections On the right side the head and neck of the femur are clearly anteverted.

On the left side the arthrogram is normal

(Plastic tube in the rectum for dosimetry Metal indicators for stereoradiographic assessment)

In the child with arthrogryposis treated with abduction (case 8) this led to stability of one hip but not of the other (Figure 5)

Reasons for failure of abduction treatment Of the six children with idiopathic instability in whom [illegible] was noted in [illegible] in Table 3) Two of these showed a reduction impediment in the hip in question at arthrography at the age of 2 months (cases 6 and 7) as shown in Figure 3, and the third at arthrography at 10 months (case 3) Retrospective evaluation of radiographs taken in the other three idiopathic cases showed that in two of these cases the femoral head was not in the correct position during the treatment. The femoral head was oriented towards

Table 4 Nine children with neonatal instability Age at arthrography and open reduction, operated side and treatment after open reduction

No	Initials and year of birth	Sex	Age in months at arthrography	Age in months at open reduction + operated side	Months in plaster after open reduction	Femoral rotational osteotomy	Pelvic osteotomy (Salter)	Results
1	KJ-73	M	4 5	5 right hip	7	yes	no	Stable
2	VL-73	F	31	37 right hip	7	no	yes	Stable
3	JN-74	F	10	11 right hip	4	yes	no	Stable
4	LL-74	F	1	1 bilat	6	yes bilat	no	Stable
5	VR-74	F	8	9 bilat	12	yes bilat	yes bilat	*Dislocated right* Subluxated left
6	SR-75	F	2	2 right hip	6	yes	yes	Stable
7	AO-76	M	2	[illegible] right hip	6	no	no	Stable
8	VV-72	F	26	27 left hip	3 5	yes	no	Dislocated
9	AH-74	F	—	2 right hip	2 5	no	no	Plaster treatment stopped because of pulmonary compl Dislocated

the upper part of the acetabulum and located more laterally than normal (Figure 4a), indicating interposition In the third case (No 2) the femoral head might have been reduced successfully but redislocation occurred when the legs were extended

Further investigation and treatment The nine patients were referred to the University Hospital in Uppsala, for clinical and arthrographic examination, eight of them because treatment had failed and one (case 9) without previous treatment

Arthrography

Bilateral arthrography was performed preoperatively in all cases except one Details of age at arthrography are given in Table 4 The examination was carried out under general anaesthesia and with a standardized technique (Lonnerholm, to be published) Films were taken in the frontal projection with the legs in a neutral position, in abduction in flexion + abduction and during attempts at provocation and reduction This examination in different positions showed whether any capsular narrowing was constant or not The size and shape of the femoral head, the acetabulum and the ligamentum capitis femoris were evaluated Pairs of stereo films were always included in order to see whether the femoral head was displaced anteriorly or posteriorly The arthrographic criteria for a reduction impediment were

(a) constant capsular narrowing with a diameter clearly smaller than that of the femoral head and
(b) a capsular fold or labrum which became interposed during an attempt at reduction

Results of arthrography

The case with primarily diagnosed irreducible dislocation was confirmed in arthrography (Figure 2b) In the other six idiopathic cases with bilateral hip instability, seven hips showed persistent dislocation and constant narrowing of the joint capsule which impeded reduction (Figures 3 and 4b) In addition the femoral head was deformed The other five hips were stable and the shape of their femoral heads normal

One of the children with arthrogryposis underwent arthrography This revealed unilateral dislocation, narrowing of the capsule and femoral head deformation of the same kind as in the idiopathic cases (Figure 5)

Figure 5 Arthrogram of a 26 month old girl w arthrogryposis (case 8) Delivered by Caesar section because of breech position Bilateral instability was noted at delivery and treated c servatively At the time of arthrography the hip was dislocated and the right hip stable

Left The small, deformed femoral head is located cranially The capsule between femoral head and acetabulum is narrow The acetabulum is only partly contra filled

Right The femoral head is deformed but l centrally in the joint The acetabul labrum is clearly visible (Metal indicato as in Figure 3)

Operative treatment

Open reduction was considered indicated wh arthrography showed that closed reduction w impossible according to the above criteria

Open reduction was performed on 11 hips wit irreducible dislocation (9 patients) An incisio was made from the middle of the iliac crest to th anterio-superior iliac spine and then in a curv down towards the anterior aspect of the thigh The attachments of the gluteus medius and th tensor fascia lata were freed and retracted. Th rectus femoris tendon was divided at it acetabular origin and then at the site of departur of the portion of the anterior inferior iliac spine The psoas tendon was divided in a Z-shape fashion, the capsule was then opened laterall over the femoral head and was divided in th medial direction down to the distal rim of th acetabulum (Figure 6) The loose soft tissu contained in the acetabulum was removed. Th ligamentum capitis femoris was excised in case where this comprised an obstacle to reduction Reduction was performed On account of th marked anteversion of the femoral head, reduction could only be achieved by strong inward rotation of the femur The joint capsule was sutured The psoas and rectus femoris tendons were sutured with elongation and thus without stretching After insertion of a tube for vacuum drainage and closure of the wound, a hip spica was applied with

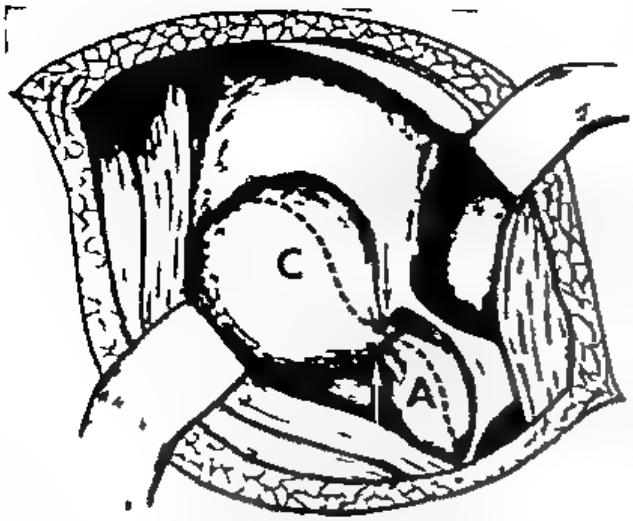

Figure 6 Schematic drawing of the capsule with its isthmus The dotted line indicates the line of incision.

The black arrow shows the capsular indentation caused by the acetabular part of the rectus femoris The white arrow shows the indentation caused by the tendon of the iliopsoas muscle

A = Acetabulum

C = Femoral head

the legs in 25° flexion and 30° abduction, and with inward rotation of the treated hip

Rotation osteotomy In eight hips an intertrochanteric rotation osteotomy of the femur was performed about 6 weeks after the open reduction Fixation was achieved either by Schantz's screws and external fixation or by internal fixation with a small angled plate

Salter pelvic osteotomy This was done in one case in connection with the open reduction (case 2) In two cases (3 hips, Nos. 5 and 6) the pelvic osteotomy was performed 16–18 months after open reduction because of persistent dysplasia and subluxation

The total duration of immobilization in plaster after the open reduction is given in Table 4 The mean duration was 6 months

Results of operative treatment

The present observation time of 6 months – 3 years after completion of treatment is too short to allow any definite conclusions to be drawn

In the seven patients with idiopathic hip dislocation open reduction was performed in nine hips with in some cases, further surgical treatment Of these, seven are clinically stable (Table 4)

In the two patients with arthrogryposis open reduction was performed on the two dislocated hips In both cases re-dislocation occurred later

Operation findings in relation to arthrographic findings

All arthrographies in cases with clinical instability revealed narrowing of the joint capsule between the femoral head and acetabulum The diameter of the isthmus was clearly smaller than that of the femoral head (Figure 3a–c), according to the criteria given above This was confirmed at operation, and reduction was not possible until the capsule had been divided along its entire length (Figure 6) The narrowing was mainly due to compression of the capsule from the outside by the psoas tendon and by the acetabular part of the rectus femoris tendon (Figure 6) The components of the interposed tissue, i e the capsular fold and the labrum, could not be differentiated at arthrography (Figures 2b, 3, 4b, 5) This was also impossible at operation (Figure 7)

The ligamentum capitis femoris was always found at operation to be lengthened but sometimes it was very thin, and sometimes rather thick A long, thick ligament may become interposed on reduction of the joint and therefore has to be excised At arthrography it was often difficult to decide whether the ligament was thin or thick As the capsular narrowing in itself constituted an impediment to reduction, it was also impossible to determine arthrographically how much of the ligament might be interposed in reduction This evaluation could only be made at operation

The femoral head was invariably deformed and was often egg-shaped with a larger diameter proximo-distally than ventro-dorsally The arthrographic and surgical findings corresponded entirely

The size and shape of the acetabulum could not be determined satisfactorily at arthrography This was due to the fact that the aceta-



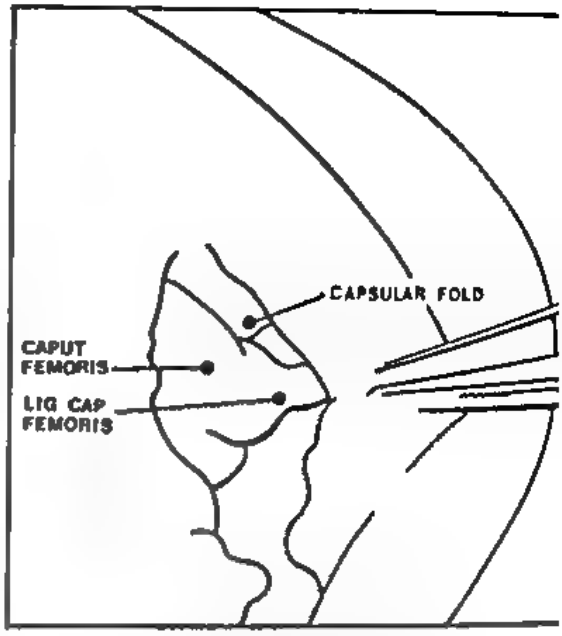

Figure 7 Photo and schematic drawing from case 3 The capsule has been opened and is held by clamp Note the capsular fold including the labrum which is interposed between the femoral head and t acetabulum

bulum was filled to a varying degree with loose, fatty tissue Not until this had been carefully dissected away at operation could the acetabulum be examined more closely

The observations at arthrography and at operation concerning the femoral head, the joint capsule and the acetabulum were the same in the arthrogryposis cases as in those with idiopathic instability

DISCUSSION

Failure of abduction treatment despite an early diagnosis and prompt initiation of therapy can be due to

(a) interposition preventing complete reduction of the femoral head, or
(b) redislocation of the femoral head because the immobilization time has been too short or the fixation inadequate during the treatment period

In one case of idiopathic hip instability interposition was diagnosed primarily and both arthrography and the findings at operation showed that closed reduction was not possible (Figure 2b) Thus all cases of neonatal hip instability cannot be treated b closed reduction

In the other six cases of bilateral idiopath hip instability the abduction treatment w successful in five of the twelve hips Concern ing three of the seven dislocated hips it w stated primarily that they were difficult t reduce and dislocated easily At arthrograph and open reduction it was found that close reduction would not have been possible It probable that a reduction impediment w present primarily in these cases also

As regards the remaining four hips, seven attempts at reduction had been made, the im mobilization time had been between 4 and 3 months, and at retrospective evaluation of th radiographs it was found that the femora head had never been completely reduced except perhaps in one case (No 2), where o one film it seemed that the reduction positio had been attained A primary obstacle t reduction in the form of interposition ma also be suspected in these four cases, with the possible exception of the latter patient

Our investigations have shown that an im pediment to reduction must be strongl suspected in neonatal hip instability if

(1) abduction is already restricted at birth,
(2) reduction of an unstable hip joint in a newborn infant is difficult and the reduced position is hard to maintain,
(3) stability of the hip has not been achieved after 6 to 8 weeks of abduction treatment.

In all these cases, arthrography should be performed as soon as an obstacle to reduction is suspected, i e within 2 months at the latest A delayed diagnosis means increased difficulty in attaining a good therapeutic result and unnecessary radiographic examinations during the early part of the treatment period. The agreement between arthrographic and operative findings was excellent This was due largely to the fact that films were taken with the legs in various positions and during attempts at provocation and reduction

Severin (1956) gives the incidence of hip joint dislocations in Sweden before the time of early diagnosis as 0 9 per thousand This implies an expected figure of 12 cases of manifest dislocation out of 13,000 births, if the diagnosis is not made at an early stage and treatment initiated immediately According to our results abduction treatment will fail and open reduction will be necessary in one case out of about 13,000 births, which may seem a high figure According to Fredensborg (1975) no such cases were encountered among about 60,000 children born in the county of Malmöhus in Sweden. Jones (1977), however, mentions two cases out of 29,000 births who were operated on because of persistent dislocation after conservative treatment Smaill (1968) reports one case out of 6000 births with a history and operation findings similar to those in our patients.

In all dislocated hips both arthrography and operation showed narrowing of the joint capsule, giving it an hour-glass shape, which has been described earlier by Leveuf (1948), among others The narrowing was caused by compression of the capsule by the psoas tendon and the acetabular portion of the rectus femoris tendon, which together exerted a pincer effect around the capsule Similar observations have been made by other authors, including Scaglietti & Calandriello (1962), Lloyd-Roberts & Swann (1966), Hirsch (1970), Ferguson (1973) and Eyre-Brook et al (1978) Even when the tendons had been divided at operation, however, some narrowing of the capsule still remained In most untreated hip dislocations discovered at a late stage some capsular narrowing is in fact observed, but this is generally less pronounced than in the cases reported here and seldom impedes closed reduction up to the age of about 2 years (Almby & Lonnerholm 1978) The extreme capsular narrowing in our cases seemed to be due to shortening of the two hip flexors, the rectus femoris and iliopsoas. A probable reason for this is that the foetus has lain with the hips hyperflexed for a long time before delivery In two of our cases with breech presentation we know that this was the case (Figure 1) Dunn (1969) described post-mortem observations in perinatal deaths that corresponded well with our findings at operation (CDH grade III according to Dunn), demonstrating that severe changes in the hip joint can be present even at delivery

After incision of the capsule, the interposed capsular fold (labrum) was no longer an impediment to reduction The excision of an entrapped labrum recommended by Somerville (1953) was therefore not considered necessary in our cases

In all of our patients there was distinct deformation of the femoral head, consisting of both flattening medio-laterally (egg-shaped) and marked anteversion The head appeared to be rotated anteriorly on the neck. Moreover, the head was small. Similar observations have been reported, among others, by Laurent (1953) and Dunn (1969), who stated that these changes occurred with so-called posterior dislocation Our stereo films showed that such posterior dislocation was present in all cases of our series. When the femoral head had left the acetabulum, it was moved postero-superiorly by the shortening of the

iliopsoas tendon and forced against the wing of the ilium

In the arthrogryposis cases the same type of capsular narrowing was found as in the cases of idiopathic instability

Conclusions

1 In occasional cases of neonatal hip instability interposed capsular tissue may impede reduction
2 It is important that this is diagnosed early – preferably within 2 months – so that open reduction can be performed without delay
3 An impediment to reduction can be suspected if
   (a) abduction is already restricted at birth
   (b) if the primary reduction is difficult and the reduced position is not easily maintained
   (c) if the instability persists after 6 to 8 weeks of treatment
4 If an impediment to reduction is suspected arthrography should be performed
5 The findings at arthrography and at operation corresponded well
6 The findings at open reduction were
   (a) a greatly narrowed joint capsule compressed by the rectus femoris and iliopsoas tendons
   (b) a capsular fold including the acetabular labrum was interposed but was not an impediment to reduction when the capsule was incised
   (c) the femoral head was markedly anteverted with varying degrees of deformation
   (d) the ligamentum capitis femoris was lengthened and was sometimes thin and sometimes broad and thick.
7 The changes mentioned were essentially the same in the patients with arthrogryposis as in those with idiopathic instability of the hip
8 On the basis of our investigation a primary impediment to reduction is probably present in one case out of at 13,000 births (= 0 08 per thousand)

REFERENCES

Almb [illegible]

642–649

Almby B & Lonnerholm T (1978) Hip joint stability after the neonatal period Diagn and treatment of 20 consecutive cases *A orthop scand* 49 371–381

Bjerkreim I (1974) Congenital dislocation of hip joint in Norway *Acta orthop sca* Suppl 157

Dunn P M (1969) Congenital dislocation of hip (CDH) Necropsy studies at birth. *Pr roy Soc Med* 62 1035–1037

Emnéus H (1966) Some new aspects of treatment of congenital dislocation of the (CDH) according to *Palmén* von *Rosen A orthop scand* 37 311–316

Eyre-Brook A L Jones D A & Harris F (1978) Pemberton s acetabuloplasty for c [illegible]

median adductor approach *J Bone Jt Su* 55 A 671–689

Fredensborg N (1975) Congenital dislocation the hip Dissertation University of Lund

Hierton T & James, U (1968) Congenital d location of the hip Experiences of ea diagnosis and treatment *J Bone Jt Su* 50-B, 542–545

Hirsch C & Scheller S (1970) Results treatment from birth of unstable h ps. A 5-ye follow up *Acta orthop scand* Suppl. 1 25–29

Hirsch, C (1970) Prevention of congenital disloc tion of the hip joint in Sweden. *Acta ortho scand*, Suppl 130 64

Jones D (1977) An assessment of the value of e amination of the hip in the new born. *J Bo Jt Surg* 59 B, 318–322.

Laurent L. E. (1953) Congenital dislocation of t hip *Acta chir scand*, Suppl 179

Leveuf J (1948) Results of open reduction "true" congenital luxation of the hip. *J Bo Jt Surg* 30-A 875–882

Lloyd Roberts G C. & Swann M (1966) Pitfal in the management of congenital d slocation the hip *J Bone Jt Surg* 48-B 666–681

Nielsen, H O (1975) Kongenit hofteluxation. Et 15-års materiale *Ugeskr Laeg* 137, 2256–2259

Palmen, K (1961) Preluxation of the hip joint *Acta paediat* 50, Suppl. 129

von Rosen S (1970) Instability of the hip in the new born 15 years' experience in Malmo *Acta orthop scand*, Suppl. 130, 13–23

Scaglietti, O & Calandriello, B (1962) Open reduction of congenital dislocation of the hip *J Bone Jt Surg* 44-B, 257–283

Severin, E (1956) Frekvensen av luxatio coxae congenita och pes equino-varus congenitus i [illegible]

524–536

Somerville, E W (1953) Open reduction in congenital dislocation of the hip *J Bone Jt Surg* 35, 363–377

Correspondence to Bo Almby, Department of Orthopaedic Surgery University Hospital S–750 14 Uppsala Sweden

Acta orthop scand 50, 329–336 1979

LONG TERM RESULTS OF SURGERY FOR NON-ACUTE ANTEROMEDIAL ROTATORY INSTABILITY OF THE KNEE

NILS ORETORP, JAN GILLQUIST & STEN OTTO LILJEDAHL

Department of General Surgery, University Hospital, Linköping Sweden

Seventy-eight patients treated by extraarticular reconstruction including pes anserinus transfer for anteromedial rotatory instability of the knee were reinvestigated 16 – 47 months (mean 28) after operation. Function before and after operation was assessed by means of a knee rating score Of these patients, 94 per cent showed a higher score after operation Twenty per cent showed full recovery with no limitation of knee function whatsoever The follow-up score was higher with preserved medial meniscus function than when this structure had been removed. When not initially torn, the medial meniscus tended to become involved with time Mild laxity in extension possibly indicative of a posterior cruciate injury previously underestimated or not observed, was found in 15 per cent of the patients. No correlation was found between late knee function and the interval between injury and operation or the interval between operation and follow-up examination

The long term results were good. Extraarticular reconstruction is thus indicated in cases of chronic rotatory instability of the anteromedial type Routine meniscectomy is not recommended in these patients, however Signs possibly indicating posterior cruciate ligament involvement should be carefully looked for, as even minor posterior cruciate injury, easily overlooked, may influence the late results.

Key words knee ligaments, articular, semilunar cartilage, surgical repair

Accepted 1 xi 78

The primary results of various surgical procedures for knee joint instability have been reported as satisfactory (Jones 1970, O'Donoghue 1973, Nicholas 1973) At this clinic, good results have been obtained with intraarticular repair using the medial third of the patellar ligament (Liljedahl & Gillquist 1972), but others have found intraarticular reconstruction unrewarding (Kennedy et al 1974) We too find it associated with certain limitations. It is technically difficult, and is not the method of choice for knees with joint degeneration Since 1971 we have therefore used an extraarticular technique of reconstruction in cases of anteromedial rotatory instability

The aims of this study were

(1) to evaluate the functional capacity of patients after extraarticular repair for chronic instability
(2) to find factors influencing late function
(3) to study whether function tends to become impaired with time.

PATIENTS

Ninety two patients were operated on for chronic anteromedial rotatory instability during the period

0001–6470/79 030329–08$02.50 ⊟

© 1979 Munksgaard, Copenhagen

FOLLOW-UP INVESTIGATION

The follow up investigation included the following

(1) The information from previous hospital records was checked directly with the patient
(2) A special questionnaire including a rating system for several variables of knee function (modified from Larson, in Smilie 1974) was filled in by one and the same examiner with the patient's collaboration.
(3) Thorough clinical examination by the same examiner was carried out Instability was recorded according to the gradation by Hughston et al (1976) which is based upon the American Medical Association grading (1968) Any difference between the injured and the non injured knee involving less than a 5 mm separation of the joint surfaces during the stress test was regarded as mild (1) instability, 5–10 mm as moderate (2), and more than 10 mm as severe instability (3) Measurement of rotatory instability is uncertain, and when present this was therefore only subjectively classified as slight or moderate

To study whether the knee function (score) at follow-up was related to the finding of medial instability and/or anteroposterior instability the knees were classified as follows category A, not fully stable medially in extension, B, moderate or severe anterior drawer sign, C, moderate valgus [illegible] overlap between these categories.

The results were treated statistically by the usual methods (Snedecor & Cochran 1967) Values are given in the text as means ± s.e mean

RESULTS

Primary

There were no serious complications of any kind Mean period in hospital after operation was 5 days (range 1–18) In one patient recovery of mobility was slow, and manipulation under anaesthesia was required

Findings at follow-up examination

Some of the functions recorded are given in Table 1 A maximum score of 100 was reached by 16 patients (20 per cent) Seventy-three (94 per cent) showed an elevated score postoperatively Three patients showed no score change, and two patients showed a lower score at follow-up than preoperatively The mean score values for the whole series were 66 2 ± 1 87 preop, and 93 4 ± 1 15 postop, mean difference 26 3 ± 1 78 ($P < 0.001$) Forty-nine (73 per cent) out of the 67 patients injured while participating in athletics returned to their particular sport, and 18 (27 per cent) gave up or changed to another

Table 1 Functional variables pre- and postoperatively Grade 1 means no pain and full performance, grade 4 incapacitating pain and inability to climb stairs Grade 3 for jumping means inability

Functional Variable	Grade 1	2	3	4
Pain				
preop ($n=74$)	5	14	50	5
postop ($n=78$)	48	23	7	—
Up-down stairs				
preop. ($n=74$)	31	[illegible]	13	1
postop ($n=78$)	70	7	1	—
Jumping				
preop ($n=74$)	7	33	34	
postop ($n=78$)	57	18	3	

Table 2 Knee joint stability at follow-up (graded according to Hughston et al 1976)

Type	Grade Fully stable	1	2	3
Medial				
0°	66	12	—	—
30°	51	25	2	—
Sagittal (ADS)	25	44	8	1

Knee joint stability Anteroposterior and medial stability are shown in Table 2 Fifty-four patients showed no rotatory instability whereas 22 patients showed slight and two moderate instability

The relations between anteroposterior,

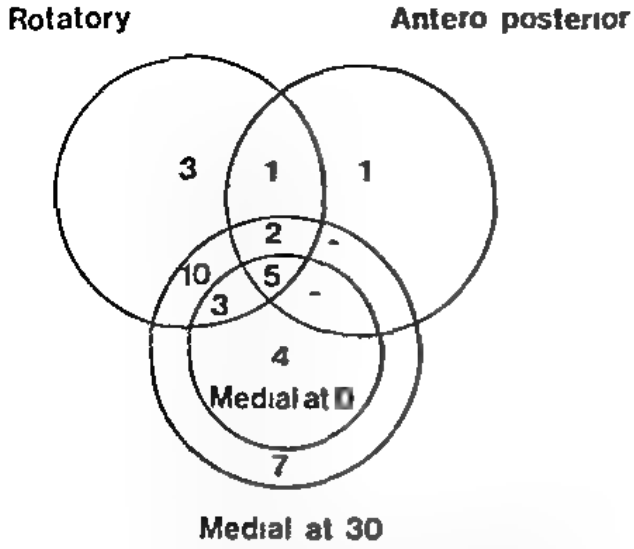

Figure 2 The relations between medial rotatory, and moderate or severe anteroposterior instability at follow-up examination (36 out of 78 patients)

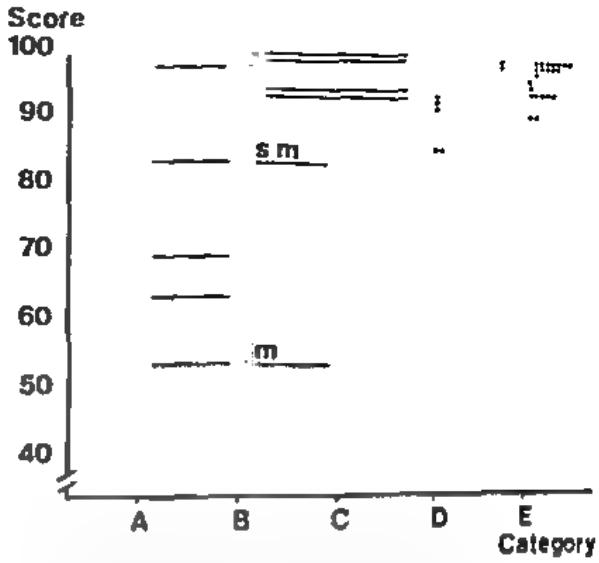

Figure 3 Scores for different classes of stability at follow up examination (78 patients)
——indicates same patients s one patient with severe ADS, m patients showing moderate rotatory instability at follow-up examination

medial, and rotatory instabilities found are shown in Figure 2 In 25/36 patients combined ligament laxity was found In 21/24 knees with rotatory instability some possibly significant medial and sagittal instability was also present Eleven out of 12 knees with mild medial instability in extension showed mild or moderate laxity at 30° flexion, and in the twelfth no other laxity was found. This patient had previously been subjected to total medial meniscectomy Moderate ADS alone was found in only one out of nine patients, and in most knees with residual moderate or severe ADS, medial and rotatory instability was also present

Knee stability – score Relations between rating score and different categories (A – E) of stability are shown in Figure 3 Sixty-nine patients with no or mild ADS (not separately classified in the figure) showed a higher score of 94 4 ± 1 03 than nine with moderate or severe ADS (category B), 85 1 ± 5 7 ($P<0$ 01) The score for category A ($n=12$) (mild instability in extension) was lower than for category E ($n=47$) (medially stable knees with or without slight ADS), means 84 1 ± 4 3 and 96 8 ± 0 6 ($P<0$ 001) The mean value for category D ($n=19$) was 90 8 ± 2.3

Previous operations – score As seen in Figure 4 patients previously operated on in the same knee showed a lower score than those operated on for the first time (means 90 2 ± 1 9 and 97 3 ± 0 7, $P<0$ 001) Patients previously treated by medial meniscectomy showed a lower preoperative score than patients in whom the medial meniscus (injured or uninjured) was still *in situ* (means 60 8 ± 3 2 and 70 4 ± 2 3 respectively $P<0$ 02) This latter group of 35 patients included 24 with torn but still unremoved medial menisci At follow-up the highest score was found in the patients with an intact medial meniscus (mean 97 3 ± 1 02) (Figure 4). However, the number of knees with intact medial menisci progressively reduced with time after trauma (Figure 5) No correlation was found between the interval between injury and operation and the score at follow-up

Joint degeneration – score Patients with cartilage degeneration in two or three compartments at the time of operation showed a lower follow-up score than those with no degenerative change (means 88 1 ± 2.8 and 95 7 ± 1 4, $P<0$ 001). Degenerative changes in only one of the knee compartments did not

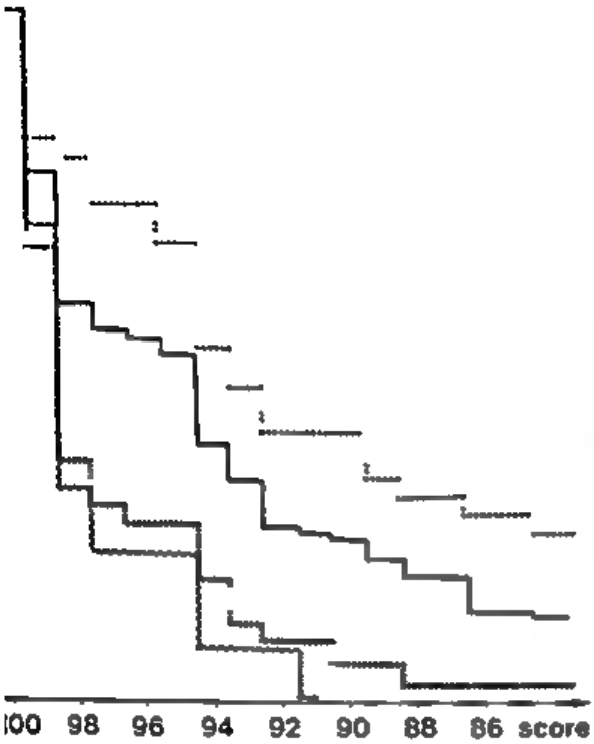

gure 4 Proportion of patients in per cent in lation to score values for the various groups (78 tients)

- *entire series of patients*
- *patients previously treated by medial meniscectomy*
- *no previous operation on the knee*
- *patients with intact medial meniscus at follow-up examination.*

ffect the functional result as reflected in the core (mean 96 3 ± 0 9)

nterval operation – follow-up Knee function howed no tendency to deteriorate with time 6–47 months after operation

Reoperation. Eight of the 78 patients subsequently underwent secondary operation for various reasons. No further ligament operations were done Four operations (local anaesthesia) were carried out for suture reactions One medial and one lateral meniscectomy were subsequently done, one after major and one after minor retrauma to the knee One patient showed a pes tendon luxation at the joint line, and another

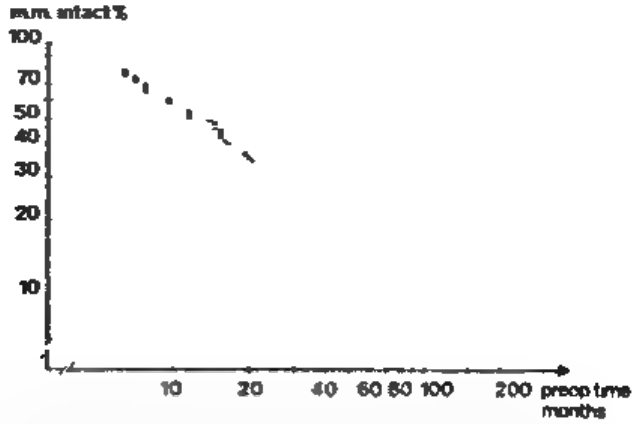

Figure 5 Proportion of patients (78 patients – 100 per cent) with intact medial meniscus in the injured knee in relation to the interval between trauma and operation (log scale)

required operation for a neuroma of the infrapatellar branch of the saphenous nerve.

DISCUSSION

For assessment of results after knee ligament surgery there is still a serious lack of objective methods that are accepted by different surgeons The assessment of results must therefore still be based on thorough clinical examination and the pre- and postoperative function of the joint A thorough rating of function is now increasingly used for evaluation of results (O'Donoghue, 1963, 1973, Slocum & Larson 1968, Alm & Gillquist 1974, Kettelkamp & Thompson 1975, Marshall et al 1975 1977, also, Hughston, J C, personal communication, 1977) However, O'Donoghue (1973) contends that laxity and instability are closely related but not identical At the time we started this study the scale set up by Robert Larson (in Smillie 1974) seemed to be the most appropriate, and we therefore used his rating sheet as the basis for the evaluation of our results.

Most injuries in this series (86 per cent) occurred during competitive sports, which is the same incidence as Alm & Gillquist (1974) found in a series of patients treated by intraarticular transfer of part of the patellar

tendon Other workers have also reported the same high incidence (Slocum & Larson 1968, Liljedahl & Nordstrand 1969, Jones 1970, Jacobsen 1977), and subsequent large series consist of athletic injuries only (Hughston & Eilers 1973, Nicholas 1973)

Fifty-five per cent of our patients had previously undergone one or more operations, medial meniscectomy being the commonest, as others have also reported (Slocum & Larson 1968, Nicholas 1973) In only a few cases had the earlier procedures led to temporarily improved knee function New relatively minor trauma had in these cases aroused new symptoms and complaints of instability and recurrent effusion Medial meniscectomy alone failed to improve function in most patients, and many experienced reduced activity tolerance In our patients with anteromedial rotatory instability the medial meniscus was not always torn at the time of injury, but tended to become involved with time A possible explanation is that the primary injury to the medial and posteromedial capsule affects the attachments and secondarily also the behaviour of the medial meniscus This can be demonstrated under arthroscopy, when valgus and outward rotatory forces are applied to the tibia, and is described by O'Connor (1974) as a pathological wave formation of the meniscus Owing to abnormal mobility within the joint the laxity will therefore make the medial meniscus prone to tearing and degeneration in the long run Further instability will then be added by the removal of the meniscus, as Nicholas (1973) has observed clinically, and Wang & Walker (1974) and Oretorp et al (1978) experimentally If operative repair is done within 1 year, the chances that the medial meniscus will survive intact are therefore greater If ligament repair can be done without medial meniscectomy, the functional result might consequently be expected to be better, to judge from our results We feel that routine meniscectomy (Slocum et al 1973, O'Donoghue 1973, Nicholas 1973) should not be recommended in cases of medial ligament reconstructions, as patients with an intact medial meniscus showed the highest score at follow-up in our present series The better results for this group than for patients also treated by meniscectomy might appear to indicate selection of more serious injuries in the latter group This does not seem plausible, however, taking into account also the preoperative score for the same groups of patients In fact the patients with torn but not yet excised medial menisci showed better function than those already subjected to meniscectomy for combined medial meniscus and ligament tears This fact seems to us to rule out selection as an explanation for the difference

Seventy-three per cent of the patients injured while participating in athletics returned to the same sport, and more than 90 per cent of all patients showed increased activity after operation These figures are comparable to those obtained after intraarticular reconstruction of the anterior cruciate ligament in a series similar to this one (Alm & Gillquist 1974) We do not yet know whether differences will exist several years after intra- or extraarticular repair, but we have found no tendency to impairment with time during the observation period. Jones (1970), however, has asserted that anatomical normality after anterior cruciate injuries is beyond expectation Twenty per cent with total functional restitution may therefore be considered a satisfactory result for these severe injuries.

Care should be taken about drawing conclusions on the degree of stabilization of the knee joint gained by the operative procedure. Comparing stability by clinical examination alone on different occasions several years apart is fraught with uncertainty We feel, however, that thorough extraarticular medial and posterior repair has reduced the degree of anterior drawer sign on these patients, and others have reported the same observation (O'Donoghue 1973, Hughston et al 19[illegible]) Even after an otherwise successful transfer of

part of the patellar tendon the anterior drawer sign is not fully eliminated (Alm & Gillquist 1974, Jacobsen & Rosenkilde 1977) Nevertheless, we have found no association between a mild anterior drawer sign and a lower score, although a significantly lower score was seen in the group with persistent moderate ADS at follow-up than among the other patients This tallies with other clinical reports (Kennedy et al 1974, Marshall et al 1975, Jacobsen 1977)

Medial instability found at follow-up was not pronounced Jacobsen (1977) has pointed out that marked medial instability is uncommon in old ligament injuries of the knee joint Nevertheless mild medial instability may be more important than mild or moderate sagittal instability, which is commoner in such cases. We believe that the finding of mild medial instability at 0° is more important than the finding of mild anterior drawer sign, and this in fact is shown by the score values Moderate or severe ADS was in all but one patient associated with mild medial instability at 0°, or more than mild at 30°, however This again illustrates the fact that ligamentous injuries of the knee are usually multiple In other words all clinical and functional factors must be taken into account, and the results not based on one single factor

Mild laxity in extension at follow-up examination of patients originally classified as cases of anteromedial rotatory instability is not merely a sign of the absence of the medial meniscus but also of some posterior cruciate injury previously not detected According to Hughston et al (1976) laxity in extension is the most reliable sign of a recent tear of the posterior cruciate ligament, but he also states that the posterior drawer sign (PDS) is always present in cases of chronic injury to this ligament Nevertheless, the possibility will always remain that a slight positive PDS might "drown" in a more marked ADS when anteroposterior instability exists. Both cruciates were visualized and examined either in arthrotomy or before the repair, at arthroscopy, however Some kind of posterior cruciate injury must have been underestimated or overlooked, and we feel that this kind of injury may be commoner than we suspected This is also in keeping with our findings at arthroscopy (Gillquist et al 1978) Noyes et al (1974) and Kennedy et al (1976) have found in experiments that after high tensile stress an apparently normal ligament may show some torn fibres, and that, on microscopic examination, these are seen to be surrounded by other disrupted fibres The findings in some of our patients of medial laxity in extension might be explained by such functionally injured but on inspection apparently normal posterior cruciates. Whether additional laxity may result from the absence of the medial meniscus is not known A significant change in medial laxity after meniscectomy has been demonstrated in dogs (Oretorp et al. 1978) It seems reasonable to assume that the same would be true in man, although experimental evidence is still lacking In any event, we feel that the finding of any slight valgus laxity in extension should be recorded pre- and postoperatively, as this sign seems to be significant with regard to prognosis.

ACKNOWLEDGEMENT

This investigation was supported by grants from "Forenade Liv" Mutual Group Life Insurance Company, Stockhom, Sweden

REFERENCES

Alm, A & Gillquist, J (1974) Reconstruction of the anterior cruciate ligament by using the medial third of the patellar ligament *Acta chir scand* 140, 289–296

American Medical Association, Committee on the Medical Aspects of Sports (1968) Standard Nomenclature of Athletic Injuries, 99 and 100 Chicago

Gillquist J & Hagberg G (1976) A new modification of the technique of arthroscopy of the knee joint *Acta chir scand* 142, 123–130

Gillquist, J, Hagberg, G & Oretorp, N (1978) Arthroscopic examination of the posteromedial compartment of the knee joint *Int Orthop* (In press)

Hughston, J C & Eilers, A F (1973) The role of the posterior oblique ligament in repairs of acute medial (collateral) ligament tears of the knee *J Bone Jt Surg* 55-A, 923–940

Hughston, J C, Andrews, J R, Cross, M J & Moschi, A (1976) Classification of knee ligament instabilities Part I and II *J Bone Jt Surg* 58-A, 159–179

Jacobsen, K (1977) Stress radiographical measurements of post-traumatic knee instability *Acta orthop scand* 48, 301–310

Jacobsen, K & Rosenkilde, P (1977) A clinical and stress radiographical follow-up investigation after Jones' operation for replacing the anterior cruciate ligament *Injury* 8, 221–226

Jones, K G (1970) Reconstruction of the anterior cruciate ligament using the central one-third of the patellar ligament *J Bone Jt Surg* 52-A, 1302–1308

Kennedy, J C, Weinberg, H W & Wilson, A S (1974) The anatomy and function of the anterior cruciate ligament *J Bone Jt Surg* 56-A, 223–235

Kennedy, J C, Hawkins, R J, Willis, R B & Danylchuk, K D (1976) Tension studies of human knee ligaments. *J Bone Jt Surg* 58-A, 350–355

Kettelkamp, D B & Thompson, C (1975) Development of a knee scoring scale *Clin Orthop* 107, 93–99

Larson, R (1974) Rating sheet for knee function *Diseases of the knee joint*, Ed Smillie, I S pp 29–30, Churchill Livingstone, Edinburgh

Liljedahl, S-O & Gillquist, J (1972) Innere Verletzungen des Kniegelenkes bei Sportlern *Münch med Wschr* 114, 1371–1376

Liljedahl, S-O & Nordstrand, A (1969) Injuries to the ligaments of the knee Diagnoses and results of operation. *Injury* 1, 17–24

Marshall, J L, Warren, R F & Fleiss, D J (1975) Ligamentous injuries of the knee in skiing *Clin Orthop* 108, 196–199

Marshall, J L, Fetto, J F & Botero, P M (1977) Knee ligament injuries A standardized evaluation method *Clin Orthop* 123, 115–129

Nicholas, J A (1973) The five-one reconstruction for anteromedial instability of the knee *J Bone Jt Surg* 55-A, 899–922

Noyes, F R, DeLucas, J L & Torvik P J (1974) Biomechanics of anterior cruciate ligament failure An analysis of strain rate sensitivity and mechanics of failure in primates. *J Bone Jt Surg* 56-A, 236–253

O'Connor, R (1974) Arthroscopy in the diagnosis and treatment of acute ligament injuries of the knee *J Bone Jt Surg* 56-A, 333–337

O'Donoghue, D H (1963) A method for replacement of the anterior cruciate ligament of the knee *J Bone Jt Surg* 45-A, 905–924

O'Donoghue, D H (1973) Reconstruction for medial instability of the knee *J Bone Jt Surg* 55-A, 941–955

Oretorp, N, Alm, A, Ekstrom H & Gillquist J (1978) Immediate effects of meniscectomy the knee joint The effects of tensile load the joint ligaments in dogs *Acta orthop scan* (In press)

Slocum, D B & Larson, R L (1968) I anserinus transplatation *J Bone Jt Surg* 5 A, 226–242

Slocum, D B, Larson, R L & James, S (1973) Late reconstruction procedures used stabilize the knee *Orthop Clin N Amer* 4 679–689

Snedecor, G W & Cochran, W G (196 *Statistical methods* Iowa State Univers Press, Iowa, USA

Wang, C J & Walker, P S (1974) Rotato laxity of the human knee joint *J Bone J Surg* 56-A, 161–170

Correspondence to Nils Oretorp, Department of Surgery, University Hospital, S-581 85 Linkopi Sweden

Acta orthop scand 50, 337–346, 1979

RECURRENT INSTABILITY OF THE ANKLE JOINT

Surgical Repair by the Watson-Jones Method

JESS HEDEBOE & A JOHANNSEN

Departments of Orthopaedic Surgery E and Diagnostic Radiology R, University Hospital, Aarhus, Denmark

Twenty-one ankle joints with recurrent lateral instability, treated with surgical repair by the Watson-Jones method were included in a follow up study 1–5 years after operation Good results were achieved in 80 per cent However, the results were not better than those after free dissection and direct suture of the ligamentous ruptures It is therefore recommended that the more extensive Watson-Jones procedure be reserved for selected cases.

Key words ankle injuries, ankle joint, ligaments articular

Accepted 18 VII 78

Over the years there has been a great deal of interest in the treatment of recurrent instability of the ankle joint The instability is usually a consequence of insufficient or erroneous treatment of a lesion of the lateral ligaments of the ankle

In order to re-establish stability of the ankle several different operative procedures have been devised Peroneus brevis tenodesis is described in several modifications (Gallie 1913, Nilsonne 1932, Evans 1953, Chrisman & Snook 1969, Viernstein et al 1974) Well known and often used is the Watson-Jones procedure from 1940 (Watson-Jones 1960, Windfeld 1953, Broström 1966, Gillespie & Boucher 1971, Cedell 1975)

Free transplants of tendon or fascia as a substitute for the damaged ligaments have been used by some authors (Elmslie 1934, Rosendahl-Jensen 1952, Weber & Hupfauer 1969), while others have found it possible to identify and free the ends of the torn ligaments even many years after the rupture, and perform direct suture (Brostrom 1966, Solheim & Aasen 1976)

The existence of so many methods arouses suspicion that none of them is convincingly preferable to the others The results of a follow-up study of patients treated for recurrent instability of the ankle by the Watson-Jones technique are presented below

MATERIAL AND METHODS

During the period 1972–1976, 20 patients, aged 14–47 years, underwent surgical repair of 22 ankle joints (15 males, 7 females) Preoperatively, all patients complained of recurrent instability of the ankle and of frequent distorsions. Seven ankles had previously been treated with a plaster-of-Paris cast for at least 4 weeks, while in the others a supportive bandage had been used for a shorter

All joints were repaired by the Watson-Jones method, the peroneus brevis tendon was cut as proximally as possible, taken through drill holes in the lateral malleolus and the neck of the talus and fastened to the malleolus with sutures. After the operation the joint was immobilized in a plaster-of-

0001–6470/79 030337–04$02 50 © © 1979 Munksgaard, Copenhagen

Paris cast for 6 weeks, which during the last 4 weeks was used as a walking boot

Nineteen patients (21 joints) were subjected to a follow-up study 1–5 years (average 2 7 years) after operation One patient did not wish to participate In addition to the clinical examination, a thorough history was obtained with special attention to the patient's own assessment of the result To disclose instability, if any, an inversion-stress radiograph was taken The distance between the articular surfaces of the talus and tibia was measured at the prominence of the lateral eminence of the trochlea tali at rest and during forced supination A difference of 3 mm or more was considered pathological (Figure 1)

The clinical and radiological examinations were performed independently of each other

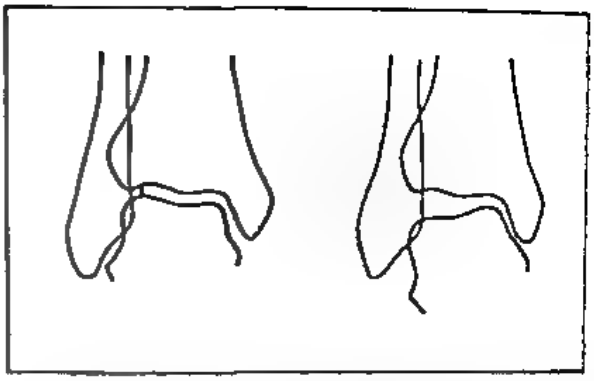

Figure 1 The opening of the tibiotalar joint (in mm) is determined by subtracting the normal distance at rest from the abnormally opened distance during forced supination (Ruth 1961)

RESULTS

The results are summarized in Table 1 Fourteen patients found that the operation had been successful The tendency to instability and distorsion had disappeared These patients had only slight discomfort from the scar and slight pain mainly localized to the malleolus itself (drill holes?), especially after a long walk Several of these patients took part in sports activities and were not impeded in any way There were no complaints of stiffness of the ankle In nine, the clinical examination revealed reduced inversion ability, while five had, clinically, a normal mobility of the ankle joint Radiographically, all 14 showed normal conditions

Three patients reported that the operation had improved the condition They complained of slight residual instability, so that they had to refrain from sports activities and similar heavy strain on the ankle Clinical examination revealed normal mobility of the ankle in these three patients Radiographically, pronounced instability, unchanged in compared with the preoperative examination, was disclosed in one of them, whereas the remaining two were normal

The remaining four patients were dissatisfied with the result of the operation They complained of persisting instability and frequent distorsions, and therefore they had to wear a supportive bandage constantly At the clinical examination, one ankle was laterally loose, two were normal, and one showed limited mobility Radiographically three four were normal

In four ankles the radiological examination disclosed abnormal mobility on the unaffected side

Table 1 Clinical assessment and the patient's own assessment of the results of operation compared with the pre and postoperative radiographic findings

Result as assessed by the patient	No of ankles	Postoperative clinical mobility			Radiologic examination			
					Preoperative		Postoperative	
		Increased	Normal	Reduced	Stable	Unstable	Stable	Unstable
Good	14		5	9	2	12	14	
Improved	3		3			3	2	1
Poor	4	1	2	1	1	3	4	
Total	21	1	10	10	3	18	20	1

DISCUSSION

Most authors who have considered this problem agree that, although they are adequate, the various methods of stabilizing the chronically unstable ankle by operation are inferior to those of repair of the fresh lesion (Ruth 1961, Weber & Hupfauer 1969, Cedell 1975, Reichen & Marti 1974) The mechanisms determining the stability of the ankle are not fully understood

That many patients have abnormal mobility of the ankle joints without symptoms of instability, and that clinical and radiological stability is not always accompanied by functional stability have been pointed out by Bosien et al (1955), Rubin & Witten (1960), Freeman (1965), and others In three ankles, the instability was not radiographically apparent preoperatively Two of these patients were satisfied with the result of the operation. Both were clinically and radiographically stable Three patients who before the operation showed clinical and radiographical instability were not satisfied with the operation, although their ankles at the follow-up were both clinically and radiologically stable It is not possible to offer any valid explanation for this functional instability A defect in the proprioceptive nerves around the ankle, caused by trauma, may be responsible (Freeman et al 1965)

Abnormal lateral mobility without symptoms occurred on the unaffected side in four patients (20 per cent) of this series. None of these ankles had previously been exposed to any severe trauma Abnormal mobility on the unaffected side was thus more frequent than normal in our series, in patients with acute trauma to the ankle are found to have abnormal mobility on the unaffected side in only 5 per cent (Johannsen 1978)

Seventeen ankles (80 per cent) were functionally stable or distinctly improved after the Watson-Jones operation. This shows the applicability of the method Similar results were reported by Gillespie & Boucher (1971). However, 20 per cent of the patients complained of instability after the operation, the method is thus not better than considerably less extensive stabilizing techniques In a follow-up study of directly sutured "old" ruptures, Brostrom (1966) found residual instability in 15 per cent. In a similar series Solheim & Aasen (1976) reported postoperative instability in 14 per cent In addition, a substantial objection to the Watson-Jones method is that the operation deprives the ankle of one of its most important pronators, so that an unsuccessful operation can aggravate the preoperative condition

These circumstances favour a more reserved attitude to tenodesis of the chronically unstable ankle A more active approach to the fresh lesion would also reduce the need for later operations (Reichen & Marti 1974)

REFERENCES

Bosien, W R, Staples, O S & Russell S W (1955) [illegible]

Cedell, C-A, (1975) Ankle lesions. *Acta orthop scand* 46, 425–445

Chrisman, O D & Snook, G A (1969) Reconstruction of lateral ligament tears of the ankle *J Bone Jt Surg* 51 A, 904–912.

Evans, D L (1953) Recurrent instability of the ankle — a method of surgical treatment *Proc roy Soc Med* 46, 343–344

Elmslie, R. C (1934) Recurrent subluxation of the ankle joint *Ann Surg* 100, 364–367

Freeman M A R (1965) Treatment of ruptures of the lateral ligament of the ankle *J Bone Jt Surg* 47-B, 661–668

Freeman, M. A R, Dean, M. R E. & Hanham, I W F (1965) The etiology and prevention of functional instability of the foot. *J Bone Jt Surg* 47-B, 678–685

Gallie, W E (1913) Tendon fixation — An operation for the prevention of deformity in infantile paralysis. *Amer J Orthop Surg* 11, 151–155

Gillespie, H S. & Boucher P (1971) Watson-Jones repair of lateral instability of the ankle *J Bone Jt Surg* 53-A 920-924

Johannsen, A (1978) Radiological diagnosis of lateral ligament lesion of the ankle *Acta orthop scand* (In press)

Nilsonne, H (1932) Making a new ligament in ankle sprain *J Bone Jt Surg* **14**, 380–381

Reichen, A & Marti, R (1974) Die frische fibulare Bandruptur — Diagnose, Therapie, Resultate *Arch orthop Unfall-Chir* **80**, 211–222

Rosendahl-Jensen, E (1952) De laterale ligamentrupturer i fodleddet *Nord Med* **47**, 13, 423–426

Rubin, G & Witten, M (1960) The talar-tilt angle and the fibular collateral ligaments *J Bone Jt Surg* **42-A**, 311–326

Ruth, C J (1961) The surgical treatment of injuries of the fibular collateral ligaments of the ankle *J Bone Jt Surg* **43-A**, 229–239

Solheim, L. F & Aasen, A O (1976) Operativ behandling av laterale ankelbåndskader *T norske Laegeforen* **23**, 1192–1194

Viernstein, K, Rosemeyer, B & Artmann, M (1974) Eine Operationsmethode zur Behandlung der chronischen fibularen Bandinsuffizienz *Arch orthop Unfall Chir* **78**, 157–159

Watson-Jones R (1960) *Fractures and joint injuries* Vol 2, 4th ed pp 821–823 E and S. Livingstone Ltd Edinburgh

Weber, B G & Hupfauer, W (1969) Zur Behandlung der frischen fibularen Bandruptur und der chronischen fibularen Bandinsuffizienz *Arch orthop Unfall Chir* **65**, 251–257

Windfeld, P (1953) Treatment of undue mobility of the ankle joint following severe sprain of the ankle with avulsion of the anterior and middle bands of the external ligament *Acta chir scand* **105**, 299–304

Correspondence to Jens Hedeboe, Frederikshaldsgade 4b, 8200 Aarhus N, Denmark

Acta orthop scand 50, 341–344 1979

PROCEEDINGS OF THE NORWEGIAN ORTHOPAEDIC ASSOCIATION

EDITOR ARNT JAKOBSEN

Oslo, January 21st, 1978

MOIRÉ TOPOGRAPHY – A METHOD FOR DIAGNOSIS OF STRUCTURAL SCOLIOSIS

Stig Willner
Malmø General Hospital, Malmø

Moire topography is an optical method for a three dimensional description of the shape of the back Using this method shadow lines or contour lines are caused by interference between a grid and its shadow on the surface of the back. The pattern of these shadows is influenced by the shape of the illuminated object The contour lines correspond to those of a topographic map In the symmetric trunk the contour lines are the same on both sides of the back In the presence of a structural scoliosis, however, the pattern of the shadows will differ in a typical way between the convex and the concave side because of the extent of the rotation

Scolioses even less than 10° (according to Cobb) can be diagnosed and documented by photography

The method seems to be suitable for school screening of spinal deformities (up to 40 children can be investigated per hour)

EFFECTS OF OXYTETRACYCLINE ON THE MECHANICAL PROPERTIES OF BONE AND SKIN IN YOUNG RATS

Lars B Engesaeter
Institute for Surgical Research, Rikshospitalet, Oslo

Acta orthop scand 49 529–534

Oslo, February 11th, 1978

FOOTBALL INJURIES IN CHILDREN AND YOUTHS

Asbjørn Roaas & Svein Nilsson
Martina Hansens Hospital, Sandvika and Health-Sport Center, Beitostølen

This study covers all injuries which occurred in 25 000 players who took part in 2987 matches during the Norway Cup in 1975 and 1977

A total of 767 consultations were due to injury during matches, one third were contusions. Only 29 fractures were registered, most of them were epiphyseolyses of the distal radius without dislocation The injury rate was 14 per 1000 hours of playing time Nine out of 10 of the injured played football the following day

It is concluded that football is a relatively safe sport for children and youths with a low injury rate, most injuries being of a minor nature.

TUBERCULOSIS OF THE GREATER TROCHANTER — STILL AN IMPORTANT AND CURRENT CONDITION

Arvid Lager & Per Stewers
Martina Hansens Hospital, Sandvika

Seventeen new cases of bone and joint tuberculosis occurred in Norway in 1976, and in 1 month in 1977 three patients were treated for tuberculosis of the greater trochanter in this hospital A regrettable delay because of wrong or late diagnosis prolonged the suffering of the patients, and in one case resulted in a destroyed hip

The importance of bearing this diagnosis in mind is stressed.

PSYCHIATRIC ASPECTS IN AN ORTHOPAEDIC SURGICAL HOSPITAL

Trygve Leite
Martina Hansens Hospital and Blakstad Hospital Sandvika

Some reflections of a psychiatrist, after working for 4 months in an orthopaedic hospital, are reported.

Initially irrational feelings of staff and patients, both positive and aggressive, were noticeable

0001–6470/79 030341 04$02 50 0

© 1979 Munksgaard, Copenhagen

Combined therapy in long-lasting neurotic disorders gave good results.

A preliminary report is given of a pilot-study of low-back pain. In more than 50 per cent of cases clinical and radiological examination did not explain the suffering Only three out of 32 patients presented neurotic conflicts indicating causal relationships. Ten patients showed marked reactive depression in non-diagnosed complaints. Iliosacral distortion (Ingebrigtsen) is pointed out as a possible explanation in some cases of low-back pain Extended cooperation between the different medical fields is necessary to help patients in the above-mentioned group

PAGET'S DISEASE OF BONE TREATED WITH CALCITONIN

Rolf Hagen & Havard Bjerkholt
Martina Hansens Hospital, Sandvika

Paget's disease is a rare disorder in the Scandinavian countries. The etiology is unknown and its pathophysiology poorly understood Chronic inflammation, virus infection, congenital defect of the collagen synthesis, autoimmune disturbances and neoplasm of the osteoprogenitor cells have been suggested as causes of the increased bone turnover

The excretion of hydroxyproline in the urine is increased and the serum alkaline phosphatase elevated.

Three patients are reported A 56-year-old man was given salmon calcitonin (100 Medical Research Council units) subcutaneously every second day for 6 months with good clinical response and normalization of the biochemical and scintigraphical findings.

Oslo, March 11th, 1978

SPINAL STENOSIS

Ole J Aarsrud
Central Hospital in Østfold, Fredrikstad

A case report of a patient, operated upon seven times for sciatica was presented He had a typical spinal claudication during walking and driving a car Sitting in a kyphotic position relieved the pain. Metrizamid myelography in a sitting position showed a total block with the back extended.

Total laminectomy and partial facetectomy from L2 to L4 was performed. Normal pulsation of the dura came after removal of the arch of L2.

The patient is relieved from pain and intermittent claudication.

The differential diagnosis between this case and a case of arterial claudication was discussed. The importance of asking the multi-operated patient about claudication symptoms, and the value of performing myelography in a sitting position was pointed out

INDOMETHACIN, NAPROXEN AND OSTEOARTHRITIS

Leif Egil Nygaard
Central Hospital in Østfold, Fredrikstad

A double-blind study of the treatment of osteoarthritis of the hip and knee with indomethacin and naproxen, comparing the effects and side effects is reported The two drugs seem to have an equal effect as far as pain and stiffness are concerned. Indomethacin seems to have slightly more gastrointestinal side effects than naproxen.

NON-UNION OF FRACTURES OF THE HUMERUS

Ole J Aarsrud
Central Hospital in Østfold, Fredrikstad

Three cases of non-union of fractures of the middle part of the humerus were presented. All had initially been unsuccessfully "treated" with a hanging-cast and later operated upon, one patient four times in 6 years.

Re-operation was performed using bone-chips and fixation was achieved with two staples. Postoperatively a thoraco-brachial plaster of Paris cast was applied. All the fractures healed in 3 months.

THE PRONATOR TERES SYNDROME

Leif Egil Nygaard
Central Hospital in Østfold, Fredrikstad

In the forearm the median nerve runs under or through the pronator teres muscle On rare occasions this muscle may have accessory bellies and the median nerve may become compressed between the main and the accessory bellies causing paresthesia and paresis.

One case is presented. The nerve was compressed between the main portion of the muscle and an accessory belly which originated from the interosseous membrane Operative treatment was successful.

WHAT CAN WE OFFER PATIENTS WITH PELVIC RELAXATION SYMPTOMS?

Erik Lie
Central Hospital in Østfold, Fredrikstad

Our experience during the past 20 years is discussed. Only in four cases has surgical treatment been offered. Arthrodesis of both sacro-iliac joints and the symphysis has been performed in these cases.

The importance of daily contact with the gynecological ward is stressed so that evaluation of these patients can be made from the onset of their complaints.

Oslo, April 15th, 1978

SUPRACONDYLAR FEMORAL FRACTURES IN OLD PATIENTS

Ulf Slungaard
Aker Hospital, Oslo

Supracondylar femoral fractures in old patients represent a problem when treated in the usual way with the AO condylar plate osteosynthesis. Loosening of the screws, a tendency to varus deformity and slow healing are frequent complications. These patients have often previously had a plate inserted in the proximal part of the same femur, and an additional plate causes a weak point between the plates.

We now treat these fractures with two Rush pins introduced from the condyles, and we find this treatment promising. It causes very little operative trauma and the fractures seem to heal with more certainty, even when accepting a far from ideal fragment position.

FRACTURES THROUGH THE RETROCONDYLAR FOSSA OF THE PROXIMAL PHALANX OF THE FINGER

Hans M. Storvik
Aker Hospital, Oslo

The author believes that the restricted flexion at the proximal interphalangeal joint associated with fractures through the retrocondylar fossa of the proximal phalanx and dorsal dislocation of the distal fragment, is produced by a mechanical blockage of the movement of the volar plate.

Several experiments have been carried out to prove this, and the importance of this blockage in the treatment of this type of fracture is stressed.

GAS GANGRENE

Tore Blom Hagen
Aker Hospital, Oslo

The most reliable protection against gas gangrene is early wound debridement and prophylactic penicillin medication in all cases of open [illegible] the need for amputation.

One case of gas gangrene infection in an open fracture of the shaft of the tibia, which led to amputation, is reported. At the time of manifest infection the patient was treated with surgical debridement and antibiotics, but no prophylactic measures were taken.

OSTEOID OSTEOMA

A. Mellerud
Aker Hospital, Oslo

After a brief survey of the characteristics of this disease and its operative treatment, two cases of osteoid osteoma in the tibia of young men are reported. One of them had multiple niduses. The significance of tomography in identifying the nidus is stressed.

Oslo, May 20th, 1978

HIP PROBLEMS IN MYELOMENINGOCELE

Cato Hellum
Kronprinsesse Marthas Institutt, Oslo

Hip dislocation is especially liable to occur when the affected level is L3–L4, with active hip flexors and adductors and paralytic extensors and abductors. Treatment aims at restoring muscular balance. This can be done by transferring m. iliopsoas to the greater trochanter *ad modum* Sharrard.

Forty-seven hips in 32 patients were operated on in this way over the last 12 years.

Results	Caput in good position	12 hips
	Improved, but dysplasia/ subluxation persists	19 hips
	Failure, dislocated as before	16 hips

More important than dislocation are contractures. These must be corrected radically. Usually capsulotomy is necessary.

Combined therapy in long-lasting neurotic disorders gave good results.

A preliminary report is given of a pilot-study of low back pain In more than 50 per cent of cases clinical and radiological examination did not explain the suffering Only three out of 32 patients presented neurotic conflicts indicating causal relationships. Ten patients showed marked reactive depression to non-diagnosed complaints Iliosacral distortion (Ingebrigtsen) is pointed out as a possible explanation in some cases of low-back pain Extended cooperation between the different medical fields is necessary to help patients in the above-mentioned group

PAGET'S DISEASE OF BONE TREATED WITH CALCITONIN

Rolf Hagen & Havard Bjerkholt
Martina Hansens Hospital, Sandvika

Paget's disease is a rare disorder in the Scandinavian countries. The etiology is unknown and its pathophysiology poorly understood Chronic inflammation, virus infection, congenital defect of the collagen synthesis, autoimmune disturbances and neoplasm of the osteoprogenitor cells have been suggested as causes of the increased bone turnover

The excretion of hydroxyproline in the urine is increased and the serum alkaline phosphatase elevated

Three patients are reported A 56-year-old man was given salmon calcitonin (100 Medical Research Council units) subcutaneously every second day for 6 months with good clinical response and normalization of the biochemical and scintigraphical findings

Oslo, March 11th, 1978

SPINAL STENOSIS

Ole J Aarsrud
Central Hospital in Østfold Fredrikstad

A case report of a patient, operated upon seven times for sciatica was presented. He had a typical spinal claudication during walking and driving a car Sitting in a kyphotic position relieved the pain Metrizamid myelography in a sitting position showed a total block with the back extended

Total laminectomy and partial facetectomy from L2 to L4 was performed Normal pulsation of the dura came after removal of the arch of L2.

The patient is relieved from pain and intermittent claudication.

The differential diagnosis between this case and a case of arterial claudication was discussed. The importance of asking the multi-operated patient about claudication symptoms, and the value of performing myelography in a sitting position was pointed out

INDOMETHACIN, NAPROXEN AND OSTEOARTHRITIS

Leif Egil Nygaard
Central Hospital in Østfold, Fredrikstad

A double-blind study of the treatment of osteoarthritis of the hip and knee with indomethacin and naproxen, comparing the effects and side effects is reported The two drugs seem to have an equal effect as far as pain and stiffness are concerned Indomethacin seems to have slightly more gastrointestinal side effects than naproxen.

NON-UNION OF FRACTURES OF THE HUMERUS

Ole J Aarsrud
Central Hospital in Østfold, Fredrikstad

Three cases of non-union of fractures of the middle part of the humerus were presented. All had initially been unsuccessfully "treated" with a hanging-cast and later operated upon, one patient four times in 6 years.

Re-operation was performed using bone-chips and fixation was achieved with two staples. Post operatively a thoraco-brachial plaster of Paris cast was applied All the fractures healed in 3 months

THE PRONATOR TERES SYNDROME

Leif Egil Nygaard
Central Hospital in Østfold Fredrikstad

In the forearm the median nerve runs under or through the pronator teres muscle On rare occasions this muscle may have accessory bellies and the median nerve may become compressed between the main and the accessory bellies causing paresthesia and paresis.

One case is presented. The nerve was compressed between the main portion of the muscle and an accessory belly which originated from the interosseous membrane. Operative treatment was successful.

WHAT CAN WE OFFER PATIENTS WITH PELVIC RELAXATION SYMPTOMS?

Erik Lie
Central Hospital in Østfold, Fredrikstad

Our experience during the past 20 years is discussed. Only in four cases has surgical treatment been offered. Arthrodesis of both sacro-iliac joints and the symphysis has been performed in these cases.

The importance of daily contact with the gynecological ward is stressed so that evaluation of these patients can be made from the onset of their complaints.

Oslo, April 15th, 1978

SUPRACONDYLAR FEMORAL FRACTURES IN OLD PATIENTS

Ulf Slungaard
Aker Hospital, Oslo

Supracondylar femoral fractures in old patients represent a problem when treated in the usual way with the AO condylar plate osteosynthesis. Loosening of the screws, a tendency to varus deformity and slow healing are frequent complications. These patients have often previously had a plate inserted in the proximal part of the same femur, and an additional plate causes a weak point between the plates.

We now treat these fractures with two Rush pins introduced from the condyles, and we find this treatment promising. It causes very little operative trauma, and the fractures seem to heal with more certainty, even when accepting a far from ideal fragment position.

[illegible]

Hans M. Storvik
Aker Hospital, Oslo

The author believes that the restricted flexion at the proximal interphalangeal joint, associated with fractures through the retrocondylar fossa of the proximal phalanx and dorsal dislocation of the distal fragment, is produced by a mechanical blockage of the movement of the volar plate.

Several experiments have been carried out to prove this, and the importance of this blockage in the treatment of this type of fracture is stressed.

GAS GANGRENE

Tore Blom Hagen
Aker Hospital, Oslo

The most reliable protection against gas gangrene is early wound debridement and prophylactic penicillin medication in all cases of open fractures. The traditional therapeutic approach is immediate surgical intervention with wide radical debridement followed by open drainage without wound closure. The drug of choice is penicillin-G or ampicillin in major doses. Hyperbaric oxygen does not alter mortality rate, but often obviates the need for amputation.

One case of gas gangrene infection in an open fracture of the shaft of the tibia, which led to amputation, is reported. At the time of manifest infection the patient was treated with surgical debridement and antibiotics, but no prophylactic measures were taken.

OSTEOID OSTEOMA

A. Mollerud
Aker Hospital, Oslo

After a brief survey of the characteristics of this disease and its operative treatment, two cases of osteoid osteoma in the tibia of young men are reported. One of them had multiple niduses. The significance of tomography in identifying the nidus is stressed.

Oslo, May 20th, 1978

HIP PROBLEMS IN MYELOMENINGOCELE

Cato Hellum
Kronprinsesse Märthas Institutt, Oslo

Hip dislocation is especially liable to occur when the affected level is L3–L4, with active hip flexors and adductors and paralytic extensors and abductors. Treatment aims at restoring muscular balance. This can be done by transferring m. iliopsoas to the greater trochanter *ad modum* Sharrard.

Forty-seven hips in 32 patients were operated on in this way over the last 12 years.

Results	Caput in good position	12 hips
	Improved, but dysplasia/ subluxation persists	19 hips
	Failure, dislocated as before	16 hips

More important than dislocation are contractures. These must be corrected radically. Usually capsulotomy is necessary.

OPERATIVE TREATMENT OF TENNIS ELBOW

Tore Grønmark
Kronprinsesse Marthas Institutt, Oslo

Surgical procedures for tennis elbows are discussed The results of surgical treatment of 27 elbows are presented Hohmann's operation with ablation of the common extensor origin and a modification of Bosworth's operation have been used The average duration of symptoms before operation was 22 months, and the average observation time was 27 months. Eighteen patients were completely free of symptoms, four patients were markedly improved and five patients were not improved Surgical treatment is advocated for those patients who fail to obtain relief after conservative treatment

INFECTION AFTER TOTAL KNEE REPLACEMENT

Olav Reikerås
Kronprinsesse Marthas Institutt, Oslo

Infection seems to be a greater problem following total knee replacement than after total hip replacement In 523 total hip replacements *ad modum* Muller we had an infection rate of 1 7 per cent In 46 knee replacements *ad modum* Shiers and Guepar, all having rheumatoid arthritis, the infection rate was 24 per cent By adequate antibiotic medication the situation was brought under control in six patients. We have removed four prostheses. In the most recently operated case intramedullary nailing from femur to tibia was performed, and gentamycin-cement added The recovery was uneventful, and the patient was mobilized after 2 weeks.

CHRISTIANSEN ENDOPROSTHESIS IN OSTEOARTHRITIS OF THE HIP

Astor Reigstad
Kronprinsesse Märthas Institutt, Oslo

The long-term results of 16 Christiansen endoprostheses for osteoarthritis of the hip are reported Average observation time is 8.3 years No infection or dislocation occurred. One patient had loosening of the stem, and total hip replacement was done Five patients (31 per cent) had acetabular problems one patient with proximal migration of the acetabulum had total hip replacement, four patients had intrusion of the prosthesis into the pelvis, only one had pain and none were re-operated

The clinical results were classified as excellent in ten (63 per cent), fair in two and poor in four patients. Compared with total hip replacement the long-term results after Christiansen endoprosthesis are less satisfactory, mainly because of the acetabular problems.

RECONSTRUCTION OF THE THUMB

Arne Rugtvett
Kronprinsesse Marthas Institutt, Oslo

Methods of treating total and subtotal thumb deficiency were reviewed and evaluated. It was proposed that pollicization of a toe is indicated when the injured hand lacks two or three fingers in addition to the thumb *Pollicization* of an index finger amputated at the proximal interphalangeal joint, with arthrodesis of the metacarpo-phalangeal joint was the operation of choice However, pollicization of a normal index finger in the same situation was held to be controversial.

A 16-year-old boy was presented on whom pollicization of a normal index finger was carried out after amputation of the thumb at the metacarpo-phalangeal joint An excellent functional and cosmetic result was obtained.

ECTOPIC BONE FORMATION FOLLOWING LOW FRICTION ARTHROPLASTY OF THE HIP AD MODUM CHARNLEY

C Kromann-Andersen, E Frigaard, F Borch Jensen, D Zdravkovic, K Hougaard & T Scherff Sørensen
Odense University Hospital, Odense, Denmark

Three hundred and nine patients with 365 operated hips were examined for the presence of ectopic bone formation. Assessment was made by studying ordinary X-rays in the a-p projection and the patients were divided into four groups according to the degree of severity (from none to bridged ectopic bone formation between acetabulum and femur) Charnley's classification concerning pain, walking ability and range of motion was used to evaluate the clinical importance of ectopic bone The average observation time was 4 years and 4 months

Ectopic bone formation occurred more frequently and was more marked in men than in women The frequency of the occurrence of ectopic bone formation increased with time Ectopic bone formation may restrict the range of motion In bilaterally operated hips there was usually a similar amount of ectopic bone formation on both sides

PROBLEMS WITH THE GREATER TROCHANTER IN CHARNLEY TOTAL HIP ALLOPLASTY

T Scherff Sørensen, Kj Hougaard, D Zdravkovic, F Borch Jensen, E Frigård & C Kromann-Andersen
Odense Hospital, Odense, Denmark

To be published in Acta

[illegible]

Hvidovre Hospital, Denmark

One hundred and forty-seven total hip replacements were reviewed The patients were 17–85 years old with a mean age of 70 years. The Stanmore prosthesis was used and the operation was performed through a posterior approach No infections occurred All patients received prophylactic antibiotic treatment with methicillin at the beginning of the operation and with dicloxacillin 5 days postoperatively The operating room was disinfected with alcohol before surgery, the air in the operating theatre did not contain microorganisms before the operation, as demonstrated by sedimentation plates

Ten postoperative dislocations were registered One patient died 13 days after surgery from pulmonary embolism, and a further four patients had thrombophlebitis but recovered within 1 week

COMPLICATIONS AFTER TOTAL HIP REPLACEMENT

Johannes Yde
Hjørring Hospital, Hjørring, Denmark

One hundred and sixty three total hip replacements according to Charnley were performed on 145 patients during the years 1974–1977 Seventy-five were operated on in an ordinary operating theatre and [illegible] in a clean air box

Peroperatively one fracture of the femoral shaft and six stem perforations of the shaft were encountered

Complications during the first 3 months comprised five deep venous thromboses and one death from pulmonary embolism There were two dislocations, both treated by closed reduction followed by traction, but no primary infections were recorded

Complications occurring more than 3 months postoperatively were 37 hips with tenderness over the trochanter region There was no relation to radiographic findings such as a broken wire, fibrous union or proximal migration of the greater trochanter Twelve hips had a radiolucent line between the femoral prosthesis and the cement Three had fractures of the cement without subjective symptoms, and two sustained a fracture of the femoral shaft and were treated by internal fixation with plates and screws. No patients developed deep infection

POSTOPERATIVE COMPLICATIONS AFTER 605 CHARNLEY TOTAL HIP REPLACEMENTS

E Dyreborg, J Jørgensen, P Krogh, E K Petersen, R. Rohr & C Schlanbusch
University Hospital of Odense, Denmark

There was one fatal complication in the series. It was not possible to identify groups with a high risk of cardiopulmonary complications Among the patients with preoperative cardiopulmonary illness we found postoperative complications in 13 per cent, compared with 21 per cent among the remaining patients Early mobilization led to a significant fall in the incidence of deep vein thrombosis and pulmonary embolism from 20 to 5 per cent Six per cent developed urinary infection postoperatively, due either to a previous urinary infection or to the use of a postoperative indwelling catheter Patients treated previously for

NINE YEARS' EXPERIENCE WITH TOTAL HIP REPLACEMENT WITH SPECIAL REGARD TO LOOSENING AND INFECTION

Imre Gabor & Olav Reikerås
Sophies Minde Orthopaedic Hospital, Oslo, Norway

We started in 1969 to use Weber's and in 1973 Ring's hip prosthesis. Both have a high frequency of loosening, up until now 50 and 10 per cent, respectively. Between 1970 and 1976, 55 patients with loose prostheses were reoperated on and fitted with a new prosthesis. The result is good in 44 and unsatisfactory in 11 patients, but 10 of these were fitted with the Weber prosthesis.

Between 1969 and 1973 there was an infection rate of 8 per cent. From 1 January 1974, operating routines based on strict aseptic principles were introduced. There has since been no instance of deep infection.

The 30 patients who developed deep infection in the earlier period were treated mainly by removal of the prosthesis and bringing the infection under control. Seven of the 30 patients have had new hip prostheses inserted 1 to 7 years after the primary prosthesis was removed. These seven patients have been observed for a period of between ½ and 3½ years, all are well with no evidence of infection.

274 TOTAL HIP REPLACEMENTS WITH CHRISTIANSEN'S TRUNNION BEARING PROSTHESIS COMPLICATIONS AND SOCIAL ASPECTS

Rolf Hagen
Martina Hansens Hospital, Sandvika, Norway

During a 4½ year period from 1 11 73 to 1 5 77, 277 arthroplasties (215 unilateral and 31 bilateral) were performed. Eighty-seven per cent of the patients were over 60 years. There were no post-operative deaths, nine died from other diseases and three were excluded (mean follow-up 2½ years). Forty-five patients had previously been operated on in the same hip

The operations were performed in a regular operating room and the posterior approach without detaching the trochanter was used. No general prophylactic antibiotics were administered but gentamicin cement was used from 1 1 76 Thrombosis prophylaxis comprised Macrodex® peroperatively and during the 1st day, early mobilization and Marevan® perorally from the 1st day.

The complications are listed in Table 1 Twelve patients required reoperation.

Table 1. Complications in 274 arthroplasties (243 patients) using Christiansen's prosthesis

Early	No.	Per cent
Haematoma	7	2.5
Haematoma with dropfoot	1	0.4
Haematoma with superficial infection	3	1.1
Infection, superficial	2	0.7
Infection, deep	1	0.4
Pneumonia	3	1.1
Dropfoot	1	0.4
Thrombosis	3	1.1
Dislocation	2	0.7
	23	8.4

Late	No.	Per cent
Loose femoral component	6	2.18 } 2.5
Loose acetabular component	1	0.36
Osteomyelitis	3	1.1
Reaction from implanted material?	2	0.7
Dislocation	1	0.36
	13	4.7

CHARNLEY

Åke S Carlsson & Carl Fredrik Gentz
Malmö General Hospital, Malmö, Sweden

Loosening was defined as the development of a zone of demarcation between metal and cement at the proximal and lateral border of the stem of the prosthesis, but zones less than 1 mm were disregarded. The demarcation was found in 103 out of 288 (36 per cent) non-infected, low friction arthroplasties. The occurrence of zones became more frequent as the years passed, and they were significantly more common in men. A previous operation was followed by a significantly increased risk of loosening Absence of cement medially at the femoral calcar or elsewhere around the prosthesis seemed to be of greater importance than the position of the prosthesis. The body weight did not differ between patients with and without a zone of demarcation. Pain on walking was found in 7 per cent of the patients without and in 21 per cent in patients with a demarcation. The difference is significant. With increasing width of the zone, there was a significantly increased proportion of painful hips.

[illegible]

C Kromann-Andersen, E Frigaard, F Borch Jensen, D Zdravkovic, K. Hougaard & T Scherff Sørensen
Odense University Hospital, Odense, Denmark

Three hundred and nine patients with 365 operated hips were examined for the presence of ectopic bone formation Assessment was made by studying ordinary X-rays in the a p projection and the patients were divided into four groups according to the degree of severity (from none to bridged ectopic bone formation between acetabulum and femur). Charnley's classification concerning pain, walking ability and range of motion was used to evaluate the clinical importance of ectopic bone The average observation time was 4 years and 4 months.

Ectopic bone formation occurred more frequently and was more marked in men than in women The frequency of the occurrence of ectopic bone formation increased with time Ectopic bone formation may restrict the range of motion In bilaterally operated hips there was usually a similar amount of ectopic bone formation on both sides

PROBLEMS WITH THE GREATER TROCHANTER IN CHARNLEY TOTAL HIP ALLOPLASTY

T Scherff Sørensen, Kj Hougaard, D Zdravkovic, F Borch Jensen, E Frigård & C Kromann-Andersen
Odense Hospital, Odense, Denmark

To be published in Acta

[illegible]

One hundred and forty-seven total hip replacements were reviewed. The patients were 17–85 years old with a mean age of 70 years. The Stanmore prosthesis was used and the operation was performed through a posterior approach. No infections occurred. All patients received prophylactic antibiotic treatment with methicillin at the beginning of the operation and with dicloxacillin 5 days postoperatively The operating room was disinfected with alcohol before surgery, the air in the operating theatre did not contain microorganisms before the operation, as demonstrated by sedimentation plates.

Ten postoperative dislocations were registered One patient died 13 days after surgery from pulmonary embolism, and a further four patients had thrombophlebitis but recovered within 1 week

COMPLICATIONS AFTER TOTAL HIP REPLACEMENT

Johannes Yde
Hjørring Hospital, Hjørring, Denmark

One hundred and sixty-three total hip replacements according to Charnley were performed on 145 patients during the years 1974–1977 Seventy-five were operated on in an ordinary operating theatre and 88 in a clean-air box

Peroperatively one fracture of the femoral shaft and six stem perforations of the shaft were encountered

Complications during the first 3 months comprised five deep venous thromboses and one death from pulmonary embolism There were two dislocations, both treated by closed reduction followed by traction, but no primary infections were recorded

Complications occurring more than 3 months postoperatively were 37 hips with tenderness over the trochanter region There was no relation to radiographic findings such as a broken wire, fibrous union or proximal migration of the greater trochanter Twelve hips had a radiolucent line between the femoral prosthesis and the cement Three had fractures of the cement without subjective symptoms, and two sustained a fracture of the femoral shaft and were treated by internal fixation with plates and screws. No patients developed deep infection

POSTOPERATIVE COMPLICATIONS AFTER 605 CHARNLEY TOTAL HIP REPLACEMENTS

E Dyreborg, J Jørgensen, P Krogh, E K Petersen, R Rohr & C Schlanbusch
University Hospital of Odense, Denmark

There was one fatal complication in the series. It was not possible to identify groups with a high risk of cardiopulmonary complications. Among the patients with preoperative cardiopulmonary illness, we found postoperative complications in 13 per cent, compared with 21 per cent among the remaining patients. Early mobilization led to a significant fall in the incidence of deep vein [illegible] infection or to the use of a postoperative indwelling catheter Patients treated previously for

bleeding from a duodenal ulcer had a high risk of postoperative gastrointestinal complications.

PROPHYLAXIS AGAINST THROMBOPHLEBITIS AND THROMBOEMBOLIC COMPLICATIONS IN TOTAL HIP ALLOPLASTY

T Scherff Sørensen & K Lund
Odense Hospital, Odense, Denmark

To be published in Acta

PREOPERATIVE REDUCTION OF WEIGHT IN HIP ALLOPLASTY

Vagn Højkjær Larsen
Odense University Hospital, Odense, Denmark

During the period 1 April 1975 to 31 March 1977, 411 patients were admitted for treatment of coxarthrosis Height and weight were registered in 395 Two hundred and fifty-two were considered overweight (normal weight plus 10 per cent) One hundred and thirty overweight patients were offered operation, provided their weight could be [illegible]

change of diet in [illegible] per cent, and regular check-ups at the general practitioner in 42 per cent Three per cent needed hospitalization during weight reduction. If the attempted reduction in weight amounted to less then 15 kg, this could be achieved within a year The average weight loss was 8 6 kg

VALUE OF EPICUTANEOUS TESTS FOR ALLERGY TO METALS IN IMPLANTATION SURGERY

T Silvennoinen, E Karaharju, P Slätis & M Hannuksela
Surgical Hospital, Helsinki, Finland

Two hundred and fifty-eight patients who were to have a metallic implant (endoprosthesis, AO plate or Kuntscher nail) were patch-tested for cobalt, chrome, nickel and iron allergy Four patients showed severe allergy before surgery The incidence corresponds to recorded figures of the frequency of metal allergy in the Finnish population.

A series of 50 of these patients, without previous allergy, [illegible] treated with hip endoprostheses [illegible] least 1 year previously were selected for a second patch test The second test was supplemented with radiographs and clinical examination. Three of the patients had developed allergy to the metals tested, two of these showed signs of loosening of their prostheses. The small numbers do not warrant conclusions on the interaction between metal allergy and loosening

METAL SENSITIVITY IN PATIENTS WITH METAL-TO-PLASTIC TOTAL HIP ARTHROPLASTIES

Åke S Carlsson & Bertil G Magnusson
Malmö General Hospital Malmö, Sweden

To be published in Acta

RESURFACING ARTHROPLASTY OF THE HIP AD MODUM WAGNER

K Aalto, P Slätis & E Karaharju
Surgical Hospital, Helsinki, Finland

Thirty Wagner resurfacing arthroplasties were performed on 28 patients. Mean age was 66 years three patients were under [illegible] The indication for operation was degenerative arthritis in 26 cases and rheumatoid arthritis in four cases. A trochanteric osteotomy had previously been performed on three hips. Radiologically, the arthrosis was severe in 18 cases The main complaints were pain and restricted walking ability

The patients were allowed out of bed on the 3rd postoperative day Slight ectopic ossification was recorded in three cases. No infection or fracture of the femoral neck was encountered. Painless walking was achieved in most cases. The overall mobility score of the hip graded according to d'Aubigné-Postel, increased from 107 to 172 degrees.

[illegible] BLOOD

CHARNLEY

K Lund & T Scherff Sørensen
Odense Hospital, Odense, Denmark

The drop in blood pressure during the cementing of the acetabular and the femoral components in 402 hip joints, was estimated retrospectively and related to the preoperative blood pressure level, the peroperative loss of blood and the technique used for reducing the pressure in the medullary cavity of the femur during insertion of the cement.

SOCIO-MEDICAL EVALUATION OF THE PATIENT'S LIFE AFTER CHARNLEY HIP ALLOPLASTY

C Kromann Andersen & K Jørgensen
Odense University Hospital, Odense, Denmark

Three hundred and ten patients were examined with reference to their socio-medical conditions

pre- and postoperatively Operation on the hip did not allow any of the preoperatively retired patients to return to work. Moreover 22 per cent of the preoperatively able-bodied patients were given a pension on socio-medical grounds, the majority because of the operated hip Other variations in the patients' occupational and pension status depended entirely on age group The patients' level of activity was assessed by a questionnaire and they were divided into five groups ranging from patients requiring nursing care to persons with physically active spare-time interests. This was compared with the patients' preoperative situation

We concluded that operation on the hip quite unequivocally improved the possibility of physical activity, in 75 per cent of the patients had normalized their life, and 50 per cent were able to enjoy physically demanding spare-time interests.

A COMPARISON BETWEEN THE SURGEONS' EVALUATION OF THE RESULT AFTER TOTAL HIP ARTHROPLASTY AND THE PATIENT'S EVALUATION OF HIP PAIN AND MOBILITY

Knud Jørgensen
Odense Hospital, Odense, Denmark

Our evaluation was made 2 and 5 years after operation, according to the Charnley numerical classification. The results are satisfactory

A questionnaire to 309 patients enquired about pain and mobility (no pain, less pain, more pain, improved or impaired mobility) Ninety five per cent had no pain or less pain after operation, 87 per cent had improved mobility

The Charnley classification was simplified in order to make it comparable with the patient's evaluation. There was an excellent agreement We asked if the operation came up to expectations, 91 per cent answered yes Finally we asked if the patients would recommend the operation to other persons with hip disease, 95 per cent answered yes. Conclusion Our evaluation corresponds with that of the patients

Olof Norman
General Hospital Lund, Sweden

The position of the femoral component of the hip prosthesis with regard to rotation can be

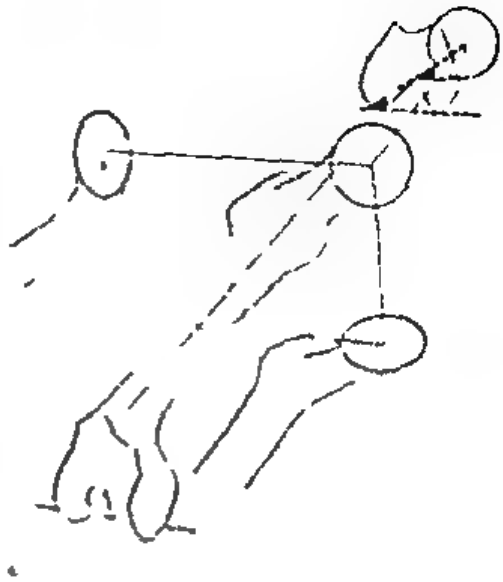

illustrated by measuring the anteversion angle The author's method is based on defined frontal and true lateral views and graphic-geometric calculation The shape of the neck can be disregarded and therefore the method is suitable for all the different types of prostheses. The patient can remain in the resting position and no co-operation is required, allowing for the method to be used pre-, per- and postoperatively

One can also derive ample information from conventional frontal and oblique lateral views, provided one knows the orientation of the femur, which is why, without moving the leg, we take an additional lateral film of the knee for assessing rotation.

MOVEMENT BETWEEN BONE AND BONE

Halldór Baldursson, Lars Ingvar Hansson, Tord H Olsson & Göran Selvik
University Hospital of Lund and University of Lund, Lund, Sweden

To be published in Acta

K Lund & N Termansen
Odense Hospital, Odense, Denmark

To be published in Acta

PROSPECTIVE MULTICENTER STUDY OF KNEE ARTHROPLASTIES

Göran Bauer, Kaj Knutsson & Anders Lindstrand Lindstrand
University Hospital, Lund, Sweden

Thirty-five departments of orthopaedic surgery are participating in a prospective study of knee arthroplasties. Data are computerized and presented twice yearly. 1774 arthroplasties have been registered from October 1975 through March 1978. The incidence of deep infection, loosening, wear and fracture of the endoprosthesis in patients followed up for at least 1 year is shown here.

One third of the complications were due to deep infection and two thirds to endoprosthesis problems. Patient and surgeon were satisfied with the 1-year result in 78 per cent of the cases.

Diagnosis	*Prosthesis*	*No*	*No of complications*	*Prosthesis Reinserted*	*Prosthesis Removed*
Osteoarthrosis	Hinged	29	7	4	2
	Non hinged	23	3	1	–
	Double unicondylar	18	1	1	–
	Unicondylar	133	9	5	2
Rheumatoid arthritis	Hinged	56	8	2	2
	Non-hinged	58	4	1	1
	Double unicondylar	[illegible]	[illegible]	2	2
	Unicondylar	21	2	2	–
Total		420	40 (=10%)	18 (=4%)	9 (=2%

FUNCTIONAL STATUS AFTER MARMOR KNEE ARTHROPLASTY STUDIED BY MEANS OF ISOMETRIC MUSCLE STRENGTH MEASUREMENTS AND GAIT-ANGLE DIAGRAM TECHNIQUE

*A. Wigren, K. Kolstad, K. Öberg, L.-O. Nordesjö, P. Berg & L. Lamoreux**
University Hospital, Uppsala, Sweden and Berkley,* California

From amongst a large group of patients in whom arthroplasty of the knee had been performed, seven underwent a special gait analysis by means of an exoskeletal goniometric system where the gait was represented by an angle diagram depicting the movements of the hip and knee. The results were compared with a clinically adapted scoring system for pain, gait and mobility and with measurements of isometric muscle strength. The examinations were performed preoperatively and 8–12 months postoperatively. The gait-angle diagram illustrated well the operative results and corresponded with the clinical findings. The muscle strength in all knees was reduced by at least 75 per cent preoperatively in comparison with a normal material, and was still unchanged one year postoperatively in spite of the absence of pain, an increase in walking distance and mobility, and a marked improvement in gait as demonstrated by the objective gait analysis.

PRECAUTIONS AND INTENSIVE TREATMENT IN KNEE ARTHROPLASTY

Anders Wigren
University Hospital, Uppsala, Sweden

In a series of 100 Marmor knee arthroplasties 75 per cent were knees with rheumatoid arthritis. The same orthopaedic surgeon evaluated the patients preoperatively, and performed the arthroplasty. Preoperative examination of the respiratory and urinary tracts and the skin often led to treatment of manifest or latent infection before operation. The patients were nursed in a special clean ward. A strict operative routine was followed. The operation was performed in epidural anaesthesia in an ordinary operating theatre using antibiotic prophylaxis. Both compartments were replaced in 90 per cent of the arthroplasties. The wound was attended to by the orthopaedic surgeon. Prophylactic treatment against thrombosis consisted of active movements and elevation of the foot of the bed. All wounds healed primarily. Duration of hospitalization was about [illegible] weeks. There was no operative mortality and secondary operations for primary complications, no signs of deep venous thrombosis, no infection and no loosening of the prosthesis. The orthopaedic surgeon has been responsible for the ambulant care of the patients, and in the case of any urgent problems examination has been

performed without delay The length of the observation period is 6 months to 2¾ years.

PRIMARY COMPLICATIONS AFTER MARMOR RESURFACING ARTHROPLASTY

K Rechnagel
Frederiksborg County Hospital, Hillerød, Denmark

During 1976–77, 90 knee arthroplasties *ad modum* Marmor were performed Primary com- [illegible]

pain-free, and 3 have some pain In these three cases one of the hinge prostheses should have been used As a rule the mobility has not been increased, but in one case of rheumatoid arthritis an anchylotic knee gained a motion of 0/70 degrees.

The resurfacing technique is applicable even in elderly patients and in those in a poor physical condition. The complications seem to be of little significance as regards the end result, and revisions are possible should they be found necessary

ICLH ARTHROPLASTY OF THE KNEE JOINT RESULTS AND COMPLICATIONS

Gunnar B J Andersson & Peter Herberts
Sahlgren Hospital, Gothenburg, Sweden

Sixty-six knees operated on with the ICLH prosthesis have been followed prospectively at regular intervals for a period of from 1 to 5 years.

The results were good with respect to pain, which disappeared or was alleviated in all but six knees. The functional improvement was less dramatic largely due to the fact that other weight bearing joints were diseased in all but three patients.

The complications included two deep infections after revision, four cases of loosening, and three cases of instability and deformity All poor results were in patients with complications. All complications could be traced to inability to position the prosthesis accurately or correct the deformity at the time of the operation

CORRELATION BETWEEN POSITION OF DUOCONDYLAR PROSTHESIS AND FUNCTION OF THE KNEE JOINT

Ian F Goldie, Christina Raner & Jan Cappelen-Smith
Sahlgren Hospital and Östra Hospital Gothenburg, Sweden

Between 1972 and 1976, 51 knee joints in 40 patients have been reconstructed with the St. Georg sledge prosthesis The patients were followed up in May 1978 with regard to the clinical condition as well as the position of the prosthesis at radiological examination A comparison was made between the position of the prosthesis and the function of the knee joint Six patients (eight knee joints) had died Of the remaining 34 patients, 25 had satisfactory radiological examinations carried out The clinical impression was that a good relationship existed between the position of the prosthesis and the joint function, i.e. good position — good function The numerical evaluation as presented in a visual analogue disclosed, however, that surprisingly many knee joints without pain and with excellent function did not have as good a position of the prosthesis as was expected.

LATERAL DISLOCATION OF THE PATELLA FOLLOWING GUEPAR ALLOPLASTY OF THE KNEE

N Fredensborg, U Klaumann & O Sneppen
Rigshospitalet, Copenhagen, Denmark

To be published in Acta as part of

LATERAL DISLOCATION OF THE PATELLA FOLLOWING MARMOR AND GUEPAR ALLOPLASTY OF THE KNEE

O Sneppen, N Fredensborg, A Karle & U Klaumann

JOINT DEBRIDEMENT FOR OSTEOARTHRITIS OF THE KNEE

Olav Reikerås
Kronprinsesse Marthas Institutt, Oslo, Norway

Osteoarthritis of the knee with normal alignment, but with osteocartilaginous excrescences, has been treated by debridement of the joint Through a medial parapatellar arthrotomy all compartments of the knee are inspected, degenerated articular cartilage is shaved off, osteocartilaginous excrescences and torn menisci are removed and a limited synovectomy is done, if indicated

In the years 1967–1976 33 knees in 31 patients have been operated on The age ranged from 47–79 years, with a mean of 57 years. They have been followed up for from 1½–11 years, with a mean of 5 4 years. Assessment was made with regard to relief from pain and improvement in movement and function. The result was found to be good/satisfactory in 85 per cent and poor in 15 per cent We also found that a good result may be maintained over a prolonged period. We conclude that debridement of the joint is a reliable method of treatment for osteoarthritis of the knee if indicated

DIAGNOSIS OF DEEP INFECTIONS FOLLOWING TOTAL HIP REPLACEMENT

Åke Carlsson
Allmänna Hospital, Malmö, Sweden

Diagnostic difficulties in patients with delayed infection are usually only encountered where raised temperature and other more general symptoms of infection are lacking. Months or years after the operation pain on walking develops slowly, and pain can be induced by passive rotation of the hip.

Postoperatively, the erythrocyte sedimentation rate increases but returns in uncomplicated cases to the preoperative level within 3 months, whereas in patients who later on develop deep infection, the ESR, markedly increased already during the early postoperative period, never returns to normal. An ESR above 40 mm more than 3 months after the operation strongly indicates a deep infection in patients with osteoarthrosis. In rheumatoid disease the ESR is of little value and one must depend on other diagnostic means. It is recommended that the ESR should be included in the routine procedure of every patient visit after total joint replacement.

ANTIBIOTIC TREATMENT IN PATIENTS WITH INFECTED TOTAL HIP ARTHROPLASTY

Lars Lidgren
University Hospital, Lund, Sweden

Fifty patients with infected Charnley total hip arthroplasties have been treated with antibiotics without extracting the prosthesis. There were 47 periods of treatment with antibiotics for more than 3 months, and 48 periods without antibiotic treatment. The antibiotic treatment was able to greatly reduce the pain. The erythrocyte sedimentation rate was significantly lowered in the treated group compared with the group without antibiotic treatment. Roentgenological investigations were performed, without additional clinical information, and showed that the X-ray changes were not progressing in half of the periods with antibiotics compared with one sixth of the periods without antibiotics. In patients with infected total hip arthroplasty and advanced age or medical contraindication for reoperation, long-term antibiotic treatment can dampen the infection.

REOPERATION OF HIP ARTHROPLASTIES WITH GENTAMICIN CEMENT

Göran Josefsson, Lars Lindberg & Åke Carlsson
Gävle, Lund and Malmö, Sweden

One hundred and forty-two hip arthroplasties were reoperated upon because of suspected deep infection. Seventy-seven with confirmed deep infection were selected for analysis – 58 after direct exchange and 19 after a two-step exchange. Thirty-five have been followed up for more than 2 years. Sixty hips are classified as healed, 4 as doubtful and 13 as infected (4 have been reoperated on a second time). At present there is no demonstrable difference in results after direct exchange and after two-step exchange of the infected total hip prosthesis.

SPECIFIC PROPERTIES OF GENTAMICIN PALACOS R

R. Helmut Wahlig
Medical Research, Department of Chemotherapy
E. Merck, Darmstadt, W. Germany

Comparing different antibiotics and bone cements, Palacos R with gentamicin proved to be the most suitable as far as release of antibiotic is concerned. Leaching of gentamicin was observed for more than 5 years. In tissue samples from the vicinity of the implanted cement in patients, high concentrations (4–36 μg/g) were found for up to 3½ years.

The bacteriology of 77 deep infections in total hip arthroplasties was investigated with a special technique. Seventeen were caused by *Staph. epid.*, 13 by *Staph. aureus*, 7 by *Propionibacterium acnes*, 8 by different anaerobic cocci and 11 by other microbes. Twenty-one of the infections were caused by a mixed flora whereas anaerobes were found in 9 cases.

DIAGNOSIS AND TREATMENT OF INFECTED KNEE ARTHROPLASTIES

Jens Langer Andersen
Lund General Hospital, Lund, Sweden

In 71 knee arthroplasties with a hinge prosthesis (66 Guepar, 5 Shier) superficial infection or delayed wound healing developed after 15 of the operations, and deep infection was suspected in 21 cases. The diagnosis of deep infection has been confirmed by laboratory e-

vestigations, bacteriology and X-ray In cases of ontaneous fistulation and in cases with fast pro-ession of X-ray changes we have found in-cations for reoperation In seven cases the pros-esis has been removed and a new prosthesis serted using gentamycin bone cement One year ter reoperation two cases have become infected, and five are without signs of infection.

EMANDS ON RESOURCES AND COSTS IN HE HOSPITAL CARE OF SOME TYPICAL RTHOPAEDIC PATIENTS

urt Kolstad & Anders Wigren
iversity Hospital, Uppsala, Sweden

To be published in Acta.

RTHROSCOPY OF THE KNEE JOINT

dd Haerum
ounty Hospital, Kristiansand, Norway

A series of 123 patients with knee joint lesions been studied with the arthroscopy technique In the period from 1 2 77 to 1 6 77, 40 knee ints were examined There were 12 mis-terpretations (31 per cent) The second part of e material, which includes 83 knee joints, was amined in the period from 1 6 77 to 20 5 78 nly eight misinterpretations were made, a failure te of 10 5 per cent If we include 27 knee joints at were only arthroscopied and the findings garded as normal, the misinterpretation rate rops to 7 2 per cent

It is concluded that arthroscopy is a useful ol in the diagnosis of knee joint injuries and a afe method of diagnosing injuries of the menisci, nnecessary arthrotomies may be avoided and misinterpretation is significantly reduced with in-reasing experience with the arthroscopy tech-nique

At the Department of Orthopaedic Surgery, rthroscopy of 236 knee joints using the Dyonics Needlescope (standard model) has been performed An antero-lateral approach under general anaesthesia was routinely employed. No com-plications were observed. In assessing the value of arthroscopy, the clinical diagnosis, the arthroscopic findings and the findings in operation have been compared.

In 167 knees with primary indication for surgery, arthroscopy refuted the clinical diagnosis in 13 cases. Of the remaining 154 the clinical diagnosis was correct in 114 cases (74 per cent), whereas arthroscopy yielded 140 correct pre-operative diagnoses (91 per cent) In 69 knees without primary indication for surgery, arthro-scopy revealed 22 cases suitable for surgery (32 per cent), while in 47 cases the diagnosis was cor-rected, supplemented or confirmed.

INTRA-ARTICULAR SHAVING OF PATELLAR CHONDROMALACIA

Kari Aalto & Kaleri Österman
Helsinki University Central Hospital, and Orthopaedic Hospital of the Invalid Foundation, Helsinki, Finland

A new film of the indications for and the operative technique in the treatment of patellar chondromalacia using the Dyonics intra-articular patellar shaver is presented

ROENTGENOGRAPHIC DETERMINATION OF ROTATIONAL DISPLACEMENT IN FRACTURES OF THE FEMUR

Olof Norman
General Hospital, Lund, Sweden

The anteversion angle of the femoral neck can be used to elucidate the relationship between the proximal and distal parts of the femur Comparison with the healthy side will give the degree of rotation The method of measurement can be used also if the leg is fixed in traction or in plaster of Paris. In this measurement I have, in agreement with most authors, made use of the short femoral axis (D-O-A_1) but since the topographic anatomy is disarranged by a fracture, the calculation should be made with the aid of the long axis (K-O-A) according to the anatomical definition. This requires knowledge of the position of point 9 which, however, does not exist, as the

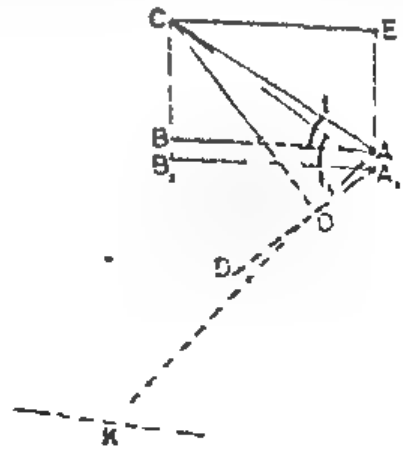

DIAGNOSIS OF DEEP INFECTIONS FOLLOWING TOTAL HIP REPLACEMENT

Åke Carlsson
Allmänna Hospital, Malmö, Sweden

Diagnostic difficulties in patients with delayed infection are usually only encountered where raised temperature and other more general symptoms of infection are lacking Months or years after the operation pain on walking develops slowly, and pain can be induced by passive rotation of the hip

Postoperatively, the erythrocyte sedimentation rate increases but returns in uncomplicated cases to the preoperative level within 3 months, whereas in patients who later on develop deep infection, the ESR, markedly increased already during the early postoperative period, never returns to normal An ESR above 40 mm more than 3 months after the operation strongly indicates a deep infection in patients with osteoarthrosis. In rheumatoid disease the ESR is of little value and one must depend on other diagnostic means It is recommended that the ESR should be included in the routine procedure of every patient visit after total joint replacement

ANTIBIOTIC TREATMENT IN PATIENTS WITH INFECTED TOTAL HIP ARTHROPLASTY

Lars Lidgren
University Hospital, Lund, Sweden

Fifty patients with infected Charnley total hip arthroplasties have been treated with antibiotics without extracting the prosthesis. There were 47 periods of treatment with antibiotics for more than 3 months, and 48 periods without antibiotic treatment The antibiotic treatment was able to greatly reduce the pain. The erythrocyte sedimentation rate was significantly lowered in the treated group compared with the group without antibiotic treatment. Roentgenological investigations were performed, without additional clinical information, and showed that the X-ray changes were not progressing in half of the periods with antibiotics compared with one sixth of the periods without antibiotics. In patients with infected total hip arthroplasty and advanced age or medical contraindication for reoperation, long-term antibiotic treatment can dampen the infection

REOPERATION OF HIP ARTHROPLASTIES WITH GENTAMICIN CEMENT

Göran Josefsson, Lars Lindberg & Åke Carlsson
Gävle, Lund and Malmo, Sweden

One hundred and forty-two hip arthroplasties were reoperated upon because of suspected deep infection Seventy-seven with confirmed deep infection were selected for analysis – 58 after direct exchange and 19 after a two-step exchange. Thirty-five have been followed up for more than 2 years Sixty hips are classified as healed 4 as doubtful and 13 as infected (4 have been reoperated on a second time) At present there is no demonstrable difference in results after direct exchange and after two-step exchange of the infected total hip prosthesis.

SPECIFIC PROPERTIES OF GENTAMICIN PALACOS R

R Helmut Wahlig
Medical Research, Department of Chemotherapy
E Merck, Darmstadt, W Germany

Comparing different antibiotics and bone cements, Palacos R with gentamicin proved to be the most suitable as far as release of antibiotic is concerned Leaching of gentamicin was observed for more than 5 years. In tissue samples from the vicinity of the implanted cement in patients high concentrations (4–36 μg/g) were found for up to 3½ years.

BACTERIAL FLORA IN INFECTED TOTAL HIP ARTHROPLASTIES

Lars Lindberg & Karl Kamme
General Hospital, Lund, Sweden

The bacteriology of 77 deep infections in total hip arthroplasties was investigated with a special technique Seventeen were caused by *Staph. epid* 13 by *Staph aureus*, 7 by *Propionibacterium acnes*, 8 by different anaerobic cocci and 11 by other microbes. Twenty-one of the infections were caused by a mixed flora whereas anaerobes were found in 9 cases.

DIAGNOSIS AND TREATMENT OF INFECTED KNEE ARTHROPLASTIES

Jens Langer Andersen
Lund General Hospital, Lund, Sweden

In 71 knee arthroplasties with a hinge joint prosthesis (66 Guepar, 5 Shier) superficial infection or delayed wound healing developed after 18 of the operations, and deep infection was suspected in 21 cases. The diagnosis of deep infection has been confirmed by laboratory in-

igations, bacteriology and X-ray In cases of itaneous fistulation and in cases with fast pro- sion of X-ray changes we have found in- tions for reoperation. In seven cases the pros- m has been removed and a new prosthesis rted using gentamycin bone cement. One year r reoperation two cases have become fected, and five are without signs of infection.

MANDS ON RESOURCES AND COSTS IN E HOSPITAL CARE OF SOME TYPICAL

o be published in Acta

THROSCOPY OF THE KNEE JOINT

I Haerum
nty Hospital, Kristiansand, Norway

H were examined There were 12 mis- rpretations (31 per cent) The second part of material, which includes 83 knee joints, was mined in the period from 1 6 77 to 20 5 78 y eight misinterpretations were made, a failure of 10 5 per cent. If we include 27 knee joints were only arthroscopied and the findings rded as normal, the misinterpretation rate ps to 7 2 per cent

t is concluded that arthroscopy is a useful l in the diagnosis of knee joint injuries and a method of diagnosing injuries of the menisci, necessary arthrotomies may be avoided and interpretation is significantly reduced with in- asing experience with the arthroscopy tech- ue.

At the Department of Orthopaedic Surgery, hroscopy of 236 knee joints using the Dyonics edlescope (standard model) has been performed antero-lateral approach under general esthesia was routinely employed. No com- cations were observed. In assessing the value arthroscopy the clinical diagnosis, the hroscopic findings and the findings at operation re been compared

In 167 knees with primary indication for rgery, arthroscopy refuted the clinical diagnosis 13 cases. Of the remaining 154, the clinical diagnosis was correct in 114 cases (74 per cent), whereas arthroscopy yielded 140 correct pre- operative diagnoses (91 per cent) In 69 knees without primary indication for surgery, arthro- scopy revealed 22 cases suitable for surgery (32 per cent), while in 47 cases the diagnosis was cor- rected, supplemented or confirmed

pital, and
Orthopaedic Hospital of the Invalid Foundation, Helsinki, Finland

A new film of the indications for and the operative technique in the treatment of patellar chondromalacia using the Dyonics intra-articular patellar shaver is presented

Olof Norman
General Hospital, Lund, Sweden

The anteversion angle of the femoral neck can be used to elucidate the relationship between the proximal and distal parts of the femur Comparison with the healthy side will give the degree of rotation The method of measurement can be used also if the leg is fixed in traction or in plaster of Paris. In this measurement I have, in agreement with most authors, made use of the short femoral axis (D-O-A_1) but since the

of point 9 which, however, does not exist, as the

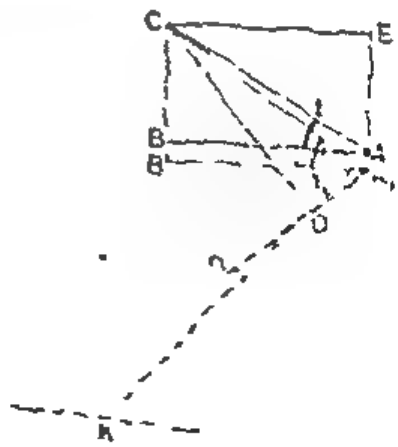

DIAGNOSIS OF DEEP INFECTIONS FOLLOWING TOTAL HIP REPLACEMENT

Åke Carlsson
Allmanna Hospital, Malmo, Sweden

Diagnostic difficulties in patients with delayed infection are usually only encountered where raised temperature and other more general symptoms of infection are lacking Months or years after the operation pain on walking develops slowly, and pain can be induced by passive rotation of the hip.

Postoperatively, the erythrocyte sedimentation rate increases but returns in uncomplicated cases to the preoperative level within 3 months, whereas in patients who later on develop deep infection, the ESR, markedly increased already during the early postoperative period, never returns to normal An ESR above 40 mm more than 3 months after the operation strongly indicates a deep infection in patients with osteoarthrosis. In rheumatoid disease the ESR is of little value and one must depend on other diagnostic means. It is recommended that the ESR should be included in the routine procedure of every patient visit after total joint replacement.

ANTIBIOTIC TREATMENT IN PATIENTS WITH INFECTED TOTAL HIP ARTHROPLASTY

Lars Lidgren
University Hospital, Lund, Sweden

Fifty patients with infected Charnley total hip arthroplasties have been treated with antibiotics without extracting the prosthesis. There were 47 periods of treatment with antibiotics for more than 3 months, and 48 periods without antibiotic treatment. The antibiotic treatment was able to greatly reduce the pain. The erythrocyte sedimentation rate was significantly lowered in the treated group compared with the group without antibiotic treatment. Roentgenological investigations were performed, without additional clinical information, and showed that the X-ray changes were not progressing in half of the periods with antibiotics compared with one sixth of the periods without antibiotics. In patients with infected total hip arthroplasty and advanced age or medical contraindication for reoperation long-term antibiotic treatment can dampen the infection

REOPERATION OF HIP ARTHROPLASTI WITH GENTAMICIN CEMENT

Göran Josefsson, Lars Lindberg & Åke Carls
Gavle, Lund and Malmo, Sweden

One hundred and forty two hip arthropla were reoperated upon because of suspected infection Seventy seven with confirmed infection were selected for analysis – 58 direct exchange and 19 after a two-step excha Thirty five have been followed up for more th years Sixty hips are classified as healed, doubtful and 13 as infected (4 have reoperated on a second time) At present the no demonstrable difference in results after di exchange and after two-step exchange of infected total hip prosthesis

SPECIFIC PROPERTIES OF GENTAMICI PALACOS R

R Helmut Wahlig
Medical Research Department of Chemother E Merck Darmstadt, W Germany

Comparing different antibiotics and b cements, Palacos R with gentamicin proved to the most suitable as far as release of antibioti concerned Leaching of gentamicin was obser for more than 5 years. In tissue samples from vicinity of the implanted cement in patients, h concentrations (4–36 μg/g) were found for up 3½ years.

BACTERIAL FLORA IN INFECTED TOTA HIP ARTHROPLASTIES

Lars Lindberg & Karl Kamme
General Hospital, Lund Sweden

The bacteriology of 77 deep infections in to hip arthroplasties was investigated with a spec technique Seventeen were caused by *Staph. ep* 13 by *Staph aureus*, 7 by *Propionibacteri acnes*, 8 by different anaerobic cocci and 11 other microbes. Twenty-one of the infections w caused by a mixed flora whereas anaerobes w found in 9 cases.

DIAGNOSIS AND TREATMENT OF INFECTED KNEE ARTHROPLASTIES

Jens Langer Andersen
Lund General Hospital, Lund, Sweden

In 71 knee arthroplasties with a hinge jo prosthesis (66 Guepar, 5 Shier) superfic infection or delayed wound healing developed af 15 of the operations, and deep infection w suspected in 21 cases. The diagnosis of de infection has been confirmed by laboratory

classification there were 24 cases of type I, 44 cases of type II, 44 cases of type III, and 27 cases of type IV One fracture in four was open Four primary nerve injuries were noted Eighty patients were treated conservatively and 78 operatively Sixteen patients had signs of postoperative infection and 9 cases of pseudarthrosis were noted

SUPRACONDYLAR FRACTURES OF THE HUMERUS IN CHILDREN A LONG-TERM FOLLOW-UP STUDY OF 107 CASES

Veijo Vahvanen & Kari Aalto
Aurora Children's Hospital, Helsinki, Finland

Published in Acta (*Acta orthop scand* 49, 225–233, 1978)

LATE RESULTS AFTER SEVERELY DISPLACED SUPRACONDYLAR FRACTURES OF THE HUMERUS VERTICAL EXTENSION VERSUS CLOSED REDUCTION

Jens Lund-Kristensen & Ole Vibild
Copenhagen Municipal Hospital, Bispebjerg, Denmark

Out of 43 children with grossly displaced supracondylar fractures of the humerus, 23 were treated with vertical extension using a Kirschner wire, 17 with manipulative reduction and plaster and 3 were operated on The functional results were equal in the first two groups As regards varus deformity the results were better after vertical extension than after closed reduction

SUPRACONDYLAR FRACTURES OF THE HUMERUS

H Hansen & A Andersen
Aalborg Hospital, Denmark

In the 5-year period 1972–1976, 45 children aged 4–12 years were treated for supracondylar fractures of the humerus at the Orthopaedic Department, Aalborg Hospital Forty three were followed up in 1978 Of these, 20 had been treated with manual reduction and plaster cast, 17 with olecranon traction and 6 with open reduction and pinning

Olecranon traction gave satisfactory results, better than those after manual reduction and plaster cast (especially in cases with marked dislocation) and equal to open reduction and pinning The functional results were good.

There were a few cases with pronounced varus (>10°) at the elbow There were no cases of Volkmann' contracture and no permanent nerve damage

NEUROLOGICAL EXAMINATION IN SUPRACONDYLAR FRACTURES OF THE HUMERUS

Thomas Dolk, Urban James & Hallbus S Mattsson
Regional Hospital, Örebro, Sweden

In a series of 96 patients with supracondylar fracture of the humerus, 10 obvious nerve injuries occurred (five medianus, four radialis and one Volkmann) Only two of these were diagnosed before treatment Two were observed after open reduction and six during traction

Primary neurological findings were normal in 46 but were not stated in 39 records A suspected but transient nerve lesion was often associated with circulatory insufficiency It was thus often difficult to tell if a neurological deficit was due to trauma or treatment

"MY HAND" – a minimal hand neurological examination – now used in our treatment programme for supracondylar fractures indicates spontaneous hand position, distribution of sweat secretion, sensibility of digital pulpa of index and little fingers, ability to close the hand and ability to spread the fingers. Adequate primary hand neurological examination is too often neglected We recommend 'My Hand" as a simple screening test in all upper limb injuries.

SUPRACONDYLAR FRACTURES OF THE HUMERUS IN CHILDREN

Kjell Bertheussen & Jens Kramhøft
Frederiksborg County Hospital, Hillerød, Denmark

Thirty-nine children were treated for severely dislocated supracondylar fracture of the humerus, In 30 cases vertical traction with an AO or Ormandy screw in the olecranon was used The fracture was reduced under general anaesthesia and retained with vertical traction and soft tissue lateral traction on the humerus Traction was maintained for 2–3 weeks, thereafter a plaster splint was applied for 1–2 weeks. Five patients needed more than one reposition, in two cases the traction was removed after a few days and a plaster used Five patients primarily had no palpable pulse distally and one showed signs of temporary nerve damage Four patients demonstrated radial nerve palsy after the reposition, all with total remission No other complications were observed We find this to be a safe and satisfactory method of treatment for this difficult fracture

OPEN REDUCTION OF SUPRACONDYLAR FRACTURES OF THE HUMERUS IN CHILDREN

Børge Krebs
Svenborg, Denmark

Twenty-three children were operated on because of supracondylar fracture of the humerus The operative procedure was in all cases open reduction and fixation with Kirschner wires The children were aged between 4 and 13 years at the time of operation Twelve patients were operated upon immediately and 11 after an average of 5 days. Mean observation time was 51 months

The patients were examined and evaluated according to the classification described by Flynn et al (1974) In 16 children the result was "excellent", in six "good" and in one "not acceptable" In two cases there were minor postoperative complications but there were no serious complications

SURGICAL AND CONSERVATIVE TREATMENT OF SUPRACONDYLAR FRACTURES OF THE HUMERUS IN CHILDREN

P Ottsen & J Evaldsen
Århus County Hospital, Århus, Denmark

During the period 1967–1977, 107 children were treated for dislocated supracondylar fracture of the humerus, and 80 of these patients (75 per cent) were seen at a follow-up examination Average observation time was 5½ years. Thirty patients were treated by open reduction and osteosynthesis (pinning with two crossed K-wires) In 50 patients closed reduction was carried out, in 29 with additional traction from the olecranon At the follow-up one operated and five conservatively treated patients had valgus or varus angulation of more than 10° Only four patients had limitation of elbow movement of more than 10° The radiographs showed accelerated bone maturity and bone growth in both groups No epiphysiodesis was found There was no significant difference concerning angulation and/or elbow movement in the conservatively versus operatively treated groups. No complications due to open reduction and fixation were found

It is concluded that osteosynthesis is a safe way of handling this fracture The average period of hospitalization was reduced from several weeks to a few days.

CAPUT FIXED SLIDING NAIL FOR TREATING EPIPHYSIOLYSIS CAPITIS FEMORIS

Lars Ingvar Hansson, Gunnar Ordeberg, A
Stenstrom & Karl-Goran Thorngren
University Hospital, Lund, Sweden

Various types of nails, screws, pins and
pegs have been used in treating epiphysio
capitis femoris They have caused peroper
complications, increased faulty position of c
femoris, and postoperative complications
resorption around the osteosynthesis material
growth in length of collum femoris This in
instances, has resulted in a new dislocatio
caput femoris. Early closure of the growth
has also been recorded

Since 1975, a new type of sliding nail (mod
Rydell nail) has been used in 25 cases (49 h
with epiphysiolysis capitis femoris The nai
placed in a drilled hole and fixed in caput femo
In four cases of acute slipping repositioning
complete before osteosynthesis In one case wi
faulty position, wedge osteotomy was perform
at the same time in collum femoris Postoperat
examinations have shown the nail to be drawn
in relation to the femur diaphysis owing
continued growth in length of collum femo
This indicates intact circulation in caput femo
After wedge osteotomy in collum femoris,
avascular necrosis developed, and no gro
ensued. Two cases showed a wide resorption
around the nail, but normal growth of coll
femoris In two cases, the nails were extrac
with a special instrument after growth had cea

GROWTH

Lars Ingvar Hansson, Stefan Arnonsson, Bi
Bylander & Göran Selvik
General Hospital and Lund University Lu
Sweden

If the growth region in children is fractured
primary diagnosis and treatment is important,
is also continued examination with regard
growth disturbance that could result in anisome
or faulty angulation Recent studies have show
difficulties in using Salter's classification for
demonstration of possible growth disturba
after a fracture through the growth region.

A prospective study determined the growth co
ditions after a fracture through the growth regio
using the rontgen stereophotogrammetric metho
Tantalum balls were implanted in the metaphys
and the bone epiphysis on both the fractured
and the healthy side The growth pattern

determined in six cases with fracture, in the distal femur [illegible]
with [illegible]
(I–IV [illegible]
turbance was demonstrated, with cessation of growth rate in three and obvious asymmetrical growth in three

This study shows that a growth disturbance can be demonstrated during the first months after the accident The degree of growth disturbance [illegible]

troduction of early surgical treatment

HEALING OF LARGE SURGICAL DEFECTS OF THE EPIPHYSEAL PLATE AN EXPERIMENTAL STUDY

Kalevi Osterman
Orthopaedic Hospital of the Invalid Foundation, Helsinki, Finland

Growth capacity and regeneration of the epiphyseal plate was studied by creating a large defect in the central part of the distal epiphyseal plate of the rabbit femur A bone bridge was prevented by using a free fat tissue transplant to fill the surgical defect The results, which were recorded by X-ray, tetracycline labelling and histology, show that most of the longitudinal growth of the bone can be preserved if bone bridge formation between the epiphysis and metaphysis is prevented Regeneration of the growth plate is observed as well

The results are in accordance with earlier experimental studies and clinical observations and support the view that removal of large bone bridges between the epiphysis and the metaphysis in young patients can restore a considerable amount of the longitudinal growth of a tubular bone

TREATMENT OF DEFORMITIES IN EPIPHYSEAL INJURIES

Kalevi Österman
Orthopaedic Hospital of the Invalid Foundation, Helsinki, Finland

Deformities caused by epiphyseal injuries depend on the site and size of the epiphyseo-metaphyseal bone bridge that typically can provoke progressive angulation or shortening Deformities of the articular surface and asymmetric growth of parallel bones must also be considered.

Operative treatment is suggested as follows Removal of the bone bridge is the method of choice in cases of progressive deformity Repeated corrective osteotomies, epiphyseodesis of the opposite side and lengthening or shortening procedures are needed as supplementary treatment An observation period of 2–4 years after epiphyseal injuries is recommended

[illegible]

S Ryöppy
Children's Hospital, University of Helsinki, Finland

A knowledge of the structure and nutrition of the growth plate is of primary importance both in planning treatment and in evaluating the risk of growth disturbances. Germinal cells, which are responsible for longitudinal growth, are supplied with blood via vessels from the epiphyseal side These vessels are vulnerable in intraarticular epiphyses even in the case of simple epiphyseal separation The zone with hypertrophied cartilage cells contains relatively little matrix, making it the weakest point in the plate. The separation caused by shearing or avulsion takes place almost invariably through this plane Splitting and crushing may cause a fracture through the plate or crushing of the cartilage cells. The risk of growth disturbances and the requirements as regards the precision of the reduction depend on the type of injury The Salter-Harris classification, based on the pathology of growth plate injuries, has proved the most practical for general use

MECHANISMS IN SPONTANEOUS CORRECTION OF ANGULAR DEFORMITIES FOLLOWING FRACTURES IN CHILDREN

S Ryoppy
Children's Hospital, University of Helsinki, Finland

The remodelling of post-traumatic deformities during growth is controlled by the same factors which determine the final shape of the skeleton Extrinsic factors include gravity, acceleration and deceleration forces and forces due to the action of muscles.

Local resorption and apposition of bone in the region of the fracture has generally been considered the most important factor in the correction of angular deformities. Relatively small forces can modify epiphyseal growth The general principle of correction is that the plane of the epiphyseal plate aligns perpendicularly to the resultant of the compressive forces. This alignment is caused by alteration of the direction of growth. In angular deformities an asymmetric

stimulation of growth can be demonstrated Recent studies have shown that this process is of primary importance in the correction of angular deformities in bones exposed to compressive forces.

Because several questions concerning the remodelling process in different situations are still open, only rough predictions for expected corrections can be made in clinical practice

GROWTH REMODELLING OF FEMORAL SHAFT FRACTURES

A Alho, T S Raugstad & K Hvidsten
Haukeland Hospital, University of Bergen, Bergen, Norway

The following conclusions are drawn on the basis of previous reports and our own preliminary results. *Ad latus* dislocation has no clinical importance Axial dislocations of less than 15–20° are remodelled satisfactorily, sagittal deformities more so than frontal ones and varus more than valgus Coxa valga and coxa vara also tend, to some degree, to correct themselves. Due to stimulation resulting in overgrowth, a shortening of 1 to 2 cm is acceptable Extensive trauma, instability, repeated reductions, and operation stimulate the overgrowth Reports concerning the spontaneous correction of rotary deformities are scanty due to technical difficulties, but seem to indicate that some remodelling takes place Our own preliminary results using the Dunlap-Rippstein method of measuring the CCD and angle show that the problem can, to a considerable degree, be eliminated by careful positioning of the fracture

DIPHOSPHONATE (EHDP) COMBINED WITH SURGICAL REMOVAL OF ECTOPIC BONE IN MYOSITIS OSSIFICANS PROGRESSIVA

Tor Hierton, Holm Holmsen & Sverker Ljunghall
University Hospital, Uppsala, Sweden

Published in Acta (*Acta orthop scand* 50, 33–38, 1979)

EFFECT OF MSH ON GROWTH AND REMODELLING OF LONG BONES

K-G Thorngren, L I Hansson & A Stenström
University Hospital, Lund, Sweden

Melanocyte stimulating hormone (MSH) from the pituitary has previously not been shown to exert any physiological effects in mammals. The effect of MSH on longitudinal bone growth and remodelling has not been investigated previously During studies of the effect of hypophyseal hormones in regulation of skeletal growth and remodelling, MSH has now been found to influence bone tissue The cortical bone remodelling along the femur diaphysis was studied both in normal, hypophysectomized and hormone-treated hypophysectomized rats In normal rats a low periosteal and endosteal apposition was found. In hypophysectomized rats there was an increased periosteal resorption and an increased endosteal apposition Administration of α-MSH to hypophysectomized animals decreased the periosteal resorption, but had no effect on the endosteal apposition Administration of growth hormone (GH) to hypophysectomized rats decreased the periosteal resorption to the same degree as MSH The endosteal apposition was not changed Thyroxine in low doses resulted in some decrease in the periosteal resorption, but in higher doses thyroxine instead increased the resorption, and increased the effect of hypophysectomy Endosteally no effect was found Adrenocorticotrophic hormone (ACTH) did not influence the periosteal resorption and had only a minor effect endosteally α-MSH did not influence the longitudinal bone growth in hypophysectomized rats, whereas GH and thyroxine stimulated the longitudinal bone growth. Thus, MSH was found to have a growth hormone-like effect on cortical bone remodelling but no influence on the longitudinal bone growth in hypophysectomized rats. Further investigations are in progress These results might lead to a synthetic bone stimulating substance for clinical use

SECRETION OF CALCITONIN IN RELATION TO TRAUMA

Arne Ekeland & Kaare M Gautvik
Rikshospitalet, Oslo, Norway

Specimens of a thyroid medullary carcinoma (MCT) were transplanted beneath the kidney capsule in young Wag/Rij rats The concentration of calcitonin (CT) in plasma collected during the operation was significantly higher ($2\alpha < 0.05$) than in the controls (Figure 1) As MCT produces CT the transfer of the tumour tissue may be the source of the increased plasma CT However another explanation may be that the surgical trauma causes this rise in plasma CT

In order to test this possibility, a standardized mid-diaphyseal femoral fracture was made in adult Wag/Rij rats Twenty five minutes after the fracture, CT in plasma was significantly higher [illegible] collected before the [illegible]

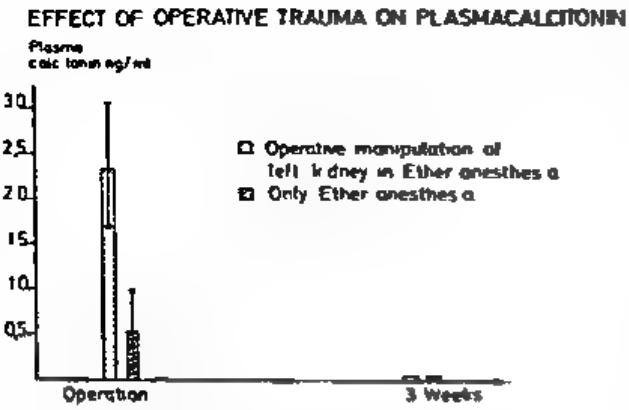

Figure 1 Median with 25 and 75 percentiles in seven operated rats and five controls After 3 weeks, CT < 0 05 ng/ml in both groups

CT, femoral fractures did not change the plasma concentration of the hormone

In conclusion, plasma concentration of CT increases following trauma in normal rats.

EFFECTS OF OXYTETRACYCLINE ON THE MECHANICAL PROPERTIES OF BONE AND SKIN IN YOUNG RATS

Lars B Engesaeter
Rikshospitalet, Oslo, Norway

Published in Acta (*Acta orthop scand* 49, 529–534, 1978)

[illegible]

Flemming Jørgensen & Erik Hørlyck
Orthopaedic Hospital, Århus, Denmark

At the Orthopaedic Hospital in Århus, in the period from 1948 to 1972, open reposition of 159 hips with late diagnosis congenital hip dislocation was performed There were 129 patients, 30 of whom were operated bilaterally Eighty nine per cent of the patients were girls.

The surgical procedure comprised capsuloplasty, after removal of obstructing substances in the acetabulum Subtrochanteric derotation osteotomy was performed at the same operation in cases of anteversion of more than 40 degrees.

Re-examination of 88 patients showed excellent X ray results in 67 per cent of the cases (Severin's groups I and II). Arthrotic changes occurred in 32 per cent Ninety per cent had normal or slightly reduced activity, 75 per cent had no substantial pain and almost normal mobility Increasing hip disability is, however to be expected with increasing age

STANDARDIZED TEMPORARY PROSTHESIS WITH TOTAL CONTACT SOCKET FOR BELOW-KNEE AMPUTEES

Bjorn M Persson
General Hospital, Lund, Sweden

Immediate fitting of geriatric patients after amputation has now been replaced by early fitting in most clinics. The tulip limb is constructed to be a one-size ready made device with a total contact socket for early training and testing, which can be carried out by the physiotherapists. The total contact socket is achieved by evacuation of air from a plastic bag, containing plastic balls, which has been wrapped around the stump after removal of the plaster shell [illegible] weeks after the the amputation The first clinical series with this so-called Tulip limb (Lic, Sweden) comprises 30 patients who used the limb for 12 days The device was found to be well tolerated.

THE UNNA PASTE BANDAGE AFTER AMPUTATION

Tor Hierton
Academic Hospital, Uppsala, Sweden

In the treatment of chronic leg ulcers the Unna Paste Bandage is well known However, its use after amputation surgery seems to be new My interest in the method was directed by Ghulamila (Albany Medical Center, New York) in 1973 I have used it for almost 5 years after lower limb amputations and would like to recommend that it be used routinely It is a light and flexible but inextensible dressing which prevents oedema and maintains the stump shape. When used for early prosthetic fitting it acts as an inner liner for the temporary plaster or plastic socket to which a pylon is attached In this respect the semi rigid dressing has many advantages not found in the plaster technique of IPOPF

ORTHOPAEDIC REHABILITATION AFTER OPEN FEMORAL FRACTURE AND ARTERIAL INJURY

Film (16 mm English text)

T Hierton, A Wigren & L. Marsh
University Hospital, Uppsala, Sweden

Primary treatment after a gun shot injury was successful as far as saving the limb was concerned. However, malunion with varus deformity, shortening, loss of sensation distally and restricted foot mobility caused permanent disability Functional improvement was obtained after BK amputation, semi-rigid postoperative dressing with Unna Paste Bandage and early fitting with a PTB prosthesis

The film shows the effectiveness of the Unna Paste Bandage in maintaining the shape of the stump and preventing oedema From a biomechanical point of view it was necessary to align the prosthetic shank in valgus This allowed the patient when walking to use an ordinary angle of adduction in his hip joint

TIBIAL OSTEOSYNTHESIS WITH THE LANE PLATE AND WITH AO COMPRESSION OSTEOSYNTHESIS A COMPARISON

Jacob H Kjaer, Esben Møller, Ove Rasmussen & Claus Kromann-Andersen
Århus Community Hospital and Odense Hospital Denmark

One hundred and seventy seven tibial fractures osteosynthesized with Lane plates and 116 tibial fractures treated with AO compression osteosynthesis were compared with regard to complications and healing

There were no definite differences between the two groups as regards primary wound infections whereas there was a two to three times higher frequency of osteitis in the AO group The frequency of skin necrosis was the same in both groups and there was no marked difference between the two groups as regards healing A somewhat higher frequency of refractures was found in the Lane group

ANTIBIOTIC PROPHYLAXIS IN COMPOUND AND CLOSED FRACTURES A CONTROLLED STUDY

Bo R Bergman
Östra Hospital, Gothenburg, Sweden

To be published in Acta

THE FREQUENCY OF OSSEOUS COMPLICATIONS IN TIBIAL SHAFT FRACTURES TREATED BY INTERNAL COMPRESSION OSTEOSYNTHESIS

K D Kristensen
Hjørring Hospital, Hjørring Denmark

Ninety-two tibial shaft fractures in 90 patients over the age of 15 were treated by compression osteosynthesis according to the AO method, but using plates and screws of vitallium Fifteen fractures (14 patients) are excluded, because they have not been followed at least 12 months The frequencies of osseous complications in the remaining 77 fractures, 39 per cent comminuted and 30 per cent open fractures were

Osteitis	1
Delayed osseous healing necessitating secondary operation	2
Loosening of screw (no secondary operation)	5
Loosened screw + refracture	1
Bent plate	1
Plate fractures	1
Refracture after removal of plate (new relevant traumas)	4

OSTEOGENIC ACTIVITY OF FREE PERIOSTEAL AND OSTEOPERIOSTEAL GRAFTS AND THEIR USE IN THE TREATMENT OF INFECTED PSEUDARTHROSES OF LONG BONES

V Ritsila, M Poussa & L-E Laurent
Orthopaedic Hospital of the Invalid Foundat
Helsinki, Finland

Earlier studies have shown that free perios grafts from the tibia transplanted into muscle rabbits and employed in fusion of scoliotic sp have a strong osteogenic capacity Experie revealed that osteoperiosteal grafts were m easily handled than bare periosteal grafts. The fore the effect of the cortical bone attached to periosteum was evaluated Experimentally it found that in 6-week-old rabbits periosteum al and 100 μ thick osteoperiosteum had almost eq osteogenic properties, whereas 200 μ thick ost periosteum was inferior to both

In humans a thin osteoperiosteal graft from healthy tibia was transplanted into 15 infec pseudarthroses of the contralateral femur lower leg At the same time reconstruction of soft tissue defects was performed Immobilizat in plaster was continued until consolidation established, in the majority of cases within 2 months

RELIEF OF SUDECK'S POSTTRAUMATIC SYNDROME BY FASCIOTOMY

Einar Sudmann
University of Tromsø, Tromsø, Norway

Distal fasciotomy on the volar aspect of t forearm or the ventral aspect of the lower leg gr rapid relief from pain at rest in eight out of n patients operated on These eight patients became symptom-free except one, in whom t normal function of a preoperatively stiff ha could only partly be restored. In contrast two o of three patients treated with physiotherapy alo ended up with a painful paretic leg and a usel stiff and painful hand

On the basis of clinical observations of 12 co secutive patients it is suggested that the fer

retinacula of the wrist and the extensor retinaculum of the lower leg may constitute a pathogenic factor in Sudeck's posttraumatic syndrome of the hand or foot

OSTEOSYNTHESIS OF [illegible] E OF THE [illegible]

[illegible] sen, Torben Johansen & Leif Thuesen
Central Hospital, Nykøbing F, Denmark

To be published in Acta

PHYSIOLOGICAL WEIGHT RELIEF DURING THE TIME BEFORE FRACTURE UNION FOLLOWING INTERNAL FIXATION OF UNSTABLE TROCHANTERIC FRACTURES

J Steen Jensen & Erik Jansen
Gentofte Hospital, Hellerup, Denmark

To be published in Acta.

[illegible] ACTURES [illegible]

Published in Acta (*Acta orthop scand* 50, 161–168, 1979)

THE SOCIAL PROGNOSIS AND THE CONSUMPTION OF RESOURCES FOLLOWING HIP FRACTURES

J Steen Jensen, Erik Tendeiold & P Hove Sørensen
Gentofte Hospital, Hellerup and Frederiksborg County Hospital, Hillerød, Denmark

To be published in Acta.

DISTAL FEMORAL FRACTURES AN 8-YEAR STUDY

Lars Kolmert & Krister Wulff
University Hospitals, Malmo and Lund, Sweden

One hundred and thirty-five patients with 137 fractures were treated in the period 1969–1976 Pathological and osteochondral fractures and fractures in children were excluded The frequency study showed one peak in the age group 16–25 years, usually involving violent trauma, another peak was seen in the age group 66–75 years where many had osteoporosis Classification into supracondylar (extra articular) biocondylar and unicondylar fractures was made A fall at ground level was the cause in 88 and traffic accidents in 30 patients. Sixty five per cent had predisposing local or general osteoporosis (earlier fracture, gonarthrosis or coxarthrosis, ethylism, epilepsy, hemiplegia, polio etc)

Eighty-nine were conservatively and 48 surgically treated Angle plates, rushpins and screws [illegible] gave good results in young patients with normal bone The other methods needed supplementary external stabilization with traction or plaster

The results were graded according to pain, mobility, limp and diminished limb length Excellent and good results were obtained in 65 per cent both in the operated and the conservatively treated groups. Indications differ however

FRACTURES OF THE CALCANEUM

P Slatis, O Kiviluoto, S Santavirta & E Laasonen
Surgical Hospital, Helsinki, Finland

Sixty-seven patients with 86 fractures of the calcaneum were re-examined 2 to 5 years after the accident Forty seven patients had multiple injuries. Mean age was 39 years and men outnumbered women by 3 1 The posterior subtalar joint of the calcaneum was involved in 73, with dislocation and/or comminution in 63, ten fractures were compound. The fractures of the calcaneum were treated predominantly by support, elevation and exercises, or by reposition of the fracture with a Steinmann pin and incorporation in plaster At follow-up, only 28 patients were symptom-free Ten patients had subsequently been treated with a subtalar or triple arthrodesis, only one of which was entirely painless with a good functional result. Analysis of the series revealed that the functional result corresponded with the severity of comminution and the depression of the posterior subtalar joint, that functional treatment gives slightly better results than immobilization in plaster, that attempts to reduce the depressed fracture with a Steinmann pin usually fail, and that painful abutment of the peroneal tendons is frequent, especially in fractures with a depressed subtalar joint.

RUPTURE OF THE LATERAL LIGAMENTS OF THE ANKLE. A CONTROLLED CLINICAL TRIAL

Tore Grønmark, Odd Johnsen & Odd Kogstad
Telemark Central Hospital, Skien, Norway

To be published in Acta.

The film shows the effectiveness of the Unna Paste Bandage in maintaining the shape of the stump and preventing oedema From a biomechanical point of view it was necessary to align the prosthetic shank in valgus. This allowed the patient when walking to use an ordinary angle of adduction in his hip joint

TIBIAL OSTEOSYNTHESIS WITH THE LANE PLATE AND WITH AO COMPRESSION OSTEOSYNTHESIS A COMPARISON

Jacob H Kjaer, Esben Møller, Ove Rasmussen & Claus Kromann-Andersen
Århus Community Hospital and Odense Hospital, Denmark

One hundred and seventy-seven tibial fractures osteosynthesized with Lane plates and 116 tibial fractures treated with AO compression osteosynthesis were compared with regard to complications and healing

There were no definite differences between the two groups as regards primary wound infections whereas there was a two to three times higher frequency of osteitis in the AO group The frequency of skin necrosis was the same in both groups and there was no marked difference between the two groups as regards healing A somewhat higher frequency of refractures was found in the Lane group

ANTIBIOTIC PROPHYLAXIS IN COMPOUND AND CLOSED FRACTURES A CONTROLLED STUDY

Bo R Bergman
Ostra Hospital, Gothenburg, Sweden

To be published in Acta

THE FREQUENCY OF OSSEOUS COMPLICATIONS IN TIBIAL SHAFT FRACTURES TREATED BY INTERNAL COMPRESSION OSTEOSYNTHESIS

K D Kristensen
Hjørring Hospital, Hjørring, Denmark

Ninety-two tibial shaft fractures in 90 patients over the age of 15 were treated by compression osteosynthesis according to the AO method, but using plates and screws of vitallium. Fifteen fractures (14 patients) are excluded, because they have not been followed at least 12 months. The frequencies of osseous complications in the remaining 77 fractures, 39 per cent comminuted and 30 per cent open fractures, were

Osteitis	1.3
Delayed osseous healing necessitating secondary operation	2.6%
Loosening of screw (no secondary operation)	5.2%
Loosened screw + refracture	1.3%
Bent plate	1.3%
Plate fractures	1.3%
Refracture after removal of plate (new relevant traumas)	4.8%

OSTEOGENIC ACTIVITY OF FREE PERIOSTEAL AND OSTEOPERIOSTEAL GRAFTS AND THEIR USE IN THE TREATMENT OF INFECTED PSEUDARTHROSES OF LONG BONES

V. Ritsilä, M Poussa & L-E Laurent
Orthopaedic Hospital of the Invalid Foundation Helsinki, Finland

Earlier studies have shown that free periosteal grafts from the tibia transplanted into muscle in rabbits and employed in fusion of scoliotic spines have a strong osteogenic capacity Experience revealed that osteoperiosteal grafts were more easily handled than bare periosteal grafts. Therefore the effect of the cortical bone attached to the periosteum was evaluated Experimentally it was found that in 6-week-old rabbits periosteum alone and 100 μ thick osteoperiosteum had almost equal osteogenic properties whereas 200 μ thick osteoperiosteum was inferior to both.

In humans a thin osteoperiosteal graft from the healthy tibia was transplanted into 15 infected pseudarthroses of the contralateral femur and lower leg At the same time reconstruction of the soft tissue defects was performed Immobilization in plaster was continued until consolidation was established, in the majority of cases within 2 months

RELIEF OF SUDECK'S POSTTRAUMATIC SYNDROME BY FASCIOTOMY

Einar Sudmann
University of Tromsø, Tromsø, Norway

Distal fasciotomy on the volar aspect of the forearm or the ventral aspect of the lower leg gave rapid relief from pain at rest in eight out of nine patients operated on These eight patients all became symptom-free except one, in whom the normal function of a preoperatively stiff hand could only partly be restored. In contrast two out of three patients treated with physiotherapy alone ended up with a painful paretic leg and a useless stiff and painful hand

On the basis of clinical observations of 12 consecutive patients it is suggested that the fibro

retinacula of the wrist and the extensor retinaculum of the lower leg may constitute a pathogenic factor in Sudeck's posttraumatic syndrome of the hand or foot

OSTEOSYNTHESIS OR [illegible] OF THE [illegible]

Torben [illegible]
Central Hospital, Nykøbing F, Denmark

To be published in Acta

PHYSIOLOGICAL WEIGHT RELIEF DURING THE TIME BEFORE FRACTURE UNION FOLLOWING INTERNAL FIXATION OF UNSTABLE TROCHANTERIC FRACTURES

J Steen Jensen & Erik Jansen
Gentofte Hospital, Hellerup, Denmark

To be published in Acta.

THE MORTALITY AFTER HIP FRACTURES

J Steen Jensen & Erik Tøndevold
Gentofte Hospital, Hellerup, Denmark

Published in Acta (*Acta orthop scand* 50, 161–168, 1979)

THE SOCIAL PROGNOSIS AND THE CONSUMPTION OF RESOURCES FOLLOWING HIP FRACTURES

J Steen Jensen, Erik Tøndevold & P Hove Sørensen
Gentofte Hospital, Hellerup and Frederiksborg County Hospital, Hillerød, Denmark

To be published in Acta.

DISTAL FEMORAL FRACTURES AN 8-YEAR STUDY

Lars Kolmert & Krister Wulff
University Hospitals, Malmo and Lund, Sweden

One hundred and thirty-five patients with 137 fractures were treated in the period 1969–1976 Pathological and osteochondral fractures and fractures in children were excluded The frequency study showed one peak in the age group 16–25 years, usually involving violent trauma another peak was seen in the age group 66–75 years where many had osteoporosis Classification into supracondylar (extra-articular), biocondylar and unicondylar fractures was made A fall at ground level was the cause in 88 and traffic accidents in 30 patients. Sixty five per cent had predisposing local or general osteoporosis (earlier fracture, gonarthrosis or coxarthrosis, ethylism, epilepsy, hemiplegia, polio etc)

Eighty-nine were conservatively and 48 surgically treated Angle plates, rushpins and screws were the most frequently used methods of fixation Only plates gave osteosyntheses stable enough for immediate postoperative training This method gave good results in young patients with normal bone The other methods needed supplementary external stabilization with traction or plaster

The results were graded according to pain mobility, limp and diminished limb length Excellent and good results were obtained in 65 per cent both in the operated and the conservatively treated groups. Indications differ however

FRACTURES OF THE CALCANEUM

P Slatis, O Kiviluoto, S Santavirta & E Laasonen
Surgical Hospital, Helsinki, Finland

Sixty seven patients with 86 fractures of the calcaneum were re-examined 2 to 5 years after the accident Forty seven patients had multiple injuries. Mean age was 39 years and men outnumbered women by 3 1 The posterior subtalar joint of the calcaneum was involved in 73, with dislocation and/or comminution in 63, ten fractures were compound. The fractures of the calcaneum were treated predominantly by support, elevation and exercises, or by reposition of the fracture with a Steinmann pin and incorporation in plaster At follow-up only 28 patients were symptom free Ten patients had subsequently been treated with a subtalar or triple arthrodesis, only one of which was entirely painless with a good functional result. Analysis of the series revealed that the functional result corresponded with the severity of comminution and the depression of the posterior subtalar joint, that functional treatment gives slightly better results than immobilization in plaster, that attempts to reduce the depressed fracture with a Steinmann pin usually fail, and that painful abutment of the peroneal tendons is frequent, especially in fractures with a depressed subtalar joint.

RUPTURE OF THE LATERAL LIGAMENTS OF THE ANKLE [illegible]

To be published in Acta.

EXTERNAL FIXATION OF UNSTABLE PELVIC FRACTURES

Erik B Riska, Henrik von Bonsdorff, Sirkka Hakkinen, Heikki Jaroma, Olli Kiviluoto & Timo Paavilainen
University of Helsinki, Helsinki, Finland

Hoffman's external fixation was used in 56 cases to stabilize unstable pelvic fractures in patients with multiple injuries Under general anesthesia three Hoffmann's screws were fixed to the iliac crest, and the dislocated pelvis was reduced and fixed with one single tie bar

The reduced position was maintained in 48 out of 51 cases. A good position was achieved in 30 cases In 16 cases a residual dislocation of less than 1 5 cm was noted at the radiographic examination after the reduction The position was maintained in these cases too In three cases a minor redislocation was noted later

Few complications could be attributed to the method of external fixation The iliac crest was fractured in one case, infection was noted in one case, and there was one case of exostosis of the iliac crest

Forty-three patients were symptom free as regards the pelvis at the time of the last follow up examination, whereas five patients had residual pains and three diffuse symptoms The method is simple but needs two surgeons at the time of reduction and fixation of the pelvis

OPERATIVE CONTROL OF MASSIVE HEMORRHAGES IN COMMINUTED PELVIC FRACTURES

Erik B Riska, Henrik von Bonsdorff, Sirkka Hakkinen, Heikki Jaroma, Olli Kiviluoto & Timo Paavilainen
University of Helsinki, Helsinki, Finland

In 42 patients, massive hemorrhages following comminuted pelvic fractures were treated by direct operative intervention through middle line, Pfannenstiel's, anterior iliac crest femoral, or posterolateral approaches, or using a combination of these The superior and inferior gluteal, pudendal and obturator arteries were the usual sources of the bleeding Bleeding from the pelvic bone tissue was of minor importance

The first step in the procedure was removal of blood clots and hematomas. Local tamponade was applied and in severe cases compression of the abdominal aorta was indicated for short intervals. All big arteries and veins which were bleeding were ligated or reconstructed.

An average of 9 units of blood was given to each patient before surgery and 30 units during or after the procedure To all 42 patients, a total 1640 units of blood was given, every sixth unit fresh blood. This necessitated a very good blood bank service

There were 12 deaths, but only three were attributable to the massive hemorrhage from pelvic region The remaining deaths were caused by concomitant injuries.

These results support the view that massive hemorrhages in pelvic fractures should be treated by direct surgical intervention

STABILITY AFTER COMPRESSION OF PELVIC FRACTURES WITH THE HOFFMANN INSTRUMENT

Ian F Goldie, Björn Gunterberg & Pär Slätis
Sahlgren Hospital, Gothenburg, Sweden and Surgical Hospital, Helsinki, Finland

Published in Acta (*Acta orthop scand* 278–286, 1978)

BRIEF OUTLINE OF TREATMENT OF PELVIC FRACTURES

Ian F Goldie
Sahlgren Hospital, Gothenburg, Sweden

Pelvic fractures are sustained when violent forces hit the body Of all fractures 3 per cent are pelvic. In two-thirds of all pelvic fractures other serious injury is present The mortality rate is present 10 per cent The treatment is both general and local

The *general* treatment should be directed against bleeding, complications from the urinary tract and respiration Bleeding occurs from large vessels and from the fracture surfaces. Rupture of the urethra must be diagnosed and precautions against DIC must be taken at an early stage

The *local* treatment depends on which zone is fractured. Non-weight bearing zones can be treated conservatively with bed rest traction and early mobilization Weight-bearing zones should preferably be treated by fixation with screws, plates and screws, wires or external fixation.

PELVIC INSTABILITY AFTER FRACTURE AND PARTURITION

Gert Walheim
Karolinska Hospital, Stockholm, Sweden

A new method has been developed to measure movements in the pelvis. A pin is inserted at

AS TENSIONS AND INTRAOSSEOUS ESSURE IN THE LONG BONES OF THE ESTHETIZED DOG

ik Tøndevold, Jørgen Eriksen & Erik Jansen
ntofte Hospital, Hellerup, Denmark

The influence of the mean arterial blood essure and arterial gas tensions upon the intra-dullary pressure in the epiphysis, metaphysis d diaphysis were investigated It was found that normal range of medullary pressure was –30 mmHg, and this remained constant as long the mean arterial pressure exceeded mgHg hen the arterial pressure was below this limit, a crease in medullary pressure down to -6 mmHg was measured

Among the blood gases only oxygen had any fluence on the medullary pressure When arterial ygen tension was below 100 mmHg a significant crease was found in the medullary pressure in l parts of the long bones Carbon dioxide, pH d standard bicarbonate concentration had no fluence upon medullary pressure

NTRAOSSEOUS PRESSURE, BONE ENSITY AND ROENTGENOLOGICAL AND LINICAL FINDINGS IN PRIMARY OSTEO-RTHRITIS OF THE HIP JOINT

iels B Termansen & P Stubbe Tegibjerg
dense University Hospital, Odense Denmark

In 108 patients with primary osteoarthritis of he *hip joint the intraosseous pressure of the* emoral head and the greater trochanter was easured prior to total hip reconstruction The ntraosseous pressure of the femoral head (mean 9 6 mmHg) was significantly higher than that of he greater trochanter (mean 31 6 mmHg), with a ositive correlation between the two A con-iderable variation was found in the pressures of he femoral heads with a distribution not differing agnificantly from a normal distribution There was a slight positive correlation between intra-osseous pressure and mean arterial blood pressure, but intraosseous pressure was not influenced by sex and age. No association was found between the intraosseous pressure of the femoral head and the severity of osteoarthritis judged by roent-genological and clinical criteria or between intra-osseous pressure and bone density of the femoral head

The results of this investigation do not support the hypothesis of intraosseous hypertension as a pathogenetic factor in primary osteoarthritis.

OSTEOARTHRITIS OF THE HIP EPIDEMI-OLOGY AND CLINICAL ROLE

Knud Jørring
Hvidovre Hospital, Denmark

Among 6321 patients who had undergone X-ray examination of the colon 4 7 per cent were found to have radiological osteoarthritis of the hip The female male ratio was 3

A follow-up was made of the patients with radiological osteoarthritis of the hip, one-half had no complaints or only mild ones In keeping with the fact that osteoarthritis was more severe in the women than in the men, the women fared the worste They had more often to apply for disable-ment pension, had more severe pain, and were more handicapped in activities of daily living

THE NORMAL GAIT MEASUREMENT OF FORCES AND THE TIME RELATIONS TO FOOT-TO-GROUND FORCES

Erik Jansen, Jens Erik Pedersen & Knud Jansen
Gentofte Hospital, Hellerup, Denmark

An instrumented treadmill has been used to measure the foot-to-ground forces for each foot during continuous walking Using an electronic computer the heel-on (in the figure indicated by △) and toe-off (in the figure indicated by ▽) is calculated In this way swing phase, stance phase and stride length are determined By comparing the vertical force of the left foot and the right foot right and left step and double support times can be calculated In a series of 14 normal persons walking with an increasing speed of 2 to 6 km/h a linear increase in stride length was found In the same study it was found that stance phase decreases, swing phase increases and double support times increase

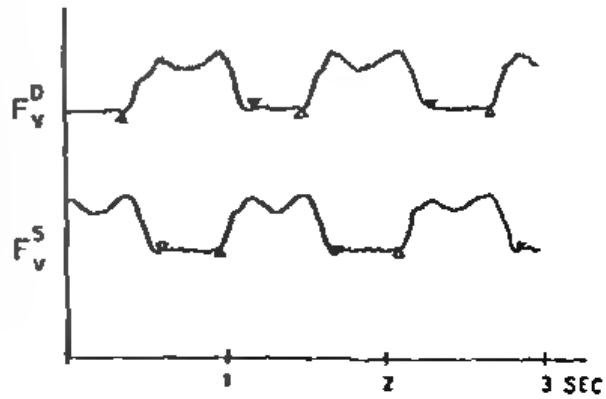

POSTERIOR FUSION IN INSTABILITY OF THE CERVICAL COLUMN IN RHEUMATOID ARTHRITIS AND FRACTURES

Ian F Goldie, Bo Althoff, Carl-Axel Carlsson & Claes von Essen
Sahlgren Hospital, Gothenburg, Sweden

Since 1972, 39 patients have been treated with posterior fusion of the cervical column in 29 cases – 17 rheumatoid patients, 9 trauma and 3 os odontoideum – a high fusion has been carried out The technique of fusion involved the fixation of the atlas to the axis by a wire running around the posterior arch of the atlas and fixed over a rush-pin drilled transversely through the spinal process of the axis. The occiput has not been involved except in three cases in which a vertical dislocation of the odontoid process into the skull had occurred In the remaining 10 cases – 2 rheumatoids and 8 trauma – fusion has been carried out at a lower level

At follow-up with an observation time of more than 1 year it was found that the clinical function was in all cases most satisfactory and radiological examination with provocation of the cervical column in flexion and extension showed that complete stability had been obtained

FRACTURES IN PATIENTS WITH RHEUMATOID ARTHRITIS

Håkan Brattström
University Hospital, Lund, Sweden

Patients with rheumatoid arthritis usually have osteoporotic bones, a condition often aggravated by steroid treatment This means that even a very minor trauma during everyday activities or during treatment (surgery under anaesthesia or physiotherapy) may cause a fracture The diagnosis of these fractures may be missed because of lack of adequate trauma and the fact that the patient as well as the staff are used to the patient always having some degree of pain The osteoporotic bone and the tendency for these patients to get stiff during external fixation call for unconventional treatment of the fracture

TORQUE STRENGTH OF EXPERIMENTAL FRACTURES TREATED BY PLATE FIXATION WITH AND WITHOUT COMPRESSION

T Holmstrom, P Slatis, E Karaharju & P Paavolainen
Surgical Hospital, Helsinki, Finland

Transverse osteotomy was performed on both tibiofibular bones in 70 rabbits The right side was stabilized with a commercial DPC plate using compression, the left side with a similar plate without compression In 20 animals both fractures healed uneventfully, and these formed the series No essential difference in healing pattern was observed macroscopically, radiographically or microscopically between fractures treated with compression and those treated without. Torque strength was measured 3, 6, 9, 12 and 24 weeks after osteotomy In both groups strength initially increased, approaching normal values during the first 9 weeks, after this the torque strength gradually decreased The increase in strength reflected the formation of new bone in the fracture area, the subsequent decrease, porotic transformation of the bone under the rigid plate There was no difference in torque strength between the plated fractures treated with and without compression

A BIOCHEMICAL STUDY OF THE STRENGTH OF IMPLANTS OF THE JEWETT AND McLAUGHLIN TYPE

J Steen Jensen
Gentofte Hospital, Hellerup, Denmark

To be published in Acta.

[illegible]

Gunnar B J Andersson, André Gaechter Jorge Galante & William Rostoker
Sahlgren Hospital Gothenburg Sweden Rush-Presbyterian, St Luke's Medical Center Chicago Gothenburg and University of Illinois, Circle Campus, Chicago USA

Forty-three resections of major segments of long bones have been performed on 38 baboons and the defect replaced by sintered titanium fibre metal prostheses Satisfactory bridging of the prosthesis with bone occurred when autologous bone was grafted Endosteal bone ingrowth occurred readily into the pores of the titanium fibre composite The bone was mature and no fibrous tissue membrane was observed between bone and metal No abnormal tissue reactions were seen. Similar prostheses have been used to replace resected segments for long bones in patients with tumors or loss of bone due to trauma The results so far are satisfactory

ertant, in order to determine the optimal time for tment, *or to decide on non-treatment If the* t doubt existed, a biopsy was taken close to normal bone and far from the fracture

THOLOGICAL FRACTURES LLOWING KIDNEY TRANS- ANTATION

Hagen
rtina Hansens Hospital, Sandvika, Norway

one necroses, pathological fractures and bable affections of the epiphyseal growth plates been recognized in association with cor- steroid therapy after kidney transplantations risk of developing these lesions seems to elate with the total steroid dose A sub- ndral fracture through osteonecrotic cancellous e of the femoral head may be detected at an ly stage by tomography and is called the scent sign.

SPONTANEOUS FRACTURES IN THE HIP *AND SHOULDER JOINTS*

Stefan Haraldsson
University Hospital, Reykjavik, Iceland

A 30-year-old man with a spontaneous sub-chondral fracture in the femoral head was treated with bone nails introduced through the articular cartilage Four months later the fracture healed and function was restored

A 40-year-old female had a hydatid cyst in the humerus with destruction of the proximal half of the humerus and a spontaneous fracture An earlier solution to such a problem resulted in the author's design of a "muscle-sling" humeral pros- thesis (*Acta orthop scand* 40, 225, 1969) for reconstruction of the proximal half of the humerus and the shoulder joint.

A 24-year-old man had a spontaneous fracture in a juvenile cyst engaging the collum, caput and trochanter major in the femur The destruction was too extensive for reconstruction of bone. A Moore arthroplasty was performed with cemen- tation of the prosthesis to the femur At follow-up 5 years postoperatively the patient was back to full-time work without signs of recurrence

SECOND MEETING OF THE EUROPEAN SOCIETY OF BIOMECHANICS

AND

FIRST SYMPOSIUM OF THE G.E B.O.A.S.

(Groupe d'Etudes de Biomécanique Ostéo-Articulaire de Strasbourg)

SEPTEMBER 13–15, 1979 STRASBOURG FR

Aims of the meeting

The purpose of the meeting is to bring together clinicians, engineers, scientists and manufa
who are interested in the interdisciplinary field of Biomechanics

Place

The meeting will be held in Strasbourg, in the Anatomy Amphitheatre of the "Hospices C

Preliminary program

— Bone and cartilage biomechanics
— Biomechanical aspects of bone healing
— Osteosyntheses biomechanics
— Different orthopaedic devices and materials
— Cardiovascular biomechanics
— Electric and magnetic stimulation of bone repair
— Joint biomechanics, normal and pathologic joints, prostheses and fixations

Registration fees

Members	**: 300FF**
Non-Members	**: 400FF**
Residents, Students	**: 200FF**
Exhibitions	**: 1000FF/m²**

Official language English

Further information

D Muster
Service de Chirurgie Maxillo-Faciale
Hospices Civils
67000 Strasbourg, France

Acta orthop scand. 50, 369–374, 1979

THE HEALING OF EXPERIMENTAL FRACTURES BY COMPRESSION OSTEOSYNTHESIS

I. *Torsional Strength*

PEKKA PAAVOLAINEN, PÄR SLATIS, ERKKI KARAHARJU & TEDDY HOLMSTRÖM

Division of Orthopaedic Surgery and Traumatology, Surgical Hospital, University Central Hospital, Helsinki, Finland

Biomechanical properties of osteotomized rabbit tibio-fibular bones fixed with 6-hole stainless steel AO/DCP plates were investigated with torsional loading 3 to 24 weeks postoperatively

During the first 9 weeks maximum torque capacity, energy absorption and torsional rigidity increased, reflecting progressive bony union between the fractured bone ends. From 9 to 24 weeks the values of torque capacity and energy absorption decreased, whereas torsional rigidity seemed to reach a steady state without further significant changes. For the three parameters considered, the mean percentage differences between the osteotomized plated bones and their paired sham-operated controls were 69, 64 and 80 per cent, respectively

The results suggest that internal fixation of fractured bones provides conditions for undisturbed fracture healing, but that subsequently the rigid nature of the implant has an adverse effect on the cortical bone, which slowly loses strength Thus the optimal time for removal of the plate seems to be shortly after the fracture has healed and before the bony tissue has been weakened by secondary changes, such as cancellous transformation and spatial rearrangement of the tubular bone

Key words bone, bone plates, fractures, fracture fixation

Accepted 20 xi 78

The use of rigid metallic plates in the treatment of fractured cortical bones leads to union by a histologically characteristic pattern of events known as primary fracture healing (Schenk & Willenegger 1964, Andersson 1965, Olerud & Danckwardt-Lillieström 1968, Rahn & Perren 1971) The morphological description of this mode of fracture healing however, does not take into account the mechanical strength of the bond between the fractured bone ends. This property of the fracture union can be quantified only by measuring the rate of recovery of normal strength and rigidity in the healing bone

Rigid plates applied to tubular bone involve the risk of morphologically untoward changes in the underlying cortical bone Porotic transformation induced by the stress protection properties of the rigid plate has been reported by some investigators (Uhthoff & Dubuc 1971, Gördes et al. 1975, Woo et al 1976, Paavolainen et al 1978b) Uniform morphological changes have been reported after

0001–6470/79 040369–06$02.50.0

© 1979 Munksgaard, Copenhagen

fixation of the plates in both intact and osteotomized bones, indicating that the main factor producing these untoward changes in the bone is not the fracture healing, but the rigidity of the implant (Slatis et al 1978)

The effect of rigid plates on the healing of experimental fractures has been studied by Lettin (1965) and by Henry et al (1968), who reported reduction of mechanical strength in the osteotomized bones as compared with their intact controls. In osteotomized canine femora, Braden et al (1973) reported recovery of only 36 7 per cent of the original torsional rigidity at 10 weeks postoperatively, when the fracture was fixed with compression plates. According to Jäger et al (1976), plate fixation of the fracture in healing rabbit tibiae caused a loss of bending strength of 70–80 per cent 16 weeks postoperatively

The aim of the present study was to investigate the changes in the torsional strength of osteotomized rabbit tibio-fibular bones in a time-related series after rigid plate fixation of the fracture



Figure 1 Rabbit tibio-fibular bone 6 weeks *fixation of the midshaft osteotomy with a six AO/DCP plate (on the right) and its pa control bone (on the left) The fracture has w and the line of osteotomy can no longer be tinguished Note the formation of new subperios bone around the plate and the increased diamet the plated bone as compared with the paired cont*

MATERIAL AND METHODS

Operative procedure

Thirty five adult rabbits weighing from 2800 to 4400 g were used. On the right tibia a midshaft osteotomy was made close to the tibio-fibular junction with a circular saw, during sawing the line of osteotomy was cooled with saline The osteotomized bone was plated with a stainless steel (AISI 316 L) six hole dynamic compression plate (AO/DCP) The length of the plate was 53 mm, width 7 mm and thickness 1 5 mm. The plate was attached to the anterolateral face of the tibia and compression was applied between the most proximal and most distal screws. The two pairs of middle screws were tightened in a neutral fashion (Figure 1).

On the left tibia a sham operation was carried out, exposing the periosteum without touching the bone No external splints or bandages were used after the operation and the animals were allowed to move freely in separate cages. They were provided with water *ad libitum* and the standard laboratory diet.

Sampling techniques

Fifteen animals had to be excluded from series because of infection and/or fracturing of plated bone

The animals were killed 3, 6 9 12 and weeks after the operation with an overdose sodium pentobarbitone Both tibio-fibular bo were exarticulated and the soft tissue remov leaving the periosteum and any callus wi Radiographs were taken before and after remo of the plate The specimens were kept at ro [illegible] ned with 0.9 per c [illegible] testing which left 19 animals for the [illegible] biomechanical testing of both tibio-fibular bon

Measurement of torsional properties

The proximal part of each fibula and [illegible] condylar bone ends were removed leaving a bo specimen of exactly 8 5 cm for the biomechan assay

The bones were fixed rigidly to the tors meter All specimens were subjected to exter rotation with a constant angular deformation 3 [illegible] degrees/second The bones were subjected

orsion up to the breaking point and the torque apacity and angular deformation were recorded imultaneously on a paper recorder displaying the oad-deformation curve

The following parameters were calculated from ach load-deformation curve where torque was isplayed on the vertical axis and the angular eformation on the horizontal axis

Maximum torque capacity (M_y) was determined rom the maximum deflection of the curve (to the nearest 0 1 mm) and expressed in Nm.

Maximum angular deformation (θ) was measured directly from the horizontal axis of the curve and expressed in degrees.

Energy absorbed at fracture (W_f) was calculated from the area under the curve, which was measured with a planimeter (type HAFF 317) The values were expressed in Nm

Torsional rigidity (G) of the specimen was measured from the slope of the linear portion of the curve and expressed in Nm/degree

Calculations

The biomechanical strength of each osteotomized and plated bone was compared with that of the contralateral sham-operated intact bone For each parameter the value obtained for the plated bone was expressed as a percentage of the value obtained for the control bone

The mechanical properties of the rabbit tibiofibular bone apart from angular deformation are critically dependent on the body weight of the animal (Paavolainen 1978) Using linear regression curves for body weight in relation to torque energy absorption and torsional rigidity in the normal rabbit tibio-fibular bones (Paavolainen 1978) the biasing effect of body weight was reduced by multiplying the test values obtained by a constant which standardized them for the mean body weight (3500 g) of the operated animals. This made the absolute values obtained from animals of different size and weight more comparable with each other but naturally did not affect the percentage differences between the paired bones from the same animal

Means and their standard deviations were calculated for each subgroup according to the postoperative time

The statistical significance of differences between the plated bones and their controls was analysed by the paired t test $P>0.05$ was taken to be non-significant

RESULTS

The results obtained were combined in subgroups according to the time after the operation 3 weeks (five animals), 6 weeks (five animals), 9 weeks (three animals), 12 weeks (three animals) and 24 weeks (three animals)

Macroscopically all specimens retained their exact reduction under the plate Manual tests showed that in all specimens solid union was achieved from 6 weeks onwards

The type of breakage of the specimen varied with the time after the fracture At 3 weeks, the site of the osteotomy opened up with a soft give as torque was applied At 6 and 9 weeks postoperatively, breakage occurred through the osteotomy with increasing resistance Later, the ultimate failure at torque occurred as a spiral fracture with a cleavage plane of 45 degrees to the long axis of the bone through the previous osteotomy site, the biomechanical properties of the specimen approaching those of intact bone with high rigidity

Figure 2A–D shows the mechanical properties of the osteotomized plated bones compared with the contralateral intact bones at various time intervals Maximum torque capacity (Figure 2A) seemed to achieve its peak value at 9 weeks postoperatively At this stage the difference between plated and control bones was no longer statistically significant (mean 83.3 per cent of the value for the paired controls) After that, however, the values declined Already at 12 weeks postoperatively, the torque capacity of the plated bones showed a statistically significant reduction ($P<0.01$) as compared with the intact controls. Subsequently, the reduction was significant ($P<0.02$) at 24 weeks postoperatively (mean 69 [illegible] per cent of the value for the paired controls)

The energy absorption until failure (Figure 2B) was found to be equivalent to the values for normal control bones [illegible] 6 weeks postoperatively After that, the values for energy absorption gradually diminished Paired statistics between the contralateral bones

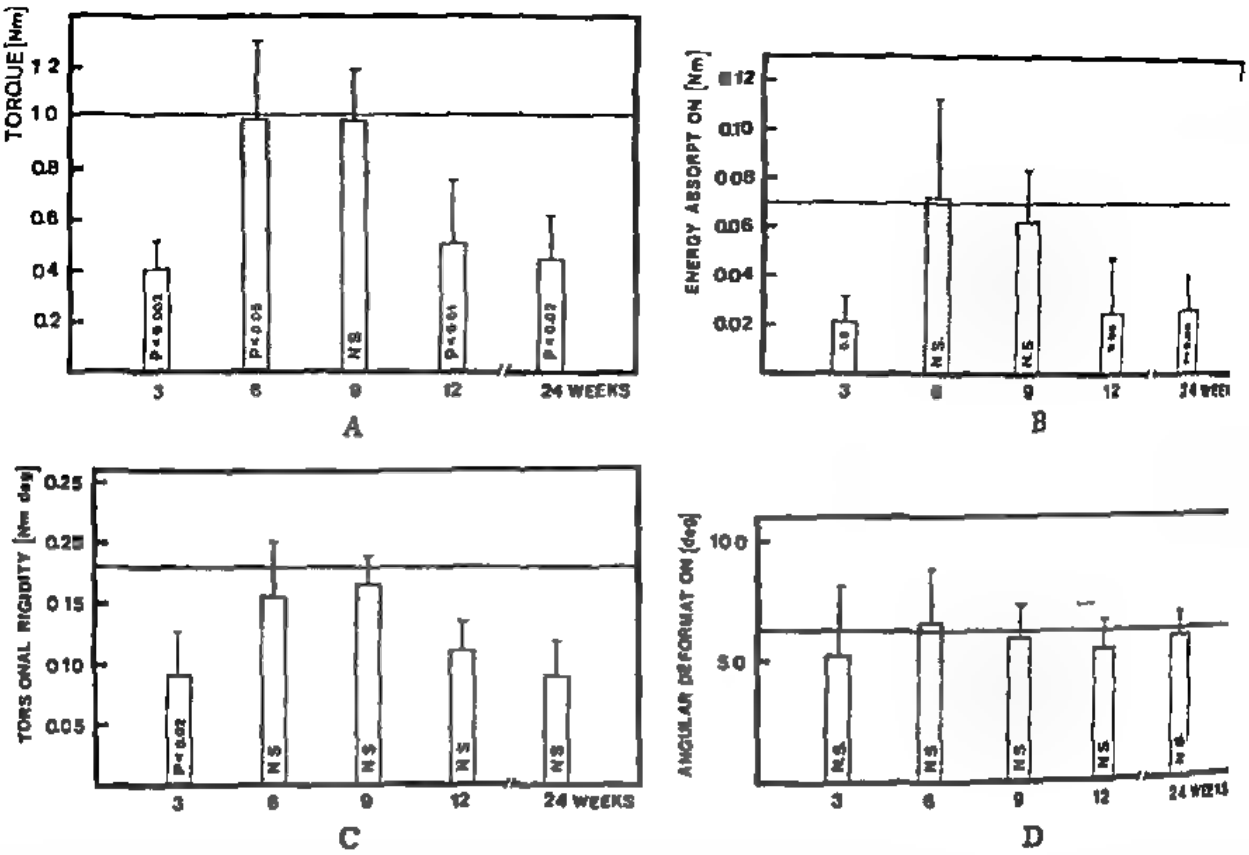

Figure 2A–D Biomechanical properties of osteotomized and plated rabbit tibio-fibular bones The white columns indicate the means of the values measured, the vertical bars representing one standard deviation Statistical significances of the differences from the paired controls (t test) are given inside the columns The stippled horizontal area indicates the mean value and two standard deviations for all control bones

revealed significant ($P<0.02$) weakening of the plated bones at 12 and 24 weeks postoperatively (mean at 24 weeks 63 6 per cent of the values for the paired controls)

Torsional rigidity (Figure 2C) was found to accord with that of the control bones 6 weeks after the operation Although the values at 12 and 24 weeks were lower than the mean value of all control bones, the paired statistics could not reveal any significance between the contralateral bones

Owing to the elastic nature of the healing osteotomy, the values for angular deformation (Figure 2D) sometimes actually exceeded those of the control bones up to the 9th week postoperatively Anyhow, there were no statistically significant differences between the paired bones regarding angular deformation in any of the subgroups

DISCUSSION

Earlier reports indicate that after experimental osteotomy the rabbit tibia achieves bony union between the 6th and 8th weeks postoperatively (Henry et al 1968 Larsen 1974, Lindsay & Howes 1931) The rapidity of fracture healing in cortical bone is seemingly the same after different types of fracture fixation and after healing without any internal fixation (Jager et al 1976 Laurin et al 1963, Lettin 1965)

White et al (1977) described four biomechanical stages of fracture healing in rabbit tibiae treated with an external compression device after experimental osteotomy Stage I is characterized by failure through the fracture site with low stiffness stage II by failure through the fracture site with high

stiffness, stage III by failure partly through ıe original fracture site and partly through ıe intact bone, with high stiffness, and stage V by failure entirely through the intact bone, ıith high stiffness. The types of breakage f our specimens under torsion closely esembled those described by White et al 1977)

The initial increase in strength followed ıy deterioration of most biomechanical proıerties of the bone, as observed in this study, hows that rigid plate fixation of an osteoomized bone leads at first to undisturbed ıony union, but that after some weeks the ıgid nature of the implant has an adverse ffect on the cortical bone Thus up to 6 or) weeks postoperatively, the values of naximum torque capacity, energy absorption ınd torsional rigidity increased almost inearly, reflecting progressive bony union ıetween the fractured bone ends. From 9 to 24 weeks postoperatively, the values for naximum torque capacity and energy absorpıion decreased, whereas torsional rigidity ıeemed to reach a steady state without signiicant changes after 9 weeks Similar bservations have been reported after rigid plate fixation of intact cortical bone (Stromberg & Dalen 1976, Paavolainen et al 1978a)

The loss of strength seems to be due to porotic transformation after rigid plate fixation with increased susceptibility to initiation of cracks from internal cavities or flaws in the microstructure of the bone (Uhthoff & Dubuc 1971, Slatis et al. 1978) This interrelationship between mechanical properties and density in composite materials like bone has been well documented by Wright & Hayes (1977) and Carter & Hayes (1977)

Henry et al. (1963) and Lettin (1965) reported reduced mechanical strength of fractures treated by rigid plate fixation, as compared with intact bones or fractured bones united by normal callus formation after non-operative treatment Jager et al (1976) observed a decrease of 70 to 80 per cent in the bending strength of osteotomized rabbit tibiae 16 weeks after rigid plate fixation, as compared with a decrease of only 40 per cent after normal callus formation at the same time Braden et al (1973) reported recovery of only 36 7 per cent of normal torque stiffness 10 weeks after plate fixation of canine femora The tendency towards diminishing strength after internal fixation is the same in the different studies, although the absolute values differ because of the different species and different testing procedures. The commercially available plate used in the present study can be considered slightly over-dimensioned when compared with the rabbit tibio-fibular bone. This may influence the profound structural changes and reduced mechanical strength of the bone specimens in the present study

Rigid plate fixation obviously induces adverse secondary changes in the underlying bone long after the fracture has healed The present study reveals a biphasic pattern in the mechanical properties observed at different time intervals after osteosynthesis. Our findings suggest that the optimal time for removal of the plate is shortly after the fracture has healed and before the rigid fixation has induced secondary changes

REFERENCES

Andersson L D (1965) Compression plate fixation and the effect of different types of internal fixation on fracture healing *J Bone Jt Surg* 47-A, 191–208

Braden T D, Brinker W O., Little R. W, Jenkis, R B & Butler D (1973) Comparative biomechanical evaluation of bone healing in the dog *J Amer vet med Ass* 163, 65–69

Carter, D R & Hayes, W C. (1977) The compressive behaviour of bone as a two-phase porous structure *J Bone Jt Surg* 59-A, 954–962.

Gordes, V Kossyk W & Hollander H (1975) Histologische und histomorphometrische Veranderungen bei Plattenosteosynthesen nach Osteotomien an der Tibia des Kaninchen *Arch orthop Unfall-Chir* 82, 123–133

Henry A, Freeman, M A R & Swanson A. V (1963) Studies on the mechanical pro-

perties of healing experimental fractures. *Proc roy Soc. Med.* 61, 40–44

Jäger, M., Gordes, W., Kossyk, W & Ugethum, M (1976) Bruchfestigkeitsuntersuchungen bei konservativ und operativ behandelten Osteotomien der Kaninchen-Tibia. *Unfallheilkunde 79, 193–201*

Laros, G S (1974) Fracture healing *Arch. Surg* 108, 698–702.

Laurin, C. A., Sison, V & Roque, N (1963) Mechanical investigation of experimental fractures. *Canad. J Surg* 6, 218–228

Lettin, A. W F (1965) The effects of axial compression on the healing of experimental fractures of rabbit tibia. *Proc. roy Soc. Med.* 58, 882–886

Lindsay, M K. & Howes, E. L. (1931) The breaking strength of healing fractures. *J Bone Jt Surg* 13, 491–501

Olerud, S. & Danckwardt-Lillestrom, G (1968) Fracture healing in compression osteosynthesis in the dog *J Bone Jt Surg* 50-B, 844–851

Paavolainen, P (1978) Studies on mechanical strength of bone. I Torsional strength of normal rabbit tibio-fibular bone *Acta orthop scand.* 49, 497–505

Paavolainen, P., Slatis, P., Karaharju, E & Holmström, T (1978a) Studies on mechanical strength of bone. II Torsional strength of cortical bone after rigid plate fixation with and without compression. *Acta orthop scand* 49, 506–511

Paavolainen, P., Karaharju, E., Slatis, P., Ahonen, J & Holmstrom, (1978b) Effect of rigid plate fixation on structure and mineral co[illegible] of cortical bone. *Clin. Orthop* 136, 287–293

Rahn, B & Perren, S M. (1971) Primary b[illegible] healing *J Bone Jt Surg* 53-A, 783–786.

Schenk, R. & Willenegger, H (1964) Zur Hi[illegible]logie der primären Knochenheilung *Langenb[illegible] Arch. klin. Chir 308, 440–451*

Slatis, P., Karaharju, E., Holmström, T., Aho[illegible] J & Paavolainen, P (1978) Structural cha[illegible] in intact tubular bone after application of r[illegible] plates with and without compression. *J B[illegible] Jt Surg* 60-A, 516–522.

Stromberg, L. & Dalen, N (1976) Influence o[illegible] rigid plate for internal fixation on [illegible] maximum torque capacity of long bones. *A[illegible] chir scand.* 142, 115–122.

Uhthoff, H K. & Dubuc, F L. (1971) B[illegible] structure changes in the dog under r[illegible] internal fixation. *Clin. Orthop* 81, 165 1[illegible]0.

White III, A. A., Panjabi, M. M & Southw[illegible] W O (1977) The four biomechanical stag[illegible] fracture repair *J Bone Jt Surg* [illegible] 188–192.

Woo S L.-Y, Akeson, W H, Coutts, R [illegible] Rutherford, L., Doty, D., Jemmot, G F [illegible] Amiel, D (1976) A comparison of cortical bo[illegible] atrophy secondary to fixation with plates w[illegible] large differences in bending stiffness. *J Bo[illegible] Jt Surg 58-A*, 190–195

Wright, T M. & Hayes, W C. (1977) Fract[illegible] mechanics parameters for compact bone—effe[illegible] of density and specimen thickness. *J B[illegible] mechanics* 10, 419–430

Correspondence to Pekka Paavolainen, Division of Orthopaedic Surgery and Traumatology Surg[illegible] Hospital, University Central Hospital, Kasarminkatu 11–13, Helsinki, Finland SF 00130.

Acta orthop scand 50 375–383 1979

THE HEALING OF EXPERIMENTAL FRACTURES BY COMPRESSION OSTEOSYNTHESIS

II *Morphometric and Chemical Analysis*

PEKKA PAAVOLAINEN§ RISTO PENTTINEN†, PÄR SLÄTIS§ & ERKKI KARAHARJU§

§ Division of Orthopaedic Surgery and Traumatology Surgical Hospital, University Central Hospital, Helsinki and † Department of Medical Chemistry, University of Turku, Finland

The effects of rigid plate fixation on the structure and chemical composition of bones during healing of experimental fractures were studied by morphometric and chemical analysis at intervals of 3 to 24 weeks after attachment of six-hole AO plates to osteotomized rabbit tibiae

After fracture union gradual porotic transformation could be observed from 9 weeks onwards, with rapid excavation and breakdown of the cortical wall During the study over 24 weeks the degree of porosity increased from 9 0 ± 4 8 per cent to 37 5 ± 10 2 per cent ($P < 0$ 001) This osteoporosis was accompanied by formation of new subperiosteal bone The changes in the tubular bone led to a progressive increase in overall diameter and in the area occupied by the medullary cavity throughout the experiment

In the osteotomy area increased values were found for the content of hexosamines and the ratio of hexosamines to hydroxyproline at 3 weeks indicating formation of connective tissue in the fracture area. Later on, no chemical signs of callus formation could be detected In spite of the slight increase in the content of hydroxyproline, reflecting the formation of new bone subperiosteally, the chemical composition of the unresorbed cortical bone remained unchanged

Key words bone, bone plates, fracture fixation, calcium, hydroxyproline

Accepted 20 xi 78

The pattern of fracture healing varies within wide limits. Usually, the more stable the fixation, the less the periosteal reaction Danis (1947) pointed out that rigid plate fixation secured union of fracture ends without formation of subperiosteal callus, calling the process "*soundure autogene*" (primary healing) Morphologically this primary bone healing is accompanied by widening of the Haversian canals, formation of resorption cavities and subsequent formation of intraosseal new bone across the fracture gap (Andersson 1965, Muller et al. 1963, Olerud & Danckwardt-Lillestrom 1968, Schenk & Willenegger 1964) Additional axial compression applied to the implant and conveyed to the underlying bone does not alter the mode of repair (Perren et al 1969)

In secondary healing the stabilizing factor is callus The cartilaginous and ossification phases can be distinguished, both morphologically and chemically, by the degree of maturation of the callus (Penttinen 1972, Slätis & Rokkanen 1967)

0001–6470/79/040375–09$02.50.0

© 1979 Munksgaard, Copenhagen

perties of healing experimental fractures *Proc roy Soc Med* **61**, 40–44

Jager, M, Gordes, W, Kossyk, W & Ugethum, M (1976) Bruchfestigkeitsuntersuchungen bei konservativ und operativ behandelten Osteotomien der Kaninchen-Tibia *Unfallheilkunde* **79**, 193–201

Laros, G S (1974) Fracture healing *Arch Surg* **108**, 698–702

Laurin, C A, Sison, V & Roque, N (1963) [illegible]

Let [illegible] pression on the healing of experimental fractures of rabbit tibia *Proc roy Soc Med* **58**, 882–886

Lindsay, M K & Howes, E L (1931) The breaking strength of healing fractures *J Bone Jt Surg* **13**, 491–501

Olerud, S & Danckwardt-Lillieström, G (1968) Fracture healing in compression osteosynthesis in the dog *J Bone Jt Surg* **50-B**, 844–851

Paavolainen, P (1978) Studies on mechanical strength of bone I Torsional strength of normal rabbit tibio-fibular bone *Acta orthop scand* **49**, 497–505

Paavolainen, P, Slatis, P, Karaharju, E & Holmstrom, T (1978a) Studies on mechanical strength of bone II Torsional strength of cortical bone after rigid plate fixation with and without compression *Acta orthop scand* **49**, 506–511

Paavolainen, P, Karaharju, E, Slatis, P, Ahonen, J & Holmstrom, (1978b) Effect of rigid plate fixation on structure and mineral conte of cortical bone *Clin Orthop* **136**, 287–293

Rahn, B & Perren, S M (1971) Primary bon healing *J Bone Jt Surg* **53-A**, 783–786

Schenk, R & Willenegger, H (1964) Zur Histo logie der primaren Knochenheilung *Langenbe Arch klin Chir* **308**, 440–451

Slatis, P, Karaharju, E, Holmstrom, T., Ahonen J & Paavolainen, P (1978) Structural change in intact tubular bone after application of rigi plates with and without compression *J Bon Jt Surg* **60-A**, 516–522

Stromberg, L & Dalen, N (1976) Influence of rigid plate for internal fixation on th maximum torque capacity of long bones *Act chir scand* **142**, 115–122

Uhthoff, H K & Dubuc, F L (1971) Bon structure changes in the dog under rigi internal fixation *Clin Orthop* **81**, 165–170

White III, A A, Panjabi, M M & Southwick W O (1977) The four biomechanical stages of fracture repair *J Bone Jt Surg* **59** [illegible] 188–192

Woo, S L-Y, Akeson, W H, Coutts, R. D. Rutherford, L, Doty, D, Jemmot, G F & [illegible]

Wr [illegible] mechanics parameters for compact bone–[illegible] of density and specimen thickness *J Bio mechanics* **10**, 419–430

Correspondence to Pekka Paavolainen, Division of Orthopaedic Surgery and Traumatology Surgical Hospital, University Central Hospital, Kasarminkatu 11–13, Helsinki, Finland SF 00130

and the third beyond the plate (III). Comparable discs were sawn from the control bones. Each of these discs was further divided radially into four sectors, one of which contained the cortical area beneath the plate (Figure 1).

Twenty-one animals were left for morphometric analysis of bone remodelling. A section through the tubular bone was removed at level II, under the plate but distal to the osteotomy. These samples were embedded in methylmethacrylate and ground to 50 μm with carborundum paper. Contact microradiographs of these undecalcified specimens were taken on films exposed with a Machlett AEG-50 tube at 10 kV, 10 mA, for 1 s, FFD 20 cm.

Morphometric measurements and estimation of resorption on cross sections of bone

The entire cross-sectional area and the area occupied by the medullary cavity were determined from ten-fold enlargements of contact microradiographs with planimetry (HAFF 317 planimeter). The values obtained were reduced mathematically to the actual size of the bone (Slatis et al. 1978). The percentage increase in the outer circumference as compared with the paired control bones was calculated for each pair of bones and indicated the degree of subperiosteal new bone formation. The area of the medullary cavity as a percentage of the entire cross-sectional area was calculated for the pairs of bones.

Photographs of the detailed structure of the cortical bone were made from the microradiographs at a magnification of × 100 with the resorption area in black and the cortical bone in white. The microradiographs were analysed by random point-sampling of each enlargement using a transparent grid on which there were lines and crossbars. The number of intersections over both black and white areas in the whole cortex were counted three times, and the number of so-called hits on the black areas was expressed as a percentage of all hits scored on cortical bone (Slatis et al. 1978). This technique permitted measurement of the proportion of cortical bone resorbed, and the results were reproducible with an error of less than 1 per cent.

A paired *t* test was performed to test the significance of the differences between the paired bones. $P > 0.05$ was taken to be non-significant.

Chemical analysis

The samples were lyophilized, weighed and ground to a fine powder in a mortar. The results were correlated with the dry weight of the material. The chemical analyses were carried out according to the methods used by Penttinen (1972). For determination of hexosamines the samples were hydrolysed in 4.0 ml of 2 N HCl for 16 hours at 105°C in sealed test tubes. A 1.0 ml portion was taken for the hexosamine assay and 2.0 ml of concentrated hydrochloric acid was added to make the solution 6 N. Hydrolysis was continued for 3 hours at 130°C in an N_2 atmosphere and the hydrochloric acid was evaporated in a boiling water bath. The specimens were dissolved in 8.0 ml of distilled water and small portions were used for determination of total nitrogen, hydroxyproline, calcium and phosphorus.

Calcium was determined in 1 per cent $LaCl_3$ with an atomic absorption spectrophotometer (Varian Techtronic Pty Ltd., Model 1100, Melbourne, Australia). The *t* test was used for establishing the significance of differences between the values for the paired bones and between the means for every possible pair of subgroups. $P > 0.05$ was taken to be non-significant.

RESULTS

Technically successful preparations for morphometric analysis were obtained from 19 animals at 3 weeks postoperatively (four animals), 6 weeks (five animals), 9 weeks (four animals), 12 weeks (four animals) and 24 weeks (two animals).

Planimetry of transverse sections of diaphyseal bone

Planimetry of transversal sections of the plated diaphyseal bone demonstrated subperiosteal new bone formation with increase in the overall cross-sectional area of the tubular bone. This was accompanied by resorption of subendosteal cortical bone leading to an increase in the area occupied by the medullary canal (Figure 2A–C).

Table 1 shows the percentage increase of the entire cross-sectional area in the plated bone when compared to the intact controls, and the size of the medullary canal in plated and control bones expressed as a percentage of the entire cross-sectional area of the tubular bone.

Rigid metallic implants on cortical bone act as stress protectors in the bone (Lanyon et al 1976) This leads to increased porotic transformation, with widening of the Haversian canals and formation of resorption cavities in dense lamellar bone (Gordes et al 1975a, Slatis et al 1978, Uhthoff & Dubuc 1971)

The attenuation technique has been used to show reduction of the mineral mass of bone after compression plating (Gördes et al 1975b, Strömberg & Dalen 1976, Tonino 1974) On the other hand as shown in our earlier reports concerning the chemical content of calcium and hydroxyproline, there is only a slight decrease in the mineral content of cortical bone (Paavolainen et al 1978b,c)

The chemical composition of the callus formed in fractures treated without any internal fixation has been thoroughly analysed (Penttinen 1972), but little is known about the chemical changes during fracture repair after rigid plate fixation

The aim of the present study was to analyse the morphometric and chemical changes after rigid plate fixation of experimental osteotomies and to compare these alterations with those earlier reported for fractures treated without any internal fixation (Penttinen 1972) The effect of these alterations on the reduced mechanical strength of bone after rigid plate fixation of fractures (Braden et al 1973, Paavolainen et al 1978a) will be discussed

MATERIAL AND METHODS

Operative techniques

Forty-one rabbits weighing from 2800 to 4400 g were used. On the right tibia a midshaft osteotomy was made near the tibio-fibular junction with a circular saw cooled with saline A stainless steel (AISI 316 L) six hole dynamic compression plate (AO/DCP) was attached to the anterolateral face of the bone. The length of the plate was 53 mm width 7 mm and thickness 1 5 mm. Compression was applied between the most proximal and the most distal screw and the

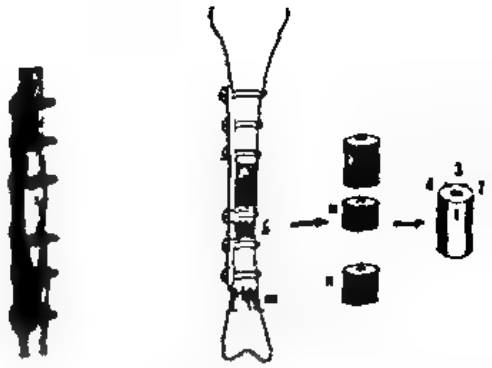

Figure 1 A diagram showing the discs of plated osteotomized rabbit tibio-fibular bone selected for chemical analysis Two of the discs were taken beyond the plate (III) Each of these discs was further divided radially into four sectors one of which contained the cortical area beneath the plate

other two pairs of screws were tightened in a neutral fashion (Figure 1)

On the left tibia a sham operation was made exposing the periosteum but without osteotomy or plate fixation

Postoperatively, the animals were housed in separate cages where they were allowed to move freely, with water *ad libitum* and a standard laboratory diet No external splints or bandages were applied after the operation.

Fifteen animals had to be excluded from the analysis because they sustained re-fractures or other postoperative complications.

Sampling techniques

The animals were divided into five subgroups killed 3, 6, 9 12 and 24 weeks postoperatively The tibio-fibular bones were exarticulated and freed from any soft tissue but the periosteum and any callus tissue were preserved intact. Bones were radiographed before and after removal of the plates.

One animal from each subgroup (five animals) was randomly selected for chemical analysis. From each tibia three discs containing the entire cross section of the tubular bone were removed at predetermined levels.

From the plated tibia, two of the discs were taken from the bone beneath the plate, one of these at the level of osteotomy (I), the second distal to the osteotomy but beneath the plate (II

Table 2 Porotic transformation of diaphyseal bone during fracture repair with rigid plate fixation

Time after operation	Porosity (per cent, mean ± s.d.)			
	Plated bone			*Control bone*
Weeks	Beneath the plate	Opposite cortex	(average)	(average)
3	5.8 ± 1.1	11.4 ± 5.2	(9.0 ± 4.8)	6.3 ± 1.5
[illegible]	12.5 ± 4.0	18.6 ± 4.5	(15.6 ± 5.1)	8.0 ± 1.9
9	12.2 ± 5.9	11.8 ± 7.8	(12.2 ± 5.9)	5.5 ± 2.5
12	31.0 ± 15.8	20.0 ± 14.5	(25.5 ± 15.2)	9.6 ± 2.9
24	39.3 ± 10.2	33.8 ± 11.2	(37.5 ± 10.2)	7.5 ± 2.0

During the first 3 weeks porosity in the cortex adjacent to the plate remained normal, but the cortex opposite the plate already showed signs of incipient porotic transformation (porosity 5.8 ± 1.1 and 11.4 ± 5.2 per cent, respectively). After this the proportion of resorbed bone increased rapidly. At 9 weeks postoperatively resorption of the cortical bone beneath the plate was equivalent to the degree of resorption at the opposite cortex (12.2 ± 5.9 and 11.8 ± 7.8 per cent, respectively). Later on, the porosity under the plate seemed to exceed the values for the opposite cortex. By 24 weeks after the operation the porosity under the plate had increased to 39.3 ± 10.2 per cent and in the opposite cortex to 33.8 ± 11.2 per cent. This increase in mean porosity in the plated bone during follow-up was statistically highly significant ($P < 0.001$).

Chemical analysis

The data obtained from chemical analyses were combined in subgroups according to the time of observation after the operation.

No significant differences could be observed between the plated bones and their controls at any of the three levels sectioned along the tubular bone (Figure 1) in any subgroup.

The values for section I, containing the line of osteotomy in plated bones and the comparable level from control bones, were used for comparisons between the various subgroups (Figure 3). In the plated bones only two of the parameters analysed showed statistically significant changes during follow-up: hexosamines (increase, $P < 0.01$) and the content of hydroxyproline (increase, $P < 0.05$). When these values were compared with the corresponding control values in the various subgroups, the differences between the paired bones were only significant for the content of hexosamines and the ratio of hexosamines to hydroxyproline at 3 weeks ($P < 0.01$ and $P < 0.05$, respectively). This may reflect formation of connective tissue in the fracture area at an early stage of fracture union. Otherwise the changes seemed to be negligible.

Whether chemical differences existed between the cortical bone adjacent to the plate and the bone in the opposite cortex was ascertained by comparing the isolated sectors I and III of the plated bones (Figure 1) in the various subgroups. These differently treated sectors showed no statistically significant differences in any of the parameters analysed.

DISCUSSION

The present study indicates that rigid plate fixation of experimental osteotomies in tibiofibular bone of rabbits induced profound structural changes in the cortical bone. The main alterations were formation of resorption cavities in the cortical wall and changes in

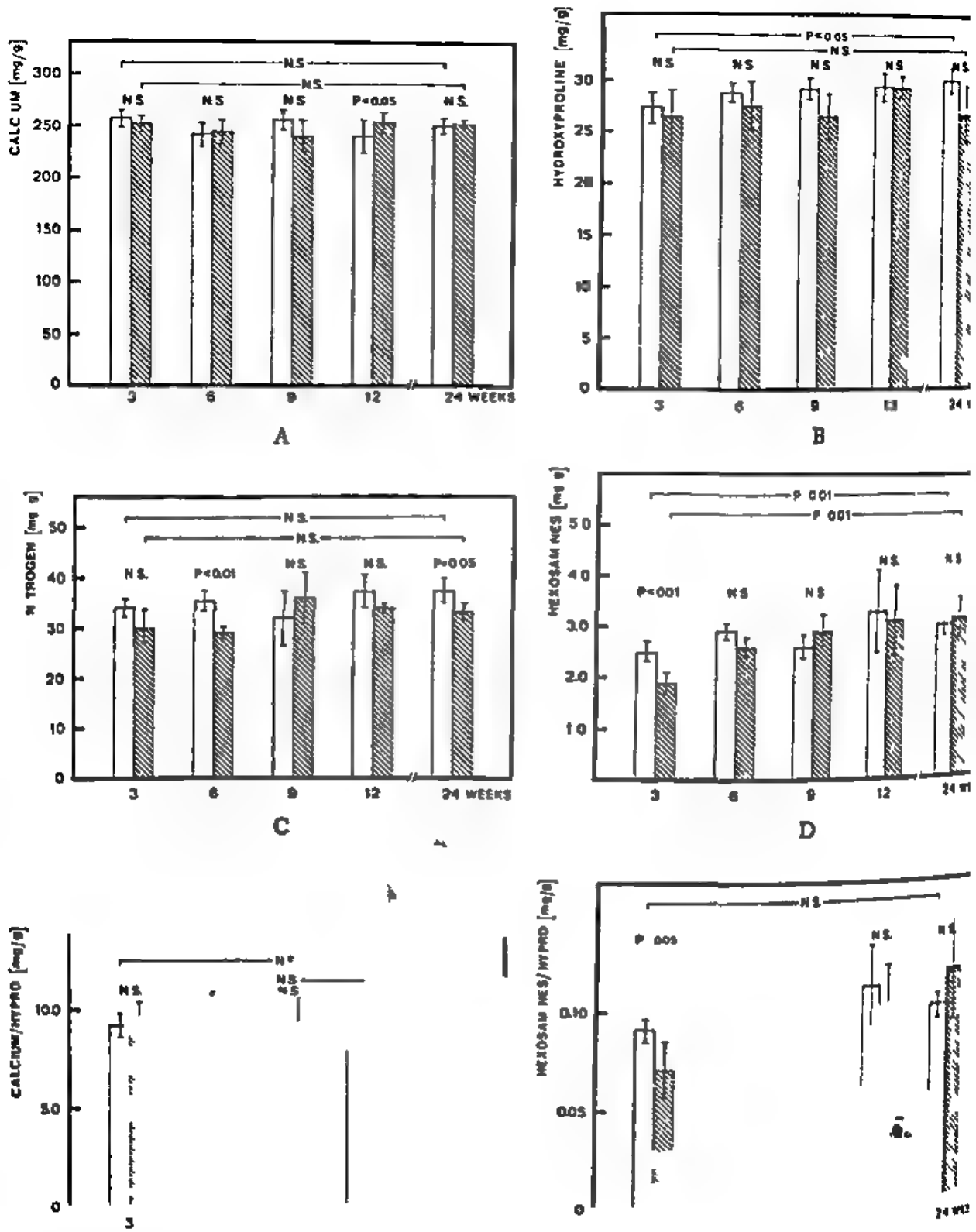

Figure 3A–F [illegible] *ratio of calcium tibio-fibular* [illegible] *bones and* [illegible] *standard deviation bones at 3 to* [illegible]

he structure of the tubular bone This may e partly due to the fact that the material pplied was of excessive dimensions when ompared with the underlying bone Yet, desite these marked structural alterations, there were only slight changes in chemical com position in the area of fracture healing or in other parts of the cortical bone

A uniform biphasic series of events could be observed in the structure of the specimens. At the first stage the outer circumference of the bone increased with subperiosteal formation of new bone, and this increase was followed by enlargement of the medullary cavity due to endosteal resorption of the cortical wall At the end of the experiment, a tubular bone was achieved with increased circumference but with almost the initial ratio between the entire cross section and the medullary cavity

Transformation of the bone begins with resorption of osteons in the cortical bone opposite the rigid plate Later on, alterations beneath the plate exceeded those in the opposite cortex, producing a porotic bone with resorption of osteons in the cortical bone shapes separating the remaining bridges of cortical bone The porotic transformation observed in the present study agrees with the changes previously described during fracture repair after compression osteosynthesis in the dog (Andersson 1965, Schenk & Willenegger 1967, Uhthoff & Dubuc 1971), sheep (Perren et al 1969) and rabbit (Gördes et al 1975a, Rahn & Perren 1971), and in man (Refior et al 1975). On the other hand, similar observations have been reported even in intact bone after rigid plate fixation (Slatis et al. 1978) In intact bone the resorptive phase started slowly 3 weeks after plating, and rapid excavation and breakdown of the cortical wall occurred from 12 weeks onwards. In 36 weeks the degree of porosity increased from 7 3 to 40 9 per cent, which is equivalent to the present series with an observation period of 24 weeks.

The torsional properties of the healing fracture after rigid plate fixation (Paavolainen et al 1979) indicated that the torque capacity and energy absorption increased linearly up to 9 weeks, reflecting fracture repair At 24 weeks postoperatively, however, these parameters were again significantly reduced as compared with those of the control bones, reflecting the stress-protective effect of the rigid metallic implant The effect of porotic transformation, with increased sites for crack initiation, seemed to exceed the mechanical effect of the increased cross section, with reduced shearing stress on the outer surface of the tubular bone (cf Carter & Hayes 1977, Wright & Hayes 1977)

Previous studies concerning the chemical changes after rigid plate fixation in intact bones (Paavolainen et al 1978a, 1978b) revealed only a slight increase in the content of hydroxyproline, reflecting formation of new bone subperiosteally and endosteally Loss of calcium content of about 15 per cent occurred during the first 2 weeks postoperatively, but there was no evidence of progressive loss of calcium, as might have been expected from the histological observations on progressive structural derangement of the bone towards the end of the experiment

The results of the chemical analysis in the present study accord with the previous observations On the other hand, the results also agree with the observations made by Mattsson (1972) and Sevastikoglou et al. (1976) of the chemical composition of bone after experimental osteoporosis due to disuse

As the loss of calcium beneath the plate might have been counterbalanced by formation of appositional new bone (Yu et al. 1975) sectors of bone adjacent to the plate and from the opposite cortex were analysed separately No differences in chemical composition were found between these two sectors. In the area of the osteotomy the content of hexosamines and the ratio of hexosamines to hydroxyproline were slightly increased at 3 weeks, reflecting formation of connective tissue between the fracture ends. Later on, there were no significant changes in the computed ratios of calcium to hydroxy-

proline, hexosamines to hydroxyproline or nitrogen to hydroxyproline, indicating no real signs of cartilaginous callus formation during the later stages of fracture repair (Penttinen 1972)

Bone mineral mass is reduced after rigid plate fixation, according to estimates made with attenuation techniques (Gordes et al 1975b, Stromberg & Dalen 1976, Tonino 1974) However, the use of attenuation techniques may lead to overestimation of the loss of minerals from non-resorbed cortical bone, owing to the reduced density of the porotically transformed bone

Our findings suggest that fixation with a rigid plate provides conditions for undisturbed union of the fracture ends without callus formation, but the rigid implant protects tubular bone from mechanical stresses and causes resorption in those parts of the diaphysis which have been deprived of their normal function (Lanyon et al 1976) The reduction of mechanical strength seems not to be connected with mineral loss or other chemical changes in the bone tissue, but due to structural and porotic transformation of the bone

REFERENCES

Andersson, L D (1965) Compression plate fixation and the effect of different types of internal fixation on fracture healing *J Bone Jt Surg* 47-A, 191–208

Brauer, T D, Brinker, W O, Little R W, Jenkis, R B & Butler, D (1973) Comparative biomechanical evaluation of bone healing in the dog *J Amer vet med Ass* 163, 65–69

Carter, D R & Hayes W C (1977) The compressive behaviour of bone as a two-phase porous structure. *J Bone Jt Surg* 59-A, 954–962

Danis, M R (1947) Le traitement operatoire des fractures. *J int Chir* 7, 311–314

Gordes W, Kossyk, W & Hollander, H (1975a) Histologische und histomorphometrische Veranderungen bei Plattenosteosynthesen nach Osteotomien an der Tibia des Kaninchens. *Arch orthop Unfall Chir* 82, 123–133

Gordes, W, Kossyk W & Bodefeld, P (1975b) Versuche zur Kalksalzdichtenbestimmung an der osteotomierten und stabilisierten Tibia des Kaninchens. *Arch orthop Unfall Chir* 125–147

Lanyon L E, Goodship A E & Baggot, D (1976) The significance of bone strain vivo" *Acta orthop belg* 42, 109–122.

Mattsson, S (1972) Reversibility of disuse osteoporosis. Experimental studies in the adult *Acta orthop scand*, Suppl 144

Muller, M E, Allgöwer, M & Willenegger H (1963) *Operative Frakturbehandl* Springer, Berlin, Gottingen Heidelberg

Olerud, S & Danckwardt Lillestrom, G (1 Fracture healing in compression synthesis in the dog *J Bone Jt Surg* 5 844–851

Paavolainen, P, Slatis, P, Karaharju, E Holmstrom, T (1979) The healing of experimental fractures by compression synthesis I Torsional strength. *Acta orth scand* 50, 369–374

Paavolainen, P, Slatis, P, Ahonen J & Karharju, E (1978a) Changes in calcium hydroxyproline content of cortical bone compression and neutral plate fixation. *orthop scand* 49, 506–511

Paavolainen, P, Karaharju, E, Slatis, P, Ahon J & Holmstrom T (1978b) Effect of plate fixation on structure and mineral con of cortical bone *Clin Orthop* 136, 287

Penttinen, R (1972) Biomechanical studies fracture healing in the rat *Acta chir scan* Suppl. 432

Perren, S M, Huggler A, Russenberger Allgower, M, Mathys R Schenk, Willenegger, H & Muller M E (1969) reaction of cortical bone to compression. *orthop scand*, Suppl 125

Rahn, B & Perren S M (1971) Primary bo healing *J Bone Jt Surg* 53-A, 783 786.

Refior, H J, Meister, P & Matzen K (19 Untersuchungen zum Verhalten der struktur der menschlichen Corticalis Druckplattenosteosynthese *Arch. orth Unfall Chir* 81, 45–56

Schenk, R & Willenegger, H (1964) Histologie der primaren Knochenheilung *Langenbecks Arch klin Chir* 308, 440–

Schenk R & Willenegger, H (1967) Morphological findings in primary fracture healing *Symp Biol Hung* 7, 75–86.

Sevastikoglou, J A, Lemperg R, Larsson, S-E & Mattsson, S (1976) Chemical composition of the skeletal parts of the extremity of the adult rat following below knee amputation immobilisation in a plaster cast *Acta chir scand*, Suppl 467, 26–30

Slatis, P, Karaharju E, Holmstrom, T, Ahon J & Paavolainen P (1978) Structural chang

in intact tubular bone after application of rigid plates with and without compression *J Bone Jt Surg* 60-A, 516–522

Slatis, P & Rokkanen, P (1967) The mineral phase in the repair of experimental fractures. *Ann Chir Gynaec. Fenn* 56, 193–201

Stromberg L & Dalen, N (1976) Influence of a rigid plate for internal fixation on the maximum torque capacity of long bones *Acta chir scand* 142, 115–122.

Tonino, A. J (1974) *Operatieve fractuurfixatie met plastic* Academisch proefschrift Amsterdam.

Uhthoff, H K. & Dubuc, F L. (1971) Bone structure changes in the dog under rigid internal fixation *Clin. Orthop* 81, 165–170

Wright, T M & Hayes, W C. (1977) Fracture mechanics parameters for compact bone—effects of density and specimen thickness. *J Biomechanics* 10, 419–430

Yu, W Y, Siu, C M, Shim, S S., Hawthorne, H M & Dunbar, J (1975) Mechanical properties and mineral content of avascular and revascularizing cortical bone. *J Bone Jt Surg* 57-A, 692–695

Correspondence to Dr P Paavolainen, Division of Orthopaedic Surgery, University Central Hospital, Kasarminkatu 11–13, Helsinki 00130, Finland.

Acta orthop scand. 50 385–390 1979

FRACTURE HEALING IN RABBITS AFTER OSTEOTOMY USING THE CO_2 LASER

C TAUBER,* I FARINE* H HOROSZOWSKI* & S GASSNER**

*Department of Orthopaedic Surgery A, Chaim Sheba Medical Center, Tel Hashomer, and
**Department of Experimental Surgery, Beilinson Medical Center, Petach Tikva Israel

Fracture healing was studied in 28 rabbits after their femurs had been osteotomized using the carbon dioxide laser Twenty rabbits whose femurs were osteotomized by means of a Gigli saw served as the control group Fracture healing was initially delayed in the laser cut femurs, yet after 60 days no significant difference between the groups could be detected The initial delay was caused by thermal damage to the laser cut bone edges. Further fragmentation of the damaged bone occurred during the immediate postoperative period

Key words CO_2 laser fracture healing, osteotomy

Accepted 13 xii 78

The carbon dioxide laser is used as a surgical tool in our Orthopaedic Department It is also employed in the treatment of haemophilia and in oncological surgery (Horoszowski et al 1976) Our clinical experience suggests that wound and bone healing are initially delayed after laser surgery Experimental evidence (Verschueren 1976, Moore 1972) has confirmed the validity of this observation

The purpose of the present study was to determine the cause of delay in bone healing after laser osteotomy, to remedy it, and to further the use, where possible, of the laser beam in surgical procedures.

MATERIAL AND METHODS

Forty-eight young adult rabbits were included in this study Thirty two osteotomies were performed with the laser* beam and twenty with the Gigli saw The latter served as controls.

The animals were divided into four groups. Three of the groups were sacrificed at weekly intervals. The last group was kept alive for 60 days. Laser osteotomies were performed on the healthy femurs of four animals prior to sacrifice

The experimental material as well as the macroscopic and roentgenologic results are summarized in Tables 1 and 2

Operative technique

Intravenous nembutal anaesthesia and a complete aseptic technique were used.

The femur was approached through an anterolateral skin incision. Skin and fascia were incised with the carbon dioxide laser, using a 15 watt output A subperiosteal osteotomy was performed with a 40 watt output A sequence of small holes was made circumferentially with the laser beam, and the bone broke easily on completion of the procedure The fracture was then fixed with one or two intramedullary Steinmann rods, although there was some unavoidable rotational instability The wound was closed in two layers. Following this the animals were X-rayed and returned to their cages, and weight bearing was not prevented. A similar operative technique was used in the control group skin and fascia were incised with the scalpel and the femur was osteotomized with a Gigli saw

* Sharplan 791 CO_2 laser

0001–6470/79/040385–06$02.50.0

© 1979 Munksgaard, Copenhagen

Table 1 Laser osteotomy

Day of sacrifice	No of osteotomies	Hypertrophic callus	Further fragmentation	Unstable	Sticky	Union	Pse arth
0	4	—	—	—	—	—	–
7	6	6	3	—	—	—	–
14	10	10	6	—	—	—	–
28	6	6	5	4	1	—	1
60	6	6	6	—	—	4	2
Total	32	28	20	4	1	4	3

Table 2 Controls

Day of sacrifice	No of osteotomies	Hypertrophic callus	Further fragmentation	Unstable	Sticky	Union	Pse arth
7	4	4	—				
14	8	8	1				
28	4	4	—	1	2	1	—
60	4	4	—	—	—	2	2
Total	20	20	1	1	2	3	2

X-ray studies

The osteotomized femur was X-rayed immediately following the operation, and examinations were repeated at weekly intervals until the rabbits were sacrificed The fourth group was not X-rayed between the 28th and the 60th day

Histological and microangiographic studies

The rabbits received intravenous nembutal anaesthesia and a 30 per cent micropaque* suspension was injected into the abdominal aorta

Twenty-four hours later the femur was carefully dissected and examined for callus size and stability

The bone was then subjected to histological preparation for the standard haematoxylin-eosin stain and according to the Spaltholtz method (Crock 1967).

RESULTS

X-ray studies

The immediate postoperative X-ray showed the osteotomized bone internally fixed in a good position (Figure 1a) After 7 days a fine opacification, disclosing the contour hypertrophic callus, was noted (Figure Fourteen days after surgery the callus was developed and could be seen clearly (Figur Thus ossification progressed for a furth days (Figure 1d), and solid union usually place about 60 days after operation (Figur

These features were common to both laser cut femurs and to the controls.

Further fragmentation at the fracture in the laser cut femurs took place durin first and rarely during the second week the operation (Figures 1b and 1c) occurred in 20 out of 28 laser cut femur incidence of 71 per cent) This phenom was observed in only one out of 20 femu the control group

Histological findings

Callus formation was not impaired by laser beam After seven days an organ haematoma with cartilage and new formation was observed

The callus matured gradually, abb

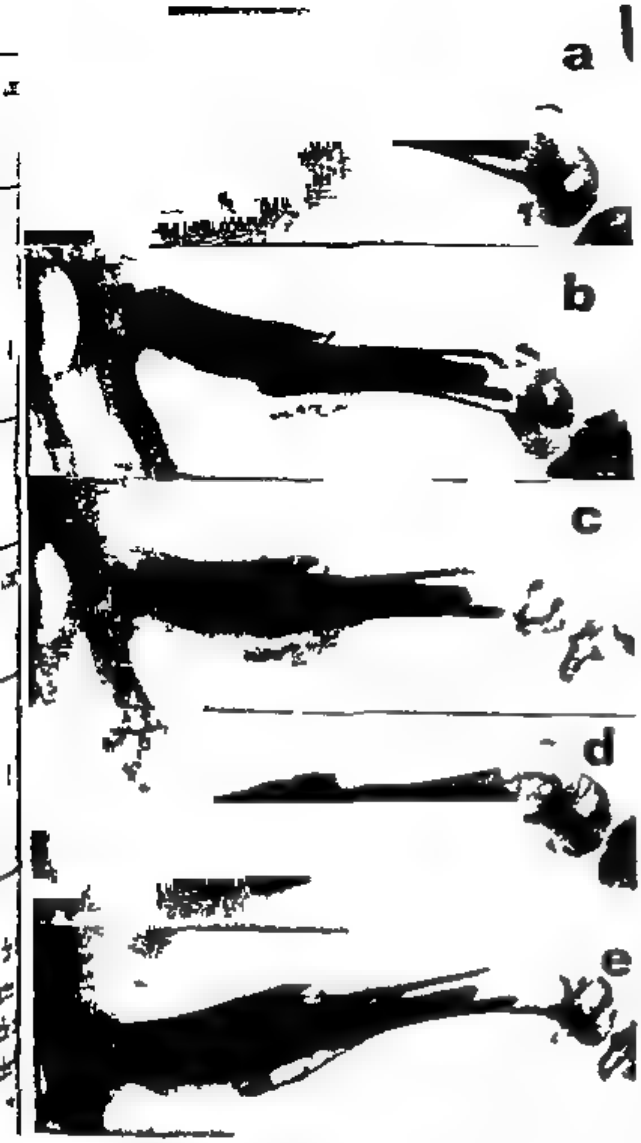

Figure 1 Healing of a laser cut femur
a Day of operation
b 7th day postoperatively
c 14th day
d 28th day
e 60th day

some remnants of cartilage and fibrous tissue were found in the united fractures up to 60 days after surgery These findings were similar to those in the controls. Microscopic differences between the laser cut femurs and the controls were observed at the cut edges of the bone On the day of operation some charred bone debris from the cut bone edge was seen The most notable finding revealed empty bone lacunae at a distance of about 450–500 microns from the osteotomy site on the remaining bone fragment (Figure 2).

Figure 2 Margin of laser cut bone edge Note the charred edge empty lacunae and pycnotic nuclei on the left side of the preparation (approximately ×212)

Pycnotic nuclei in the lacunae marked the transitional area between 'lased' and viable bone

The cellular damage was much wider than the apparent damage to the bone matrix. All the osteocytes remained in place after osteotomy with the Gigli saw Another notable feature was the sealing of small blood vessels in the bone (Figure 3) This phenomenon has been described by Ben Bassat et al. (1976), Verschueren (1976) and Frishmen et al. (1974)

Figure 4 shows the osteotomy site after 7 days. Non viable bone and charred debris lie between the fragment and the haematoma.

Charred debris was incorporated into the callus and could be detected at the healed fracture site up to 60 days following the operation

Microangiographic studies

There was a marked vascular response at the fracture site as early [illegible] 7 days after osteotomy New vessels were formed, mainly in the periosteum and to a lesser degree in the endosteum (Figure 5) The vascular hyperplasia, which reached its peak 14 days after osteotomy, declined gradually

Twenty-eight days after osteotomy the vascular hyperplasia was still noted, but at this stage the development of an overt pseudarthrosis in one specimen could be observed

Figure 3 A sealed blood vessel in the bone at the laser cut edge Note also the empty lacunae (approximately ×212)

Figure 4 Osteotomy site after 7 days. charred bone has broken off the cut edge [illegible] the empty lacunae are seen (×85)

Figure 5 Osteotomy site after 7 days Periosteal vascular hyperplasia and endosteal vessels growing towards the fracture site (×5 7)

Figure 6 A 28-day-old osteotomy developing a pseudarthrosis Note the sequestrum [illegible] (×3 7)

(Figure 6) Endosteal vascular hyperplasia was marked in the femurs that united after 60 days.

DISCUSSION

Our findings correlate well with those of other authors (Verschueren 1976, Moore 1972) An initial delay in wound healing was also observed by Hall (1971) This initial delay is usually overcome at a later stage by the natural tissue healing process. A paraincisional necrotic zone due to thermal damage was observed macroscopically It consisted of the charred bone which usually fell off, and an area half a millimetre wide in which the bone lacunae were devoid of osteocytes. This zone was at least twice as wide as a comparable area of damaged skin and mucous membranes, as demonstrated by Ben Bassat et al (1976) A possible explanation is the fact that bone is a better heat conductor than soft tissues. The damaged bone was microscopically divided into three zones a) the charred bone in the near vicinity of the cut area, which broke off during the laser cutting process, b) dead bone devoid of osteocytes, c) a transitional zone in which pycnotic nuclei were seen in the lacunae (Figure 2) We assume that further fragmentation of the laser cut bone occurs during the first postoperative week (Figure 1b) and that this is due to thermal damage which is more extensive than that which can be detected by simple light microscopy

Haemostasis in laser cut tissues is obtained by sealing off small blood vessels without clotting (Ben Bassat et al 1975), which was also observed by us in the laser cut bone edges (Figure 3) The vascular response, as examined in the microangiographic specimens, was essentially the same in the laser cut femurs and in the controls. It was compatible with the findings of other authors (Gothman 1961, Rhinelander 1973)

The internal fixation employed by us was not a rigid one and weight-bearing was not prevented Thus hypertrophic callus formation was anticipated The initial delay, caused by bone necrosis and further fragmentation, was overcome between the 4th and 8th week after surgery and was helped by the large callus which did in fact develop

Verschueren (1976) employed compression plates in laser osteotomized femurs of dogs. In his series, bone healing was delayed for a much longer period than in the present report. This difference could be attributed to a) a different species of experimental animal, b) the rigid internal fixation method, which prevented the formation of a large callus.

In our small series the incidence of pseudarthrosis in the laser cut femurs was lower than in the control group, after a period of 60 days. However, since the series is a small one, we do not consider the evidence to be conclusive In spite of dead bone and charred debris at the fracture site, there were no deep-seated bone infections in our series, as might have been expected The only two superficial wound infections occurred in the control group We suggest that better haemostasis and an absolute "no touch technique" with the laser beam might explain this finding

The implications of our study are

A delay in healing after laser osteotomy is to be expected so long as the paraincisional bone necrosis cannot be minimized Further experimental studies with an intermittent pulse beam, or with an inbuilt cooling system, should be conducted for possible solutions to this problem A solution of this kind might also prove that the laser is a superior surgical instrument, particularly on account of its haemostatic effects and better aseptic properties.

ACKNOWLEDGEMENTS

The technical preparation of the specimens, as well as the histology and photography were carried out at the Department of Medical Embryology and Teratology Sackler School of Medicine Tel-Aviv University, and the Chaim Sheba Medical Center, Tel Hashomer, Israel

I wish to thank Professor L Nebel for his [illegible] histological specimens and the photographs, respectively

REFERENCES

Ben Bassat, M, Ben Bassat, M & Kaplan, J (1976) An ultrastructural study of the cut edges of skin and mucous membrane specimens excised by carbon dioxide laser *Proceedings of the 1st International Symposium on Laser Surgery* Jerusalem Academic Press 1976

Crock, H V (1967) *Blood supply of the lower limb bones in man (descriptive and applied)* E & S Livingstone, Edinburgh

Frishman, A, Gassner, S, Kaplan, J & Ge[illegible] (1974) Excision of subcutaneous fibrosarcoma in mice A comparative experimental study of various methods. *Israel J med. Sci.* 13, 637–641

Gothman, L (1961) Vascular reaction in expe[illegible]

Ha[illegible] 222–225

Horoszowski, H, Farine, I & Engel, J (1976) The Laser in orthopaedic surgery *Proceedings of the 1st International Symposium on Laser Surgery* 1975, Jerusalem Academic Press

Moore, Y H (1972) Laser energy in orthopaedic surgery International Congress of Orthopaedic Surgeons, Tel-Aviv

Rhinelander, F W (1973) Effects of medullary nailing on the normal blood supply of diaphyseal cortex A.A O S Instructional Course Lectures 22, 161–187

Verschueren, R (1976) *The CO_2 laser in [illegible] surgery* Van Gorcum, Assen, Amsterdam.

Correspondence to C. Tauber, M D, Department of Orthopaedic Surgery A, The Chaim Sheba Medical Center, Tel Hashomer, Israel.

Acta orthop. scand 50, 391–398, 1979

ASSESSMENT OF FRACTURE HEALING BY VIBRATION

TAKASHI SEKIGUCHI* & TAKUJI HIRAYAMA**

* Sekiguchi Orthopedic Hospital, Maebashi, and
** Nippon Electronic Co., Ltd., Tokyo Japan

The wave signal from percussion of a bone (i.e. percussion-note) has been used to evaluate the extent of bony consolidation after fracture

Forty-one cases with a fresh tibial fracture and eight cases of delayed union of the tibia were investigated. The medial malleolus of the tibia was struck with a tipper and the vibration signal was picked up at the medial region of the tibial tuberosity The changes in the signal waveform of the percussion-note with time were investigated

As healing proceeds, the signal waveform of the fractured bone approaches that of intact bone In cases of delayed union, the character of the wave does not improve sufficiently with time. The authors are convinced that this is a promising new method for the early diagnosis of delayed union.

Key words delayed union, fractures, fracture healing, percussion note, vibration

Accepted 4 1 79

Lippmann (1932) reported on the usefulness of a percussion-auscultation method as an indicator of displacement in femoral fractures. McGaw (1942) used percussion-auscultation in the assessment of fracture healing in the femoral neck, femoral shaft and tibia Jernberger (1967) introduced vibrations at frequencies from 20 to 10,000 Hz into the fractured tibia, investigated the propagation of vibration and suggested the possibility of assessment of fracture healing by vibrations. Dencker & Moberg (1967, 1968) tested soft tissue interposition between the fragments by the diminution of propagation using vibration at a frequency of 1,000 Hz

It appears, however, from the reports above that the use of vibration to study the process of fracture healing is very complicated and reliable diagnostic criteria have not yet been established.

The purpose of the present investigation was to establish a new method of estimation of fracture healing using vibrations within the audible range It was hypothesized that the vibration properties of bones change when the bone is fractured and as healing of the fracture progresses If we could record the note for each stage as a signal waveform, it could be used as an objective measure of the condition of the fracture and by measuring the changes in the signal waves we could follow the healing process. We carried out a series of experiments to check this theory

MATERIALS AND METHODS

At each stage of this study intact bone of the uninjured extremity was compared with fractured bone Forty-one cases of fracture of the tibial shaft were followed from the time of injury Twenty-two of these cases were treated conservatively and 19 were operated upon. The age distribution is shown in Figure 1 Eight cases of delayed union in each of which cancellous bone grafting was performed, were similarly investigated.

0001–6470/79/040391–08$02.50 0

© 1979 Munksgaard, Copenhagen

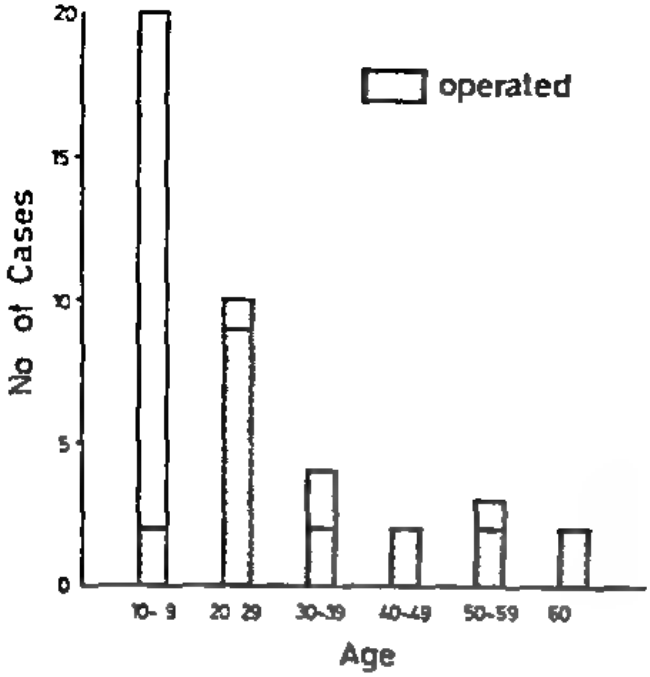

Figure 1 Age distribution in 41 cases of fresh fracture of the tibia

A diagram of the tapper is shown in Figure 2 and the vibration signal measurement system in Figure 3 The wave signals produced when intact bones are tapped with this tapper will have the same pattern (Figure 4) Therefore using this tapper we can obtain a uniform percussion note (p-note) The medial malleolus is struck with the tapper and the vibration is picked up at the medial region of the tibial tuberosity and transmitted to the synchroscope The resulting

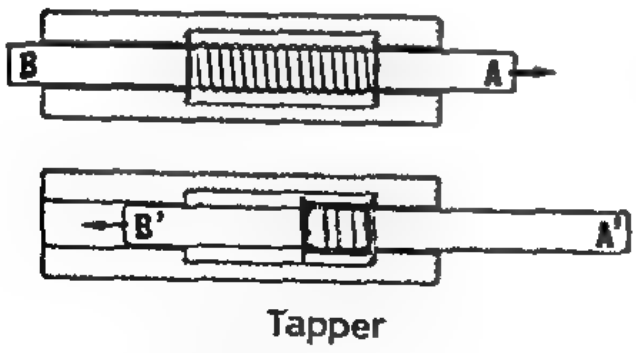

Figure 2 The structure of the tapper
Draw A to A and release Then B returns to B and taps the bone

	Cylinder	Spring
Material	wood	piano wire
Diameter	15 mm	0 6 mm
Length	170 mm	[illegible] mm
	plane ends	coil interval 60/16mm

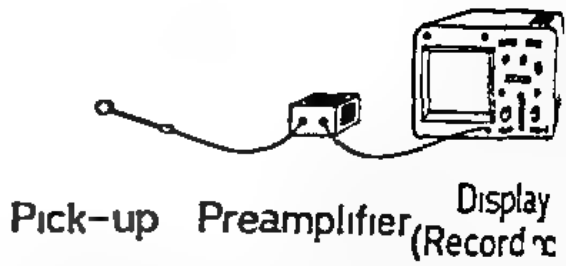

Figure 3 The vibration signal measure diagram.
Pick up Matsushita (National) EFP P600 Piezoelectric sensor
Preamplifier transistorized amp.
power source dry battery
frequency band 10 Hz~100 KHz
Display (recording) Iwasaki SS5100 CRT synchroscope.

waveform is photographed with a polaroid camera for later evaluation

The p-note induced by the tapper may also picked up at the medial region of the tibial tuberosity with a stethoscope bell and recorded tape It is played back to a wave analyser and analyzed Simultaneously each p-note is transmitted to the wave analyser and the waveform corresponding to it recorded and studied.

Initial X ray findings were classified as follows
Group A. Only a crack or a slight displacement
Group B A transverse fracture or an oblique fracture with moderate displacement
Group C. A free fragment
Group D A comminuted fracture
The relationship of these X ray findings to the distribution pattern of the waveforms of the p note was evaluated

RESULTS

The signal waveform of the p-note of an intact bone has a nearly constant pattern Figure 4 shows two such signal waveforms for intact bones. The horizontal axis is a time scale, 2 ms per cm The vertical scale is the output signal 2 V per cm The waveforms exhibit the standard envelope pattern of an attenuated curve. Note that in the first 2~3 ms after the build-up time the intact bone has a superimposed 4~5 cycle wave.

Figure 5 compares the p-note of fractured bones (on the right) and intact ones (on the

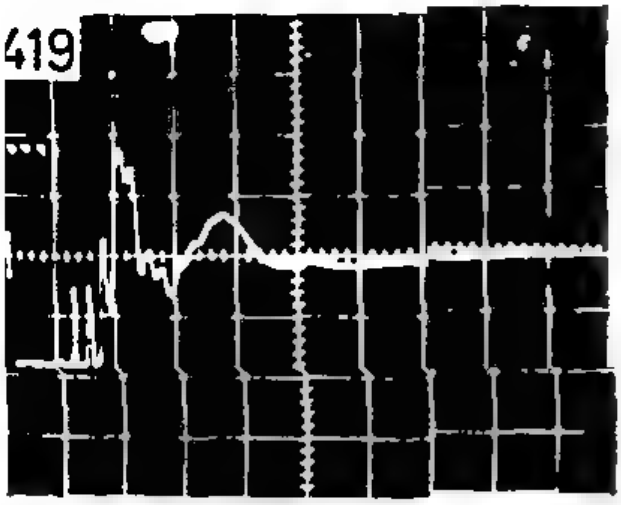

Type 3 (intact)

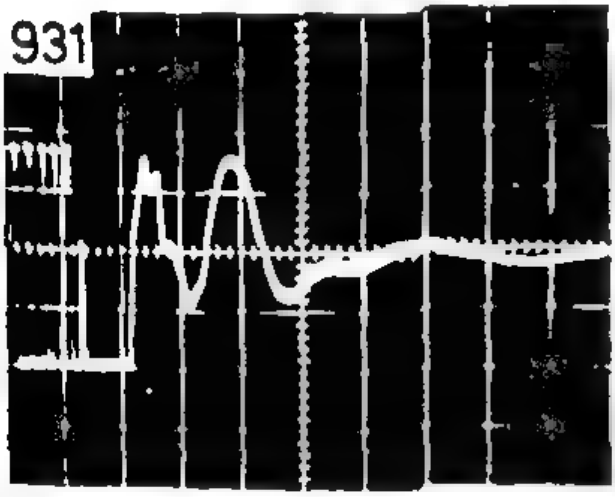

Type 3 (intact)

Figure 4 The signal waveform of the p-note of an intact bone

left). For the fractured bones, in the first 2 ms there is a one cycle wave in Figure 5A and a two cycle one in Figure 5B

Though there is variation between the waveforms obtained in our investigation, both in the intact bone and in the fractured bone, we are able to classify the signal waveforms as follows

Type 1 is a one cycle wave (the right side of Figure 5A)

Type 2 is a two or three cycle wave (the right side of Figure 5B)

Type 3 is a four or five cycle wave (the left side of Figure 5A and B)

Type 1 and 2 are pathological and Type 3 is normal

The distribution of the different waveforms in 41 cases of fresh fracture is shown in Table 1 Pathological waveforms are seen in 40 out of the 41 cases. The one case showing Type 3 will be discussed later

Figure 7 shows the frequency spectra and p-note waveforms corresponding to the Type 1 and Type 3 results of Figure 6 In the range 700 to 4800 Hz, there is a remarkable difference between the intact and the affected parts The spectra at low frequencies are nearly equal but at high frequencies there is remarkable attenuation for the fractured bone This difference in high frequencies explains both the differences in waveform seen in Figure 7B and the changes in p-note waveform and in the p-note itself

Figure 8 illustrates that the signal wave of the fractured bone tends to improve gradually to finally equal that of the intact bone Just after injury the waveform of the fractured bone is Type 1 At the stage of clinical and roentgenographic union it is Type 2 and 1 month later it is Type 3

The distribution of the different waveforms at the stage of clinical and roentgenographic union and weight-bearing is shown in Table 2 The original number of Type 1 cases is reduced to two The majority exhibit Type 2 waves.

Following complete union there is almost no difference in the signal waves of the intact

Table 1 Waveform types in fresh fractures

Waveform type	No of cases
Type 1	25
Type 2	15
Type 3	1
Total	41

A Case 1. A 19-year-old female with a shaft fracture of the right tibia

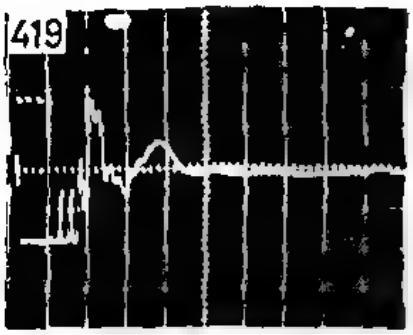

Type 3 (intact)

Type 1 (fractured)

B Case 2 A 14-year-old boy with a shaft fracture of the right tibia

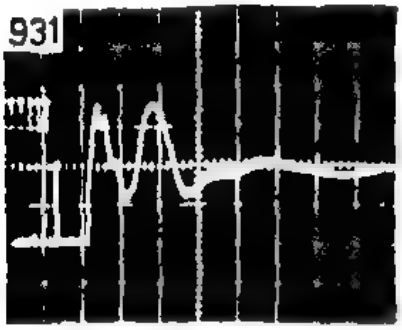

Type 3 (intact)

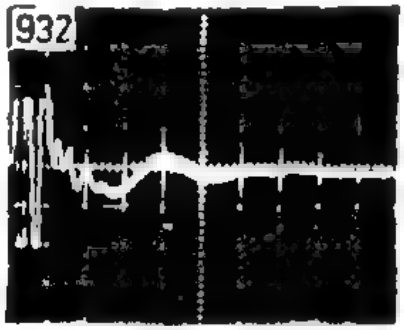

Type 2 (fractured)

Figure 5 The signal waveform of the p-note of fresh fractures and their corresponding X-rays.

C. Case 3. A 30-year-old male with a shaft fracture of the right tibia

After two and a half months of conservative treatment

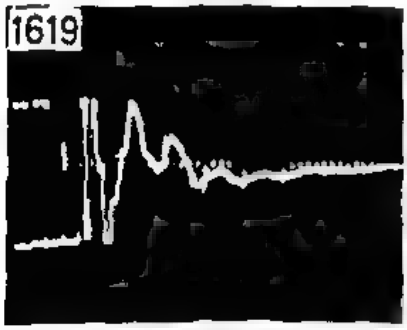

Type 3 (intact)



Type 1 (fractured)

Figure 6 Fracture of the tibial shaft in which wave analysis was performed

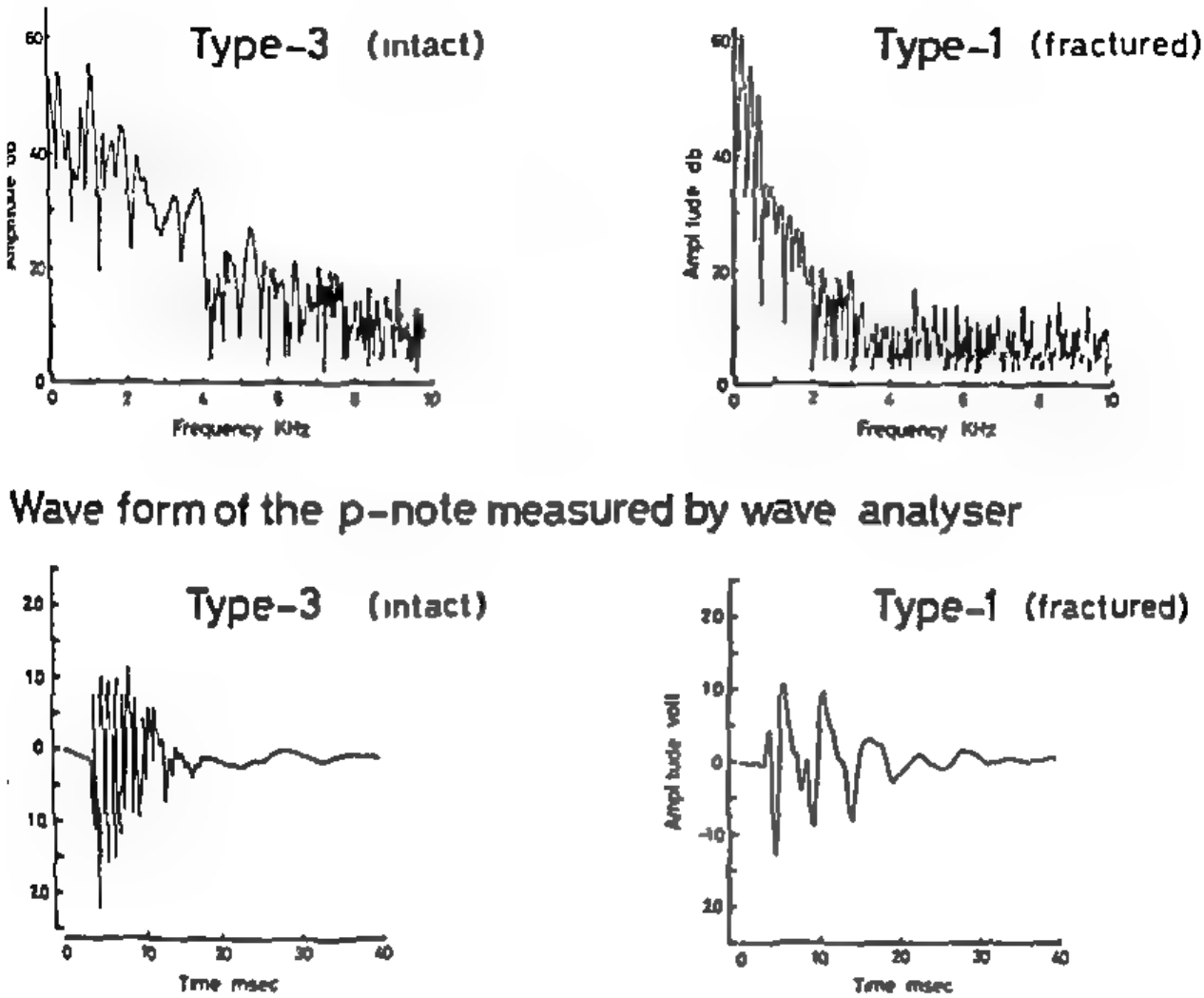

igure 7 The frequency spectra and p-note waveform corresponding to Figure 6, and obtained using the ave analyser

id the fractured bone The period necessary r normalization of the signal wave is shown Table 3 The shortest time is 2 months and the longest 1 year, and the average period is 4 4 months. This average period is 1 9 months longer than the average period (2 5 months) for clinical and roentgenographic union

able 2 Waveform types at the stage of clinical and roentgenographic union

Waveform type	No of cases
Type 1	2
Type 2	37
Type 3	2
Total	41

In delayed union the signal waveform shows no improvement with time In each case abnormal mobility was confirmed by operation Cancellous bone grafting was performed The distribution of the waveforms is shown in Table 4 There were two Type 1 cases, five Type 2 cases and one Type 3 The periods necessary for normalization of the p-note signal waves varied from 4

A. Two days after injury

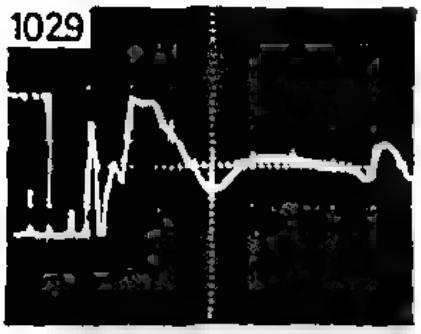

Type 3 (intact)

Type 1 (fractured)

B. Three months after operation (the stage of weight bearing)



Type 3 (intact)



Type 2 (fractured)

C. Four months after operation



Type 3 (intact)



Type 3 (fractured)

Figure 8 Changes in the signal waveforms of p-notes corresponding to fracture healing A 35-year-old male with a shaft fracture of the left tibia

Table 3 Period necessary for the normalization of the signal wave

Period necessary for the normalization of signal wave	No of cases
2 months	2
3 months	5
4 months	4
5 months	7
6 months	6
6 months~1 year	5
Total	29

delayed union received primary treatment in other hospitals, we could not investigate the process of p-note before our operation

The distribution of the signal waveforms corresponding to the initial X ray findings are shown in Table 5 In Group A four out of 14 cases are of Type 1, and nine are of Type 2 In Group B 15 out of 21 cases are of Type 1 and six are of Type 2 In this group the majority exhibit Type 1 In Group C all six cases are of Type 1 In other words, the more noticeable the displacement on the X-ray, the higher the number of cases exhibiting Type 1

Table 4 Cases of delayed union

Case no	Age	Time elapsing before operation	Waveform before operation	Waveform at the stage of clinical and roentgenographic union	Period necessary for normalization of the p-note
1	44 years	1 year 6 months	Type 2	Type 2	———
2	41	1 year	2	2	1 year
3	23	5 months	1	2	1 year
4	19	11 months	3	2	5 months
5	59	1 year	1	2	1 year
6	56	4 months	2	2	6 months
7	42	1 year 10 months	2	2	7 months
8	25	4 months	2	2	4 months

Table 5 Waveform type corresponding to the X-ray findings for fresh fractures (see text for X-ray classification)

X-ray	No of cases	Waveform type		
		Type 1	Type 2	Type 3
Group A	14	4	9	1
Group B	21	15	6	
Group C	6	6		
Group D	0			
Total	41	25	15	1

months to 1 year In case 4 the initial waveform was Type 3 and at the stage of weight-bearing the waveform was Type 2. This will be discussed later Because all of the cases of Cases in Group D were not seen in this study The unusual case showing the signal wave of Type 3 at the stage of injury cited earlier was in Group A In this case (and in the similar one with delayed union) we believe that the instrumentation amplification was inadequate to reveal any abnormality

If there is edematous swelling at the medial malleolus, the input is unstable and the correct p note cannot be obtained Therefore edematous swelling in the malleolar region makes the bone unsuitable for this kind of investigation

In our experiment, it was shown that the p-note, if it passes through one joint, loses the high frequency spectrum For example, if we tap at the lateral condyle of an intact

humerus and pick up the p-note at the acromion, the signal wave is Type 1 Similarly, if we tap the lateral malleolus of an intact fibula, the signal wave of the p-note picked up at the medial region of the tibial tuberosity is Type 1 On the other hand with greater amplification, we can observe a p-note exhibiting the signal waveform of Type 3 at the acromion

DISCUSSION

Thirty-seven out of the 41 cases of fresh fracture exhibited a signal waveform of Type 2 at the stage of clinical and roentgenographic union and weight-bearing so that the period necessary for normalization of the p-note waveform is longer than the period necessary for clinical and roentgenographic union, i e, this test may be more sensitive to pathological changes in bones than X-rays The results led us to conclude that, by following changes in the p-note with time, it should be possible to tell when the fracture is healing satisfactorily and to get an early indication of a delayed union

The lower leg consists of the tibia and the fibula Therefore, we have to check the influence of propagation of the vibration through the fibula as well But the results of our investigation indicate that the influe the fibula is negligible

Our study has been limited to fractu the tibia because the tests are easil formed in this area But in future we b extend our procedure to the femur a humerus.

ACKNOWLEDGEMENT

The authors wish to express their thanks t Naoki Morisaki Department of Orth Surgery, Tokyo Women's Medical College encouragement and advice throughout this

REFERENCES

Dencker, H & Moberg E (1967) Early dia of interposition in fractures with the a vibrator *Acta orthop scand* 38, 396.

Dencker, H & Moberg, E (1968) Diagno soft tissue interposition in shaft fractu the humerus and femur by measuring th duction of vibrations across the fracture. *chir scand* 134 540–542.

Jernberger H (1967) A method for a registration of fracture healing *Acta o scand* 38, 393–394

Lippmann R K (1932) The use of auscul percussion for the examination of fractu *Bone Jt Surg* 14 118–126

McGraw, N H (1942) Osseosonometry *Surg* 45, 195–205

Correspondence to Takashi Sekiguchi, 2–1–6 Chiyodacho Maebashi Gunma Japan

Acta orthop scand 50, 399–406, 1979

'HE VASCULARIZATION IN THE AMPUTATION STUMPS)F RABBITS

Microangiographic Study

HR HANSEN-LETH

epartment of Orthopaedic Surgery U, Rigshospitalet, Copenhagen, Denmark

With the aid of microangiography the vascularization in the amputation stumps of 108 rabbits was studied, both in extremities with normal circulation and in those supplied with collaterals It was found that the vascularization of the normal leg was altered by amputation, with the development of newly-formed, pathological, spirally-twisted vessels. Closure of the stump with myoplasty, however, counteracted this vessel formation, and hypervascularization took place through normal arteries. After amputation of extremities supplied with collaterals, the influence of amputation on collateral function and vascularization in the amputation stump was dependent on the time interval between arterial occlusion and amputation

Key words amputation, collateral circulation, microangiography, myoplasty

Accepted 2 1.79

'he vascularization in the operated extremity s altered by amputation, primarily because of mputation trauma and secondarily because f the change in muscle function (Hansen-.eth Karle 1978a) Utilization of various echnical procedures during amputation can mprove the vascular conditions in the mputation stump This is of particular mportance in amputations on extremities upplied by collaterals, where the preoperative blood flow is reduced at the level of the imputation.

In this work the morphological changes in the vascular structure after amputation were investigated by the use of microangiography in rabbits with normal circulation and in rabbits supplied with collateral circulation in the operated extremity

MATERIAL AND METHODS

The experimental animals were 108 adult rabbits of both sexes weighing 3 4 kg Sixty animals had normal vascular anatomy in the leg before amputation The amputation techniques and the amputation levels are presented in Table 1 Ligation of the femoral artery was carried out on 48 rabbits, of which 34 were subsequently amputated on the crus on the same side of the body after varying time intervals (Table 1)

The operations were performed on animals anaesthetized with Nembutal In proximal crus amputation the bone was sawn through at the tibiofibular synostosis and the muscles were severed 1 cm distal to the bone stump In myoplastic closure the muscles were sewn together over the bone stump, whereas in the absence of myoplasty they were excised at the level of the bone stump When amputations were performed distally on the crus the muscles were severed distal to the muscle-tendon transition of the triceps surae, and the bone stump was closed myoplastically In osseous plugging the medullary cavity was plugged with cortex obtained from amputated bone The femur was amputated in the midbone and was closed with myoplasty The femoral artery was located proximally, isolated from the vein and femoral nerve and double-ligated with silk thread Minor defects on the tips of the amputation stumps due to stress developed

0001–6470 79 04039 7–08$02.50.0

© 1979 Munksgaard Copenhagen

Table 1 The amputation techniques and the amputation levels

Rabbits with undisturbed vascularization

Amputation level	Cases	+ myoplasty	− myoplasty	+ medullary plugging
Amp prox. cruris	34	18	16	(9)
Amp distalis cruris	14	14		
Amputatio femoris	12	12		(3)
	60	44	16	(12)

Rabbits with collateral circulation in the amputated leg

Operation	Cases	Time interval between ligation and amputation			
		1 hour	3 days	2–4 weeks	7–13 weeks
Ligatura art. femoralis	48				
Ligatura art fem + amp prox. cruris	34	3	12	11	8

in 16 animals, but no infection was detected in any of these cases.

The animals were sacrificed from 1 hour to 130 days, postoperatively, and microangiography was performed After heparinization, a catheter was implanted in the abdominal aorta, the hindquarters were perfused with saline under a pressure of 1 m water, followed by an infusion of 25 per cent Micropaque, 10 per cent Formalin and ½ per cent Berlinerblue for about three-quarters of an hour After removal of the skin the hindquarters were fixed in 10 per cent formalin and then photographed with a Machlett A E G X-ray tube at a distance of 40 cm Industry film Gevaert Structurix D7 and Kodak PE 4006 was used (exposure time 1 minute, 7 mAmp/24 Kv)

RESULTS

The vascularization of the amputation stumps after *amputation in extremities with normal circulation* is presented in Figure 1 It can be seen that amputation was accompanied by vascular changes, partly dependent on the level of amputation and partly dependent on the nature of stump closure *Proximal amputation of the crus closed with myoplasty* caused hypervascularization for from ½–10 weeks, postoperatively (Figure 2), whereas *amputation* at the same level *without myoplasty*, as well as *distal amputation of the crus*, resulted in transient hypervascularization, the vascularization of t stump in these latter cases was implemen predominantly by newly formed, spira twisted vessels (Figures 3 and 4). Increa vascularization of the stump of quite sh duration was similarly observed af *amputation of the femur*, without contr filling of the large arteries, and spira twisted vessels were seen 3 weeks af surgery A decrease in vascularization of t stumps was found in all of the amputa animals 10 weeks after amputation, and th was accompanied by the appearance contrast filling of irregularly-dilated, twis veins. Osseous plugging of the medull cavity produced no distinct change in the vascular conditions.

Ligation of the femoral artery prior amputation caused an initial reduction vascularization of the crus musculo (Figure 5) but a moderate hypervascula ization through collaterals, as well as th appearance of newly-formed, spirally-twis vessels, occurred 1 week later Hyper vascularization declined after 5 weeks whereas the collaterals were functional 16 weeks after arterial occlusion.

When amputation was performed prim ually on the crus 1 hour after ligation of th femoral artery, only slight collateral devel

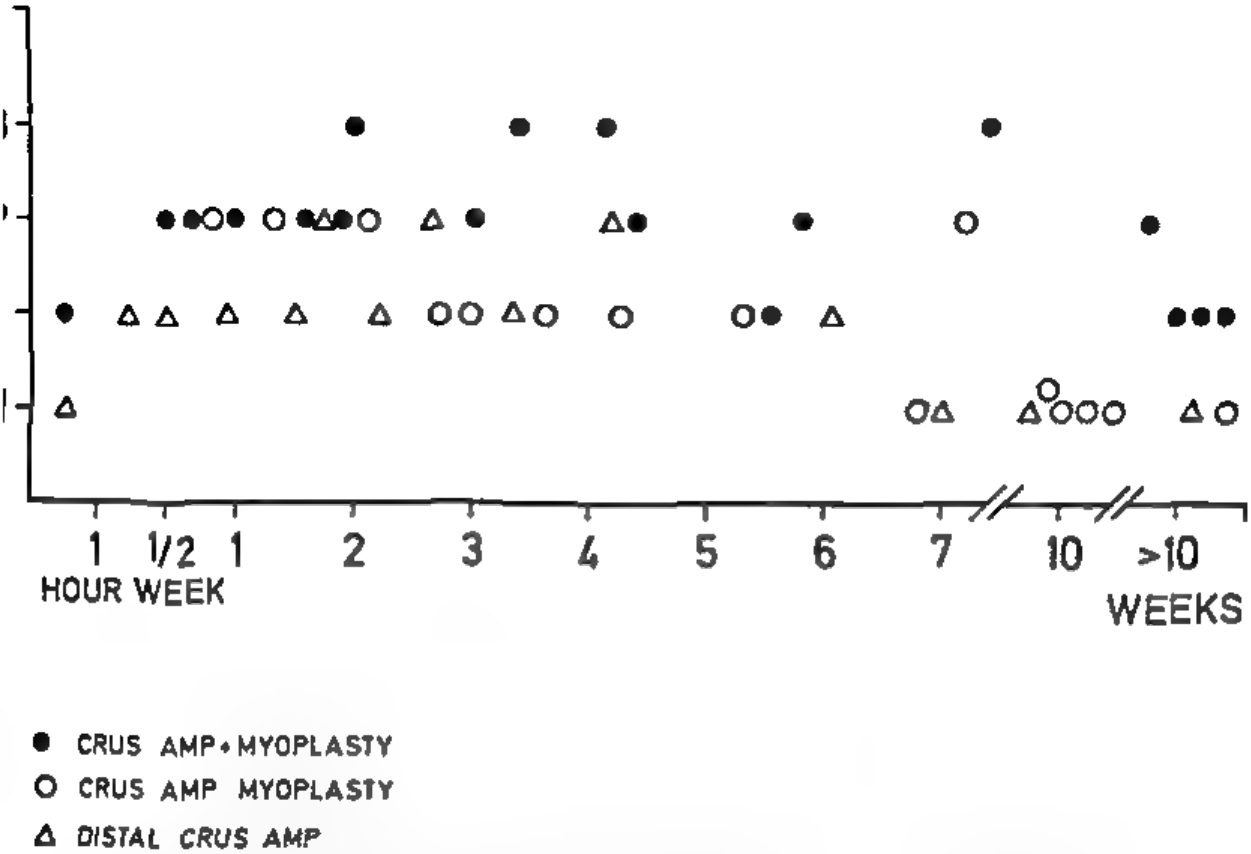

igure 1 Vascularization in the amputation stump Explanation of numbers on the ordinate 1 – Same s at the corresponding level on the unoperated leg 2 – Moderately increased 3 = Markedly increased 1 = Less than at the corresponding level on the intact leg

Figure 2 Proximal crus stump with myoplasty 9 weeks after amputation (rabbit R42)

Figure 3 Proximal crus stump without myoplasty 6 weeks after amputation (rabbit P9)

Figure 4 Distal crus stump with myoplasty 14 weeks after amputation (rabbit R31)

ment and vascularization of the stump w seen, but if the amputation was comb with osseous plugging of the medullary cr a dilation of the collaterals and hy vascularization of the amputation stump w observed (Figure 6) If crus amputation w undertaken 3 days after arterial ligation collaterals immediately became functio after amputation, and an initial hy vascularization of the stump was (Figure 7) After 10 weeks the circulation w dominated by dilated veins and increa numbers of spirally-twisted vessels (Figure When amputation was carried out 2–4 we after arterial occlusion no clear initial hy vascularization of the amputation stump w found, and the manifestation of stump hy vascularization declined with increasing ti intervals between arterial occlusion a amputation, despite the occurrence of dila twisted collaterals on the femur (Figure 9)

The results of this investigation therefo indicate that amputation of an extrem

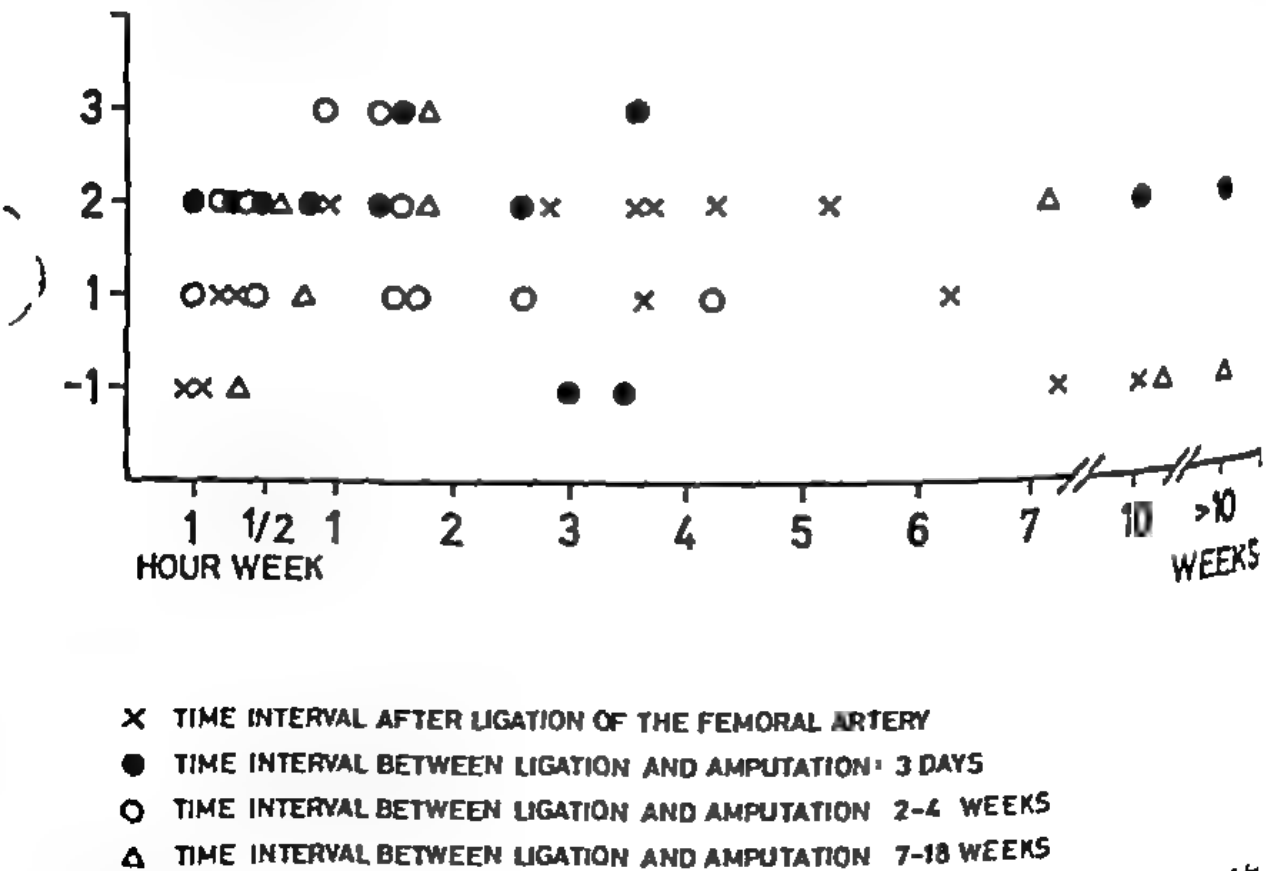

Figure 5 Vascularization in the amputation stump supplied with collaterals (See text to Figure 1 for explanation)



igure 6 Crus amputation with myoplasty and edullary plugging 12 weeks after amputation abbit N55)

Figure 7 Crus amputation 3 days after femoral artery occlusion photographed 1 hour after amputation (rabbit N4)

upplied with collaterals produces a hyper ascularization of the amputation stump hich is similar to that found after amputa on of an extremity with a normal circula ion but that this effect is dependent on the ime interval between arterial occlusion and mputation

DISCUSSION

Previous investigations have shown that amputation evokes hypervascularization in the amputation stump as well as the formation of newly formed spirally twisted

Figure 8 Crus amputation 3 days after femoral artery occlusion photographed 10 weeks after amputation (rabbit N33)

Figure 9 Crus amputation 18 weeks after femoral artery occlusion photographed 2 days after amputation (rabbit N47)

Figure 10 Cross section of triceps surae a) in an unoperated leg, b) 4 weeks after proximal crus amputation without myoplasty, c) 3 weeks after distal crus amputation with myoplasty

vessels (Hulth & Olerud 1962, Erikson & Olerud 1966, Hansen-Leth & Reimann 1972) This hypervascularization may in part be a component of a reparative process and may in part be a consequence of immobilization of the amputated extremity (Hulth & Olerud 1961) Muscular trauma in the amputation stump is greatest in amputation without myoplasty The muscles are excised in the region of amputation and are retracted This involves arterial occlusion and arterial dilatation and a rise in blood pressure in the remaining intact arteries, which induces the development of new circulatory paths Erikson (1965) found that spirally-twisted arteries occurred in one-half of the amputation stumps in amputations without myoplasty, and he proposed that both a metabolic disturbance as well as an alteration in the nervous stimulation were involved in the formation of the vessels.

It was found in the present investigation that spirally-twisted vessels are present in the amputation stump 1–2 weeks after amputation, irrespective of the amputation technique or amputation level However, while the hypervascularization of the stump in proximal crus amputations with myoplasty was implemented by arteries of normal appearance, it was brought about by newly-formed, spiral arteries in the stumps of proximal crus amputations without myoplasty, in distal crus amputations and in femur amputations with myoplasty (Figure 10) The length and small diameter of these vessels considerably increased the flow resistance and, hence, reduced the muscular blood flow Determinations of muscular blood flow in amputation stumps (Hansen-Leth 1976, 1977) disclosed that blood flow in distal crus amputations and in proximal crus amputations without myoplasty was less than in proximal crus amputations with myoplasty In femur amputations in the rabbit Itohara (1972) found that myoplasty induced hypervascularization in the stump in contrast to decreased vascularization in amputations without myoplasty Hansen Leth & Reimann (1972) observed in amputations in not fully-grown rabbits that spiral vessels were more numerous in the absence of myoplasty

After amputation there is an immobilization of the amputated leg as well as a muscular inactivity in the amputation stump After immobilization of the hind legs of rabbits in plaster casts Ferguson & Akahoshi (1960) and Hulth & Olerud (1961) observed a hypervascularization and a dilation of the larger arteries, whereas increased formation of small vessels was seen after muscular inactivity resulting from tenotomy (Ferguson & Akahoshi 1960) In the present work it was found that the hypervascularization after amputation with myoplasty corresponded to the vascular changes occurring after immobilization, whereas amputation without myoplasty evoked vascular changes corresponding to those described after tenotomy

The results of the present investigation therefore suggest that the amputation trauma, as well as the immobilization and muscle inactivity, bring about the vascular changes in the amputation stump There is less amputation trauma and muscular inactivity in amputations with myoplasty, and hypervascularization in these cases takes place through normal arteries

Crus amputation with myoplasty on an extremity supplied with collaterals similarly causes hypervascularization of the amputation stump, but its magnitude is dependent on the time interval between arterial occlusion and amputation Collaterals are preformed vessels and can quickly become functionally active after arterial occlusion (Krahl et al. 1954), but if the amputation is performed immediately after arterial occlusion vasospasm is aroused by the amputation (Erikson & Olerud 1966, Hansen-Leth & Karle 1978b) and this counteracts the collateral development If the collaterals are open and functional the amputation will rapidly produce a hypervascularization of the amputation stump In the case of amputations carried out after a longer time interval between arterial occlusion and amputation, however, no initial hypervascularization of the stump takes place, despite dilation of the supplying collaterals.

Schoop & Jahn (1961) differentiate between primary collaterals, which are anatomically unmodified vessels that rapidly become functionally active, and secondary collaterals, which are arteries that undergo anatomical development due to their new function in the course of weeks or months. These secondary collaterals have the appearance of dilated and twisted vessels, constituting a considerable resistance, and thereby reducing the muscular blood flow

The results of this investigation are in agreement with the findings of Schoop & Jahn (1961) The vascularization in the crus declines 8 weeks after ligation of the femoral artery, even in the presence of intact collaterals, and crus amputation after this time evokes a lower hypervascularization, despite the occurrence of dilated and twisted collaterals Similarly, determinations of muscular blood flow in the amputation stump after the development of collaterals (Hansen-Leth 1978) demonstrated an increased blood flow in the stump that was dependent on the time interval between arterial occlusion and amputation.

REFERENCES

Erikson, U (1965) Circulation in traumatic amputation stumps. *Acta radiol (Stockh)* Suppl 238

Erikson, U & Olerud S (1966) Healing of the amputation stump, with special reference to vascularization and bone *Acta orthop scand* 37, 20–28

Ferguson, A B Jr & Akahoshi, Y (1[illegible] Vascular pattern in immobilized, denervated devascularized limbs. *J Bone Jt Surg* [illegible] 617–622.

Hansen-Leth, C. & Reimann, I (1972) Amputation with and without myoplasty on rabbits with special reference to the vascularization *Acta orthop scand* 43, 68–77

Hansen-Leth, C (1976) Muscle blood flow after amputation with special reference to the influence of osseous plugging of the medullary cavity *Acta orthop scand* 47, 613–618

Hansen-Leth, C (1977) Muscle blood flow after amputation with special reference to the influence of the amputation level. *Acta orthop scand* 48, 10–14

Hansen-Leth, C (1978) The influence of collateral circulation on amputation *Int Orthop* [illegible] 195–198

Hansen-Leth, C & Karle, A (1978a) Intraarterial arteriographic study on vascular changes in amputated rabbits. *Acta orthop scand* [illegible] 457–463

Hansen-Leth, C & Karle, A (1978b) Amputation after development of collateral circulation. *Acta orthop scand* 49, 557–564

Hulth, A & Olerud, S (1961) Disease of the extremities II *Acta chir scand* 120, 339–[illegible]

Hulth, A & Olerud S (1962) Studies [illegible] amputated stumps in rabbits. *J Bone Jt Surg* 44-B, 431–435

Itohara, M (1972) The angiographical, pathological and histological investigations [illegible] amputation stump *J Jap orthop Ass* [illegible] 245–262.

Krahl, E, Pratt, G H, Rausselot, L M [illegible] Ruzicka, F F (1954) The collateral circulation in the arterial occlusion disease of the lower extremity *Surg Gynec Obstet* 98, 324–[illegible]

Schoop, W & Jahn, U (1961) Entwicklung [illegible] studien, arteriellen Kollateralen und [illegible] begriffliche definition. *Z Kreisl Forsch* [illegible] 249–254

Correspondence to Chr Hansen-Leth, Centralsygehuset, 7400 Herning, Denmark.

Acta orthop scand 50, 407–410 1979

. LATE NEUROLOGIC COMPLICATION OF COLIOSIS SURGERY IN CONNECTION /ITH SYRINGOMYELIA

NDERS NORDWALL & CARSTEN WIKKELSØ

epartment of Orthopaedic Surgery, and Department of Neurology, Sahlgren Hospital, oteborg, Sweden

A case of scoliosis in connection with syringomyelia is described. Theories are proposed to explain the progression of the neurological symptoms after surgical correction and fusion of the deformity Special points are emphasized that will aid in the recognition of syringomyelia in scoliosis patients.

i) Abnormal neurology, in particular a dissociated disturbance of pain and temperature in the upper extremity
ii) Abnormal localization of a scoliosis curve
iii) Rapid progression of the scoliosis.
iv) Bony anomalies of the upper cervical spine
v) Increased diameter of the cervical spinal canal.

Key words complications scoliosis, surgery, syringomyelia

Accepted 29 xi 78

coliosis has long been recognized in connec- ion with syringomyelia, which is always ientioned as one of the neurogenic causes of coliosis There is an abundant literature on yringomyelia and its etiology and treatment ut very few reports on the treatment of coliosis in association with this disease ave been published (Huebert & MacKinnon 969, Hall et al. 1976). In the present work, eurologic complications after surgical reatment for scoliosis in a patient with yringomyelia are reported Theories are roposed to explain the progression of yringomyelia in connection with the perative treatment of scoliosis, and special oints are emphasized for the recognition of yringomyelia in patients with scoliosis.

CASE REPORT

The patient is a 15 year-old boy normally delivered and with normal development. At the age of five, he refused for a period of 1 week to stand on his left leg and was thought to have meningitis. There were no known sequelea from this, and he was otherwise reported to be healthy with normal physical activity At the age of 13, a right convex structural scoliosis was noted and considered to be idiopathic The curve measured 37 degrees (Cobb) it corrected well in a Milwaukee brace to 28 degrees. The apex of the curve was at T5 In spite of adequate brace treatment the curve progressed, and after 2 years it was 55 degrees, extending from T1 to T10

It was then decided to operate. When the boy was admitted to hospital 4 months later, the deformity had rapidly increased further and now measured 80 degrees in a standing A P X-ray His skeletal age was 14 years, his iliac apophyses had not yet appeared. Routine neurological examination was normal, with normal tendon reflexes in the upper and lower extremities, and normal sensibility and muscle tone and power

At surgery the curve was corrected with a Harrington distraction rod inserted from T2 to L1 and fused. Nothing abnormal was experienced at the operation However because of unusual

0001–6470/79/040407–04$02.50.0

© 1979 Munksgaard Copenhagen

fragility of the laminae, a force of only 200 N was used for correction, while ordinarily 400 N is used (Nachemson & Elfstrom 1969). Postoperatively the curve measured 50 degrees.

Immediately after the operation the patient was well, with full sensibility and muscle function, voiding normally. Ten days later he complained of difficulty in voiding. Examination revealed a diminished sensibility for pain and touch at the T10 level and a positive Babinsky sign on the left side, but no paresis.

Six days later, however, the symptoms had progressed to spastic paraparesis and the patient was hardly able to lift his legs. There was diminished sensibility bilaterally from T10 distally. In addition, there was loss of the right biceps reflex and weakness of the triceps muscle of the right arm. Gas myelography showed a complete obstruction at the T10 level upwards, and obstruction at the cervical level from C5 and downwards, due to enlargement of the cervical medulla. The cervical spine had an increased sagittal diameter on X-ray. The diagnosis of syringomyelia was suspected.

The patient was again operated on 17 days after the scoliosis operation with decompressive laminectomy of T8 and T9. The dura was distended and the medulla was found to be bulging from several thin walled cysts containing a clear fluid, 2 cm³ of which was aspirated. The Harrington rod was in the original position and the remaining distraction force amounted to only approximately 50 N. The rod was left in place to stabilize the fusion.

Postoperatively, the patient was ambulated in a Milwaukee brace. First, crutches were used because of paraparesis. There was a steady regression of symptoms and increase of muscle power. Six months after the scoliosis operation the patient had normal muscle power in his arms, the legs still showed atrophy and slight weakness although muscle function tests all gave a normal (5) rating on a 0 to 5 scale. He walked without support, also on stairs, and had normal bladder and fecal control. The correction of the scoliosis remained unchanged at 50 degrees.

DISCUSSION

The deformity in this patient was first classified as an idiopathic curve, yet three traits were unusual for an idiopathic scoliosis. One was the high location of the curve in the spine, which occurs only in approximately 2 per cent of idiopathic cases (Nordwall 1973). Another was the sudden onset of a fast progression of the deformity, 25 degrees in 4 months. Such a fast progression is [illegible] common in idiopathic scoliosis. A third [illegible] most important unusual trait was the widened diameter of the cervical spinal canal, visible on plain radiograms. These signs would all make a neurological diagnosis probable, and are compatible with syringomyelia.

Various neurological diseases are [illegible] complicated by scoliosis and syringomyelia considered to be one such cause of deformity. In different reports the incidence of scoliosis in syringomyelia has been from 20 to 80 per cent (Perret 1963, McIlroy & Richardson 1965, MacRae & Standen 1966), the incidence being higher and the scoliosis more severe if the neurological disease starts before the end of the growth period. The spinal deformity may appear before the onset of neurological symptoms (Hertel et al. 1973).

The only work describing operative treatment of scoliosis in connection with syringomyelia is that of Huebert & MacKinnon (1969). These authors report two cases treated surgically for scoliosis, one of which became paraplegic after the operation. As these authors point out there is obviously an increased risk in corrective operative treatment of these patients, and it is [illegible] important to recognize and differentiate patients with syringomyelia from those with idiopathic scoliosis before the operation.

Clinically, the first symptoms of syringomyelia are usually a dissociated disturbance of pain and temperature sensibility in the upper extremity. There is usually a slow progression, although a fast progression has been reported as well (McIlroy & Richardson 1965). The first symptoms can be explained by the location of cysts centrally in the cord. As the cavities multiply and grow other parts of the medulla will be compressed or destroyed, producing muscle weakness, atrophy and spasticity.

Most commonly the cervical spine is involved. Bony anomalies are found in the upper part of the spine in approximately [illegible] per cent of these patients (MacRae & Standen

966, Logue 1971) and often syringomyelia is ssociated with defects such as Arnold Chiari eformity, basilar impression, spina bifida nyelomeningocele and Klippel-Feil syndrome lso, patients with syringomelia developing at young age have been shown to have an ncreased diameter of the cervical spine ompared with normal (Wells et al 1959, Iertel 1973)

Huebert & MacKinnon (1969) described a heory for the etiology of scoliosis in yringomyelia They believe the cysts comromise the medial nuclei groups of cells which innervate the muscles of the trunk However, the development of scoliosis does not depend solely on engagement of the motor neurons. In experimental work in nimals Liszka (1961) showed that division f the posterior nerve roots produced an even greater scoliosis than if the anterior roots lone were divided This would fit well with he other sensory disturbances that these patients demonstrate in the early course of he disease The location and extent of the ysts will probably determine whether scoliosis is an early sign or not

The connection between the operative cor ection of the scoliosis and the occurrence of neurological symptoms must be considered Williams (1969) proposed the theory that ncrease of intracranial pressure may cause nlargement of the cysts due to a valve-like nechanism in anomalies around the foramen magnum This may occur during the operation and early postoperative period as there certainly will be transitory venous pressure changes within the spine and skull rom coughing, apnea at induction of nesthesia intubation and extubation, positive pressure breathing lifting and positioning of the patient etc

Circulatory changes cannot be excluded as a pathogenic mechanism for the progression of neurological deficits in connection with the surgery Domisse (1974) has shown that cord levels T4 to T10 are most sensitive to circulatory changes. The syringomyelia cysts may interfere with the circulation here, and this may be further compromised by the stretching of the spine in corrective surgery If this is suspected the correction device should be immediately removed (MacEwen et al 1975) In the present case, however, the gradual onset of symptoms over weeks, and the picture of compression of the pyramidal tracts did not imply a circulatory change and hence the Harrington rod was left in place to stabilize the fusion

Consequently, in the presence of normal neurology, the following signs will point to the diagnosis of syringomyelia in scoliosis patients

(1) Abnormal curve
(2) Very rapid progression
(3) Bony anomalies of the upper cervical or occipital region (X-ray of whole spine) Increased sagittal diameter or interpeduncular distance in the cervical spine on X-ray

If syringomyelia is suspected in a patient who is to be surgically corrected, an extended neurological examination should include pain, temperature and touch sensibility tests of upper and lower extremities Special roentgenograms of the upper cervical spine should be taken A gas myelography should be carried out

At surgery the correction should be moderate, the Harrington rod mainly used as a stabilizing device The patient should be extremely carefully handled in lifting, turning and during the anesthesia

REFERENCES

Domisse G F (1974) The blood supply of the spinal cord *J Bone Jt Surg* 56-B 225–235

Hall P V Lindseth, R E Campbell R I & Kalsbeck, J R (1976) Myelodysplasia and development scoliosis A manifestation of syringomyelia *Spine* 1, 48–56

Hertel G (1973) The width of the cervical spinal cord and the size of the vertebral bodies in syringomyelia. *Europ Neurol* 9, 168–182.

Hertel G Kramer S & Placzek R (1973) Die Syringomyelie Klinischen Verlaufsbeobachten bei 323 Patienten *Nervenarzt* 44, 1–13

Huebert H T & MacKinnon W R (1969) Syringomyelia and scoliosis *J Bone Jt Surg* 51-B 338–343

Liszka O (1961) Spinal cord mechanism leading

to scoliosis in animal experiments. *Acta med pol* 2, 45–64

Logue, V (1971) Syringomyelia A radiodiagnostic and radiotherapeutic saga *Clin Radiol.* 22, 2–16

MacEwen, G D., Bunnell, W P & Spiram, K (1975) Acute neurological complications in the treatment of scoliosis. A report of the Scoliosis Research Society *J Bone Jt Surg* 57-A, 404–408

MacRae, L D & Standen, J (1966) Roentgenologic findings in syringomyelia and hydromyelia. *Amer J Roentgenol* 98, 695–703

McIlroy, W J & Richardson, J C (1965) Syringomyelia A clinical review of 75 cases. *Canad med Ass J* 93, 731–734

Nachemson, A & Elfström, G (1969) A fa indicating distractor for the Harrington procedure. *J Bone Jt Surg* 51-A, 1690–

Nordwall, A (1973) Studies in idiopathic sco relevant to etiology, conservative and op tive treatment *Acta orthop scand.* Sup 150

Perret, G (1963) Congenital and developme anomalies. *Clin Orthop* 27, 9–27

Wells, C. E. C., Spillane, J D & Bigh, A (1959) The cervical spinal canal syringomyelia *Brain* 82, 23–40.

Williams, B (1969) The distending force production of communicating syringom *Lancet* ii, 189

Correspondence to Anders Nordwall, M D., Dept. of Orthopaedic Surgery, Sahlgren Hospital, S-413 45 Göteborg, Sweden.

Acta orthop scand 50, 411–413, 1979

THE ROLE OF HLA-B27 IN THE DIAGNOSIS OF LOW BACK PAIN

IVO JAJIĆ

Ward for Rheumatic Diseases Department of Orthopaedics, Medical Faculty, Zagreb University, Yugoslavia

The HLA B27 antigen was determined in 652 patients with low back pain which had lasted for more than 3 months. A clinical and roentgenological examination of the sacroiliac joints and the thoraco-lumbar spine was performed in all the patients. The control group consisted of 302 unrelated persons who did not show signs of low back pain.

Antigen HLA-B27 was found in 276 of these 652 patients attending the ward for rheumatic diseases (42.4 per cent) and in 37 of the 302 unrelated

back pain

Key words low back pain, antigen HLA-B27, diagnosis

Accepted 2 1 79

There are a wide variety of causes of low back pain such as inflammatory and degenerative diseases of the spine and sacroiliac joints, trauma, congenital malformations, acquired deformities, vertebral osteopathies and tumorous growths. On the other hand, changes in the skeleton and the musculature, changes in the connective and nerve tissue, vascular changes and lesions of the visceral organs, as well as psychogenic diseases, may be considered as extravertebral causes resulting in the syndrome of low back pain (Armstrong 1965)

The lumbar syndrome may sometimes be an indication of inflammatory and degenerative and other changes of the sacroiliac joints (Jajić 1975) Due to pathological changes of the spine and the sacroiliac joints, low back pain may spread into the gluteal region downwards along the leg as far as the knee or in very rare cases as far as the foot (Ogryzlo 1974) These syndromes, especially if they are present in younger male patients, should arouse suspicion of one of the ankylosing spondylopathies and clinical and X-ray examinations and scintigraphy should be undertaken In these cases the determination of HLA–B27 antigen is important in the diagnosis and the early application of adequate therapy For this reason the determination of the histocompatibility antigen in all patients with low back pain of more than 3 months duration was carried out

PATIENTS AND METHODS

Our investigation comprised 652 patients of various ages (15–70 years) There were 402 men

0001–6470/79/040411–03$02.50

© 1979 Munksgaard Co

Acta orthop. scand 50, 415–425, 1979

POSTERIOR FUSION OF THE LUMBOSACRAL SPINE

Evaluation of the Operative Results and the Factors Influencing Them

T TUNTURI M KATAJA L KESKI NISULA, M LAPINSUO P LEPISTÖ
T PAAKKALA, H PÄTIALA P ROKKANEN

Institute of Clinical Sciences, University of Tampere and Central Hospital Tampere Finland

The operative results of 79 patients subjected to posterior fusion of the lumbosacral spine were evaluated on the basis of a follow-up examination performed on average 5 4 years after operation A method of evaluation was developed which measured the patients' subjective improvement and working capacity The method proved appropriate for clinical use and gave a more correct picture of the operative result than methods relying on the patient's own opinion or the radiographic assessment as the only criterion Sixty per cent of the patients were subjectively improved, 40 per cent had returned to their previous or a corresponding occupation and 24 per cent had a good operative result assessed by the method applied.

A statistical analysis was performed in order to find the factors influencing the operative results. Age over 40 years heavy or moderately heavy preoperative work and over 6 months' preoperative disability had a statistically significant, unfavourable effect on the results In the case of labourers in heavy occupations, working capacity was seldom restored to a degree sufficient for return to their previous work

The operative technique proved reliable with 91 per cent successful fusions, assessed from functional radiographs Successful fusion did not [illegible]

Key words backache, lumbar vertebrae, lumbosacral region, non fusion, operative results, spinal diseases, spinal fusion, spondylolisthesis working capacity

Accepted 4 1 79

Operative fusion of the lumbosacral spine is used in the treatment of low back pain due to instability caused by anomalies and diseases of the lumbosacral spine Fusion is accomplished by various operative techniques. The different methods have often been evaluated using the radiological success of the operation as the principal criterion (Thompson & Ralston 1949, Adkins 1955, Boucher 1959, Buck 1970) However, successful fusion does not necessarily imply that the patient is improved (Cleveland et al 1948, Shaw & Taylor 1956, Stauffer & Coventry 1972, Morscher 1974, Samimi 1974, Weber & Peyer 1974)

The goal of the operation is to relieve the patient's backache and to bring about functional improvement of the back. Hence, the patient's subjective symptoms and working capacity must be considered in evaluating

0001–6470/79/040415–11 $02.50

© 1979 Munksgaard, Copenhagen

the results. Little is known about the effect of lumbosacral fusion on the patient's capacity for work.

An understanding of the factors influencing the operative results is a prerequisite for appropriate selection of patients for operation and avoidance of unnecessary operations. In previous series, purely medical and surgical aspects have been the main objects of investigation. Only exceptionally have the economic, social, occupational and psychological factors been considered in connection with operative fusion of the lumbosacral spine (Eriksen 1950, Rombold 1956, Stauffer & Coventry 1972, Kokan et al. 1974, Weber & Fever 1974).

One purpose of the present investigation was to develop a clinically useful method for the evaluation of the operative results of lumbosacral fusion; another purpose was to detect factors influencing the results. In this paper a method of evaluation considering the patient's subjective improvement and working capacity is described, and the follow-up results in 79 cases of lumbosacral fusion and the factors influencing these results are presented.

PATIENTS AND METHODS

Patients

The series consisted of 89 patients subjected to posterior fusion of the lumbosacral spine at the Central Hospital, Tampere, between 1958 and 1975.

The mean age of the patients was, at the time of operation, 35 years, range 16–59. Forty-three patients were female, 46 male. Eighty-four were labourers, five sedentary workers. The occupations represented fell into the category of heavy manual labour in 49 cases, moderately heavy in 24 and light in 11.

All patients had suffered from low back pain causing working disability or marked restriction of daily activities. The average duration of preoperative low back pain was 8 years and 8 months, ranging from 7 months to 28 years. The preoperative duration of disability w[illegible] 10 months and 2 weeks, ranging fr[illegible] years.

Almost all patients had been conser[illegible] treated for low back pain. Rest was the therapy and had brought relief in four-fifths [illegible] cases. Previously a total of 23 back op[illegible] had been performed on 15 of the patients.

The operative diagnosis was spondylolis[illegible] spondylolisthesis in over half of the patients, degeneration of the lumbosacral spine in less [illegible] one quarter (Table 1).

Operative technique and postoperative treatment

A straight longitudinal skin incision [illegible] midline was made at the level of L2–S1. The [illegible] bosacral fascia was split on both sides [illegible] spinous processes. The muscles were de[illegible] beginning from the midline and turned aw[illegible] spinous processes and laminae were freed [illegible] soft tissue and freshened. The sacrum was [illegible] with the posterior surface of the sacrum if [illegible] was to be extended that far. The joints [illegible] crushed with a chisel.

A bone graft 2 cm in breadth and corresp[illegible] in length to the fusion area was detached fr[illegible] iliac crest and split. The two bone grafts obtained were modelled to fit the fusion area [illegible] applied longitudinally on both sides of the sp[illegible] processes. The gaps remaining between the [illegible] grafts and the freshened surfaces were filled [illegible] chips of cancellous bone taken from the ilia[illegible] (Figure 1).

Table 1. Operative diagnoses of 89 patients

Diagnoses	Number of pa[illegible]
Spondylolysis and -olisthesis[1]	49
Grade I	[illegible]
Grade II	[illegible]
Grade III	[illegible]
Grade IV	[illegible]
Degeneration of the lumbosacral spine	30
Disc degeneration	[illegible]
Disc herniation	12
Lumbarization–sacralization	4
Unsuccessful previous fusion	2
Chronic lumbosacral insufficiency	2
Lumbar scoliosis	1
Sequela of fracture of L5	[illegible]
Total	89

[1] Meyerding's (1932) classification
[2] Six of these patients were previously operated for a herniated disc
[3] Three of these were recurrent herniations

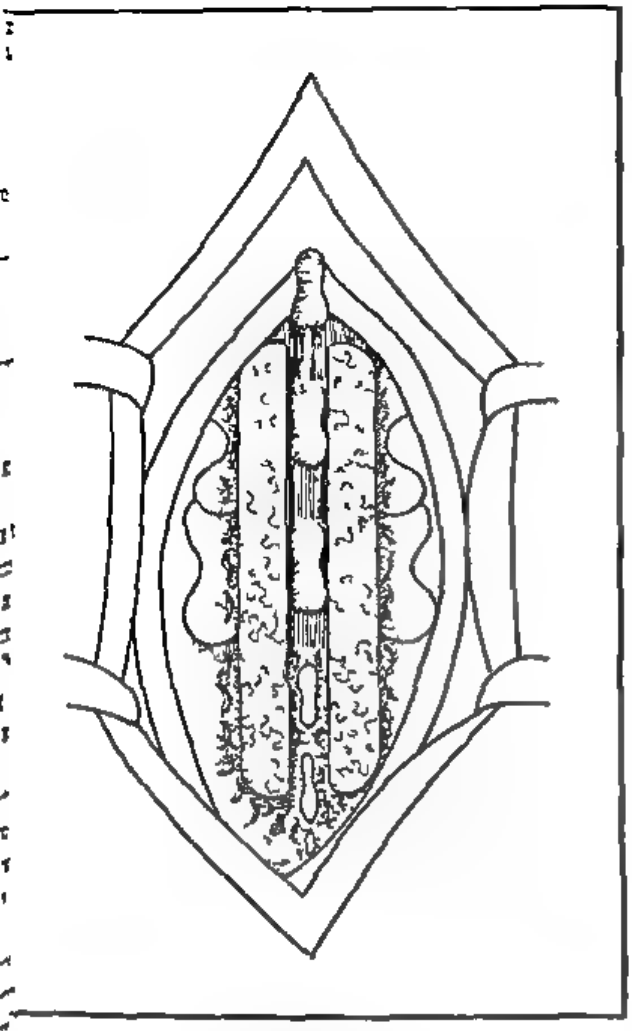

Figure 1 Operation area with the massive iliac bone grafts and cancellous bone chips

Postoperatively the patient was nursed prone in the bed for 3 weeks, after which cautious turning was allowed Getting out of bed was allowed after 5 weeks. Isometric exercises of the back muscles were started under the guidance of a physiotherapist on the day after operation. The lower extremities were bandaged with elastic dressings in order to avoid venous thrombosis. The patient was discharged in the seventh postoperative week and allowed to sit and to bend his back cautiously 3 to 4 months after the operation No lumbosacral support was used The patients were allowed to return to work between 4 and 6 months after operation, depending on the occupation.

Fusion was performed by the technique described above (a combination of Hibbs' (1911) and Albee's (1911) methods) in 82 cases, by other methods in seven The fusion area was L4-sacrum in 70 cases (79 per cent), L3-sacrum in 14, L5 sacrum in three, L2-L5 in one case, and L3-L5 in one Six operations included excision of a herniated disc.

The duration of operation was on average 2 hours and 5 minutes, the range being from 1 hour and 15 minutes to 3 hours and 10 minutes. The average peroperative bleeding was about 1000 g, range 200 to 4000 g During operation or postoperatively 71 patients received an average of 1100 g blood

Complications

Complications occurred in 18 patients (20 per cent) during their stay in hospital Pulmonary embolism was diagnosed in two cases (one of these patients died on the eighth postoperative day), deep venous thrombosis of the lower limb in four, wound infection in two, urinary infection in seven, respiratory infection in three, an allergic skin reaction due to sulphonamide medication in one, and in one case a bedsore developed during the period of bed rest

In eight patients (9 per cent) the following late complications developed superficial wound infection in the back in two, superficial infection of the wound in the donor area in one, vertebral L4–5 block in two (in consequence of postoperative spondylitis), osteitis in the fused area in one and osteophytosis in the donor area in two cases.

Follow-up examination

Preliminary data were obtained from the patients' records, and additional information at the follow-up, including the results of clinical and radiological examinations. Invitation to follow-up was accepted by 79 patients (89 per cent) The follow-up period was on average 5 years and 5 months, ranging from 1 year and 3 months to 9 years.

Evaluation of the operative results

The operative result was assessed in the individual case by a score given on the criteria presented in Table 2. A score of 16–20 points represented a good result, a score of 9–15 points a fair result and a score of 0–8 points a poor result. The success of fusion was not taken into account in assessing the result of operation.

Radiological examination

The patients attending the follow-up were subjected to radiological examination of the lumbosacral spine, with the exception of two pregnant women. A radiographer took an anteroposterior

Table 2 Criteria for evaluation of operative results

Criteria for evaluation	Scores
Change of subjective symptoms	
Much better	5
Better	3
No change	1
Worse	0
Symptoms at follow-up (only the lowest score considered)	
No pain	5
Pain during heavy work	3
Pain after lengthy sitting	2
Pain during light work	1
Persistent pain	0
Working capacity	
Previous or a corresponding work	5
Lighter work owing to back pain	2
Lighter work for other reasons	*
Pensioned because of back pain	0
Pensioned for other reasons	*
Succeeds in work (pensioner in daily activities)	
Well	5
Fairly well	3
Poorly	0

* Same score as for "symptoms at follow-up"

view and two lateral views, one in extension, the other in flexion, with the patient recumbent. A radiologist completed the examination by taking pictures under fluoroscopic control with the patient standing in maximum extension and flexion.

Intervertebral movement in the fused area was considered a sign of non-fusion. A change by at least 2 mm in height of the anterior portion of the intervertebral space or a dislocation by at least 2 mm in the horizontal plane, measured on the extension and flexion views, were considered the criteria of movement.

As suggested by Meyerding (1932), spondylolisthesis was classified into four grades on the basis of the extent of dislocation.

Statistical and computational methods

The numerical data was processed by a universal digital computer (DGC Eclipse C/300). The data description was achieved by library programmes. The individual routines needed in the study were programmed. In testing statistical hypotheses the chi-square and *t* tests were used. The computation of the test scores was included in the programmes in order to avoid consuming manual calculations.

The groups were considered comparable the null hypothesis was not refused on the le = 0 1 or the chi-square statistic computed the fourfold table (ν = 1) was smaller than

RESULTS

Clinical results

The clinical results were analysed in det those 63 patients, who had been subject their first fusion by the technique desc above and had a radiologically succ fusion

Subjective improvement At follow-up patients (60 per cent) stated that their was much better, and 17 that it was b than before operation. Four pat symptoms were unchanged and four we the opinion that their back was worse.

Working capacity The duration of operative disability was under 5 mont four patients, from 5 to 7 months in 21 7 to 12 in 15 and over 12 months in 23

At the time of follow-up 40 per cent o patients worked in their previous or a responding occupation, while 25 per cen shifted to lighter work (Table 3). Tw patients (35 per cent) were unable to because of the condition of their bac these, 16 had been constantly disabled operatively, while four had worked f least 1 year and then become disabled.

Of those patients who consi themselves much improved, nearly quarter had shifted to lighter work and than one quarter were disabled owing to pain (Table 3). The proportion of pe who succeeded well in their previous corresponding work was 14 per cent.

Factors influencing the postoperative wo capacity Working capacity at the tim follow-up was compared with age at the of operation, the kind of preoperative

Table 3 Working capacity at follow-up compared with subjective improvement in 57 patients[1]

ubjective mprovement	Number of patients	Previous or a corresponding work	Lighter work owing to the back pain	Pensioned because of back pain
Much better	34	17	8	9
etter	15	2	4	9
o change	4	3	1	0
orse	4	1	1	2
otal	57	23	14	20

[1] From the table are omitted two patients who had shifted to lighter work and four who were disabled or some cause other than the back pain.

ie duration of peroperative symptoms and isability, the benefit possibly derived from reoperative rest or the use of a lumbosacral orset and the number of previous back perations.

A statistically significantly more reduced postoperative working capacity was noted in

patients over 40 years old compared with those under 40 ($P<0.025$) (groups comparable with regard to kind of preoperative work and duration of disability),

labourers doing heavy work compared with the remainder of the patients ($P<0.0025$) (groups comparable with regard to age and duration of disability),

patients preoperatively disabled for over 6 months compared with those disabled for less than 6 months ($P<0.0125$) (groups comparable with regard to age and kind of preoperative work)

The number of previous back operations, the duration of preoperative symptoms and the benefit possibly derived from rest or the use of a lumbosacral corset had no effect on postoperative working capacity

Operative results and factors influencing them According to the criteria applied (Table 2) the operative result was good in 15 patients (24 per cent) fair in 29 (46 per cent) and poor in 19 (30 per cent) The mean score was 11 6

The operative results were compared with age at the time of operation (Table 4), kind of preoperative work (Table 5) and duration of preoperative disability (Table 6) On the basis of the scores for the patients, the operative result was poorer to a statistically significant extent in

Table 4 Operative results compared with age at operation in 63 patients

Age years)	Number of patients	Operative result Good	Fair	Poor	Mean score	
≤20	7	2	5	—	14 4	
21 30	14	2	7	5	11 9	12.4
31–40	20	6	8	6	12.1	
41–50	17	5	5	7	9 9	10 1
>50	5	—	4	1	11 0	
Total	63	15	29	19	11 6	

Table 5 Operative results compared with type of preoperative work in 63 patients

Type of work	Number of patients	Operative result Good	Fair	Poor	
Heavy manual labour	38	6 (16 %)	19	13	10
Moderately heavy manual labour	15	4 (27 %)	7	4	12
Light manual labour	5	4 (80 %)	1	0	15
Sedentary work	5	1	2	2	11
Total	63	15	29	19	11

Table 6 Operative results compared with preoperative duration of disability in 63 patients

Preoperative disability (months)	Number of patients	Operative result Good		Fair	Poor		Mean sc
<1	15	7	(35 %)	5	3	(16 %)	14 5
1–6	22	6		13	3		12 8
6–12	9	0	(8 %)	4	5	(50 %)	8 0
>12	17	2		7	8		9 3
Total	63	15		29	19		11 6

- patients over 40 years old compared with those under 40 ($P<0.05$) (groups comparable with regard to kind of preoperative work and duration of disability),
- labourers doing heavy work compared with the remainder of the series ($P<0.05$), labourers doing heavy or moderately heavy work compared with those doing light work ($P<0.0125$) and labourers doing heavy work compared with those doing light work ($P<0.01$) (groups comparable with regard to age and duration of preoperative disability),
- patients who had been disabled preoperatively for over 6 months compared with those disabled for less than 6 months ($P<0.0005$) (groups comparable with regard to age and kind of preoperative work)

Patients with previous back surgery had slightly poorer results than those who had not previously undergone any back operat This difference was statistically al significant ($P<0.1$), but it was explained greater number of patients over 40 year in the first group

On the other hand, the duration of operative symptoms, preoperative benefit lumbosacral support and the oper diagnosis had no statistically significant e on the results of operation.

Patients with non-fusion. Radiological amination showed that fusion had fail occur in six patients, three of whom h fair and three a poor clinical result. Tw these patients stated that their back much better than before operation, three it was better, while one patient reporte creased back pain

The mean score for the patients with fusion was 8 2 and the operative results

statistically significantly ($P<0.05$) poorer in this group than in the group of successful fusions.

The group of patients with non-fusion was comparable with the successfully fused patients with regard to age and preoperative duration of disability, but their preoperative work was statistically significantly ($P<0.05$) lighter in character.

Radiological results

Success of fusion. Of the patients subjected to their first fusion by the technique described above, 69 were radiologically examined as described in the foregoing. Fusion was established in 63 cases (91 per cent) and non-fusion in six (9 per cent). In two cases non-fusion was only noticed on the functional radiographs taken under fluoroscopic control with the patient standing.

The frequency of successful fusions was not influenced by the number of fused segments, the operative diagnosis, the degree of spondylolisthesis, the age or the sex of the patient.

Spinal stenosis. Radiologically, narrowing of the medullary canal was not observed in any patient, but plain radiographs of fused patients hardly permit any confident statement on this point.

DISCUSSION

The results of fusion of the lumbosacral spine have been extensively studied for the last 50 years. A wide variation noticeable in the results is obviously due to differences in the series and in the methods of assessment. In evaluating the operative results, the patient's subjective estimates and working capacity, and the success of fusion are the possible aspects to be considered. Furthermore, factors influencing the operative results and the value of operative fusion in the treatment of low back pain are essential objects of discussion.

The patient's subjective estimate

The patient's opinion of the operative result is an important criterion in evaluating the results of fusion, since the patient's subjective symptoms constitute the indication for operation. However, this approach to evaluation implies sources of error, since subjective improvement may be influenced also by factors not related to the operation.

In previous reports, complete relief of symptoms has been achieved by lumbosacral fusion in 0 per cent (Stauffer & Coventry 1972) to 97 per cent (Werlinich 1974). In general, at least a good subjective result has been achieved in 70–93 per cent of patients subjected to anterior interbody fusion (Harmon 1960, 1963, Sacks 1965, Hoover 1968, Freebody et al. 1971), in 65–96 per cent of those subjected to posterior interbody fusion (Cloward 1963, Wiltberger 1964), in 76–93 per cent of posterolateral fusion cases (Truchly & Thompson 1962, Rombold 1966, Enslin 1975, Saunders & Jacobs 1976), in 83–94 per cent of H-graft fusions (Bosworth et al. 1955, Barr et al. 1967, Langenskiöld 1967) and in 72–99 per cent of cases operated on by various methods of posterior fusion (Howorth 1964, Lettin 1967, Weber & Peyer 1974, Attenborough & Reynolds 1975). Although the series are not comparable with regard to indications for operation and principles of assessment, it appears that no definite differences can be demonstrated in the degree of subjective improvement achieved by the different operative methods.

Of the present patients, 60 per cent had a good subjective improvement (much better than before operation), which is a somewhat poorer result than those reported in previous series. However, since only 13 per cent were entirely symptom-free and only 14 per cent tackled their previous work successfully, subjective improvement alone must be considered an inadequate measure of the results of fusion.

Postoperative working capacity

Since the aim of lumbosacral fusion usually is to restore the patient's working capacity,

this is an important consideration in assessing the results. Furthermore, working capacity may be regarded as an essentially objective criterion, compared with the opinions of the patient or the doctor examining him, which are subjective criteria The value of working capacity as a criterion is, however, reduced by the fact that it is in part influenced by factors other than medical motivation for work, the job market and the advantages offered by the social security and insurance systems.

A comparison of previous investigations seems to indicate that postoperative working capacity is dependent on the operative diagnosis, but not on the operative method In series of fusions principally connected with excision of a herniated disc, 79–98 per cent of the patients returned to their previous occupations (Cloward 1963, Harmon 1963, Barr et al 1967, Thompson et al 1974, Werlinich 1974) On the other hand, in series consisting for the most part of re-operations, a working capacity permitting return to previous work was attained by only 53–63 per cent (Truchly & Thompson 1962, Stauffer & Coventry 1972, Saunders & Jacobs 1976) Of patients with spondylolisthesis, 47–69 per cent are postoperatively found "free from trouble in all work" (Laurent 1958, Klenerman 1962)

Our results were somewhat poorer Statistical analysis, performed to detect the sources of our poor results, showed that age over 40, a preoperative occupation implying heavy manual work and over half a year's preoperative disability were significant causes of reduced postoperative working capacity

Methods of assessment

Friberg (1939) introduced a method of assessment combining the subjective (patient's own opinion) and objective (working capacity) results of operation However, in analyses of the results of lumbosacral fusion, many authors have used subjective improvement as the only criterion (Cleveland et al 1948, Bosworth et al. 1955 Ha 1960, Howorth 1964, Sacks 1965 Rom 1966, Lettin 1967, Hoover 1968 Freebo al 1971, Weber & Peyer 1974 Attenbor & Reynolds 1975, Enslin 1975)

The present investigation shows tha estimate of the operative results b exclusively on subjective evaluation favourable (Table 3) On the other h working capacity alone represents only aspect of the total situation since patient's symptoms are not taken account A combination of these two cri seemed reasonable, and the method assessment was developed on this prin (Table 2) Using this method a good o ative result was noted in 24 per cen patients, which is more realistic a result t 60 per cent good results based on subjec improvement alone

Factors influencing the operative results

The low ratio of good results obtaine this series gave occasion for a statistical an sis aimed at detecting factors of progno value for the results of operation

A statistically significant difference observed between patients over and under years old, the results for the former be poorer Rombold (1966) and Weber & Pe (1974) also reported more favourable res in younger than in older patients, wher Stauffer & Coventry (1972) were not able demonstrate any effect of age on operative results

A preoperative occupation implying hea manual work impaired the results to statistically significant extent This is agreement with Eriksen's (1960) observati that lumbosacral fusion is of no real benefit workers in heavy occupations On the oth hand Stauffer & Coventry (1972) and Kok et al (1974) noticed no effect of occupati on the results of fusion

The results for those who had been disabl for over months preoperatively we statistically significantly poorer than t

esults for patients with a shorter duration of isability In previous reports attention has ot been paid to this factor, which the pre-ent authors regard as a very important one

It has been shown that previous operations mpair the results (Harmon 1963, Wiltberger 964, Kokan et al 1974, Thompson et al 974) A similar trend was noticed in this eries

We have previously believed that patients enefitting preoperatively from the use of a umbosacral support would have good perative results. This assumption proved rroneous.

On the basis of this study, the factors in-luencing the operative results of lumbosacral usion are not purely medical or surgical, but ather related to occupational and social spects.

Assessment of the success of fusion

Although the aim of fusion is to alleviate he patient's back symptoms, there are two easons why the technical success of fusion must also be considered

1 A measurement of the technical reliability of various fusion methods is desirable
2 To make it possible to assess the role of fusion in the patient's improvement, it is necessary to know whether fusion has occurred

In this investigation two methods of functional radiography were used, one of which differed from the hospital routine While checking the bendings with the aid of fluoroscopy, the radiologist took views with the patient standing It was thus ascertained that the projections were entirely straight, that the radiographs were taken at the right level and that maximum extension and flexion were maintained. For the assessment of non-fusion this method proved superior to the ordinary functional examination performed by a radiographer

In previous reports fusion of two segments performed by Hibbs' (1911) technique has been successful in 70–75 per cent (Thompson & Ralston 1949, Howorth 1964), by the H-graft technique in 64–83 per cent (Cleveland et al 1948, Barr et al 1967), while interbody two-segment fusions have been successful in 53–79 per cent (Wiltberger 1964, Stauffer & Coventry 1972) and posterolateral in 93–94 per cent (Truchly & Thompson 1962, Thompson et al 1974) The high rate of successful fusions in the present series (91 per cent) may be attributable to the extensive operative technique and the long immobilization in bed A comparable success rate for two-segment fusions has only been reported with the posterolateral technique

Relationship between operative results and success of fusion

Many previous authors have reported that non-fusion did not impair the operative results (Eriksen 1960, Kelly 1962, Howorth 1964, Lettin 1967, Freebody et al. 1971, Turner & Bianco 1971, Morscher 1974, Samimi 1974, Rothman & Booth 1975), while others, in agreement with this study, have noticed more favourable results in connection with successful fusions (Cleveland et al 1948, Bosworth et al 1955, Laurent 1958, Stauffer & Coventry 1972, Thompson et al 1974, Weber & Peyer 1974) In the light of these contradictory observations the value of lumbosacral fusion in the treatment of patients with low back pain seems doubtful

Value of lumbosacral fusion

There has been a considerable difference of opinion concerning the value of lumbosacral fusion in the treatment of low back pain Friberg (1954) believed that it is usually sufficient if the patient shifts over to lighter work Nachemson (1976) also was of the opinion that fusion is hardly ever indicated in chronic cases of backache, except in young patients with spondylolisthesis and in cases of recurrent disc herniations. On the other hand, Cloward (1963) considered fusion the best therapy for low back pain, irrespective of the diagnosis.

It is beyond dispute that very favourable

results have been reported in some previous investigations, but the attitude to the principles of evaluation could have been more critical, and the best results have been obtained in series consisting mainly of disc herniations. Young et al (1955) reported 20 per cent more satisfactory long-term results when excision of a disc was combined with fusion than when disc excision alone was performed By contrast, Barr et al (1967) and DePalma & Rothman (1969) observed no significant difference between the operative results in these two groups. Considering, in addition, that in many investigations no essential difference in improvement has been noted between the fusion and non-fusion groups, it may be stated that lumbosacral fusion is of relatively little value in the treatment of patients suffering from low back pain

ACKNOWLEDGEMENT

This work has been aided by Tampereen Kaupungin Tiederahasto.

REFERENCES

Adkins, E W O (1955) Lumbo-sacral arthrodesis after laminectomy *J Bone Jt Surg* 37-B, 208–223

Albee, F H (1911) Transplantation of a portion of the tibia into the spine for Pott's disease *J Amer med Ass* 57, 885

Attenborough, C G & Reynolds, M T (1975) Lumbo-sacral fusion with spring fixation *J Bone Jt Surg* 57-B, 283–288

Barr, J S, Kubik, C S, Molloy, M K, McNeill, J M, Riseborough, E J & White, J C (1967) Evaluation of end results in treatment of ruptured lumbar intervertebral discs with protrusion of nucleus pulposus *Surg Gynec Obstet* 125, 250–256

Bosworth, D M, Fielding, J W, Demarest, L & Bonaquist, M (1955) Spondylolisthesis. *J Bone Jt Surg* 37-A, 767–785

Boucher, H H (1959) A method of spinal fusion *J Bone Jt Surg* 41-B, 248–259

Buck, J E (1970) Direct repair of the defect in spondylolisthesis *J Bone Jt Surg* 52-B, 432–437

Cleveland, M, Bosworth, D M & Thompson, R (1948) Pseudarthrosis in the lumbosac spine *J Bone Jt Surg* 30-A, 302–312

Cloward, R B (1963) Lesions of the ant vertebral discs and their treatment by ma body fusion methods. *Clin Orthop* 2 51–77

DePalma, A F & Rothman, R. H. (19 Surgery of the lumbar spine *Clin Orthop* 6 162–170

Enslin, T B (1975) Debridement and fusion the lumbo-sacral area through an iliolumb approach. *Orthop Clin N Amer* 6, 291 29

Eriksen, B (1960) Lumbo-sacral fusion. *J Bone Surg* 42-B, 660–661

Freebody, D, Bendall, R & Taylor R.D (19 Anterior transperitoneal lumbar fusion. *Bone Jt Surg* 53-B, 617–627

Friberg, S (1939) Studies on spondylolisthesis *Acta chir scand*, Suppl. 55

Friberg, S (1954) Lumbar disc degeneration in th problem of lumbago sciatica *Bull Hosp J Dis* 15, 1–20

Harmon, P H (1960) Anterior extraperitone lumbar disk excision and vertebral body fusion *Clin Orthop* 18, 169–198

Harmon, P H (1963) Anterior excision an vertebral body fusion operation for inte vertebral disk syndromes of the lower lumb spine *Clin Orthop* 26, 107–127

[illegible] for progressive

Howorth, B (1964) Low backache and sciatica Results of surgical treatment *J Bone Jt Surg* 46-A, 1485–1499

Kelly, R P (1962) Intertransverse fusion of th low back *Trans sth surg Ass* 74, 193 20

Klenerman, L. (1962) Posterior spinal fusion spondylolisthesis. *J Bone Jt Surg* 44-B 637–641

Kokan, P J, Wing, P C & Thompson W (1974) Factors associated with failure of lum bar spine fusion *Canad J Surg* 17 294–298

Langenskiold, A (1967) Spinal fusion by fixation with a bilaminar iliac bone graft wedged on th spinous processes in the sagittal plane *Act orthop scand* 38, 306–312

Laurent, L E (1958) Spondylolisthesis. *Act orthop scand*, Suppl 35

Lettin A W F (1967) Diagnosis and treatment of lumbar instability *J Bone Jt Surg* 49-B 520–529

Meyerding, H W (1932) Spondylolisthesis. *Surg Gynec Obstet* 54, 371–377

Morscher, E (1974) Indikation und Technik der vorderen Spondylodese der Lumbalwirbel bei degenerativen Erkrankungen. *Z Orthop* 112, 763–766

Nachemson, A. (1976) Vad kan vi gora med patienten som inte har diskbrack *Läkartidn* 73, 1310–1313

Rombold, C (1966) Treatment of spondylolisthesis by posterolateral fusion, resection of the pars interarticularis, and prompt mobilization of the patient *J Bone Jt Surg* 48-A, 1282–1300

Rothman, R H & Booth, R (1975) Failures of spinal fusion. *Orthop Clin N Amer* 6, 299–304

Sacks, S (1965) Anterior interbody fusion of the lumbar spine *J Bone Jt Surg* 47-B, 211–223

Samimi, H (1974) Klinische Untersuchungsergebnisse nach interkorporaler Spondylodese im LWS-Bereich nach der Methode von Cloward in Modifizierter Form nach Wiltberger *Z Orthop* 112, 770–773

Shaw E. G & Taylor, J G (1956) The results of lumbo-sacral fusion for low back pain. *J Bone Jt Surg* 38-B, 485–497

Saunders, E A & Jacobs, R R (1976) The multiply operated back Fusion of the posterolateral spine with and without nerve root compression *Sth med J (Bgham, Ala)* 69, 868–871

Stauffer, R N & Coventry, M B (1972) Anterior interbody lumbar spine fusion *J Bone Jt Surg* 54-A, 756–768

Thompson, W A. L & Ralston, E L. (1949) Pseudarthrosis following spine fusion *J Bone Jt Surg* 31-A, 400–405

Thompson, W A L, Gristina A G & Healy, W A (1974) Lumbosacral spine fusion *J Bone Jt Surg* 56-A 1643–1647

Truchly, G & Thompson W A. L (1962) Posterolateral fusion of the lumbosacral spine *J Bone Jt Surg* 44-A 505–512.

Turner, R H & Bianco, A. J (1971) Spondylolysis and spondylolisthesis in children and teen-agers. *J Bone Jt Surg* 53 A, 1298–1306

Weber, A & Peyer, J (1974) Ergebnisse der dorsalen lumbosacralen spondylodese. *Z Orthop* 112, 779–781

Werlinich, M (1974) Anterior interbody fusion and stabilization with metal fixation *Int. Surg* 59, 269–273

Wiltberger, B (1964) Intervertebral body fusion by the use of posterior bone dowel *Clin Orthop* 35, 69–79

Young H H., Love, J G, Svien, H J, Price, R D & Kroll, H G (1955) Low back and sciatic pain Long term results after removal of protruded intervertebral disk with or without fusion *Clin Orthop* 5, 128–137

Correspondence to Dr T Tunturi Institute of Clinical Sciences, University of Tampere, Teiskontie 35 SF-33520 Tampere 52, Finland

-ta orthop scand 50, 427–432, 1979

:OST-BENEFIT ANALYSIS OF POSTERIOR FUSION OF THE .UMBOSACRAL SPINE

- TUNTURI, P NIEMELÄ, J LAURINKARI, H PÄTIALA & E ROKKANEN

nstitute of Clinical Sciences, University of Tampere and Central Hospital, Tampere Department of ocial Policy, University of Helsinki, Department of Public Health Science, University of Kuopio, inland

In this study the cost-benefit ratio of posterior fusion of the lumbosacral spine was assessed. The calculations were based on 118 operated patients, followed up for an average of 4 8 years.

Costs were calculated using the average costs of treatment at central hospitals, visits to the outpatient department and travelling The costs for one patient exceeded on average 5,569 US dollars.

The economic benefits derived from the operations were estimated by the work output of those 36 patients who postoperatively returned to their previous or a corresponding occupation The postoperative work output was estimated using the coefficients for known causes of retirement (emigration mortality, disability) The benefits of one lumbosacral fusion amounted on average to 16 075 US dollars.

Fusion of the lumbosacral spine proved to be profitable at a cost benefit ratio of 1 2 9 If the selection of patients for operation could be made so as to guarantee that working capacity is restored by operative treatment, the cost-benefit ratio might be improved to 1 9 5

It is emphasized that cost benefit analyses of surgical procedures are important from the standpoint of principles of treatment and priority of operations. This study deals with economic aspects only The medical aspects of the present material have been presented in two previous papers.

Key words cost benefit analysis, medical economics, spinal fusion

Accepted 28 ii 79

The amount of money allocated to health services in the USA constituted 8 3 per cent (119 billion US dollars) of the gross national product in 1975 (Knowles 1977) The corresponding figure for Finland was 6 8 per cent (2.0 billion US dollars) in 1976 (Laakintohallitus 1978) These enormous sums emphasize the importance of quantitative measurements of health benefits produced in the different sectors of the medical service (Talousneuvosto 1972, Grant 1974)

Health political measures are to an increasing extent evaluated by cost-benefit analysis (Kocher 1972, Second Symposium on the Efficiency of Medical Care 1972, Elo et al 1974, Niemela et al 1975, Dahlberg & Nachemson 1976, Schoenbaum et al. 1976) Although measurements of the economic value of health are open to criticism (Laurinkari et al 1974), even rough systematic estimates are useful in health-political decision making (Elo et al 1974) The economic benefits from surgical pro-

0001 6470 79 040427–06 $02.50 0

© 1979 Munksgaard Copenhagen

cedures have previously been evaluated by cost-benefit analysis in only a few studies (Pätiälä et al 1976)

The aim of this study was to assess the cost-benefit ratio of operative fusion of the lumbosacral spine by means of cost-benefit analysis. In the present study purely economic aspects are considered

PATIENTS AND METHODS

The material consisted of 133 patients subjected in 1968–1975 to posterior fusion of the lumbosacral spine at the Central Hospital of Tampere, Finland (Tunturi et al 1979b) or the Central Hospital of Middle Finland (Tunturi et al. 1979a). Of these patients 116 attended follow-up examinations in 1976–1977 The average period of follow-up was 4 8 years. Two patients died of pulmonary embolism on the seventh to eighth postoperative day The analysis was thus based on 118 patients.

The following set of data, derived from the results of follow-up examination and other sources, was used in the cost-benefit analysis

A Preoperatively, conservative treatment had failed to restore working capacity and the patients were disabled as regards their own occupation.

B The average duration of hospital treatment for these patients was 58 days, including treatment for late complications. In 1976, the daily cost of treatment at a central hospital amounted to 92.49 US dollars (Sairaalalaitto 1977).

C The average number of postoperative visits made by these patients to a central hospital outpatient department was 5 8 In 1976, the cost per visit was 28 04 US dollars (Sairaalalaitto 1977)

D Journeys to the hospital for treatment or for outpatient department visits were assumed to have taken place half by public transport, and half by taxi (expert's opinion on the appropriate means of transport required) Forty kilometers was accepted as the average distance to a central hospital (Niemelä et al 1974) The average fare for a return journey was 2.86 US dollars by public transport (train) and 33 90 US dollars by taxi

E The economic benefits derived from the operations were calculated on the basis of the patients' postoperative work output

Out of 60 men, 18 (30 per cent) had returned postoperatively to their previous or a corresponding occupation after an av disability period of 10 months The m between operation and follow-up wa average 54 months. Thus, economic be could be calculated on the basis of a p of 44 months for each of the 18 men.

Out of 56 women, 18 (32 per cent) returned postoperatively to their previo a corresponding occupation (14 emplo four housewives) after an average disa period of 6 months. The average m between operation and follow-up wa months. Benefits could thus be calculate the basis of a period of 52 months for ea the 18 women.

F Postoperative capacity for lighter work not regarded as a benefit derived from op tion

G For the rest of life (i.e. work output follow-up) economic benefits were estim using various coefficients of retirement. per cent was accepted as the annual ra postoperative retirement from work du spinal disease (on the basis of follow- Inevitable retirement was taken into acc using available statistical data (emigra and mortality, Tilastokeskus 1978, disab Eläketurvakeskus 1977 and Kansaneläke 1978).

H The mean age at the time of operation 36 years, after the inevitable postoper sick-leave period the potential future durat of work performance was thus on averag years for each patient (pensionable age Finland 65 years).

I Ten per cent was accepted as the rate discount

J Costs and benefits were calculated accor to the index for 1976 It was assumed 118 operations were performed in 1976 addition, the mean costs and benefits patient were calculated by dividing the sums by the total number of patients

K The mean industrial wages per hour in were used as a basis for calculation (m 3 91 US dollars, women 2.87 US dolla For housewives the mean wage per hou domestic assistants in 1976 was used (US dollars) Thus, the mean annual inc amounted to 8 032 US dollars for men, 5 US dollars for employed women, and 3 US dollars for housewives.

RESULTS

Costs

The costs of the operations consisted of sum of the costs of hospital treatment, vis

Table 1 Costs of 118 operations (for principles of calculation, see text)

ources of costs		US dollars	
osts of hospital treatment			623,730 70
Patients who died	2 × 8 × 92 49 =	1,479 79	
Patients attending follow up	116 × [illegible] × 92 49 =	622,250 91	
osts of visits to the outpatient department	116 × 5 8 × 28 04 =	18,865 48	18,865 48
ravelling costs			14,497 54
Train	116 × 3 4 × 2 86 =	1,128 05	
Taxi	116 × 3 4 × 33 90 =	13,369 49	
otal			657,093 72

; the outpatient department and travelling Table 1)

The overall cost of the 118 operations mounted to some 657,000 US dollars and ne cost for one operation to an average of ,569 US dollars The costs of hospital reatment constituted 95 per cent of the total osts, while visits to the outpatient department and travelling accounted for about half ach of the remaining 5 per cent

Benefits

The overall benefits derived from the operations calculated according to items A and E–K amounted to 1 10 million US dollars or the men, 0 67 million for the employed vomen, and 0 13 million for the housewives. The economic benefits derived from 118 operations thus totalled 1,896,870 US dollars (Table 2), the benefit derived from one operation amounted to an average of 16,075 US dollars.

Summary of costs and benefits and the cost-benefit ratio

The difference between the benefits and costs of 118 operations was 1,239,776 US dollars, the corresponding figure for one operation was 10,507 US dollars. The cost-benefit ratio was 1 2 9

DISCUSSION

Evaluation of costs and benefits

In studies such as the present one the principal problems relate to the estimation of

Table 2 Economic benefits from 118 operations (for principles of calculation, see text)

Working capacity	Number of patients	Benefits (US dollars) Period before follow-up	Period after follow-up
Died postoperatively	2	–	–
Shifted to lighter work or pensioned	80	–[1]	–[1]
In previous or a corresponding occupation	36	770,094[2]	1,126,776[3]
Total	118	1,896,870	

[1] see item F
[2] see items E, I–K
[3] see items G–K

cedures have previously been evaluated by cost-benefit analysis in only a few studies (Patiäla et al 1976)

The aim of this study was to assess the cost-benefit ratio of operative fusion of the lumbosacral spine by means of cost-benefit analysis. In the present study purely economic aspects are considered

PATIENTS AND METHODS

The material consisted of 133 patients subjected in 1968–1975 to posterior fusion of the lumbosacral spine in the Central Hospital of Tampere Finland (Tunturi et al 1979b) or the Central Hospital of Middle Finland (Tunturi et al 1979a) Of these patients 116 attended follow-up examinations in 1976–1977 The average period of follow-up was 4 8 years Two patients died of pulmonary embolism on the seventh to eighth postoperative day The analysis was thus based on 118 patients.

The following set of data, derived from the results of follow-up examination and other sources was used in the cost-benefit analysis

A Preoperatively, conservative treatment had failed to restore working capacity and the patients were disabled as regards their own occupation

B The average duration of hospital treatment for these patients was 58 days including treatment for late complications. In 1976, the daily cost of treatment at a central hospital amounted to 92 49 US dollars (Sairaalalitto 1977)

C The average number of postoperative visits made by these patients to a central hospital outpatient department was 5 8 In 1976 the cost per visit was 28 04 US dollars (Sairaalalitto 1977)

D Journeys to the hospital for treatment or for outpatient department visits were assumed to have taken place half by public transport and half by taxi (expert's opinion on the appropriate means of transport required) Forty kilometers was accepted as the average distance to a central hospital (Niemela et al 1974) The average fare for a return journey was 2 86 US dollars by public transport (train) and 33 90 US dollars by taxi

E The economic benefits derived from the operations were calculated on the basis of the patients' postoperative work output

Out of 60 men, 18 (30 per cent) had returned postoperatively to their previous or a corresponding occupation after an av disability period of 10 months. The int between operation and follow up was average 54 months. Thus, economic ben could be calculated on the basis of of 44 months for each of the 18 men.

Out of 56 women, 18 (32 per cent) returned postoperatively to their previou a corresponding occupation (14 four housewives) after an average period of 6 months. The average inte between operation and follow-up was months. Benefits could thus be the basis of a period of 52 months for eac the 18 women

F Postoperative capacity for lighter work not regarded as a benefit derived from op tion

G For the rest of life (i.e. work output a follow-up) economic benefits were estim using various coefficients of retirement. per cent was accepted as the annual rate postoperative retirement from work spinal disease (on the basis of follow- Inevitable retirement was taken into using available statistical data and mortality, Tilastokeskus 1978 disab Elaketurvakeskus 1977 and Kansaneläke 1978).

H The mean age at the time of operation 36 years after the inevitable postoper sick-leave period the potential future dur of work performance was thus on averag years for each patient (pensionable ag Finland 65 years).

I Ten per cent was accepted as the ra discount

J Costs and benefits were calculated accor to the index for 1976 It was assumed 118 operations were performed in 1976 addition the mean costs and benefits patient were calculated by dividing the sums by the total number of patients.

K The mean industrial wages per hour m were used as a basis for calculation 3 91 US dollars women 2 87 US dol For housewives the mean wage per hou domestic assistants in 1976 was used US dollars) Thus, the mean annual inc amounted to 8 032 US dollars for men, 5 US dollars for employed women and 3 US dollars for housewives.

RESULTS

Costs

The costs of the operations consisted of sum of the costs of hospital treatment

However, a patient suffering from severe, ronic low back pain is not easily habilitated to his previous or a corsponding occupation by any conservative ethod Hence, the only alternative to perative treatment is employment of patient in lighter work As long as years ago, Friberg (1954) stated that ifting to lighter work is often sufficient eatment for a patient suffering from low ack pain If this can be accomplished ithout occupational retraining, a satisfactory esult is achieved without any major conomic loss for the patient and without osts for society Retraining, on the other and, involves considerable costs for society g half a year's retraining 4,422 US dollars lus missed work output for the same period) urthermore, retraining does not guarantee mployment Thus, after expensive retraining previously disabled patient may be able to ork, but is not employed

It would have been desirable to compare e profitability of operative and conservative eatment but this was impossible owing to ick of a control material On the other hand, onservative treatment had failed, in all the atients in this series, to restore working apacity preoperatively Thus, it seems istified to attribute the restored working apacity of the 36 patients to the fusion peration Furthermore, in these 36 cases perative treatment proved superior to conservative methods.

Priority sequence of surgical procedures

Because of the limited economic resources f surgery, a priority sequence should be esablished for various operations. Economic dvantage would be one criterion of priority prerequisite for the application of this riterion is that the costs and benefits of arious surgical procedures are known Assessment of the cost-benefit ratios of fferent operations therefore seems to be an mportant subject of investigation

ACKNOWLEDGEMENTS

This work had been aided by the Tampereen Kaupungin Tiederahasto

REFERENCES

Dahlberg, L & Nachemson, A. L (1976) The economic aspects of scoliosis treatment *Scoliosis*, pp 73–101 Academic Press, London

Dasgupta, A K & Pearse, W (1972) *Cost benefit analysis Theory and practice* Macmillan Press, London

Elo, O, Laurinkari, J & Niemela, (1974) *Cost-benefit analysis of rubella vaccination* University of Tampere, Finland Department of Public Health Sciences. Publication Series A Research and Studies 4, 1–137

Elaketurvakeskus (1977) Tilastotietoja työelakkeen saajista vuodelta 1976 1–147, Helsinki (The Central Pension Security Institute (1977) Statistical data of pensioners in 1976 pp 1–147, Helsinki, Finland)

Eriksen, B (1960) Lumbo-sacral fusion. *J Bone Jt Surg* 42 B, 660–661

Friberg S (1954) Lumbar disc degeneration in the problem of lumbago sciatica *Bull. Hosp Jt Dis* 15, 1–20

Grant, J A. (1974) Quantitative evaluation of a screening program *Amer J publ Hlth* 64, 66–71

Harmon, P H (1963) Anterior excision and vertebral body fusion operation for intervertebral disk syndromes of the lower lumbar spine *Clin Orthop* 26, 107–127

Kansanelakelaitos (1978) Statistics of demographic changes for the period 1970–1976 (The Social Insurance Institution, Helsinki, Finland) (unpublished data, personal communication)

Knowles, J H (1977) Doing better and feeling worse *Health in the United States* Ed Knowles, J H, 2, W W Norton & Company Inc., New York.

Kocher, G (1972) Kosten-Nutzen Analysen im Gesundheitswesen. Referate und Diskussionen anlasslich eines gesundheitsokonomischen Seminars in Egerkingen (Schweiz). Pharma Information Basel, 1–67

Kokan P J, Wing C & Thompson W J (1974) Factors associated with failure of lumbar spine fusion. *Canad J Surg* 17, 294–298

Laurinkari J Elo & Niemela, (1974) Survey of aspects of measurements of

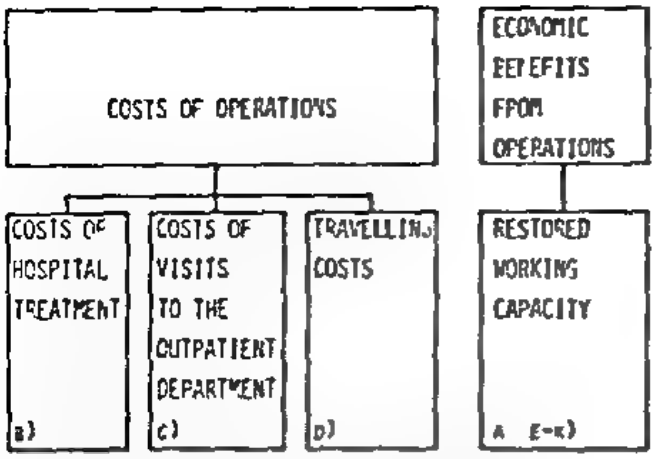

Figure 1 Costs of and benefits due to fusion of the lumbosacral spine, systemic delimitation (for explanation of the letters A–K, see text)

benefits The cost-benefit analysis here employed (Pitkänen 1970, Dasgupta & Pearse 1972, Valtiovarainministeriö 1975), is well suited for this purpose Systemic delimitation (Figure 1) was considered a necessary basis for the analysis.

Only those operations which restored the patient's capacity to work in his previous or a corresponding occupation were considered a source of economic benefit Postoperative capacity for lighter work was not considered a benefit derived from operation, since the patients concerned might have been able to perform such work without any treatment It was difficult to calculate the benefits, because working capacity was known only during the follow-up period, not afterwards If inability to work in the future is less than calculated, benefits increase, in the opposite case, they decrease

The discount rate (10 per cent) applied agrees well with those previously used (Mattson 1970, Elo et al 1974, Patiala et al 1976)

The mean industrial wages per hour may be considered an appropriate basis for calculation in this study, because most of our patients had been labourers in heavy or moderately heavy manual work

As the average daily cost of treatment at a central hospital was known this was used as a basis for calculating the costs incurred by operation, although the hospital cos surgical patients may differ from this value More exact calculations would m a detailed estimate of the distribution o total costs among the various factors.

Cost benefit ratio and methods of treatme

In the present series, fusion of lumbosacral spine proved to be economically profitable procedure (benefit ratio 1 2.9), even though only 31 cent of the operations restored the pat capacity to work in his previous or a responding occupation However lumbos fusion proved less profitable knee synovectomy, for instance (Patiala 1976, cost-benefit ratio 1 5 2–6 2). every operation restored the patient' capacity to match his previous or a responding occupation, the cost-benefit would have risen to 1 9 5 Hence if the were to improve the economic benefit from lumbosacral spine fusion, only t patients whose prognosis with regard to restoration of working capacity is opt should be selected for operation. This w presuppose recognition of those factors are of prognostic value in respect of operative results. Some relevant data ma extracted from previous reports (Eri 1960, Harmon 1963, Wiltberger 1 Rombold 1966, Kokan et al 1974 Thom et al 1974, Weber & Peyer 1974). In recent papers the present authors directed attention to some prognostic fa and discussed the conclusions drawn by o investigators (Tunturi et al 1979a b).

On the other hand, problems will also if patients are selected for operation on strict criteria, and exclusively with a vie improving the cost-benefit ratio of treatment in question If operative fusio not regarded as indicated because of a prognosis, another method of treatment be chosen, which represents an economic better alternative

-ta orthop scand 50 433–441, 1979

)NTROLLED HYPOTENSION IN HIP JOINT SURGERY

Assessment of Surgical Haemorrhage :ring Sodium Nitroprusside Infusion

K VAZEERY & O LUNDE

partment of Anaesthesiology and Department of Orthopaedic Surgery, Central Hospital of Rogaland, vanger, Norway

Controlled hypotension combined with light balanced anaesthesia, was employed during total hip replacement operations on 25 patients. Sodium nitroprusside (Nipride, Roche) in the form of a 0 01 per cent (100 μg/ml) infusion was used as a hypotensive agent The mean arterial blood pressure (MABP) was lowered from 108 to 64 mmHg (range 60–70) (P<0 001). The average blood loss during the operations was 212 ml and none of the patients required homologous blood transfusion. In comparison with 25 normotensive patients undergoing similar surgery, the difference in the mean volume of haemorrhage between the two groups was 826 ml

Key words controlled hypotension, sodium nitroprusside, transfusion during surgery

Accepted 20 VIII 78

iduced hypotension in major surgical)erations has been in vogue for several years :t its application has been hampered by :casional unpleasant side effects caused by ther a lack of knowledge of the hypotensive gent or of the technique used to accomplish ie diminished bleeding The earlier ypotensive techniques of arteriotomy)ilsland 1951) were abandoned in favour of iore beneficial methods when the autonomic anglion blocking agents were introduced, roviding a relatively avascular field for ırgical procedures (Royester et al 1951, teven & Tovell 1954, Holms 1956, Nayman 960) Deliberate hypotension has been mployed in thoracic surgery (Lewis 1951), rostatic surgery (Bruce 1960) and in large lood vessel surgery (Glenn et al 1954) in order to diminish the blood loss. It has also been used to attain ischaemia of the surgical wound in orthopaedic surgery (Holms 1956), in gynaecological surgery (Linacre 1961) and in reconstructive plastic surgery (Enderby 1961) Deviations from the normal clinical state, such as hypovolaemic anaemia and polycythaemia, have been clear-cut contraindications in the same way as cardiovascular or cerebrovascular, renal or hepatic pathological involvement In spite of the fact that there has been considerable criticism of hypotensive anaesthesia, the promising results after surgical ischaemia cannot be denied (Gillies 1950, Safar 1955, Enderby 1961, Learmonth 1976) Nevertheless, deliberate hypotension cannot be regarded as a routine procedure and it is

001–6470/79/040433–09$02 50

© 1979 Munksgaard Copenhagen

employed only when specifically indicated (Eckenhoff 1955, Adams 1975) After the initial introduction of methonium compounds in induced hypotension, trimetaphan (arfonad) became very popular due to its evanascent action (Nicholson et al 1953) Later clinical experience, however, showed that its application was not all that straightforward (Payne 1956) because of the histamine release Moreover, it often created problems due to tachyphylaxis. Halothane has been used as an adjuvant to hypotensive drugs (Smith et al 1960, Neill & Nixon 1965, Taylor et al 1970) but its application in elderly people cannot be entirely justified as it has a potent myocardial depressive action The introduction of sodium nitroprusside (SNP) has eliminated many of the hazards of ganglion blocking agents although its administration by experienced anaesthesiologists is absolutely essential due to its highly potent action Its use has been declared safe by Vesey et al (1976) (with appropriate authenticity) provided the dose does not exceed a maximum of 1 5 mg/kg body wt This investigation was conducted to assess the volume of haemorrhage during as well as after surgery on the hip using SNP in the dose recommended by the above-mentioned authors (Vesey et al 1976)

PATIENTS AND METHODS

A comparative study was conducted of 50 patients with coxarthrosis who were operated on and fitted with a Charnley prosthesis. The patients comprising this group showed no cardiovascular or other systemic (Deliberate hypotension has been employe over 300 orthopaedic patients and clinical criteria have been observed in ea The standard Charnley operative techni used Postoperatively the patients were routinely with Warfarin sodium Twenty five patients were operated upo normotension (NTN) and in the rema patients controlled hypotension (CH induced prior to operation There we patients who were operated on bilaterally one side under NTN and on the other sid CHN The average age of the patients, 36 and 14 men in both the groups was 70 The ranges, however varied slightly bein years in the normotensive group and 55– in the hypotensive group (Table 1).

The surgical haemorrhage was meas weighing the wet swabs and the Postoperative blood loss was determ measuring the volume of blood in the drain which was usually removed 1 3 da the operation A meticulous watch was the postoperative diuresis and a compari made with the normotensive group At the insertion of the acrylic material, the changes in the patient if any were observed The patients were not gi phylactic treatment with antib oti hydrocortisone

The number of blood transfusion determined and compared with the normo group In the event of blood loss exceed ml, homologous blood was used for repla The hypotensive group included a patie refused blood transfusion on relig ous grou her wishes were complied with. Her haem level dropped from 13 6 g on the day of op to 11 4 on the following day It returned to during the subsequent days.

The results of this investigation were co with a study conducted at the Academic H

Table 1 Patients treated for coxarthrosis with Charnley s prosthesis under normotension (NTN) or controlled hypotension (CHN) and light balanced anaesthesia (Data given as mean and range)

No of patients	Normotension 25	Controlled hypotension 25
Age (years)	70 4 (57–86)	70 4 (55–80)
Weight (kg)	68 6 (52–85)	69 (54–90)
Hb (g%)	13 8 (11 7–16 8)	13 9 (12.2–16 9)
Duration of operation (min)	109 4 (95–120)	94 (82–105)

psala Sweden (Jakobson & Wigren 1972) The patients in this study underwent 27 operations ng Muller's prosthesis on the hip Twelve ients in this group received epidural aesthesia and 15 were operated under general aesthesia

NAESTHETIC TECHNIQUE

er a standard premedication with atropine 0 6 , pethidine 50–100 mg and promethazine 25–50 (Hopkins et al 1957) 1 hour before the opera anaesthesia was induced using methohex ne 70–100 mg followed by suxamethonium 50 All the patients were artificially ventilated PV & Hyperventilation) with a mixture of –50 per cent oxygen and nitrous oxide ialgesia was provided using fentanyl and further uscular relaxation was obtained with d pocurarine (Albertson et al 1956 Neill & Nixon 65) All the patients received 1 0 l Ringer s tate and 1 0 l fructose on the day of the surgery Prior to the commencement of sodium troprusside infusion (0 01 per cent solution in 5 per cent glucose) an intra arterial cannula was inserted into the radial artery for the continuous monitoring of the mean arterial blood pressure (MABP) Five minutes before the skin incision the MABP was lowered to 60–65 mmHg Torr and this was maintained throughout the surgery Halothane was added only when absolutely necessary The SNP infusion was discontinued just before the closure of the surgical wound in order to restore the blood pressure to the pre-SNP levels. The surgeon was then asked to check the bleeding points if any The recording of the MABP was as in Table 2 Arterial blood specimens were collected before during and after the administration of SNP in order to keep an eye on any possible changes in the blood chemistry of the patient All the patients were lying in the supine position during surgery

RESULTS

Haemorrhage during surgery The average blood loss during controlled hypotension was 212 ml (range 160–350 ml) In the normotensive group the mean surgical

Table 2 Mean arterial blood pressure (MABP) in mmHg (range in parentheses)

Normotension		Controlled hypotension	
t admission	126 1 (87–180) [a]	At admission	125 2 (85–183)
efore induction of anaesthesia	114 (80–107) [b]	Before induction of anaesthesia	108 2 (90–130) [c]
uring operation	93 7 (80–107)	After induction of anaesthesia	91 8 (73–117) [d]
		During SNP infusion	64 4 (60–70) [e]
		10 mins after discontinuation of SNP	92.6 (78–120)
fter extubation	98 8 (75–133)	After extubation	104 1 (85–127)
t recovery from anaesthesia	116 2 (80–140)	At recovery from anaesthesia	119 (83–143)

Difference a–b=20 3 (N S)
Difference c–d=36 4 ($P<0.05$)
Difference c–e=43 8 ($P<0.001$)

Table 3 Mean haemorrhage in ml (range in parentheses)

	Normotension	Controlled hypotension
Haemorrhage during operation	1038 (500–1750) [a]	212 (160–350) [b]
Postoperative haemorrhage	808 (590–1205)	877 (695–1130)
Total haemorrhage	1846 (1090–2725) [c]	1328 (905–1335) [d]

Difference a b=826 ($P<0.001$)
Difference c–d=518 ($P<0.01$)

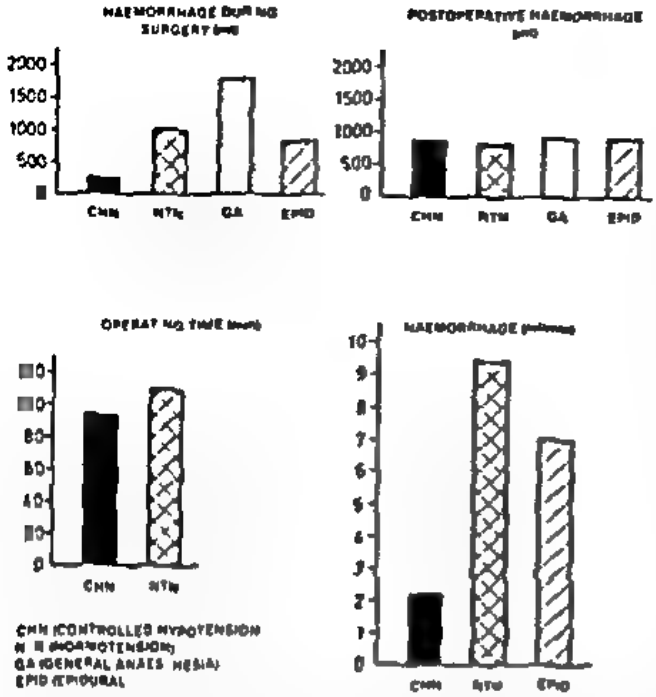

Figure 1 Haemorrhage and operating time during surgery for total hip replacement with different anaesthetic techniques

haemorrhage was 1038 (range 500–1750 ml) The difference between the two groups was highly significant, i e 826 ml ($P<0.001$) (Table 3) In the Swedish investigation, the average blood loss was 1775 ml using general anaesthesia but it was reduced to 820 ml using epidural anaesthesia (Figure 1) The difference between the epidural and the hypotensive groups was also highly significant ($P<0.001$)

Postoperative haemorrhage It was noted that the blood loss after CHN was slightly more (mean 877, range 695–1130 ml) as compared with NTN (mean 808, range 590–1205 ml) The difference, however, was clinically insignificant (Table 3) In the work done at Uppsala the postoperative blood loss was 900 ml with both epidural and general anaesthesia (Figure 1)

Total haemorrhage The total blood loss under controlled hypotension was on average 1328 ml (range 905–1335 ml) as compared with the normotensive group where the mean haemorrhage was 1846 ml (range 1090–2725) The difference between the two groups significant ($P<0.01$) (Table 3)

Operating time The operating time w reduced to a certain extent, i e from a of 109 4 min (range 95–120) with sion to a mean of 94 min (range 82–105) hypotension ($P<0.05$) (Table 1)

Bilateral total hip replacement In the bilaterally operated patients the di the blood loss during the operations wa average 820 ml The operating time reduced by 15 per cent

Blood transfusions A blood loss of more 500 ml was replaced by homologous b during the operation or immed afterwards With CHN the patients requ an average of 1 6 units of blood Under N the unilateral and the bilateral replacements needed 3 3 and 3 16 units blood, respectively Under hypotension no single patient required transfusion du surgery The difference in blood transfus between the normotensive and hypoten groups was highly significant ($P<0.001$)

Clinical evaluation of the patients

The following unusual complications w observed,

	Normotension	Controlled hypotension
	1	–
Moderate haematoma	2	1
Thrombophlebitis		
Myocardial insufficiency (moderate total haemorrhage 2725 ml)	1	–
Supraventricular tachycardia during SNP infusion	–	1
(treated with practolol)	–	6
Moderate reduction in Po_2	–	1
Accidental fracture		

Under SNP-induced hypotension one ıtient developed a tachycardia of 150/min he was treated with practolol and the pulse abilized and no further complications ısued One patient needed 0 5–1 per cent alothane ın order to maintain the MABP at ıe desired low level. During SNP ımınıstration there was an arterial reduction f Po_2 ın six patients (mean reduction 13 2 er cent) as compared with pre-SNP levels. lowever all patients acquired their normal o_2 levels after the discontinuation of sodium ıtroprusside Postoperatively, there was ne incident of thrombophlebitis ın the ypotensive group 30 days after surgery It ras not related to SNP and the patient was eated successfully A moderate haematoma ccurred ın the normotensive group There vere no such complications after SNP dmınıstration One of the hypotensive atients sustained a fracture of the femur, on he day before discharge She was reoperated pon and had to stay ın the hospital for everal months. This patient had been doing ery well before this accident happened and it ould not be attributed ın any way to the ıypotension The postoperative diuresis was lelayed ın patients ın the hypotensive group ıut when compared to the normotensive group there was no significant difference linically There was no incidence of oligurea ır anurea ın patients given controlled ıypotension At the time of the insertion of he acrylic material there was no change ın ıny of the parameters being monitored con- ınuously However, there was a slight eduction ın systolic blood pressure ın two of he normotensive patients (a mean reduction of 11 per cent) The postoperative clinical valuation was conducted with the assistance of the medical department of the clinic. In the 25 patients investigated, there was no evidence of cardiovascular, cerebrovascular, enal or hepatic complications immediately after surgery or during the ensuing days. All he patients were discharged after an average ıospital stay of 31 days (range 29–41) with the exception of the patient who sustained a fracture of the femur

DISCUSSION

Systematic hypotension without compensatory oxygenation of the central nervous system leads to neuropathological consequences derogatory to cerebral function due to reduction ın the cerebral blood flow However, the circulatory insufficiency responsible for the diffuse changes ın the brain of the Rhesus monkey, ın the study by Brierley & Excell (1966), has not been attributed entirely to the systemic hypotension but to a combination of hypotension and the head-up position of the subject (Adam et al 1966) This combination results ın a markedly reduced oxygenation of the brain tissue and thus a deleterious effect on brain metabolism (Brierley & Excell 1966) The effects of deliberate hypotension on cerebral haemodynamics are dependent largely on the compensatory mechanisms present ın an individual There appears to be little danger of cerebral anoxia ın the supine position when the mean arterial blood pressure is reduced to a level as low as 55 mmHg (Morris et al 1953) with ganglion blockade There is no evidence of cerebral dysfunction ın induced hypotension as long as the blood flow ın the brain is not interrupted significantly (Slack & Walter 1963) Deliberate hypotension is regarded as safe, as long as the systolic blood pressure is not reduced below 50 mmHg (Slack & Walter 1964) In actual practice, levels of mean arterial blood pressure lower than 60–65 mmHg are not necessary and no undesirable effects have been reported with a combination of careful monitoring and correct positioning of the patient subjected to induced hypotension (Royester et al 1951, Eckenhoff 1955, Tough 1960, Enderby 1961, Linacre 1961, Lindop 1975) Continuous arterial monitoring is a simple procedure and without ill-effects on the patients (Brown et al 1969, Zorab 1969) This was achieved in all 25 patients in the present investigation and did not inconvenience the patients in any way There were no psychological disturbances, assessed on the same principles as suggested by Eckenhoff et al (1964).

Respiratory function has not been found to be reduced after exposure to deliberate hypotensive anaesthesia On the contrary it has been proposed that hypotension can increase the vital capacity of the patient (Bromage 1956) There was no evidence of any significant changes in the pattern of diuresis as compared to normotensive anaesthesia Measurement of diuresis in relatively short-term surgery (mean operating time, 94 min) was considered unjustifiable due to the possible risk of infection Previous studies have shown that induced hypotension does not significantly change the renal blood flow, due to the presence of compensatory mechanisms resulting in renal vasodilatation and increased renal plasma flow offering protection from significant anoxic effects (Shipley & Study 1951, Miles et al 1952, Evans & Enderby 1952)

After these comprehensive studies on the capability of the vascular system to withstand a low systolic blood pressure of 50 mmHg and attain recovery by compensatory methods (Kohlstaedt & Page 1943), patients were submitted to a brief period of simulated shock, with simultaneous continuous monitoring, with beneficial results In addition to trials with arteriotomy (Bilsland 1951), high spinal anaesthesia has been employed concomitantly to facilitate surgery (Sarnoff & Arrowood 1946, Lynn et al 1952) Thus surgery on the hip which was considered a serious undertaking has been rendered more beneficial and without grave after effects (Kern 1952, Welch et al 1975, Donaldson 1975) Nevertheless the fact remains that, in the performance of arthroplasty, both trauma and profuse haemorrhage remain a challenge to the surgeon and the anaesthesiologist The prevention of shock can be accomplished by efficient surgical techniques and prompt blood transfusion (Keith 1977) but it is a disturbing fact that one has to submit these often old and frail patients to massive blood transfusions

For several years methonium compounds as well as trimetaphan (arfonad) have been employed to avoid cumbersome blood transfusions or in the majority of the cases diminish them Recent clinical application of a peripheral vasodilator, sodium nitroprusside, which was recommended as early as 1929 by Johnson, has solved many problems for those engaged in hypotensive anaesthesia However, its high potency and the use of inadvertently large doses have led in a few cases, to highly disappointing results (MacRae & Owen 1974 and others) which cannot be overlooked After its initial clinical trials (Page et al 1955, Moraca et al 196 Taylor et al 1970, Siegal et al. 1971), its metabolic effects have been extensively investigated (Vesey et al 1974 1976) and it has been found not to cause any significant changes in cerebral haemodynamics (Griffith et al 1974) It is thus considered superior to other hypotensive agents (Styles et al 19 Landauer 1976) It can, however cause tachycardia as well as moderate reduction of the arterial Po_2 levels but these return to normal levels after its discontinuation (Wildsmith et al 1975) The maximum dose which earlier was considered to be 3 5 mg/kg body wt (McDowall et al 1974) has been reduced to 1 5 mg/kg body wt after comprehensive investigations (Vesey et al 19 6) In the study reported herein an average dose of 0 54 mg/kg body wt was employed (Table 4), which is well below the recommended maximum dose In a further investigation it has been demonstrated that the dosage of SNP can be successfully lowered by using larger doses of neuroleptic drugs in patients undergoing a variety of different types of surgery (Vazeery et

Table 4 Sodium nitroprusside (SNP) infusion

Duration of SNP infusion (mean and range)	80 (66–100) min
Amount of SNP (mean and range)	37 4 (13–50) mg

) Its use over longer periods is not recom-
ended (Nourok et al 1964) Controlled hypo-
ension accomplished by a combination of
odium nitroprusside, curare (Thomas 1957,
Jeill & Nixon 1965), and moderate hyperven-
lation (Schieve & Wilson 1953, Harp &
Vollman 1973) can be extremely beneficial to a
atient undergoing total replacement of the hip,
rovided the clinical state of the patient is
onitored continuously by experienced anaes-
hesiologists. It has its value in major ortho-
aedic surgery when it is mandatory to avoid
arge blood transfusions.

EFERENCES

dams, A P (1975) Techniques for vascular control for deliberate hypotension during anaesthesia. *Brit J Anaesth* 47, 777–792.

dams, J H, Brierley, J B, Connor, P C & Treip, C S (1966) The effects of systemic hypotension upon the human brain Clinical and neuropathological observations in 11 cases. *Brain* 89, 235–267

lbertson, H A, Trout, H H & Morfin, E (1956) The safety of curare in anaesthesia *Ann Surg* 143, 833–837

ulsland, W L (1951) Controlled hypotension by arteriotomy in intracranial surgery *Anaesthesia* 6, 20–25

rierley, J B & Excell, B J (1966) The effects of profound systemic hypotension upon the brain of M Rhesus. Physiological and pathological observations. *Brain* 89, 269–297

romage, P R. (1956) Hypotension and vital capacity *Anaesthesia* 11, 139–148

rown, A E., Sweeny D B & Lumley, J (1969) Percutaneous radial artery cannulation. *Anaesthesia* 24, 532–536

ruce A. W (1960) Blood loss in prostatic surgery *Brit J Surg* 32, 422–426

onaldson W F (1975) Orthopaedic surgery *Surg Gynec Obstet* 140, 204–205

ckenhoff J E (1955) The use of controlled hypotension for surgical procedures. *Surg Clin N Amer* 35, 1579–1584

ckenhoff, J E., Compton, J R., Larson, A. & Davies, R. M (1964) Assessment of cerebral effects of deliberate hypotension by psychological measurements. *Lancet* ii, 711–714

nderby G E. H (1961) Hypotensive anaesthesia in plastic surgery *Brit J plast Surg* 14, 41–46.

Evans, B & Enderby G E H (1952) Controlled hypotension and its effect on renal function. *Lancet* i, 1015–1016

Gillies, J (1950) Anaesthetic factors in the causation and prevention of excessive bleeding during surgical operations. *Ann roy Coll Surg Engl* 7, 204–221

Glenn, W W L, Hampton, L J & Goodyer, A V N (1954) Use of controlled hypotension in large blood vessel surgery *Arch Surg* 68, 1–6

Griffiths, D F J, Cummins, B H., Greenbaum, R., Griffith, H B, Staddon, G E, Wilkins, D G & Zorab, J S M (1974) Cerebral blood flow and metabolism during induced hypotension with sodium nitroprusside *Brit J Anaesth* 46, 671–679

Harp, J R & Wollman, H (1973) Cerebral metabolic effects of hyperventilation and deliberate hypotension. *Brit J Anaesth* 45, 256–262

Holms, F (1956) Induced hypotension in orthopaedic surgery Hexamethonium bromide (C6) in 407 orthopaedic operations. *J Bone Jt Surg* 38-B, 846–854

Hopkins, D A B, Hurter, D & Jones, C. M (1957) Promethazine and pethidine in anaesthesia a new approach to pre-anaesthetic medication. *Anaesthesia* 12, 276–281

Jakobson, S & Wigren, A. (1972) Epiduralanestesi och blodning vid stor höftkirurgi. *Svenska Lak.-Tidn* 69, 267–270

Johnson C C. (1929) The action and toxicity of sodium nitroprusside *Arch int Pharmacodyn* 35, 480–496

Keith, I (1977) Anaesthesia and blood loss in total hip replacement *Anaesthesia* 32, 444–450

Kern, E R. (1952) Problems of anaesthesia and transfusion in major surgery on the hip-joint *Anesth Analg Curr Res* 31, 350–357

Kohlstaedt, K G & Page, I H (1943) Haemorrhagic hypotension and its treatment by intraarterial and intravenous infusions of blood *Arch Surg* 47, 178–191

Landauer, B (1976) Die kontrollierte hypotension mit nitroprussidnatrium. *Anaesthesist* 25, 266–273

Learmonth, J (1976) The surgeon and ischaemia *Brit med. J* 1, 743–748

Lewis, J (1951) Value of hypotensive drugs in minimising blood loss in thoracic surgery *Lancet* ii, 150–151

Linacre J L. (1961) Induced hypotension in gynaecological surgery A review of 1000 major cases. *Brit J Anaesth* 33, 45–50

Lindop M J (1975) Complications and morbidity of controlled hypotension. *Brit J Anaesth* 47, 799–803

Lynn, R B, Sancetta, S M, Simeone, F A & Scott, R W (1952) Observations on the circulation in high spinal anaesthesia *Surgery* 32, 195–213

MacRae, W R & Owen, M (1974) Severe metabolic acidosis following hypotension induced with sodium nitroprusside *Brit J Anaesth* 46, 795–797

McDowall, D J, Keany, N P, Turner, J M, Lane, J R & Okuda, Y (1974) The toxicity of sodium nitroprusside *Brit J Anaesth* 46, 327–332

Miles, B E., Wardener, H E, Churchill-Davidson, H C & Wylie, W D (1952) The effect on the renal circulation of pentamethonium iodide during anaesthesia *Clin Sci* 11, 73–79

Moraca, P P, Bitte, E. M, Hale, D E, Wasmuth, C. E & Poutasse, E. F (1962) Clinical evaluation of sodium nitroprusside as a hypotensive agent. *Anesthesiology* 23, 193–199

Morris, G C, Jr, Moyer, J H, Synder, H B & Haynes, B W, Jr (1953) Cerebral haemodynamics in controlled hypotension *Surg Forum* 4, 140–143

Nayman, J (1960) Treatment of haemorrhage with ganglion blocking agents A preliminary report *S Afr med J* 34, 26–31

Neill, R S & Nixon, B A (1965) Halothane and tubocurarine A study of changes in blood pressure *Anaesthesia* 20, 250–257

Nicholson, M J, Sarnoff, S J & Crehan, J P (1953) The intravenous use of a thiophanium derivative (Arfonad-RO2-2222) for the production of flexible and rapidly reversible hypotension during surgery *Anesthesiology* 14, 215–225

Nourok, D S, Glossock, R J, Solomon, D H & Maxwell, M H (1964) Hypothyroidism following prolonged sodium nitroprusside therapy *Amer J Med Sci* 248, 129–138

Page, I H, Cocoran, A C, Dustan, H P & Koppanyi, T (1955) Cardiovascular actions of sodium nitroprusside in animals and hypertensive patients. *Circulation* 11, 188–198

Payne, J P (1956) Histamine release during controlled hypotension with arfonad Proceedings World Congress of Anaesthesiologists, Scheveningen, The Netherlands, September, 1955, pp 180–181 Burgess Publ. Co, Minneapolis

Royester, H P, Pendergrass, H P, Walker, J M & Barnes, M R N (1951) The value of blood volume determinations in radical operations for cancer of the head and neck, including measurements of operative blood loss. *Ann Surg* 133, 830–836

Safar, P (1955) A study of deliberate ' in anaesthesia with special considerat surgical blood loss in comparable group normotensive and hypotensive anaesth *Surgery* 37, 1002–1018

Sarnoff, S J & Arrowood, J G (1 Differential spinal block a preliminary re *Surgery* 20, 150–159

Schieve, J F & Wilson, W P (1953) The cha in cerebral vascular resistance of man m perimental alkalosis and acidosis. *J Invest* 32, 33–38

Shipley, R E & Study, R S (1951) Change renal blood flow, extraction of in glomerular filtration rate, tissue pressure urine flow with acute alterations of renal ar blood pressure *Amer J Path* 167, 676–68

Siegal, P, Moraca, P P & Green, J R. (19 Sodium nitroprusside in the surgical treatm of cerebral aneurisms and arteriove malformations. *Brit J Anaesth* 43, 790–79

Slack, W K. & Walter, W W (1963) Cere circulation studies during hypoten anaesthesia using radioactive Xenon 1 *Lancet* i, 1082–1083

Slack, W K. & Walter, W W (1964) Cere circulation in induced hypotension Meas ment using radioactive Xenon 133 *Anaesthe* 19, 494–500

Smith, D L, Didier, E P & Clagett, O T (19 Controlled hypotension in radical mastectom Second 5-year review *Ann. Surg* 1 263–266

Steven, R. J M & Tovell R M (1954) H amethonium salts as an aid to the orthope surgeon *J Amer med Ass* 154, 402–404

Styles, M, Coleman, A J & Leary, W P (19 Some hemodynamic effects of sodi nitroprusside *Anesthesiology* 38, 173–176.

Taylor, T H, Styles, M & Lamming A J (19 Sodium nitroprusside as a hypotensive agent anaesthesia *Brit J Anaesth* 43, 859–864

Thomas, E T (1957) The effect of Tubocurarine chloride on the blood pressure the anaesthetised patient *Lancet* i, 772–773.

Tough, I C K (1960) Induced hypotension postoperative bleeding *Anaesthesia* 1 154–157

Vazeery, A K., Skere, S, Aspelund, K., Sydne S & Halvorsen, S Sodium nitroprusside hypotensive agent in surgery Determination its minimum requirement in combination wi larger doses of neuroleptic drugs. *Brit J Anaesth* (Submitted for publication).

Vesey, C. J, Cole, P V, Linnell J C & Wilson J (1974) Some metabolic effects of sodiu nitroprusside in man *Brit med. J* 1 140–142

:y, C J, Cole, F V & Simpson, P J (1976) Cyanide and thiocyanate concentrations ollowing sodium nitroprusside infusion in ıan. *Brit J Anaesth* **48**, 651–660

:h, R B, Taylor, L W & Wynn, G (1975) Total hip replacement as a salvage in traumatic :sions about the hip *Surg Gynec Obstet* **140**, 708–714

lsmith J A W, Drummond, G B & MacRae, W R (1975) Blood-gas changes luring induced hypotension with sodium nitroprusside *Brit J Anaesth* **47**, 1205–1211

Yashon D, Locke G E, Bingham, W G, Wiederholt, W C & Hunt, W E. (1971) Cerebral function during profound oligemic hypotension in the dog *J Neurosurg* **34**, 494–499

Zorab, S M (1969) Continuous display of the arterial pressure A simple manometric technique *Anaesthesia* **24**, 431–437

respondence to Afzal K Vazeery, Department of Anaesthesiology, Central Hospital of Rogaland, ranger, Norway

acta orthop scand 50, 443–449, 1979

STEOSYNTHESIS OF DISPLACED FRACTURES F THE FEMORAL NECK

Comparison Between Smith-Petersen Osteosynthesis and iding-Nail-Plate Osteosynthesis – A Radiological Study

:TER A FRANDSEN

-partments of Orthopaedic Surgery O and Ø, University Hospital, Odense, Denmark

Smith-Petersen osteosynthesis has been compared with sliding-nail-plate osteosynthesis in a prospectively planned, randomized, follow-up study of 197 cases of displaced medial fractures of the femoral neck. A total of 131 patients were followed for more than 2 years. After Smith-Petersen osteosynthesis 66 per cent of the fractures united and after sliding nail-plate osteosynthesis 77 per cent united. The results showed that the choice of fixation devices is of minor importance compared with exact reduction of the fracture and optimal positioning of the nail

Key words choice of fixation devices, displaced medial fracture of the femoral neck, osteosynthesis

Accepted 26 xi.78

ince 1931 when Smith-Ptersen et al introuced the trifin nail in the treatment of femoral eck fractures, this method has been widely sed in the Scandinavian countries. During the ist 20 years many new methods of osteosynnesis have appeared and one of these is the liding-nail-plate osteosynthesis

The report presents the results of a andomized, prospectively planned, follow-up xamination of displaced medial fractures of he femoral neck, in which we have compared he Smith-Petersen osteosynthesis and the liding-nail-plate osteosynthesis

/ETHOD

In admission to hospital, traction (usually ithout internal rotation) was applied through the bial tubercle Final adjustment of the fracture ras made under general anaesthesia on the fracture able with fluoroscopy and an image intensifier Operation was performed at the earliest opporunity, but not as an emergency

A Thornton nail was used in the Smith-Petersen osteosynthesis (Figure 1) The appliance shown in Figure 2 was used in the sliding-nail-plate osteosynthesis. In both osteosyntheses the aim was to place the nail as steeply as possible, so that it rested on the femoral calcar and was a little posterior and inferior to the centre of the femoral head (Figure 3)

In the postoperative treatment early mobilization was encouraged. If there were no contraindications, the patient sat in a chair the day after the operation On the second or third day, the patient was allowed to walk with elbow crutches. Weight-bearing on the operated leg up to the threshold of pain was allowed. As avascular necrosis of the femoral head most often occurs between 1 and 2 years after the operation, it was decided to make the follow-up period no less than 2 years, unless failure was evident earlier

PATIENTS

This study includes all patients with displaced medial fractures of the femoral neck treated in the

0001-6470/79/040443-07$02.50.0

© 1979 Munksgaard, Copenhagen

Figure 1 Radiograph of the Thornton nail in a femoral neck fracture

Figure 2 The sliding nail plate A nail in its longest and shortest position.

Orthopaedic Departments O and II between March 1972 and May 1975

The fractures have been divided according to Garden s classification (1961) Stage 1 incomplete fracture (impacted valgus fracture) Stage 2 complete fracture without displacement Stage 3 complete fracture with partial displacement Stage 4 complete fracture with full displacement Only stage 3 and stage 4 fractures have been considered in this series.

The two orthopaedic departments receive emergency admissions on alternating days and the patients have been randomized according to this. To a large extent the operations were performed by the same doctors in both departments, because all doctors except the chief surgeons rotate between the two departments for periods of 1 year

From March 1972 to May 1975 205 patients with 207 displaced medial fractures of the femoral neck were admitted to the hospital. The following 10 patients were excluded from the study three patients with pathological fractures three patients who died before the operation was performed one patient with a fracture at least 4 weeks o surgery was not indicated one patient in the fracture could not be reduced and there Moore prosthesis was inserted instead patients due to age – both 28 years old.

Smith Petersen osteosynthesis was perfor 100 cases and sliding nail plate osteosynthe 97 cases. The age distribution is given in T In the Smith Petersen group the average ag 78 years (range 51 96 years). In the sliding plate group the average age was 76 years 48–93 years) Thirty-eight patients in the S Petersen group and 24 patients in the sliding plate group died before the 2 year follo period was over Four patients (one w American tourist) – all in the sliding-nail group – were lost to follow-up

For those fractures that united the av follow up period in the Smith Petersen grou 31 months (range 24–65 months) and i sliding nail plate group 34 months (range months)



ure 3 Radiograph of the sliding nail plate in a noral neck fracture

ESULTS

he results were divided into three groups
Union which implied bone union of the fracture with radiographically visible trabeculation across the fracture line
Failure, which implied any recurrence of the fracture deformity including all cases in which the appliance failed Avascular necrosis is not included in this group
A group was planned as Position holding, but union doubtful This implied that bone union was not visible, although the fracture maintained its position After 2 years follow-up no patients were left for this group

The overall results are listed in Table 2 In the Smith-Petersen group 66 per cent united and in the sliding-nail-plate group 77 per cent united The frequency of avascular necrosis was about 20 per cent in both groups. In Table 3 the results are analysed according to Garden's classification

At the end of each operation – the patient still under general anaesthesia – radiographic pictures both in the frontal and lateral view were taken The analysis in Tables 4 and 5 are based on these pictures. The reduction of the fracture was measured both in the frontal and lateral view In the frontal view the Garden angle (1961) between the central axis of the medial group of trabeculae in the capital fragment and the line of the medial femoral cortex was used This angle is normally 160–165 degrees (Figure 4) In the lateral view the anterior or posterior angulation of the head was measured by the angle between a line drawn from the midpoint of the fracture surface of the distal fragment to the centre of the femoral head and a line through the central axis of the neck of the femur The reduction of the fracture was divided into Good frontal angle 160–179 degrees, lateral angle less than 15 degrees. Fair frontal angle either 150–159 degrees or 180–189 degrees, lateral angle 15–25 degrees. Poor frontal angle either less than 150 degrees or more than 190 degrees, lateral angle more than 25 degrees. The results are listed in Table 4

The position of the tip of the fixation appliance was analysed according to three segments of the femoral head in both frontal

Table 1 Age distribution of 197 cases of displaced medial fracture of the femoral neck

ıge	40–49	50–59	60–69	70–79	80–89	90–	Total
ımith Petersen nail	—	7	16	34	35	8	100
·liding-nail plate	1	5	19	33	31	8	97

Table 2 Results of the follow-up

Type of osteosynthesis	Number of patients	Union	Failure	
Smith-Petersen	62	41 (66 %)	21	8 (20 %)
Sliding-nail-plate	69	53 (77 %)	16	11 (21 %)

$0.20 > P > 0.10$, Chi square test

Table 3 Results of the follow-up related to the degree of fracture displacement

Type of osteosynthesis	Displacement	Number of patients	Union	Failure	Avascular necrosis
Smith-Petersen	Stage 3	33	26 (79 %)	7	6 (23 %)
	Stage 4	29	15 (52 %)	14	2 (13 %)
Sliding-nail	Stage 3	35	32 (91 %)	3	6 (19 %
	Stage 4	34	21 (62 %)	13	5 (24 %

In both groups, fractures in stage 3 healed significantly better than fractures in stage 4 ($P < 0.0$ square test)

Table 4 Results of the follow-up related to the quality of reduction

Type of osteosynthesis	Reduction	Number of patients	Union	Failure	Avascular necrosis
Smith-Petersen	Good	31	25 (81 %)	6	5
	Fair	20	15 (75 %)	5	3
	Poor	11	1 (9 %)	10	—
Sliding-nail	Good	41	36 (88 %)	5	7
	Fair	19	14 (74 %)	5	2
	Poor	9	3 (33 %)	6	2

Table 5 Results of the follow-up related to the position of the nail

Type of osteosynthesis	Position of the nail	Number of patients	Union	Failure	Avascular necrosis
Smith-Petersen	Good	36	28 (78 %)	8	6
	Fair	14	10 (71 %)	4	1
	Poor	12	3 (25 %)	9	1
Sliding nail	Good	39	36 (92 %)	3	7
	Fair	21	15 (71 %)	6	3
	Poor	9	2 (22 %)	7	1

gure 4 Radiograph illustrating the Garden igle in a normal (right side) and a fractured moral neck (see text for details)

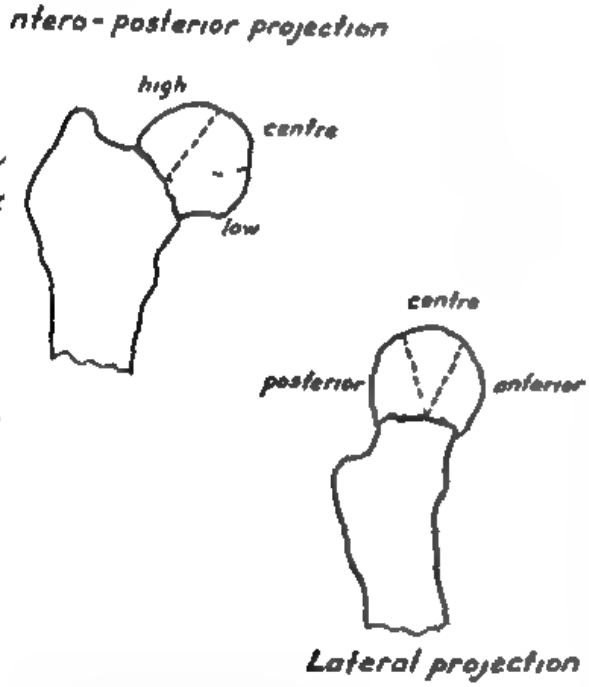

gure 5 Diagrams illustrating the different areas the femoral head in which the various positions the nails were recorded

Figure 6 Radiograph showing that the sliding-nail has telescoped across the fracture line followed by redisplacement of the fracture

ıd lateral radiographs (Figure 5), and vided into three groups accordingly Good ntral in both views. Fair posterior and/or ferior Poor anterior and/or superior If the p of the nail was not within 1 cm of the ticular surface of the femoral head, the osition of the fixation appliance was graded one group Furthermore, a few ses with the nail placed in the inferior ıd/or posterior position were classified as poor, because the position of the nail was so peripheral that it was outside the neck and/or the head of the femur The results are listed in Table 5

In the Smith-Petersen group 21 cases did not unite In 12 (19 per cent) of these cases the nail slid out of the capital fragment In six cases (9 per cent) in the sliding-nail-plate group the nail telescoped across the fracture line, allowing redisplacement of the fracture (Figure 6)

The frequency of certain postoperative complications are listed in Table 6

DISCUSSION

From Table 7 it can be seen that the results in this study do not differ a great deal from

Table 6 Postoperative complications in 197 patients operatively treated for a displaced medial of the femoral neck

Complications	Smith-Petersen	Sliding-nail-pla
Death within 1 month	14	7
Cardiac diseases	2	3
Pulmonary diseases	15	9
Pulmonary embolism	5	3
Phlebothrombosis	3	1
Deep infection	1	2
Decubital ulcer	8	6
Number of patients with complications	34	25

If a patient had more than one complication, each complication is listed separately

Table 7 Survey of published follow-up studies after operative treatment of medial fractur femoral neck

	Union (per cent)		Avascular necrosis (per c	
	Stage 3	Stage 4	Stage 3	Stag
SLIDING-NAIL-PLATE				
Brown & Abrami (1964)	90	65	21	30
Graham (1968)	85	71	28	28
Barnes et al (1976)	75	70	—	—
Present study	91	62	19	24
SMITH PETERSEN				
Nieminen (1975)	66	65	16	26
Barnes et al (1976)	58	49	—	—
Present study	79	52	23	13

ly studies using Garden's classification have been included in Table 7

ults reported earlier Barnes et al (1976) nd in a prospective, non-randomized, lti-centre trial that the failure rate was sistently about 20 per cent higher after ith-Petersen nailing compared to other ition devices, including sliding-nail-plate, ssed screws, low angle screws and low angle nails (Table 7) However, their results have not been confirmed in the present series, which showed that the rate of union was only about 10 per cent higher in the sliding-nail-plate group than in the Smith-Petersen group

From Tables 4 and 5 it is evident that both an exact reduction of the fracture and a centrally placed nail are the most important factors in obtaining a good Furthermore, it can be seen that the high rate of union in stage 3 fractures low rate of union in stage 4 fractures implies that Garden's classification (19 some extent can be used to pick out patients most suited for a primary pro replacement

The frequency of postoperative c cations was a little higher after S Petersen nailing than after sliding-nail osteosynthesis We can offer no explan for this, in as much as both the preope and the postoperative treatment were e the same in the two departments

age, which was a little higher in the ith-Petersen group, seems insufficient to lain the difference

The conclusion drawn from this study is t the choice of fixation devices is of minor portance compared with an exact reduction the fracture and an optimal positioning of nail.

FERENCES

nes, R, Brown, J T, Garden, R S & Nicoll, E A. (1976) Subcapital fractures of the femur *J Bone Jt Surg* B, 2–24

Brown, J T & Abrami, G (1964) Transcervical femoral fracture *J Bone Jt Surg* 46-B 648–663

Graham, J (1968) Early or delayed weight-bearing after internal fixation of transcervical fracture of the femur *J Bone Jt Surg* 50-B, 562–569

Garden R S (1961) Low-angle fixation in fractures of the femoral neck. *J Bone Jt Surg* 43-B, 647–663

Niemunen, S (1975) Early weight-bearing after classical internal fixation of medial fractures of the femoral neck *Acta orthop scand* 46, 782–794

Smith-Petersen, M N, Cave, E F & Vangorder, G W (1931) Intracapsular fractures of the neck of the femur *Arch Surg* 23, 715–759

respondence to Peter A Frandsen, Engvej 11, Dk-5230 Odense M, Denmark

JBCAPITAL FRACTURES OF THE FEMUR

-operations with Internal Fixation

RL ZETTERBERG[1], LARS IRSTAM[2] & GUNNAR B J ANDERSSON[1]

partments of Orthopaedic Surgery[1] and Diagnostic Radiology[2], Sahlgren Hospital,
teborg Sweden

Over a period of 5 years, 55 re-operations with internal fixation were performed on 51 patients. The re-operations constituted 9 2 per cent of all [illegible]

location of the fracture

Only 26 per cent of the re-nailed fractures healed Seventy-three per cent showed avascular necrosis and 61 per cent non-union

Key words femoral fractures, femoral neck fractures, femur head necrosis, femur neck, fracture fixation

Accepted 4 1 79

he treatment of subcapital fractures of the mur is a matter of considerable contro- rsy Various methods of internal fixation, as ell as primary prosthetic replacement, all ive their proponents (Boyd & Salvatore 964, Fredriksen et al 1967, Flynn 1974, unter 1974, Steen-Jensen & Holstein 1975, 'Arcy & Devas 1976) The obvious reason r this uncertainty is the high incidence of mplications in these fractures, compli- itions which at present cannot be fully edicted (Garden 1961, 1971, 1974, Ellison Mull 1974, Flynn 1974, McCown & Miller 976)

When reduction and internal fixation is referred, three main complications occur on union, avascular necrosis with late gmental collapse of the femoral head, and roblems related to the internal fixation evice These frequently occur simul- taneously While non-union and avascular ecrosis have been thoroughly discussed in the literature, less interest has been devoted to the problems arising from the fixation device This is understandable since non- union and late segmental collapse are clearly the dominating complications. Also, there are many methods of fixation each having different problems (Albright & Weinstein 1975, Burkhardt et al 1975, Weinstein 1975, Barnes et al 1976)

The problems related to the fixation device are mainly penetration into the hip joint and *lateral slipping of the fixation device with or* without fracture displacement Fracture of the appliance itself and local irritation at the lateral tip of the device also occur When these complications are clinically significant the surgeon can either remove the fixation device without further treatment, insert a new device or insert a prosthesis.

The purpose of the present investigation was to study the results in patients in whom a second fixation device was inserted

001-6470/79/040451-05$02.50.0

© 1979 Munksgaard, Copenhagen

PATIENTS AND METHODS

During the 5-year period, 1965 through 1969, 595 operations were performed in which internal fixation was used in the treatment of subcapital fractures of the femur Fifty-five of these (9 2 per cent) were re-operations.

The re-operations were performed on 51 patients, four were re-operated twice The mean age of the patients in the time of the second operation was 68 years (ranging from 36 to 91 years), 70 years in 40 women, and 61 years in 11 men

Thirty-six patients were followed for more than 1 year, 13 for less than a year, and two were lost to follow-up

In the 36 patients surviving the first year with the femoral head intact, the follow-up was continued until femoral head necrosis was obvious a prosthetic replacement or Girdlestone type operation was performed, or the patient died The Garden system of classification was adopted to determine the type of fracture, the degree of displacement, the accuracy of reduction and the position of the fixation device (Garden 1961, 1964, 1971, 1974, Nieminen & Satokari 1975, Barnes et al 1976)

The fracture was considered united when uninterrupted bone extended over the fracture line, which was partly or completely filled by calcified tissue Pseudarthrosis was defined as a situation in which the fracture line was open and the bone sclerotic on both sides Necrosis of the femoral head was characterized by localized sclerosis and segmental collapse causing deformity

The results were evaluated with respect to the following factors the age and sex of the patient, the delay before the first operation and the time interval between the first operation and re-operation, the indication for re-operation, the type of fracture, the accuracy of reduction, and the position of the fixation device

Statistical analysis was performed at the 5 per cent level of significance using the chi² test

The primary operation

A Stage IV fracture, according to Garden, was present in 44 patients (86 per cent), a Stage III in 5 (10 per cent), and a Stage II in 2 (4 per cent) The operation was performed within 3 days in 16 patients, between 4 and 7 days in 26 and with a delay of 8 to 14 days in 9

Closed reduction was used in 48 patients open in 3 The accuracy of reduction, according to Garden, was acceptable or good in 35 fractures (70 per cent) and poor in 14 (27 per cent) Two

Figure 1 Johansson three-flanged nail. J with a cross nail

sets of radiographs could not be p evaluated The method of fixation Johansson nail in 48 femurs, an Aronsson two and a Thornton nail in one, i.e. flange were used in all patients. Twenty-eight Johansson nails were secured laterally cross-nail to prevent slipping (Figure 1) location of the nail was central on both X-r jections in 19 patients, in one of the project 22, and in none in 8 Again, it was not poss evaluate two of the sets of radiographs (T

The re-operation

The indications for re-operation penetration through the femoral head in (37 per cent) lateral slipping of the nail fracture dislocation in 13 hips (26 per cent lateral slipping with simultaneous dislocat 19 hips (37 per cent) Clinical symptoms present in all subjects, mainly a decrease in range of motion The time between the primary operation and th operation was less than 3 months in 20 p (40 per cent) from 3 to 6 months in 14 (cent) and more than 6 months in 17 (33 per Those patients in whom lateral slipping of t

le 1 Location of the nail (Central means that the nail is positioned within the central 30° of the head in each projection)

ero-posterior ection	Anterior	Lateral projection Central	Posterior
h	0	4	1
tral	4	19	5
r	4	9	3

dislocation of the fracture occurred were, as ile, re-operated on earlier than the others ure 2)

re-operation a Johansson nail was used in atients, an Aronsson nail with a cross-screw 0 (Figure 3) Closed reductions were made in of the 19 fractures in which dislocation rred

SULTS

he 51 patients a third operative procedure necessary in 26 patients, a fourth in nine, a fifth in one Thus, a total of 139 rations were performed on the 51 ients, an average of 2.7 operations each. urteen endoprostheses, 15 nail-removals, Girdlestone operation and 7 nail or screw tions were performed at these later rations

Thirteen fractures united (26 per cent), ile pseudarthrosis occurred in 31 (61 per it) (Table 2) Neither union nor pseud-hrosis was established in the seven ctures followed for less than 6 months.

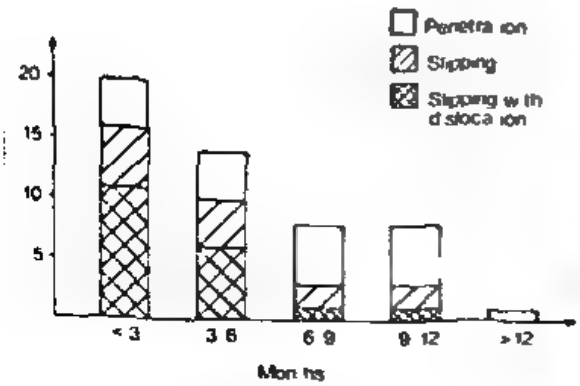

gure 2 The time interval between the first and second nailing for the different indications

Necrosis, with late segmental collapse, occurred in 37 hips (73 per cent) (Table 2). In 30 of these there was a simultaneous occurrence of pseudarthrosis and necrosis.

Figure 3 Aronsson flanged nail Inserted with a cross screw

Table 2 Results

Indication for re-operation	Number of patients	United Number	Pseud-arthrosis Number	Follow up < 6 months	Necr Num
Penetration into hip joint	19	3	13	(3)	15
Lateral sliding/ no dislocation	13	6	5	(2)	8
Lateral sliding/ dislocation	19	4	13	(2)	[illegible]
Total	51	13	31	(7)	37

Seven cases of necrosis developed in hips where the fracture had healed, and in hips with a follow-up of less than 6 months

Of the 13 patients with a follow-up less than a year, five had died, four had had a prosthetic replacement, and two had developed a femoral head necrosis during that time

Age and sex did not statistically significantly influence the result The results were significantly better in patients in whom lateral slipping without simultaneous dislocation of the fracture occurred, than for the two other indications ($P<0.05$, Table 2) The delay before the first operation, the time before re-operation, the type of fracture, the accuracy of reduction and the position of the fixation device were all without statistically significant influence on the end-result

DISCUSSION

The poor results in the present study confirm those reported earlier by Carlquist (1947), Johansson (1964) and Öhman et al (1969) Carlquist found 16 cases of necrosis among 24 re-operated patients, Johansson noted 30 among 48, and Öhman et al observed 9 among 12 The incidence of necrosis is considerably higher than that reported in the literature for primary internal fixation of fractures of the neck of femur (Ohman et al 1969) It is probable that some of the pate in the present study could have benef from the use of a different salvage proced such as a prosthetic replacement. Albrigh Weinstein (1975) have described a number alternative salvage procedures, and Maq (1976) and others advocate the use of femoral osteotomy

Other methods of internal fixation t those used in the present study permit better compression in the fracture are n widely used and seem to improve the prim result (Pugh 1955, Fielding et al. 19 Wehner 1974, Ziegler 1974, Burkhardt et 1975, Fielding 1975, Forgon 1975 Forgon al 1975) The result of the present stu indicates that re-operation with inter fixation is a method in which frequ complications can be expected The risk complications seems particularly high patients in whom a re-dislocation of fracture occurs Prosthetic replaceme should thus be considered as the second operation

REFERENCES

Albright J P & Weinstein S L. (19 Treatment for fixation complications. *Am Surg* 110, 30–36

Barnes, R, Brown J T, Garden, R S & Nav E A (1976) Subcapital fractures of the fem A prospective review *J Bone Jt Surg* 58 2–24

l, H [illegible] & Salvatore, J E (1964) Acute racture of the femoral neck, internal fixation r prosthesis? *J Bone Jt Surg* 46-A, 066–1068

hardt, G, Markwardt, D & Weygandt, A 1975) Die Kirschner Drahtbündelung proximaler Oberschenkelfraktur *Beitr Orthop Traum* 22, 267–272

quist N (1947) Comparison of the results rom non-operative treatment and from osteosynthesis by multiple nailing of medial fractures of the collum femoris. *Acta chir cand* 45, Suppl. 127

rey, J & Devas, M (1976) Treatment of fractures of the femoral neck by replacement with the Thompson prosthesis. *J Bone Jt Surg* 58 B, 279–286.

son N & Mull, T D (1974) Unique anesthetic problems in elderly patients coming to surgery for fracture of the hip. *Orthop Clin N Amer* 5, 493–508

lding J W., Wilson, S & Ratzan, [illegible] (1974) A continuing end-result study of the intracapsular fracture of the neck of the femur treated with the telescoping Pugh-nail. *J Bone Jt Surg* 56-A, 1464–1472.

lding J W (1975) Pugh-nail fixation of displaced femoral neck fractures. A long term follow up *Clin Orthop* 106, 107–116

nn, M (1974) A new method of reduction of fractures of the neck of the femur based on anatomical studies of the hip joint *Injury* 5, 309–317

rgon, M (1975) Bessere Stabilisierung der Schenkelhalsfraktur mittels Zugschrauben-Osteosynthese nach der Principen der AO *Arch. orthop Unfall-chir* 81, 207–217

rgon, M., Mamel, [illegible] & Kuukh, F (1975) Lassen sich mit Verbesserung der Stabilität einer Schenkelhalsosteosynthese die Komplikationen bei der Heilung vermindern. *Arch orthop Unfall-chir* 81, 219–224

edriksen, T, Grewald, I, Hansen, J B, Jensenius, H., Langberg K. & Nielsen, F U (1967) The prognosis for patients with medial femoral neck fracture *Acta chir scand* 133, 369–374

Garden, R S (1964) Stability and union in subcapital fractures of the femur *J Bone Jt Surg* 46-B, 630–647

Garden, R S (1961) Low-angle fixation in fractures of the femoral neck. *J Bone Jt Surg* 43 B, 647–663

Garden, R. [illegible] (1971) Malreduction and avascular necrosis in subcapital fractures of the femur *J Bone Jt Surg* 53-B, 183–197

Garden, R S (1974) Reduction and fixation of subcapital fractures of the femur *Orthop Clin N Amer* 5, 683–712.

Hunter, G A (1974) A further comparison of the use of internal fixation and prosthetic replacement for fresh fractures of the neck of the femur *Brit J Surg* 61, 382–384

Johansson, [illegible] H (1964) The prognosis of femoral neck fractures with special reference to complications and old age *Acta Soc Med upsalien* 69, 125–160

Maquet, P (1976) Guérison de la pseudarthrose du col femoral par modification des contraintes. *Acta orthop belg* 42, 5–11

McCown, P L. & Miller, W A (1976) Long term follow-up of hip fractures. *S med J (Bgham, Ala)* 69, 1540–1542.

Nieminen, S & Satokari, K. (1975) Classification of medial fractures of the femoral neck *Acta orthop scand* 46, 775–781

Öhman, U, Bjorkegren, N-Å & Fahlstrom, [illegible]

Pu

[illegible]

Steen-Jensen, J & Holstein, P (1975) A long term follow-up of Moore-arthroplasty in femoral neck fractures. *Acta orthop scand* 46, 764–774

Wehner, W (1974) Die Schenkelhalsfraktur *Zbl. Chir* 99, 1029–1040

Weinstein, S L. (1975) Femoral neck fractures Complications of internal fixation. *J Iowa St med. Soc* 65, 17–20

Ziegler, R. (1974) Zur Technik der Schenkelhalsnagelung *Beitr Orthop Traum.* 21, 641–642.

rrespondence to Dr Carl Zetterberg Department of Orthopaedic Surgery I, Sahlgren Hospital, S-413 45 teborg, Sweden.

a orthop scand. 50 457–463, 1979

'TAL HIP REPLACEMENT BY THE MULLER-CHARNLEY OSTHESIS

'ollow-up Study of 238 Operations after 2 to 7 years

:N S OLSSON ACKE JERNBERGER & DAGNY TRYGGÖ

artment of Orthopaedic Surgery, Central Hospital of Norrköping, Sweden

A prospective study of 238 total hip replacements, with the Muller prosthesis, [redacted] presented The complications in the total material and the results in 216 hips with follow-up times from [redacted] to 7 years are described. Eighty-four per cent of the hips were free from significant pain and 64 per cent had a total range of motion exceeding 160 degrees. Aseptic loosening of the femoral component, entailing reimplantation, has occurred in 6 7 per cent and in addition, 9 2 per cent show radiological evidence of deterioration of the fixation of the femoral component. No deep infection has been encountered None of the hips has ended as an excision arthroplasty

Key words hip joint surgery, infections in orthopaedic surgery, prophylactic antibiotics, total hip arthroplasty

Accepted 4 : 78

ur hundred and thirty-eight total replace-
nts of the hip joint *ad modum* Muller have
:n performed at the Department of
thopaedic Surgery, Central Hospital of
orrkoping, Sweden, since 1969

The design of the prosthesis and the
erative technique have been described by
uller (1970)

The purpose of this paper is to present the
sults and complications of the first 238
erations and to show that deep infection may
avoided in a general hospital without special
hopaedic facilities if a heavy dose of pro-
ylactic antibiotics [redacted] used

.TIENTS AND METHODS

ie operations were performed from December [redacted] through September 1975 The follow up
nes varied between 2 and 7 years with a mean
low-up time of 3 years and 9 months.

There were 238 operated hips in 207 patients, 131 were women and 107 men. The youngest patient was 40 and the oldest [redacted] years at operation The mean age was 66 years (Table 1)

A total of 216 hips in 187 patients were available for the follow up examination Four hips had been re-operated because of loosening less than 2 years after the original operation, 14 patients, two of whom were bilaterally operated, had died and two [redacted]tients could not be traced.

The preoperative diagnoses were primary osteoarthritis in 170 hips, rheumatoid arthritis in 17 and osteoarthritis secondary to trauma, CDH or epiphyseolysis [redacted] 29

In 30 hips various hip operations had been performed prior to the replacement (Table 2)

The replacement operations were made according to the original description by Muller (1970) The patients as a rule were mobilized on the third postoperative day and allowed to walk with two walking supports during the first 6 weeks. Prophylactic anticoagulants were not used.

The operation took place in a conventional operating theatre From the start of the operation the patients received prophylactic antibiotics

01–6470/79/040457–07$02.50 [redacted]

© 1979 Munksgaard, Copenhagen

Table 1 Sex distribution and age at operation

Age (years)	40–44	45–49	50–54	55–59	60–64	65–69	70–74	75–79	80–84	7
Women		3	9	12	26	37	25	17	2	
Men	1	1	5	15	19	29	20	15	2	
Total	1	4	14	27	45	66	45	32	4	

Numbers include data for both operations in patients operated bilaterally

Table 2 Previous operations

Intertrochanteric osteotomy	9
Osteosynthesis of hip fracture	7
Adductor tenotomy	4
Hemiarthroplasty	5
McKee-Farrar arthroplasty	2
Acetabuloplasty	1
Arthrodesis	1
Epiphyseodesis	1
Total	30

[illegible] stable

To evaluate the results, the patients were questioned and examined both preoperatively and [illegible] the follow-up examination and cl according to the numerical rating described by Merle d'Aubigné & Postel (19 modified by Charnley (1972)

X-ray examination of the hips was performed in all patients who had exceeding 30 mm/h or who felt any discom the hip, but later in the greater part material all hips have been examined

To facilitate the assessment of walkin material was divided according to Charnley into three categories "A" denoting unila involvement and absence of other dis interfering with walking "B" bilater involvement and "C" presence of some contributing to impaired walking In the series 38 patients belonged to category "A" category "B" and 103 to category "C"

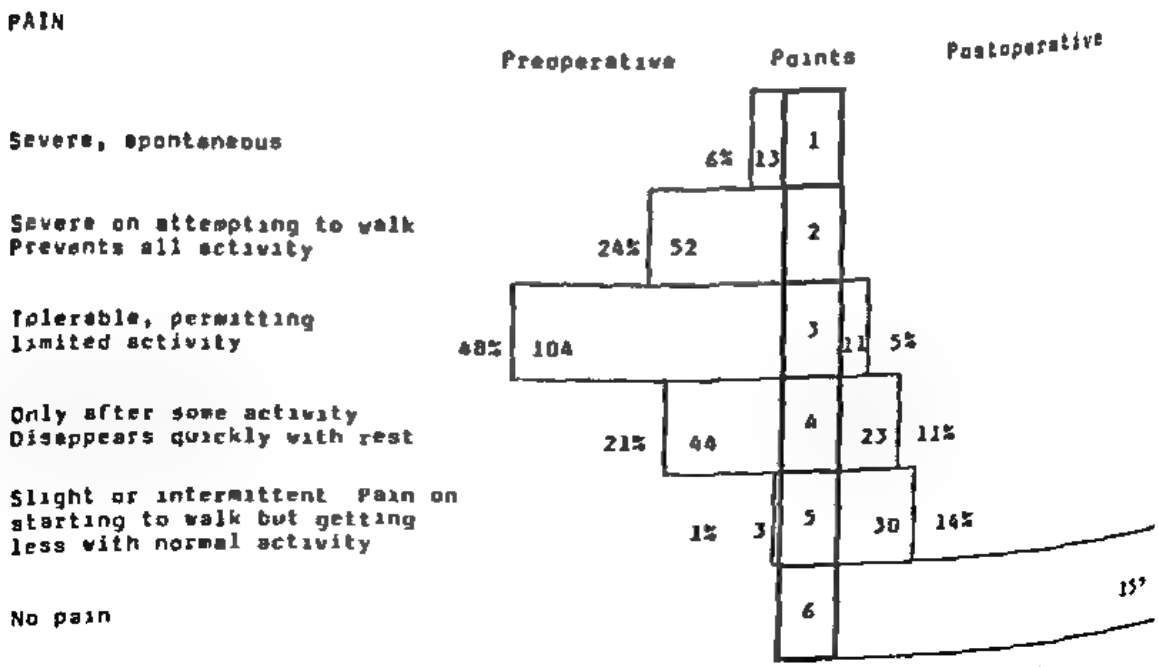

Figure 1 Numerical grading for pre- and postoperative pain in 216 total hip replacements

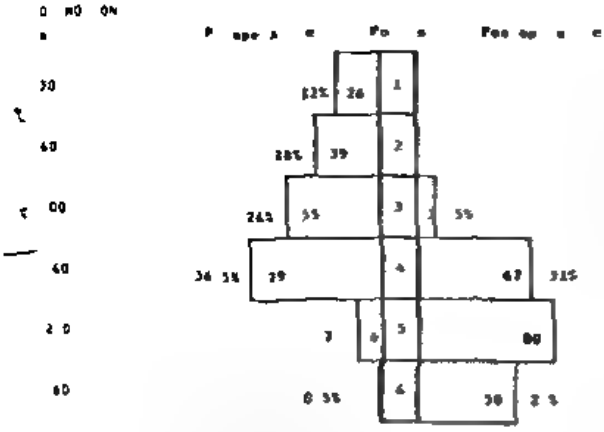

ure 2 Numerical grading for pre- and operative total range of motion in 216 total replacements

SULTS

results with reference to pain, range of tion and ability to walk are presented in gures 1–3 Pain constituted the most portant indication for arthroplasty and the ief of pain was the most striking effect of operation (Figure 1) Before operation, in was continuous at rest or induced by all ovements or weight bearing, causing con- e restriction of activity, in 78 per cent After operation, 84 per cent of the hips were free from significant pain Pain at night, disturbing sleep, was present in 69 per cent of the hips before and in 2 per cent after the operation The use of analgesics because of hip pain is shown in Table 3 The average grade for pain was 2 9 before and 5 5 after the operation

Table 3 Use of analgesics because of hip pain

	Per cent of hips	
	Preop	Postop
Never	25	85
Occasionally	25	10
Regularly	50	5

The range of motion represents the sum of degrees of movement in all three standard directions (Figure 2) The average grading for motion was 3 1 before and 4 9 after the operation, corresponding to a sum of 85° and 180°, respectively To get a reference material, we also measured the range of motion in the contralateral hip at the follow-up examination In 81 asymptomatic hips the

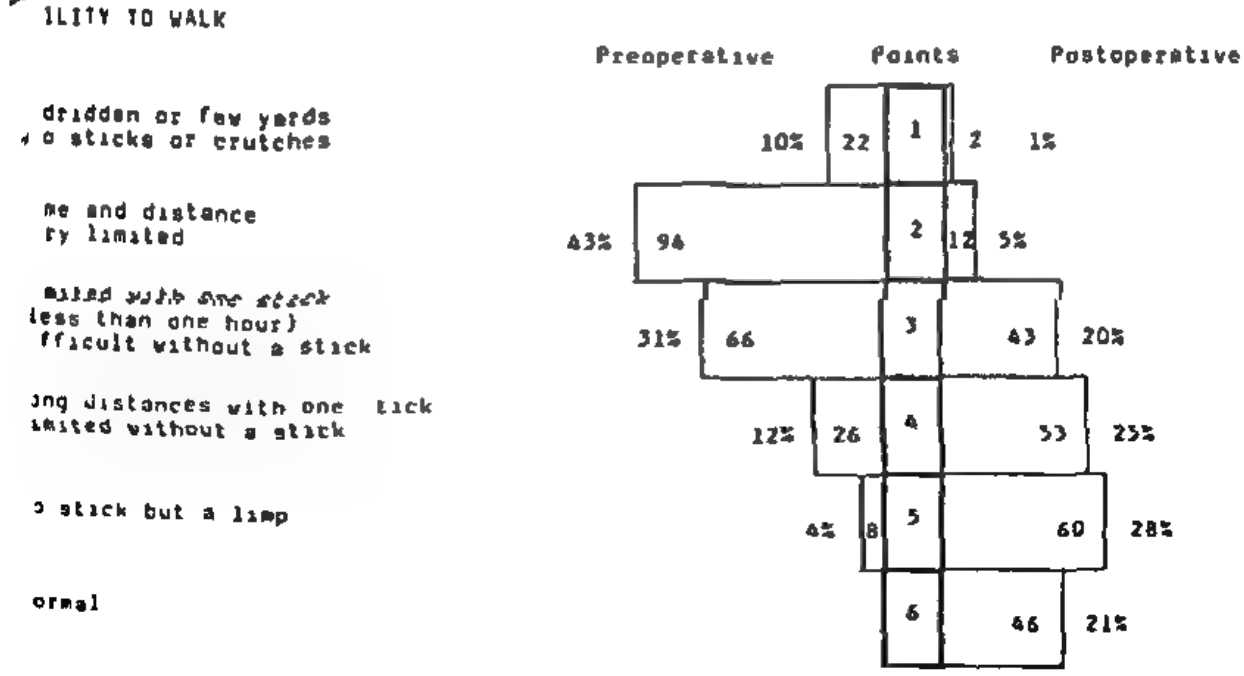

igure 3 Numerical grading for pre- and postoperative walking ability in 216 total hip replacements

Table 1 Sex distribution and age at operation

Age (years)	40–44	45–49	50–54	55–59	60–64	65–69	70–74	75–79	80–84	7
Women		3	9	12	26	37	25	17	2	
Men	1	1	5	15	19	29	20	15	2	
Total	1	4	14	27	45	66	45	32	4	

Numbers include data for both operations in patients operated bilaterally

Table 2 Previous operations

Intertrochanteric osteotomy	9
Osteosynthesis of hip fracture	7
Adductor tenotomy	4
Hemiarthroplasty	5
McKee-Farrar arthroplasty	2
Acetabuloplasty	1
Arthrodesis	1
Epiphyseodesis	1
Total	30

consisting of continuous infusion of 20 × 10^6 I U of penicillin/d for 3 days and penicillinase stable penicillin perorally for the following 11 days.

To evaluate the results, the patients were questioned and examined both preoperatively and at the follow-up examination according to the numerical rating described by Merle d Aubigne & Postel (19 modified by Charnley (1972).

X ray examination of the hips was performed in all patients who had an exceeding 30 mm/h or who felt any discom the hip but later in the greater part material all hips have been examined

To facilitate the assessment of walki material was divided according to Charnley into three categories A" denoting unila involvement and absence of other interfering with walking "B" bila involvement and C" presence of some other contributing to impaired walking In the series 38 patients belonged to category "A" category "B and 103 to category "C"

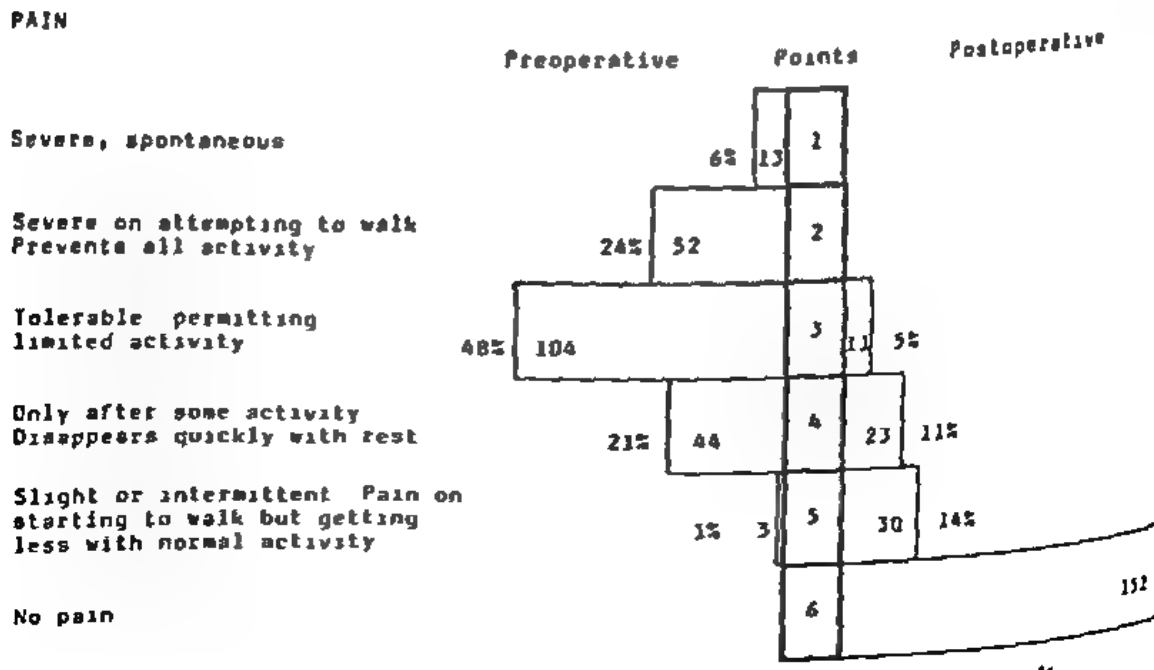

Figure 1 Numerical grading for pre and postoperative pain in 216 total hip replacements

Postoperative bleedings, wound haematomas and superficial wound ruptures have occurred after ten operations but have not led to other complications

In one hip which was earlier osteotomized and where a trochanteric osteotomy was done at the replacement operation, a purulent infection in the trochanteric region appeared after 2 years Simultaneously a septic arthritis developed in the knee joint Both infections probably were manifestations of hematogenous spreading from an infected wound in the foot After wound drainage, extraction of the trochanteric wires and antibiotic treatment, the infection healed At the follow-up examination, 3 5 years later, there were no signs of deep or superficial infection

Aseptic loosening of the femoral head prosthesis, necessitating reimplantation, has occurred in 16 hips. In the earliest implantations, Muller femoral prostheses were used, and after two of these procedures loosening recurred Reimplantation was then carried out with insertion of straight long-stem femoral prostheses. Among the other 14 reimplantations, there have been no other major local complications and no further case of repeated loosening Cystic erosions of the femoral cortex as described by Harris et al (1976) were seen in two of the hips with loosening of the femoral part At the reimplantations, there have been no other medullary cavities including the lytic areas were thoroughly curetted and multiple samples submitted for bacteriological and histological examination No evidence of infection was present, the patients are pain-free 1 year after the reimplantations and radiologically there are no signs of loosening or of recurrence of the erosions.

In all femoral prosthesis loosenings, the separation has taken place between metal and cement, whereas the cement has been firmly attached to the bone except in the most proximal part, where it is often fragmented Fractures of femoral prostheses have occurred twice, and in both cases the implants had loosened before fracturing

In addition to the reoperated hips, the X-ray examinations have revealed sinking of the femoral prosthesis exceeding 2 mm or a separation of the cement from the upper part of the stem exceeding 2 mm in 22 hips in which symptoms are absent or too slight to justify reoperation

No loosening of the acetabular component has been detected

DISCUSSION

The results in this series correspond well with those presented in earlier reports (Charnley 1970, Patterson & Selby-Brown 1972, Goldie 1977, Visuri et al 1977)

It should be noted that 14 hips with femoral prosthesis loosenings, all in grades 3 and 4 for pain at the follow-up examination (Figure 1), have later been successfully reoperated

The improvement with regard to range of motion (Figure 2) is less impressive than the effect on pain However, it is doubtful whether grade 6 should be regarded as a normal value for range of motion of the hip joint in these patients. Charnley (1972) states that the normal range of motion in a patient 60 years of age is "anything over a total of 260 degrees", but in the present material, with a mean age of 70 years at the time of the follow-up examination the range of motion in asymptomatic, non-operated hips exceeded 210 degrees, which is the lower limit for grade 6, in only 64 per cent of the hips

The superiority of total hip replacement over intertrochanteric osteotomy, which is in some patients an alternative method of surgical treatment for hip osteoarthritis, is mostly attributable to the restoration of hip motion which can be achieved by total replacement In this series, postoperative motion was 100 degrees or less in only 5 per cent of the hips, which can be compared with 55 5 per cent (Goldie et al 1973) and 44 per

cent (Olsson 1974) reported in follow-up studies after intertrochanteric osteotomies

The observations concerning the general physical capacity of the patients show that, generally speaking, total hip replacement does not allow the patient to return to work, but it greatly reduces his dependence upon other persons in activities of daily living

Deep infection is a serious threat to the success of arthroplasty with joint replacement and it is encouraging to find that the programme of antibiotic prophylaxis used in this series has proved to be effective, so that none of the operated hips has ended as an excision arthroplasty Benson & Hughes (1975) reported an infection incidence of 5 3 per cent in 321 hip arthroplasties, performed in general operating theatres, used by a variety of surgical specialties. As shown in several reports it is possible to reduce the frequency of deep infections to the magnitude of 1–2 per cent by prophylactic use of antibiotics (Carlsson et al 1977, Fitzgerald et al 1977, Visuri et al 1977) or by improved aseptic conditions in the operating-room environment (Charnley 1970, Brady et al 1975) A series of 252 total hip replacements, followed for 2 to 5 years, without any deep infections, has been presented by Collis & Steinhaus (1976), who stress the importance of strict operating-room discipline to limit contamination

Aseptic loosening of the prosthesis was reported in 4 8 per cent of 369 hip replacements of various types by Goldie (1977), in 2 1 per cent of 189 Brunswik hip replacements by Visuri et al (1977) and in 8 per cent of 1042 McKee-Farrar hip replacements by Dandy & Theodorou (1975) Marmor (1976) reported ten hips with varying stages of femoral loosening in a series of 160 Charnley hip replacements. In the present series, 16 of the total number of 238 hips (5 7 per cent) required reoperation for aseptic femoral prosthesis loosening In addition, 22 hips (9 2 per cent) show radiological signs of deteriorated femoral prosthesis fixation In these hips symptoms are absent or slight and in some of them pro a subsidence into a new, stable positio taken place, as described by Web Charnley (1975) On the other hand, a loosening may become increasingly fre after longer observation times demonstrated by Beckenbaugh & I (1978) who found evidence of fe component loosening in 4 5 per cent 1 after the operation and in 24 per cent af average follow-up time of 5 5 years in 2 replacements They also state that alt most of the patients with roentgenog evidence of loosening are asympto further breakdown of the fixation o femoral component may ultimately trouble

Varus position and insufficient i cement support of the proximal part femoral component have been pointed factors that may result in loosening (\ al 1975, Bocco et al 1977, Galante 1975) In our material, a preliminary the radiographs indicate that these facto responsible for the majority of fe component loosenings The curved da the Muller prosthesis stem facilitat insertion without osteotomy of the g trochanter but it makes valgus posit more difficult or even impossible especi femora with narrow medullary canals. it can be placed in valgus on the other there will be a loss of support at the femorale In the continued study of our including clinical and radiological exa tion after a minimum follow-up time years, special attention is being given further clinical and radiological cour arthroplasties with femoral comp loosening and the possible factors respo for this complication

REFERENCES

Beckenbaugh, R D & Ilstrup D M (19 3) hip arthroplasty A review of three hu and thirty three cases with long follow- *Bone Jt Surg* 60 A 306–313

rison, M K. D & Hughes, S P F (1975) Infection following total hip replacement in a general hospital without special orthopaedic facilities. *Acta orthop scand* **46**, 968–978

co, F, Langan, P & Charnley, J (1977) Changes in the calcar femoris in relation to cement technology in total hip replacement *Clin Orthop* **128**, 287–295

dy, L. P, Enneking, W F & Franco, J A (1975) The effect of operating-room environment on the infection rate after Charnley low-friction total hip replacement *J Bone Jt Surg* **57-A**, 80–83

rlsson, Å S, Lidgren, L. & Lindberg, L (1977) Prophylactic antibiotics against early and late deep infections after total hip replacements *Acta orthop scand* **48**, 405–410

arnley, J (1970) Total hip replacement by low-friction arthroplasty *Clin Orthop* **72**, 7–21

arnley, J (1972) The long-term results of low-friction arthroplasty of the hip performed as a primary intervention *J Bone Jt Surg* **54-B**, 61–76

ollis, D K & Steinhaus, K. (1976) Total hip replacement without deep infection in a standard operating room *J Bone Jt Surg* **58-A**, 446–450

andy, D J & Theodorou, B S (1975) The management of local complications of total hip replacement by the McKee-Farrar technique *J Bone Jt Surg* **57-B**, 30–35

itzgerald, R H, Nolan, D R, Ilstrup, D M., von Scoy, R. E, Washington, J A & Coventry, M B (1977) Deep wound sepsis following total hip arthroplasty *J Bone Jt Surg* **59-A**, 847–855

alante, J O, Rostoker, W & Doyle, J M (1975) Failed femoral stems in total hip prostheses. A report of six cases. *J Bone Jt Surg* **57-A**, 230–236

Goldie, I, Andersson, G B J & Olsson, S S (1973) Long-term follow-up of intertrochanteric osteotomy in osteoarthritis in the hip joint *Clin Orthop* **93**, 265–270

Goldie, I (1977) Complications in total replacement of the hip joint *Läkartidn* **74**, 419–426

Harris, W H, Schiller, A L, Scholler, J M, Freiberg, R A. & Scott, R (1976) Extensive localized bone resorption in the femur following total hip replacement *J Bone Jt Surg* **58-A**, 612–618

Marmor, L (1976) Femoral loosening in total hip replacement *Clin Orthop* **121**, 116–119

Merle d'Aubigné, R & Postel, M (1954) Functional results of hip arthroplasty with acrylic prosthesis. *J Bone Jt Surg* **36-A**, 451–475

Müller, M E (1970) Total hip prostheses. *Clin Orthop* **72**, 46–68

Nolan, D R, Fitzgerald, R. H, Beckenbaugh, R D & Coventry, M B (1975) Complications of total hip arthroplasty treated by reoperation *J Bone Jt Surg* **57-A**, 977–981

Olsson, S S (1974) Intertrochanteric osteotomy of the femur with AO-technique for osteoarthritis of the hip joint *Acta orthop scand* **45**, 914–925

Patterson, F P & Selby-Brown, C (1972) The McKee-Farrar total hip replacement Preliminary results and complications of 368 operations performed in five general hospitals. *J Bone Jt Surg* **54-A**, 257–275

Visuri, T, Salenius, P & Laurent, L. E (1977) Total hip replacement by the Brunswik prosthesis. A preliminary report of 189 operations *Acta orthop scand* **48**, 197–203

Weber, F A. & Charnley, J (1975) A radiological study of fractures of acrylic cement in relation to the stem of a femoral head prosthesis. *J Bone Jt Surg* **57-B**, 297–301

orrespondence to Sven S Olsson, M D Ortoped-kirurgiska klinken, Centrallasarettet, S-601 82 Norrkoping, Sweden.

orthop scand. 50 465–470, 1979

YCOSAMINOGLYCAN METABOLISM OF THE MEDIAL ENISCUS, THE MEDIAL COLLATERAL LIGAMENT AND THE P JOINT CAPSULE IN EXPERIMENTAL OSTEOARTHRITIS USED BY IMMOBILIZATION OF THE RABBIT KNEE

PIO VIDEMAN[1] ILKKA ERONEN[2], CLAES FRIMAN[3] & ANDERS LANGENSKIOLD[1]

titute of Occupational Health and the Research Laboratory of the Orthopaedic Hospital he Invalid Foundation, [2]Fourth Department of Medicine, University Central Hospital, partment of Orthopaedics and Traumatology, University Central Hospital, Helsinki Finland

A study was made of glycosaminoglycan metabolism in experimental osteoarthritis caused by immobilization of the rabbit knee in extension Samples from the medial meniscus the medial collateral ligament of the knee and the hip joint capsule were obtained and analysed after 2, 6, 10, 17, 30 and 87 days of immobilization samples from the mobile limb serving as controls

glycosaminoglycans. In both early and advanced immobilization osteoarthritis, the synthesis rate and the content of glycosaminoglycans were increased in all tissues

Key words glycosaminoglycans, immobilization, joint capsule, osteoarthritis

Accepted 30 m 78

ie aetiopathogenesis of osteoarthritis (OA) is clear Immobilization with or without com-ession has been successfully employed in the perimental production of degenerative joint anges similar to those of human OA (for view, see Moskowitz 1972) Muscle contrac-n causing a static compression of the icular cartilage probably contributes to the generative changes occurring in immobilized nts (Thaxter et al 1965, Videman & ichelsson 1977) Changes in the articular rtilage in human OA and in various ex-rimental OA models have been extensively idied (for reviews, see Mankin 1976 and Muir 77), but comparatively little is known about possible alterations of other articular or periarticular structures. Thickening of the joint capsule is a regular feature of human OA of the hip (Lloyd-Roberts 1953) OA induced by the immobilization of the rabbit knee in extension causes thickening of the knee and ipsilateral hip joint capsules, as well as increased uptake of ^{35}S-sulphate in these structures, in the menisci and in the medial collateral ligament (Videman et al. 1976) Immobilization of the rabbit knee in flexion for 9 weeks, on the other hand, causes joint contracture and a diminished content of water, hyaluronate and chondroitin –4/–6–sulphate of the periarticular connective tissues.

01–6470/79 040465–06$02.50/0

© 1979 Munksgaard, Copenhagen

but no change in total collagen content (Akeson et al 1973) The concentration of soluble collagen is reduced however and the degree of joint stiffness has been found to correlate with the loss of hexosamine from the periarticular connective tissues (Woo et al 1975) which also display an increase in $NaBH_4$ reducible cross links in collagen (Akeson et al 1977)

The purpose of the present study was to investigate further possible changes of glycosaminoglycan (GAG) metabolism in the medial meniscus, the medial collateral ligament and the hip joint capsule after various periods of immobilization of rabbit knees in extension

MATERIALS AND METHODS

The right knees of 18 rabbits older than 9 months were immobilized according to the method of Langenskiold et al. (1975). Two rabbits were after 2 5 10 and 30 days, six after 17

and the joint capsule (full thickness) of Tissues from the mobile left leg material The administration of ^{35}S-sulphate processing of the samples and the hexosamine uronic acid DPM/µg hexosamine, in another report (Eronen et al. 1978). Statistical significances were evaluated by Student's Differences were considered value was < 0 05

RESULTS

In the *meniscus* the tissue concentration of hexosamine ($P < 0.01$) and uronic

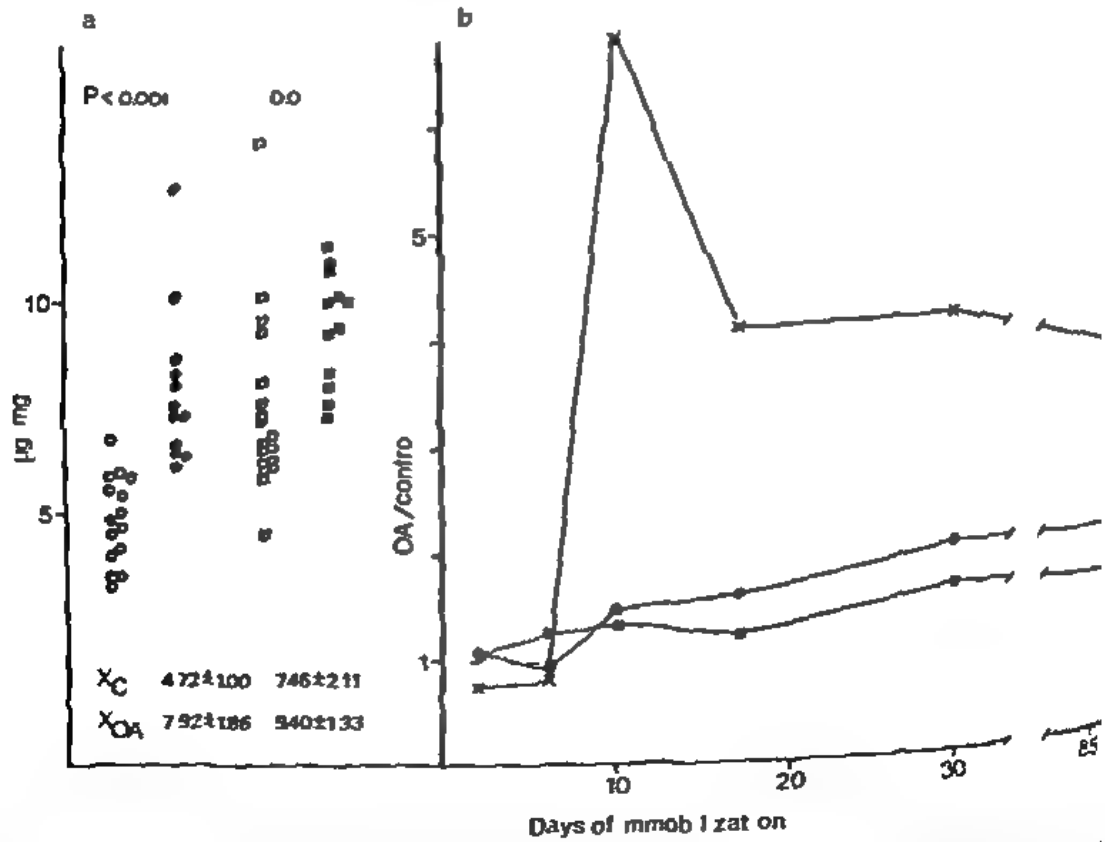

Figure 1 Medial meniscus (a) Tissue concentrations (µg/mg dry defatted tissue) of uronic acid (□ = control values ● osteoarthritis values) and of hexosamine (HA) (□ control values ■ = arthritis values) The mean values for the immobilized limbs have been calculated with the 2 10-day results excluded since the disease is not manifest after these short periods of immobilization Mean ratios of osteoarthritis (OA) control values of parameters measuring glycosaminoglycan metabolism as a function of immobilization time (● — uronic acid ■ hexosamine × specific activity)

0 001) were significantly higher in the ples from immobilized joints than in e from controls (Figure 1a) The mean entrations of hexosamine and uronic acid eased during the immobilization until reached their maximum levels at 30 s. The remained at this level until the day The average hexosamine and uronic l concentrations were approximately 150 200 per cent of the corresponding control es respectively After a small initial line specific ^{35}S-activity reached a ximum at 10 days of immobilization when evenfold elevation above the control level seen indicating greatly increased thesis of sulphated GAG A fourfold ation of ^{35}S-activity was discerned at 30 s and this elevation persisted until the end immobilization (87 days) (Figure 1b)

the *medial collateral ligament* of the e the tissue concentrations of both hexomine ($P<0\,001$) and uronic acid ($P<0\,001$) were markedly elevated as compared with the corresponding concentrations in controls (Figure 2a) The mean hexosamine and uronic acid concentrations increased with the immobilization time were maximal at 17 days and were still markedly above the control levels at 30 and 87 days of immobilization (Figure 2b) The mean ^{35}S activity in this tissue also reached a maximum at 10 days (a 17 fold increase above the control level) but it was reduced to a sixfold increase at 30 days and to a twofold increase at 87 days (Figure 2b)

In the *joint capsule of the hip* the changes in GAG metabolism resembled those found in the meniscus and the collateral ligament The tissue concentrations of hexosamine ($P<0\,001$) and uronic acid ($P<0\,001$) were significantly higher in samples from immobilized joints when compared with those of controls (Figure 3a) This increase was marked at 17 days of immobilization was

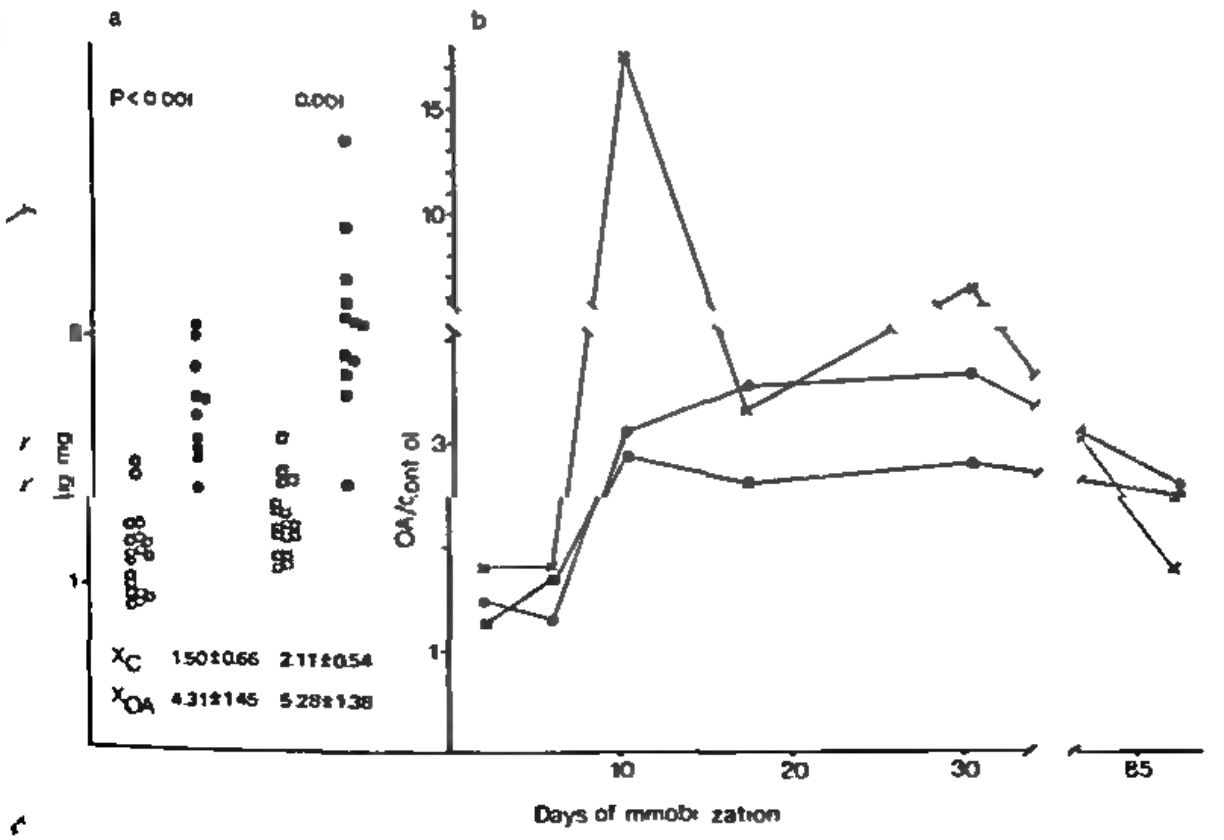

Figure 2 Medial collateral ligament of the knee (Explanation of symbols can be found in text to Figure 1)

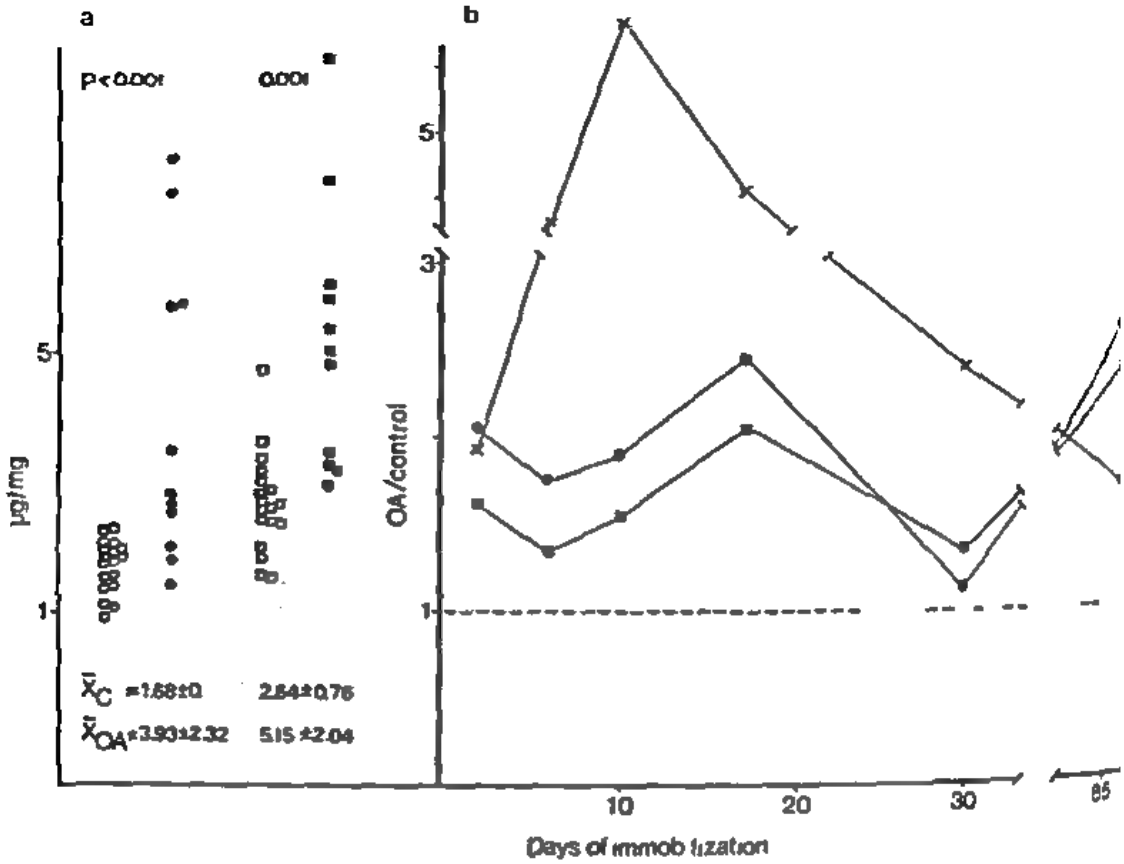

Figure 3 The joint capsule of the hip (Explanation of symbols can be found in text to Fig

only slight after 30 days and was again marked at 87 days (Figure 3b) The increase in mean ^{35}S-activity was again maximal at 10 days (almost a sevenfold increase above the control level), and it remained distinctly above the control level at 30 and 87 days.

The results can be summarized as follows In all the tissues studied immobilization caused an increased uptake of ^{35}S-sulphate, i e an increased synthesis rate of sulphated GAG, which led to elevated tissue concentrations of GAG that were discernible even after 87 days of immobilization

DISCUSSION

The present study and an earlier one (Eronen et al 1978) showed that immobilization of rabbit knees in extension causes an increased synthesis of sulphated GAG in articular cartilage, meniscus, collateral ligament and joint capsule (also hip) In hyaline ca and meniscus increased GAG synthes observed after 10 days whereas only 2 d immobilization sufficed to stimulate synthesis in the joint capsule and col ligament In non-weight bearing car meniscus, collateral ligament and capsule the GAG concentration rose synthesis occurred, but in weight-b cartilage GAG concentration fell results are in accordance with our studies using histological, roentgenol and autoradiographic methods (Videm al 1977)

It has been shown that immobilizati rabbit knees in flexion leads to a dimin concentration of GAG in menisci and articular connective tissues (Akeson 1973) The difference between these st present results may be due to the fact immobilization in flexion causes diffe oriented forces and stress in the

ctures than immobilization in extension our development work on the OA model, immobilized rabbit knees in flexion for 0 weeks, but only in a few cases was ographic and macroscopic evidence of t degeneration obtained, and immobilion in extension was thereafter employed human OA the total hexosamine content of enerative areas of menisci has been found increase (Ghosh et al 1975, Peters & illie 1972)

n human OA, fibrous thickening, oblastic proliferation and, occasionally, l cartilage metaplasia are characteristic tological changes of the hip joint capsule kolloff 1969, Lloyd-Roberts 1953) Similar inges are, to various degrees, observable in present immobilization OA model deman et al 1976) It is obvious that imbilization causes thickening and shortening the joint capsule, and these changes increase ssure on the cartilage and thus cartilage mage and other OA changes. Via this chanism capsular changes may have an portant role in the production of OA, and the nerally held view that capsular changes are condary could in many instances be inurate

CKNOWLEDGEMENTS

his study was supported by grants from the grid Juselius Foundation and the Juho Vainio undation We wish to express our gratitude to Institute of Occupational Health for their help

eson, W H, Amiel, D, Mechanic G L, Woo S L Y, Harwood, F L & Hamer M L (1977) Collagen cross linking alterations in joint contractures Changes in the reducible cross-linkings in periarticular connective tissue collagen after nine weeks of immobilization *Connective Tissue Research* 5, 15–19

keson, W H, Woo, S L Y Amiel D Coutts R D & Daniel D (1973) The connective tissue response to immobility Biochemical changes in periarticular connective tissue of the immobilized rabbit knee *Clin Orthop* 93, 356–362.

Eronen, I, Videman, T, Friman, C. & Michelsson, J-E (1978) Glycosaminoglycan metabolism in experimental osteoarthrosis caused by immobilization *Acta orthop scand* 49, 329–334

Ghosh, P, Ingman, A M & Taylor, T K F (1975) Variations in collagen, non-collagenous proteins and hexosamine in menisci derived from osteoarthritic and rheumatoid arthritic knee joints *J Rheumatol* 2, 100–107

Langenskiold, A, Michelsson, J-E Videman, T (1975) Osteoarthritis of the knee in the rabbit produced by immobilization. *Scand J Rheum*, Suppl 8, 7–8

Lloyd Roberts, G (1953) The role of capsular changes in osteoarthrosis of the hip joint *J Bone Jt Surg* 35-B, 627–642.

Mankin H J (1976) Biochemical changes in articular cartilage in osteoarthritis. *A.A S Symposium on Osteoarthritis*, pp 1–22. Mosby, St Louis.

Moskowitz R W (1972) Experimental models of degenerative joint disease *Sem Arthr Rheum* 1, 95–116

Muir, H (1977) Molecular approach to the understanding of osteoarthrosis (Heberden Oration, 1976) *Ann rheum Dis* 36, 199–208

Peters, T J Smillie, I S (1972) Studies on the chemical composition of the menisci of the knee joint with special reference to the horizontal cleavage lesion *Clin Orthop* 86, 245–252.

Sokoloff L. (1969) In *The biology of degenerative joint disease*, pp 5–20 The University of Chicago Press Chicago and London

Tharter, T H, Mann, R A Anderson, C E (1965) Degeneration of immobilized knee joints in rats. *J Bone Jt Surg* 47-A, 567–585

Videman, T & Michelsson, J-E (1977) Inhibition of development of experimental osteoarthritis [illegible]

A (1977) The [illegible] changes in experimental osteoarthritis provoked by immobilization of the knee in rabbits. *Int res comm Syst. Med. Sci* 5, 62.

Videman, T, Michelsson J-E., Rauhamäki, R Langenskiold, A (1976) Changes in ^{35}S-sulphate uptake in different tissues in the knee and hip regions of rabbits during immobilization, remobilization and the development of osteoarthritis. *Acta orthop scand* 47, 290–298

Woo, S L Y, Matthews, J V., Akeson, W H,

Amiel, D & Convery, F R (1975) Connective tissue response to immobility Correlative study of biomechanical and biochemical measurements of normal and rabbits' knees. *Arthr and Rheu* 257–264

Correspondence to Dr Tapio Videman, M.D, Institute of Occupational Health, Dept. of Phys Laajanuityntie 1, SF-01620 Vantaa 62, Finland

orthop scand 50, 471–479 1979

≈GNIFICANCE OF FREE DORSIFLEXION ' THE TOES IN WALKING

IN BOJSEN-MØLLER & LARRY LAMOREUX

ıtomy Department C, University of Copenhagen, Denmark and
ɔoratory of Biomechanics, University of California at Berkeley, USA

Dissection reveals that the ball of the foot contains a connective tissue framework with transverse, vertical, and sagittal fibers, all connecting the skin with the proximal phalanges of the toes. Dorsiflexion of the toes tightens the framework and thereby restricts passive movements of the skin, enabling shear forces to be transferred to the skeleton. An electromechanical oscillator was constructed that applied oscillatory shear forces of constant amplitude (±0 2 N) to the skin and at the same time measured the resulting motions. It was found that the toes should be dorsiflexed by 35–40° to restrict skin mobility to 50 per cent and by 50° to restrict it maximally The results were compared to actual dorsiflexions of toes during walking These dorsiflexions were measured on slow motion film and with still pictures with light tracks formed by light emitting

Key words biomechanics, foot, gait, ligaments, metatarsophalangeal joint, photography

Accepted 3 III.79

ıe ball of the foot consists of three ınsverse zones, each with a specific con- ctive tissue frame (Figures 1 and 2) 1) a stal zone mainly with transverse lamellae, 2) ı intermediate zone, in which vertical fibers rm a connective tissue cushion below each etatarsal head, and 3) a proximal zone in hich ten sagittal septa pass the deep fibers the plantar aponeurosis to the proximal ıalanges of the five toes (Henkel 1913, ojsen-Møller & Flagstad 1976) Fat lobules e enclosed between the elements of the amework, and the two tissues endow the all with softness and great internal strength. The lamellae, the cushions, the septa and ıe plantar aponeurosis are all attached to the skin as well as to the proximal phalanges. At each dorsiflexion of the toes the slack of the fibers is therefore taken up, causing the soft and pliable ball to be transformed into a firm pad that can resist tangential, or shear, forces. This happens twice during the stance phase at foot contact, where there is a stopping of the forward movement of the foot, and at push off, where the foot transmits a backward force against the ground (Napier 1957, Close et al. 1967) It is the purpose of the present paper to describe and illustrate the dorsiflexion of the toes and its functional significance in walking, including how tangential forces are intercepted and how shoes can affect the function.

001-6470/79/040471-09$02.50/0

© 1979 Munksgaard Copenhagen



Figure 1 Sagittal section through the second interosseous space of a left foot Fat is removed to show the connective tissue framework of the ball of the foot The metatarsal bone, the proximal phalanx and the plantar ligament (pl) are outlined The ball consists of 1) a distal zone with 4–5 transverse lamellae and the insertion in the skin of the plantar aponeurosis (pa), 2) an intermediate zone in which vertical fibers (vf) form a cushion below the metatarsal head, and 3) a proximal zone in which retinacula cutis (rc) and the deep fibers of the plantar aponeurosis are connected through sagittal septa (ss) to the plantar ligament The fibers of all three zones are ultimately attached to the proximal phalanx and become tensed when the phalanx is dorsiflexed

Figure 3 Stance phase of right foot M aspect Light emitting diodes placed at the great toe (A), at the metatarsophala (B), below the medial malleolus (C) medial side of the shank (D) form

ms The shock absorbing calcaneogra lasted 100 ms From time 100 ■ time 54 has rested with its sole on the ground shank has rolled forward and reached an tion of approx 20° During the digitigrade phase of the push off (from

stretched gradually

Duration and range of the dorsiflexion

Two gait cycles for each of 21 students with normal feet were filmed at 200 frames per second using a 16 mm ciné camera placed at ground level A few cycles were also filmed at 400 frames per second The students walked barefooted with cadences and lengths of approximately 100 steps minute and 65 cm, respectively The film analyzed frame by frame and the dur and range of the dorsiflexion of the toes measured

The events were further studied by ■ of still pictures with interrupted light ■ formed by light emitting diodes fixed to foot and leg at four different sites (Figure The diodes were placed at the tip of the toe, at the metatarsophalangeal joint on heel below the medial malleolus and on middle of the shank The diodes flashed a frequency of 50 Hz giving a 20 periodicity on the pictures. A strobe showed the position of the foot ■ every

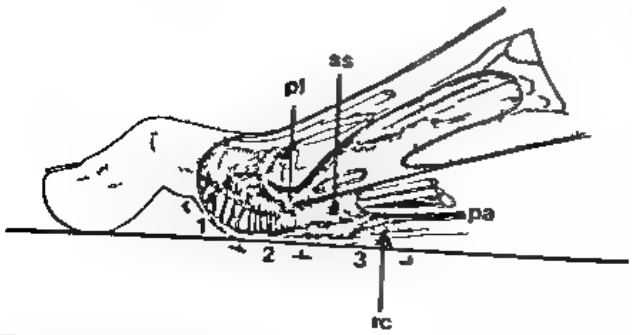

Figure 2 Diagram showing the connective tissue framework of the three zones of the ball of the foot Abbreviations as in Figure 1

< 1 Duration of and joint movements in the four phases of the stance phase for twelve push offs analyzed with light emitting diodes as shown in Figure 3

	range	mean	1 st dev	% of total
meograde ms	60–100	87	15 6	10 3
igrade ms	320–440	375	33 2	44 4
igrade e ms	200–320	267	37 5	31 6
ligrade e ms	100–140	116	14 4	13 7
ms	760–900	844	38 0	100 0
imal atarsophalangeal siflexion at strike	20°–30°	25°	3 0°	
tal delay at strike ms	40–120	110	74 6	13 0
al inclination eel rise	10°–25°	21°	4 2°	
imal tatarsophalangeal siflexion during h off	50°–60°	58°	3 4°	

ih of the diodes, enabling the light periods all four tracks to be identified and mbered consecutively from heel strike to off Twelve stance phases of the same foot lking with approximately the same speed re analyzed with this technique (Table 1).

During midswing the toes were slightly rsiflexed to clear the ground At heel strike great toe was dorsiflexed 20–30° and ched the ground 40–120 ms later than the ball, which itself touched down 60–100 ms after heel strike Toe contact was established either by all five toes at the same time or by the first and fifth toes together with the ball, followed by a delayed contact of the second, third and fourth toes.

During the following plantigrade phase in which full contact was maintained with the ground, the leg rolled forward on the foot and reached a forward inclination of 20–25° The

plantigrade phase lasted on average 375 ms or 45 per cent of the total stance phase After that period the push off started with rising of the heel Using terms from comparative anatomy the push off could be divided into a digitigrade and an unguligrade phase each lasting 32 per cent and 14 per cent of the stance phase, respectively In the former phase the toes rested on the ground while the heel circled 60° about an axis at the metatarsophalangeal joints (Figure 4 axis B) The latter phase started with a sudden displacement of the axis to the tip of the great toe, and while the toe and the metatarsophalangeal joint circled 90° about this distal point (Figure 4 axis A), the relative dorsiflexion of the toes was undone, allowing the hindfoot to follow a more gently curved or straighter path At the conclusion of the unguligrade phase only the tip of the great toe and its nail had contact with the ground, and the foot was straight and formed an angle of approximately 90° with its position at the beginning of the push off Finally, the foot continued forward and slightly upward with a translatory movement into a new swing phase

Heel rising is initiated when the shank has a forward inclination of 8–25° (Table 1) (Wright et al 1964, Close et al 1967, Lamoreux 1971) This is well before the joint has reached its maximum possible dorsiflexion and is therefore caused by tension built up in the triceps muscle and not by tension in the capsule or the ligaments For the same reason it is tension built up in the flexor hallucis longus which causes the elevation of the ball of the foot after a submaximal dorsiflexion of the toes in the digitigrade phase

Effects of free dorsiflexion on the mechanics of the foot

Compared to a rigid lever, the foot with its intermediate break at the metatarsophalangeal level has several advantages for smooth accomplishment of the vertical and horizontal accelerations that are necessa initiation of the swing phase of walking

a) In the first interval where the acc tion is mainly antigravitational arm of the foot is diminished by nearly 3 cent as the distance from the ankle metatarsophalangeal joint relates to length of the lever (ankle to tip of gre as 5 7 (Figure 4, CB CA = 5 7)

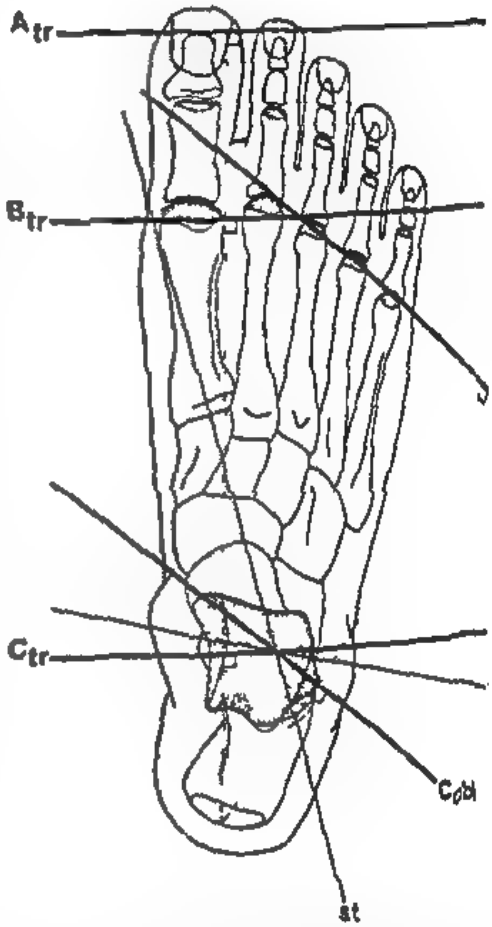

Figure 4 Diagram of right foot showing location of the axes During push off the mechanical axes of the ankle joint complex (tc st) combine into axes (C_{tr} and C_{obl}) which parallel in the horizontal plane with the pr axes (B_{tr} and B_{obl}) at the metatarsophala level The push off can thus be performed ab set of transverse axes or a set of oblique With the transverse axes the foot is a lever with C_t B_r as the resistance arm in the phase of the push off and C_{tr} A_{tr} as the resis arm in the final phase (compare with Figure With the oblique axes the resistance arm C_{ob} is shorter and there is no advanced axis tc mechanical axis of the talocrural joint. st mechanical axis of the subtalar joint.

-nands upon triceps surae are thereby ..uced

The fact that the resistance arm of the foot ...reases as the horizontal speed of the foot ...reases allows the triceps to provide useful ...es over a longer period of time, thereby ...ucing the peak forces required to achieve ...necessary horizontal speed at toe-off

) The flexor hallucis longus is stretched, l therefore reaches a higher tension for its ...k, which is to force the great toe back to eutral position and deliver the final thrust.

n the human foot the second metatarsal ...e is characteristically the longest one ood Jones 1944) As a consequence two ferent axes exist at the metatarso-alangeal level one passing transversely ough the heads of the first and second tatarsal bones and the other obliquely ough the heads of the second to the fifth tatarsal bones (Figure 4) The two axes n be used for different mechanical purposes their distances to the ankle joint complex, d thus the resistance arms of the foot, are ferent In a previous work (Bojsen-Møller 78) it was thus found that the resistance m of the foot is 20 per cent longer in the itigrade phase when the push off is rformed about the transverse axis than hen it is performed about the oblique With transverse axis the leverage is further epped up with the final advancement of the as to the tip of the strong first toe, while ith the oblique axis the push off continues ore as a roll over the ball of the foot with e lateral toes yielding dorsally, unable to stablish an unguligrade phase of their own

The two metatarsophalangeal axes with ...ir long and short resistance arms can be sed for different mechanical demands such ...s fast level walking and uphill walking, spectively They can further be used to djust the direction of the propulsion in ccordance with the requirement for balance nd the requirements of an uneven ground ree mobility of the five metatarsophalangeal ints is, however, a prerequisite for the refoot to exploit these options.

Effect on arch support

The plantar side of the joint capsule of each metatarsophalangeal joint is reinforced by a *plantar ligament*, which is attached to a prominent facet on the base of the proximal phalanx, while it is connected to the metatarsal bone by a synovial fold only The five plantar ligaments continue across the foot as the deep transverse metatarsal ligament and proximally into the fascia covering the adductor hallucis and the interossei The plantar aponeurosis is connected by its deep fibers in the ten septa to the plantar ligaments and thus to the proximal phalanges (Figures 1 and 7)

Hicks (1954) pointed out that the plantar aponeurosis acts as a tie for the longitudinal arch of the foot In normal standing position and in the phase where the foot has full contact with the ground, the aponeurosis is slack and unable to support the arch When the toes are dorsiflexed, however, a pull is exerted on the plantar aponeurosis by a "windlass action" where the head of the metatarsal bone acts as the drum The mechanism springs into action as soon as the heel leaves the ground, and the stress on the arch becomes augmented (Figure 7)

Transfer of shear forces from the skin to the skeleton

Relaxed, the ball of the foot is a soft and pliable pad The plantar skin can be moved from side-to-side and proximo-distally Dorsiflexion of the toes changes this situation, the ball becomes tense, firm and pale, and mobility of the skin becomes greatly reduced This stiffening ensures that shear forces resulting from accelerations, decelerations or twists are not carried by the skin alone, but are conveniently taken up by the underlying connective tissue frame and transferred to the skeleton

To permit objective measurement of the rigidity of attachment of plantar skin, an electromechanical oscillator, or vibrator, was constructed that applied oscillatory shear

forces to the skin and measured the amount of skin motion that resulted The shear forces were of constant sinusoidal amplitude and were applied at a relatively high frequency (40 Hz) to allow the mass of the foot itself to minimize skeletal movement, thereby eliminating the necessity for rigid fixation of the foot to an external reference structure The rigidity of the skin over the underlying structures was characterized by the peak-to-peak magnitude of skin motion caused by the constant-amplitude shear forces Forces were applied to the skin by the end of a lightweight tubular aluminium arm, 50 mm long and 8 mm in diameter This arm was rigidly mounted at a right angle to the shaft of an oscillatory torque motor (MFE Model T4–150A) capable of generating torques up to ± 0 075 Nm over a range of ± 15° In use, the peak force at the tip of the arm was arbitrarily set to ± 0 2 N, which caused skin movement of ± 5 mm or less, corresponding to maximum torque motor rotations of ± 6° Motion of the shaft is sensed by a rotary variable differential transformer (Shaevitz Model R30D) The electrical output is calibrated in terms of displacement of the tip of the arm, in mm

The free end of the vibrator arm was attached to the skin by double-sided adhesive tape, and measurements were made on 27 students with normal feet at four s points 1) in the intermediate zone of th of the foot between the first and the metatarsophalangeal joint 2) at the metatarsophalangeal joint, 3) at the of the deep fibers of the plantar and 4) over the central compartment sole (Figure 8) Measurements each 10° of dorsiflexion of the toes a accordance with the two kinds of pos for dorsiflexion of the first and second (transverse axis) and for the second t fifth toes (oblique axis)

The results are shown in Table Figure 9 It was found that the restrict the skin movements is more influenc dorsiflexion of the first and second toes by dorsiflexion of the second to the fifth except over the lateral part of the ball (s It was further found that a relatively dorsiflexion (35–40°) was needed to 50 per cent restriction of the amplitude. means that a moderate restriction o freedom of the toes, imposed by a shoe hinder the tightening of the connective framework and thus the normal trans shear forces. It was finally found that the of the lateral part of the ball was the movable This is paralleled in the hand the skin was found less movable ove ulnar part of the palm than over the

Table 2 Skin displacement in mm at the four locations shown in Figure 8 For each site are show 27 persons a mean value together with one standard deviation for dorsiflexion through 50° of th and second and of the second to the fifth toe, respectively

Site no		Dorsiflexion of the toes 0°	10°	20°	30°	40°	
1	1st–2nd toe	1 87 (0 58)	1 66 (0 63)	1 45 (0 70)	1 19 (0 64)	0 90 (0 52)	0 8 (
	2nd–5th toe	1 88 (0 57)	1 73 (0 66)	1 56 (0 66)	1 26 (0 63)	1 00 (0 53)	0.83 (
2.	1st–2nd toe	1 46 (0 49)	1 31 (0 49)	1 11 (0 47)	0 97 (0 44)	0 83 (0 40)	0.89 (
	2nd–5th toe	1 43 (0 51)	1 16 (0 48)	0 96 (0 47)	0 79 (0 39)	0 61 (0 30)	0 53 (
3	1st–2nd toe	2 81 (1 00)	2 49 (1 05)	2 12 (1 11)	1 63 (1 04)	1 3 (0.90)	0.99 (
	2nd–5th toe	2 88 (1 00)	2 47 (1 04)	2 1 (1 01)	1 75 (0 93)	1 37 (0 85)	1 97 (
4	1st–2nd toe	3 27 (0 97)	3 01 (1 11)	2.64 (1 12)	2 24 (1 07)	1 78 (0 95)	1.25 (
	2nd–5th toe	3 46 (0 98)	3 15 (1 06)	2 86 (1 09)	2 42 (1 01)	2.16 (1 01)	2.04 (

.sen-Møller [illegible] Lamoreux, unpublished [illegible]) Individual differences in skin mobility [illegible] e pronounced, as can be seen from the [illegible]

.t the time the ball made contact with the und and became involved in the decelera- ı of the foot, the proximal phalanges were siflexed 25–30° (Table 1) At that instant, refore, the skin mobility at site 3 of an rage foot would have reached half of its ximally obtainable restriction During push the toes became dorsiflexed through -60° Maximal restriction of the skin bility at sites 1 and 2, which in this phase re the ground contact, is reached already at 50° dorsiflexion The skin and its un- lying connective tissue framework are thus ll adapted to take up the shear forces of final rapid acceleration

It should finally be noted that the direction the collagenous fibers in the different zones the ball are in keeping with the direction of forces they shall intercept (Figures 1 and At push off the skin of the ball will tend to de anteriorly, but is prevented from doing by the superficial fibers of the plantar oneurosis, which insert in the distal zone id thereby are able to transmit the forces to e calcaneus At braking, it is the proximal ne which has the ground contact, and the osterior pull is intercepted by anteriorly oping fibers which proceed from the tinacula cutis through the sagittal septa to e proximal phalanges.

ffects of shoes

Using the light-track technique, two shoes of ifferent stiffness were tested on the same oot performing push-offs about the ansverse axes.

In Figure 5 a shoe (Trimsko[2]) with a soft pper and soft rubber sole is shown In the ecelerative phase of the heel strike the great oe is dorsiflexed 12° In the digitigrade hase of the push off the heel point C circles

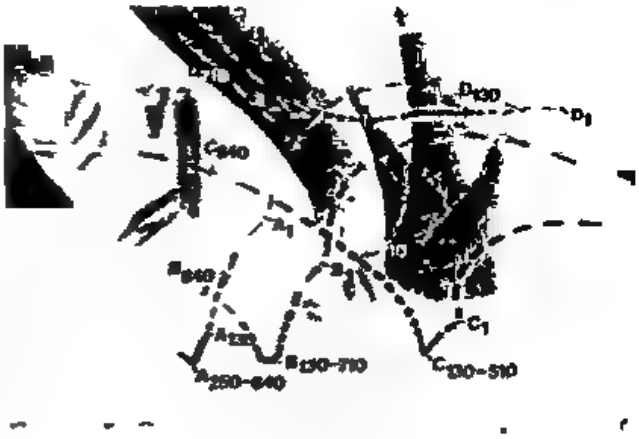

During push off the heel point C has circled around the metatarsophalangeal point B for 200 ms (C_{510} C_{710}) and the toes have reached a dorsiflexion of 45–50° The axis has then been advanced to A allowing C to follow a straighter path and the resistance arm of the foot to increase its length

for 200 ms about the metatarsophalangeal axis while the great toe reaches a maximal dorsiflexion of 45–50° The axis is then transferred to the tip of the great toe and the dorsiflexion is undone with a gradual increase of the resistance arm of the foot as a consequence This shoe imposes hardly any restrictions on the performance of the foot

The sole of a minus heel shoe is

Figure 6 Stance phase of a minus heel shoe

SECOND MEETING OF THE EUROPEAN SOCIETY OF BIOMECHANICS

AND

FIRST SYMPOSIUM OF THE G.E.B.O.A.S.

(Groupe d'Etudes de Biomécanique Ostéo-Articulaire de Strasbourg)

SEPTEMBER 13–15, 1979 STRASBOURG FRA

Aims of the meeting

The purpose of the meeting is to bring together clinicians, engineers, scientists and manufactu who are interested in the interdisciplinary field of Biomechanics

Place

The meeting will be held in Strasbourg, in the Anatomy Amphitheatre of the "Hospices Civ

Preliminary program

— Bone and cartilage biomechanics
— Biomechanical aspects of bone healing
— Osteosyntheses biomechanics
— Different orthopaedic devices and materials
— Cardiovascular biomechanics
— Electric and magnetic stimulation of bone repair
— Joint biomechanics, normal and pathologic joints, prostheses and fixations

Registration fees

Members	**: 300FF**
Non-Members	**: 400FF**
Residents, Students	**: 200FF**
Exhibitions	**: 1000FF/m²**

Official language English

Further information

D Muster
Service de Chirurgie Maxillo-Faciale
Hospices Civils
67000 Strasbourg, France

RANSPLANTABLE OSTEOSARCOMA IN MICE

ructural Characterization of a Transplantable Osteosarcoma ɔtained in an Allogenic System

'EN ERIK LARSSON RONNY LORENTZON
IK LUNDGREN & LENNART BOQUIST

partments of Orthopaedic Surgery and Pathology University of Umeå Umeå Sweden

Light microscopic histochemical and ultrastructural studies of a transplantable mouse osteosarcoma were carried out. The osteosarcoma grew in CBA mice after injection of cultured cells derived from a Dunn osteosarcoma. The tumour differed from the original Dunn osteosarcoma with respect to metastatic potential and structural features

The transplantable tumour was an anaplastic richly vascularized, fibroblastic osteosarcoma with alkaline phosphatase activity and rather sparse osteoid formation resulting in death of the animals within 6 to 8 weeks. Virus particles were found intracellularly mainly localized to cisterns of rough endoplasmic reticulum and extracellularly often close to plasma membranes and collagen fibres. Signs suggestive of formation of collagen fibres by tumour cells were observed A possible viral influence upon the tumour was suggested also by its growth behaviour *in vitro*

The results indicate that this new transplantable tumour obtained in an allogenic system represents a clonal derivative of the original Dunn osteosarcoma

Key words bone neoplasm electron miscroscopy morphology osteosarcoma transplantable virus particles.

Accepted 8 11 79

The poor results obtained with surgery or radiation therapy for osteosarcomas, in particular those located proximal to the knee and elbow joints (cf Larsson et al 1978a) have focused attention upon the newer therapies such as chemotherapy and immunotherapy Regression of human osteosarcoma has been described after adaptive and active immunotherapy (Marcove et al 1971, Marsh et al. 1972) and the presence of tumour-specific antigens, capable of evoking both humoral (Lewis et al 1969, Hellstrom & Hellstrom 1973) and cell mediated antibody responses (cf Hellstrom et al 1971, Kumar et al 1972) has been demonstrated in osteosarcoma

The present study describes a transplantable murine osteosarcoma obtained after injections of cultivated tumour cells originating from the Dunn osteosarcoma*

Supported by grants from the Swedish Cancer Society (No 711–B–77–05XC) and Lions Research Foundation, Department of Oncology Umeå, Sweden.

*Obtained through the courtesy of Dr Miriam P Finkel, Argonne National Laboratory Argonne Illinois.

001 6470/79/050481 09$02.50 0

© 1979 Munksgaard, Copenhagen

While osteosarcoma rarely arises spontaneously in laboratory animals, the Dunn osteosarcoma is routinely transplantable both to C_3H and CBA mice and the pleomorphic, osteoid-producing tumour causes death of the host within [illegible] to 8 weeks after implantation (cf Miller et al 1976) Our transplantable osteosarcoma obtained in an allogenic system was readily transplantable and resulted in death of the animals by continuous local growth The purpose of the present study was to characterize the transplanted tumour light microscopically and ultrastructurally Subsequent studies will deal with the anti tumoral effects evoked by immunotherapy with BCG and with injected killed tumour cells

MATERIAL AND METHODS

Cell culture

The osteosarcoma cells were obtained as a cell line growing in monolayer The cells were growing in 90 mm Nunclon plastic dishes (Nunc, Roskilde Denmark) The medium used was Eagle's minimum essential medium (MEM) supplemented with antibiotics and 10 per cent foetal calf serum The cultures were incubated in humidified air with 5 per cent CO_2 at 37°C The cells were split in a 1 4 ratio every third or fourth day by trypsinization

Cell number was estimated in an electronic cell counter (Linson Counter 411 Lonsom Instrument Stockholm Sweden) Cell viability was approximated by the trypan blue dye exclusion test Mycoplasma could not be detected by standard culture methods

Animals and single-cell injections

A total of 185 CBA mice*, 10 to 15 weeks old of both sexes were used Their body weight was 20 to 30 g They were housed 5 or 10 in one cage and were kept on a standard laboratory ration** which together with drinking water, was supplied without restriction.

Monocellular suspensions of cultivated cells were prepared by trypsinization Approximately 2 × 10^6 viable tumour cells in 0 5 ml of serum free MEM were injected subcutaneously into the flank of 150 of the animals. After 8 weeks, when none of the animals had presented a growing [illegible] nor any tumour showing spontaneous regression a second subcutaneous injection of 2 × 10 [illegible] tumour cells was given in each animal All [illegible] were examined once a week for the occurrence tumour

After 6 months, a rapidly growing tumour occurred in one animal at the site of the injection while none of the others showed any ev[illegible] tumour Thirty five of the latter non[illegible]

[illegible]

tumour occurrence

Transplantation of standardized sections

The tumour bearing animal was killed 6 w[illegible] after the appearance of the tumour which had then reached a considerable size There were metastases to the lungs or elsewhere The [illegible] tumour, which possessed some areas of bleed[illegible] was dissected free under sterile condi[illegible] Standardized rounded sections with a diameter 3 0 mm and a thickness of 2 0 mm were randomly from the tumour with a special [illegible] equipped with two scalpel blades mou[illegible] parallel and one trepane The wet weights of sections showed a mean of 0015 g w[illegible] coefficient of variation of 9 5 per cent.

The sections were transplanted subcutaneo[illegible] to the dorsum of 35 animals which had been [illegible] injections of monocellular suspensions 6 mo[illegible] earlier, and to 35 intact control mice. [illegible] operations were performed under sterile c[illegible] ditions and light ether anaesthesia. Each [illegible] received two standardized tumour sections [illegible] 0 03 g of tumour tissue and were then left [illegible] planned observation period of 6 months du[illegible] which they were examined individually on[illegible] week with regard to growth or regression of [illegible] tumour which could easily be felt below the sk[illegible]

Animals exhibiting growing tumours w[illegible] sacrificed when the tumour had reached a c[illegible] siderable size that would have killed the a[illegible] within another 1 or 2 weeks. After careful dis[illegible] tion the tumour was completely removed and [illegible] wet weight recorded Specimens were then [illegible] for light and electron microscopic stu[illegible] Thorough autopsy examinations were [illegible] and tissue suspected to contain metastases removed for microscopic study

In a comparative study on 15 separate mice [illegible] incidence of growing tumour was studied [illegible] transplantation of [illegible] 06 g of tumour tissue.

*Obtained from Karolinska Institutet Stockholm Sweden

**Obtained from Ewos Co, Sodertalje Sweden

t microscopy and histochemistry

ecimens for light microscopy were fixed in [illegible] cent neutral formalin and paraffin-embed- sections were stained with haematoxylin and ı, van Gieson's stain, periodic acid Schiff S), and Laidlaw's silver stain.

istochemical demonstration of alkaline phatase was carried out on fresh frozen ons using the method described by [illegible]arka & ɛrson (1963)

tron microscopy

he specimens taken for ultrastructural study : fixed in 2 5 per cent glutaraldehyde in 0 34 Veronal acetate buffer adjusted to pH 7 4 wed by postfixation in 1 per cent osmium ɔxide in the same buffer Embedding was ıed out in Epon 812 Thick sections stained ı toluidine-blue were used for identification of ıble areas for the thin sections which were ıed with uranyl acetate and lead citrate prior xamination in a Siemens Elmiskop 1 A or 101

SULTS

insplantation of standardized tumour ·tons

reported above, injection of Dunn os- sarcoma cells derived from *in vitro* culture ,sed a growing tumour in only one out of) of our CBA mice This tumour occurred t after [illegible] months of observation

:n contrast, transplantation of standardized tions constituting 0 03 g of this particular nour gave rise to growing tumours in 28 : of 35 animals, ı e 80 per cent The nours grew rapidly and we had to kill all nour-bearing animals 6 to [illegible] weeks after nsplantation, otherwise the animals would have died because of extensive local tumour growth The other seven animals showed initial spontaneous disappearance of their tumour

Transplantation of 0 06 of tumour tissue gave rise to growing tumour in all the animals, ı e. in 100 per cent.

Out of the 35 animals receiving transplanted tumour sections 6 months after the cultured cell injection there were five which developed growing tumours, ı e. 14 per cent No evidence of tumour whatsoever was found at repeated examinations throughout the observation period of [illegible] months in the remaining 30 animals. The tumours thus showed spontaneous disappearance without any evidence of initial tumour growth

Three of the mice with tumours in this group were killed 7 weeks after transplantation At this time the tumours were considerably smaller than those observed at the same time after transplantation in the control animals. The other two tumour-bearing mice in the cell-injected group were killed 13 weeks after transplantation At this time the tumour size was comparable to that observed in the control mice 6 to 8 weeks after transplantation

Autopsy findings

Immediately after sacrifice, the tumours were dissected free and removed *in toto* The wet weights of the tumours, tumour growth period, and tumour incidence are shown in Table 1

The tumours had a smooth outer surface

ıble 1 Some data regarding the growth of transplantable osteosarcomas in cell injected and control animals

roups of ımals	Incidence (per cent)	Tumour growth period (weeks)	Tumour wet weight (mean ± s.d. grams)
:ll injected	14	7–13	2.17±2.53
ɔntrol	80	6–8	4 33+2.69

The cut sections were solid with rather sharply demarcated areas of bleeding There was no evidence of bone formation macroscopically Metastases to lungs or elsewhere were not found in any of the animals from any of the groups

Light microscopy and histochemistry

All growing, transplanted tumours, whether from the controls or the cell-injected mice, were essentially similar both as to light and electron microscopic features and alkaline phosphatase activity Therefore no differentiation will be made in the description below between the two groups of mice

The light microscopic studies disclosed solid tumours rich in cells which usually were closely packed, occasionally in a parallel and whorled arrangement Fibroblast-like cells predominated They were more or less spindle shaped and possessed a moderate amount of cytoplasm with slight or moderate staining affinity The cell boundaries were rather indistinct Most nuclei were oval or rounded (Figure 1), and contained one, two or more, moderately large, distinct nucleoli The chromatin was finely dispersed and the nuclear membranes rather distinct Other fibroblast-like cells possessed more or less elongated nuclei with coarse chromatin pattern and rather indistinct nucleoli (Figure 2)

Osteoblast-like cells could be seen in some portions of the tumours. These cells were more sparsely represented than the fibroblast-like cells. They were often irregularly shaped and possessed rounded, oval or irregular nuclei with moderately coarse chromatin pattern and one or more moderately distinct nucleoli The nuclear membranes were easily discerned A moderate amount of light staining cytoplasm was observed The cell membranes were indistinct

Mitotic figures typical and atypical were found both among the fibroblast-like and osteoblast-like cells, often in great numbers (Figure 3) No bone or cartilage was identified in the tumours.

Figure 1 Photomicrograph of mouse osteosarc of fibroblastic type showing fibroblast like with rather large, rounded or oval nuclei moderately distinct nucleoli and mitotic fi (arrows) (Haematoxylin & eosin, × 500).

Figure 2 Mouse osteosarcoma demonstr fibroblast-like cells with elongated nuclei pos ing moderate chromatin density (Haematox eosin, × 500)



ure 3 Area of mouse osteosarcoma monstrating at least 12 mitotic figures (Haema yl n & eosin × 500)

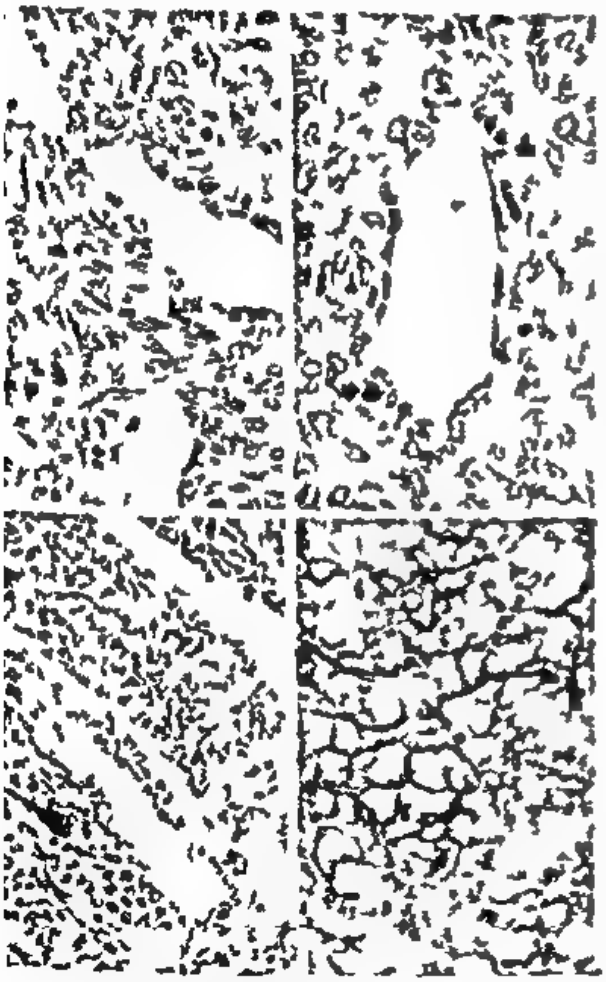

gure 4 Rather wide blood spaces in mouse os eosarcoma (Haematoxylin & eosin × 380)

igure 5 Blood space in mouse osteosarcoma lined y endothelial like cells Erythrocytes are seen in he lumen Mitotic f gures are also demonstrated arrow) (Haematoxyl n & eosin × 460)

igure 6 Mouse osteosarcoma inf ltrating among keletal muscle f b es (Haematoxyl n & eosin 270)

igure 7 Alkal ne phosphatase activity in mouse steosarcoma (× 450

In general the polymorphism varied somewhat in different parts of the tumours. Most areas showed a moderate or high degree of polymorphism Some portions of the tumours showed rich vascularization with the occurrence of widely anastomosing blood spaces containing erythrocytes (Figure 4) These blood spaces were mainly observed in areas with osteoblast like cells. The vascular spaces were lined by more or less distinct endothelial cells (Figure 5) Areas of bleeding and necrosis could be observed in some parts of the tumours. The peripheral areas of the tumours occasionally exhibited a fibrous tissue capsule Tumour infiltration was seen in parts of this capsule Growth of tumour was also observed in adipose tissue and skeletal muscles (Figure 6)

Histochemistry disclosed unambiguous alkaline phosphatase activity in the tumours (Figure 7)

Electron microscopy

The findings made under the light microscope were verified ultrastructurally Thus, there was a predominance of elongated fibroblast like cells with rounded or elongated nuclei and a varying chromatin density and nucleolar size The cytoplasm was moderately or sparsely developed and exhibited a moderate electron density numerous free ribosomes and a rather prominent rough surfaced endoplasmic reticulum The cisterns of endoplasm c reticulum were either electron lucent or contained slightly electron dense flocculent material The Golgi complex was rather inconspicuous. The mitochondria were medium sized and elongated or rounded and showed distinct membranes and a moderate matriceal density The cell membranes were irregular

The osteoblast like cells possessed rounded oval or irregular nuclei with moderate chromatin density and nucleoli of varying size A prominent rough surfaced endoplasmic reticulum was observed Amorphous masses of low dens ty were seen in most cisterns of endoplasmic reticulum

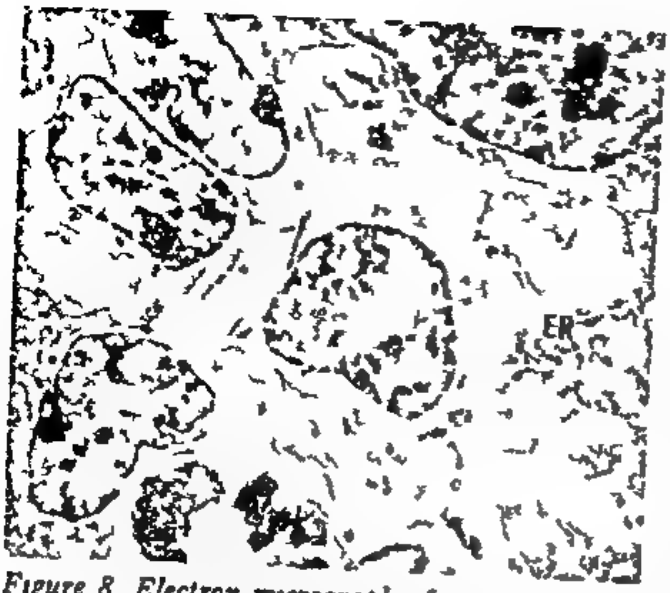

Figure 8 Electron micrograph of mouse osteosarcoma showing solid tumour tissue with one mitotic figure Prominent whorled endoplasmic reticulum is seen in one of the tumour cells (ER) (× 3 000)



Figure 11 Extracellularly localized collagen fibres (C) at some places seemingly associated with osteoblast like cells (c) Virus particles are seen among the collagen fibres (arrows) and intracellularly in the cisterns of endoplasmic reticulum (× 8 000)



Figure 9 Thin fibrils in cytoplasm of osteoblast like cell Virus particles are seen in cisterns of endoplasmic reticulum (× 20 000)



Figure 12 Higher magnification of collagen fibres at periphery of osteoblast like cell (× 38 000)

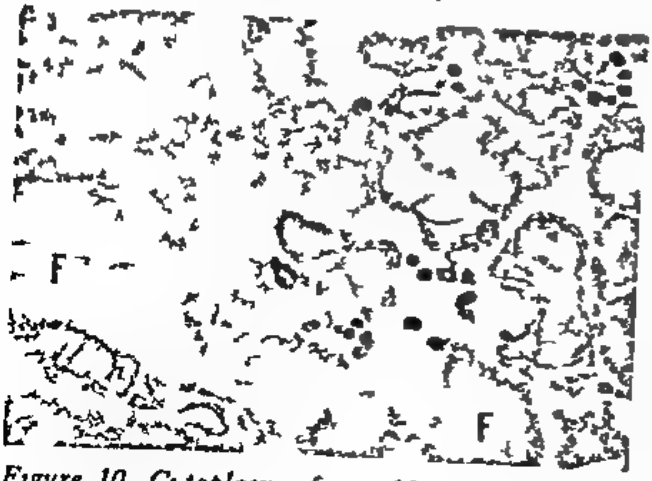

Figure 10 Cytoplasm of osteoblast like cell containing bundles of fibrils (F) Virus particles are seen in cisterns of endoplasmic reticulum (× 10 000)

The Golgi complex was rather large The mitochondria were small or medium-size and possessed distinct cristae A moderate density was seen in the matrix of the mitochondria The cytoplasmic ground substance exhibited varying electron density and a varying number of free ribosomes Mitotic figures were frequently encountered among the tumour cells both of the fibroblast like and osteoblast like type (Figure 8)

Thin cytoplasmic fibrils of low or moderate density were seen in the cytoplasm of most osteoblast like cells (Figure 9). In some cells bundles of fibrils were observed (Figure 10) Collagen fibres were seen extracellularly (Figure 11) Occasionally signs suggesting formation of collagen fibres from osteoblast like cells were found (Figures 11 and 12) Microtubules were observed in the osteoblast like cells (Figure 14)

ure 13 A rich number of virus particles in 'ened cisterns of rough endoplasmic reticulum 9 000)

us particles

A prominent ultrastructural feature was the sence of virus particles in the tumours. ey occurred with varying frequency both the fibroblast like and in the osteoblast like ls, as well as extracellularly Most virus rticles were localized to the cisterns of igh endoplasmic reticulum (Figures 9 10 and 13) A few virus particles were calized to electron lucent smooth vacuoles the cytoplasm of the tumour cells The ex icellular virus particles were found among e collagen fibres and often close to the asma membranes Budding of virus irticles was seen both in endoplasmic ticulum (Figure 14) and extracellularly igure 15)

rowth in vitro

The original cell line grew as fibroblast like ells in a monolayer When confluency was chieved the cells grew in a criss-cross attern with extensive piling up The ransplantable solid tumour was easily onverted to a monolayer cell line again This ell line had the same general culture haracteristics as the original cell line lycoplasma could not be detected However n many dishes a spontaneous cytopathic ffect (CPE) was observed especially when

Figure 14 Portion of osteoblast like cell demonstrating cytoplasmic fibrils (f) microtubules (m) and budding of virus particle (b) (× 22 000)

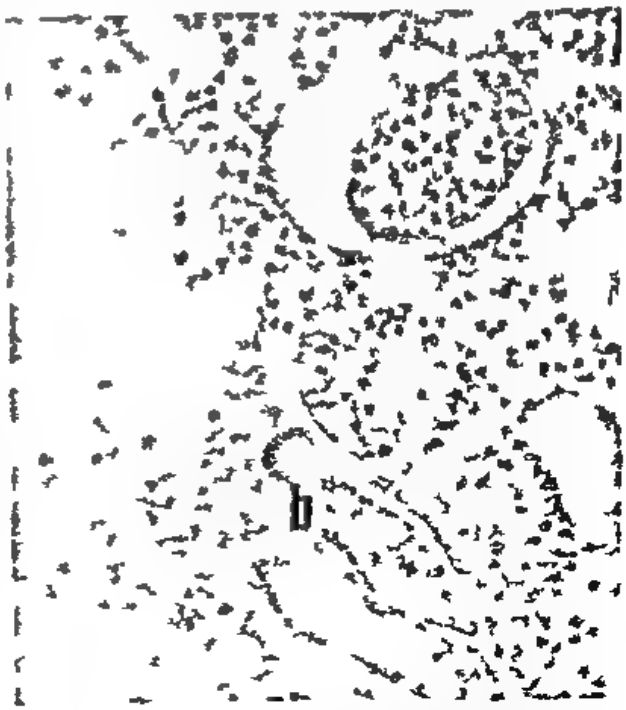

Figure 15 Peripheral portion of osteoblast like cell demonstrating budding (b) of virus particle Fibres are seen extracellularly (× 24 000)

the cells grew in the same medium for more than 2 days In this study no attempts were made to isolate a virus from the cultivated cells

DISCUSSION

The transplantable tumour in our mice displayed considerable anaplasia, high mitotic activity, unequivocal although relatively sparsely occurring osteoid, and clear alkaline phosphatase activity Fibroblast-like cells predominated Osteoblast-like cells showed signs suggestive of production of collagen fibres No chondromatous components were found We therefore classify the tumour as osteosarcoma of fibroblastic type

The tumour described here exhibited only sparse bone formation and displayed some characteristics similar to those described for the so-called Ridgway osteosarcoma, which, however, is transplantable only in AKR mice (cf Urist et al 1977) Our tumour differed also from the metastasizing line of the Dunn osteosarcoma (cf Miller et al 1976)

Because of the rich vascularization of the tumour, a so-called teleangiectatic osteosarcoma could be considered The presence, or at least the prognostic significance, of this type of osteosarcoma has been questioned in human bone pathology In our opinion, a few human osteosarcomas are so distinctly teleangiectatic that their distinction from other types of osteosarcomas is warranted (Larsson et al 1978b) The pattern of vascularization of the mouse osteosarcoma described here was not prominent enough for classification as teleangiectatic osteosarcoma Thus, we regard our transplantable mouse tumour as an osteosarcoma of fibroblastic type with rich vascularization The light microscopic, histochemical and ultrastructural features were not essentially different from those of human osteosarcoma

A prominent ultrastructural feature in the neoplastic transplanted tissue was the occurrence of virus particles, which can be observed also in Dunn osteosarsarcoma not known if the observed CPE cultures was due to the same virus, known if the observed virus represent a tumour virus activated in allogenic system used The particles well represent a C-type RNA virus, according to Urist et al (1977) occurs in Dunn osteosarcoma Characterization of virus and its ability to transform into tumour cells will be the subject of further study Development of at the site of intratibial injection of sarcoma virus (Moloney) has recently reported (Urovitz et al 1976).

Injections of tumour cell suspen obtained from cultures of the original D osteosarcoma more than 6 months before transplantation evoked a high degree resistance against the tumour by the h There are good reasons to believe that was of immunological nature because of incompatibility with respect major transplantation antigens assuming the present tumour-host system is genetic different from the original D osteosarcoma host system (cf Miller et 1976)

The osteosarcoma obtained was transplantable in the allogenic host incidence could be increased from 80 to per cent if the weight of the transplant increased from 0 03 to 0 06 g The reason the increased transplantability is not kn One possible explanation insufficient munological defence in relation to increase in tumour burden The observ that the easily transplantable tumour was accepted by animals which had received suspension 6 months earlier is no proof occurrence of a specific immunolo tumour defence However, the results of current subsequent studies indicate presence of a specific immunological de towards the tumour cells, although munotherapy with BCG did not have effect in stimulating the immuno-defence further (to be published).

FERENCES

ıa, T & Anderson, P J (1963) *Histochemistry Theory, practice and bibliography*, p 240 Harper and Row, Publ ;nc., New York, Evanston and London

lstrom, K. E., Sjogren, H O & Warner, G A 1971) Demonstration of cell-mediated immunity to human neoplasms of various histological types. *Int J Cancer* 7, 1–12

:lstrom, K E & Hellstrom, J (1973) Lymphocyte mediated cytotoxicity and blocking serum activity to tumor antigens. *Adv Immunol* 18, 209–216

'mar, S, Taylor, G, Steward, J K., Waghe, M ;A & Pearsson, A (1972) Cellular immunity in Wilm's tumor and neuroblastomas. *Int J Cancer* 10, 26–42

rsson, S-E, Lorentzon, R., Wedren, H & Boquist, L (1978a) Osteosarcoma A multifactorial clinical and histopathological study with special regard to therapy and survival *Acta orthop scand* 49, 571–581

ırsson S-E, Lorentzon, R & Boquist, L (1978b) Telangiectatic osteosarcoma A clinical, roentgenological and morphological study *Acta orthop scand* 49, 589–594

Lewis, M G, Ikonopisov, R. L, Nairn R C, Phillips, T M, Hamilton-Fairley, G, Bodenham, D C. & Alexander, P (1969) Tumor-specific antibodies in human malignant melanoma and their relationship to the extent of the disease *Brit med J* 3, 547–555

Marcove, R C, Southam, C M & Levin, A (1971) A clinical trial of autogenous vaccine in osteogenic sarcoma in patients under the age of twenty-five *Surg Forum* 22, 434–435

Marsh, B, Flynn, L & Enneking W (1972) Immunologic aspects of osteosarcoma and their application to therapy *J Bone Jt Surg* 54–A, 1367–1389

Miller, C W, DeBlasi, R F & Fisher, S J (1976) Immunological studies in murine osteosarcoma *J Bone Jt Surg* 58–A, 312–317

Urist, M R, Nakata, N, Felser, J M., Nogami, H, Hanamura, H, Miki, T & Finerman, G AmM (1977) An osteosarcoma cell and matrix retained morphogen for normal bone formation *Clin Orthop* 124, 251 266

Urovitz, E P., Cristrom, A. A., Langer, F, Gorss, A. E & Pritzker, K P H (1976) Immunogenicity of virus-induced rat osteosarcoma *J Bone Jt Surg* 58–A, 308–311

orrespondence to Sven-Erik Larsson, M D, Department of Orthopaedic Surgery, University of Umeå, -901 87 Umeå, Sweden

orthop scand 50, 491–499 1979

HE OSTEOGENIC CAPACITY OF FREE PERIOSTEAL ND OSTEOPERIOSTEAL GRAFTS

Comparative Study in Growing Rabbits

IKKO POUSSA & VEIJO RITSILA

e Orthopaedic Hospital of the Invalid Foundation, Helsinki, Finland

The behaviour of free periosteal and 200 micron thick osteoperiosteal grafts was studied histologically in 40 six-week-old rabbits. The grafts were taken from the tibia and fixed on either side of the same lumbar vertebra between the spinous and mamillary processes. The free stripped periosteum had better osteogenic activity than the 200 micron thick osteoperiosteum The new bone was formed by the osteogenic cells of the cambium layer in both types of graft

Key words osteogenesis, periosteal grafts, osteoperiosteal grafts

Accepted 1 11 79

he cortical growth of long bones is brought bout mainly by the diaphyseal periosteum his fact has been widely accepted since the ioneer investigations of Duhamel (1739) lowever, some opposing concepts have been resented For instance, MacEwen (1912) tated that the periosteum is merely a miting membrane preventing the osteolasts from being scattered from the surface f the bone into the soft tissues where their resence could be harmful MacEwen considered the osteoblasts of the osseous tissue esponsible for osteogenesis. In some respects e was right The question then arises as to where the boundary between bone and periosteum definitely lies The periosteum omprises the outer fibrous layer and the nner proliferative "cambium layer" When studying the osteogenic capacity of free periosteal transplants, the results are nfluenced by many variables including age, species, bone type, site from which the bone is derived (Fang et al 1934) and the bed to which it is grafted (Cohen & Lacroix 1955 Burwell 1969, Melcher & Accursi 1971, Alhopuro 1978) In addition, the method of detaching the periosteum from the underlying bone may also be of importance For instance, in an adult dog the stripping of periosteum from a long bone leaves the cambium layer attached to the shaft (Phemister 1914) All these factors contribute to the controversial views concerning the osteogenic capacity of the periosteum and especially of free periosteal grafts.

The constantly positive results achieved in our laboratory in investigations using young rabbits (Ritsila et al 1972a, Ritsilä & Alhopuro 1972a, b, 1973a, b, 1975, Alhopuro et al 1973a, Alhopuro 1978) have led to some clinical applications, mainly spinal fusions of idiopathic scoliosis (Snellman et al 1977) In these operations some technical difficulties were encountered A free periosteal graft stripped from the tibia of the patient has a tendency to shrink to about one third of its original length In addition it also has a tendency to curl These difficulties prompted us to experiment with

0001 6470 79 050491 09$02.50 © 1979 Munksgaard Copenhagen



Figure 1 Photomicrograph from the surface of the proximal part of the tibia of a 6 week-old r (H-E, × 250) On the right a schematic presentation (fb, fibroblast, pob, preosteoblast, ob, osteoblast o teocyte)

grafts comprising both the periosteum and a thin shaving of underlying bone, as such grafts would be easier to handle Nevertheless, taking into consideration the weak osteogenic capacity of cortical bone, the effect of the underlying bone on the osteogenic capacity of the periosteum had to be investigated

Microscopy of the surface of the cortical bone in 6-week-old rabbits (Figure 1) revealed a folded boundary between the cortex and the periosteum The periosteum sends osteogenically active buds of cambium layer into the cortex When the periosteum is stripped off, it is possible that part of the cambium layer, the buds, remain on the bone surface This can be avoided by taking part of the underlying cortex with the graft To test the hypothesis a comparative study was made in which the osteogenic capacity of free stripped periosteum was compared with periosteum attached to 200 micron thick cortical bone

MATERIAL AND METHODS

Forty 6-week-old rabbits of both sexes were used in this series, 20 of them belonging to the pilot series The animals were housed in wire mesh cages and received food pellets (Hankkija, Finland) and water *ad libitum*. The operations were performed under anaesthesia with Hypnorm[a] (Philips, Duphar) 0 5 ml/kg im and local infi tion with 0 5 per cent Lidocaine[a] wi Exadrine The periosteal and the 200 micron osteoperiosteal grafts were taken from proximal third of the medial facet of the (Figure 2) The area was first delineated wi scalpel and the periosteal graft was taken stripping The osteoperiosteal graft was dete as a whole with a circular saw The cortex made thinner by reaming the excess bone from medullary side of the graft When reaming a slow velocity was used and the graft was moist and prevented from overheating by Ringer's solution during the procedure thickness (200 micron) was checked with operating microscope In some grafts the bone was removed with a chisel No differen were noted in the behaviour of the grafts these two methods of thinning Thereafter two grafts were fixed to a lumbar (Figure 3) Through a midline incision the and mamillary processes were exposed. were sewn with 6–0 nylon

The rabbits were killed 3, 7, 11, 14 21 and 84 days postoperatively The whole vertebra was separated with its muscles and fixed in 10 per cent phosph buffered neutral formaldehyde for 1 to 2 decalcified in formic acid, dehydrated in gr alcohols, cleared in xylene, and embedded paraffin Transverse sections of 5–7 thickness were cut and stained with haematox eosin and van Gieson

RESULTS

The results are expressed as histolo findings at various periods after the graf

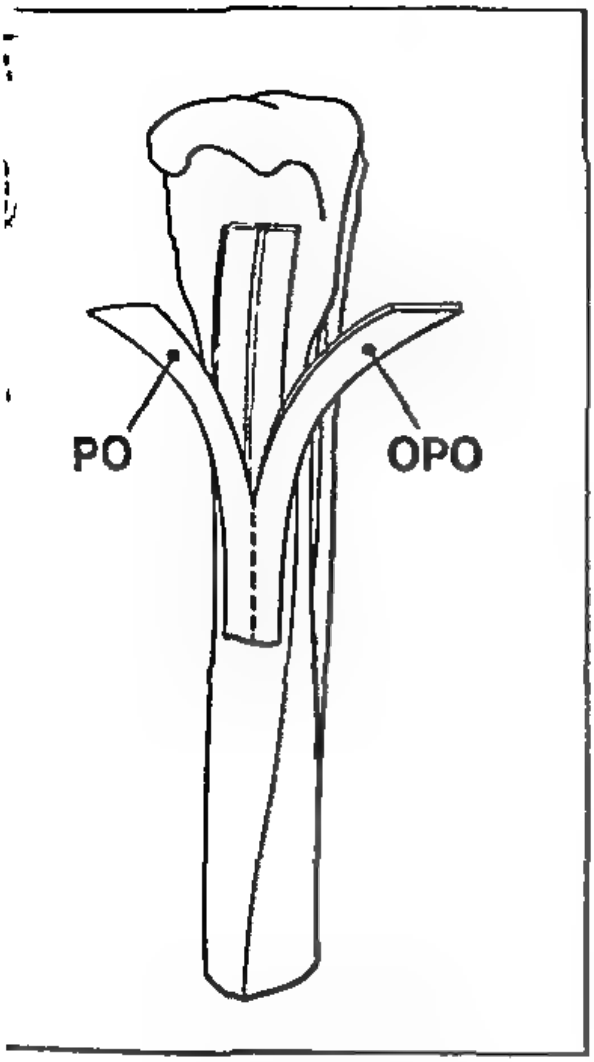

gure 2 Schematic presentation of the way of taching the grafts from the proximal part of the ia (PO, periosteum OPO, osteoperiosteum)

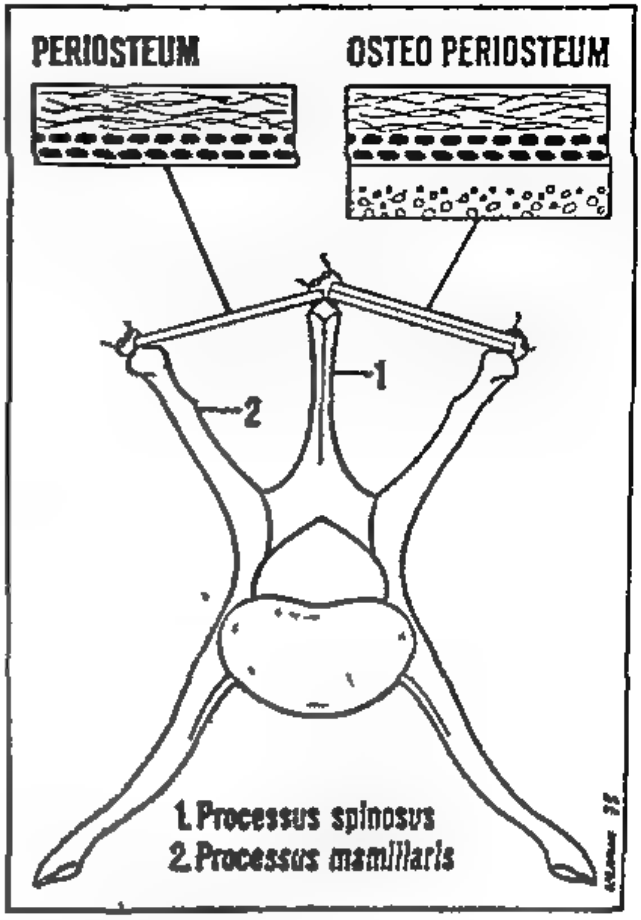

Figure 3 Schematic presentation of the method of fixing the grafts between the spinous and mamil lary processes of the lumbar vertebra

peration Comparison is thus made between ie two grafts in the same exposition

bservation period, 3 days

On the side of the free stripped periosteum iere was marked proliferation of the cells of ie cambium layer (Figure 4) Mitoses were so seen in the cambium layer The fibrotic yer, on the other hand seemed very iactive

In the 200 micron thick osteoperiosteum ie two layers of the periosteum were clearly een as well as the buds from the cambium lyer into the cortical bone No active proliteration of the cambium was noted In the art of the cortical bone facing the muscle there was a thin layer of bone with empty lacunae On the other hand, beneath the periosteum the osteocytes seemed intact and the nuclei were preserved

Observation period, 7 days

In most preparations the free stripped periosteum had formed an ossicle through the activity of the cambium cells. It looked as if the cambium cells, through proliferation, first produced cartilage which then ossified and formed woven bone (Figure 5) In the last stage the cartilage cells seemed to hypertrophy and become replaced by woven bone The ossicle was frequently situated in the middle part of the periosteal graft

On the side of the 200 micron thick osteoperiosteum no marked activity was seen Obviously the cortical part of the graft was dying with an inflammatory reaction in the

Figure 4 Low power photomicrograph (×5) from the grafts in the lumber vertebra 3 days post tively The cambium layer of the periosteum has proliferated This is clearly seen in the higher m cation (×125) of the area marked on the left (a) In the osteoperiosteum (×125) (marked area right) the folded boundary between the periosteum and the underlying cortex is seen (b) (rev G.

muscle beneath the graft A gap between the muscle and the cortex was frequently seen

Observation period, 14 days

The free stripped periosteum had formed a uniform bone-cartilage bridge between the spinous and the mamillary processes (Figure 6) The bone here resembled young woven bone, abundant osteoblasts lining its trabeculae A new thick proliferating periosteum surrounded this newly formed bone-cartilage bridge

On the side of the 200 micron thick osteoperiosteum the cambium-layer cells formed cartilage in the space between the periosteum and the cortex In some preparations there were signs of incipient bone formation in the cartilage The cortical bone was obviously dead and there was a gap between the muscle and the cortex

Observation period, 21 days

A uniform bone bridge had been formed the periosteum (Figure 7) Also the os periosteum had formed bone, but there existed some cartilage between the co and the muscle The cortical bone in osteoperiosteum was being resorbed T histological structure of the bone trabecular, abundant osteoblasts lining trabeculae The cartilage here was so-ca "secondary cartilage", i e it was be replaced by woven bone as maturation p gressed

Observation period, 28 days

A bone bridge was seen on both s (Figure 8) On the periosteal side the haematopoietic marrow in the middle of bridge On the osteoperiosteal side the p



(a)

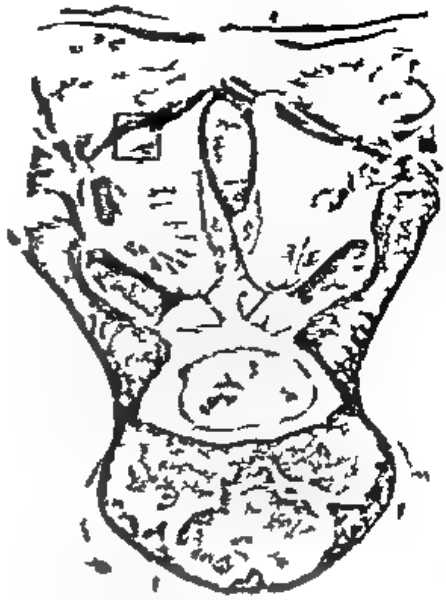

Low power photomicrograph (× 5) from the grafts 7 days postoperatively The free periosteum (left formed an ossicle which at a higher magnification (× 250) (a) is seen to consist of cartilage and e No activity in the osteoperiosteum (van Gieson)

Low power photomicrograph (× 6) from fts 14 days postoperatively The peri has formed a uniform bone-cartilage bridge osteoperiosteum cartilage has been formed the cortex and periosteum (van Gieson)

cortex was still clearly seen and surrounded by proliferating new bone

Observation period 42 days

A bone bridge with visible bone marrows had been formed on both sides (Figure 9) No difference could be observed in the stage of osteogenesis. The bone tissue formed began to resemble the structure of the neighbouring bones i e that of the processus spinosus and mamillaris

Observation period 84 days

Remodelling of the previously formed bone was the main feature that separated this stage from the former one (Figure 10) The bone formed was structurally compact and resembled that of the adjacent processes

DISCUSSION

The known prerequisites for bone formation are proper osteogenic cells proper environment and proper stimulus Yet the basic

Figure 7 Low power photomicrograph (×6) from the grafts 21 days after the grafting proce[illegible] periosteum on the left has formed a bone bridge between the spinous and mamillary processes On the[illegible] the osteoperiosteum the secondary cartilage is being replaced by trabecular bone The hypertrophic ca[illegible] cells are clearly seen in the higher magnification on the right (× 125 van Gieson)

Figure 8 Low power photomicrograph (×5) from the grafts 28 days postoperatively On the left of the figure bone formed by the periosteal graft haematopoetic marrow in the middle On the right the cortex still visible surrounded by new bone (van Gieson)

Figure 9 Symmetrical bone bridges [illegible] operatively Medullary cavity visible [illegible] sides (van Gieson ×5)

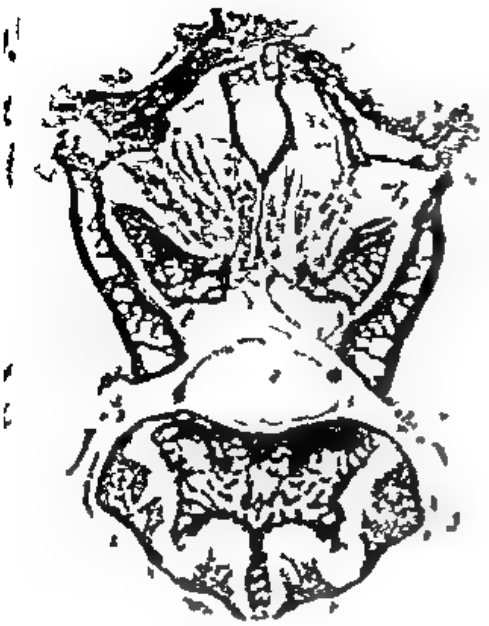

re 10 Remodelling of the bone bridges has rred 84 days postoperatively (van Gieson

chanisms of osteogenesis are obscure asset 1962) It is now widely accepted that bone transplantation part of the cells of the ft retain their vitality and after the trans ntation begin to proliferate and form new ne (Heslop et al 1960, Elves & Pratt 1975, rvo 1975) In the inner layer of the riosteum of young animals there are a lot of teogenically active cells. The present dies were performed with growing rabbits n the other hand, in earlier studies free riosteal grafts from old rabbits also formed one (Ritsila et al. 1972a) Earlier studies ive pointed out that with free periosteal afts the bone formation mechanism is direct oliferation of the cambium cells (Tonna & ronkite 1962, 1963, Ritsila et al 1972a, b, tsila & Alhopuro 1973a, b) Thus quite a rapid ocess, as it was also in this investigation ortical bone, on the other hand, is known to be teogenically weak (Gallie 1931, Burwell 69) and the mechanism of osteogenesis is fferent It occurs mainly through resorption the graft and the new bone is formed through mechanism of "creeping substitution" and modelling

There are some observations in the terature concerning the size of the graft Andersson (1961) studied the size of cortical chips Smaller, 0 3–7 mm, chips underwent complete necrosis and in addition incited a strong inflammatory reaction So-called cortical shavings without periosteum are said to be of no value as grafting material (Keith 1934, Siffert 1955) A too massive bone graft, on the other hand, becomes necrotic because of difficulties in revascularization (Zeiss et al. 1960) The ideal size of a bone graft is one of the many unsolved problems of the grafting procedure (Burwell 1969)

The aim of this investigation was to study the effect of the cortical bone in the osteoperiosteal graft In theory, several factors could have an influence Firstly, removal of a piece of underlying bone with the periosteum means that all the osteogenic cells and thus the maximal amount of osteogenic material is included in the graft Secondly, death of the cortical bone could stimulate the periosteum and in this way enhance osteogenesis in the graft (Richany et al 1965, Gage et al 1966) Thirdly, as resorption of the cortical bone takes place first a delay in bone formation is to be expected

The results of this study showed that periosteum alone had a more potent bone forming capacity than the 200 micron thick osteoperiosteum In the osteoperiosteal grafts the resorption of the cortical bone perhaps took place first and osteogenesis could begin first thereafter Also the development of circulation which is known to occur simultaneously with resorption can be delayed in the osteoperiosteum when compared with free periosteum

The process of bone formation seemed consistently to go through a cartilage phase These cartilage cells showed great similarity to the cartilage cells seen in the zone of proliferation in the growth columns of epiphyseal lines Although the arrangement was not as orderly there was often a suggestion of palissading of cartilage cells as they underwent enlargement and swelling This cartilage can be called secondary cartilage because through the ingrowth of vessels and osteoblasts it was replaced by bony

structures Here the periosteum was taken from the tibia, a bone of endochondral origin, but the same phenomenon has also been observed with periosteum from the calvarium and the scapula (Alhopuro 1978) The resulting bone resembled that of the spinous and mamillary processes and not that of the tibia This effect of the surrounding tissues was also observed in earlier studies (Ritsila & Alhopuro 1973a, b, Alhopuro 1978)

Further studies are envisaged to examine the effect of the thickness of the cortical bone, especially the effect of thinner grafts, as then the resorption process could be shortened or could perhaps be totally avoided

REFERENCES

Alhopuro, S, Ranta, R & Ritsila V (1973a) Growth of the rabbit snout after bony fusion of the frontonasal suture achieved by means of a free periosteal transplant *Proc Finn Dent Soc* 69, 166–167

Alhopuro, S (1978) Premature fusion of facial sutures with free periosteal grafts. *Scand J plast reconstr Surg*, Suppl 17

Andersson, K J (1961) The behaviour of autogenous and homogenous bone transplants in the anterior chamber of the rat's eye A histological study of the effect of the size of the implant *J Bone Jt Surg* 43-A, 980–995

Basset, C A L (1962) Current concepts of bone formation *J Bone Jt Surg* 44-A, 1217–1244

Burwell, R G (1969) The fate of bone grafts *Recent advances in orthopaedics*, Ed Appley A G, pp 115–191 Churchill, London

Cohen, J & Lacroix, P (1955) Bone and cartilage formation by periosteum *J Bone Jt Surg* 37-A, 717–730

Duhamel H L (1739) Cited by Basset, C. A L in *Current concepts of bone formation J Bone Jt Surg* 44-A, 1217–1244

Elves M W & Pratt L M (1975) The pattern of new bone formation in isografts of bone *Acta orthop scand* 46, 549–560

Fang, H C & Miltner, L J (1934) Comparison of osteogenic power of periosteal transplants from rib and tibia *Proc Soc exp Biol Med* 31, 386–388

Fang, H C., Yuan, Y K & Miltner, L J (1934) Osteogenic power of tibial periosteum. *Proc Soc exp Biol Med* 31, 1239–1240

Gage, A A, Greene, G W, Jr, Neiders M E & Emmings, F G (1966) Freezing bone, excision An experimental study of bone destruction and manner of regrowth *Amer med Ass* 196, 770–774

Gallie, W E (1931) The transplantation of [illegible] *Brit med J* 2, 840–844

Heslop, H E, Zeiss, J M & Nisbet, N W [illegible] Studies on transference of bone. I A [illegible] son of autologous and homologous implants with reference to osteogenesis and host reaction. *Brit J Path* 41, 269–287

Keith, W S (1934) Small bone grafts *J Bone Surg* 16, 314–330

MacEwen, W (1912) The growth of bone [illegible] vations on osteogenesis. *An inquiry into the development and [illegible] of diaphyseal bone* James Maclehose & S. Glasgow

Melcher, A H & Accursi, G D (1971) On [illegible] of periosteal and osteogenic [illegible]

Phe [illegible] bone and regenerative power of its [illegible] constituents. *Surg Gynec Obstet* [illegible] 303–333

Richany, S F, Sprinz, H, Kraner K, [illegible] & Merrill, T G (1965) The role of the diaphyseal medulla in the repair and regeneration of the femoral shaft in the adult cat *J Bone Surg* 47-A, 1565–1584

Ritsila, V, Alhopuro, S & Rintala, A (1971) Bone formation with free periosteum. *Scand J plast reconstr Surg* 6, 51–56

Ritsila, V, Alhopuro S, Gylling U & Rintala (1972b) The use of free periosteum for bone formation in congenital clefts of the [illegible] *Scand J plast reconstr Surg* 6, 57 60

Ritsila, V & Alhopuro, S (1972a) Posterior spinal fusion in growing rabbits with [illegible] periosteal grafts *Scand J clin Lab Invest* 29, Suppl 122, 51

Ritsila, V & Alhopuro, S (1972b) Experimental studies on the repair of bone defects [illegible] tracheal cartilage defects with free periosteum *Scand J clin Lab Invest* 29, Suppl 122

Ritsila, V & Alhopuro, S (1973a) The repair of bone defects with free periosteum. *Acta orthop scand* 44, 137

Ritsila, V & Alhopuro, S (1973b) Reconstruction of experimental tracheal cartilage defects with free periosteum *Scand J plast reconstr Surg* 7, 116–119

Ritsila, V & Alhopuro, S (1975) Spinal [illegible] with free periosteal grafts and its effect on vertebral growth in young rabbits *J Bone Surg* 57-B, 500–505

R [illegible] (1955) Experimental bone isplants. *J Bone Jt Surg* 37-A, 742–758

an, O, Osterman, K & Ritsila, V (1977) nal fusion of idiopathic scoliosis with free osteal grafts A preliminary report *Acta iop scand* 48, 339 (Abstract)

T. (1975) Autogeenisen ja kortikaalisen siirrannäisen revaskularisoituminen ja reanisoituminen Doctoral Thesis, University Helsinki

, E A & Cronkite, E P (1962) An autoiographic study of periosteal cell proliferation with tritiated thymidine *Lab Invest* 11, 455–462.

Tonna, E A & Cronkite, E P (1963) The periosteum Autoradiographic studies on cellular proliferation and transformation utilizing tritiated thymidine *Clin Orthop* 30, 218–232

Zeiss, J M, Nisbeth, N W & Heslop, B F (1960) Studies of transference of bone II Vascularization of autologous and homologous implants of cortical bone in rats. *Brit J exp Path* 41, 345–363

ipondence to Mikko Poussa, The Orthopaedic Hospital of the Invalid Foundation, ilantie 10, 00280 Helsinki 28, Finland.

orthop scand. 50, 501–506 1979

NE THICKENING IN OSTEOARTHROSIS

ervations of an Osteoarthrosis-Prone Strain of Mouse

RK WALTON* & MICHAEL W ELVES†

itute of Orthopaedics, Stanmore, England

Estimations were made of the amount of bone (histologically) and the rate of bone formation (^{85}Sr incorporation) in the epiphyses of the knees of osteoarthrosis-prone (STR/ORT) and normal (CBA/ORT) mice Though the bone was significantly thicker in the STR/ORT mice, this was not the cause of the articular degeneration Bone sclerosis and cartilage breakdown were chronologically very closely related with perhaps the cartilage changes occurring initially In male STR/ORT mice bone formation was depressed in the cancellous bone of the epiphyses as, unlike the normal mice, it was at the same level as the compact bone of the femoral shaft As there was no elevation of the osteoblastic activity in knee joints with developing osteoarthrosis, it would appear that bone sclerosis associated with the disease was due to decreased osteoclasis.

Key words bone formation, bone thickening, mouse, osteoarthrosis

Accepted 29 III 79

e thickening of subchondral bone under ;enerating articular cartilage is an integral t of the disease process in osteo-hrosis (degenerative joint disease) ollins 1949, Sokoloff 1969) It has been nerally accepted that the bone thickening is econdary reaction of the tissue to the dis-egration of the overlying cartilage Contrary this belief, Radin et al (1972) have stulated that initially the bone becomes ickened as a result of the repair of crofractures caused by excessive impulse iding of the joint Consequently, they ined, the weight-bearing tissues become s phiable so that there is greater shock sorption by the cartilage itself, which as a result, degenerates However the exact sequential appearance of subchondral bone sclerosis relative to cartilage breakdown cannot be investigated in the human and has not been studied in a naturally occurring form of osteoarthrosis in animals.

A murine form of osteoarthrosis in the knee joint of the STR/ORT strain, which has been described in some detail (Walton 1977a, b and c, 1978, 1979), appeared to be a suitable model for examining the sequential appearance of subchondral bone sclerosis and cartilage degeneration and to study the rate *of bone turnover in the development of the* disease

esent addresses
Dept. of Orthopaedic Surgery, Univ of Otago edical School, P O Box 913, Dunedin New aland

† Microbiology Division, Glaxo-Allenburys Research Greenford England

01 64"0 79 050501–0650 50 D

© 1979 Munksgaard, Copenhagen

MATERIALS AND METHODS

Mice from the osteoarthrosis-prone strain STR/ORT were taken at 2 (mostly pre-arthrotic), 7 (mostly early arthrotic) and 10 (mostly advanced arthrotic) months of age As controls, mice of the same ages were used from the non-osteoarthrosis-prone strain CBA/ORT (Walton 1977a)

Epiphyseal bone content Histological preparations of coronal sections of the knee joints from male mice were used to assess the proportion of the epiphyses that consisted of lamellar bone Under a magnification of ×160 and with a Chalkley random point graticule inserted in one eyepiece, the medial and lateral, tibial and femoral epiphyses were positioned in turn such that only cancellous bone filled the field covered by the graticule Of the 25 randomly scattered dots on the graticule, only those that were on or partly on lamellar bone were counted Serial sections from a minimum of eight knee joints from four STR/ORT mice and ten from six CBA/ORT mice were scored in each age group The results were calculated as a percentage of the epiphysis which was occupied by lamellar bone This was repeated for the medial and lateral sides of the tibial and femoral epiphyses for each strain in the three age groups. In addition each joint was scored for the severity of osteoarthrosis as previously described (Walton 1977b) Student's *t* test was applied to assess the level of significance of the bone content (a) between the various ages and (b) between the various grades of osteoarthrosis.

Rates of bone accretion The method used was modified from that of Elves (1974) Portions of bone from a total of 82 male and female, CBA/ORT and STR/ORT mice were used Each animal was given 0 08 μC ^{85}Sr/10g body weight by the intraperitoneal route, and was killed 3½ days later Lateral and antero-posterior radiographic views of the knee joints were taken The femur and proximal end of the tibia were removed from each side of the animal and scraped clean Two portions of the femur were excised, (a) the distal epiphysis (including the growth plate) which was then divided, through the patella groove and intercondylar notch, into medial and lateral halves, and (b) the shaft The proximal epiphysis of the tibia was also taken and divided between the two condyles into medial and lateral portions. After immediate weighing, the radioactivity of each piece of bone was measured using a Nuclear Enterprise 8312 β/γ counter The results were calculated as specific activity of ^{85}Sr/mg of bone In order to ascertain the type of bone that constituted the femoral shaft, histological examinations were made of samples taken from each age group of both strains and sexes

RESULTS

Epiphyseal bone content

The results were very consistent w each group as shown by the low val the standard errors (Figure 1). Gener individual non-arthrotic joints the val bone content were reasonably throughout all the serial sections. joints with early osteoarthrosis thicker in sections showing degen changes in the articular cartilage

In the normal young mice of CBA/ORT strain the bone was signifi thicker in their medial compared with their lateral tibial ($P = 0\ 05$–$0\ 02$) femoral ($P = 0\ 05$) epiphyses. However in the medial tibial epiphysis, where there was a rise of 7 7 per cent between 2 and months of age, did the density of increase significantly with age ($P = 0\ 02$

The tibial epiphyses of male STR mice had significantly more bone o

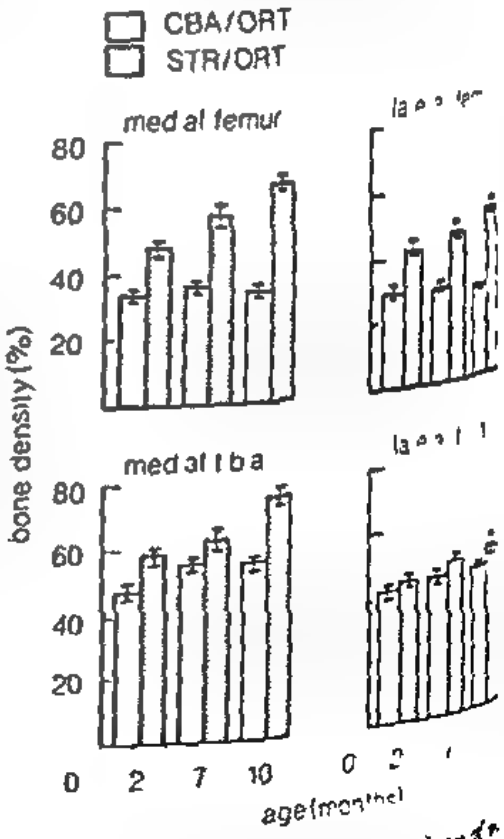

Figure 1 Density of bone in the epiphyses of STR/ORT and CBA/ORT mice The standard error is indicated at the top of each column

al side at 2 months of age ($P < 0.005$) no such asymmetry occurred in the ral epiphyses With age in all the bone ons the content of bone increased ficantly Between 2 and 10 months the int of bone in the tibial epiphyses ased twice as much on the medial side per cent) compared with the lateral side per cent) Over the same period the al femoral epiphyses consisted of 19 1 cent more lamellar bone compared with ncrease of only 9 0 per cent laterally

omparing the results from the two ns the medial tibial epiphyses of the T/ORT mice contained 10 7 per cent more than the comparable region of the T/ORT mice at 2 months of age < 0 005) At all ages, three regions were ificantly more dense ($P < 0.005$) than the esponding CBA/ORT epiphyses The ption was the lateral tibial epiphysis ch had a greater density of bone than the ivalent CBA/ORT, but the difference een the two was not significant

able 1 shows the mean content of bone in medial tibial epiphyses of those joints h each grade of severity of osteoarthrosis m this data it will be seen that the greater severity of the lesion the greater was the ntent of bone in the epiphysis. There were tistically significant differences between des 0 and 1 and between grades 2 and 4 ~ 0 005 and <0 005, respectively) There was also a significant difference between grade 0 STR/ORT knee joints and those of 2-month-old CBA/ORT mice ($P = 0.025$)

ble 1 Correlation between the grade of severity osteoarthrosis and the degree of bone sclerosis in the medial tibial epiphyses

ade of eoarthrosis	No of joints	Content of bone (% volume of epiphysis ± s.e.)
R/ORT		
0	7	55 1 ± 2.1
1	7	65 8 ± 2 7
2	5	68 1 ± 3 2
3	1	75 3
4	5	90 6 ± 2.1
A/ORT		
0	30	53 0 ± 3 2

Rates of bone accretion

A minimum of six results were obtained from each sex and strain for every age and each of the bone portions. A mean of the six results was calculated In some instances a high value of the standard error reflected considerable deviation of individual readings from the mean value The medial epiphyses of male STR/ORT tibiae incorporated more radiostrontium than the lateral side at 2 months of age ($P = 0.05$) However, as the differences in uptake between lateral and medial epiphyses in all the other groups were not statistically significant, the data from both sides were combined to give the final values The results from the left and right femoral shafts were also combined The results are presented in Figures 2, 3 and 4

Overall there was a general decline in the uptake of the radionuclide with age The male CBA/ORT and the females of both strains incorporated more ^{85}Sr in the cancellous bone of their epiphyses than in the compact bone of their femoral shafts. In contrast, the levels of radioactivity in both the shafts and epiphyses of the male STR/ORT were similar Thus though the levels in males of both strains were very similar in the compact bone the levels were higher in the epiphyses of the CBA/ORT strain than the STR/ORT Female CBA/ORT mice showed lower incorporation of the radionuclide than their male counterparts, whereas the female STR/ORT mice always had much higher levels than the male of that strain

Severe degenerative lesions in the form of deep erosions could be seen by the naked eye on the medial condyles of some of the male STR/ORT specimens. In some of these joints both the medial and lateral epiphyses had incorporated approximately half the ^{85}Sr than the mean for their age group However, the other osteoarthrotic joints deviated little from the age group mean

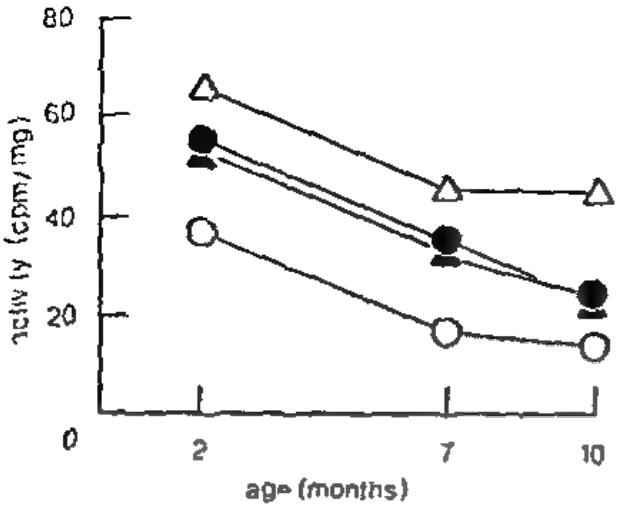

Figure 2 Femoral shafts

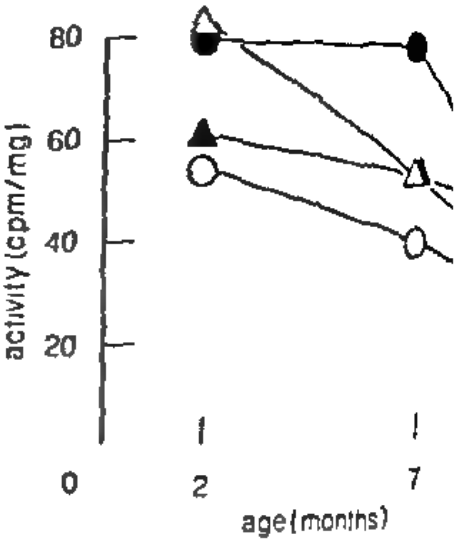

Figure 4 Proximal tibial ep

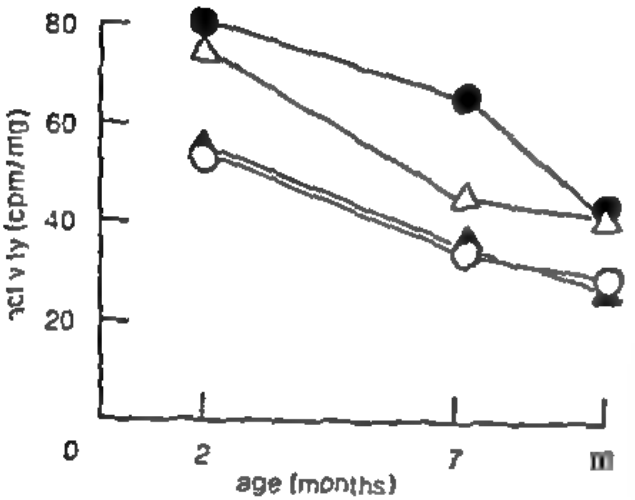

Figure 3 Distal femoral epiphyses



Figures 2, 3 and 4
Radioactivity of portions of bone 3½ day
traperitoneal administration of 0 05 μC
body weight

DISCUSSION

Some degree of flexibility will enable a structure to widely distribute through its mass mechanical forces applied to it On the other hand if the structure is rigid, then there is little dissipation of the applied forces, which are therefore borne by a smaller mass of the structure Thus weight bearing by an articulating surface of a joint is not likely to damage the tissues if the force-attenuating properties of the cartilage and underlying bone are such that they can absorb and spread the load However, Radin & Paul (1970) have pointed out that cartilage has visco-elastic properties which mea there is a time delay in its response bearing, consequently the subchond probably takes the brunt of the m loads applied to the joint The area thus the stiffness of this bone is the major factor in the nature of the mec response of the joint and conseque health of the tissues. If the volume chondral bone relative to marrow sp creases, then mechanically it will be s but less flexible (Behrens et al. 1974)

The present study has shown th

nt of bone in the medial tibial epiphyses 3A/ORT and non-arthrotic STR/ORT is greater than that of the lateral yses A similar situation is present in Behrens et al 1974, Lereim et al 1974) een strains at 2 months of age there was per cent more bone in the medial tibial yses of the STR/ORT strain than in the sponding region in the CBA/ORT strain ver this difference is not an explanation e differential occurrence of osteoarthrosis een the strains The onset of isease in individual STR/ORT mice is d over a wide span of ages (2–11 hs, Walton 1977b) As some 10-month-nce had no histological signs of osteo-osis (grade 0) yet had a higher yseal bone content than the CBA/ORT it would appear that the abnormal nts of bone do not as such give rise to rticular degeneration

cording to Radin et al (1973) the initial ss of bone thickening in osteoarthrosis is to callus formation at the sites of ple fatigue microfractures However, in lentical experiment, Serink et al (1977) l that microfractures were rare and they dered them to be artefactual Bone osis in STR/ORT mice appears only r degenerating articular cartilage It first in the small inner portion of the al tibial epiphysis and then slowly extends ards as the cartilage lesion spreads is the condyle At all stages of develop-the bone thickens by the laying down of al lamellar bone on existing trabeculae in the form of woven bone was never When the disease in STR/ORT mouse joints was prevented by surgical means subchondral bone sclerosis did not occur lton 1979)

active thickening of the bone was a pre-isite for the disease then a wide ability in the content of bone in grade 0 would be expected, some individual ts would have been abnormally thickened r to an early onset and there would have others with normal amounts of bone ch would develop the disease later in life However, this was not the case, as the grade 0 joints included some from 2, 7 and 10 months of age, and yet the variation between the individual joints was small as demonstrated by a low standard error It would seem more likely that if one of the pathological features had preceded the other, then the cartilage degeneration had occurred before bone thickening

The actual amount of bone present in any skeletal system is determined by a dynamic equilibrium between formation and resorption The incorporation of radio-strontium into the mouse bones indicates the level of bone accretion over a 3¼ day period, after which non-incorporated radionuclide has disappeared from the tissues (Elves 1974) With the larger osteogenic surfaces of cancellous bone as opposed to compact cortical bone, greater formation would be expected, and was indeed found in CBA/ORT mice, in the bone of the epiphyses compared with that in the bone of the shafts However, incorporation of the radionuclide in the bones of the male STR/ORT strain was similar in the epiphyses and shafts. This could be explained by either the thicker bone of the STR/ORT epiphyses, resulting in reduced surface area for appositional bone formation, or it may be due to an abnormal depression of the osteoblastic activity in the epiphyses. Certainly in both femoral and tibial epiphyses of the male STR/ORT mice the levels of radionuclide were very much lower than in the CBA/ORT mice, even at 2 months of age before any significant amount of sclerosis was evident This would indicate that there is a reduced rate of bone formation in these animals.

The epiphyses of the femur and tibia were divided in order to detect any differences in bone formation rates between the medial side, where osteoarthrosis always occurs in the male STR/ORT mice, and the lateral side which invariably remains normal Only in 2-month-old male STR/ORT mice was there any significant difference between medial and lateral sides. This is unlikely to be due to early sclerosis as the incidence of osteo-

arthrosis is low in this age group At subsequent ages in male STR/ORT mice, medial and lateral sides were not statistically different in their ^{85}Sr uptake, which was unexpected in view of the fact that sclerosis was actively developing medially in a high proportion of the 7 month-old mice The explanation for this must be that bone sclerosis in degenerative joint disease of male STR/ORT mice is due to reduced osteoclasis rather than enhanced osteoblastic activity

Thus the epiphyses of male STR/ORT mice have an abnormally low bone turnover with reduced bone formation and resorption In addition it appears from the estimations of epiphyseal bone content that the articular cartilage in the knee joints of male STR/ORT mice may be degenerating before the underlying bone thickens, though both processes are closely related pathologically and chronologically Certainly in animal models of osteoarthrosis in which cartilage is enzymatically denatured bone sclerosis is a secondary event (Bentley 1971) However Radin et al (1973) found that increased stiffness of subchondral bone preceded cartilage degeneration in mechanically induced osteoarthrosis in rabbits. Contrary to this finding Serink et al (1977) in an identical experiment found that Young's modulus of the subchondral bone decreased (i e the tissues softened) after the same amount of stress that caused cartilage degeneration

ACKNOWLEDGEMENT

This study was supported by a grant from the Wellcome Trust to Dr Audrey U Smith.

REFERENCES

Behrens, J C Walker P S & Shoji H (1974) Variation in strength and structure of cancellous bone at the knee. *J Biomech* 201–207

Bentley G (1971) Papain-induced c arthritis of the hip in rabbits. *J Bone* 53 B 324–337

Collins, D H (1949) *The pathology of and spinal diseases* Edward Arnold L

Elves, M. W (1974) An evaluation of the strontium^{85} for the bone grafts. *Acta orthop scand* 41 (

Lereim P Goldie I & Dahlberg, E Hardness of the subchondral bone condyles in the normal state and arthrosis and rheumatoid arthritis *Acta scand* 45, 614–627

Radin E L Parker H G, Pugh J Steinberg R B Paul, I L & Rose (1973) Response of joints to impact b III Relationship between microfractures and cartilage degener *Biomechanics* 6, 51 59

Radin E L & Paul, I L. (19 0) Does cartilage compliance reduce skeletal impact load relative force-attenuating propert cartilage synovial fluid, peri-articular tissue and bone *Arthritis Rheum* 139–144

Radin E L. Paul I L. & Rose, R M Role of mechanical factors in the path of primary osteoarthritis. *Lancet* i, 519

Serink M T Nachemson A & Hansson (1977) The effect of impact loading on knee joints. *Acta orthop scand* 48, 5

Sokoloff L (1969) *The biology of degen joint disease* University of Chicago Press

Walton M (1977a) Degenerative joint the mouse knee rad ological and morpho observations. *J Path* 123, 9 10

Walton M (1977b) Degenerative joint dis the mouse knee histological observation *Path* 123, 109–122

Walton M (1977c) Degenerative joint dis the mouse knee joint scanning e microscopy *J Path* 123, 211 217

Walton M (1978) Obesity as an aet factor in the development of osteo *Gerontology* 25, 36–42

Walton M (1979) Patella displacement osteoarthrosis of the knee joint in mice *J P* 127 (In press).

Correspondence to Dr Mark Walton Dept of Orthopaedic Surgery University of Otago School P O Box 913 Dunedin New Zealand

thop scand. 50, 507–512, 1979

NE-MARROW PRESSURE AND BONE STRENGTH

UMAR*, P R. DAVIS** & B PICKLES*

ersity of Alberta, Edmonton, Canada, and
iversity of Surrey, Guildford, United Kingdom

The pattern of bone-marrow pressure changes differed with the mode of stress application. Intra-medullary pressure remained steady during most of the slow loading During rapid dynamic loading, however, a slight rise in intra-medullary pressure was observed Contraction of the femoral muscles also resulted in a greater bone-marrow pressure increase A correlation of 0 98 ($P < 0$ 001) between stimulus strength and intra-medullary pressure was obtained The rise in intra-medullary pressure with femoral muscle contraction is suggested to have a possible role under extreme stresses in living conditions.

Key words bone-marrow pressure, hydraulic strengthening of bones, nerve stimulation and intra-medullary pressure, muscle contraction and bone-marrow pressure

Accepted 14 m 79

f (1960) claimed that when spinal com- occurred the vertebral end plate l and blood was forced out of the ellous bone of the vertebral body into the vertebral sinuses, and that this was the energy dissipating mechanism on

irgin (1951), Hirsch (1951), Brown et al 7), Hardy et al (1958), Roaf (1960), Ere , and Smith (1969) have shown that vertebral bodies and end plates fail *in vitro* experiments when pressures than those calculated by Bradford & (1945), Bartelink (1957), and Morris (1961) for *in vivo* situations are applied st (1964) and McPherson & Juhasz (1965) e suggested that bones may be con- strengthened hydraulically by the fluid pressure & Freeman (1966) rejected this ity on the basis of results from com- experiments performed on dried and femora However, resistance to stress of bone *in vivo* may be different from that in *in vitro* situations, due to the effects of vessel occlusion and muscle contraction demonstrated by Herzig & Root (1959), Azuma (1964), and McPherson & Juhasz (1965) Shaw (1963) showed that, in 90 out of 100 experiments, the intra-medullary blood flow was directly related to the marrow pressure in the hind limb of cats. This finding was confirmed by Azuma (1964) for dogs.

The present experiments were undertaken to determine the effects of slow and fast loading of the femur on the femoral marrow pressure in rats. The effect of graded contractions of the overlying quadriceps muscle on femoral marrow pressure was also investigated

APPARATUS

The output of the duly calibrated pressure transducer (SE 4–81) from bone-marrow was fed to the d c amplifier via the carrier amplifier (SE 4912) of the Electro-Medical Multichannel

647 0 79 050507–06$02.50 0

c 1979 Munksgaard, Copenhagen

arthrosis is low in this age group At subsequent ages in male STR/ORT mice, medial and lateral sides were not statistically different in their ^{85}Sr uptake, which was unexpected in view of the fact that sclerosis was actively developing medially in a high proportion of the 7-month-old mice The explanation for this must be that bone sclerosis in degenerative joint disease of male STR/ORT mice is due to reduced osteoclasis rather than enhanced osteoblastic activity

Thus the epiphyses of male STR/ORT mice have an abnormally low bone turnover with reduced bone formation and resorption. In addition it appears from the estimations of epiphyseal bone content that the articular cartilage in the knee joints of male STR/ORT mice may be degenerating before the underlying bone thickens, though both processes are closely related pathologically and chronologically Certainly in animal models of osteoarthrosis in which cartilage is enzymatically denatured, bone sclerosis is a secondary event (Bentley 1971) However *Radin et al (1973)* found that increased stiffness of subchondral bone preceded cartilage degeneration in mechanically induced osteoarthrosis in rabbits Contrary to this finding, Serink et al (1977) in an identical experiment found that Young's modulus of the subchondral bone decreased (i e the tissues softened) after the same amount of stress that caused cartilage degeneration

ACKNOWLEDGEMENT

This study was supported by a grant from the Wellcome Trust to Dr Audrey U Smith

REFERENCES

Behrens, J C Walker P S & Shoji H. (1974) Variation in strength and structure of cancellous bone in the knee *J Bone* [illegible] 201–207

Bentley, G (1971) Papain induced [illegible] arthritis of the hip in rabbits *J Bone* [illegible] *53-B*, 324–337

Collins, D H (1949) *The pathology* [illegible] *and spinal diseases* Edward Arnold [illegible]

Elves M W (1974) An evaluation of the strontium^{85} for the assessment of bone grafts. *Acta orthop scand* 45, [illegible]

Lereim P, Goldie I & Dahlberg, E. Hardness of the subchondral bone [illegible] condyles in the normal state and [illegible] arthrosis and rheumatoid arthritis [illegible] *scand* 45, 614–627

Radin E L Parker H G, Pugh [illegible] Steinberg, R S, Paul I L & Rose [illegible] (1973) Response of joints to impact [illegible] III Relationship between [illegible] microfractures and cartilage degeneration *Biomechanics* 6, 51–59

Radin E L. & Paul, I L. (1970) Does [illegible] compliance reduce skeletal impact [illegible] relative force-attenuating properties of [illegible] cartilage synovial fluid, periarticular tissue and bone *Arthritis Rheum* 139–144

Radin, E L, Paul I L & Rose R. M Role of mechanical factors in the path[illegible] of primary osteoarthritis. *Lancet* 1, 519–[illegible]

Serink, M T, Nachemson A & Hi[illegible] (1977) The effect of impact loading o[illegible] [illegible] *scand* 48, [illegible]

[illegible] observations *J Path* 123, [illegible]

Walton, M (1977b) Degenerative joint [illegible] the mouse knee histological observa[illegible] *Path* 123, 109–122.

Walton M. (1977c) Degenerative joint [illegible] the mouse knee joint, scanning [illegible] microscopy *J Path* 123, 211 217

Walton M (1978) Obesity as an [illegible] factor in the development of osteo[illegible] *Gerontology* 23, 36–42.

Walton M (1979) Patella d[illegible] osteoarthrosis of the knee joint in mice [illegible] 127 (In press)

Correspondence to Dr Mark Walton Dept of Orthopaedic Surgery, University of Otago School, P O Box 913 Dunedin New Zealand



re 2 Photograph showing the femur of an sthetised rat gripped in the compression ce

ilation to produce contraction of the ying muscles a transverse incision along the joint of the left leg was prolonged on the al side The femoral nerve was traced up to groin and divided as proximally as possible patella was separated from the tibia, reflected ard and a hole drilled in the longitudinal axis ie femur through the condyle. The knee joint flushed with warm saline and the needle ing the transducer was inserted deep into the marrow All muscles overlying the bone were undisturbed. The cut distal end of the oral nerve was placed on the bipolar electrode he stimulator (Figure 2)

SULTS

normal resting range of bone-marrow ssure in all the rats studied in the present varied from 1 07 to 2.40 kPa (8 to 18 Hg) [mean resting pressure 1 65 kPa (12 4 Hg) standard error of the mean 0 08 kPa mmHg)]. The most frequently observed ies were between 1 6 kPa to 1 87 kPa (12 14 mmHg) The marrow pressure tended vary within the range of 0 267 kPa (± Hg) under resting conditions.

Slow loading

The bone-marrow pressure did not alter either during the period of loading or on completion of the process and maintenance of the load In higher ranges of loading sometimes an obvious fluctuation of bone-marrow pressure within the normal pressure variation range was observed.

Fast loading

During fast loading, bone-marrow pressure variations were normal within the range of 0 to 2 7 kg Beyond this level as the loads were swiftly applied, sudden pressure changes were observed, these being more pronounced if the loading omitted two of the intermediate steps. A rise of 2 kPa (15 mmHg) was observed when the compression was raised from 4 kg to 12.25 kg Generally, a higher magnitude of compression engendered greater increases in the intra-medullary pressure

Contraction of the overlying muscles

Stimulation of the femoral nerve, causing contraction of the quadriceps muscles resulted in a considerable rise in bone-marrow pressure (Figures 3 and 4). There was a progressive increase in bone-marrow pressure with each increment in stimulus strength. A maximum pressure rise of 8 kPa (60 mmHg) was recorded with 5 V stimulation A high degree of correlation between stimulus strength and intra-medullary

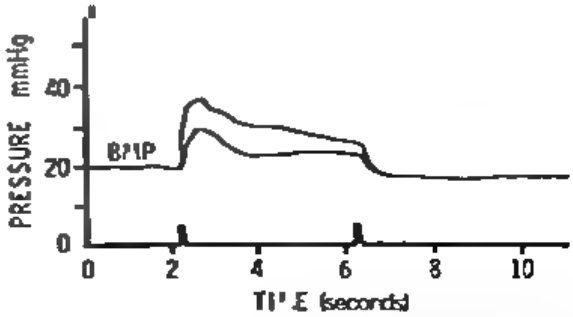

Figure 3 Trace showing the bone marrow pressure (BMP) during contraction of the overlying muscle due to electrical stimulation of 1 0 volt

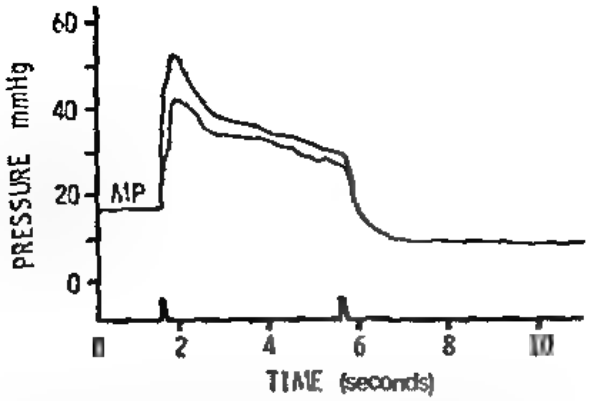

Figure 4 Trace showing the bone-marrow pressure (BMP) during contraction of the overlying muscle due to electrical stimulation of 3 0 volts

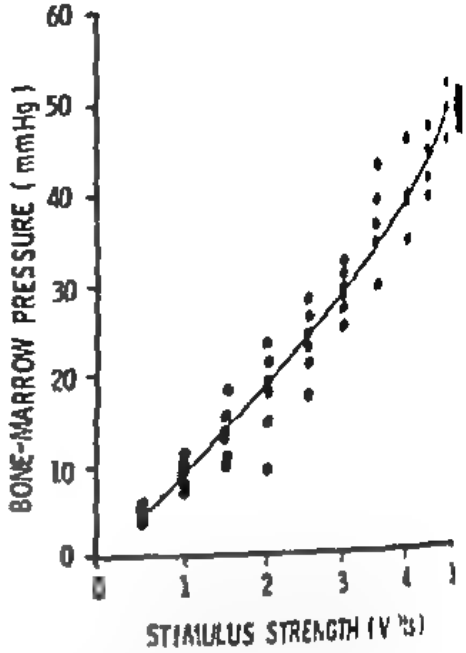

Figure 5 Graph showing femoral intra-medullary pressure with increasing stimulus strength

pressure ($r = 0\,98$, $P < 0\,001$) was found within the range of experimental setting (Figure 5)

DISCUSSION

Following their compression experiments on dried and defatted femora, Swanson & Freeman (1966) concluded that bones are not hydraulically strengthened The present study has shown that mere compression of bone, through either slow or fast loading, produced only small changes in the intra-medullary pressure and that the contraction of overlying muscles produced greater increases In life, excessive compression stress tends to cause bone fracture which can be resisted by the sudden and significant rise of marrow pressure caused by simultaneous contraction of the overlying muscles Elimination of this vital factor renders the conclusion of Swanson & Freeman (1966) unacceptable

The mechanism of rise of intra-medullary pressure during electrical stimulation of the cut distal end of the femoral nerve was compression and closure of the venous drainage channels from the bone when the overlying muscles were in a state of contraction The large magnitude of the rise in intra-medullary pressure [8 kPa (60 mmHg)] recorded in a small animal is thought considerable and suggested to provide hydraulic strengthening However, it is suggested that this factor is unlikely to be of major significance in normal stresses encountered in life U compression, on the other hand, when the intact bone is reaching its strength, the raised fluid pressure may an important role It is recognised that a tissue may not exhibit the

A vasoconstrictor function has attributed by Drinker & Drinker (1914) sympathetic fibres which richly innervate arterioles of bone marrow Constriction these arterioles produced either by elec stimulation or drugs results in reduced marrow blood flow and pressure (Herzig Root 1959, Azuma 1964, and McPherson Juhasz 1965) Stimulation of the cut end of the femoral nerve does not affect bone-marrow pressure or blood flow if traction of the overlying muscles is prev (Shaw 1963) It is, therefore clear that above observation, reported by Shaw (1 was due to lack of sympathetic activity the electrical stimulation employed current study was similar to that of S (1963), it is considered that the pressure changes observed were due occlusion (Herzig & Root 1959 Shaw Azuma 1964, and McPherson & Juhasz caused by muscle contraction. The were not influenced by sympathetic

y Indeed, sympathetic vasoconstrictor will only tend to diminish the tude of the pressure increase recorded ite of such a contradictory influence, was a large marrow pressure rise Thus, an safely suggest a greater hydraulic in in life as no sympathetic activity is d during voluntary contraction of es

results (Figures 3 and 4) show an diate rise in intra-medullary pressure on action of the quadriceps muscles This n marrow pressure was followed by a reduction during the remaining time for muscle contraction was sustained This ure reduction may result from the on of venous blood from the femur gh vascular openings around the femoral As the femoral nerve was cut at the of the inguinal ligament and the nerve ly to ilio-psoas and muscles in the region ie femoral neck arise proximal to this it is presumed that muscles in that area ined in a relaxed state in these exnents and did not exert any force to close venous channels It is possible that in a life situation a contraction of the ilios muscles, simultaneously with the iriceps group, would reduce the outflow ugh these channels, thereby enhancing hydraulic strengthening effect

lthough the present experiments sured intra-medullary pressure changes in femur, it has been shown by Yamamoto 5) Sabin & Doan (1927–1928), and Foa 3) that in spite of the diverse distribution he marrow in different bones in the body, behaviour and physiology is essentially ilar in all situations.

ith presently available techniques direct erimentation on vertebral bodies under *in o* conditions presents many problems. ough no experimental proof has been nished, it would appear reasonable for findings from the present study to be plied to the vertebrae This suggestion ns further support from the observations de by Batson (1940 1957) Willis (1949) l Smith & Stephens (1968)

Batson (1940, 1957) has shown large venous channels emerging from the vertebrae and entering the erector spinae muscles Willis (1949) has described very large venous foraminae emerging from the vertebral bodies Contraction of the erector spinae muscles would be expected to produce a considerable increase in the intra-medullary pressure within the vertebral bodies The large cross-sectional area of human vertebral bodies will tend to further magnify the effect of hydraulic support, when such a rise in pressure occurs

Smith & Stephen (1968) have shown that vertebral bodies compressed *in vitro* undergo considerable shortening, although no such shortening has been observed in life During trunk manoeuvres, when the muscles are actively contracting and the spine is simultaneously subjected to a large compression, the fluid content of the vertebral body will tend not to be allowed to escape Therefore, it is possible that these two stresses may have a cumulative effect on the pressure changes of spinal marrow

Davis (1956 and 1959), Bartelink (1957), and Morris et al (1961), suggested that a raised intra-abdominal pressure produced by a contraction of the abdominal wall muscles helps to relieve compression forces on the lumbar vertebra A rise in intra-abdominal pressure would tend to reduce venous outflow from the vertebral bodies, further reduction in outflow is likely when the overlying psoas muscles are in a stage of contraction Thus, it is suggested that anatomical characteristics and physiological patterns are conducive to and compatible with the hydraulic mechanism of strengthening of bones. Such a mechanism has a significant role in protecting bones under extreme stresses.

REFERENCES

Azuma H (1964) Intraosseous pressure as a measure of haemodynamic changes in bone marrow *Angiology* 15, 396–406

Bartelink, D L (1957) The role of abdominal pressure in relieving the pressure of the lumbar intervertebral discs. *J Bone Jt Surg* 39 B 718–725

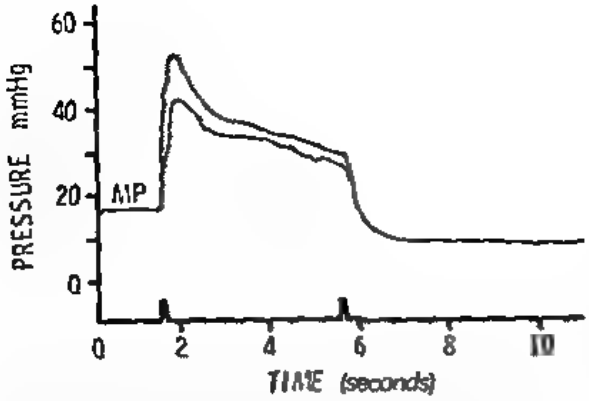

Figure 4 Trace showing the bone marrow pressure (BMP) during contraction of the overlying muscle due to electrical stimulation of 3 0 volts

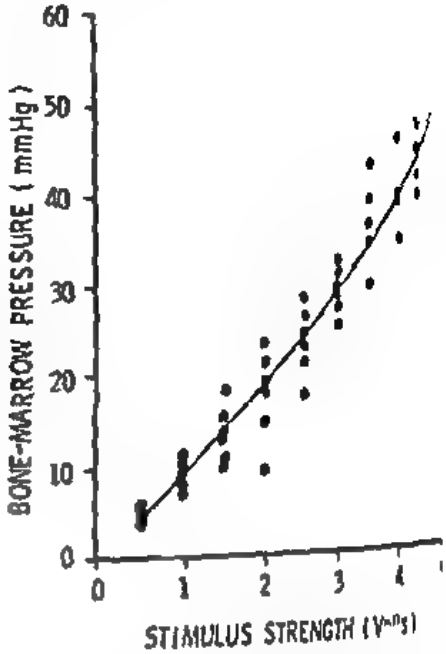

Figure 5 Graph showing femoral intra-medullary pressure with increasing stimulus strength

pressure ($r = 0.98$, $P < 0.001$) was found within the range of experimental setting (Figure 5)

DISCUSSION

Following their compression experiments on dried and defatted femora, Swanson & Freeman (1966) concluded that bones are not hydraulically strengthened The present study has shown that mere compression of bone, through either slow or fast loading, produced only small changes in the intra-medullary pressure and that the contraction of overlying muscles produced greater increases In life, excessive compression stress tends to cause bone fracture which can be resisted by the sudden and significant rise of marrow pressure caused by simultaneous contraction of the overlying muscles Elimination of this vital factor renders the conclusion of Swanson & Freeman (1966) unacceptable

The mechanism of rise of intra medullary pressure during electrical stimulation of the cut distal end of the femoral nerve was compression and closure of the venous drainage channels from the bone when the overlying muscles were in a state of contraction The large magnitude of the rise in intra medullary pressure [8 kPa (60 mmHg)] recorded in a small animal is thought considerable and suggested to provide hydraulic strengthening However, it is suggested that this factor is unlikely to be of major significance in normal stresses encountered in life Under ex compression, on the other hand when the intact bone is reaching its the strength, the raised fluid pressure m an important role It is recognised th as a tissue may not exhibit this pro

A vasoconstrictor function has attributed by Drinker & Drinker (1916 sympathetic fibres which richly inner arterioles of bone marrow Constric these arterioles produced either by el stimulation or drugs results in redu marrow blood flow and pressure (He Root 1959, Azuma 1964 and McPher Juhasz 1965) Stimulation of the cut end of the femoral nerve does not af bone-marrow pressure or blood flow traction of the overlying muscles is pr (Shaw 1963) It is, therefore clear th above observation reported by Shaw was due to lack of sympathetic activity the electrical stimulation employed current study was similar to that of (1963), it is considered that the pressure changes observed were due occlusion (Herzig & Root 1959 Azuma 1964, and McPherson & Juhas caused by muscle contraction. Th were not influenced by sympathe

thop scand 50 513–517, 1979

NOVIORTHESIS WITH RADIOACTIVE GOLD IN MOPHILIACS

ical and Radiological Follow-up

AHLBERG & HOLGER PETTERSSON

rtment of Orthopedic Surgery and Department of Diagnostic Radiology, o General Hospital, (University of Lund) Malmö, Sweden

Twenty-seven patients with hemophilia treated with intra articular injection of radioactive gold were followed up clinically and radiologically for 3 to 9 years after treatment To assess the radiological changes, a new classification was designed, with a score describing the severity of the

still reversible. If the treatment was begun at a later stage, the arthropathy seemed to progress independently of the effect on the bleeding frequency No negative effect of the radioactive gold was observed on the joint or the growing zone

Key words hemophilia, joint bleeding, radio-isotopes, synoviorthesis

Accepted 11 XII.78

patients with hemophilia repeated intra-icular hemorrhages or chronic synovitis y result in an arthropathy with typical hological changes of various degrees. One thod of treating synovitis and preventing urrences of bleeding is synoviorthesis with mical or radiological preparations (Ahlberg 71, Menkes et al 1975) Radioactive gold Au) has been used at the International mophilia Treatment Centre in Malmo ice 1968 The effect on synovitis and joint eding has been good (Ahlberg 1977) but long-term effect on the arthropathy is still known. The present investigation was rried out in order to study the influence of ra articular injection of ^{198}Au on the velopment of radiological changes in mophilic arthropathy

PATIENTS

During the period 1968–1978 65 hemophiliacs aged 2–46 years were treated by intra-articular injection of ^{198}Au in 97 joints (46 knees, 25 elbows, 20 ankle joints, 6 shoulder joints) because of chronic effusion and/or repeated intra articular bleeding which had not responded to conservative treatment (immobilization substitution therapy). Depending on the size of the joint, 2–5 mCi ^{198}Au in a colloidal solution with a particle size of [illegible] mμ was injected into the joint and the patient was immobilized for 1–2 days. Before the injection the level of A- or B factor was raised to 20 per cent (Ahlberg 1977). Out of this group all patients with a follow-up of 3 years or more, in whom a radiological examination of the joint had been performed less than 3 months prior to the gold injection, were included in this investigation. The material consisted of 14 children (16 joints) aged 2–15 years at the time of

1 64-0179 050513-05$02.50 0

© 1979 Munksgaard, Copenhagen

Table 1 Distribution of joints included in the study

	Children	Adults
Shoulder	0	2
Elbow	2	4
Knee	9	5
Ankle	5	3
Total	16	14

treatment and 13 adults (14 joints) aged 17–46 years (Table 1) Children were by definition, those in whom epiphyseal fusion had not occurred at the time of treatment Twenty-two patients had hemophilia A (17 severe and 5 moderate) four had hemophilia B (severe) and one von Willebrand s disease (severe) In three patients the administration of radioactive gold was repeated after 1–3 years and in two of these surgical synovectomy was performed 1 and 2 years after the first gold injection owing to the detrimental effect of the injections

METHODS

The patients were recalled for clinical investigation and radiological examination of the treated and contralateral joints The clinical effect of the administration of radioactive gold was assessed according to the frequency and severity of joint hemorrhages before and after the treatment

All available radiograms of the treated and the contralateral joints were reviewed covering a period of 1–15 (mean 5 2) years before and 3–9 (mean 5 6) years after the treatment To record radiological changes from one examination to the next, a classification was devised in which the changes were estimated as described in Table 2. At each examination the joint was given a total sum of points of 0–13 according to Table 2. This score expressed the severity of the radiological changes. The radiographs were also examined for the time and mode of epiphyseal fusion and skeletal growth A detailed description of the evaluation of the radiological findings will be published separately (Pettersson in preparation).

The course of development of the radiological changes before and after the treatment with radioactive gold was compared and correlated with the frequency of hemorrhages.

Table 2 Radiological classification of arthropathy

Radiological finding	P
Effusion	[illegible]
Soft tissue changes	[illegible]
Enlarged epiphysis	[illegible]
Osteoporosis	[illegible]
Irregular subchondral surface	[illegible]
Erosions at joint margins	[illegible]
Subchondral cyst formation	[illegible]
Narrowing of joint space	[illegible]
Incongruence of articular surfaces	[illegible]
Deformity (valgus, varus, rotation)	[illegible]
Possible score	[illegible]

RESULTS

The effect of the radioactive gold on synovitis and joint bleedings in this group patients agreed well with that described the total material (Ahlberg 1977). In 12/ no bleeding occurred after treatment in the frequency decreased markedly in f frequency decreased temporarily and there was no clinical improvement. T two patients were later synovectomized

Figure 1 illustrates the development joint score before and after injection of in all the joints studied Irrespective clinical effect of the treatment the progression of the radiological changes was affected if the joint had a score of points or more at the time of administration of the radioactive gold (Figure 2). In the of four joints with a score of two p less at the time of treatment no f bleeding occurred and in the fourth frequency markedly diminished In all joints there was no progression of the logical changes during the follow-up treatment No difference between children and adults was noted in these respects

Acceleration or retardation of epiphyseal fusion or dysplastic skeletal growth was noted in any case

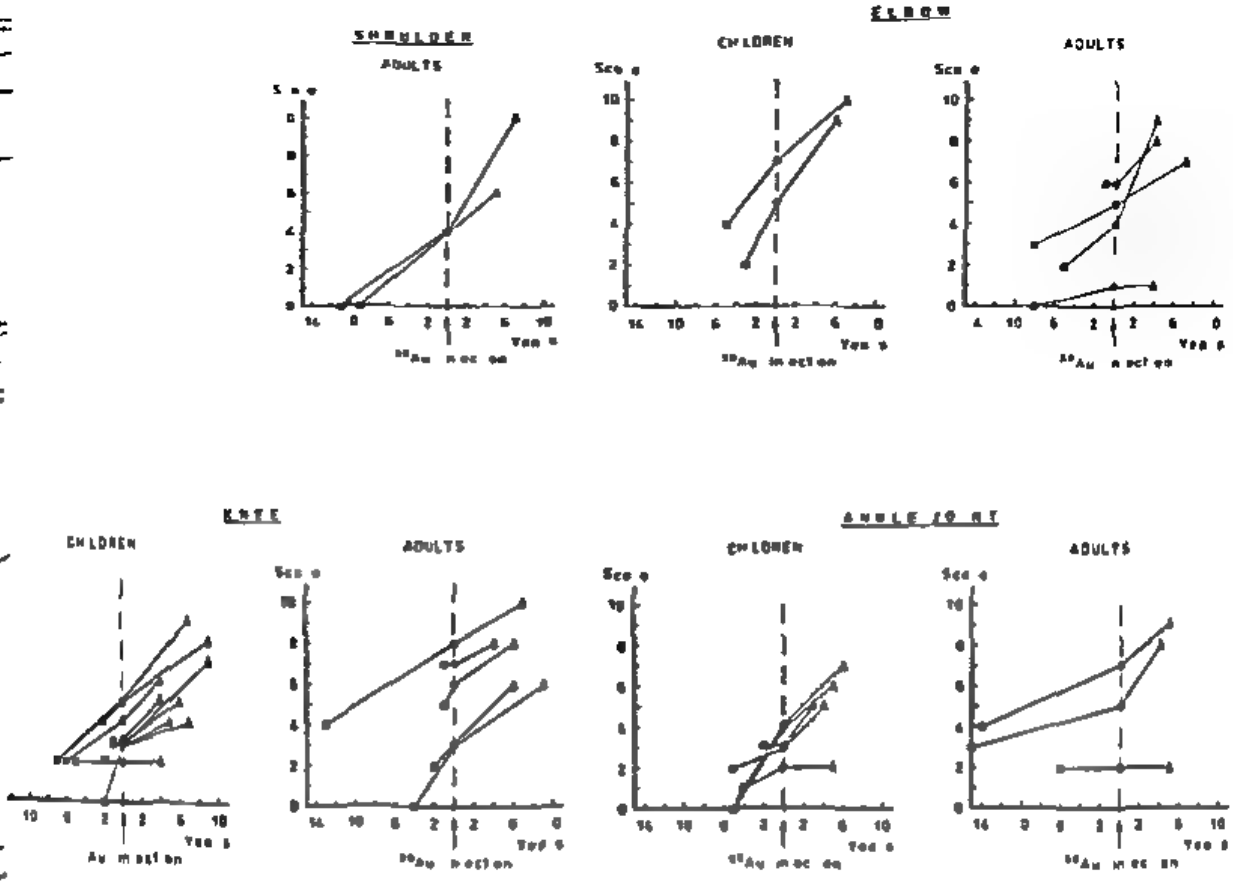

Figure 1 Development of joint score before and after injection of ^{198}Au

;CUSSION

modern prophylaxis and treatment of ophilia, radiology may be one objective hod to assess the efficacy of the treatment the arthropathy In this assessment, small nges occurring between two examinations the same joint may be important Various thods for classification of the arthropathy e been described (De Palma & Cotler 6, Jordan 1958, Ahlberg 1967, Wood et al. 9, Arnold & Hilgartner 1977) In several ients in the present study, however, these thods proved to be insufficient to record progression of the radiologically revealed hropathy, and for that reason a new classific- was designed (Table 2)

All the changes used in this classification, which are well known in the literature of hemophilic arthropathy, were given 0–2 points. The changes are listed in the order they occur chronologically Effusion in the joint was given 0 points, since it may reflect only an acute stage of hemorrhage and not the more chronic consequences of the bleeding Soft tissue changes were also given 0 points for the same reason and also owing to the varying technical quality of the radiograms which do not always allow an assessment of the soft tissues. The rest of the findings gave a maximal score of 13 points per joint, making it possible to register even small changes from one examination to another

(a) (b

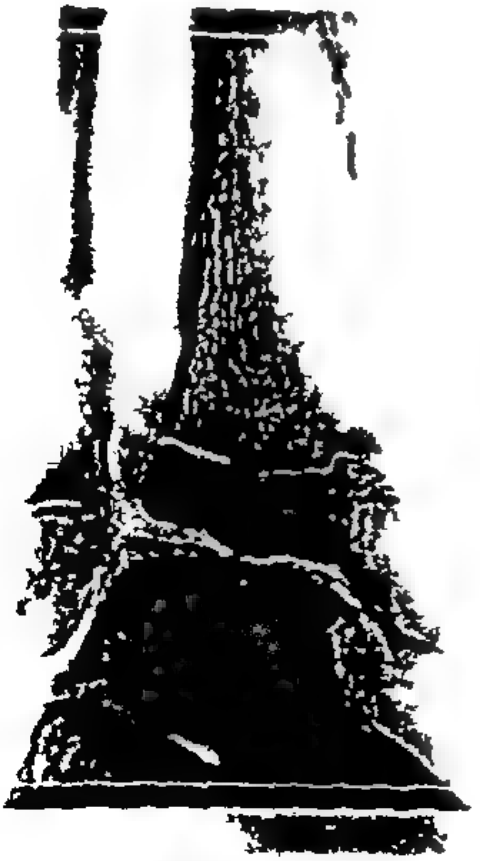

Figure 2 Progress of rad ological ch
good effect on joint bleed ng
a Five years before treatment ge 3
Score 0
b Immediately before treatment ge 3
epiphysis (compared with contralat
point Osteoporosis (compared w
side) 1 point Irregular subchond
point Narrowing of jo nt space 1 po
points
c Six years after treatment ge 14
epiphysis 1 po nt Osteoporosis 1 po
subchondral surface 2 points
space 2 points Subchondral cyst
point Score 7 points

the patients with a score of two or less treatment the effect was good not only on ritis and bleeding but also on the radiolly revealed changes, which did not ress. In all patients with a score of three ore at treatment there was progression of radiological changes in spite of the often effect on the bleeding frequency This is greement with the findings by Nilsson et 1976) who studied a group of children had been given prophylactic treatment AHF infusions In their series the rity of children with unaffected joints at onset of treatment also had intact joints 2–13 years of prophylaxis. In another p of children with partly destroyed joints e onset of the prophylaxis, the joint desion continued despite the prophylaxis.

fthough the pathophysiology underlying ophilic arthropathy is not fully known, it is that there exists an early stage with rsible changes, characterized by synovial tion, and a late irreversible stage of llage degeneration as well as joint ruction resembling both rheumatoid ritis and osteoarthritis (van Creveld et al. I, Arnold & Hilgartner 1977) From the sent study it seems that the late stage is only irreversible but also progressive and this progression occurs irrespective of her bleeding into the joints.

Thus, synoviorthesis with radioactive gold, probably also other methods used to imize the frequency of hemarthroses, uld be performed as early as possible in the course of the arthropathy in order to prevent the development of irreversible changes.

REFERENCES

Ahlberg, Å (1967) Treatment and prophylaxes of arthropathy in severe hemophilia. *Clin Orthop* 53, 135–146

Ahlberg, Å (1971) Radioactive gold in the treatment of chronic synovial effusion in hemophilia. *Proc VII Cong of the World Federation of Haemophilia*, Teheran, pp 212–215 Excerpta Medica, Amsterdam

Ahlberg, Å (1977) Synoviorthèse avec l or radioactif dans l'hemophilie. *Rev Rhum* 44, 41–44

Arnold, W D & Hilgartner, M W (1977) Hemophilic arthropathy *J Bone Jt Surg* 59-A 287–305

van Creveld, S, Hoedemaeker, P J, Kingma, M J & Wagenvoort, C A. (1971) Degeneration of joints in haemophiliacs under treatment by modern methods. *J Bone Jt Surg* 53-B, 296–302.

De Palma, A F & Cotler, J M (1956) Hemophilic arthropathy *Clin Orthop* 8, 163

Jordan, H H (1958) *Hemophilic arthropathies* Charles C Thomas, Springfield, Illinois.

Menkes C J, Simon, F, Broutart J P & Delbarre, F (1975) Le traitement des arthropathies hémophiliques par la synoviorthès médicale *Path Biol* 23, (Suppl.) 28–32.

Nilsson, I M, Hedner, U & Ahlberg A. (1976) Haemophilia prophylaxis in Sweden. *Acta paediat scand* 65, 129–135

Wood R, Omer, A. & Shaw, M T (1969) Haemophilic arthropathy *Brit J Radiol* 42, 498

respondence to Dr Åke Ahlberg, Department of Orthopedic Surgery, Malmo General Hospital S-01 Malmo Sweden.

thop scand 50, 519–525 1979

ATIONSHIPS BETWEEN OXYGEN AND CARBON DIOXIDE NSIONS AND ACID-BASE BALANCE IN ARTERIAL BLOOD D IN MEDULLARY BLOOD FROM LONG BONES IN DOGS

EN ERIKSEN ERIK TØNDEVOLD ERIK JANSEN & JENS ERIK PETERSEN

rtment of Orthopaedic Surgery T-2 and Department of Anaesthesiology, Gentofte Hospital, Hellerup, Department of Anaesthesiology, Herlev Hospital, Herlev, Denmark

By means of an invasive technique the relations between arterial and medullary gas tensions (PO_2 and PCO_2), and arterial and medullary acid base balance (pH and standard bicarbonate) were determined in long bones in seven anaesthetized dogs.

A semilogarithmic correlation was found between the arterial oxygen tension and the oxygen tension in the medullary blood Between the arterial carbon dioxide tension and the medullary blood carbon dioxide tension a linear correlation was demonstrated A linear correlation was also found between arterial pH and standard bicarbonate values and the corresponding values obtained from medullary blood.

With regard to the parameters investigated no difference was demonstrated between epiphyseal, metaphyseal or diaphyseal medullary blood

Key words aetiology, blood supply, bone, femur head, osteoarthritis, physiology, regional blood flow

Accepted 8 11.79

asurements of long bone medullary oxygen sion (PO_2), carbon dioxide tension (PCO_2) l acid-base balance most often are made medullary blood taken from bones suffer- from some pathological condition oodhouse 1962, Brookes & Helal 1968, ookes 1971, Pujol et al 1973) Only in the dy of Pujol et al (1973) is information en about the corresponding arterial values. The purpose of the present investigation s to determine the normal correlations ween arterial and long bone medullary gas sions and acid-base balance in the iesthetized dog

ATERIAL AND METHODS

en mongrel dogs weighing 29–42 kg were used the experiment. All dogs were more than 2 years old. The dogs were all premedicated with propionylpromazin (Combilen®) and anaesthesia was induced with thiopenthal given intravenously After oro-tracheal intubation anaesthesia was maintained with halothane-N_2O-O_2 Muscle relaxation was provided by intermittent doses of pancuronium bromide Ventilation was performed with a Servo®-900 ventilator

Arterial blood pressure was continuously measured from the right brachial artery on an Ellab monitor using a Statham P 23Db transducer

carotid artery and left external jugular vein and, after heparinization (300 i.u./kg body weight)

continuously monitored.

1 64-0/79 050519–07$02.50 0

© 1979 Munksgaard, Copenhagen

hop scand 50 519–525 1979

ATIONSHIPS BETWEEN OXYGEN AND CARBON DIOXIDE ISIONS AND ACID-BASE BALANCE IN ARTERIAL BLOOD) IN MEDULLARY BLOOD FROM LONG BONES IN DOGS

EN ERIKSEN ERIK TØNDEVOLD ERIK JANSEN & JENS ERIK PETERSEN

tment of Orthopaedic Surgery T-2 and Department of Anaesthesiology, Gentofte Hospital, Hellerup, epartment of Anaesthesiology, Herlev Hospital, Herlev, Denmark

By means of an invasive technique the relations between arterial and medullary gas tensions (PO_2 and PCO_2), and arterial and medullary acid-base balance (pH and standard bicarbonate) were determined in long bones in seven anaesthetized dogs.

A semilogarithmic correlation was found between the arterial oxygen tension and the oxygen tension in the medullary blood Between the arterial carbon dioxide tension and the medullary blood carbon dioxide tension a linear correlation was demonstrated. A linear correlation was also found between arterial pH and standard bicarbonate values and the corresponding values obtained from medullary blood

With regard to the parameters investigated no difference was demonstrated between epiphyseal, metaphyseal or diaphyseal medullary blood

Key words aetiology, blood supply, bone, femur head, osteoarthritis, physiology, regional blood flow

Accepted 8 ii 79

isurements of long bone medullary oxygen ion (PO_2), carbon dioxide tension (PCO_2) acid-base balance most often are made medullary blood taken from bones suffer- from some pathological condition odhouse 1962, Brookes & Helal 1968, okes 1971, Pujol et al 1973) Only in the ly of Pujol et al (1973) is information en about the corresponding arterial values. he purpose of the present investigation s to determine the normal correlations ween arterial and long bone medullary gas sions and acid-base balance in the esthetized dog

ATERIAL AND METHODS

en mongrel dogs weighing 29–42 kg were used the experiment. All dogs were more than 2 years old The dogs were all premedicated with propionylpromazin (Combilen®), and anaesthesia was induced with thiopenthal given intravenously After oro-tracheal intubation anaesthesia was maintained with halothane-N_2O-O_2 Muscle relaxation was provided by intermittent doses of pancuronium bromide Ventilation was performed with a Servo®-900 ventilator

Arterial blood pressure was continuously measured from the right brachial artery on an Ellab monitor using a Statham P 23Db transducer

Arterial oxygen tension (PaO_2), arterial carbon dioxide tension ($PaCO_2$) and pH were monitored continuously using an artificial arterial venous shunt. This was prepared by cannulating the right carotid artery and left external jugular vein and, after heparinization (300 I.U./kg body weight), pumping the output of the carotid artery through a special blood gas cuvette (Henningsen 1968) back into the external jugular vein.

Electrocardiogram and rectal temperature were continuously monitored.

1-6470/79 050519 07$02 50 0

© 1979 Munksgaard, Copenhagen

Metal cannulas with a diameter of 2 mm were introduced into the bone marrow of the left femoral epiphysis, the right femoral metaphysis and the right humeral diaphysis. A 1 8 mm drill was used to penetrate the cortex Correct positioning of the cannula tips in the middle of the bone marrow was ensured by X-ray examination.

PO_2, PCO_2 pH and standard bicarbonate were determined on a Radiometer ABL 1 blood gas analyser One ml samples drawn anaerobically by slight aspiration of arterial blood from the brachial artery and of medullary blood from the femoral epiphysis, metaphysis and the humeral diaphysis were investigated

arterial PO_2 PCO_2 and pH remained constant samples were at the same time drawn from the arterial catheter and the bone marrow cannulas. Hereafter, with a constant $PaCO_2$ (40 mmHg) FiO_2 was varied and samples were drawn at various values of PaO_2

After termination of this part of the study PaO_2 was kept constant at about 100 mmHg, and $PaCO_2$ was varied

Hypercapnia was obtained by the addition of CO_2 to the inspired gas mixture Hypocapnia was obtained by hyperventilation Samples were drawn at various values of $PaCO_2$

Equilibration periods of at least 10 minutes were used prior to every sampling

Statistics and calculations Least squares regression lines were calculated. Correlation

regressions and for differences between *epiphyseal, metaphyseal* and *diaphyseal* values at the various arterial values was taken as $P < 0\ 05$ Calculations of hyperbolas indicating 95 per cent confidence limits around the regression lines were done by means of the formula $s_y =$

$$1\ 984 \times s_{(x\ y)} \times \sqrt{1 + \frac{1}{n} + \frac{(x-x)^2}{\Sigma(x-x)^2}}$$

(Snedecor 1956) $s_{(x\ y)}$ = sample standard deviation of the regression coefficient n = number of correlative samples, x = mean values of abscissa values.

RESULTS

The correlations between corresponding values of PO_2, PCO_2, pH and standard bicarbonate in medullary and arterial are shown in Table 1 and Figures 1-4 of the regression lines was drawn on of at least 89 measurements. Only obtained when mean arterial blood was above 70 mmHg have been used f calculations.

No differences could be between blood samples obtained epiphyseal, metaphyseal or diaphyseal The shaded areas on the figures indicate widest 95 per cent confidence limits

Oxygen tensions (Figure 1). When oxygen tensions were below changes in PaO_2 caused almost changes in medullary oxygen this level, however, only small increases seen in medullary oxygen tensions as oxygen tensions increased In this study varied between 26 and 492 mmHg medullary PO_2 between 22 and 135 The best fit of correlation seemed

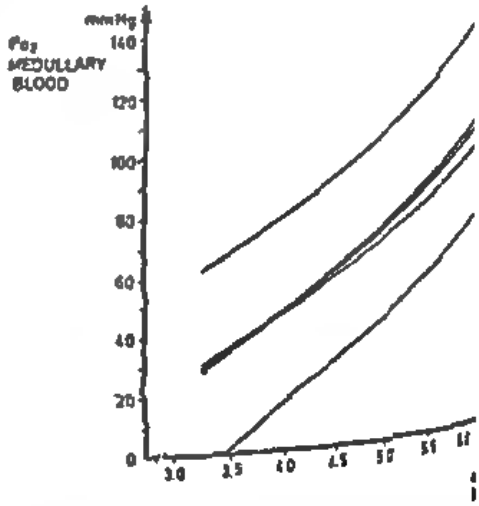

Figure 1 Least square regressions of m epiphyseal (I), metaphyseal (II) and di (III) PO_2 in relation to natural logar arterial PO_2 (PaO_2) Shaded area indicat broadest 95 per cent confidence limits
I $P_{epiphysis}O_2 = 21\ 53\ \ln PaO_2 - 39\ 65$ r = P < 0 001
II $P_{metaphysis}O_2 - 24\ 35\ \ln PaO_2 - 49\ 80$ r = P < 0 001
III $P_{diaphysis}O_2 - 26\ 00\ \ln PaO_2 - 57\ 94$ r P < 0 001

confidence limits (s_y), number of correlative samples (n), correlation coefficient (r) [illegible]

Regression equation	Equation for hyperbola indicating 95 % confidence limits (s_y)	Number of correlative samples (n)	Correlation coefficient (r)	Significance of correlation coefficient
$P_{epiphysis}O_2 = 21.53 \ln PaO_2 - 39.65$	$\pm 21.60 \sqrt{1.01 + \frac{(x - 4.85)^2}{31.27}}$	92	0.76	$P < 0.001$
$P_{metaphysis}O_2 = 24.35 \ln PaO_2 - 49.80$	$\pm 25.73 \sqrt{1.01 + \frac{(x - 4.85)^2}{31.27}}$	92	0.74	$P < 0.001$
$P_{diaphysis}O_2 = 26.00 \ln PaO_2 - 57.94$	$\pm 31.65 \sqrt{1.01 + \frac{(x - 4.85)^2}{31.27}}$	92	0.69	$P < 0.001$
$P_{epiphysis}CO_2 = -0.87 PaCO_2 + 7.39$	$\pm 9.34 \sqrt{1.01 + \frac{(x - 37.38)^2}{304711936}}$	90	0.94	$P < 0.001$
$P_{metaphysis}CO_2 = 0.97 PaCO_2 + 4.21$	$\pm 7.59 \sqrt{1.01 + \frac{(x - 37.17)^2}{212226624}}$	89	0.96	$P < 0.001$
$P_{diaphysis}CO_2 = 0.92 PaCO_2 + 6.12$	$\pm 9.17 \sqrt{1.01 + \frac{(x - 37.27)^2}{172633321}}$	90	0.95	$P < 0.001$
$pH_{epiphysis} = 0.764 pH_a + 1.673$	$\pm 0.361 \sqrt{1.01 + \frac{(x - 7.27)^2}{0.931225}}$	91	0.88	$P < 0.001$
$pH_{metaphysis} = 0.812 pH_a + 1.329$	$\pm 0.310 \sqrt{1.01 + \frac{(x - 7.27)^2}{0.931225}}$	91	0.78	$P < 0.001$
$pH_{diaphysis} = 0.887 pH_a + 0.771$	$\pm 0.186 \sqrt{1.01 + \frac{(x - 7.27)^2}{0.931225}}$	91	0.95	$P < 0.001$
$st\ bic._{epi} = 0.56\ st\ bic._a + 6.34$	$\pm 4.15 \sqrt{1.01 + \frac{(x - 16.54)^2}{202476}}$	90	0.56	$P < 0.001$
$st\ bic = 0.43\ st\ bic._a + 9.01$	$\pm 4.73 \sqrt{1.01 + \frac{(x - 16.53)^2}{198878}}$	90	0.40	$P < 0.001$
$st\ bic._{dia} = 0.52\ st\ bic._a + 7.12$	$\pm 4.33 \sqrt{1.01 + \frac{(x - 16.51)^2}{208332}}$	90	0.53	$P < 0.001$

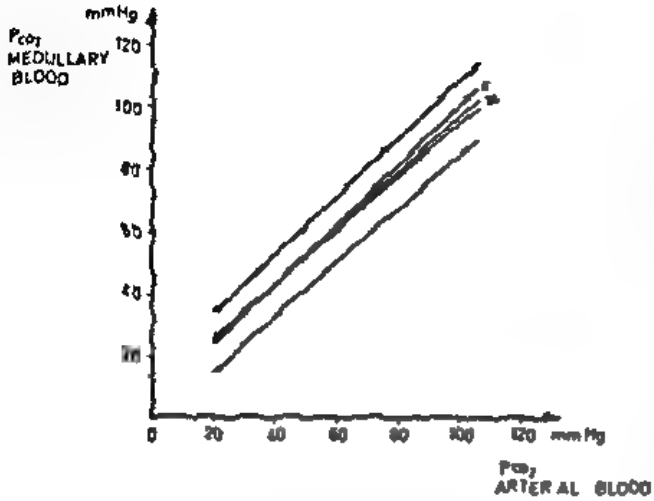

Figure 2 Least squares regressions of medullary epiphyseal (I), metaphyseal (II) and diaphyseal (III) PCO_2 in relation to arterial PCO_2 ($PaCO_2$) Shaded area indicates the broadest 95 per cent confidence limits

I $P_{ep\ physis}CO_2 = 0\ 87\ \ PaCO_2 + 7\ 39,\ \ r = 0\ 91,$ $P < 0\ 001$

II $P_{metaphysis}CO_2 = 0\ 97\ PaCO_2 + 4\ 21,\ r = 0\ 96,$ $P < 0\ 001$

III $P_{d\ aphysis}CO_2 = 0\ 92\ PaCO_2 + 6\ 12,\ r = 0\ 95,$ $P < 0\ 001$

semilogarithmic, mean correla (r) was 0 73 ($P < 0\ 001$)

Carbon dioxide tensions (Figure 2) correlations were found between PCO_2 and $PaCO_2$, mean correlation (r) = 0 95 ($P < 0\ 001$) $PaCO_2$ varied between 20 and 103 mmHg Medullary PCO_2 between 20 and 102 mmHg

pH (Figure 3) Linear correlations mean correlation coefficient (r) of ($P < 0\ 001$) were found between arterial and medullary blood The arterial pH was 6 92–7 41 The medullary pH values was 6 88–7 43.

Standard bicarbonate (Figure 4) T of correlation seemed to be with a mean correlation coefficient (r) ($P < 0\ 001$) The arterial standard bi varied in the study between 20 mmol/l

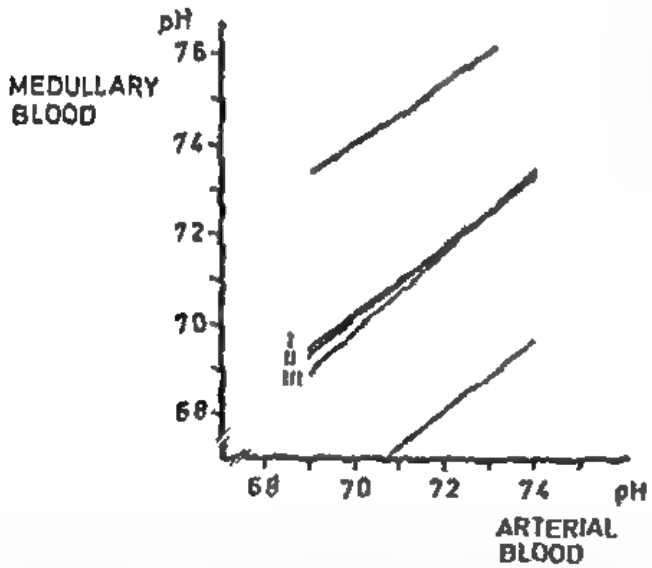

Figure 3 Least square regressions of medullary epiphyseal (I), metaphyseal (II) and diaphyseal (III) pH in relation to arterial pH (pH_a) Shaded area indicates the broadest 95 per cent confidence limits

I $pH_{ep\ physis} = 0\ 764\ \ pH_a + 1\ 673$ $r = 0\ 88$ $P < 0\ 001$

II $pH_{metaphysis} = 0\ 812\ \ pH_a + 1\ 329,$ $r = 0\ 78,$ $P < 0\ 001$

III $pH_{d\ aphysis} = 0\ 887\ \ pH_a + 0\ 771$ $r = 0\ 95,$ $P < 0\ 001$

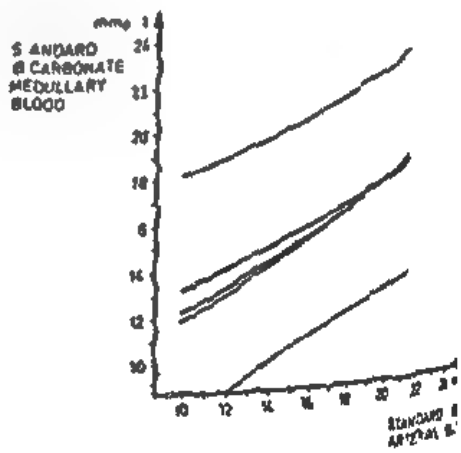

Figure 4 Least square regressions of m

limits

I $st\ bic_{ep\ physis} = 0\ 56\ \ st\ bic_a + 6\ 31$

$P < 0\ 001$

II $st\ bic_{metaphysis} = 0\ 43\ st\ bic_a + 9\ 01$

$P < 0\ 001$

III $st\ bic_{d\ aphysis} = 0\ 52\ st\ bic_a + 7\ 1$

$P < 0\ 001$

:JSSION

.us study we have determined the ›nships between PO_2 PCO_2, pH and .ird bicarbonate in arterial blood and in .lary blood taken from three different in long bones the epiphysis the ›hysis and the diaphysis With regard to arameters tested no differences in com- on were found between the three types ;dullary blood

e vascular arrangement in long bones been studied in detail by Trueta & ison (1953), Brånemark (1959) Trueta & gan (1960) and Brookes (1971) The blood ies the bone marrow through an afferent y In the bone marrow long wide sinusoids • up a functional lattice in which osteo- ic cells are distributed, and in which and gas exchange between blood and ›unding tissues takes place From the siods the blood flows through collecting ies back into hte systemic circulation.

e do believe that the samples of illary blood we have investigated in this y represent sinusoidal blood, but we are aware that this could be a matter of ute The perforating technique used to in the samples is rather traumatic to the m and consequently, around the cannula some of the normal vascular and bony :tures may have been destroyed. hermore, the tip of the cannula might • been placed near either a predominantly nal or venous end of the sinusoid ›ever, because of the large number of ples investigated most of these sources of r have been overcome and we believe the measured PO_2 PCO_2 pH and idard bicarbonate values are repre- :ative of the milieu in which osteoblastic s are situated.

ne amount of oxygen available for lullary metabolism depends on medullary ›d flow rate and arterial oxygen content. : rate of medullary flow was not in tigated in this study and some of the in- ›ogeneity characterizing our results might be explained by an unstable flow rate A decreased flow with an unchanged oxygen consumption will lead to an increased o ›en extraction from the blood flowing through the area and vice versa a relation which earlier had been proposed as a way of estimating the medullary flow (Ingebrigsten et al 1963)

We did not find any significant difference between simultaneously measured oxygen tensions in epiphyseal, metaphyseal or diaphyseal medullary blood. Brookes (1965, 1967) has found decreased blood flow in epiphyseal zones, using an isotope technique for flow estimation Our technique cannot reject this hypothesis.

With the exception of the work of Pujol et al (1973), most information about human medullary oxygen tensions are given without details concerning simultaneously measured arterial oxygen tensions (Woodhouse 1962, Brookes & Helal 1968) Furthermore, all samples in these studies have been drawn from bones suffering from some pathological condition Assuming a normal arterial oxygen tension of about 100 mmHg and assuming that our results of animal experiments could be transferred directly to humans most measurements of oxygen tension in human medullary blood given in the literature would lie within our 95 per cent confidence limits

Linear correlations with narrow 95 per cent confidence limits were also found between arterial and medullary carbon dioxide tensions. A raised PCO_2 in bone marrow stimulates osteoblastic differentiation and promotes calcification, both essential aspects of bone production (Richards & Brookes 1969) From other studies too, it is known that active osteogenesis is dependent on an increased PCO_2 (Wilmer 1965) The highest medullary PCO_2 values have been found in impacted fractures of the femoral neck in which a PCO_2 of 77 mmHg has been measured (Brookes & Helal 1968)

Anaesthesia induced hypoventilation with a grave acidosis could not induce changes in medullary PCO_2 to that extent

The medullary pH values are difficult to

interpret Changes in medullary pH could be due to changes in medullary PCO_2 and/or to variations in local metabolism An increased anaerobic glycolysis because of either reduced medullary flow or reduced oxygen content in medullary blood, or both, will contribute to changes in pH However, as good correlations were seen to arterial pH, medullary pH values will also depend on arterial PCO_2 and systemic metabolism

Alkaline drift and especially an elevated pH are found when cancellous bone is formed, whereas a reduced pH is supposed to be the local stimulus for cells possessing osteogenic potency, hereby provoking an increased calcification (Brookes 1971)

Standard bicarbonate is the bicarbonate concentration of fully oxygenated blood at 38° Celsius when the PCO_2 has been adjusted to 40 mmHg (Astrup et al 1960) By adjusting the PCO_2 to 40 mmHg, alterations in bicarbonate in blood secondary to changes in PCO_2 disappear and the standard bicarbonate therefore exclusively describes metabolic acid base changes The correlations found between arterial and medullary standard bicarbonate values were not as good as for the other parameters tested even if a mean correlation coefficient (r) of 0 50 and $P < 0.001$ was seen Some of the scatter round the regression line could be explained by variations in local pH giving large variations in the standard bicarbonate concentration Arterial values in this study indicate a metabolic acidosis During the investigation the dogs were treated with saline intravenoulsy which dilutes plasma bicarbonate and results in a dilutional acidosis Low haemoglobin values too will change standard bicarbonate (Siggaard-Andersen 1963)

In presenting our results no attention has been paid to variations in blood pressure as long as this parameter lay within the normal range Variations in local blood flow were measured Our results are obtained d circumstances simul the ditions during wh could be taken given in this study represent a tool for investigations, primarily of a

In this study close correlations were between simultaneously measured tensions and acid base balance in medullary blood from long bones in the No significant differences in these could be demonstrated in samples the same time from three different long bones the epiphysis, the metaph the diaphysis

Information about gas tensions and base balance in medullary blood should be given without information about responding arterial values.

ACKNOWLEDGEMENTS

The authors are grateful to L Mohr B Sv B Holm M Kjærumgaard and Robert E for their technical assistance

REFERENCES

Astrup P Andersen O S Jørgensen Engel K (1960) The acid-base metabo new approach *Lancet* 1 1035–1039

Brånemark P J (1959) Vital microscope marrow in rabbit *Scand J clin. Lab* Suppl 38

Brookes, M (1965) Red cell volumes and patterns in long bones. *Acta anat.* 35–52.

Brookes M (1967) Blood flow rates in and cancellous bone and bone mar *Anat (Lond)* 101 533–541

Brookes, M & Helal B (1968) teoarthritis, venous engorgement teogenesis *J Bone Jt Surg* 50-B 49

Brookes, M (1971) *The blood supply of* 6 290 297–301 Butterworth & Co London

Henningsen, P (1968) Continuous meas of PO_2 PCO_2 and pH in blood. *Scand* *Lab Invest* 22 33–36

Ingebrigtsen R Krog J & Lerand, S Circulation distal to arteriovenous fis the extremities. A polarographic study *scand* 125 308–317

Tran M A. & Arlet J (1973) d une étude gazométrique d hanténen dans les coxopathies 5–519

..s, D J & Brookes, M (1969) Physico-
nical sequelae of experimental osteotomy
roy Soc Med 62, 435–438
or, G W (1956) *Statistical methods* Fifth
ion pp 138–139 The Iowa State College
Ames, Iowa.
d Andersen, O (1963) Blood acid base
ment nomogram. *Scand J clin Lab*
st 15, 211–217
, J & Harrison, M H M (1953) The
normal vascular anatomy of the femoral head
in adult man *J Bone Jt Surg* 35-B, 442–461
Trueta, J & Morgan, J D (1960) The vascular
contribution to osteogenesis I Studies by the
injection method. *J Bone Jt Surg* 42-B,
447–454
Wilmer, E N (1965) *Cells and tissues in culture,*
Vol I Academic Press, London.
Woodhouse, C. F (1962) Anoxia of the femoral
head *Surgery* 52, 55–63

pondence to Erik Tøndevold, M D, Department of Orthopaedic Surgery T-2 Gentofte Hospital,
00 Hellerup Denmark.

op. scand 50 527–531, 1979

:RVATIONS ON LONG BONE MEDULLARY PRESSURE IN \TION TO MEAN ARTERIAL BLOOD PRESSURE IN THE :STHETIZED DOG

ØNDEVOLD JØRGEN ERIKSEN & ERIK JANSEN

nent of Orthopaedic Surgery T-2 and Department of Anaesthesiology, Gentofte Hospital, Hellerup, partment of Anaesthesiology, Herlev Hospital, Herlev, Denmark

To study the influence of variations in mean arterial pressures (MAP) on long bone medullary pressures, seven anaesthetized dogs were investigated The medullary pressures were measured in the epiphyseal, the metaphyseal and the diaphyseal regions and remained rather constant when MAP was above 80 mmHg Below this level of MAP a statistically significant ($P < 0.01$) reduction of the medullary pressures was seen Comparing the mean medullary pressures obtained with ranges of MAP of 81–100 mmHg (the control medullary pressures) and of 61–80 mmHg, the [illegible]

measured by our technique were between 20–30 mmHg and this is in accordance with measurements in normal humans found by other authors.

Key words aetiology, blood supply, bone, femur head, osteoarthritis physiology, regional blood flow

Accepted 8 11.79

bone medullary pressure is an indirect ssion of the medullary blood flow A low llary pressure means a low blood flow high medullary pressure is related to an ased blood flow or an intraosseous con- on of blood due to obstruction of the us outflow (*Shaw 1963, Azuma 1964,* 1968) The influence of venous obstruc- on the medullary pressure in long bones been described under both normal and ological conditions (Stein et al 1957, & Kelly 1965, Arnoldi et al 1972)

ne purpose of this study was to in- gate the influence of variations in the al blood pressure on the epiphyseal, iphyseal and diaphyseal medullary sures in long bones in the anaesthetized

MATERIAL AND METHODS

Seven mongrel dogs, weight 29–42 kg, and all above 2 years of age were investigated Anaesthesia, technique and some of the monitoring equipment have previously been described (Eriksen et al 1979) For continuous measurements of arterial blood pressure a catheter was placed in the left brachial artery Central venous pressure was measured in the superior caval vein via a catheter introduced into the left brachial vein Recording of arterial and central venous pressures were done using an Ellab M5-BCM amplifier and a Statham P 23Db transducer

The medullary pressures were measured through metal cannulas (diameter 2 mm) placed with their tips centrally in the bone marrow of the left femoral epiphysis, the right femoral metaphysis and the right humeral diaphysis. To penetrate the bone cortex, drilling was necessary and a 1 8 mm drill was used for this purpose No

6470/79/050527–05$02.50

© 1979 Munksgaard, Copenhagen

leakage of medullary blood was seen when the metal cannulas were placed in the bones. The correct positioning of the cannulas was confirmed by X-ray. Simonsen & Weel AE 840 transducers and Simonsen & Weel BAP 001 amplifiers were used for the continuous recording of the medullary pressures.

Using different levels of halothane anaesthesia and different intravenous loading with saline, variations in the arterial blood pressure were accomplished. Equilibration periods of at least 10 minutes during which the mean arterial pressure (MAP) remained constant were used before sampling of data. Registration of the medullary pressure in epiphyseal, metaphyseal and diaphyseal regions were performed at different levels of MAP. During the study the arterial oxygen tension and the arterial carbon dioxide tension were maintained at normal levels and monitored using a continuous blood gas analyser (Henningsen 1968).

All medullary pressures given are medullary perfusion pressures, i.e. the measured medullary pressure minus the central venous pressure. This correction has been made because of the obvious influence of venous stasis on the magnitude of medullary pressures in long bones (Shaw 1963, Keck & Kelly 1965).

In presenting our results various ranges of MAP have been chosen: <61 mmHg, 61–80 mmHg, 81–100 mmHg, 101–120 mmHg and >120 mmHg. Within these ranges both the values ± s.e. mean of MAP and the values ± s.e. mean of the corresponding pressures in the epiphyseal, the metaphyseal and the diaphyseal regions have been calculated.

The Mann-Whitney rank sum test for data has been used for the statistical analysis of the results obtained. The level of significance of differences was chosen as $P < 0.05$.

RESULTS

Table 1 summarizes the results of our [illegible] and Figures 1, 2 and 3 show the epiphyseal, metaphyseal and diaphyseal medullary pressure variations in relation to the different ranges of MAP. Within the normal range of MAP (81–100 mmHg) the corresponding medullary pressures were the control pressures.

Looking at the ranges of MAP above 80 mmHg medullary pressures in the respective regions were rather [illegible] with mean epiphyseal medullary pressures of 25.2–30.7 mmHg, mean metaphyseal pressures of 18.9–20.5 mmHg and diaphyseal pressures of 24.3–26.7 mmHg. However, with a range of MAP

Table 1. [illegible] anaesthetized [illegible] mean of MAP [illegible] have been calculated [illegible] normal range of [illegible]

(81–100 mmHg)

Number of observations	Mean arterial pressure (MAP) (mmHg) Range	Mean ± s.e. mean within the range	Medullary pressures (P) (mmHg) $P_{epiphysis}$ Mean ± s.e. mean	$P_{metaphysis}$ Mean ± s.e. mean	$P_{diaphysis}$ Mean ± s.e. mean
14	61	47.1 ± 3.9	5.9 ± 1.0 xxx	8.3 ± 1.0 xxx	8.1 ± 1.1 xx
14	61–80	72.9 ± 1.3	8.1 ± 1.8 xxx	10.9 ± 1.0 xxx	8.3 ± 1.3 xx
18	81–100 (normal range)	95.3 ± 1.2	25.2 ± 3.5 (control medullary pressures)	18.9 ± 2.0	26.7 ± 3.3
29	101–120	112.9 ± 0.9	30.7 ± 2.6 +++	20.5 ± 1.5	25.7 ± 1
17	120	135.3 ± 3.9	23.2 ± 3.5	17.5 ± 1.5	24.3 ± 2.9

Within the respective medullary regions xxx $P < 0.01$ indicates statistical significance of differences [illegible] control medullary pressures.

Within the respective ranges of MAP + $P < 0.005$ and +++ $P < 0.01$ indicate statistical significance of difference of metaphyseal medullary pressure from epiphyseal or diaphyseal medullary pressure.

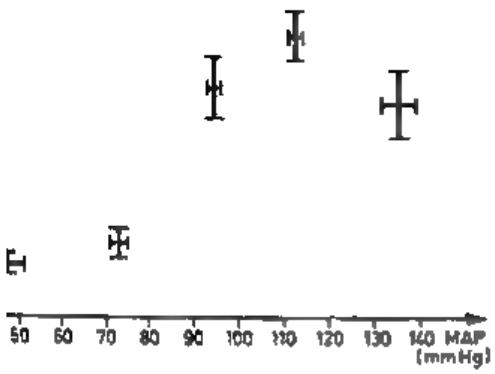

Figure 1 Long bone epiphyseal medullary pressures ($P_{epiphysis}$) in relation to the mean arterial blood pressure (MAP) Mean values ± s e mean of the epiphyseal medullary pressures obtained within different ranges of MAP (<61, 61–80, 81–100, 101–120, and >120 mmHg) are shown in relation to the mean values ± s e mean of MAP within these ranges

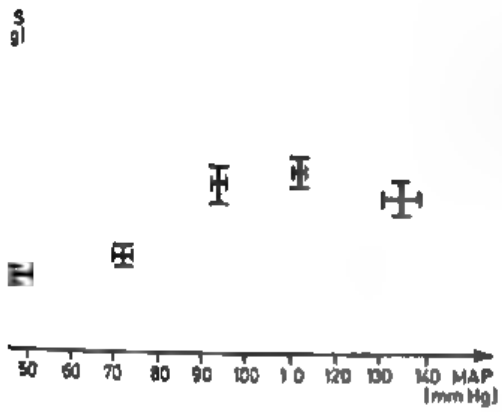

Figure 2 Long bone metaphyseal medullary pressures ($P_{metaphysis}$) in relation to the mean arterial blood pressure (MAP) Mean values ± s e mean of the metaphyseal medullary pressures obtained within different ranges of MAP (<61, 61–80, 81–100, 101 120, and >120 mmHg) are shown in relation to the mean values ± s e mean of MAP within these ranges

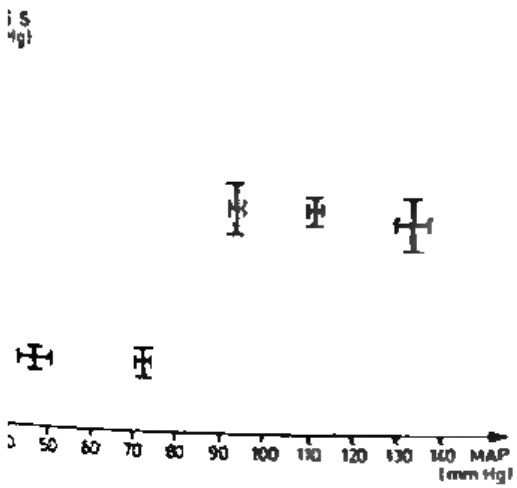

Figure 3 Long bone diaphyseal medullary pressures ($P_{diaphysis}$) in relation to the mean arterial blood pressure (MAP) Mean values ± s e mean of the diaphyseal medullary pressures obtained within different ranges of MAP (<61, 61–80, 81–100, 101–120, and >120 mmHg) are shown in relation to the mean values ± s e mean of MAP within these ranges

61–80 mmHg a significant ($P < 0.01$) reduction of the medullary pressures in all three regions was seen Comparing the mean medullary pressures with a range of MAP of 81–100 mmHg the greatest decline was seen in the epiphyseal and the diaphyseal regions, from 25.2 mmHg to 8.1 mmHg and from 26.7 mmHg to 8.3 mmHg, respectively The corresponding decrease in the metaphyseal region was from 18.9 mmHg to 10.9 mmHg

When MAP was between 101 and 120 mmHg the mean metaphyseal medullary pressure (20.5 mmHg) was significantly lower than both the mean epiphyseal medullary pressure (30.7 mmHg) and the mean diaphyseal medullary pressure (25.7 mmHg) By contrast, with a range of MAP of 61–80 mmHg the mean metaphyseal medullary pressure (10.9 mmHg) was significantly higher than the mean epiphyseal medullary pressure (8.1 mmHg) Apart from this no significant differences were observed between mean epiphyseal metaphyseal or diaphyseal pressures within the various ranges of MAP

DISCUSSION

From this study performed on anaesthetized dogs it seems that long bone medullary pressures exhibit a great constancy and are independent of arterial blood pressures as long as the MAP remains above 81 mmHg Below an MAP of 81 mmHg a significant lowering of the medullary pressures is seen This relation could be demonstrated in the epiphyseal the metaphyseal and the diaphyseal regions.

The medullary pressures found at levels of MAP above 81 mmHg correlate well with medullary pressures obtained from the proximal femur in humans (Arlet et al 1972)

The pressures measured by means of metal cannulas introduced into the bone marrow are probably in their origin a mixture of pressures, and provoked by the pulsations in small arteries arterioles and capillaries, due to the fact that these structures are by a stiff, non-elastic cortical bone & Shim 1970) For normal medullary tissues to be maintained various physiologic conditions, one expect the presence of some sort of r mechanism, which within wide lim would secure a stable and tramedullary pressure. If no such re mechanism were present increasing pressures might result pressures and hereby gradually a pression of the medullary tissue.

As mentioned earlier long bone pressures give an indirect expres medullary blood flow rate (Arima 19 1968) In most tissues, muscles abov blood flow rate is controlled in proper the need for nutrition oxygen in pa (Stainsby 1973) The regulation of flow rate seems to occur locally by a influence of oxygen (Guyton et al. 1 local blood flow regulatory mechan rather sensitive to external factors, normal resting conditions is F sufficient to maintain stable relationships within the bone ma However, during variations in the blood pressure the local re mechanism might be insufficient to a of 15 per cent (Guyton et al Drinker & Drinker (1916) have that the arterioles of the bone marr supplied with sympathetic nerve fibres vasoconstrictor function In most tissue autonomic nervous system is not inv local blood flow regulation during function of circulation but provid increased effectiveness of control under conditions such as exercise or haem (Granger & Guyton 1969) A specific fo of the sympathetic vasoconstrictor fibres supplying the medullary arteri till now not been described but perhaps are involved in an active mechanism which prevents a high pressure during increases in arterial pressure

ſsignificant lowering of the medullary - s seen at mean arterial pressures ſl mmHg ■ probably the result of the attempt to maintain sufficient blood the most vital organs, such as heart ſin, and caused by mobilization of both ſ and hormonal blood flow and blood ſe control mechanisms

ſ our results it seems that a rather ſt epiphyseal, metaphyseal, and ſeal medullary pressure is maintained nal or above normal ranges of MAP ſer, decreases of MAP to levels below Hg cause great pressure falls within ſe marrow of long bones Probably low ſry pressures mean insufficient ſry blood flow and subsequently in- ſnt oxygenation and potential necrosis. ſy the observations made in the present ſnay give a clue as to the cause of some ſaedic conditions in which an ſthic" necrosis is involved

ſOWLEDGEMENTS

ſthors are grateful to L Mohr, ■ Saurbrey, ſn and M Kjærumgaard for their technical ſice

ſRENCES

ſ, Ficat P & Sebbay, D (1968) Intérêt de ſesure de la pression intra médullaire dans ſmassif trochanterien chez l'homme en ſiculier pour le diagnostic de l ostéonécrose ſoro-capitale. *Rev Rhum* ■ 250–256

Arlet, J, Ficat, P, Lartique, G & Tran M A (1972) Recherches cliniques sur la pression intra-osseuse dans la metaphyse et l'epiphyse fémorales supérieures chez l'homme *Rev Rhum* 11, 717–723

Arnoldi, C C, Linderholm, H & Mussbichler, H (1972) Venous engorgement and intraosseous hypertension in osteoarthritis of the hip *J Bone Jt Surg* 54-B, 409–421

Azuma, H (1964) Intraosseous pressure as a measure of hemodynamic changes in bone marrow *Angiology* 15, 396–406

Drinker, C K. & Drinker, K R (1916) A method for maintaining an artificial circulation through the tibia of the dog, with a demonstration of the vasomotor control of the marrow vessels *Amer J Physiol* 40, 514–521

Eriksen, J, Tøndevold, E, Jansen, E & Pedersen J E (1979) Relationships between oxygen and carbon dioxide tensions and acid-base balance in arterial blood and in medullary blood from long bones in dogs *Acta orthop scand* 50,

Granger, H J ■ Guyton, A C (1969) Autoregulation of the total systemic circulation following destruction of the central nervous system in the dog *Circulat Res* 25, 379–388

Guyton A. C, Coleman, G & Granger, J (1972) Circulation Overall regulation. *Ann Rev Physiol* 34, 13–46

Hawk, H E & Shim, S S (1970) The nature of the intramedullary pressure of bone *Surg Forum* 21, 475–477

Henningsen P (1968) Continuous measurement of PO_2, PCO_2 and pH in blood *Scand J clin Lab Invest* 22, 33–36

Keck, S W & Kelly, P J (1965) The effects of venous stasis on intraosseous pressure and longitudinal bone growth in the dog *J Bone Jt Surg* 47-A, 539–544

Shaw N E (1963) Observations on the intramedullary blood flow and marrow pressure in bone *Clin Sci* 24 311–318

Shim, ■ S (1968) Physiology of blood circulation of bone *J Bone Jt Surg* 50-A, 812–824

Stainsby, W N (1973) Local control of regional bloodflow *Ann Rev Physiol* 35, 151–168

Stein, A H., Morgan, H C. & Reynolds, F C (1957) Variations in normal bone-medullary pressure *J Bone Jt Surg* 39 A, 1129–1134

ſpondence ■ Erik Tøndevold, M ■ Department of Orthopaedic Surgery T 2, Genofte Hospital, DK ſellerup, Denmark

op scand 50, 533–535

ICAL AND CHEMICAL INVESTIGATION OF FREE IES IN ARTICULAR OSTEOCHONDROMATOSIS

TÉR G LÉNÁRT & G RISCHÁK

lweis University, Department of Orthopaedics, National Geological Survey, st, Hungary

Physical and chemical analysis of the newly formed calcified bodies in articular osteochondromatosis was carried out X-ray diffraction showed

Key words articular osteochondromatosis, crystallography, derivatography, carbonate apatite, Francolite, Dahllite

Accepted 20 xi 78

ular osteochondromatosis was first bed by Ambrois Paré (Pontiville et al and the symptoms and pathology of this e are well known However, no ive physical and chemical analysis of ewly formed calcified bodies was found available literature In the following, a t with this disease will be described case is of interest because the removed ied bodies were investigated both cally and chemically

IENT AND METHODS

a male aged 53 years, was admitted to our rtment because of stiffness and pains in both X-ray examination revealed severe osteodromatosis of both knees. A synovectomy performed on the right, and later on the left and the loose osteocartilaginous bodies, ly filling the joint cavity, were removed

e removed calcified bodies were carefully ed from the soft tissues, lyophilized, and then nd to 0 5–1 00 mm grain size The fat was cted with fine petrol and the dry specimen ground again in 325 mesh fineness. With nentation in alcohol the smallest and the est parts were eliminated, and the remainder l and rehomogenized in an agate mortar before ys.

e following methods and instruments were to clarify the crystallographic structure of the bodies

X ray diffraction analysis Instrument used Mueller Mikro 111 diffractometer

Infrared spectroscopy Instrument used MOM Spektromom Type 2000 rock salt prism IR spectrophotometer

Chemical analysis This analysis corresponded to that used generally in wet chemical analysis of sedimentary rocks containing organic matter

Thermal analysis Instrument used MOM Derivatograph.

RESULTS

X-ray diffraction (Figure 1) This revealed that the investigated sample was a carbonate apatite from the group Francolite-Dahllite. It can be assumed that the sample investigated was an intermediary member of the isomorphous substitution series.

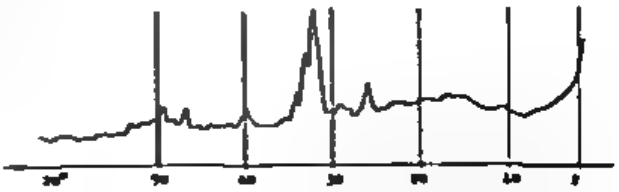

Figure 1 X-ray diffractogramme of the free bodies in articular osteochondromatosis The pattern shows a rather typical crystallized apatite variant

-6470/79/050533-03$02.50.0

c 1979 Munksgaard Copenhagen

Infrared spectroscopy A well distinguished peak and a joining shoulder could be observed showing an unstable energetic arrangement (Figure 2)

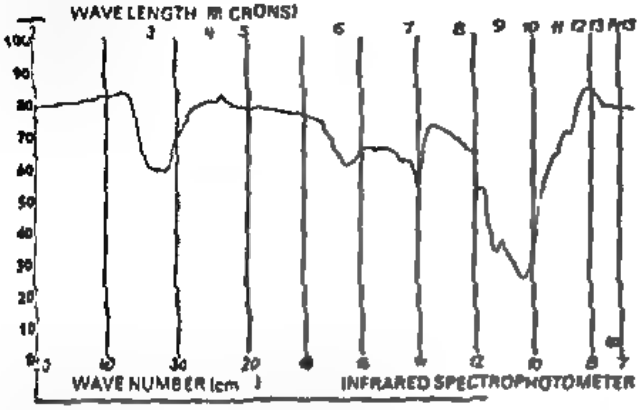

Figure 2 Infrared spectrum of the free bodies in articular osteochondromatosis showing an unstable energetic arrangement

Chemical analysis The compounds found in the wet chemical analysis are presented in Table 1 CaO and P_2O_5 seemed to be the major constituents, several minor elements were however also found

Table 1 Wet chemical analysis of free bodies in articular osteochondromatosis

	Per cent
SiO_2	0 29
TiO_2	0 00
Al_2O_3	0 60
Fe_2O_3	0 083
MnO	0 06
MgO	tr
CaO	37 37
Na_2O	1 16
K_2O	0 06
P_2O_5	26 62
F	2 22
Cl	0 08
H_2O/–/120C°	5 60
Ignition loss from this	26 60
CO_2	3 66
Organic C	9 23
O loss	–0 95
Sum total	99 793

Differential thermal analysis (Figure 3) This showed that the inherent water found at the chemical analysis originated partly from the decomposition of the organic m remaining in the sample, partly fr water content of the crystal structure

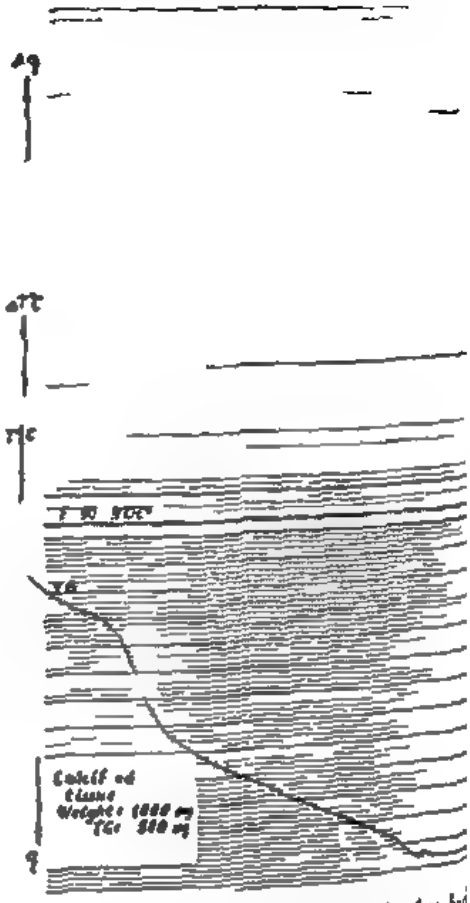

Figure 3 Derivatogramme of the free bo articular osteochondromatosis showing a uniform weight loss, so the first derivat TG curve could help in the determinati water content of the crystal structure

DISCUSSION

The X-ray diffraction pattern fits ver with that described by McConell (1960 for Dahllite and Francolite On the ba the high fluorine content the specimen be attributed to the Francolites which c a large quantity of fluorine If ho McConell's crystallochemical calculatio carried out, a crystallochemical form be derived which does not equal Dahllite or Francolite but is interm between them The crystallochem cal fo of the carbonate apatite of the calcified investigated based on this calculation follows

$Na_{0.5}H_3O_{0.4}C_{0.12}K_{0.018}Mn_{0.01})$
$_{0.97})(F_{1.57}OH_{0.4}Cl_{0.03})$

ust also take into consideration in a
:ated case like this the existence of
crystals. This would not be in contra-
to the concept described above, it
even mean according to Keppler (1969)
ution of the whole carbonate apatite
n The crystal chemistry of the mixed
, however, is for the time being
m

RENCES

, P G & Nash, J T (1968) Compositional, infrared and X-ray analysis of fossil bone *Amer Mineral* 53, 445–455

Hoffman, V & Trdlicka, Z (1967) Uber ein Carbonat Apatit (Francolith) von Kutná Hora *Acta Univ Carolinae Geol* 3, 195–202

Keppler, H (1969) Carbonat-Apatit als anomaler Mischkristall *N Jahrbuch f Mineral* 8, 343–349

McConell, D (1938) A structural investigation of the isomorphism of the apatite group *Amer Mineral* 23, 1–19

McConell D (1960) The crystal chemistry of *Dahllite Amer Mineral 45, 209–216*

Pontiville M Piganiol, G , Camuset, P , Horiot, J C & Dinglinger, H (1965) Les formes radiologiques de l osteochondromatose articulaire *Ann Radiol* 8, 339–351

ondence to Dr J Pinter, Semmelweis University, Department of Orthopaedics Budapest, a ut 27 II 1113 Hungary

iop scand 50, 537 546 1979

ODELLING AFTER DISTAL FOREARM FRACTURES 'HILDREN

Effect of Residual Angulation on the Spatial Orientation of the Epiphyseal

I FRIBERG

ment of Orthopaedic Surgery, University of Umeå, Sweden

The effect of residual fracture angulation on the distal radial and ulnar epiphyseal plates was studied in children aged 1 to 15 years. Thirty-eight fractures located in the distal fifth of the forearm bones were observed for 1 to 25 months after the fractures had healed The forearms were examined radiographically on two to five occasions and the inclinations of the epiphyseal plates in relation to the long axis of the proximal fragments were measured

The results showed that an abnormal inclination of the epiphyseal plate after healing of a distal forearm fracture induced an alteration of growth in the epiphyseal plate The redistribution of growth tended to correct the abnormal inclination The rate of correction followed an exponential course

The age of the child at the time of the fracture and the distance from the fracture to the epiphyseal plate did not influence the capacity for correction

Key words child, epiphyses, forearm, fracture, growth, remodelling

Accepted 3 iii 79

mechanisms behind the remodelling 'ess after fractures are still not clarified main reports have focused on the correc- of angulation at the fracture site (Konig 3, Önne & Sandblom 1949, Attenborough 3, Ghandi et al 1962, Miyagi & rayama 1964, Lanzi 1965, Bennek & inert 1966, Grewe & Niemann 1966, inemann 1969, Spissak et al. 1969, Swaan Oppers 1971, Hansen et al 1976, gstrom et al 1976). Very little attention been paid to the possible role of the physeal plate in the remodelling process. inert (1966) suggested, but without icrete evidence, that the epiphyseal plate ght be of importance Pauwels (1975) observed a normalization of the inclination of the subcapital epiphysis of the femur in a case with a subtrochanteric fracture which had healed with angulation. However, the first consistent evidence was given by Ryöppy & Karaharju (1974), who showed in an experimental study in rats that the epiphyseal plates changed their direction of growth after fractures uniting with residual angulation

In the present study the contribution of the epiphyseal plate to the remodelling process was investigated in more detail The most common fracture in the child, i e. the distal forearm fracture (Ghandi et al. 1962, Ehalt 1961, Wong 1965), was chosen The aim was to study the effects of residual angulation in

1 6470 79 050537–10$02.50.0

© 1979 Munksgaard, Copenhagen

healed fractures on the spatial orientation of the distal epiphyseal plates of the radius and ulna

MATERIAL AND METHODS

Repeated radiography of 38 wrists and forearms was performed in 37 children with residual angulation after healing of fractures in the distal fifth of the forearm The patients were selected from all cases of distal forearm fractures in children treated at the Department of Orthopaedic Surgery in Umeå during the years 1970–73 The selection was made so as to obtain a representative series with regard to different ages, degrees of residual angulation and directions of residual malposition The radiographs at the time of healing of the fracture (removal of plaster) were used as a basis for the evaluation. Both wrists of the patients were then re-examined radiographically on one to four occasions The change in inclination of the distal radial epiphyseal plate was measured in the lateral (dorso-volar plane) and frontal (radio-ulnar plane) projections. The distal ulnar epiphyseal plate was studied in the lateral (dorso-volar plane) projection Further details of the characteristics of the [illegible] given in Table 1

Radiographic technique at re-examination

The fractured and contralateral [illegible] examined on a skull table (film-focus 70 cm) When possible, the arm was [illegible] with 90° abduction in the humeroscap[illegible] and the elbow joint flexed 90° (Morn[illegible] 1968). The frontal and lateral proje[illegible] achieved by pronation and supination [illegible] forearm

In the radiographic examinations [illegible] with a difference in rotation of 10 degre[illegible] were accepted for the study ([illegible] Lundström 1977) No correction for [illegible] rotation was made as a rotational differe[illegible] degrees will introduce an error of less [illegible] degrees for an angulation of the ep[illegible] of 30 degrees.

Measuring technique

The inclinations of the distal radial [illegible] epiphyseal plates in relation to the [illegible] the distal third of the proximal fragme[illegible] measured on superimposed drawings

Table 1 Distribution in the series of the variables used for the statistical analysis of the results and standard deviations are given where not otherwise stated Ranges in brackets

	Angulations in the radius, dorso-volar plane		Angulations in the radius radio-ulnar plane		Angulations in the ulna dorso-volar plane	
No of examinations	No of fractures	Observation time months	No of fractures	Observation time months	No of fractures	[illegible]
1	36		14		7	5 5
2	36	6 4 ± 4 5	14	5 0 ± 3 6	7	1 1
3	17	11 5 ± 4 8	5	7 8 ± 4 0	3	
4	5	15 6 ± 5 9	2	6 5 ± 0 7	-	
5	2	16 5 ± 0 7	1	16	-	
Totals	96		36		17	
Age at fracture, years	9 4 ± 3 6 (1 15)		9 8 ± 3 3 (3 14)		7 1 ± 3 1 (3-10)	
Sex, no of boys/girls	25/11		12/2		4/3	
Side, no of right/left	19/17		7/7		4/3	
Primary angulation of the epiphyseal plate degrees	14 2 ± 8 3		10 1 ± 4 7		14 1 ± 7 9	
Type of fracture	No		No		No	
Torus	11		2		1	
Greenstick	10		2		3	
Complete	15		10		4	
Treatment plaster of paris	No		No		No	
+ No reposition	18		2		2	
1 reposition	13		7		3	
>1 reposition	4		3		2	
Op reduction	1		2		0	
Distance of fracture from the epiphyseal plate in per cent of total diaphyseal length	11 ± 5		11 ± 5		11 ± 7	

phs. Furthermore when possible, the inal growth produced by the epiphyseal assessed The prerequisite for adequate ments was that the inner borders of the vere used as reference points as the outer of the cortex in most instances were by new bone formation and resorption clination of the epiphyseal plate in the d wrist was expressed as the angle the epiphyseal plates in the fractured and contralateral wrists (Friberg & Lundstrom Figures 1 and 2) In the bilateral case an f 90 degrees between the epiphyseal plate central axis of the distal third of the bone osen to represent the normal inclination der to ascertain if there occurred any major ion of the angulations of the fractures of idius, the shortest distances from the nts of the epiphyseal plates to the central f the proximal fracture fragment were

total error of the measuring procedure was ted by repeated measurements and was 1 2 s + s d = 0 4 degrees for the inclinations of iphyseal plates and 0 9 millimetres ± s.d = illimetres for the longitudinal growth at the seal plates.

tics

means and standard deviations are given differences between group means were ed by the z and t tests. Standard computer ams (BMD02R) were used for the regression s. The influence was not considered to be cant with $P > 0.05$

RESULTS

General findings

With few exceptions the distal epiphyseal plates of both the radius and the ulna were found to alter their inclinations in relation to the long axis of the bones. No tendency to correction of the inclination of the epiphyseal plate was found in five fractures of the radius with minimal primary angulations (mean 4°, range 2°–7°) Without exception, changes in inclination tended towards normalization of the spatial orientation of the epiphyseal plates *(Figures 1, 2 and 3)*

No reduction in the shortest distance between the midpoints of the epiphyseal plates and the central axis of the proximal fracture fragments occurred This showed that the alternation in the inclination of the epiphyseal plates was not due to a correction of the angulation in the fracture

Capacity for correction of abnormal inclinations of the epiphyseal line expressed as a function of time

Mean correction expressed as degrees/month

The mean correction at the radial epiphyseal

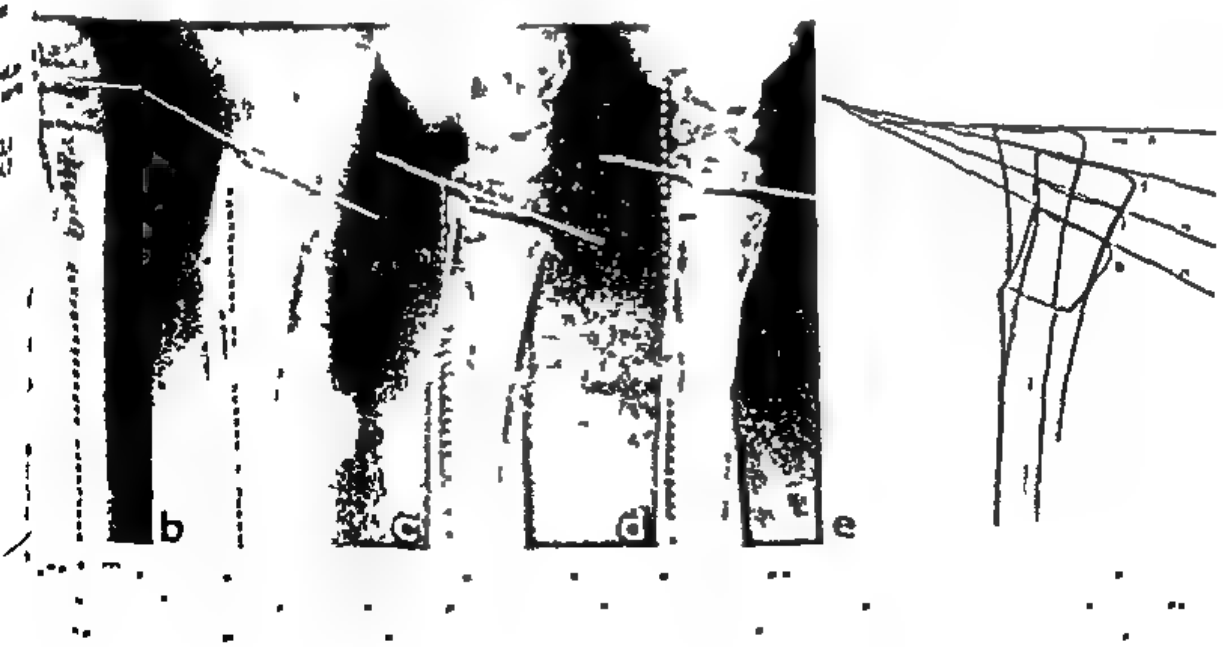

ing of (a) – (d)



Figure 2 The chan[illegible]

drawing of (a)–(d)

plate was calculated to be 0 9 degrees/month (60 observations) in the dorso-volar plane and 0 8 degrees/month (22 obs) in the radio-ulnar plane The ulnar epiphyseal plate showed a correction of 0 8 degrees/month (10 obs) in the dorso-volar plane (Table 2) No differences existed between the two different projections of the radius or between the radius and the ulna

When the material was divided [illegible] with regard to the residual angulat[illegible] healing (0°–4°, 5°–14°, > 15°), it w[illegible] that the rate of correction was h[illegible] groups with larger primary ang[illegible] (Table 2) Furthermore, the shape [illegible] graphic curves suggested a tendenc[illegible] reduction in the rate of correct[illegible] normalization proceeded (Figure 3).

Table 2 Capacity for correction of the epiphyseal line inclination expressed in degrees, mont[illegible] and s d are given

	RADIUS		ULNA
	Dorso-volar plane	Radio-ulnar plane	Dorso-volar
All observations	0.91 ± 0.57 60 obs. (36 cases)	0 80 ± 0 31 22 obs. (14 cases)	0.82 ± 0 43 10 obs (7
Primary angulation 0° - 14°	0 25 ± 0.28 4 obs. (4 cases) (**)	-	
Primary angulation 5° - 14°	0.75 ± 0.56 30 obs. (18 cases) (***)	0.74 ± 0.28 18 obs. (13 cases)	0 68 ± 0 37 8 obs (5 c
Primary angulation ≥15	1.18 ± 0.47 26 obs. (14 cases)	1.08 ± 0.29 4 obs. (1 cases)	1.36 ± 0 08 2 obs (2 c

The statistical significance of differences between the groups with differ[illegible] primary angulations in the dorso-volar plane of the radius was tested ag[illegible] group with primary angulations of 5° - 14° and is indicated by asterisks [illegible] table ** 0.01 > P > 0 001, *** = P < 0.001.

Capacity for correction of the epiphyseal line inclination expressed as β (CPC) Means and s d are given

	RADIUS		ULNA
	Dorso-volar plane	Radio-ulnar plane	Dorso-volar plane
bservations	0.087 ± 0.058 60 obs. (36 cases)	0.112 ± 0.041 22 obs. (14 cases)	0.101 ± 0 046 10 obs. (7 cases)
ary angula- 0° - 4°	0.072 + 0.083 4 obs. (4 cases)	-	-
ary angula- 5° - 14°	0.095 ± 0.070 30 obs (18 cases)	0.119 ± 0.037 18 obs. (13 cases)	0.101 ± 0.043 [illegible] obs (5 cases)
ary angula- ≥15°	0.074 ± 0.029 26 obs (14 cases)	0 077 ± 0.041 4 obs (1 cases)	0 101 ± 0.051 2 obs (2 cases)

atistically significant differences were found between the groups with differe ry angulations in the dorso-volar plane of the radius.

matical analysis of the correction ity The observations mentioned above sted that the process followed an ex- itial course In order to test this hesis the following exponential equation designed to describe the correction

$$V_0 \exp(-\beta C) \quad \text{where} \quad \beta = \frac{\ln (V_0/V_1)}{C}$$

ividual correction factor, C=other s, e g time, growth, V_0= angulation of piphyseal plate at the first observation correction, V_1 = angulation of the yseal plate after correction during the C

e exponential expression can be lated into a constant percentage correc- (CPC) of the residual angulation

ample Calculation of correction to be ted in a case with a 30-degree inclina- of the epiphyseal plate after healing of a ure Hypothetical value of β=0 105, month

30° exp (−0 105 × 1) V_1 = 30° × 0 90 27, correction = 3° during the first h.

Percentage correction = 10 per cent/month A correction of 10 per cent a month the residual angulation will give during the following month 2 7° of correction (V_1 = 27° exp (−0 105 × 1), V = 24 3°)

Mean correction expressed as constant percentage correction/month The mean CPC capacity found at the distal radial epiphyseal plate was 9 per cent/month in the dorso-volar plane and 11 per cent/month in the radio-ulnar plane A mean value of 11 per cent/month was found for the distal ulnar epiphyseal plate The corresponding values for β are illustrated in Table 3 An analysis of the CPC capacities in the dorso-volar plane of the radius showed no differences between the groups with different primary angulations

When all observations were considered, the CPC capacities found at the distal radial epiphyseal plate were similar to those found at the distal ulnar epiphyseal plate The CPC values for angulations of the distal epiphyseal plate of the radius were 0 082 ± 0 059 (53 obs.) in the dorsal direction, 0 136 ± 0 050 (7 obs.) in the volar direction, [illegible] 105 ± 0 037 (17

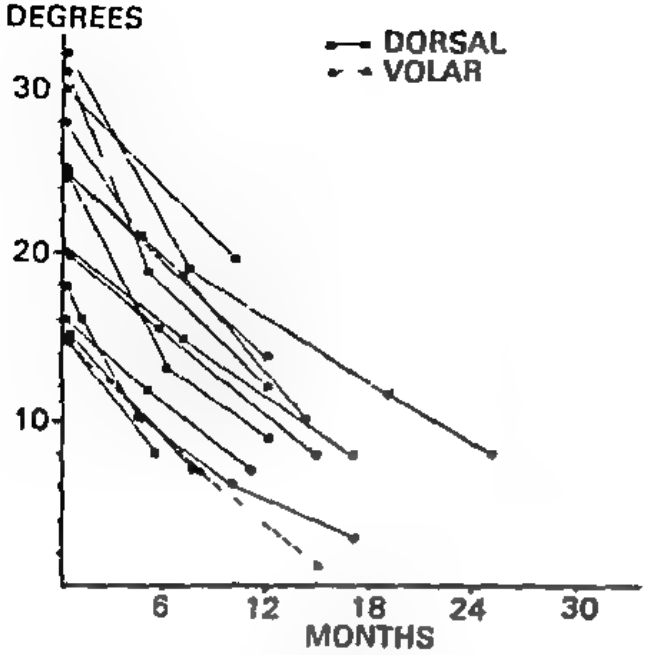

Figure 3 The spontaneous change in inclination of the epiphyseal plates found in the dorso-volar plane of the radius in cases with more than 14 degrees of primary angulation The different directions of angulation are illustrated

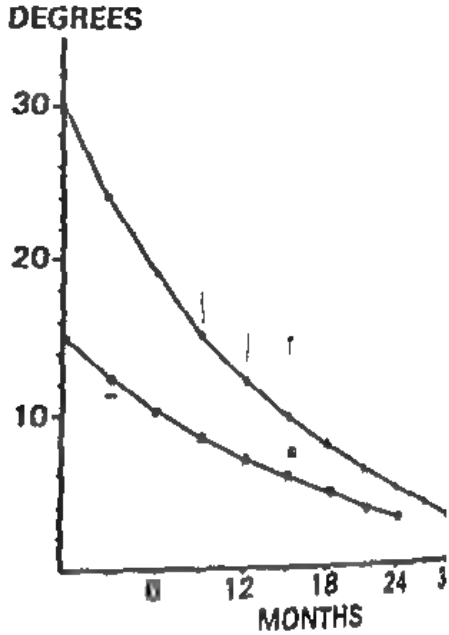

Figure 4 The normalization of the epiphyseal plate in two hypothetical cases with primary angulations of 15 and 30 degrees The mean of β found in the lateral view of the radius been used β = 0 074 ± 1 × s d = 0 0 9 CPC correction = 6 1 per cent

obs) in the radial direction and 0 134 ± 0 049 (5 obs) in the ulnar direction These values showed that in the distal radial epiphyseal plate the CPC capacity was lower for angulations in the dorsal direction than for those in the volar and ulnar directions ($P = 0\ 001$ and 0 03, respectively)

The correction of hypothetical inclinations of 15 and 30 degrees was calculated using the mean value of CPC for primary angulations over 14 degrees in the dorso-volar plane of the radius (Figure 4) These curves are to be compared with the curves from patients with comparable angulations of the epiphyseal plate (Figure 3)

Correlations of different variables with the constant percentage and the linear correction (degrees/month) In the dorso-volar plane of the radius the mean values of the CPC and linear correction (LC) for each patient (36 obs) were analysed by correlation matrices and stepwise regression analysis A non-significant correlation was found between the CPC capacity and the primary angulation contrast, the LC was highly significantly related ($P < 0\ 001$), corr coeff = 0 64) the primary angulation in the sense increased primary angulation results higher LC values.

A significant correlation ($0\ 05 > P >$ corr coeff = 0 35) existed between the capacity and the type of fracture The capacity decreased slightly from simple fractures through greenstick to comminuted fractures The correlation between parameter and the LC was not significant

No significant correlations existed between age, sex, side, treatment and distance fracture from the epiphyseal plate and correction capacities calculated by the methods

Prognostic value of constant percentage and linear correction The mean values for CPC and the LC found in the dorso-volar plane of the radius were tested for prognostic value The expected correction

ng to these mean values was ed for each observation This expected on was then compared with the actual on found in the patients

mean absolute deviation for each tion (60) was 2 2° ± 1 69° when the as used. The linear correction values l in a higher ($P = 0.003$) mean deviation (3 6° ± 4 1°)

e same part of the material the means h individual patient found by the two s were compared as a prognostic tool individual patient This resulted in a significant ($P < 0.001$) increase in stic accuracy for both methods when ed with the general prognosis stated The absolute mean deviation for the 8° ± 0 58°) was also in this prognosis antly ($P = 0.02$) lower than the values or the linear correction (1 4° ± 1 65°)

pacity for correction expressed as n of longitudinal growth

rate of correction was expressed in rt of the study as a function of the dinal growth produced by the seal plate, i e growth was substituted ie

mean CPC capacity and the linear y for correction as a function of were found to be similar to the cor- ding ones found for time Thus the CPC for growth was 9 per cent in the olar plane and 10 per cent in the ulnar plane of the radius The ulnar sis showed a correction of 10 per cent lues found for correction as a function wth were further tested as prognostic n the series No differences in accuracy ound when these results were compared hose obtained for time

USSION

effect of residual angulation of healed forearm fractures in children on the l orientation of the distal epiphyseal plates of the radius and ulna was investigated The general finding was that the epiphyseal plates had a definite spontaneous ability to change their inclinations in relation to the bones of the forearm Without exception, the change in inclination tended towards a normalization of the inclination of the epiphyseal plate This is in agreement with the results recently observed in experimental studies (Ryoppy & Karaharju 1974, Karaharju et al 1976) and with the case report made by Pauwels (1975) The capacity for correction expressed as degrees per month was found to be dependent on the degree of primary angulation after healing of the fracture Thus, increased angular deviation from the normal position increased the correction capacity Furthermore, the correction capacity diminished with increasing degrees of normalization In isolated cases with small primary angulations no change in epiphyseal inclination occurred

The probable explanation for spontaneous normalization of abnormal inclinations of the epiphyseal plate is an altered distribution of growth within the plate, probably due to a change in the direction and amplitude of the biomechanical forces acting on the plate (Ryöppy & Karaharju 1974, Pauwels 1975) From the results of the present study the following general rules for the behaviour of the process may be deduced A redistribution of growth in the epiphyseal plate is induced by an abnormal inclination of the plate An increase in the abnormal inclination will increase the redistribution of growth Minor changes in inclination do not necessarily result in a redistribution of growth Once started the process strives to restore a normal orientation of the epiphyseal plate

The highly significant correlations found between the capacity for angular correction expressed as degrees per month and the amount of primary angulation of the epiphyseal plate strongly indicated that the correction process was not linear with time Instead, the general behaviour of the process suggested an exponential dependence, i e a constant percentage correction (CPC). Such a

dependence can also be traced from the experiments performed by Karaharju et al (1976) To test this hypothesis, an exponential model equation was designed to express the course of the process When the model equation was used, the dependence on the primary angulation disappeared To further investigate whether the CPC was a more accurate method for describing the correction than the linear term, degrees per month, the mean values for the parameters were used as prognostic tools in the series The result was that the use of CPC produced a marked increase in prognostic accuracy compared with linear correction This proved that the general course of the process of correction was more accurately described by an exponential than by a linear expression

The mean values for the correction of abnormal inclinations of the epiphyseal line found in this study permit an evaluation of the rate of correction to be expected in the individual case A further increase in the accuracy of the estimation of the correction to be expected in a specific case will ensue if a CPC value for the individual is obtained The possibility of calculating the correction to be expected opens a way for early detection of growth disturbances due to epiphyseal damage

It is also possible to calculate the approximate time needed for adequate correction of the inclination of the epiphyseal plate or, in other words, adequate correction of the inclination of the joint plane The latter possibility is of decisive importance, especially in adolescent patients in whom epiphyseal closure will occur within a few years The present results suggest, but have not proved, that full correction will, in fact, occur Theoretically, the exponential equation implies that full correction cannot be reached In clinical practice the calculation of the time needed for correction must therefore be performed for adequate correction, e g 2 degrees of remaining angulation This assumption will give the following formula for the time in months (t) for adequate correction (2°)

$$t = \frac{\ln (V_0/2)}{\beta}$$

No significant correlations wer between the correction capacity and at the time of the fracture At first sc result is not in agreement with the opinion that the capacity for the fracture site is more pronounced younger age groups (Önne & Sandblo Blount 1955, 1967, Miyagi & Murayam Sharrard 1971, Ryöppy 1972) Th crepancy can be explained by the fact earlier reports remodelling at the site fracture – not the correction of the seal plate – has been studied Provid a normalization of the inclination epiphyseal plate occurs, an a reduction of the angulation at the f site must follow due to the lengthwise produced by the plate This w reduction in angulation will then be pronounced in a younger child

In the present series of fractures distal fifth of the bones no differences rate of correction of the epiphyseal pl found in fractures located at d distances from the plate It is possib the relatively small differences in d were insufficient to produce any de changes in the capacity for correction prevailing opinion expressed in the Li is that the capacity for remodelling fracture site decreases with inc distance between the fracture an epiphyseal plate (Önne & Sandblom Blount 1955, 1967, Sharrard 1971 & 1972) However, the present results are patible with the observations made fracture site as the growth in length pr by the epiphyseal plate will autom reduce any angulation of the bone reduction in total angulation of the bo then of necessity be more pronounce closer the fracture is located to the gr line

No previous study has been publi

the remodelling capacity of different can be compared directly In the study the radial and ulnar epiphyseal had similar capacities for correction similarity might be due to the location structures in the same anatomical area must not be interpreted to mean that epiphyseal plates with different nical locations will necessarily have a rate of correction At the distal radial seal plate volar and ulnar angulations d in a higher rate of correction than tions in a dorsal direction This tes that local factors pertaining to a epiphyseal plate are capable of ing the correction capacity Comparable have been found in tibial fractures angulations in the antero-posterior are known to have a better capacity for delling than angulations in the tibiofibular (Blount 1955, 1967, Bennek & Steinert Spissak et al 1969, Sharrard 1971)

e process of correction must be uted to a reorientation of growth at the yseal plate Consequently, there was the bility that the amount of longitudinal th produced by the epiphyseal plates d give a more exact picture of the correc- capacity However, no major differences found between the correction expressed function of time and as a function of th These results support the observation longitudinal growth of long bones has a paratively linear relationship with time ersson et al 1963, 1964, Diethelm 1968, strom 1969)

ERENCES

rson, M, Green, W & Messner, M B (1963) rowth and prediction of growth in the lower xtremities. *J Bone Jt Surg* 45-A, 1–14

erson, M, Messner, M B & Green, W T 1964) Distribution of lengths of the normal mur and tibia in children from one to ighteen years of age *J Bone Jt Surg* 46-A, 197–1202

nborough C G (1953) Remodelling of the humerus after supracondylar fractures in childhood *J Bone Jt Surg* 35 B, 386–395

Bennek, J & Steinert, V (1966) Knochenwachstum nach deformverheilten Unterschenkelschaftfrakturen bei Kindern *Zbl Chir* 91, 633–639

Blount, W P (1955) *Fractures in children* pp 2–7, Williams & Wilkins Co, Baltimore

Blount, W P (1967) Forearm fractures in children *Clin Orthop* 51, 93–107

Diethelm, L (1968) *Handbuch der Medizinischen Radiologie* IV-2, Springer-Verlag, Berlin

Ehalt, W (1961) *Verletzungen bei Kindern und Jugendlichen* Enke Verlag, Stuttgart

Friberg, S & Lundstrom, B (1976a) Radiographic measurements of the radio-carpal joint in normal adults. *Acta radiol Diagn* 17, 249–256

Friberg, S & Lundstrom, B (1976b) Radiographic measurements of the radio-carpal joint in distal radial fractures. *Acta radiol Diagn* 17, 869–876

Gandhi, R K., Wilson, P, Mason Brown, J J & Macleod, W (1962) Spontaneous correction of deformity following fractures of the forearm in children *Brit J Surg* 50, 5–10

Grewe, H E & Niemann, F (1966) Wachstumsstorungen nach Frakturen im Kindesalter *Bruns' Beitr klin Chir* 212, 185–205

Hansen, B A, Greiff, J & Bergman, F (1976) Fractures of the tibia in children *Acta orthop scand* 47, 448–453

Hedstrom, Ö (1969) Growth stimulation of long bones after fracture or similar trauma A clinical and experimental study *Acta orthop scand*, Suppl 122

Hogstrom, M, Nilsson, B E. & Willner, S (1976) Correction with growth following diaphyseal forearm fractures. *Acta orthop scand.* 47, 299–303

Karaharju E O, Ryoppy, S A & Makinen, R J

Lanzi, F (1965) Evoluzione delle fratture di avambraccio dell'infanzia e dell'adolescenza *Arch Ortop (Milano)* 78, 327–335

Miyagi, S & Murayama T (1964) Clinical observations on spontaneous correction of fracture of the shaft of growing long bones. *Kurume med J* 11, 19–37

Movin A & Karlsson, U (1969) *Skelettröntgenundersökningar* Svenska bokforlaget, Stockholm

Nonnemann, H C. (1969) Grenzen der spontankorrektur Fehlgeheilter Frakturen bei Jugendlichen *Langenbecks Arch klin Chir* **324**, 78–86

Önne, L & Sandblom, P H (1949) Late results in fractures of the forearm in children *Acta chir scand* **98**, 549–567

[illegible] *Orthop* **113**, 1–5

Ryoppy, S (1972) Injuries of the growing skeleton *Ann Chir Gynaec Fenn* **61**, 3–10

Ryöppy, S & Karaharju, E O (1974) Alteration of epiphyseal growth by an experimentally produced angular deformity *Acta orthop scand* **45**, 490–498

Sharrard, W J W (1971) *Paediatric orthopaedic and fractures* Blackwell Scientific Publ. Oxford and Edinburgh

Spissak, L, Majesky, I & Holletschek (1969) Nase skusenosti s zut diafyzarnych zlomenin predkolenia u deti *Chir orthop Traum cech* **36**, 176–17[illegible]

Steinert, V (1966) Unterarmfrakturen im Kindesalter *Bruns' Beitr klin. Chir* 170–184

Swaan, J W & Oppers, V M (19[illegible]) [illegible] fractures in children *Arch Chir* [illegible] **23–24**, 259–272.

Wong, P C N (1965) A comparative epidemiologic study of fractures among Malay and Swedish children *Med J M[illegible]* **20**, 132–143

Correspondence to K S I Friberg, M D, Department of Orthopaedic Surgery, University of U[illegible] S-901 85 Umeå, Sweden

ıop scand. 50 547–548, 1979

)SITIS OSSIFICANS LOCALISATA AS A COMPLICATION ſETANUS

ıJIĆ & JURAJ RULNJEVIĆ

or Rheumatic Diseases and Rehabilitation of the Departments of Orthopaedics and
ve Diseases, Medical Faculty, Zagreb University, Yugoslavia

The authors describe and illustrate three cases of myositis ossificans localisata which occurred among five cases of elbow contracture following tetanus.

Key words tetanus, myositis ossificans

Accepted 25.xi 78

itis ossificans is a rare complication of ıı None of the cases of tetanus ibed previously in our country have been licated by myositis ossificans, and very cases of myositis ossificans following ıı have been described in the world cal literature (Gunn & Young 1959, Pitts Ferni-Pearse & Olowu 1971, Mitra) (Table 1) Hence, we are reporting further cases of myositis ossificans wing tetanus.

• 1 *Myositis ossificans as a complication of tetanus Published reports*

ors	Year	No of cases
ı & Young	1959	1
	1964	1
Pearse & Olowu	1971	2
	1976	1
		5

ſENTS AND METHODS

patients, one man and two women aged 30 to ars were in a coma for 10 to 30 days. During time they were given Diazepamum 1200 mg endovenously and per os, and Pan ıu bromidum up to 24 ampoules per day in travenously in both cubital veins, which had a sedative and relaxant effect on the muscle spasm

The elbow joint was swollen, red and painful, and the contracture developed rapidly, in one of the patients on one side only, but in the other two bilaterally The other joints were not affected Myositis ossificans developed about 6 weeks after the onset of tetanus.

Depending on the condition of the patients, passive exercises were carried out in the early stages, and active exercises were encouraged after the patients regained consciousness. In spite of the continued kinesitherapy, the contractures were not improved even after a period of 3 months. In two of the patients the gross contractures considerably damaged the function of the arms. One of the women patients had the joint operatively mobilized which markedly improved the functional capacity of the elbow and the arm

DISCUSSION

The three patients had heterotopic calcification and ossification of the muscle attachments to the elbow, ossification of the capsule, and contracture of the joint, which developed while recovering from tetanus (Figures 1, 2) Skeletal survey did not show any other abnormalities.

Gunn & Young (1959) were the first to describe myositis ossificans as a complication

6470/79 050547 02$02.50/0

© 1979 Munksgaard, Copenhagen

Figure 1 X ray of the right and left elbows showing the mass of new bone in the brachialis and triceps brachii muscles and the capsule of the joint

Figure 2 Tomogram of the right elbow (same patient as in Figure 1) showing a normal joint space

of tetanus and several reports have appeared subsequently in the literature (Pitts 1964, Femi Pearse & Olowu 1971, Mitra 1976)

The calcification a slow passive deposition of calcium salts in the tissue is seen as an amorphous shadow on the radiograph hardly noticeable at first and then gradually becoming more and more dense Finally, as the bony masses develop in soft t acquire bone-like properties.

The mechanism of ossification is a quite clear but in these cases appear similar to that of ordinary myosit following trauma (Meffert & Webe Jajić & Zečevic 1974) Severe musck causing partial rupture or stretching the formation of a hematoma in and the muscles which subsequentr ossified The ossification may be either by invasion of the hematoma b blasts from the damaged periosteum metaplasia of fibroblasts.

It is assumed that the severe spasms of tetanus and also the physio exercises given in the early stages ma in trauma to the joint and soft tissues opinion these factors may cause n ossificans ossification of the capsu contracture of the elbow joint.

REFERENCES

Femi Pearse D & Olowu A O (19 1) ossificans – a compl cation of tetan *Radiol* 22, 89–92

Gunn D R & Young W B (1969) ossificans is a complication of tetanus *Jt Surg* 41-B 535–540

Jajić, I & Zečević, J (1974) Myositis o localisata *Medicinski arhiv* 28 49

Meffert O & Weber H-G (1973) Be Myositis ossificans local sata *Dtsch H schr* 98, 653 656

Mitra M (1976) Myos tis ossificans trau complication of tetanus *J Bone Jt S* A 885–886

Pitts, N C (1964) Myositis ossificans plication of tetanus *J Amer med A* 237–239

Correspondence to Professor Ivo Jajc M D D Sci Klinika za ortopediju, Šalata 5, 41000 Yugoslavia

hop scand 50 549–553 19 9

JMATIC HIP DISLOCATION IN CHILDHOOD

ort of 26 Cases and a Review of the Literature

IIO BARQUET

: and Department of Orthopaedics and Traumatology Montevideo Uruguay

Twenty six cases of traumatic hip dislocation in children are presented Although closed reduction was achieved in most instances, open procedures had to be employed in two cases of soft tissue interposition and in a patient with ipsilateral fracture of the femoral shaft In 16 patients with a follow up averaging 14 years, the incidence of complications (avascular necrosis, coxa magna and arthrosis) was significant Factors predisposing to abnormal results were delayed reduction and severe trauma Neither the method of immobilization nor the interval without weight bearing over 4 weeks were of influence Principles of treatment are suggested

Key words hip hip dislocation children

Accepted 10 in 79

iatic hip dislocation (THD) in ood in rare As far as we could nine no more than 500 cases have been ed The follow up a significant factor ially too brief (Funk 1962) Therefore int behaviour after traumatic dislocation s age group has not been adequately ented in order to provide defined eutic principles.

in report based on 26 cases collected in ountry and including a review of the literature in an attempt to face these ems..

IENTS AND METHODS

ity six cases of THD in children under 16 of age from our Institute and from private ds, were reviewed Ages ranged from 4 to 15 , averaging 10 years. Boys were involved times as often as girls. Injuries were grouped slight such as falls from the same level rate such as athletic traumas, and severe were slight in 25 per cent of cases and these occurred predominantly in younger children The severity of injuries increased with age. Twenty four dislocations were posterior and two were anterior Among the posterior cases there were six retroacetabular dislocations the femur had only suffered a posterior rotatory displacement (Figure 1) There were no fracture-dislocations. In one patient severely injured there was a peroneal nerve palsy and in another an obturator dislocation was associated with an ipsilateral fracture of the femoral shaft (Figure 2)

Diagnosis was made within the first 12 hours in 23 patients while in the other 3 cases it was delayed over 40 hours. Of these only one was due to delayed consultation. The interval before reduction was less than 24 hours in 20 cases, and in the other 6 children it ranged from 40 hours to 8 days.

Treatment

Initial attempts at closed reduction employing the Allis method were made in all cases. General anaesthesia was used in all patients except two in whom rachianaesthesia and analgesia were used These attempts were effective in 23 patients. The remaining three cases underwent open reduction Two of them had soft tissue interposition

64 0779/050549 05$02.50/0

© 1979 Munksgaard Copenhagen

Figure 1 An example of retroacetabular dislocation The femur has only suffered a rotatory movement, with neither lateral nor altitudinal displacement Note the concentric projection of the femoral head and acetabulum

acetabular labrum in one and labrum and capsule in the other In both cases, X-rays after manipulation showed a greater gap between the femoral head and the acetabulum than on the contralateral side In the remaining case the femoral fracture made closed manoeuvres inefficient As to the post-reduction procedure, various methods were employed (bedrest, skin and skeletal traction, cast) from 10 days to 12 weeks, averaging 5 weeks Except in one case, weight bearing was permitted without an additional interval

Complications

Sixteen patients have been followed from 1 5 to 31 years, with an average of 14 5 years and complications were found in seven The peroneal nerve palsy remained unchanged 22 years after trauma In three children whose dislocations were reduced more than 40 hours after injury avascular necrosis was diagnosed 5, 19 and 20 months later The injuries were classified as slight severe and

Figure 2 An exceptional case of obturator dislocation of the hip associated with ipsilateral of the femoral shaft in a girl of 6 years

moderate, respectively The first patient found to have an asymptomatic coxa plana post-reduction In the second, arthrosis present after 5 years and severe after 11 (Fig 3) The other patient had an asymptomatic deformed epiphysis 31 years after injury (Fig 4) One patient developed coxa magna with a short and wide femoral neck This was of the children undergoing open and closed reduction for soft tissue interposition was also present in another patient, X-rays years after his severe injury The patient peroneal nerve palsy also showed hip pain limp at the final evaluation, he refused to be rayed, but it may be assumed that he was arthrotic

RESULTS

Only hips followed to skeletal maturity considered Gartland's criteria were employed and a hip was judged abnormal if there pain, limited motion, shortening of the

3 End result of a dislocated hip, reduced urs after the injury Avascular necrosis ed 19 months later This radiogram, taken ars later, shows the deformed femoral head e degenerative joint changes

1 Pertinent data of 10 children with THD followed to skeletal maturity

Age (years)	Severity of injury	Interval before reduction (hours)	Reduction procedure	Non weight bearing interval (weeks)	Follow-up (years)	Result
4	M	192	C	5	31	A
12	Se	6	C	4	28	N
15	Sl	7	C	4	25	N
6	M	6	C	6	20	N
15	Se	6	C	6	20	N
15	Se	8	C	6	22	A
13	Se	6	C	8	16	N
12	Se	8	C	4	18	A
14	Se	40	C	5	18	A
15	Se	12	C	5	5	N

Moderate
Severe
Slight

C = Closed
A = Abnormal
N = Normal

Figure 4 Thirty one years after dislocation This was a case reduced by closed procedure 8 days after injury Avascular necrosis was diagnosed 20 months later Note the deformed epiphysis and the wide and short femoral neck

limp, or if there were radiographic abnormalities (Pennsylvania Orthopaedic Society 1968) Ten patients, followed from 5 to 31 years, were in this situation (Table 1) A normal result was obtained in six cases, whilst in four it was abnormal The factors which appear to have favoured the abnormal results are delayed reduction and severe trauma Neither initial post-reduction procedures nor the intervals without weight-bearing over 4 weeks influenced the results There are no findings to indicate whether age or reduction procedure should be considered

DISCUSSION

THD in childhood occurs predominantly in older boys, which is probably due to their higher traumatic morbidity (Morton 1959, Fischer et al 1971) Hip dislocation, especially in younger children, may result from slight trauma (Fineschi 1956, Schlonsky & Miller 1973) as in this series, and this might be related to the anatomic characteristics of this age group (Bado, personal communication 1977) Giraud (1927) suggested that anterior dislocations are proportionally more frequent than in adults, but our findings do not confirm this opinion There were in this series six retroacetabular dislocations this type, quoted by few authors (Trillat & Ringot

1951, Chavatte 1968, Fischer & Imbert 1969), may cause diagnosis difficulties, as isolated frontal radiograms showing a concentric projection of epiphysis and acetabulum are not always demonstrative As already mentioned by Piggot (1961) and Schlonsky & Miller (1973), our findings show that fracture-dislocations are exceptional in children, perhaps as a consequence of the particular plasticity of their joints Associated neurological injuries are rare, but they may lead to poor results Dislocations associated with femoral shaft fracture, though rare, are remarkable as in more than 50 per cent of previously reported cases dislocation was initially missed, the fracture providing an obvious injury and acting as a corrective osteotomy (Wadsworth 1961, Helal & Skevis 1967)

Closed reduction is usually effective in recent dislocations without fracture Irreducibility in these cases is rare and it is caused by soft tissue interposition (acetabular labrum, capsule and muscles) as it has also been found by Funk (1962), Fernández (1965), Fordyce (1971) and Pearson & Mann (1973) Only X-rays are definitive for the diagnosis in these cases and open reduction is indicated If there is associated femoral shaft fracture, closed reduction should be attempted, including certain procedures such as manipulation of the proximal fragment of the femur by means of screws or pins or even after its surgical exposure (Dehne & Immerman 1951, Helal & Skevis 1971, M'Bamalli 1975) Open reduction is required if these measures fail Post-reduction treatment has been very variable in this series, as in other reports

Avascular necrosis is a redoubtable complication As it may be diagnosed until 24 months after injury, the evaluation of its incidence should be made on the basis of cases followed for at least that interval Necrosis appears to be the result of interference with the extraosseous blood supply at the time of the injury (Cros 1959, Haliburton et al 1961, Gula 1972) However, alternative mechanisms have been mentioned (Epstein 1973) The essential factor predisposing to necrosis in this series delayed reduction, and this has [illegible] found by Haliburton et al [illegible] Pennsylvania Orthopaedic Society (1[illegible] Hammelbo (1976) Another accepted [illegible] severe trauma (Gula 1972, Epste[illegible] Open reduction has also been [illegible] (Funk 1962), but if performed [illegible] can also be associated with a good [illegible] (Schoenecker et al 1978) Coxa magn[illegible] by few authors (Glass & Powe[illegible] Hovelius 1974, Macfarlane & Kin[illegible] may be caused by a physeal disturba[illegible] can also be related to vascular in[illegible] Arthrosis is the common end result of [illegible] complications, though it may also [illegible] their absence, especially after sev[illegible] its incidence seems higher than usu[illegible] sidered The incidence of post-[illegible] treatment on complications and end-[illegible] still under discussion According to [illegible] series, the non weight bearing period [illegible] not be longer than 4 weeks, and [illegible] the opinion of Pearson & Mann (19[illegible] Hammelbo (1976)

CONCLUSIONS

Every child with hip or knee trauma [illegible] slight), with multiple injuries or [illegible] femoral shaft fracture should be [illegible] routine X ray of the pelvis includ[illegible] hip views If hip dislocation is [illegible] immediate closed reduction preferably [illegible] Allis method is indicated Manoeuvre[illegible] be monitored radiographically to avoi[illegible] reductions Open reduction, although [illegible] required, is necessary in the case [illegible] tissue interposition and in d[illegible] associated with femoral shaft fract[illegible] which closed procedures have failed [illegible] reduction treatment may include bedre[illegible] traction or a cast for a period of 4 w[illegible] allow healing of soft tissue injuries, fo[illegible] by free weight bearing Clinical [illegible] radiological examinations should be [illegible] formed quarterly during the first 2 [illegible] and then periodically until matu[illegible] disclose eventual complications.

OWLEDGEMENTS

. I Milano for secretarial help, and to Mr ero for the photographs.

RENCES

te, J (1968) Luxation traumatique de la he chez l'enfant. These, Lyon.

A (1959) Osteochondrosis of the upper oral epiphysis following traumatic dislocation of the hip joint. *J Bone Jt Surg* 41-A, 5–1338

E. & Immermann, E (1951) Dislocation of hip combined with fracture of the shaft of femur on the same side *J Bone Jt Surg* A, 731–745

, H (1973) Traumatic dislocations of the *Clin Orthop* 92, 116–142

idez Herrera, E (1965) Luxación traumatica error de la cadera en la infancia. *Bol méd p infant (Méx)* 22, 95–99

hu, G (1956) Die traumatische Hüftrenkung bei kindern *Arch orthop Unfall-* 48, 225–236

, L. & Imbert, J (1969) Luxation umatique de la hanche rétro-cotyloidienne chez l'enfant, sans déplacement en uteur *Lyon méd* 222, 825–826

, L., Venouil, J, Baulieux, J et al (1971) ixations traumatiques de la hanche chez nfant *Cah Méd Lyon.* 47, 3325–3331

ee, A (1971) Open reduction of traumatic slocation of the hip in a child *Brit J Surg* , 705–707

, F (1962) Traumatic dislocation of the hip children. *J Bone Jt Surg* 44-A, 1135–1145

d, D (1927) Contribution a l'étude de la xation traumatique de la hanche chez nfant. These, Bordeaux

, A. Powell, H (1961) Traumatic dislocation of the hip in children *J Bone Jt Surg* 43-B, 29–37

Gula, D (1972) Recurrent traumatic dislocation of the hip in children *J Amer Osteopathol Ass* 72, 32–39

Haliburton, R, Brockenshire, F Barber, J (1961) Avascular necrosis of the femoral capital epiphysis after traumatic dislocation of the hip in children *J Bone Jt Surg* 43-B, 43–46

Hammelbo, T (1976) Traumatic hip dislocation in childhood *Acta orthop scand* 47, 546–549

Helal, B & Skevis, X (1967) Unrecognised dislocation of the hip in fractures of the femoral shaft *J Bone Jt Surg* 49-B, 293–300

Hovelius, L (1974) Traumatic dislocation of the hip in children *Acta orthop scand* 45, 746–751

Macfarlane, I & King, D (1976) Traumatic dislocation of the hip joint in children *Aust N Z J Surg* 46, 227–231

Morton, K (1959) Traumatic dislocation of the hip in children *Brit J Surg* 47, 233–237

M'Bamah, E (1975) Unusual traumatic anterior dislocation of the hip *Injury* 6, 220–224

Pearson, D & Mann, R (1973) Traumatic hip dislocation in children. *Clin. Orthop* 92, 189–194

Pennsylvania Orthopaedic Society (1968) Traumatic dislocation of the hip joint in children *J Bone Jt Surg* 50-A, 79–88

Piggot, J (1961) Traumatic dislocation of the hip in childhood *J Bone Jt Surg* 43-B, 38–42.

Schlonsky, J & Miller, P (1973) Traumatic hip dislocation in children *J Bone Jt Surg* 55-A, 1057–1063

Schoenecker, P., Manske, P & Sertl, G (1978) Traumatic hip dislocation with ipsilateral femoral shaft fractures. *Clin Orthop* 130, 233–238

Trillat, A & Ringot, A (1951) Erreurs d'interpretation radiographique dans les fractures du cotyle avec luxation de la tête femorale *Lyon chir* 46, 472–474

Wadsworth T (1961) Traumatic dislocation of the hip with fracture of the shaft of the ipsilateral femur *J Bone Jt Surg* 43 B, 47–49

espondence to Antonio Barquet M D Avda Joaquín Suárez 3132, Montevideo, Uruguay

op scand. 50, 555–561, 1979

EOTOMY IN OSTEOARTHRITIS OF THE HIP

spective Study

OLLERT* & PER GILLSTRÖM**

tment of Orthopaedic Surgery, St Göran's Hospital, and
artment of Orthopaedic Surgery, Karolinska Hospital, Stockholm, Sweden

Ninety-two patients (94 hips), who in 1971–1972 underwent intertrochanteric osteotomy for painful osteoarthritis of the hip, were assessed and graded according to a well-defined rating system immediately before operation and 1 and 5 years postoperatively At the 1-year follow-up pain was absent or only slight in 73 5 per cent of the patients. Five years postoperatively this figure had decreased to 45 5 per cent, 41.5 per cent of the patients deteriorated between the two investigations. Nineteen patients had been reoperated upon and total hip replacement performed It was not possible to predict the effect of the osteotomy from the preoperative clinical and roentgenological picture Nor was the operative procedure (amount of medial displacement, varus angulation, tenotomy of the iliopsoas) found to have any influence on the results. Though the effect of the osteotomy is not as long-lasting as previously believed, it is concluded that it still has a place in the operative treatment of painful osteoarthritis of the hip in younger patients.

Key words gait, hip, osteoarthritis, osteotomy, results

Accepted 31 x.78

pain-relieving effect of intertrochanteric otomy in osteoarthritis of the hip has t demonstrated by many authors (Adam pence 1958, Nicoll & Holden 1961, King Jooley 1962, Ottolenghi & Frigerio 1962, ht & Tarp 1967, Tillberg 1968, Hirsch & die 1968, Gudmundsson 1970, Morscher L 1971, Salenius et al. 1971, Hansen et al. 3, Goldie et al. 1973) It is often claimed t this effect is long-lasting but this umption would seem to be less well subntiated.

n 1971 a prospective study was initiated evaluate the effect of intertrochanteric eotomy in osteoarthritis of the hip In an empt to assess its long-term effect, a comison was made between the results of two follow-up examinations, performed 1 and 5 years after operation.

PATIENTS AND METHODS

The original series in the present study includes 97 patients who between January 1971 and March 1972 underwent intertrochanteric osteotomy for osteoarthritis of the hip at the Department of Orthopaedic Surgery, Karolinska Hospital, Stockholm. Two of the patients had bilateral operations at intervals of 6 and 12 months, respectively, making 99 operated hips in all

The investigation was designed as a prospective study The patients were examined on three different occasions

1 On admission to hospital one or a few days preoperatively

11-6470/79 050555 07$02.50 0

© 1979 Munksgaard Copenhagen

Table 1 Method of assessment and classification of pain

Pain on starting to walk	No	0 point
	Yes	1 point
Pain on weight bearing	No	0 point
	Slight	1 point
	Severe	2 points
Pain at rest	No	0 point
	After exertion	1 point
	Spontaneous	2 points

Group I 0–1 points
Group II 2–3 points
Group III 4–5 points

2 One year after operation
3 Five years after operation

The first and second examinations included a clinical assessment, roentgenographic examination of both hips in standard projections, and a gait investigation on an electronic walkway The third examination included only clinical assessment and roentgenographic investigation

Clincial assessment was performed by means of a grading system developed by Andersson & Moller-Nielsen (1972) with some modifications (Collert 1974) The method provides a rating scale, permitting classification of the series into three groups according to degree of pain, loss of mobility, and functional impairment Table 1 shows the method of classification of pain

Roentgenological classification On the basis of the preoperative AP roentgenograms, the cases were classified with respect to roentgenological type and stage of osteoarthritis, according to the following definitions *Lateral type* The destruction of the cartilage (evident in narrowing of the joint space) initially appears and becomes most marked in the lateral-proximal part of the joint, leading to a lateral and proximal displacement of the head of the femur *Medial type* The destruction of the cartilage initially appears and becomes most marked in the medial part of the joint, leading to medial displacement of the head *Stage I* Partial or total obliteration of the joint space along at least part of the joint Secondary deformation of the bony surface of the femoral head absent or only slightly *Stage II* Marked secondary deformation of the bony surface of the head

The gait study was conducted with the aid of a 5 m long double force-plate electronic walkway, which registered the vertical and anterop[illegible] horizontal forces exerted by the foot on [illegible] ground during walking The recorded [illegible] permitted analysis of certain temporal and [illegible] factors Special emphasis was placed on [illegible] weight-bearing capacity of the operated hip was defined as the sum of the vertical [illegible] exerted during the stance phase

Final series Of the 97 patients who were [illegible] in the first examination and underwent [illegible] five patients were not available for examination [illegible] year postoperatively (one had died, three [illegible] suffering from some other serious disorder [illegible] one had moved to a distant part of the country [illegible] leaving 92 patients and 94 hips. At the [illegible] follow-up another 17 patients were excluded [illegible] the following reasons nine patients were [illegible] two were senile and unable to cooperate and [illegible] could not be traced Thus 75 patients and [illegible] were included in the 5-year follow-up. For reasons of convenience, each operated hip is [illegible] following counted as a separate case

Age and sex The series includes 48 women [illegible] 46 men The mean age at the time of operation was 59 6 years, ranging from 32 to [illegible] (Table 2)

Operative procedure and postoperative care [illegible] 39 cases intertrochanteric osteotomy [illegible] combined with a varus angulation of 10 degrees [illegible] more, and in 43 cases with at least 1 cm [illegible] displacement of the shaft In 48 cases tenotomy [illegible] the iliopsoas was performed Internal fixation [illegible] an AO nail-plate following compression was [illegible] in all cases

One postoperative death due to pulmonary embolism occurred Nine patients had [illegible] suggestive of thrombosis following operation

Table 2 Age and sex distribution

	Male	Female	Total
	1	1	2
	5	6	11
	15	11	26
	17	26	43
	8	4	12
	46	48	94

our patients had a superficial wound infec- Healing time i e the interval between ion and the first roentgenographic examina- show consolidation of the osteotomy was an 3 months for 55.5 per cent, and less than ths for [illegible] per cent of the series. One case of on was found at the 1 year follow up

JLTS

e 5 year follow-up 19 patients had been rated on with total hip replacement and hat reason were excluded from the sment of mobility and functional ity As it was assumed that they all had pain at rest as well as weight-bearing they were classified in pain group III

ce the main indication for osteotomy was all patients at the preoperative examina- belonged to group II (22 per cent) or p III (78 per cent) with respect to pain le 3) One year postoperatively 73 5 per (69 patients) had no pain or it was only it and they were classified in group I Five years postoperatively this figure had decreased to 45 5 per cent (35 patients)

A closer analysis of the type of pain shows that preoperatively only 3 per cent (3 patients) never had pain at rest (spontaneous or after exertion) One year after operation 78 per cent (73 patients) were free from pain at rest and after 5 years 47 per cent (36 patients) With respect to weight bearing pain, all patients except one (1 per cent) had complaints preoperatively One year postoperatively 55 per cent (52 patients) were free from weight-bearing pain and 5 years after operation 35 per cent (27 patients)

The result was somewhat better for cases of lateral osteoarthritis than for the medial type (47 per cent pain free as against 40 per cent at the 5-year follow-up) but the difference is statistically not significant The roentgenological stage of osteoarthritis had no influence on the effect of the operation in providing relief of pain

The operative procedure (amount of medial displacement of the shaft fragment, varus angulation, tenotomy of the iliopsoas) was found to have no influence on the results.

Mobility

The operation produced an increase in mobility 1 year postoperatively in a number of cases (Table 4) Four years later hip mobility had decreased in some cases but it was still better than preoperatively There was on the whole a good correlation between increased pain and impaired mobility between 1 year and 5 years postoperatively

Table 3 Pain preoperatively and 1 and 5 years postoperatively

	Group I	Group II	Group III	Total
Preoperatively	0 0%	21 22%	73 78%	94 100%
1 year postop	[illegible] 73 5%	19 20%	6 6 5%	94 100%
5 years postop	35 45 5%	9 11 5%	33 43%	77 100%

Table 4 Mobility

	Group I	Group II	Group III	Total
Preoperatively	36 62%	22 38%	0 0%	58 100%
1 year postop	49 84 5%	8 14%	1 0 5%	58 100%
5 years postop	42 72 5%	13 22 5%	3 5%	58 100%

Table 5 Function

	Group I	Group II	Group III	Total
Preoperatively	42 72 5%	14 24%	2 3 5%	[illegible] 100%
1 year postop	51 88%	6 10%	1 2%	58 100%
5 years postop	42 72 5%	12 20 5%	4 7%	[illegible] 100%

Function

With respect to functional capacity, evaluated according to the assessment table for the 58 patients followed up for 5 years, 72 5 per cent (42 cases) belonged to group I preoperatively One year after operation this figure had increased to [illegible] per cent and 5 years postoperatively it was again 72 5 per cent (Table 5)

Twenty-three of the 58 patients followed up did not use walking aids for outdoor walking before operation One year after operation this applied to 24 patients and 5 years postoperatively to 32 patients

Gait

The effect of the operation on gait pattern was assessed by comparing the values obtained 1 year after operation with the preoperative values *Weight bearing capacity* of the osteotomy leg increased in 40 cases (45 per cent), was unchanged in 30 (34 per cent) and decreased in 19 cases (21 per cent) effect of the operation on weight-bearing capacity 1 year postoperatively is statistically significant ($P < 0 01$) There was a statistically highly significant relationship ($P < 0$ between improved weight bearing capacity relief of weight-bearing pain

The operation also had a statistically significant effect ($P < 0 01$) on *stride length* i e the distance between two consecutive heel-strikes with the same leg when walking with the same cadence (number of steps per Stride length increased in 46 per cent of cases, was unchanged in 38 per cent and decreased in 16 per cent There was a statistically significant relationship ($P < 0$ between increase of stride length and relief of weight-bearing pain

Roentgenological appearance of the coxarthritis

A comparison was made between roentgenograms (AP views) taken

Roentgenological appearance of the osteoarthritis in relation to pain 5 years postoperatively

oentgenological pearance	Pain Group I	Group II	Group III	Total
egression	13	1	0	14
change	18	5	8	31
ogression	4	3	[illegible]	13
otal	35	9	14	58

ly prior to operation and those it the 5 year follow-up with a view ssessing any changes in the nographic appearance of the osteo- s. This assessment was based on pe of the bony surface of the femoral he degree of sclerosis, and the amount e of cysts in the head and acetabulum the 58 cases investigated, the ince of the osteoarthritis was ged in 31 cases, while regression oted in 14 cases and progression oarthritic changes in 13 cases There good correlation between regression eoarthritic changes and pain relief 6)

t's assessment

the 1-year and 5-year follow-up the were asked to state whether they atisfied with the result of the operation they felt that it had been worthwhile ts reoperated upon with total hip ement were assumed to be dissatisfied he result of the osteotomy Thus, 1 year steotomy 52 per cent (49 patients) were satisfied with the result, 33 per cent patients) were satisfied with some ation, and 15 per cent (14 patients) dissatisfied The corresponding figures 5 postoperatively were 47 per cent (36 , 14 per cent (11 patients) and 39 per cent atients) The patient's own assessment s good agreement with the figures for pain

Interval between initial follow-up and change in condition

Thirty-two patients (including those reoperated upon with total hip replacement) reported a deterioration of their condition between the 1-year and the 5-year follow-up In 12 cases this had occurred during the second year after operation, in 7 cases during the third, in 7 cases during the fourth, and in 6 cases during the fifth post-operative year All 6 patients classified in pain group III at the 1-year follow-up, implying deterioration during the first year or a total lack of improvement postoperatively, subsequently had a total hip replacement

Ten patients, all classified in pain group I at the 1-year follow-up, reported a subsequent improvement in their condition at the 5-year follow-up This improvement consisted mainly in increased strength and walking ability, which meant that some of these patients were able to discard their walking aids even out of doors.

DISCUSSION

The present investigation would seem to be the only prospective study of an osteotomy series in which the patients were assessed and graded according to the same well defined criteria both before operation and on two occasions at definite intervals after operation The results 1 year postoperatively confirm the findings of earlier studies indicating that intertrochanteric osteotomy has

a good effect in providing relief of pain, 73 5 per cent of the patients had no pain or it was only slight The effect of the operation is most marked with regard to pain at rest, which disappeared in 78 per cent of cases, while relief of weight-bearing pain was obtained in 55 per cent The positive effect on the subjective symptoms is substantiated by the results of the gait analysis At the 1-year follow-up, 45 per cent of the patients put more weight on the osteotomy leg than they did before operation, and a very good correlation was found between improved weight-bearing capacity and relief of weight-bearing pain This gait study, which has been reported in detail elsewhere (Collert 1974), appears to be the only investigation to demonstrate the effect of osteotomy in osteoarthritis of the hip by objective methods

Our study shows that the initially favourable effect of intertrochanteric osteotomy is not as long-lasting as previously believed Between the first and fifth postoperative year, 41 5 per cent of the patients deteriorated At the 5-year follow-up only 45 5 per cent showed an acceptable result (absent or only slight pain) Nineteen of the patients in the original series had been treated with a total hip replacement.

Through the years various theories have been advanced concerning the mechanism underlying the effect of osteotomy Pauwels (1950, 1961) and Blount (1964) are among those who stress changed biomechanical conditions as an important factor, while others (Phillips et al 1967, Arnoldi et al 1971, 1972) have pointed out that osteotomy has an effect on the intraosseous pressure and the venous drainage from the femoral head Although the present study was not intended to elucidate the mechanism underlying the effect of the operation, it clearly shows that biomechanical factors are not of crucial importance Neither medial displacement of the shaft fragment, varus angulation, or tenotomy of the iliopsoas muscle are of any consequence for the long-term results Similarly, none of the other factors analyzed in relation to the effect of pain, i e roentgenological type and stage of osteoarthritis, age, sex , flexion, and preoperative any difference to the results.

It is impossible, therefore effect of an osteotomy on the bas or roentgenological features. Since osteotomy does not seem to be of importance either, it is advisable to procedures such as medial the shaft, which may complica total hip replacement or other cedures at a later date

Our study shows that a patient who h obtain relief of pain in the postoperative stage cannot expect appreciable improvements during the few years

Even though relief of pain of the hip in some cases may spontaneously in due time (Danielsson our study shows that osteotomy immediate and good relief of pain in two-thirds of the cases and that this lasts for at least 5 years in almost total number Although this is a when compared with more than 90 pe relief of pain following total hip we should keep in mind that failure w latter procedure may have disastrous c quences and that so far relatively fe perience has been gained regarding the term durability of total hip prosthes view of this, we feel that intertroch osteotomy still represents a go alternative treatment for osteoarthritis hip in younger persons.

REFERENCES

Adam A & Spence, A J (1958) In osteotomy for osteoarthritis of the hip J *Jt Surg* 40–B 219–226

Andersson G & Moller Nielsen, J (1 after arthroplasty of the hip with V thesis. *Acta orthop scand.* 32, 39–4

C. C., Lemperg, R K & Linderholm, H .) Immediate effect of osteotomy on the medullary pressure of the femoral head neck in patients with degenerative osthritis. *Acta orthop scand* 42, 357–365

C. C., Linderholm, H & Müssbichler, H !) Venous engorgement and intraosseous rtension in osteoarthritis of the hip *J Jt Surg* 54–B, 409–421

W P (1964) Osteotomy in the treatment steo arthritis of the hip *J Bone Jt Surg* 1297–1325

S (1974) *Results after intertrochanteric* otomy in osteoarthritis of the hip *Thesis* er A. B , Stockholm

son, L G (1964) Incidence and prognosis oxarthrosis. *Acta orthop scand* Suppl 66

I , Andersson, G & Olsson, S (1973) g term follow-up of intertrochanteric otomy in osteoarthritis in the hip joint *Orthop* 93, 265–270

ndsson, G (1970) Intertrochanteric disement osteotomy for painful osteoarthritis he hip *Acta orthop scand* 41, 91–109

F W , Hansen Leth, C & Jensen, E G 3) Intertrochanteric osteotomy with A O nique in arthrosis of the hip *Acta orthop d* 44, 219–229

, C & Goldie, I (1968) Osteotomy in eoarthritis of the hip joint *Acta orthop d* 39, 182–202.

T & Dooley, B (1962) Observations on the results of the McMurray osteotomy for osteoarthritis of the hip *J Bone Jt Surg* 44–B, 595–601

Lucht, U & Tarp, M (1967) Osteoarthritis of the hip treated with intertrochanteric displacement osteotomy *Acta orthop scand* 38, 501–519

Morscher, E (1971) *Die intertrochantere Osteotomie bei Coxarthrose Analyse und Auswertung von 2251 nachuntersuchten intertrochanteren Osteotomien* Verlag Hans Huber, Bern, Stuttgart, Wien

Nicoll, E A & Holden, N T (1961) Displacement osteotomy in the treatment of osteoarthritis of the hip *J Bone Jt Surg* 43–B, 50–60

Ottolenghi, C E & Frigerio, E (1962) Intertrochanteric osteotomies in osteoarthritis of the hip *J Bone Jt Surg* 44–A, 855–895

Pauwels, F (1950) Ueber eine kausale Behandlung der Coxa valga luxans *Z Orthop* 79, 305–315

Pauwels, F (1961) Neue Richtlinien fur die operative Behandlung der Koxarthrose *Verh dtsch orthop Ges* 94, 332–366

Phillips, R S , Bulmer, J H , Hoyle, G & Davies, W (1967) Venous drainage in osteoarthritis of the hip A study after osteotomy *J Bone Jt Surg* 49–B, 301–309

Salenius, P , Langenskiold, A & Österman, K (1971) Intertrochanteric displacement osteotomy in the treatment of osteoarthritis of the hip *Acta orthop scand* 42, 63–77

Tillberg, B (1968) Intertrochanteric valgus osteotomies in hip arthrosis. *Acta orthop scand* 39, 539–548

pondence to Sven Collert, Department of Orthopaedic Surgery, St Goran's Hospital, Box 12500, Stockholm Sweden

MPARISON OF THE FUNCTIONAL PERFORMANCE ATIENTS WITH CHARNLEY AND MULLER AL HIP REPLACEMENT

-Year Follow-up of Eighty-Nine Cases

MURRAY, DONALD R GORE, BRUCE J BREWER, M GARDNER & SUSAN B SEPIC

logy Research Laboratory, Veterans Administration Center, Wood (Milwaukee), Wisconsin, and edical College of Wisconsin, Milwaukee, Wisconsin, USA

Measurements of functional performance in 35 cases with Charnley total hip replacement were compared with those of 54 cases with Müller replacement before surgery and at 6- and 24-month follow-up intervals. The measurements included strength of the hip abductor and adductor muscles, hip motion, the amount of weight borne on the involved limb during [illegible] and fast walking, and [illegible] groups improved [illegible] h groups reached [illegible] m weight-bearing ability, cadence, and some components which relate to smoothness of walking performance The groups with Müller and Charnley replacement differed most in some components of range of hip motion, hip muscle strength, and lateral lurching during walking

Key words arthritis, biomechanics, gait, hip joint, joint prosthesis, muscle contraction

Accepted 19 1 79

purpose of this study is to determine ner there are differences in the functional rmance between patients with Muller Charnley total hip replacements. The mination is based on comprehensive iologic measurements of functional perance before surgery and 6 and 24 months surgery

THODS

lly a total of 104 consecutive patients with up replacements were referred for this study were completed on 75 patients (89 total hip cements) who fulfilled the criteria for sion in this comparative study The criteria were that the total hip replacement be uncomplicated by loosening or infection and that the patients have no neurological disease or major problems with other joints in the lower extremities. Twenty-nine patients had 35 Charnley replacements and 46 had 54 Müller replacements. There were 16 women and 13 men with Charnley replacement and 25 women and 21 men with Muller replacement. Patients with Charnley replacement averaged 61 years of age (range, 22–77) and patients with Muller replacement averaged 63 years of age (range, 34–77).

The preoperative diagnosis was osteoarthritis in all the hips replaced except for three with Müller replacement which had rheumatoid arthritis.

The operations were performed by the techniques described by the originators of the prostheses (Charnley & Ferreira 1964 Muller 1970) The procedures were performed by one of two ex-

64-0 79 050563-0-$02.50

© 1979 Munksgaard, Copenhagen

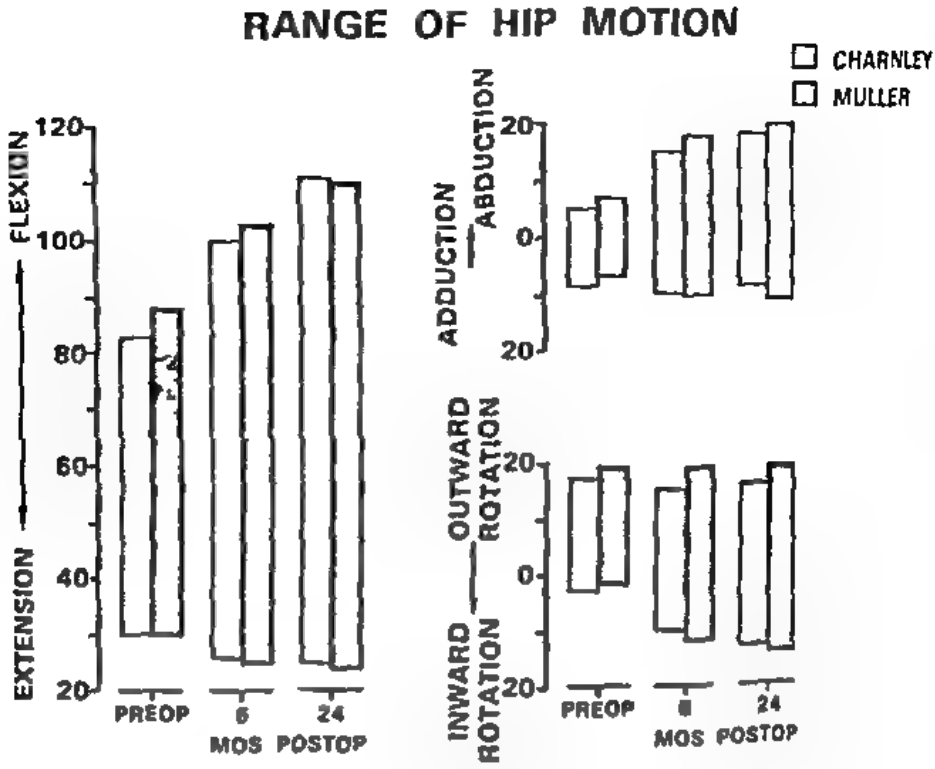

Figure 1 Bar graphs showing the mean ranges of hip motion before, and 6 and 24 months after hip replacement for 35 hips with Charnley replacement and 54 hips with Muller replacement.

perienced hip surgeons, thus minimizing differences in surgical technique within a given replacement group Trochanteric osteotomies were performed in all patients.

Range of hip motion was measured by standard methods (American Academy of Orthopaedic Surgeons 1965) The strength of the hip abductor and adductor muscles during maximum isometric contraction was measured as the product of a force recorded by a transducer attached to the lower limb and the distance between the transducer attachment and the center of the hip joint (Murray & Sepic 1968) The average amount of weight supported under the right and left feet during 1 minute periods of quiet standing was monitored with dual force platforms (Murray & Peterson 1973) and measurements of multiple simultaneous displacement patterns of free-speed and fast walking were made from photographs obtained with interrupted light photography (Murray et al 1964) The measurements of walking performance reported in this study were made while the patients walked without support In addition, the force applied to canes or crutches was measured in those patients who routinely used assistive devices to walk outdoor distances of approximately 150 meters (Seireg et al 1968)

A multiple classification analysis of variance was used to test the significance of the differences in functional performance between the pre- and postoperative testing sessions and also the patient groups

RESULTS

Preoperatively both replacement gro similar deficits in the measurem various components of function. The had limited hip motion, particularly extension, abduction and inward (Figure 1) and they had profound of the hip abductor and adductor (Figure 2) During quiet standing mo patients bore substantially less weig limb to be operated than on the con limb (Table 1) Most of the patie assistive devices during walking average amount of force applied du stance phase of the involved limb considerably among the patients (ran 38 kg) Their gait abnormalities were teristic of the antalgic limp of patie hip pain (Murray et al 1971). For e their walking speeds were subnorm result of both slower cadences and

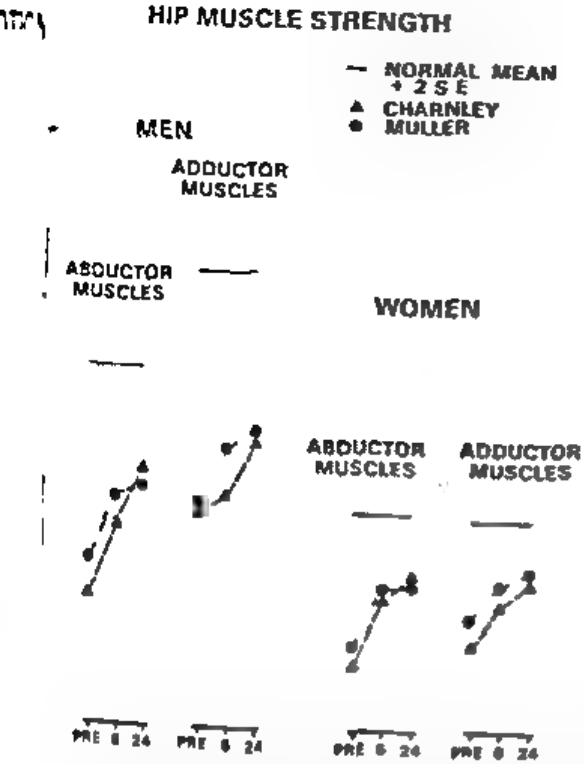

2 Mean maximum isometric strength of abductor and adductor muscles before and 24 months after total hip replacement for 35 with Charnley and 54 hips with Muller ement The horizontal line and shaded area cts represents the mean ± 2 standard errors ormal men and women (Murray & Sepic At the preoperative test session the women ive Muller replacement had significantly adductor torque than the women to have ley replacement (P < 0 05)

lengths (Figure 3) The successive step hs were uneven with the shorter step ly occurring when the sound limb was ird and the affected limb was behind amount of flexion-extension used at the ted hip was very limited during walking re 3) mainly because of failure to extend up and this limited use of hip extension was related to the amount of hip flex contracture The single-limb-suppo phas o the operative limb was short compa ed to that of the contralateral limb (Table 3) The patients had excessive lateral lurching F ure 3) and their forward motion was chara ter ized by a stop-start type of limp which was quantitated by making a ratio of forward velocity during single-limb-support on the untreated limb to that on the operative limb This velocity index was usually less than 1 00 because patients with unilateral hip pain typically move forward faster over the painful limb than the sound limb (Table 2) In addition the vertical excursions of the head of the patients were of lesser amplitude during the supportive phase on the operative limb than during the supportive phase on the contralateral limb (Table 3) Preoperatively, the gait deviations from normal were typically more pronounced during fast walking than free-speed walking

Two years after surgery there was significant improvement in all of the parameters of function measured for both replacement groups ($P < 0\ 01$) except for motions into hip adduction and inward rotation

Ranges of normal variability have been established for hip-muscle strength weight-bearing ability and each of the components of walking performance, these are indicated in the graphs and tables On an average the largest improvement toward normal function for both replacement groups consistently occurred during the first 6 postoperative months but additional improvement occurred between 6 months and 2 years, postoperatively

*Table 1 Percent body weight borne on limb with total hip replacement**

up	Number of pat ents	Preop	6 months postop	24 months postop
ley	21	33 + 1 7	42 + 1 6	48 + 2.0
r	33	35 + 2.2	44 + 1 0	46 + 1 1
al				50 ± 1 4

an values and one standard error for patients with un lateral hip replacement only

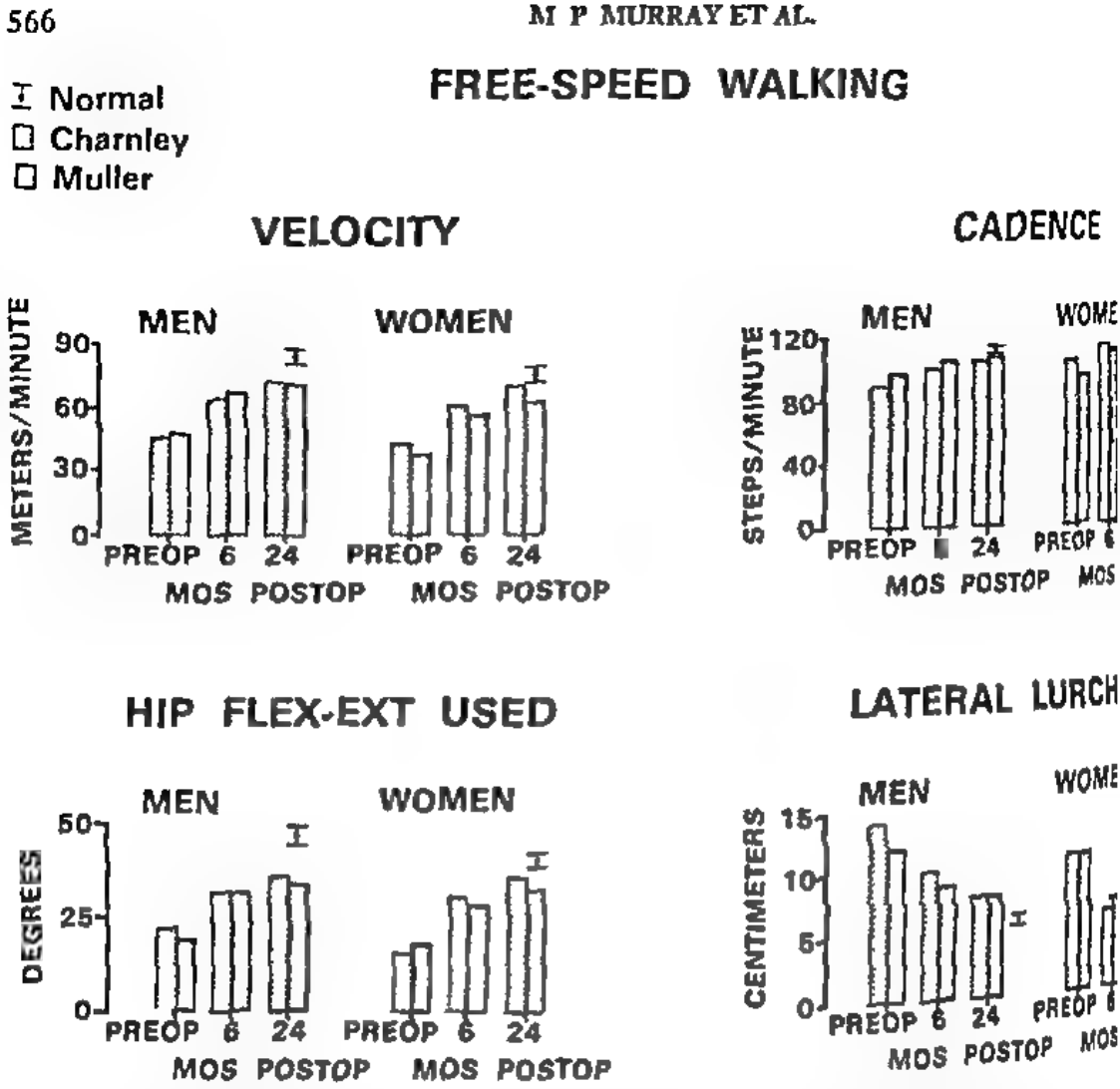

Figure 3 Bar graphs showing mean velocity cadence hip flexion extension used and later during free speed walking for 29 patients with Charnley replacement and 46 pat erts w replacement For hip flexion extension both hips of those with bilateral replacement were r the mean values The dots indicate means and the vertical lines 2 standard errors above and mean for normal men (Murray et al 1969) and normal women (Murray et al. 1970) operative test session the women scheduled for Muller replacement used significantly more h extension than the women scheduled for Charnley replacement (P < 0 05)

*Table 2 Velocity index**

Group	Number of patients	Preop Mean	Preop Range	6 months postop Mean	6 months postop Range	24 months p Mean	24 months p
Charnley	21	0 81	(0 43–1 01)	0 92	(0 70–1 01)	0 96	(0.
Muller	33	0 78	(0 34–0 95)	0 93	(0 80–1 00)	0 97	(0
Normal						1 00	(0.

* Velocity index is a ratio of the patient s forward velocity during single-limb-support on the limb to his velocity during single-l mb support on the treated l mb Patients with bilateral h ment have been excluded

groups reached or were remarkably ı reaching the lower limits of normal ıty in cadence, weight-bearing ability ocity index It was not unusual, how- ı find several *individuals* within each who had normal performance in other ıents of function such as velocity for ed walking, and equality factors such le-limb-support ratios and differences essive step lengths The components of ı for which the groups were most ıal 2 years after surgery included hip strength, velocity during fast walking, lurching and hip flexion-extension used both walking speeds.

rison of groups with Charnley and replacements

ıgs of hip pain 2 years after surgery sky 1967) were slightly more favorable : group with Charnley than for the with Müller replacement. Sixty-six ıt of those with Charnley and 48 per of those with Müller replacement d no pain Approximately 24 per cent h group reported slight pain on initiating motion which decreased with activity Eleven per cent of those with Charnley and 28 per cent of those with Müller replacement reported pain which was initiated by activity and disappeared with rest None of the patients had severe pain

Postoperatively, improvement in the use of assistive devices was dramatic for most patients Sixty-six per cent of the patients in each replacement group discontinued using assistive devices during the 2-year period Eight patients with Müller and one with Charnley replacement were still using a cane 2 years after surgery All but one of these were applying less force than preoperatively and their average forces ranged from 2 to 12 kg

Two years after surgery no statistically significant differences were found between the groups with Muller and Charnley replacement in measurements of walking performance and weight supported between the feet during quiet standing In the strength tests, the men and women with Charnley replacement had more improvement from before to 2 years after surgery in hip abductor-muscle torque than the men and women with Muller

3 *Inequality in successive single limb support times, step lengths and vertical excursions of the head*

ı	Preop Mean ± 1 s.e	1 months postop Mean ± 1 s.e	24 months postop Mean ± 1 s.e
	*Ratio of successive SLS times**		
ley	0 86 ± 0 03	0 96 ± 0 03	1 02 ± 0 03
ıl	0 83 ± 0 03	0 95 ± 0 02	0 96 ± 0 02
			1 00 ± 0 01
	Average difference in successive step lengths (cm)		
ley	6 7 ± 1 3	3 9 ± 0 6	3 5 ± 0 5
ıl	5 8 ± 0 8	4 3 ± 0 5	3 2 ± 0 4
			2.9 ± 0 3
	Average difference in successive vertical excursions of the head (cm)		
ley	1 3 ± 0 3	0 5 ± 0 2	0 4 ± 0.1
ıl	1 2 ± 0 2	0 7 ± 0 1	0 6 ± 0 1
			0 0 ± 0 1

rative single-limb-support time divided by opposite single-limb-support time

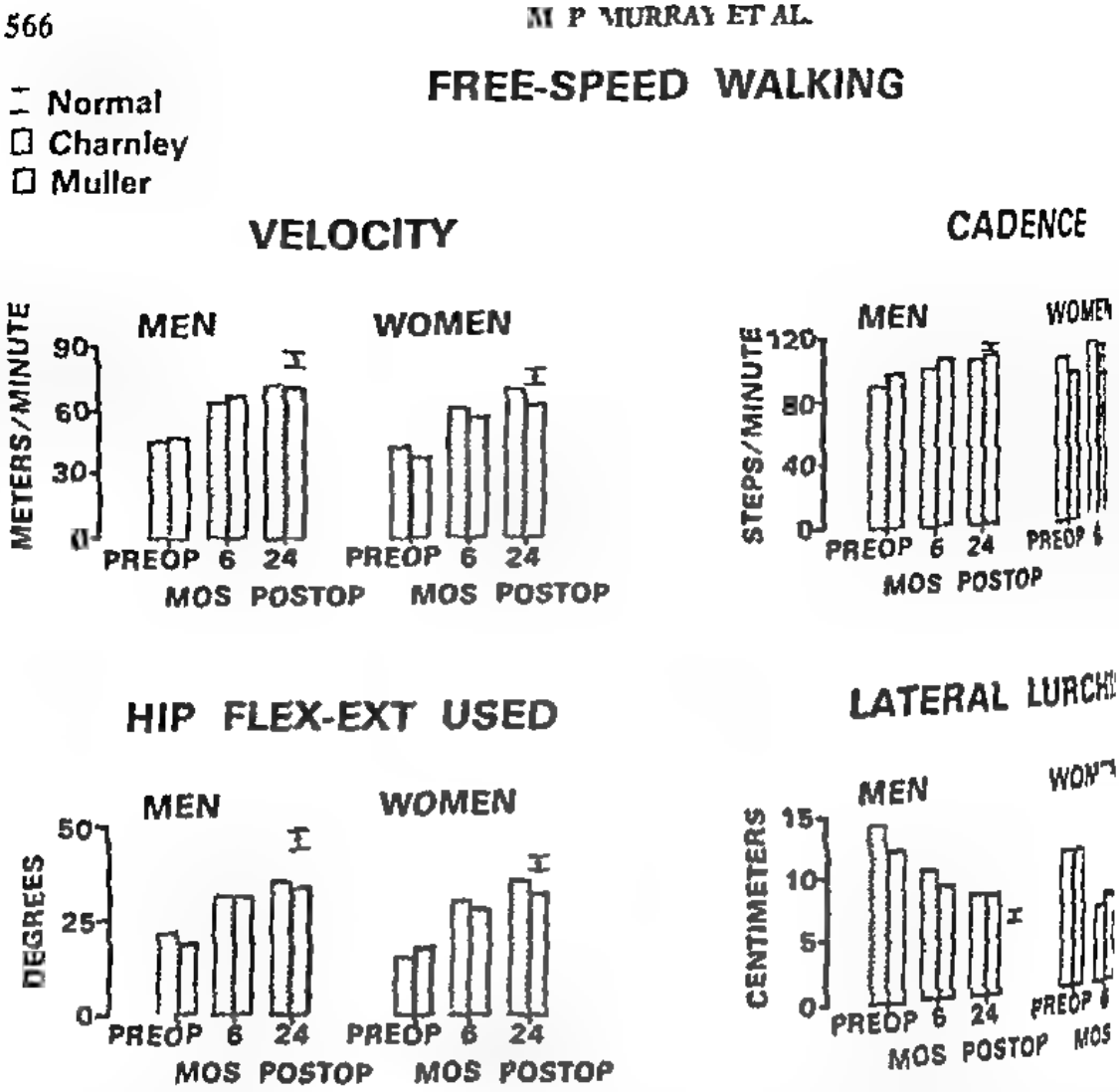

Figure 3 Bar graphs showing mean velocity cadence, hip flexion-extension used and lateral during free-speed walking for 29 patients with Charnley replacement and 46 patients w replacement For hip flexion extension both hips of those with bilateral replacement were in the mean values The dots indicate means and the vertical lines 2 standard errors above and mean for normal men (Murray et al 1969) and normal women (Murray et al. 1970) operative test session the women scheduled for Muller replacement used significantly more h extension than the women scheduled for Charnley replacement (P < 0 05)

*Table 2 Velocity index**

Group	Number of patients	Preop Mean	Preop Range	6 months postop Mean	6 months postop Range	24 months postop Mean	
Charnley	21	0 81	(0 43–1 01)	0 92	(0 70–1 01)	0.96	(0.5
Muller	33	0 78	(0 34–0 95)	0 93	(0 80–1 00)	0.97	(0.6
Normal						1 00	(0.9

* Velocity index is a ratio of the patient s forward velocity during single-limb-support on the limb to his velocity during single-limb support on the treated limb Patients with bilateral h ment have been excluded

ıENCES

ın Academy of Orthopaedic Surgeons
ɔ) *Joint motion Method of measuring and ding* Academy of Orthopaedic Surgeons, ago

y, J & Ferreira, A de S D (1964) Trans- ation of the greater trochanter in ·oplasty of the hip *J Bone Jt Surg* 46-B, ·197

ɜy, M G (1967) A method for grading *J Bone Jt Surg* 49-B, 644–651

M E. (1970) Total hip prostheses . *Orthop* 72, 46–68

, M. P & Peterson, R M (1973) Weight ribution and weight-shifting activity during *nal standing posture Phys Ther* 53, -748

Murray, M P & Sepic, S B (1968) Maximum isometric torque of hip abductor and adductor muscles. *Phys Ther* 48, 1327–1335

Murray, M. P, Drought, A B & Kory, R C (1964) Walking patterns of normal men *J Bone Jt Surg* 46-A, 335–360

Murray, M P, Kory, R. C & Clarkson, B H (1969) Walking patterns in healthy old men *J Geront* 24, 169–178

Murray, M P., Kory, R C. & Sepic, S B (1970) Walking patterns of normal women *Arch phys Med Rehab* 51, 637–650

Murray, M P, Gore, D R, & Clarkson, B H (1971) Walking patterns of patients with unilateral hip pain due to osteo-arthritis and avascular necrosis. *J Bone Jt Surg* 53 A, 259–274

Seireg, A A H, Murray, M P & Scholz, R C. (1968) A method of recording the time, magnitude and orientation of forces applied to walking sticks. *Amer J phys Med* 47, 307–314

ɔondence to Dr M. P Murray, Kinesiology Research Laboratory/151, Veterans Administration . Wood, Wisconsin 53193, USA

nop scand 50, 571–572, 1979

ſAL BLOOD PRESSURE MEASUREMENT IN /ER-LIMB AMPUTEES

LIND-SØRENSEN & J MARQVERSEN

ment of Orthopaedic Surgery and Section of Nuclear Medicine, The Municipal Hospital, sity of Århus, Denmark

Reamputation above the knee after failure of primary below-knee amputation was related to the distal blood pressure With pressures of 20, 30 and 40 mmHg, two-thirds, one-third and one-seventh, respectively, of the below-knee amputations required reamputation above the knee

Key words amputation level, below knee amputation, distal blood pressure

Accepted 7 ii 79

ower-extremity amputation it is very rtant to save the knee, and thus improve ossibility of walking with a prosthesis. cent years the relative number of above- (A-K) amputations has been declining isson 1964, Burgess et al 1971, Hierton mes 1973, Harris et al 1974, Kolind-nsen 1974, Couch et al 1977, Hutton & nie 1977) Amputation on the crus, how- involves an increased risk of non-healing e stump and secondary amputation above knee, which is of course a severe strain on patient Therefore objective methods to rmine the probability of satisfactory ing of a below-knee (B-K) amputation are reat value and we have, for this purpose, l preoperative determination of the al blood pressure of the skin (Holstein & sen 1973, Lassen & Holstein 1974)

ſIENTS

ing the period 1974–1977 a total of 77 lower-emity amputations were carried out In nine of e cases bilateral amputation was performed, so the number of patients was [illegible] The reason the amputation was arteriosclerosis, co- ting in 17 cases with diabetes mellitus The indication was severe pain or gangrene of the foot The level of the amputation was decided by clinical estimation (Kelly & Janes 1957) Only in cases where the skin of the middle of the lower leg was markedly cold, white or cyanotic, was femur amputation chosen

METHODS

With a hypodermic needle 5 μCi ^{131}J and 0 01 mg histamine chloride was injected into the skin 10 cm below the patella Above the point of injection a water-bag fixed by an ordinary blood pressure cuff was placed

The radioactivity was measured continuously with a scintillation detector, and every 2 minutes the pressure in the cuff was increased in steps of 10 mmHg, until a constant counting speed was registered. The result was given as the lowest pressure, which was capable of stopping the washing out of the injected radioactivity

Crus amputation was performed by sagittal incision (Persson 1974), emphasizing an atraumatic surgical technique, especially concerning the skin

RESULTS

Fifty-six primary B-K amputations were carried out and the number of reamputations

1-647 0 79 050-571 02502.50 0

© 1979 Munksgaard C

Table 1 The amputation level related to the distal blood pressure

Amputation level		Number	Blood pressure		
			≥40	30	≤20
Primary	B-K	56	30	9	17
Reamputation to	A-K	17	4	3	III
Remaining	B-K	39			
Primary	A-K	21	7	3	11
Total	A-K	38			

above the knee were related to the distal blood pressure of the skin (Table 1) When the distal blood pressure was ≤ 20, 30 and ≥ 40 mmHg, two-thirds, one-third and one-seventh, respectively, of the B-K amputations required reamputation above the knee

DISCUSSION

In selecting the level of amputation the aim is to save the patient's knee in as many cases as possible, at the same time avoiding secondary amputation

In gangrenous areas, or where the skin is markedly cold, white or cyanotic, healing is not possible according to common clinical experience, but in all other cases there is a possibility of healing but a risk of reamputation The risk, if great, is perhaps not worth taking in old and frail patients whose prospects of being able to walk again are meagre

A more accurate means of determining the risk is therefore very important Assessment of the distal blood pressure of the skin offers a numerical estimation of the reamputation if a primary B K amp performed

REFERENCES

Burgess, E M, Romano, R L, Zettl, Schrock, R D (1971) peripheral vascular insufficiency *J Surg* 53-A, 874–890

[illegible] Tilney N L & [illegible]

scand, Suppl 69

Harris, P L, Read, F Eardley, A Clark D, Wakefield, J & Sellwood, R (19[illegible] of the elderly amputees *Brit J S* 665–668

Hierton, T & James, U (1973) Lower e amputation *Acta orthop scand* 44, 5

Holstein, T & Lassen N A (1973) Radi clearance technique for measurement blood pressure in skin and muscles *S clin Lab Invest* 31, (Suppl 128), 143

Hutton, M & Rothnie N G (1977) T mobilization of the elderly amputee *Surg* 64, 267–270

Kelly, T J & Janes, J M (1957) Cri determining the proper level of amput *Bone Jt Surg* 39-A 883–891

Kolind-Sørensen V (1974) Follow-up o limb amputees *Acta orthop scan* 97–104

Lassen, N A & Holstein, P (19[illegible]) radioisotopes in assessment of distal bl and distal blood pressure *Surg C Amer* 54, 39–54

Persson, B M (1974) Sagittal incision fo knee amputation *J Bone Jt Surg* 110–114

Correspondence to V Kolind Sørensen, Haslevangsvej 18, DK 8210 Aarhus V, Denmark

op scand 50 573–581 1979

AINFUL CHRONIC ANTERIOR LOWER LEG SYNDROME

ctive Clinical and Experimental Study

DMANN

it of Orthopaedic Surgery, University of Tromsø, Tromsø, Norway

A presumed painful chronic anterior lower leg syndrome was diagnosed in 51 patients (73 legs), 30 women and 21 men, aged 11 to 70 years, over a 2-year period The duration of the syndrome varied from 1 month to 10 years. The

technique in 6 patients suggest that the more severe the syndrome the lower the pressure in the tibialis anterior muscle Blind diathermic fasciotomy in 25 patients (36 legs) with a typical history relieved the pain and paresis completely or partly in 33 (92 per cent) out of 36 legs. No postoperative complications worth mentioning were observed It is concluded that 1) a chronic painful anterior lower leg syndrome should be suspected in patients with pain on walking and at rest located in the ventral part of the lower leg, 2) intracompartmental pressure measurements seem to be of little preoperative

history

Key words compartment syndrome dogs fascia humans, leg, nerve compression syndromes pain, tissue pressure

Accepted 27 11 79

the anterior muscle compartments of r leg on exertion can be caused by a ompartment syndrome Muscle com- syndromes are usually classified ite and chronic forms The acute e is best known and it is usually nized by a progressive increase in in- artmental pressure, which if not by fasciotomy, may eventually lead to of the tissues in the compartment 1975)

ourse of the chronic syndrome is less and it is frequently overlooked very orts are found in the literature 1975). The patient s main complaint is pain in the anterior part of the lower leg on exertion The diagnosis can be made probable by excluding other causes especially affections of the central nervous system and vascular disease However, since increased intracompartmental pressure is supposed to be a central pathogenic factor in both acute and chronic compartment syndromes (Reneman 1968, Matsen 1975) it should be possible to arrive at a diagnosis by measuring the intracompartmental pressure

The aims of the present prospective study were 1) to evaluate the diagnostic usefulness of preoperative intracompartmental pressure measurements in patients with pain of

0 79 050573–09$02.50 0

© 1979 Munksgaard Copenhagen

unknown cause in the medial anterior muscle compartment of the lower leg on exertion and at rest, and 2) to see whether the pain could be relieved by surgical intervention, in this case blind diathermic fasciotomy as outlined by Reneman (1968)

PATIENTS AND METHODS

Patients

The investigation was carried out on 51 patients (73 legs) with pain of unknown cause in the anterior lower leg, who were referred to us in the period May 1976 to May 1978 The patients were non-selected and, unlike Reneman's material (1968), only 2 out of the 51 were military recruits Twenty-nine patients (40 legs), 18 women and 11 men aged 14 to 70 years, underwent blind diathermic fasciotomy, whereas 22 patients (33 legs), 12 women and 10 men aged 11 to 67 years, were not operated on (Figure 1) Operative treatment is planned for only two of these

Precipitating cause of the syndrome

Five patients reported trauma, including fractures, as the apparent precipitating cause of their leg pain, but the remaining 46 were not aware of any cause Two patients had a unilateral chronic painful leg syndrome, with marked neurological findings, after a treated presumed non traumatic compartment syndrome

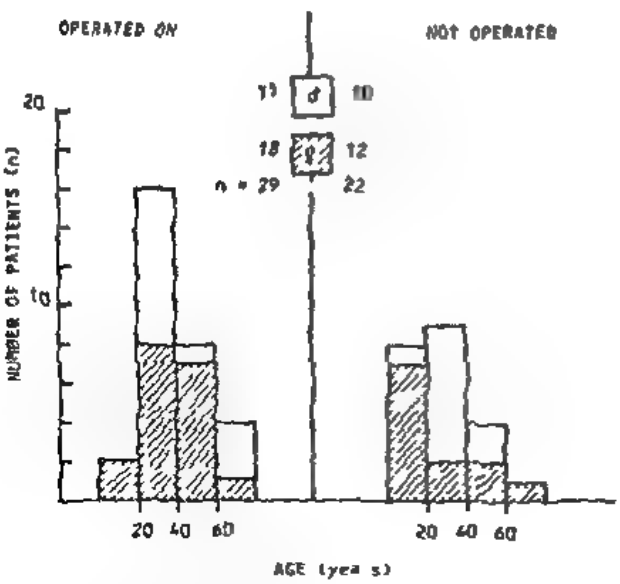

Figure 1 Histogram, left to right In the 29 patients (40 legs) operated on the ages varied from 14 to 70 years, and in the 22 patients (33 legs) not operated on the ages varied from 11 to 67 years

Duration of syndrome

The patients who were operated perienced leg pain for 3 months ■ 15 median 3 years, whereas those not had had leg pain for 1 month to 5 year and 9 months.

Symptoms and findings

The patients' main complaint was pa exertion in the anterior aspect of the lower addition two patients had pain on anterior to the ankle joint and on the the foot Twenty-two had pains in both leg patients (14 legs) had leg pain a by walking Nine patients reported p episodes of oedema in the lower leg downhill sometimes aggravated the pain did the use of high heeled shoes (for women

Slight paresis of the tibialis anter extensor hallucis longus muscles and the extensor digitorum brevis mu in 10 patients (12 legs) and severe pare same muscles in 2 others (2 legs) How in the leg often made muscle testing Hyperaesthesia or hypoaesthesia in web space, corresponding to the sensor the fibularis profundus nerve was noted The symptoms and findings in the patients are listed in Table 1 Neurological were absent in the patients not operated on

Before being referred to us 7 out of patients with lower leg extensor muscle were examined by electromyography nerve conduction velocity in the deep fibu was estimated No significant path findings were observed except in one pa patient who had a unilateral chronic pain syndrome, with pain at rest and paralys extensor muscles, after a conservatively presumed non traumatic subacute muscle partment syndrome In this case electromyogram showed denervation pote the affected tibialis anterior and the e digitorum brevis muscles. An attempt to the nerve conduction velocity in the deep nerve in this patient failed

Selection of patients and diagnosis

All patients who complained of p unknown cause in the anterior medial

Table 1 Preoperative data in 40 legs (29 patients)

f leg pain	No of legs	Neurological findings Sensory	Motor	None
ı exertion	25	5	7	13
rest, ated by walking	14	6	6	3
ıly after g	1	1	1	0
	40	12	14	16

tment of the lower leg on exertion or at ggravated by walking were included in the In addition, four atypical cases were d three patients who complained of post- ıtic pain either in the anterior lateral muscle rtment ventrally to the ankle joint or on the ı of the foot, and one patient who had leg ıly after and not on exertion

r the first few patients had obtained relief pain by blind diathermic fasciotomy ann 1977) the general practitioners and ns in the district were urged to refer such ts to our outpatient clinic. The diagnosis ssumed to be confirmed when fasciotomy elief from pain

s

ays of the lower leg, the ankle and the foot led no significant pathological findings. Four f the six patients, who in addition to lower ıresis also complained of low back pain had ctional lumbar myelography with metrizamide This was normal in all four

volume recordings

cording to Darling et al. (1972) segmental volume recordings are a valuable non- ıve diagnostic technique in vascular disease accordingly made pulse volume recordings) over the middle part of the tibialis anterior le in 12 randomly selected patients with a med chronic leg syndrome and in three ıal subjects. The electronic equipment for recordings was built as outlined by Aashid onal communication) The PVR obtained by ıet-up seemed to be normal

ıcompartmental pressure measurements

rst we estimated intracompartmental pressure e patients (10 legs) either by the manometer needle technique as outlined by Reneman (1968) or by a needle threaded with a nylon wick as outlined by Aukland et al. (1975) However, the measurements were often invalidated by subfascial bleeding caused by the needle (in one patient in four out of five measurements). Furthermore the needle nylon wick technique required about 15 to 20 minutes to obtain equilibrium Finally, neither of the methods allowed continuous measurement or the recording of pressure fluctuations on muscular exertion and they were therefore abandoned After our experiences with these pressure measurements we changed the technique as follows.

Equipment Portex plastic epidural catheters (type 100/380/300 Portex Ltd, Kent, England) were suitably tailored and threaded by hand with a polyglycolic acid wick made from Dexon sutures (Davis & Geck, Hampshire, England) as outlined by Mubarak et al (1976) The wick catheters were resterilized in an automatic formaldehyde autoclave The wick catheter was connected to the sterile disposable dome on a standard AE 840 physiological pressure transducer (A/S Mikroelektronikk, Horten, Norway) The catheter and the dome were first filled with heparinized isotonic saline and the catheter was then introduced subfascially through a standard 16 gauge blunt epidural needle which was thereafter withdrawn. We were able to feel when the needle pierced the fascia. The transducer was operated in conjunction with standard Beckman pressure recording electronic systems (Beckman Instruments Inc, Ill, USA) The patency of the wick was checked by tapping the skin over the wick with a finger If it was patent, immediate pressure jumps would be expected

Canine studies The accuracy and response of the Dexon wick catheter technique was tested in two anaesthetized (pentobarbital 25 mg/kg body weight i v) and intubated Samoyed dogs each weighing about 10 kg We measured pressure in the anterolateral leg compartment as outlined by Mubarak et al. (1976) No physiological pressure

fluctuations were recorded there and so we also measured subfascial pressure in the distal part of the left lumbar region 3 cm lateral to the lumbar spinous processes.

Pressure at rest and pressure fluctuations during the respiratory cycle were recorded. In addition we infused subfascially close to the wick either canine plasma or high molecular weight dextran (Macrodex, Pharmacia, Uppsala, Sweden) in order to increase intracompartmental pressure to a maximum of about 90 mmHg. During the infusion the pressure was registered by the wick technique. Finally we repeated this experiment and recorded pressure fluctuations with the wick technique and with a small solid-state pressure probe (prototype, A/S Mikro-elektronikk, Horten, Norway) simultaneously (see Figure 2). In these experiments we assumed intracompartmental pressure to be equal to the height of the infusion column (Mubarak et al. 1976). At the end of each measuring session we made a skin incision and verified that the wick, probe and infusion needle had penetrated into the muscle.

Human studies. Since we had no Dexon-wick pressure measurements in presumed normal individuals for reference we selected the following patients for intracompartmental pressure measurements because they could serve as their own controls. One group of four male patients of athletic build aged 20 to 45 years who had leg pain on exertion, and one group of two male patients aged 63 and 70 years who had leg pain at rest as well and paresis of the lower leg extensor muscles. One patient in each group was bilaterally affected, but the syndrome was marked only in one leg. In these patients we obtained paired measurements from the right and left legs simultaneously and since one leg was presumably normal (or markedly less affected) this was used as the control. In two additional patients we were not able to obtain paired measurements.

One wick was introduced into each leg in the middle part of the tibialis anterior muscle 3 cm lateral to the tibial crest. The protruding part of the catheter was carefully taped to the skin. Pressure recordings were obtained from the right and left legs simultaneously with the patient prone (resting pressure), sitting, standing plantigrade and standing on the toes and on the heels. Thereafter pressure was recorded immediately after the patient had walked about 1000 steps for 10 minutes in a corridor. Finally pressure was recorded in one leg at a time during and immediately after standardized exertion of the extensor muscles as outlined by Reneman (1968). According to Reneman (1968) valuable diagnostic results can be obtained by determining intracompartmental pressure [illegible] immediately after exercise (P_0) and, for [illegible] minutes later (P_6). Selected pressure [illegible] that is, ΔP_0 (P_0 minus P) and ΔP_1 (P_1 [illegible] P_0), are supposed to be more valuable [illegible] parameters than the absolute pressure [illegible] (Reneman 1968).

Muscle biopsies and fasciotomy.

Peroperative biopsies were taken [illegible] proximal part of the tibialis anterior [illegible] eight randomly selected patients. The [illegible] were placed in isotonic saline [illegible] and stained by ATPase and ordinary [illegible] There were no significant pathologic[illegible]

Blind diathermic fasciotomy over the anterior muscle was performed as [illegible] Reneman (1968). By means of a [illegible] we passed an insulated wire beneath the [illegible] from a small proximal to distal skin incision [illegible] we passed the probe and the wire back [illegible] the subcutaneous tissue to the proximal [illegible] fascia was thus encircled by an [illegible] diathermic sling. We made a small cut the [illegible] insulation at the distal end of the sling so [illegible] wire could cut the fascia when the [illegible] pulled from the proximal end. The [illegible] fascia was elongated proximally and [illegible] (including the extensor retinaculum) with [illegible] scissors. The deep fibularis nerve was [illegible] for (in the distal wound).

Indications for operative treatment and f[illegible]

Fasciotomy was considered the treat[illegible] choice in patients with 1) neurological de[illegible] with leg pain at rest and 3) with leg [illegible] exertion which hindered the patient's [illegible] physical activity. Thirty-one (61 per cent) [illegible] 51 patients fulfilled these criteria [illegible] advised to undergo operative treatment. [illegible] nine out of the 31 have now been operated [illegible] the postoperative observation periods ran[illegible] months to 2½ years.

RESULTS

Intracompartmental pressure recording[illegible]

Canine studies. With the Dexon-wick [illegible] technique we registered a normal [illegible] tracompartmental pressure of 2–3 mm [illegible] the leg. Pressure measurements in the [illegible] varied with the respiratory cycle from [illegible]

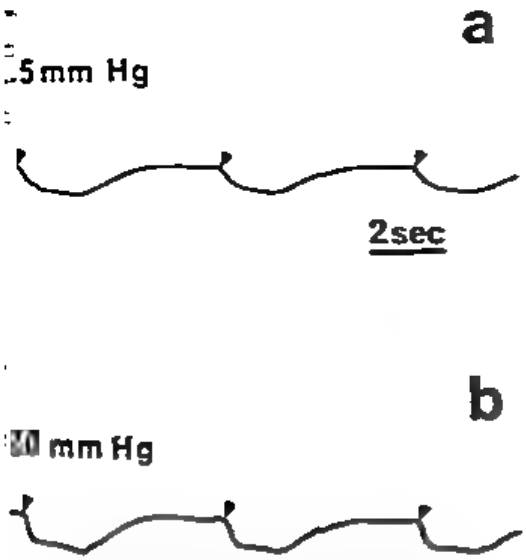

2 Simultaneous registration of in-partmental pressure as measured with the -wick technique (a) and a solid state re probe (b) during respiration. It should be that this registration was obtained during ated infusion. Arrowheads indicate start of ation

.0 + 4 mmHg The pressure was highest diately after expiration and fell rapidly to zero on inspiration. The response of the was slightly slower than that of the solid-pressure probe (Figure 2). The pressure



re 3 Scatter diagram. Six different heights of infusion column are plotted against the cor nding pressure readings as measured with the on-wick technique The intracompartmental ure as measured with the Dexon-wick cor ted well with the height of the infusion mn. Insert shows relative position of wick tion needle and solid state pressure probe

measured with the wick technique correlated well (r 0 99) with the height of the infusion column (Figure 3) and with the solid-state pressure probe (r = 0 98, Figure 4)

Human studies Although they were carefully taped to the skin of the leg, some Dexon wick catheters slid out on muscular exertion. When this happened the pressure fluctuations on exertion were reduced as compared to intracompartmental recordings in the same leg A new wick was then inserted in the usual way Two pressure increments, ΔP_e, after standardized extensor muscle exertion (Reneman 1968), were invalidated by a blood clot in one contralateral catheter

The pressure varied considerably according to the patient's position and activity, ranging from −4 to +124 mmHg The resting pressure varied from −2 to +16 mmHg (Figure 5).

In the four athletic patients aged 20 to 45 years with leg pain on exertion we found that the pressure in the more painful leg was

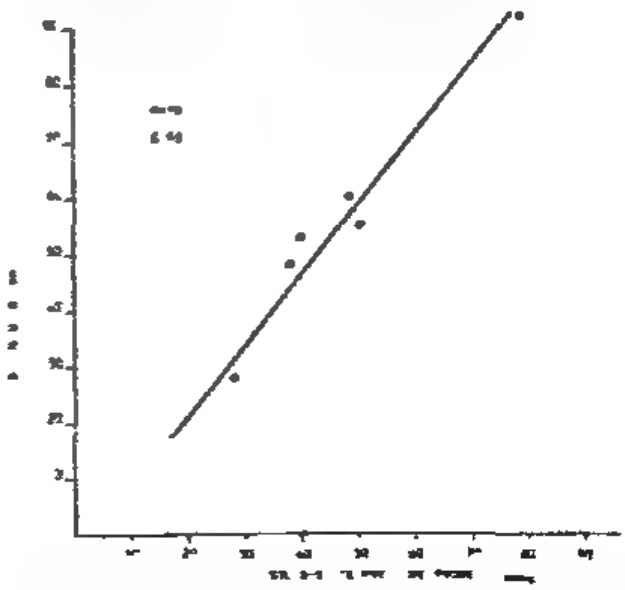

Figure 4 Scatter diagram. Simultaneous pressure measurements with the Dexon-wick and a solid state pressure probe Six different pressure readings as measured with the solid state pressure probe are plotted against the corresponding readings as measured with the Dexon-wick technique Intracompartmental pressure as measured with the wick correlated well with that of the solid state pressure probe.

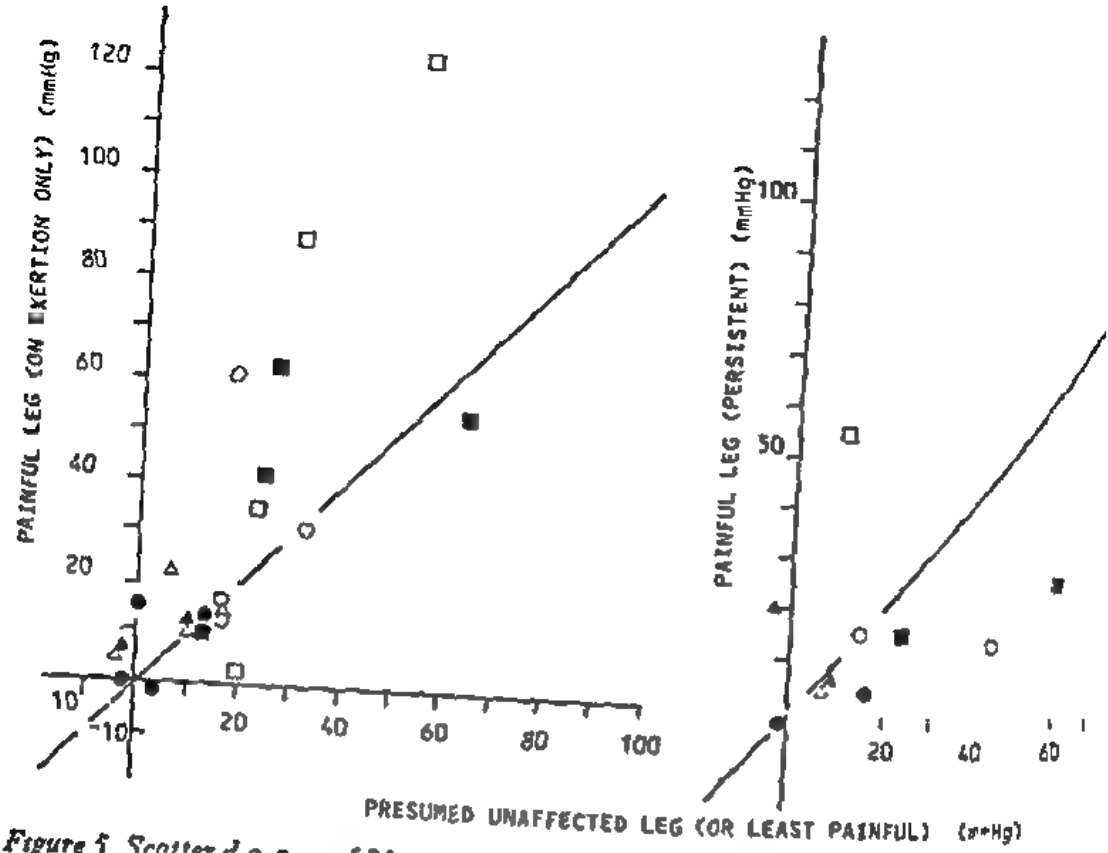

Figure 4 Scatter d
the
con
the
patients in two patients with pain at rest as well (right)
●=resting pressure, △=sitting, ○=standing plantigrade, ■=standing on the toes, □ stan
heels, ▲=△P_e(see text)

higher (Figure 5), whereas in the two patients aged 63 and 70 years with pain at rest and paresis of extensor muscles the pressure was mostly found to be lower in the more painful leg (Figure 5)

With our technique, the absolute pressure measurements in the painful legs of the four athletic patients were higher than registered in the two older patients, this was not so in the less painful legs (Figure 5)

The pressure increments, ΔP_e after minutes walk in a corridor varied from +9 mmHg No special trend was noted

Table 2 Pain relief by fasciotomy in 40 legs (29 patients)

Type of pre-operative pain	Relief from pain			No of legs
	Complete	Partial	None or worse	
Pain on exertion	17	3	5	25
Pain at rest, aggravated by walking	11	3	0	14
Pain only after walking	0	0	1	1
No of legs	28 (7[illegible]%)	[illegible]%)	6 (15%)	40 (1[illegible])

·lief by fasciotomy

ıotomy relieved leg pain both at rest ı exertion completely or partly in 34 (85 ɔt) out of 40 legs operated on Six legs r cent) did not improve (Table 2) We ɔlanned an open fasciotomy in one of patients, who was bilaterally affected, ■ blind fasciotomy seemed ■ give ɛte relief from leg pain at rest and on ɔn in one leg, but not, for some reason, other If four patients (four legs) with ɾpical history are excluded, fasciotomy ·d pain completely or partly in 33 (92 ·nt) out of 36 legs The relief from pain ɔciotomy was most dramatic in the 10 ı its with pain at rest

ciotomy relieved the paresis of extensor —es in all patients except one, who — e pain relief in the lower leg — had not ıed function in her paralysed muscles 8 ·ns after the operation We had the im- ıon that the distal part of the fascia con- ·ed more than the proximal part to the ·enance of the painful syndrome

ro patients experienced severe constant ɔ of unknown cause in the leg after the tion One of these patients recovered aneously, the other was not relieved of eg pain by the fasciotomy No other ıperative complications were noted

CUSSION

ıtient with low back pain and pain and le paresis on exertion on the lower leg present a difficult diagnostic problem ·tions of the central nervous system and ·ular disease should be excluded before ɔrming a minor operation like fasciotomy he leg On the other hand, ■ is essential xclude a chronic lower leg compartment ırome before embarking on a major ation such ■ laminectomia for a umed lumbar spinal stenosis or a disc ıation.

ffections of the central nervous system · here ruled out by a thorough neurological clinical investigation in all patients. In addition, patients with severe neurological deficits were examined by functional myelography Furthermore, a non-invasive screening test such as pulse volume recording made vascular disease unlikely in randomly selected patients.

In the chronic compartment syndrome neither oscillometry, electromyography and arteriography at rest and during pain nor phlebography before and after exertion seem to be of any diagnostic value (Reneman 1968) It might thus be assumed that a chronic compartment syndrome can only be diagnosed by excluding other causes. Since increased intracompartmental pressure is supposed to be the principal pathogenic factor in a compartment syndrome (Matsen 1975), intracompartmental pressure measurements seem to be a valuable diagnostic aid (Reneman 1968) However, the trend in our estimates of the intracompartmental pressure in the few patients tested suggests that the more severe and painful the syndrome, the lower the pressure registered Nevertheless, most of the patients we operated on were relieved from pain by fasciotomy, which is thought to relieve the symptoms in both acute and chronic compartment syndromes (Reneman 1968, Matsen 1975) Furthermore, the greater the pain our patients experienced preoperatively, and thus the lower the pressure recorded, the more dramatic the relief from pain by fasciotomy How can these apparently paradoxical observations be explained?

With the exception of a few case reports (see Reneman 1975), only one published clinical study could be found describing the *chronic* anterior compartment syndrome of the leg (Reneman 1968) Reneman's material seems to consist of 51 patients, 49 men and 2 women Most of them were young male military personnel (median age 21 years) Reneman's patients were thus highly selected None of his patients had constant pain at rest or any neurological deficits The results of his pressure measurements, estimated by the

needle-manometer technique, indicate that the normal rise in intracompartmental *pressure on exertion is significantly reduced* with increasing age, and he found a significantly higher pressure in men as compared to women and in patients as compared to presumed normal persons in the same age group Furthermore, the pressure increase Reneman found after a standardized muscle exertion normally fell to the resting *value (about zero mmHg) within 6 minutes,* whereas in patients the pressure fall was significantly slower within the same period of time Reneman therefore claims that pressure measurements are a valuable diagnostic aid

The wick technique is supposed to measure interstitial pressure, while the needle-manometer technique is supposed to measure *total intramuscular pressure (Scholander et al* 1968, Reneman 1968, 1975)

The Dexon-wick technique seems to be a fairly useful and reliable method for estimating intracompartmental pressure (Mubarak et al 1976) Our measurements in dogs support this contention (Figures 2–4) However, in the author's opinion these *pressure measurements are only an estimate* — or index — of intracompartmental pressure Furthermore, we did not verify the actual position of the wicks in patients as we did in the animal experiments The results of our measuring sessions suggest, however, that the wicks were located subfascially and not subcutaneously

Our paired pressure measurements suggest that the more severe the syndrome, the lower the pressure (Figure 5) Since forceful muscular contractions are supposed to increase intracompartmental pressure (Reneman 1968), these observations may be explained by the fact that the more severe the syndrome in our patients, the less forceful the muscle contractions, owing to pain and paresis, and thus the lower the pressure This contention is supported by eight paired intracompartmental Dexon-wick pressure recordings measured as outlined above in a 63-year-old man, who contracted unilateral painless drop foot of unknown [illegible] paralysed leg the maximum [illegible] *registered was 2 mmHg* [illegible] other, presumedly normal leg [illegible] mmHg (unpublished data)

In a young athletic patient with a [illegible] history the diagnosis presented no [illegible] and the indications for fasciotomy [illegible] solely on the patient's failing [illegible] manage everyday activities including [illegible] *Although a relatively high* [illegible] recorded (Figure 5) pressure measurements seem thus to be of little diagnostic [illegible] such patients. In contrast in a middle- or elderly person, with for example, low back pain, leg pain at rest and paresis of the muscles of the lower leg the diagnosis may in many cases be very [illegible] *In the two patients* tested with the Dexon technique the pressure seemed to be lowest the most painful leg These observations suggest that increased pressure within whole medial muscle compartment of the leg was not a main pathogenic factor in two patients Thus, paradoxically tracompartmental pressure measurements *seem to be of least* diagnostic aid when they most needed Furthermore, in selected patients neither electromyography of leg muscles nerve conduction velocity measurements deep fibular nerve were of any diagnostic [illegible]

Most of our patients were relieved of pain by fasciotomy, often quite dramatically Since fasciotomy is supposed to relieve not only in compartment syndromes (Reneman 1968, Matsen 1975), but also anterior entrapment syndrome (Kurtz [illegible] an anterior entrapment syndrome of the might also be considered

The anterior entrapment syndrome [illegible] lower leg is supposed to be caused by [illegible] or indirect trauma causing entrapment [illegible] deep fibular nerve where it passes under [illegible] extensor retinaculum (Kopell & Thompson 1976, Kurtz 1976) The initial symptoms signs are supposed to be located in the [illegible] the nerve distal to the entrapment but retrograde pain may occur Further

[illegible] local secondary autonomic dysfunc- may be encountered (Kopell [illegible] pson 1976, Kuritz 1976) Only 5 of the [illegible] tients investigated here reported trauma [illegible] apparent precipitating cause of their [illegible] un, and the initial pain was usually [illegible] in the leg and not on the dorsum of [illegible] foot Moreover, the more severe [illegible] ogical deficits registered here were [illegible] to the proximal and not to the distal [illegible] of the deep fibular nerve Thus, the [illegible] l leg syndrome — or syndromes — of [illegible] atients do not seem to fit either the [illegible] ption of the anterior entrapment [illegible] ome as outlined by Kuritz (1976) or the [illegible] c anterior leg compartment syndrome [illegible] utlined by Reneman (1968) and the [illegible] ogy and pathophysiology of the leg [illegible] ome in our non-selected patients seem [illegible] re

[illegible] ght pressure on a previously sensitized [illegible] is supposed to cause pain by fibre in- [illegible] on (Granit [illegible] al 1944) These [illegible] vations may suggest that slight pressure [illegible] or within — the deep fibular nerve in [illegible] ompartment may be a pathogenic factor [illegible] atients with a painful anterior lower leg [illegible] rome

NOWLEDGEMENTS

[illegible] grateful to Rune Aaslid, Division of [illegible] eering Cybernetics, University of [illegible] dheim, Trondheim, who constructed and [illegible] the electronic equipment necessary for the pulse volume recordings, and to Jens Dagfinn Hansen, University of Tromsø, for technical assistance in tissue pressure measurements

REFERENCES

Aukland, K, Fadnes H O & Johnsen, H M (1975) Protein concentration and oncotic pressure of interstitial fluid collected by wick technique *Biol anat Basel* **13**, 43–46

Darling, R C, Raines, J K, Brener, B J & Austen, W G (1972) Quantitative segmental pulse volume recorder A clinical tool *Surgery* **72**, 873–887

Granit, R, Leksell, L & Skoglund, C R (1944) Fibre interaction in injured or compressed region of nerve *Brain* **67**, 125–140

Kopell, H P & Thompson, W A L (1976) *Peripheral entrapment neuropathies* 2nd ed pp 35–38 Krieger, New York

Kuritz, H M. (1976) Anterior entrapment syndromes. *J Foot Surg* **15**, 143–148

Matsen, F A (1975) Compartmental syndrome A unified concept *Clin Orthop* **113**, 8–14

Mubarak, S J, Hargens, A R, Owen, C A, Garetto, L P & Akeson W H (1976) The wick catheter technique for measurement of intramuscular pressure A new research and clinical tool *J Bone Jt Surg* **58-A**, 1016–1020

Reneman, R S (1968) *The anterior and the lateral compartment syndrome of the leg* Mouton The Hague

Reneman, R S (1975) The anterior and the lateral compartmental syndrome of the leg due to intensive use of muscles. *Clin Orthop* **113**, 69–80

Scholander, P F, Hargens, A R & Miller, S L. (1968) Negative pressure in the interstitial fluid of animals. Science **161**, 321 328

Sudmann, E (1977) Chronic anterior compartment syndrome of the leg (Abstract) *Acta orthop scand* **48**, 555

[illegible] spondence to Einar Sudmann, M D, Hagevik Orthopaedic Hospital, University of Bergen, N 5220 [illegible] rik, Norway

op scand 50 583–591, 1979

ITEAL CYSTS (BAKER'S CYSTS) IN ADULTS. I.

al and Roentgenological Results of Operative Excision

GANG RAUSCHNING & PER GUNNAR LINDGREN

ments of Orthopaedic Surgery and Diagnostic Radiology,
sity Hospital, Uppsala, Sweden

Forty patients were re-examined between 6 months and 15 years (mean 4 years) after excision of a popliteal cyst Forty-six operations had been performed, including one bilateral cyst and five recurrent cysts The history was reviewed with respect to the preoperative symptoms, clinical and roentgenological signs, the operative and histopathological findings and the postoperative course Fifteen operations were followed by wound healing complications or tense swelling of the calf simulating deep venous thrombosis At clinical follow-up a recurrent cyst was found in 63 per cent of the knees. A simplified follow-up arthrography was performed in all knees, and revealed a cyst-like cavity in all but one knee The majority of the recurrent cysts displayed irregularities of the wall that had not been seen in the preoperative arthrograms.

Despite this high rate of recurrence most of the patients had fewer symptoms from the popliteal space at the time of follow-up than before the operation

As associated knee disorders were present in the majority of patients, popliteal cysts (Baker's cysts) should be regarded and, if possible, treated as secondary to the basic pathological condition of the joint Only if the knee disorder is not curable and if the symptoms from the popliteal region are troublesome should excision of the cyst and tight closure of the communication with the joint be considered

Key words popliteal cyst, Baker's cyst, postoperative results, associated knee disorders, follow-up arthrography, recurrent cyst formation

Accepted 14 III 79

than 200 popliteal cysts are operated annually in Sweden (Lindgren 1978) It he experience of many surgeons that iteal cysts frequently reappear after ation (Harvey & Corcos 1960, Childress Vahvanen 1973), while others consider excision more beneficial (Haggart 1943, erding & van Demark 1943 Burleson et 1956) Since we have observed several rrences following routine excisions of liteal cysts, we considered it of interest to xamine a series of patients in this respect

The first part of this retrospective investigation consists of a preoperative survey concerning the type of trauma, symptoms and clinical signs from the popliteal space and associated knee disorders, and also the findings at operation and the postoperative course The second part comprises a clinical follow-up examination and a simplified arthrographic investigation of all patients

The aim of this study was to compare the clinical and roentgenological features before the operation and at follow-up, and to analyse

647079 050583–09$02.50 0

© 1979 Munksgaard Copenhagen

Table 1. Grading of symptoms from the knee joint. A patient was assigned to the [illegible] or she fulfilled three or more parameters

0	No swelling No pain No instability or weakness No limitation of movement No limitation of work or participation in sports
I	Slight swelling Slight discomfort *following strenuous exercise* Some giving-way or weakness, muscular atrophy < 1 cm Negligible limitation of movement < 10° No hard labour, no elite sports
II	Moderate swelling [illegible] trophy 1–2 cm [illegible] No physical work, limited participation in sports
III	Considerable and tense swelling [illegible] *pain at rest* [illegible] > 2 cm [illegible] Stopped working because of knee derangement, no sport

the postoperative complications. The mode of recurrent cyst formation and the operative technique are discussed.

PATIENTS AND METHODS

During the period 1961–1976, 48 patients were operated on for a popliteal cyst (in five cases for a recurrence) at the Department of Orthopaedic and General Surgery in Uppsala and in two Uppsala County hospitals.* Forty of these patients were available for the investigation. As one patient had bilateral cysts the material consisted of 41 knees – 17 right and 24 left.

Thirty-three of the patients were males and seven females. Their age at the time of operation varied from 13 to 76 years (mean 46.8 years). At re-examination the ages ranged from 17 to 77 years (mean 50.8 years). The average interval between the operation and the follow-up was 4 years (range 6 months to 15 years).

*Samariterhemmets sjukhus and Enkopings sjukhus

Case histories

The case records were reviewed wi[illegible] attention to any history of knee tr[illegible] previous knee operations, and to the r[illegible] from the knee joint and the popliteal w[illegible] preoperative *joint symptoms* were g[illegible] shown in Table 1, according to swelling, stability, limitation of movement, and [illegible] work and participate in sports. The [illegible] *symptoms* were divided into four ca[illegible] when there was no swelling or pain, [illegible] some swelling occurred only during or [illegible] strenuous use of the joint, causing [illegible] comfort, "II" when swelling occurred [illegible] after normal activities, causing tenderne[illegible] knee flexion and extension but not [illegible] range of movement, "III" when the[illegible] constant tense swelling of the popl[illegible] causing considerable tenderness and pa[illegible] limited the range of movement.

Histopathological examination and p[illegible] arthrography

Seventeen cysts had been e[illegible] histologically and these were reexam[illegible] pathologist with regard to the presence [illegible] of inflammatory changes and fibrosis [illegible] walls.

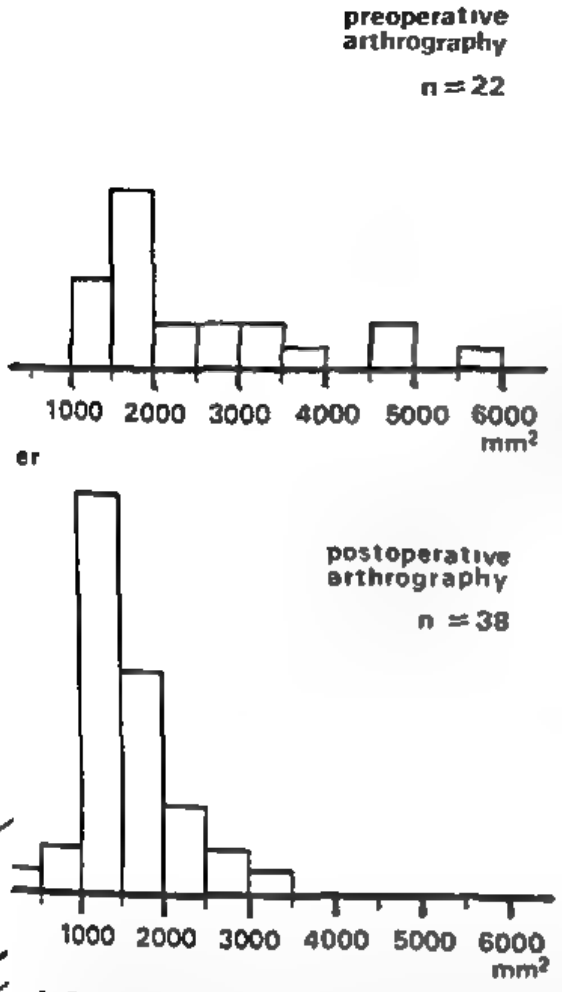

e 1 Radiographic size of the communicating teal cavities before operation and at follow-up (see Methods)

22 knees arthrography had been performed to operation On these radiographs the ast filled gastrocnemius-semimembranosus was examined. In the lateral view the shape wall configuration of the bursa were studied ts length and sagittal width were measured product of these dimensions was used as an ation of the size of the bursa (Lindgren).

ical and radiographic follow-up

all cases clinical examination of the popliteal n was performed, and the knee joint was also ined for any associated disorders. The nts were asked about preoperative symptoms the knee joint and popliteal region, and t the postoperative course and the present ptoms, which were classified in the same way lescribed above If relevant, additions were made to the case records In cases where a distinct localization was possible the pre- and postoperative symptoms were assigned to the medial or lateral aspect of the knee, the patellofemoral region and the popliteal space When the symptoms were diffuse or difficult to localize they were referred to the whole joint (Table 2)

At follow up all knees were examined radiographically 10–15 ml of Urografin 45 per cent was injected into the joint After the injection the knee was flexed without the use of force or resistance to about 90° and the movement of the contrast medium was studied by fluoroscopy with the patient lying on his side One or two radiographs were taken in this lateral projection Whenever a contrast filled cavity communicating with the joint was observed in the popliteal space it was compared with the bursa in the preoperative arthrogram with respect to size (Figure 1), configuration and outline

RESULTS

Preoperative – case history, symptoms and arthrography

In 34 knees there had been symptoms from the popliteal space (for less than 6 months in 9 cases, 6 months to less than 2 years in 17 cases and more than 2 years in 8 cases), and in 7 knees there had been symptoms from the joint but none from the popliteal space Effusion was observed in 9 knee joints, this was uncertain or not commented upon in 4 joints and no effusion was found in 28 joints A cystic swelling in the popliteal region was noted in 24 knees, there were no cysts in 10 knees and in 7 knees the physical signs were uncertain or not recorded

The 22 preoperative radiographs showed communicating gastrocnemio-semimembranosus bursae of varying sizes (Figure 1) Eleven had a smooth wall (Figure 2) and the other 11 were lobulated to a varying extent

Twelve patients had a history of trauma preceding the onset of the popliteal symptoms. Anterior synovectomy had been performed on [redacted] patients (2 years and 4 weeks,

Figure 3(A–D) Recurrent communicating cavities at the site of the preoperative bursa at the arthrography

A Marked lobulation of the cavity wall

B Blurred outline in the lower portion

C Irregularity, diverticula formation and some leakage of contrast medium at the upper

D Slightly lobulated wall resembling a normal gastrocnemio-semimembranosus bursa (cf Figure

of follow-up arthrography

) of the 41 follow-up arthrograms the int was seen to communicate with a at the site of the primary bursa Two e cavities could not be measured, for al reasons. Nineteen recurrent cavities be compared with the primary cysts ere smaller and 9 were about the same igure 1) Eight of the 10 patients in the cavity had diminished had milder oms at the time of re-examination The ity of the recurrent cavities displayed an ll wall contour, moderate irregularity of ll was noted in 15 cavities and marked anty in another 15 (Figure 3, A–C) 10 were slightly lobulated thus resem- the shape of the normally occurring (Figure 3 D) In the recurrent cavities, ssions of the gastrocnemius and semi- ranosus tendons were consistently ed, as are seen in gastrocnemio-semi- ranosus bursae (Figure 2)

USSION

eal cysts are usually regarded as dary to intra-articular knee disease ng effusion (Baker 1877) It might thus pected that cure of the intra-articular der will abolish the symptoms from the (Gristina & Wilson 1964, Childress).

one of our patients a meniscectomy was rmed at the cyst operation Another nt had undergone synovectomy and a patient meniscectomy 1 month prior to on of the cyst The other 38 knees seen he follow-up had undergone no surgery from the operation on the cyst

cept for one case, follow-up rography disclosed a communicating ty at the site of the primary cyst ntgenologically all cysts in which the ule had been closed, recurred This would us to expect renewed symptoms from the iteal space The results of this study, however, revealed a marked reduction of the popliteal symptoms at follow-up The majority of patients obviously benefited from the excision of the cyst

It is not known how the walls of the recurrent cavities develop Radical excision of the whole cyst is reputedly difficult Presumably, remnants will be left in the deep portion, which by outgrowth of synovial lining cells could form a new cyst

If the capsular opening is not tightly closed, increased intra-articular pressure due to postoperative effusion will pump synovial fluid out of the joint This might stimulate the mesenchymal cells of the interstitial tissue to become transformed into synovial lining cells to form an encapsulating barrier The morphological findings at the arthrographic follow-up support the view that the recurrent cavities grow stepwise by repeated wall rupture and encapsulation, thus forming a wall structure with numerous diverticulae (Figure 3) This uneven wall contour might also be due to postoperative changes such as scar formation A histopathological investigation of recurrent popliteal cysts would render further information on this matter

Synovial fluid outside the joint is known to have tissue-irritating properties, which might account for the high rate of wound-healing complications. It has been reported that an escape of synovial fluid to the deep compartments of the calf causes symptoms simulating deep vein thrombosis (Dixon & Grant 1964, Good 1964, Hughes & Pridie 1970) This would explain the postoperative calf swelling and tenderness in 6 of the patients in this series

The high rate of recurrence may be due to the following factors Firstly, the commonly used incision over the most prominent part of the swelling provides a poor view of the communication due to the overlapping gastrocnemius and semimembranosus muscles. Secondly, closure of the communication is difficult, owing to the absence of a pedicle Recent dissection studies have shown that the communication consists of a transverse slit located at the site where the gastrocnemius

tendon merges with the capsule (Lindgren & Willén 1977) Thirdly, catgut can hardly withstand the high fluid pressures occurring in joints with effusion during normal activities (Grant & Dixon 1963, Dixon & Grant 1964, Jayson & Dixon 1970) and the considerable tearing forces from the tendons in this region A tight closure of the capsule with non-absorbable material may improve the results.

CONCLUSION

In the reviewed series of 41 popliteal cyst excisions the rate of postoperative morbidity, wound healing complications and calf swelling was high At clinical re-examination 63 per cent of the patients had a recurrent cyst, but most of them reported relief of popliteal symptoms The follow-up arthrograms revealed communicating cyst-like cavities in all cases but one, although in the majority of operations closure of the capsule had been attempted

In view of the fact that Baker's cysts* are regarded as secondary to an intra-articular lesion (Doppman 1965), their presence should initiate a thorough knee examination in which arthroscopy (Casscells 1971) may add valuable diagnostic information to the clinical and arthrographic findings Only if the associated derangement of the knee joint is not curable and if the symptoms from the popliteal region are troublesome should atraumatic excision of the cyst and tight closure of the communication be considered

ACKNOWLEDGEMENTS

This investigation was supported by the Swedish National Association against Rheumatism

The authors wish to thank Dr Erik Wilander for re-examining the histopathological specimens.

*The eponym 'Baker's cyst' should only be used when a communicating gastrocnemio-semimembranosus bursa seen at arthrography causes clinical symptoms.

REFERENCES

Baker, W M (1877) The formation of cysts in the leg in connection with dis the knee joint *St Bart. Hosp. R.* 245–261

Burleson, R J, Bickel, W H & Dahl (1956) Popliteal cyst A clinicopath. survey *J Bone Jt Surg* 38 A, 1265-12

Casscells, S W (1971) Arthroscopy of the joint *J Bone Jt Surg* 53 A, 28 38

Childress, H M (1970) Popliteal cysts with undiagnosed posterior lesions medial meniscus. *J Bone Jt Surg* 1487–1492

Dixon, A & Grant, C. (1964) Acute rupture in rheumatic arthritis Clinical experimental observations. *Lancet* 4, 74

Doppman J L (1965) Baker's cyst and normal gastrocnemio-semimembranosus *Amer J Roentgenol* 94, 646–6

Good, A E (1964) Rheumatoid arthritis cyst, and "thrombophlebitis" *Rheum* 7, 56–64

Grant, C & Dixon, A (1963) Synovial and intraarticular pressure during joint *Arthr and Rheum* 6, 274

Gristina A G & Wilson, P D (1964) cysts in adults and children 4 cases *Arch Surg* 88, 357–363

Haggart, G E (1943) Synovial cysts popliteal space Clinical significance ment *Ann Surg* 118, 439–444

Harvey, J P & Corcos, J (1960) Lower lower leg originating in the knee patients with rheumatoid arthritis *Rheum* 3, 218–228

Hughes, G R & Pridie R B synovial rupture of the knee diagnosis from deep vein thrombosis *roy Soc Med* 63, 587–590

Hultén, O & Gellerstedt, Abnutzungsprodukte in Gelenken Resorption unter dem Bilde detritica *Acta chir scand* 84,

Jayson, M I V & Dixon, A St J articular pressure in rheuma knee III Pressure changes *Ann Rheum. Dis* 29, 401–408

Lindgren, P G & Willén, Gastrocnemio-semimembranosus relation to the knee joint histology *Acta radiol. (Stockh)* 18,

Lindgren P G (1978) — sidérations. *Acta radiol. (Stockh)* 609–622.

ng, H W & van Demark, R E (1943) rior hernia of the knee (Baker's cyst, teal cyst, semimembranosus bursitis, al gastrocnemius bursitis and popliteal bursitis) *J Amer med Ass* **122**, 858–861

Vahvanen, V. (1973) Popliteal cyst A follow-up study on 42 operatively treated patients *Acta orthop scand* **44**, 303–310

ondence to Wolfgang Rauschning, M D, Department of Orthopaedic Surgery, University d, S–750 14 Uppsala, Sweden

ɔop scand. 50, 593 598, 1979

AL SHAFT FRACTURES

requency of Local Complications in Tibial Shaft Fractures ed by Internal Compression Osteosynthesis

TAN D KRISTENSEN

.ment of Orthopaedic Surgery, Hjørring Hospital, Denmark

Ninety-two tibial shaft fractures in 90 patients over the age of 15 were treated by compression osteosynthesis according to the AO method, but using plates and screws of Vitallium* Fifteen fractures (14 patients) were excluded, because the follow-up period was less than 12 months. The frequency of complications in the remaining 77 fractures, 44 per cent comminuted and 30 per cent open fractures, were skin necrosis over the osteosynthesis material 5 2 per cent, osteitis 1 3 per cent, delayed osseous healing necessitating secondary operation 2 6 per cent, loosened screw (not requiring secondary operation) 5 2 per cent, loosened screw + refracture 1 3 per cent, plate bending 1 3 per cent, plate fractured 1 3 per cent, and refracture after removal of the plate (new relevant traumas) 4 8 per cent In this series there was a markedly high frequency of complications in comminuted fractures with laceration of skin and muscles, whereas an increased tendency for complications to develop in the remaining injury groups was not seen

Key words AO compression osteosynthesis, delayed healing infection, postoperative, refracture, tibial shaft fractures

Accepted 27 ii 79

re is no ideal method of treatment for ıl shaft fractures but there are several arently equally valuable methods available miento 1974, Bauer & Hulth 1973, lström & Olerud 1973) The various hods of treatment should therefore be jected to critical examination based on extence with large groups of patients but iparison is complicated by the different ice of treatment in the various centres this reason it is necessary that a greater nber of smaller series be used to assess a thod of treatment, despite the known ficulties in obtaining clear definitions.

This is a retrospective investigation of ıal shaft fractures treated by compression eosynthesis according to the AO method üller et al 1965, 1970), but using plates and screws of Vitallium* The purpose has been to examine the frequency of osteitis, delayed osseous healing, and refractures prior to and after removal of the plate According to some reports (Wade 1970, Bauer & Hulth 1973, Sarmiento 1974, Brown 1974), these complications occur with an unacceptable frequency

PATIENTS AND METHODS

During the 9-year period 1968–1976 183 fractures of the shaft of the tibia, in patients over the age of 15, were treated at the Department of Orthopaedic Surgery, Hjørring Hospital, Denmark Ninety-two (50 3 per cent) were treated by compression osteosynthesis 30 (16 4 per cent) were treated with other operative methods (osteotaxis with the Hoffman apparatus (13 cases)

11-6470/79 050593 06$02.50/0

© 1979 Munksgaard Copenhagen

lag-screws, Rush pins, Eggers plates and one primary amputation) and 61 (33 3 per cent) were treated conservatively with, if necessary, closed reduction and immobilization in a high plaster cast

Of the 92 tibial shaft fractures (90 patients) treated by compression osteosynthesis 15 in 14 patients were excluded because they had not been followed for at least 12 months There were nine "tourists" who received secondary treatment elsewhere, three older patients (four fractures) who were dependent on continuous nursing care and two patients who died for reasons other than the fracture and the osteosynthesis. After exclusion of the above patients the material comprised 77 fractures

The age and sex distribution ■ shown in Figure 1 Sixty-six fractures (85 8 per cent) were purely diaphyseal fractures, nine (11 7 per cent) also involved the distal metaphysis and two (2 6 per cent) the distal articular surface All the 77 fractures were displaced Table 1 lists the classification according to Edwards (1965) Longitudinal fractures were defined as fractures in which the fracture line formed an angle of less than 45° with the long axis of the diaphysis, transverse fractures were those with an angle of more than 45° Almost 60 per cent were transverse fractures Comminuted fractures were defined as fractures with a least one intermediate fragment than half the diameter of the diaphysis (17 6 per cent) of the comminuted segmental Twenty-three (29 5 per cent) open fractures. 16 (20 8 per cent) with perforation and 7 (9 1 per cent) with muscle laceration Forty-seven per cent comminuted fractures were open transverse fractures.

Eighty-two per cent of the fractures operated on within 10 hours after Osteosynthesis in the remaining fractures performed within 14 days. T performed by 12 surgeons. Plates and vitallium were used as axial lag-screws combined with neutralization Most of the plates were applied to the surface In two comminuted fractures bone autografts were used in the operation to fill bone defects In open systemic antibiotics (penicillin, administered beginning pre- or perioperatively continuing for about 3 days or less operatively Most patients had post supplementary plaster splintage for 10 days that a complete exercise programme was Full weight bearing was allowed when the clinically and roentgenologically was consolidated be solid enough for walking without crutches

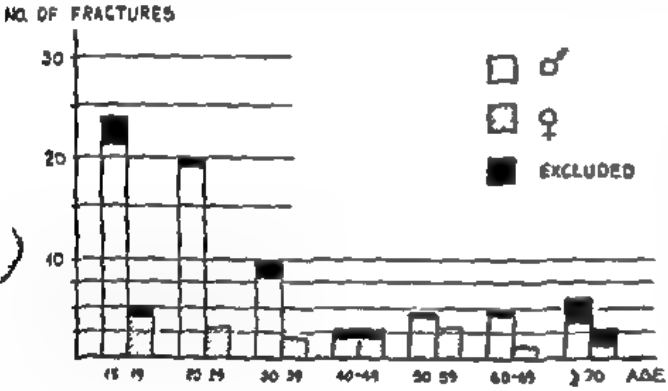

Figure 1 Age and sex distribution

RESULTS

Local complications which prolong healing time are presented in T Circulatory disturbances did not problems Compartment syndromes seen

Skin necrosis over the osteo material was observed in four cases patients the implants were removed

Table 1 Classification of tibial shaft fractures

		No of fractures	Percentage of whole material	No of comminuted fractures	Per of
Longitudinal	closed	24 (28)	31	10 (11)	
	open	7 (9)	9	5 (6)	
Transverse	closed	30 (36)	39	8 (8)	
	open	16 (19)	21	11 (13)	
Total		77	100	34	

(—) before exclusion of 15 fractures.

Table 2 Local complications following compression osteosynthesis in 77 fractures

	Longitudinal fractures		Transverse fractures		Total	Per cent
	closed	open	closed	open		
ecrosis over mthesis	1		2	1	4	5 2
al s				1	1	1 3
ed osseous	1			1	2	2 6
ned screw	2			2	4	5 2
ned screw acture		1			1	1 3
plate	1				1	1 3
ured plate			1		1	1 3
cture after val of plate*			3		3	4 8
	5	1	6	5	17	23 0

ractures followed for at least 12 months after removal of the plate

planned The healing course was nged in two patients

teitis occurred in one patient with an transverse comminuted fracture with laceration. The osteosynthesis was rmed within a few hours A deep tion developed into osteitis despite inued administration of appropriate biotics, in accordance with bacterial sen- ity, and removal of the implants. Bone sion was done three times in combination 1 cancellous bone autografts and trans- tion leading to healing

1 Figure 2 it can be seen that after 5 ths 50 per cent of the patients were ing full weight on the fractured leg All ents except the one with osteitis were wed full weight-bearing within 15 months. "healing time" for comminuted fractures s markedly prolonged Fifty per cent had r osteosynthesis material removed 19 nths after the accident (Figure 3)

Delayed osseous healing necessitating a ondary operation was observed in two es. Both were comminuted fractures in

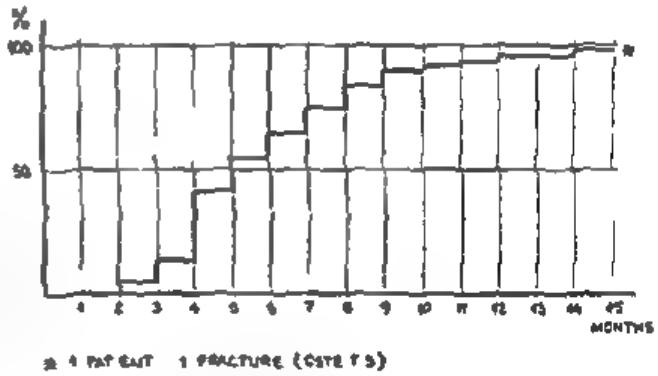

Figure 2 The time from accident to full weight-bearing (cumulated percentage)



Figure 3 The times for removal of the osteosynthesis material (cumulated percentage)

elderly persons bearing weight on the affected limb earlier than intended New osteosyntheses with bone grafts were done Full weight-bearing was allowed 10 and 12 months after the injuries Loosening of screws was brought about by weight-bearing before firm union A new period without weight-bearing led to healing Refracture and loosening of the implant was observed in one patient and was caused by a second injury 4 months after he had started full weight-bearing Closed reduction and immobilization in a high plaster cast was followed by an uneventful course Plate bending occurring before healing was caused by a new trauma Secondary measures were not necessary Plate fractures before solid union in a comminuted fracture occurred secondary to loosened screws and excessive weight-bearing A second plating was performed without healing disturbances

To assess the frequency of refracture after removal of the osteosynthesis material 12 months was chosen as the minimum observation time and only 62 of the 77 fractures had fulfilled this criterion Refracture after removal of the implant was observed in three footballers and was caused by new relevant traumas during football matches 6 weeks, 5 and 11 months after removal of the implants, which were removed 12, 17 and 14 months after the injuries. In the first and second patient fissures had developed and high plaster casts were applied The third showed a dislocation and a new osteosynthesis was performed In this patient the screw holes had not healed in spite of the fact that a period of 11 months had elapsed since the removal of the implants The three patients had not followed the advice which was given to all patients, i e to avoid forceful strain on the affected limb for 1–1½ year after the removal of the implants.

Sufficient information about 13 ("tourists", patients dependent on nursing care) of the 15 excluded fractures has been obtained for periods from 10 to 48 months (on an average 18 months) after the traumas On the basis of this information the only complication recorded was a case of delayed healing necessitating a new osteosyn[illegible] an open comminuted fracture.

DISCUSSION

In the last few decades there has [illegible] decreasing infection rate in both [illegible] and operative treatment of [illegible] fractures (Karlström & Olerud 1974 [illegible] & Anderson 1976) Therefore comparisons should be made between series from the 5–10 year period In this material one p[illegible] developed osteitis (1 3 per cent) In Ole[illegible] Karlstrom's series from 1972 (13) four out of seven cases with deep [illegible] developed into osteitis (3 0 per cent), were treated by administration of [illegible] and seven secondary operations. Th[illegible] these occurred in open comminuted fr[illegible] In the series of Solheim (1973), Th[illegible] al (1975) and Jensen et al (19[illegible] frequency of osteitis varied between 1 [illegible] per cent The frequency in rigid [illegible] fixation of closed fractures is reported [illegible] 1–4 per cent, whereas in open fractures [illegible] & Olerud 19[illegible]

Delayed rigid internal fixation [illegible] after the injury reduced the frequency [illegible] siderably when the soft tissue injury [illegible] moderate (Solheim 1973, Aho & Halk[illegible] 1974, Smith 1974 Gallinaro et al 19[illegible] high-energy traumas with extensive [illegible] to the soft tissue, transfixation [illegible] recommended by Olerud (1973) and Ge[illegible] & Anderson (1976)

The time from accident to full [illegible] bearing was a little longer in this series [illegible] the 50 per cent level (5 months) th[illegible] Olerud & Karlström's series (19[illegible] can be explained by a higher percentage [illegible] comminuted fractures in the material [illegible] Hjørring At the 90 per cent level there [illegible] no difference Delayed osseous [illegible] recorded as the number of fractures [illegible] secondary measures (osteotomy [illegible] obtain bone union, was observed in [illegible]

his can be compared with Olerud & m (1972) 4 4 per cent, Solheim (1973) cent, Thunold et al (1976) 11 0 per d Ruedi et al (1976) 1 9 per cent In 's series 50 per cent of the fractures eated by delayed primary fixation and cent by secondary fixation because of union after mainly conservative treat- Smith (1974) showed that delayed nthesis reduced the frequency of l union This can explain the low cy in Solheim's series Thunold et al ed the normal time to union as full -bearing stability within 4 months, was gained by 75 per cent of the es This could explain why 11 per cent a secondary internal fixation to obtain g

the series presented here refractures caused by new relevant traumas One er cent) was prior to removal of the and three (4 8 per cent) were observed removal of the osteosynthesis material lerud & Karlstrom's material (1972) figures were 6 7 per cent and 4 1 per respectively The refractures before val of the implant were caused by non- osteosyntheses and excessive weight- ng Refractures after plate removal were d by slight and moderate traumas, in ase the fracture had not been completely d at the time of removal of the osteo- hesis material Solheim (1973) and Jensen al (1977) observed a high rate of ctures after the removal of the osteo- hesis material (11–12 per cent) due to r and major traumas In their series the ants were removed 1 year after the ation The 50 per cent level for the time removal of the implants was in the erial from Hjørring 19 months and in that Uppsala (Olerud & Karlstrom) 17–18 ths. It is likely that removal of the os- ynthesis material 1 year after the ration will cause a higher percentage of ractures than when it is removed 6 months

The operations in this series, were performed 12 surgeons, nearly 30 per cent of the operations by younger residents, but under the supervision of an experienced orthopaedic surgeon Several authors (for example Muller et al 1970 and Olerud & Karlstrom 1972) have emphasized that the operation should be restricted to very experienced surgeons to reduce the frequency of complications

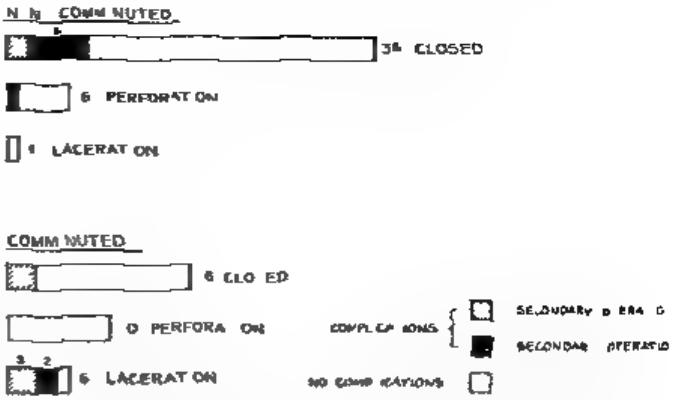

Figure 4 Comparison between the distribution of the complications in the whole material in relation to the extent of injury

In this series there was a markedly high frequency of complications in comminuted transverse fractures with laceration of skin and muscles, whereas an increased tendency for complications to develop in the remaining injury groups was not seen (Figure 4)

REFERENCES

Aho, A J & Hakkarainen, S (1974) Closed leg fractures *Acta chir scand* 140, 457–465

Bauer, G & Hulth, A (1973) Kompressions-osteosyntes enligt AO vid underbenets diafys-frakturer bor overges *Svenska Lak -Tidn* 70, 4752–4753

Brown, P W (1974) The early weight-bearing treatment of tibial shaft fractures. *Clin Orthop* 105, 167–178

Edwards P (1965) Fracture of the shaft of the tibia 492 consecutive cases in adults. Importance of soft tissue injury *Acta orthop scand*, Suppl 76

Gallinaro, P, Crova M & Denicolai, F (1974) Complications in 64 open fractures of the tibia *Injury* 5, 157–160

Gustilo R B & Anderson, J T (1976) Prevention

of infection in the treatment of one thousand and twenty-five open fractures of long bones *J Bone Jt Surg* 58 A, 453–458

Jensen, J S, Hansen, W H & Johansen, J (1977) Tibial shaft fractures A comparison of conservative treatment and internal fixation with conventional plates or AO compression plates. *Acta orthop scand* 48, 204–212

Karlstrom, G & Olerud, S (1973) Har stabil plattosteosyntes av tibiafrakturer nagot berattigande? *Svenska Läk-Tidn* 70, 4754–4755

Karlstrom, G & Olerud, S (1974) Fractures of the tibial shaft A critical evaluation of treatment alternatives *Clin Orthop* 105, 82–115

Muller, M E, Allgower, M & Willenegger, H (1965) *Technique of internal fixation of fractures* Springer, Berlin, Heidelberg, New York.

Müller, M E, Allgöwer, M & Willenegger, H (1970) *Manual of internal fixation* Springer, Berlin, Heidelberg, New York

Olerud, S & Karlstrom, G (1972) Tibial fractures treated by AO compression osteosynthesis perience from a five year material [illegible] *scand*, Suppl 140

Olerud, S (1973) Treatment of fractures [illegible] Vidal-Adrey method *Acta orthop scand* [illegible] 516–531

Ruedi, T, Webb, J K & Allgower M [illegible] perience with the dynamic compression (DCP) in 418 recent fractures of the shaft *Injury* 7, 252–257

Sarmiento, A (1974) Editorial Fractures of the tibia *Clin. Orthop* [illegible]

Smith J E M (1974) Results of early delayed internal fixation for tibial fractures. *J Bone Jt Surg* 56-B [illegible]

Solheim, K (1973) Tibial fractures [illegible] according to the AO method [illegible] 213–220

Thuroold, J, Varhaug J E & Bjerkeset, T [illegible] Tibial shaft fractures treated by rigid internal fixation The early results in a [illegible] *Injury* 7, 125–133

Wade P A (1970) ASIF compression [illegible] problem *J Trauma* 10, 513–515

Correspondence to Kristian D Kristensen, M D, Arsenalvej 68 DK 9800 Hjørring Denmark

p scand 50 599–600, 1979

TERAL HALLUX SALTANS

of a Case

B ANDERSEN & IVAN HVID

nent of Orthopaedic Surgery D, Central Hospital, Nykøbing F , Denmark

A case of bilateral hallux saltans in a 13-year-old girl is reported The signs and symptoms were a tender nodule behind the medial malleolus and a

Key words hallux, tendons, tenosynovitis

Accepted 2 1 79

us saltans is a well known condition of ngers with a tender nodule and "trigger r" (Fogh-Andersen 1947, Fahey & nger 1954, Weilby 1970) This disorder ts only the flexor tendons (Crawford ns 1971) The pathogenesis is thickening e entrance to the tendon sheath and local ression of the tendon with spindle-ed thickening of the tendon proximally ind Sørensen 1970, Weilby 1970, rford Adams 1971) The disease most affects the thumb (Weilby 1970, ton et al 1973) A related condition is de vain's tendovaginitis (Crawford Adams Faithfull & Lamb 1971) In this der "trigger finger" is very rare (Liavaag).

our knowledge only a single case of *uni-al* digitus saltans on the feet has pre-sly been reported (Lewin 1941)

e have observed a case of *bilateral* us saltans of the big toe The present r deals with this case

CASE REPORT

For 2 years a 13-year-old, healthy girl had been suffering from pain localized to the flexor aspect

bending the great toe upwards, and at the same time it would suddenly snap up Physical examination showed a typical snap in the left great toe on hyperextension and a tender nodule *behind the medial malleolus, approximately where* the click could be located. No other abnormalities were found, in particular no sign of hallux saltans on the right foot. Eight months previously the patient had been treated, *ineffectively, with* Brufen® (ibuprofen) and ultrasound.

Operation revealed thickening of the flexor retinaculum behind the medial malleolus over the left flexor hallucis tendon (*Figure 1*) Proximally to the retinaculum the tendon showed spindle-shaped thickening extending for 1½–2 cm. The retinaculum was divided in its proximal 3 cm, and in this area there was narrowing of the tendon indicating compression Before the retinaculum was divided there was definite difficulty in tendon movement which after its division was normal.

6470 79 050599 02$02.50 0

© 1979 Munksgaard Copenhagen

When seen 7 months postoperatively the patient had no remaining signs of hallux saltans, nodule, or tenderness, and the mobility of the great toe was normal

On the right foot, however, there was now a recently developed, tender nodule behind the medial malleolus and an audible click on movement of the right great toe There was a slight snap in the toe on hyperextension during simultaneous plantar flexion of the ankle joint, but no pain The complaints were so mild that it was decided to adopt an expectant attitude

Figure 1 The flexor hallucis longus tendon with its compressed part corresponding to the flexor retinaculum

DISCUSSION

Bilateral hallux saltans has not been described previously, however a single case of unilateral digitus saltans of the big toe caused by tenosynovitis of the flexor hallucis longus tendon has been reported in the literature (Lewin 1941) In our present case there was no history of trauma (Burman 1953, Weilby 1970) The patient had been riding once weekly for several years, but had not been exposed to any unusual strain (Lewin 1941, Martens et al 1968 Weilby 1970) No similar conditions were observed in her two elder siblings or in her parents and the family history was negative for rheumatoid arthritis and diabetes mellitus, conditions that may predispose to trigger fingers, de Quervain's disease and trigger wrists (Lang Weilby 1970, Davalbhakta et al 1[illegible]

The pathogenesis appears to be [illegible] to de Quervain's disease, thickening [illegible] retinaculum The changes of the ten[illegible] be secondary to those of the retinaculum

At follow-up incipient hallux [illegible] observed on the right side. The [illegible] disease was bilateral and that no [illegible] systemic aetiology could be found indicate that the disease was caused by [illegible] genital retinacular anomaly In this [illegible] tion it should be mentioned that the [illegible] did not exhibit signs of retinacula [illegible] other locations

The treatment, in cases causing symptoms, is resection of the retinaculum

REFERENCES

Burman M (1953) Stenosing tendovaginitis [illegible] foot and ankle *Arch Surg* 67 [illegible]

Crawford Adams, J (1971) *Outline of [illegible] paediatrics* 7th ed pp 304–306 [illegible] Livingstone, Edinburgh and London

Davalbhakta V V, Bailey M S & Bu[illegible] (1972) Trigger wrist Report of two cas[illegible] *J Plast Surg* 25, 376–379

Fahey J J & Bollinger J A (1954) Trig[illegible] in adults and children *J Bone Jt Surg* [illegible] 1200–1218

Faithfull, D K & Lamb D W (19[illegible] Quervain's disease – a clinical review [illegible] 23–30

Fogh Andersen Poul (1947) Digitus saltans [illegible] *Med* 34 1156

Hueston J, Wilson W F & Soin K (19[illegible] thumb *Med J Aust* 2, 1044–1045

Kolind Sørensen V (1970) Treatment of [illegible] fingers *Acta orthop scand* 41 [illegible]

Lewin, P (1941) *The foot and ankle* [illegible] 204 Lea and Febiger, Philadelphia

Liavaag K (1945) Om stenoserende [illegible] vaginitter *Nord Med* 28 [illegible]

Martens M, Muhler J C & Taylor W [illegible] Chronische Aspecifieke tenosynovitis [illegible] pees van de tibialis tendon *Acta orthop belg* [illegible] 991–998

Weilby, A (1970) Trigger finger *Acta orthop scand* 41, 419–427

Correspondence to Lars Ib Andersen Department of Orthopaedic Surgery [illegible] Central [illegible] Nykobing F, 4800 Denmark

p. scand 50, 601–605

EEDINGS OF FINNISH ORTHOPAEDIC ASSOCIATION

i, Finland, November 11, 1978

A. ALHO

RS' EXPERIENCE OF KÜNTSCHER G IN FINLAND

ndholm
ty of Oulu, Oulu

rst report concerning Kuntscher nailing in was published by Wasastjerna in 1943 g to the published reports, reaming of the y canal makes closed Küntscher nailing y appropriate in the treatment of closed se and oblique midshaft fractures of the adults In tibial fractures, the method is nded as a very valuable alternative to itive treatment of midshaft fractures, es- if early mobilization is advisable In injuries, the operative indications appear roader for the purpose of stabilization of emities. Küntscher nailing of the upper l the forearm has been performed too in- ly to permit analysis.

e treatment of non-union of the femur, ier nailing has also been recommended as od of choice at sites not too close to ses. It has also been recommended in the tibial and forearm non-union Only limited ice has been gained of this method in the nt of non union of the humerus. Closed cephalic nailings of pertrochanteric s of the femur in the elderly have been ied with results comparable to those d with open methods of internal fixation her nailing of metastatic fractures in long ias been recommended as a useful palliative on

general operative risk of Kuntscher nailing low to moderate Local complications have ldom resulted in permanent disability

IMS OF FIGHTS AND ASSAULTS NDING A CASUALTY DEPARTMENT

nkanen, O Kiviluoto & R Nordstrom
tment of Orthopaedics and Traumatology, ki University Central Hospital Department lic Health Science, University of Helsinki

ims of fights and assaults comprise about 8 nt of all injured adult patients. The purpose of this study was to analyse their personal characteristics and injuries. From a yearly (1973) computer file of a large casualty department 518 victims of fights and assaults (=victims) and 496 persons accidentally injured (=controls) were randomly selected

There was a greater proportion of males among the victims than among the controls (76 per cent vs. 61 per cent) and a greater number in the age group 15 to 44 years (81 per cent vs 64 per cent) Fifty per cent of the victims and 8 per cent of the controls were intoxicated, while the rates of chronic misuse of alcohol were 37 per cent and 18 per cent, respectively Forty-seven per cent of the victims and 18 per cent of the controls visited the emergency department at night

Head injuries predominated in the victims (71 per cent vs. 22 per cent) A head wound was the most common diagnosis and a blow from a fist the most common mechanism of injury in the victim series, while ankle sprain and falls represented the most common injuries in the control series.

ELECTRICAL STIMULATION OF FRACTURE CALLUS CELLS *IN VITRO*

H Aro, R Penttinen & A J Aho
Departments of Biochemical Chemistry and Surgery, University of Turku, Turku

Electrical stimuli, applied in various ways, are known to enhance osteogenesis *in vivo* The mechanism behind this cellular response is still unknown

In the present work callus cells, isolated from 9-day-old rat tibial fractures and cultured as oligolayers were stimulated directly by biphasic asymmetric voltages (AC voltage pulses 150 mV, DC voltage 150 mV – 600 mV) The currents supplied had positive (+100 μA – +300 μA) and negative (−100 μA – −200 μA) peaks. Culture flasks were equipped with two Pt-Ir L-shaped electrodes and were stimulated for up to 96 hours.

The mitotic rate was monitored by counting the cells and the DNA synthesis by determining the uptake of ^{3}H-thymidine In the early phase of

ISSN 0 79 050601–05$02.50 0

© 1979 Munksgaard, Copenhagen

proliferation the incorporation of thymidine increased significantly by 45 per cent per cell [illegible]

cultures responded to low voltage stimulation (DC 150 mV) by an increase in collagen synthesis, especially in the cathodal half of cell layer (30 per cent). Increase in the DC voltage up to 600 mV inhibited both DNA and protein syntheses. The stimulation – inhibition effect seems to be more dependent on voltage than on current

THE ROLE OF APOPHYSEAL JOINTS IN LOW BACK PAIN AND SCIATICA

M Tulila
District Hospital Kemijarvi

The apophyseal joints play an important role in spinal stenosis. In a series of 50 consecutive operations of the lower back the cause of pain was protrusion of the intervertebral disc alone in 17 cases, protrusion and spinal stenosis in 10 cases, spinal stenosis alone in 9 cases, and instability and other causes in 14 cases. Derangements of the apophyseal joints were the main cause of pain in 12 cases in this series.

CLOWARD'S ANTERIOR FUSION IN THE TREATMENT OF TRAUMATIC INJURY AND DEGENERATION OF THE CERVICAL SPINE

T Turturi O Leikkonen T Paakkala P Lepisto & P Rokkanen
Institute of Clinical Sciences, University of Tampere and Central Hospital Tampere

The series consisted of 29 patients operated on in 1968–75 25 of whom were followed up until 1978 In 12 cases the indication for operation was severe radicular symptoms which did not respond to conservative treatment and which were connected with considerable degeneration of the corresponding spinal segment only Seventeen patients were operated on for instability of the cervical spine caused by traumatic injury The injury had been dislocation and radicular or medullary symptoms which persisted in spite of conservative treatment with skull traction or a collar

The late result was evaluated with a view to objective neurological improvement subjective improvement, present symptoms and working capacity All fusions were radiologically successful. The late result was fair or better in 7/11 in the degeneration group and in 12/14 in the injury group An age of over 35 [illegible] operative motor defect were significant factors for a poor prognosis in the injury group. Preoperative radicular [illegible] operative symptoms lasting over 6 months prognostic factors for a poor result degeneration group

PARAPLEGIA AND TETRAPLEGIA IN SPINAL INJURIES

P Lepisto M Harkonen T Paatiala Patiala & P Rokkanen
Institute of Clinical Sciences, University of Tampere and Central Hospital, Tampere

Paraplegia was present in 11 and tetraplegia in 19 trauma patients treated at Tampere Central Hospital in *1968–75 The mean age* of patients was 33 years. Twenty-one patients were injured in the months May–August. The hospital stay was 71 days. Reduction and osteosynthesis with Williams plates were carried on four patients with paraplegia. The patients with tetraplegia were treated conservatively. Tracheostomy was performed on seven patients with tetraplegia Tracheal stricture developed in two patients. Continuous catheterization was initially infection of the urinary tract developed in all cases. Deep venous thrombosis developed in eight cases and pulmonary embolism in [illegible]. Pressure ulcers developed in eight patients. Three patients died in hospital and three died [illegible]

After an average interval of 5 years [illegible] time of injury seven patients with paraplegia three with tetraplegia were being cared for at home while one and six, respectively were in institutional care Five paraplegic patients were mobile in a wheelchair one was bedridden two were able to walk. Six tetraplegics used a wheelchair and three were bedridden patients were disabled.

It is concluded that the care of patients with paraplegia and tetraplegia should be organized centrally on a national basis in order to [illegible] level of therapy

BRUNSWIK ARTHROPLASTY OF THE JOINT OPERATIVE TECHNIQUE COMPLICATIONS AND RESULTS

H Patiala A Vaahto A. Lehto & P R[illegible]
Institute of Clinical Sciences, University of Tampere, and Central Hospital, Tampere

At Surgical Unit II Tampere Central Hospital during an 18-month period, 6 patients [illegible]

' hip prostheses using a postero-lateral
The mean duration of surgery was 67
for teams with two to three surgeons and
for teams with one surgeon No
ally significant differences between the
rere observed at follow-up with regard to
urrence of complications, the frequency of
e mobility of the hip or the ability to walk.

MAL TIBIAL OSTEOTOMY AN
SIS OF 172 KNEES

iluoto, P Salenius & L.-E Laurent
iedic Hospital of the Invalid Foundation,
1

ig the period 1966 to 1973, a proximal
steotomy was performed on 183 patients
pain in the knee joint In 1976 a
nnaire was sent to the patients. Answers
btained *from 162* patients, *10 of whom*
perated on bilaterally (172 knees) The in-
1 for operation was osteoarthritis-135,
e after intra articular fractures-15,
toid arthritis-9, and faulty position of the
int-13 There were 117 varus knees and 45
knees. Curved osteotomy was performed in
ses and wedge osteotomy in 24 cases.
less knees were found in 33 per cent of
s 3–10 years after surgery The condition
er cent of patients was improved after os-
) 9 per cent were worse than before the
ion and in 11 per cent the pain remained
iged. The range of flexion increased after
y ($P<0.05$). The results were better in
s than in males ($P<0.01$) and the results
better with curved osteotomy than with
osteotomy ($P<0.05$) When the patients
treated postoperatively with a plaster from
oin to the malleolar region the results were
favourable than those obtained with a full-
plaster ($P<0.01$) Immobilization for more
10 weeks produced poorer results than im-
zation of shorter duration ($P<0.01$)

NOSIS OF ACUTE KNEE LIGAMENT
RIES

ho & A Molster
n of Orthopaedics and Traumatology,
rsity of Bergen, Norway

ty-one patients were admitted for acute knee
es. After the primary evaluation, the knee
immoblized in a plaster splint overnight In
ses after a repeated clinical examination it
considered that adequate information had
obtained Eleven patients were treated con-
tively and the follow-up proved this choice to
be correct In 14 cases the result of the clinical examination remained uncertain due to pain and muscle spasms. In four of these an examination under anaesthesia revealed that an operation was indicated

Among the 30 operated patients, an abduction injury was diagnosed in 24 cases In 15 cases with combined medial and anterior cruciate injuries a clear anteromedial instability was present. In two cases a rupture of the posterior cruciate ligament was also present with a valgus instability in extension in both cases and a positive anterior drawer sign in internal rotation in one case An adduction injury was diagnosed in five cases and a sagittal injury in two cases. It is concluded that the aim of the preoperative examination of instability is not to get an anatomical diagnosis but an indication for operation In doubtful cases, an examination under anaesthesia and arthroscopy may provide valuable additional information.

THE EFFECT OF IBUPROFEN AND INDOMETHACIN ON RECENT ANKLE AND FOOT SPRAINS

J-E Michelsson, M Pasila & A Sundholm
Department of Orthopaedics and Traumatology, Helsinki University Central Hospital

Sixty consecutive patients with recent ankle and foot sprains were treated with a Tensoplast® elastic bandage extending from the metatarsal heads to above the ankle The patients were randomized into three groups, each consisting of 20 patients. After the application of the bandage the patients in the first group were given 1200 mg of ibuprofen, in the second group indomethacin, and in the third group a corresponding amount of placebo capsules daily for 5 days. The recovery of the sprains was compared using 10 parameters active dorsal and plantar flexion, inversion and eversion of the foot, tolerance of body weight support on the toes and heel, swelling, pain at rest, local tenderness and limping The examinations and registrations were performed at the beginning of the treatment and 1 week later The patients were followed up until they returned to work It was possible to complete examinations on 56 of the 60 patients. Wilcoxon's test was used for the statistical analyses.

The mean sick leave period was 9–10 days in each group There were no statistically significant [illegible]

ibuprofen and indomethacin

ARTHRODESIS OF THE WRIST IN RHEUMATOID ARTHRITIS

V Vahvanen & P Kettunen
Aurora Hospital, Helsinki

Sixty-two arthrodeses were performed on 58 patients. The arthrodesis technique was bone grafting using the distal end of the ulna in 54 patients, and a modified version of the technique of Mannerfelt & Malmsten (1971) in 8 patients All eight wrists immobilized with a Rush pin healed well There were two cases of pseudarthrosis (3 2 per cent), rearthrodesis by bone grafting was successful in both cases One patient had a snapping phenomenon in the ulna and four patients had some other complaints

The joint between the trapezium and the scaphoid was open in 48 per cent and the joints around the os triquetrum were open in about 47 per cent In 37 per cent the second carpometacarpal joint fused spontaneously and the third carpometacarpal joint nearly as often The first and fifth carpometacarpal joints were always open and mobile, and the fourth carpometacarpal joint was fused in only three patients

According to our functional analysis, the position of the hand should show only slight ulnar deviation with the angle between the radius and the second metacarpal bone being less than 10° Either slight dorsal flexion or zero position is recommended

ENTRAPMENT NEUROPATHY OF THE RADIAL NERVE IN THE FOREARM

M Vastamäki & K A Solonen
Orthopaedic Hospital of the Invalid Foundation, Helsinki

The present series consists of 12 patients with entrapment of the radial nerve Eight patients had "radial tunnel syndrome" with compression of the nerve at the level of the radiohumeral joint They had paraesthesia and sensory disturbances and, in two cases, symptoms of tennis elbow Four patients had compression of the deep motor branch as it passes beneath the fibrous arcade of Frohse into the supinator muscle They had weakness in the corresponding motor functions.

The mean age of the patients was 33 years, five

TOE-TO-THUMB TRANSFER [illegible] NEUROVASCULAR ANASTOMOSES

K A Solonen, H Brummer & T [illegible]
Department of Hand Surgery [illegible]
Hospital of the Invalid Foundation, H[illegible]

O'Brien's method (1975, 1977) was [illegible] free toe-to-thumb transfer by [illegible] anastomoses in three cases.

The first patient was a girl of 12 [illegible] all but 1½ ulnar digits of her right hand [illegible] earlier The second toe was transplan[illegible] thumb metacarpal The second patient [illegible] of 28 He had lost the right thumb th[illegible] MP joint 9 months earlier In this case [illegible] to-thumb transfer was performed. T[illegible] patient, a female aged 31 had had [illegible] amputation of her right hand transm[illegible] loss of the first and second digits of the [illegible] transmetacarpally 12 months prev[illegible] transfer of the left great toe [illegible] the l[illegible] replace the thumb was performed.

There were no postoperative compl[illegible] the hands, and the primary results are [illegible] The observation time however is too [illegible] permit final assessments.

SOFT TISSUE SARCOMAS A REP[illegible] 153 CONSECUTIVE CASES

S Santavirta, P Gröhn E Hre[illegible] Sandelin & B Sundell
Radiotherapy Department, Dive[illegible] Orthopaedic Surgery and Trauma [illegible] Division of Plastic Surgery Surgical [illegible] University Central Hospital, Helsinki

A total of 153 patients with soft tissue [illegible] were treated during 1965–1975 The age [illegible] patients varied between 12 and 60 years [illegible] years) Fibrosarcoma and undifferentiated [illegible] represented more than 50 per cent of the [illegible] series. Most of the tumours (67 per cent [illegible] located in the extremities.

The disease recurred in 100 cases ([illegible] per [illegible] in the 3 year follow-up period Th[illegible] local recurrences and 52 distant metastases [illegible] primary site of distant metastases was [illegible] (44/52) Rhabdomyosarcoma turned out [illegible] most aggressive (15/16 recurred) The pa[illegible] with synovial sarcoma differed from the [illegible] they developed only distant metastases [illegible] lungs. The size of the tumour had a prog[illegible] value

THE VOLVO AWARDS FOR LOW BACK PAIN RESEARCH

In order to encourage research into low back pain, the Volvo Company of Gotebor[illegible] has again this year sponsored three prizes of US$3000 each Awards will be ma[illegible] petitively on the basis of scientific merit in the following three areas

I Clinical studies

II Bioengineering studies

III Studies in other basic scientific areas

Papers submitted for the contest must contain original material that has not been p[illegible] previously Multiple authorship is acceptable The manuscripts should be full leng[illegible] suitable for submission to a scientific journal Five copies of each paper submitted [illegible] received by January 1, 1980

One of the authors should be prepared to come to New Orleans, USA [illegible] the time [illegible] meeting of the International Society for the Study of the Lumbar Spine May 24-[illegible] 1980, to present the paper and to receive the prize

A board of referees will be chaired by the undersigned and will contain members f[illegible] fields of clinical medicine, bioengineering and biochemistry

Please direct all correspondence to

Professor Alf Nachemson
Past President, ISSLS
Department of Orthopaedic Surgery I
Sahlgren Hospital
S-413 45 Goteborg
Sweden

The International Society for Prosthetics and Orthotics (I S P O), in collaboration [illegible] INTERBOR (The International Association of Orthotics and Prosthetists), will [illegible] 3rd World Congress of I S P O in Bologna, Italy on September 28 – October 4 [illegible] programme will provide substantial coverage of technical scientific and admin[illegible] associated with amputation surgery, prosthetics, orthotics and related areas of [illegible] and rehabilitation engineering

The Congress will also provide symposia to treat very special and sometimes [illegible] subjects in detail, and plenary sessions in which world leaders will present [illegible] progress in the major aspects of prosthetic and orthotic rehabilitation.

Simultaneous translation will be available in four different locales at the [illegible] Languages offered include English, French, German and Italian

Further information from

Organizing bureau Studio B C
via ugo bassi 10
40123 Bologna
Italy
Tel 051–268877

iop scand 50 609–611 1979

IDISK ORTOPEDISK FORENING
IDIC ORTHOPAEDIC ASSOCIATION

Anniversary

year the Nordisk Ortopedisk Förening) (the Nordic Orthopaedic Association) rates its 60th anniversary and in view of ong and close co-operation between the ty and *Acta Orthopaedica Scandinavica* ditorial committee would like to take this rtunity to acknowledge the occasion

ie founding of NOF is closely associated the development of orthopaedics in the lic countries and it is fitting to give a short ription of this

1 outstanding feature of Scandinavian opaedics is its origin in social service ing the latter part of the 19th century there a growing interest in assisting young bled persons by providing them with a tical education in special centres and eby ensuring them a means of employment foremost advocate of these ideas was the ish clergyman, Hans Knudsen, and on the is of his conceptions persons engaged in ial work in the Nordic countries founded ieties which undertook the organization of h institutions

The clientele was mixed, being mostly cases congenital deformities, infantile paralysis, l disability after accident It was often essary to correct deformities in these ients, and it was soon obvious that beds did have to be provided in direct co-ration with the social institutions The dical side of this undertaking gradually in-isified and even if progress developed along ghtly different lines in the various Nordic untries, ward facilities were substantially reased during the first decades of the 20th ntury Clinics were set up and orthopaedics d gained a firm footing The senior doctors in ese clinics came to play an important role in e development of the orthopaedic team

Another orthopaedic departure was in the field of tuberculosis. The disease was widespread in Scandinavia and was justifiably considered a major public health problem Determined efforts were therefore made to treat these patients Even on this occasion the social commitment of the individual played an important part in the establishment of specialized hospitals The doctors in charge of these hospitals quickly adapted to the treatment of cases involving bone surgery, and they too became pioneers in orthopaedic surgery Both these groups of doctors were joined by yet another circle from which orthopaedic surgeons were recruited These were the general surgeons who within their field of work had developed a special interest in bone surgery

World War I had a definite influence on the development of orthopaedics in Europe and America The vast numbers of critically injured, including amputees, who required treatment and rehabilitation lent more and more significance to the speciality Its profile became more pronounced and, as a consequence, the orthopaedic surgeons began to form national societies Also in Scandinavia representatives of this young speciality considered the time was ripe to assert themselves through their own society It was agreed to found a joint Nordic association because at the time there was no basis for national societies, the orthopaedic groups in the individual countries being too small

On the initiative of H C Sloman Denmark, Patrik Haglund and Sven Johansson, Sweden 19 orthopaedic representatives gathered in Gothenburg and founded the Nordic Orthopaedic Association. Patrik Haglund was chosen as first president, an appointment he

ISSN 0300-6474/79/060609-03$02.50 © © 1979 Munksgaard, Copenhagen

THE VOLVO AWARDS FOR LOW BACK PAIN RESEARCH

In order to encourage research into low back pain, the Volvo Company of Goteborg, S has again this year sponsored three prizes of US$3000 each. Awards will be mar petitively on the basis of scientific merit in the following three areas

I Clinical studies

II Bioengineering studies

III Studies in other basic scientific areas

Papers submitted for the contest must contain original material that has not been p previously Multiple authorship is acceptable The manuscripts should be full-length a suitable for submission in a scientific journal Five copies of each paper submitted sh received by January 1, 1980

One of the authors should be prepared to come to New Orleans, USA, at the time meeting of the International Society for the Study of the Lumbar Spine May 24-3 1980, to present the paper and to receive the prize

A board of referees will be chaired by the undersigned and will contain members fr fields of clinical medicine, bioengineering and biochemistry

Please direct all correspondence to

Professor Alf Nachemson
Past President, ISSLS
Department of Orthopaedic Surgery I
Sahlgren Hospital
S-413 45 Goteborg
Sweden

The International Society for Prosthetics and Orthotics (ISPO), in collabora w INTERBOR (The International Association of Orthotics and Prosthetists), will orga 3rd World Congress of ISPO in Bologna, Italy on September 28 – October 4 19 programme will provide substantial coverage of technical, scientific and admin strat associated with amputation surgery, prosthetics, orthotics and related areas of orth and rehabilitation engineering

The Congress will also provide symposia to treat very special and sometimes contr subjects in detail and plenary sessions in which world leaders will present triennial re progress in the major aspects of prosthetic and orthotic rehabilitation

Simultaneous translation will be available in four different locales at the sam Languages offered include English, French, German and Italian

Further information from

Organizing bureau Studio B C.
via ugo bassi 10
40123 Bologna
Italy
Tel 051–268877

[illegible] 1952 [illegible]

[illegible] and Acta has been invaluable society's members obtained a reliable n for their scientific publications whose lard has contributed to making *Acta opaedica Scandinavica* internationally m and respected

The editors have every reason to look back with gratitude on the years during which the Association and *Acta Orthopaedica Scandinavica* have worked together and would like to express the hope that the mutual understanding of our common problems will continue in the future

Gunnar Wiberg

thop scand 50, 613–619, 1979

CIFICATION OF AGING ARTICULAR CARTILAGE
MAN

I SHITAMA

-tment of Pathology, School of Medicine, Fukuoka University, Fukuoka Japan

Calcification of the articular cartilage was studied ultrastructurally using normal femoral heads obtained from necropsies of persons ranging in age from 11 months to 80 years. Mineral crystals which appeared during the initial stages of deposition were morphologically divided into two types Type A crystals
to 360 nm in ler
curved, measurin
found mainly in the developing epiphysis during childhood Type B crystals were generally found in the calcified zone of adult articular cartilage Both types of crystals initially appeared in close proximity to extracellular membrane-invested electron dense particles called "matrix vesicles", and gradually increased in number to form calcified cartilage matrix The morphological differences between type A and B crystals might be caused by biochemical alterations of the cartilage matrices and/or biomechanical changes in the joints of children and adults.

Key words articular cartilage, calcification, matrix vesicles, mineral crystals, ultrastructural study

Accepted 5 v 79

early childhood, the epiphysis of the long nes in humans is composed of hyaline tilage containing a vascular network veral months after birth, the secondary ater of ossification, in which endochondral ne formation occurs, appears in close oximity to the vascular network in the nter of the epiphysis (Wilsman & Van chle 1970), and extends continuously itward until only a thin layer of cartilage retained at the articular surface ndochondral bone formation is characterized y a gradual calcification of the cartilage atrix adjacent to the hypertrophic or egenerating cartilage cells (Bloom & Bloom 940) In adult articular cartilage, a prominent basophilic line or "tidemark" (Fawns & Landells 1953) runs transversely from the base of the articular cartilage to the surface of the joint and eventually becomes the underlying calcified zone The tidemark amd the calcified zone firmly connect the non-calcified cartilage layer to the subchondral bone (Redler & Mow 1975) However, the differences in the mode of calcium deposition between the developing epiphysis in childhood and the permanent articular cartilage in adulthood have not been clarified

The present paper aims to study the mode of calcification of articular cartilage in children and adults using femoral heads obtained at necropsy

001-6470/79 060613–07$02 50 0

© 1979 Munksgaard Copenhagen

MATERIALS AND METHODS

Articular cartilages were obtained from the weight-bearing portion of femoral heads taken from 23 necropsies of persons ranging in age from 11 months to 80 years. These femoral heads were selected from patients who had pathologically normal hip joints. Complete cross sections of the articular cartilage, including subchondral bone were cut into small pieces perpendicularly to the joint surface. For light microscopic observation, specimens were fixed in neutral buffered formalin and the sections were stained with hematoxylin and eosin, von Kossa alcian blue and safranin-O fast-green iron hematoxylin. Specimens for electron microscopy were not decalcified. Samples were immediately fixed in 1.4 per cent glutaraldehyde in 0.1 M Sorensen's phosphate buffer, and post-fixed in buffered 1 per cent osmium tetroxide for 2 hours. After dehydration in increasing concentrations of alcohol, the specimens were infiltrated with and embedded in Epon 812. Relatively thick sections were stained with alkaline toluidine blue for general light microscopic observations. Ultrathin sections were cut on a Porter-Blum MT-1 ultramicrotome using glass knives. The sections were stained either doubly or triply with uranyl acetate lead citrate and phosphotungstic acid and examined with a Hitachi H 500 electron microscope at an accelerating voltage of 75 kv. For assessment of the quantity and quality of mineral deposits, the thin sections were coated with carbon for analysis by a JEM 100-B with an Ortec intregated electron probe X-ray microanalyzer.

RESULTS

Light microscopic observations

The articular cartilages and underlying subchondral bone were well preserved and showed no pathological abnormalities.

In children up to 12 years of age, the secondary center of ossification appeared in the epiphysis and displayed endochondral bone formation. It was characterized by a central ossified area with peripheral hypertrophic or degenerating cartilage cells embedded in a wide zone of basophilic cartilage matrix. In addition, island-like aggregations of basophilic granules were frequently found in the outer zone of the peripheral hypertrophic cartilage cells and in close proximity to colonies of cartilage cells (Figure 1A).

In adults ranging from 26 to 80 years of age, cartilage cells, arranged perpendicular to the articular surface, were found within the articular cartilage. A basophilic line or "tidemark", transversely to the articular surface, the innermost part of the articular into calcified and overlying zones. Just above the tidemark, a number of small basophilic granules observed which contrived into the basophilic cartilage matrix (Figure 1B). basophilic granules and basophilic matrix observed in children and showed a strong positive reaction subjected to von Kossa staining.

Electron microscopic observations

Mode of crystalline deposition. In children basophilic granules appeared ultrastructurally

Figure 1 A. A secondary center of ossification in an 11-month-old child. A wide basophilic calcified matrix (CM) is found between upper hyaline cartilage and lower bone marrow (× 150).

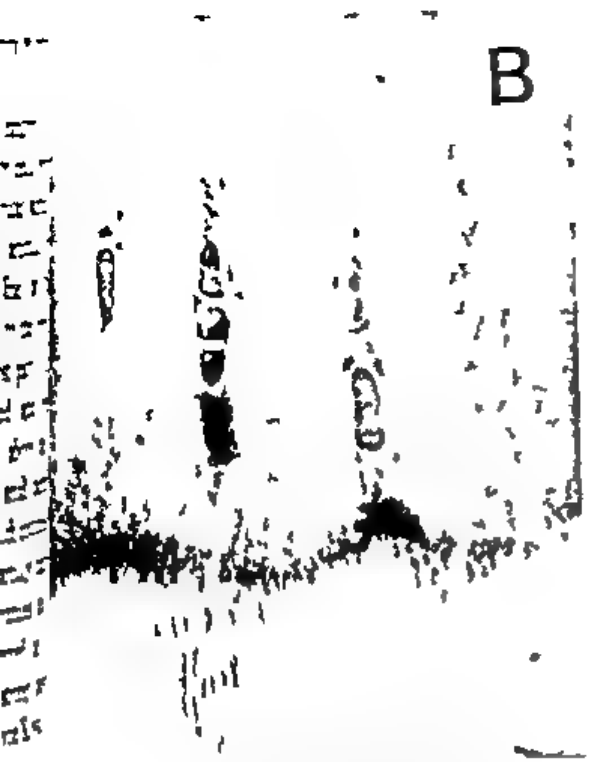

re 1 B A tidemark (TM) of an adult ular cartilage running transversely between upper non calcified and lower calcified zones 50)

Figure 2 A secondary center of ossification of a 2 year-old child Focal aggregations of electron dense crystalline clusters (arrows) are seen in the vicinity of the hypertrophic cartilage cells (C) (× 2 900) Inset shows the crystalline deposits of the perilacunar matrix (× 29 000)

electron dense crystalline clusters which e focally aggregated in the cartilage rix among hypertrophic or degenerating tilage cells (Figure 2) They were sposed of needle-shaped crystalline sters and appeared in close proximity to mbrane-invested round or oval electron se particles located chiefly in the rilacunar matrix (Figure 2 inset) In an tron dense cartilage matrix the crystalline sters were diffusely deposited in the tilage matrix with the exception of the unar matrix

In adults, these electron dense crystalline sters appeared in cartilage matrix deep thin the articular cartilage Just above the demark they were largely found in the rilacunar and interlacunar matrix (Figure These crystalline deposits were also close the membrane-invested electron dense rticles (Figure 3 inset) In the tidemark and derlying calcified zone of the articular rtilage electron dense crystalline clusters gradually increased in number forming the electron dense cartilage matrix, where collagen fibrils run perpendicularly to the articular surface

The electron dense particles of the perilacunar matrix were larger, more irregular in shape and more abundant than those of the interlacunar matrix Occasionally electron dense crystals were found in the form of large polyhedral or round electron dense masses which varied in size

Fine structure of crystals Morphologically, electron dense crystals in the initial stages of deposition were divided into types A and B Type A crystals were found mainly in the

MATERIALS AND METHODS

Articular cartilages were obtained from the weight-bearing portion of femoral heads taken from 23 necropsies of persons ranging in age from 11 months to 57 years. These femoral heads were selected from patients who had pathologically normal hip joints. Complete cross sections of the articular cartilage, including subchondral bone, were cut into small pieces perpendicularly to the joint surface. For light microscopic observation, specimens were fixed in neutral buffered formalin and the sections were stained with hematoxylin and eosin, von Kossa, alcian blue and safranin-O fast-green hematoxylin. Specimens for electron microscopy were not decalcified. Samples were immediately fixed in 1.4 per cent glutaraldehyde in 0.1 M Sorensen's phosphate buffer, and post-fixed in buffered 1 per cent osmium tetroxide for 2 hours. After dehydration in increasing concentrations of alcohol, the specimens were infiltrated with and embedded in Epon 812. Relatively thick sections were stained with alkaline toluidine blue for general light microscopic observations. Ultrathin sections were cut on a Porter-Blum MT-1 ultramicrotome using glass knives. The sections were stained either doubly or triply with uranyl acetate, lead citrate and phosphotungstic acid and examined with a Hitachi H-500 electron microscope at an accelerating voltage of 75 kV. For assessment of the quantity and quality of mineral deposits, the thin sections were coated with carbon for analyses by a JEM 100-B with an Ortec integrated electron probe X-ray microanalyzer.

RESULTS

Light microscopic observations

The articular cartilages and underlying subchondral bone were well preserved and showed no pathological abnormalities.

In children up to 12 years of age, the secondary center of ossification appeared in the epiphyses and displayed endochondral bone formation. It was characterized by a central ossified area with peripheral hypertrophic or degenerating cartilage cells embedded in a wide zone of basophilic cartilage matrix. In addition, island-like aggregations of basophilic granules were frequently found in the outer zone of the peripheral hypertrophic cartilage cells and in close proximity to colonies of cartilage cells (Figure 1A).

In adults ranging from 26 to 57 years of age, cartilage cells, arranged perpendicular to the articular surface, were found within the articular cartilage. A basophilic line or "tidemark", transversely to the articular surface, separated the innermost part of the articular cartilage into calcified and uncalcified zones. Just above the tidemark a number of small basophilic granules were observed which continued into the basophilic cartilage matrix (Figure 1B). The basophilic granules and basophilic matrix observed in children and adults showed a strong positive reaction subjected to von Kossa stain.

Electron microscopic observations

Mode of crystalline deposition. In the basophilic granules appeared [illegible]

Figure 1 A. A secondary center of ossification in an 11 month-old child. A wide basophilic matrix (CM) is found between upper hyaline cartilage and lower bone marrow (x 3[illegible])



Figure 6 A point X ray microanalysis from a d (× 4800) A taken from an area of sparse stalline deposits shows that the phosphate k is high area s osited ws th calcium peak is more prominent and arated into K_α and K_β

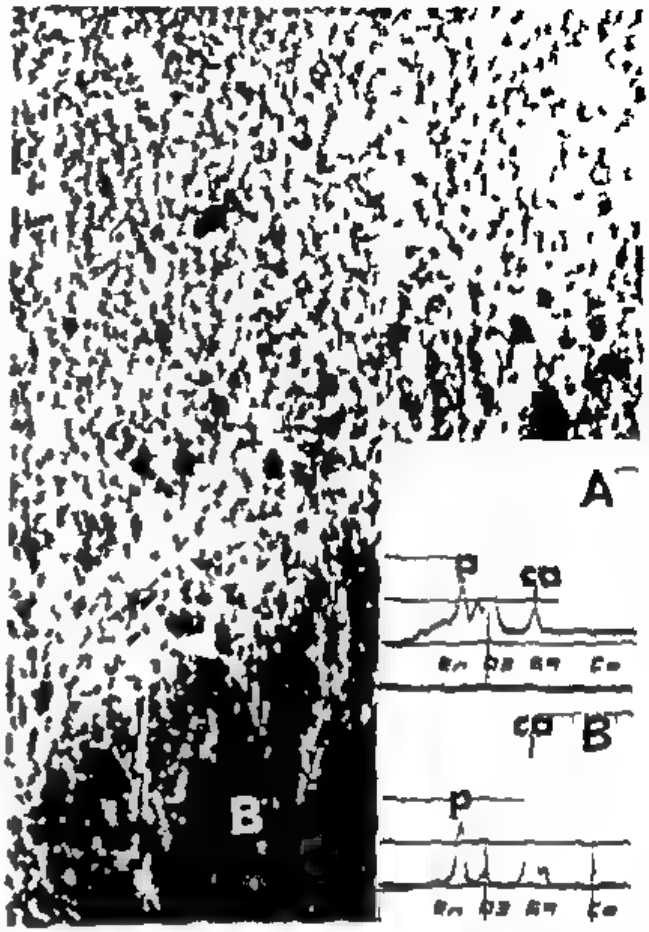

Figure 7 A point X ray microanalysis from an adult (× 6000) The detected peaks are similar to those of a child A is from the crystalline clusters just above the tidemark and B is from the tidemark

ominent than that of phosphate and was aracteristically separated into K_α and K_β igure 6B) A point analysis of an adult icular cartilage revealed a pattern similar that of a child (Figure 7A and B) The ineral composition however was in stinguishable between type A and B stals.

ISCUSSION

the present study the mode of calcification human articular cartilage at different ages as documented at the fine structural level he mineral crystals in the cartilage matrix were morphologically divided into types A and B Type A crystals found mainly in children formed clumped crystalline clusters among hypertrophic and degenerating cartilage cells Type B crystals, found mainly in adults, were smaller than type A and formed sunburst shaped crystalline clusters. Morphological differences between mineral crystals were observed by Bosman et al (1977) who reported the coexistence of three different types of crystals during the initial stages of calcification of cartilage in the pathological condition of chondrodystrophia calcificans congenita However the fine structure and distribution of the crystals observed in the present study differed from those described by Bosman et al The morphological differences between mineral

crystals in the cartilage of children and adults may depend upon the chemical alteration of the ground substances of the cartilage matrix, including proteoglycans (Mourão et al 1976) and/or collagen (Gay et al 1976, von der Mark & von der Mark 1977) Moreover, the biomechanical roles of the joints in childhood may differ from those in adulthood, the former has the characteristics of epiphyseal development and remodelling while the latter, completely ossified may serve as a resistance to biomechanical stresses of the joint Such biochemical and biomechanical changes in articular cartilage between children and adults may be responsible for the *morphological differences in the mineral* crystals of the cartilage

During the initial stages of mineral deposition *in the cartilage matrix, the mineral* crystals appeared closely related to the extracellular membrane-invested electron dense particles the morphological features of which resembled "matrix vesicles" or "calcifyin globules"as previously reported by Anderson (1969) and Bonucci (1970) respectively It has been widely accepted that the matrix vesicles serve as the initial site of calcium deposition in various calcifying tissues such as bone (Bonucci 1971), dentine (Bernard 1972) cartilage (Bonucci & Dearden 1976) and in pathological conditions (Schajowicz et al 1974 Williams et al 1976) Ali & Evans (1973) demonstrated that the matrix vesicles incorporated calcium and phosphate to form hydroxyapatite Arsenis (1972) and Brighton & Hunt (1974) postulated that mitochondria may participate in the initial process of calcification and that the membrane-invested particles could be released from the cytoplasm to form matrix vesicles In the present study, however, the mineral crystals were deposited in a mass composed of irregular electron dense particles of various sizes They are presumed to be derived from cell debris or degenerated cartilage cells

By using a non-dispersive electron probe X-ray microanalyzer, type A and type B crystals were found to be identically made up of calcium and phosphate Probably hydroxyapatite Based on mi composition alone, however type A cr could not be distinguished from typ crystals. Such zonal differences in calcium/phosphate ratio may be due not o to changes in concentration of the min components but also to alterations in the teoglycans of the cartilage matrix.

ACKNOWLEDGMENT

The author wishes to express his sincere gra to Prof Dr Ryohei Suzuki, Departme Orthopaedic Surgery Nagasaki University S of Medicine for his critical review of manuscript and to Prof Dr Shigeo Takeha and Assistant Prof Dr Akinori Kasuo, De ment of Pathology School of Medicine Fu University for their invaluable advice encouragement throughout th s study

REFERENCES

Ali S Y & Evans L (1973) The uptake of [calcium ions by matrix vesicles isolated fr calcifying cartilage *Biochem J* 134 64

Anderson H C (1969) Vesicles associated w calcification in the matrix of epiphyseal cart *J Cell Biol* 41, 59–72

Arsenis C (1972) Role of mitochondria in calci tion Mitochondrial activity distribution in epiphyseal plate and accumulation of calc and phosphate ions by chondrocyte mitoch dria *Biochem Biophys Res Commun* 1928–1935

Bernard G W (1972) Ultrastructural observ of initial calcification in dentine and enamel *ultrastruct Res* 41, 1–17

Bloom W & Bloom M A (1940) Calcification ossification Calcification of developing bones embryonic and newborn rats *Anat Rec* 497–523

Bonucci E (1970) Fine structure histochemistry of calcifying globules epiphyseal cartilage *Z Zellforsch Mikr Anat* 103, 192–217

Bonucci, E (1971) The locus of initial calcificati in cartilage and bone *Clin Orthop* 108–139

Bonucci E & Dearden L C (1976) Matrix vesi in aging cartilage *Fed Proc* 35, 163–168

• an, C, Bonucci, E, Guglianini, P & Sagui, L (1977) Ultrastructural aspects of chondrostrophia calcificans congenita (syndrome of mradi-Hünermann) *Virchows Arch path Pat.* **373**, 23–35

ıton C T & Hunt, R M (1974) Mitochondrial alcium and its role in calcification *Clin rthop* **100**, 406–416

ıs, H T & Landells, J W (1953) istochemical studies of rheumatic conditions. Observations on the fine structure of the atrix of normal bone and cartilage *Ann heum Dis* **12**, 105–113

Muller, P K, Lemmen, C, Remberger, K, Matzen, K Kuhn, K (1976)

Dietrich, C P (1976) The distribution of chondroitin sulfates in articular and growth cartilages of human bones *Biochem biophys Acta (Amst)* **428**, 19–26

Redler, I & Mow, V C (1975) The ultrastructure and biomechanical significance of the tidemark of articular cartilage *Clin Orthop* **112**, 357–362

Schajowicz, F, Cabrini, R L, Simes, R J & Klein-Szanto, J P (1974) Ultrastructure of chondrosarcoma *Clin Orthop* **100**, 378–386

von der Mark, K von der Mark, H (1977) The

Williams, A H, Schwinn, C P & Parker, J W (1976) The ultrastructure of osteosarcoma A review of twenty cases. *Cancer* **37**, 1293–1301

Wilsman, N J Van Sickle, D C (1970) The relationship of cartilage canals to the initial osteogenesis of secondary centers of ossification *Anat Rec* **168**, 381–392.

respondence to Dr Kenji Shitama, Department of Pathology, School of Medicine, Fukuoka Univer-, 34 Nanakuma, Nishi ku, Fukuoka 814, Japan

orthop scand. 50, 621–627, 1979

DOMETHACIN-INDUCED INHIBITION OF HAVERSIAN MODELLING IN RABBITS

AR SUDMANN & GISLE BANG

artment of Orthopaedic Surgery, University of Tromsø, Tromsø, and Department of Oral Pathology Forensic Odontology, School of Dentistry, University of Bergen, Norway

The effect of indomethacin on haversian remodelling in the radius was studied in 16 rabbits. An osteotomy and a saw-cut almost through the bone were made in the middle and distal parts of the right radius, respectively In order to obtain biological osteosynthesis in the osteotomy and the saw-cut the rabbits were not treated in any way during the following 3 weeks. They were then given either indomethacin or placebo suspensions per os, 10 mg/kg/day for 2 weeks, followed by 5 mg/kg/day for 4 weeks. The extent of haversian remodelling was estimated by calcein and oxytetracycline fluorochrome labels given at the start of the indomethacin treatment and 3 weeks later, respectively After 2 weeks of indomethacin treatment (10 mg/kg/day) the indomethacin plasma levels were about 0 18 µg/ml 24 hours after the last dose Indomethacin treatment significantly ($2P < 0.019$) inhibited haversian remodelling as estimated by fluorochrome labelling

Key words anti-inflammatory agents, bone, fractures, non-union, haversian remodelling, fluorochrome labelling, indomethacin, pseudarthrosis, rabbits

Accepted 15 v 79

ecent studies indicate that indomethacin ay inhibit woven-fibred bone tissue rmation both in experimental animals and humans (Sudmann 1975 b, Rø et al 1976, udmann & Hagen 1976) This contention has een supported by a prospective study of atients receiving indomethacin and showing gnificantly inhibited heterotopic ossification fter hip surgery (Almåsbakk & Røysland 977). As the healing of fractures immobilized y plaster casts depends mainly on periosteal oven-fibred bone formation, indomethacin reatment may inhibit healing in these cases Sudmann 1975 b, Sudmann et al 1979)

Rigid plate osteosynthesis with interfragmentary compression appears to nduce a different type of fracture healing, hich apparently depends mainly on longitudinal haversian remodelling across the fracture, and periosteal callus is usually not seen (Schenk & Willenegger 1964) The problem is whether doses of indomethacin that inhibit periosteal fracture healing also inhibit haversian remodelling in rigidly immobilized fractures or osteotomies The aim of this study was to investigate the effect of indomethacin treatment on this type of haversian remodelling in rabbits.

MATERIAL AND METHODS

Animals

Sixteen female Dutch rabbits were divided into two equal weight-matched groups At the start of the experiment they were about 4½ months old

0'1-64'0/79 060621–07$02.50/0

© 1979 Munksgaard Copenhagen

and their weights ranged from 2.0 to 2.7 kg. They were given an ordinary rabbit laboratory diet (Felleskjøpet, Trondheim, Norway) and water *ad libitum* from noon to the following morning. To make them take the indomethacin or placebo suspensions more readily at noon, they were deprived of water during the morning. They were kept separately in metal cages at 21°C, with 60 per cent humidity, and a 12 h light, 12 h dark cycle.

Experimental design

Operative procedure. Under neuroleptanaesthesia (Hypnorm Vet. 0.3 ml/kg intramuscularly, Meeos, Helsingborg, Sweden) and sterile conditions a 0.12 mm wide transverse osteotomy was made in the middle of the right radius by means of a circular dental saw. Another cut was made almost through the bone 12 mm distal to the osteotomy (Figures 1, 2). The periosteum of the radius between the osteotomy and the cut was removed and the wound was closed in layers.

To enable a sheath of callus to form around the osteotomy, providing stability, the rabbits were not given any treatment for 3 weeks following the operation. In this way a biological osteosynthesis was achieved before the indomethacin or placebo regimens were started.

Indomethacin treatment. Three weeks after the operation, indomethacin suspension (Confortid, Dumex Ltd., Copenhagen, Denmark) or placebo (Vehiculum, Confortid suspension) was squirted into the rabbits' mouths once a day, 6 days a week (Sudmann, 1975 b). The doses were 10 mg/kg/day for 2 weeks followed by 5 mg/kg/day for another 4 weeks. The rabbits were weighed once a week and the dosage adjusted accordingly.

Fluorochrome labels. On the first day of indomethacin treatment a single dose (5 mg/kg) of calcein (type 2315, Merck, Darmstadt, Germany) was given slowly intravenously under neuroleptanaesthesia. The calcein was given as a 2 per cent solution dissolved in 2 per cent $NaHCO_3$. Three weeks later the animals were given a single dose (33 mg/kg) of oxytetracycline (OTC) (Oxy-Dumocyclin, Dumex Ltd., Copenhagen, Denmark) by the same method.

Evaluation

All the laboratory analyses and evaluations were carried out without knowledge of which groups (indomethacin or placebo) the specimens or histological sections belonged to.

Indomethacin analysis. Heparinized blood samples for indomethacin analysis were drawn from anaesthetized animals 12 and 43 days after the start of the indomethacin treatment. They were taken 24 hours after the daily dose of indomethacin or placebo. The blood samples were centrifuged and plasma samples were stored frozen and stored at −21°C until analysis (Sudmann, 1978). The presence of the concurrent indomethacin metabolite desmethylindomethacin was not tested for by this method. The samples were analysed by Dumex, Copenhagen, Denmark.

X-rays. Radiographs of the right radius were obtained on Kodak dental film 3 weeks after the operation (Figure 2).

Histological examination. The animals were killed by a lethal intravenous dose of pentobarbital and the radius and the ulna were dissected free from the soft tissue and removed *en bloc*. The specimens were fixed in 4 per cent formaldehyde and sectioned transversely with a circular dental saw. The right radius and ulna were cut through at the levels of the osteotomy and in the middle of the bone fragment between the two. The left radius and ulna were cut only once (Figure 1). The bone specimens were embedded and fastened with crown wax and 90 μm thick sections were cut in a thin sectioning machine (Gillings-Hamco, Hamco Machines Inc., Rochester, N.Y., USA). Those from the right side were numbered 1 to 6 as shown in Figure 1.

All sections were evaluated by incident

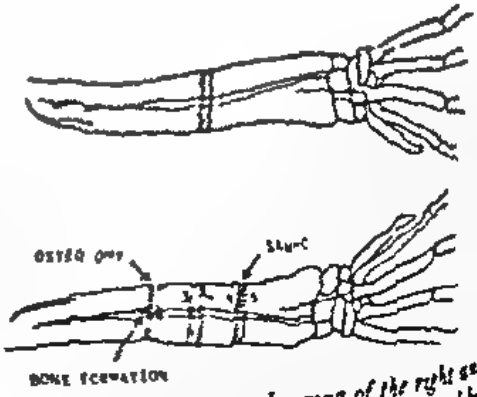

Figure 1. Schematic drawing of the right radius and ulna. The osteotomy is bridged by a bone on the ulnar side. At sacrifice one decalcified 90 μm cross section was cut from the hatched area. The cross sections from the right side were numbered 1 to 6.



2 Radiograph of typical right forelimb
otomy (O) is bridged by sparse mineralized
(C) on the ulnar side 3 weeks after the
m The saw-cut (S) is barely visible The
e between the osteotomy and the saw-cut
d 12 mm

nce microscopy with a standard Leitz
an fluorescence microscope Blue excitation
n and Leitz suppression filter 530 nm were
The area of the cortex, excluding any
and endosteal callus, was measured in
mixed image planimetry (Sudmann 1975 a)
rochrome-labelled haversian systems were
The number of OTC-labelled haversian systems in specimens from the right side were expressed as a percentage of the calcein labelled ones in the same sections.

Statistics Differences in measurements were tested by the Wilcoxon two-sample rank sum test and the Wilcoxon-Van Elteren block test for grouped data (Høyland & Walloe 1977). The *P* values given refer to two-tailed tests. Differences [illegible] 0 05, except [illegible] were con- [illegible] The results [illegible]

RESULTS

The animals tolerated the osteotomies well. One rabbit died after 37 days of indomethacin treatment and was excluded from the results of OTC fluorochrome labelling At autopsy (by the State Veterinary Laboratory for Northern Norway, Harstad, Norway) recent gastrointestinal bleeding was observed There was no significant difference in weight



Fluorescence photomicrograph of three fluorochrome-labelled haversian systems in different phases
lelling Left and middle outer label is green (calcein) and inner yellow (OTC) Right yellow label
mly Undecalcified cross section from right radius of placebo-treated rabbit Objective 25x/0 65
idth, 0 4 mm.

and their weights ranged from 2.0 to 2.7 kg. They were given an ordinary rabbit laboratory diet (Felleskjøpet, Trondheim, Norway) and water *ad libitum* from noon to the following morning. To make them take the indomethacin or placebo suspensions more readily at noon, they were deprived of water during the morning. They were kept separately in metal cages at 21°C, with 60 per cent humidity and a 12 h light, 12 h dark cycle.

Experimental design

Operative procedure. Under neurolept anaesthesia (Hypnorm Vet. 0.3 ml/kg intramuscularly, Mecos, Helsingborg, Sweden) and sterile conditions a 0.12 mm wide transverse osteotomy was made in the middle of the right radius by means of a circular dental saw. Another cut was made almost through the bone 12 mm distal to the osteotomy (Figures 1, 2). The periosteum of the radius between the osteotomy and the cut was removed and the wound was closed in layers.

To enable a sheath of callus to form around the osteotomy, providing stability, the rabbits were not given any treatment for 3 weeks following the operation. In this way a biological osteosynthesis was achieved before the indomethacin or placebo regimens were started.

Indomethacin treatment. Three weeks after the operation indomethacin suspension (Confortid, Dumex Ltd., Copenhagen, Denmark) or placebo (Vehiculum Confortid suspension) was squirted into the rabbits' mouths once a day, 6 days a week (Sudmann, 1975 b). The doses were 10 mg/kg/day for 2 weeks followed by 5 mg/kg/day for another 4 weeks. The rabbits were weighed once a week and the dosage adjusted accordingly.

Fluorochrome labels. On the first day of indomethacin treatment a single dose (5 mg/kg) of calcein (type 2315, Merck, Darmstadt, Germany) was given slowly intravenously under neurolept anaesthesia. The calcein was given as a 2 per cent solution dissolved in 2 per cent $NaHCO_3$. Three weeks later the animals were given a single dose (33 mg/kg) of oxytetracycline (OTC) (Oxy-Dumocyclin, Dumex Ltd., Copenhagen, Denmark) by the same method.

Evaluation

All the laboratory analyses and evaluations were carried out without knowledge of which groups (indomethacin or placebo) the specimens or histological sections belonged to.

Indomethacin analysis. Heparinized blood samples for indomethacin analysis were taken from anaesthetized animals 12 and 4 days before the start of the indomethacin treatment. These were taken 24 hours after the daily dose of indomethacin or placebo. The blood samples were centrifuged and plasma [illegible] frozen and stored at −21°C until [illegible] 1978). The presence of the [illegible] indomethacin metabolite desmethylindomethacin was not tested for by this method (Jensen [illegible]). The samples were analysed by Dumex, Copenhagen, Denmark.

X-rays. Radiographs of the right radius were obtained on Kodak dental film 3 weeks after the operation (Figure 2).

Histological examination. The animals were killed by a lethal intravenous dose of pentobarbital and the radius and the ulna were dissected free from the soft tissue and removed en bloc. The specimens were fixed in 4 per cent formaldehyde and sectioned transversely with a circular dental saw. The right radius and ulna were cut through at the levels of the osteotomy and [illegible] in the middle of the bone fragment between the two. The left radius and ulna [illegible] (Figure 1). The bone specimens were dehydrated and fastened with crown wax and 90 μm [illegible] sections were cut in a thin sectioning machine (Gillings-Hamco, Hamco Machines Inc., Rochester, N.Y., USA). Those from the right side were numbered 1 to 6 as shown in Figure 1.

All sections were evaluated by [illegible]

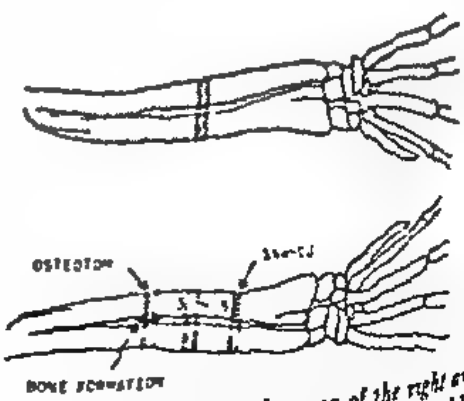

Figure 1. Schematic drawing of the right and left radius and ulna. The osteotomy is bridged by a [illegible] bone on the ulnar side. At sacrifice one [illegible] decalcified 90 μm cross section was cut from each [illegible] hatched area. The cross sections from the right side were numbered 1 to 6.

gen (1976) found subnormal osteoclastic steoblastic activity indices in the iliac of a patient with indomethacin-induced ion of periosteal fracture healing The gs of the present study and of this us study seem to support the conten- that indomethacin inhibits normal remodelling However, in a fractured eotomized bone the rate of haversian elling is markedly increased by the a inflicted on the tissues, whereas post- atic inflammation is absent in normal homeostasis Thus our findings throw light on the question of whether ethacin also affects the normal rates of l remodelling

ent studies indicate that indomethacin inhibit fracture healing in patients l by plaster casts (Sudmann 1975 b, Rø 1976, Sudmann & Hagen 1976, bakk & Røysland 1977, Sudmann et al This study suggests that the same s to fractures and osteotomies treated id internal osteosynthesis. Thus, in- hacin should preferably not be given to atients with recent fractures or os-

OWLEDGEMENTS

esent study was supported by grants from orwegian Council for Science and the ities and AO-International Bern land Indomethacin and placebo suspensions were put at our disposal by Dumex Ltd, Copenhagen, Denmark, who also performed the indomethacin analysis.

REFERENCES

Almåsbakk, K & Røysland P (1977) Does indomethacin (IMC) prevent postoperative ectopic ossification in total hip replacement? (Abstract) *Acta orthop scand* **48**, 556

Alván, G, Orme, M, Bertilsson, L, Ekstrand, R & Palmér, L (1975) Pharmacokinetics of indomethacin *Clin Pharmacol Ther* **18**, 364–373

Høyland, A Walløe, L (1977) *Elementaer statestikk*, p 128–129, Tapir Trondheim

Jensen, K M (1978) Determination of indomethacin in serum by an extractive alkylation technique and gas liquid chromatography *J Chromatogr* **153**, 195–202.

Matter, P, Brennwald, J & Perren, S M (1974) Biologische Reaktion des Knochens auf Osteosyntheseplatten *Helv chir Acta*, Suppl. 12

Rø J, Sudmann, E & Marton, P F (1976) Effect of indomethacin on fracture healing in rats. *Acta orthop scand* **47**, 588–599

Schenk, R & Willenegger, H (1964) Zur Histologie der primaren Knochenheilung *Langenbecks Arch klin Chir* **308**, 440–452.

Sudmann E (1975 a) Mixed-image planimetry Assessment of a new method for stereometric analysis in microscopy *Acta orthop scand*, Suppl 160 45–64

Sudmann E (1975b) Effect of indomethacin on bone remodelling in rabbit ear chambers. *Acta orthop scand*, Suppl 160, 91–115

Sudmann E & Hagen, T (1976) Indomethacin induced delayed fracture healing *Arch orthop Unfall Chir* **85**, 151–154

Sudmann, E, Dregelid E, Bessesen A & Mørland, J (1979) Inhibition of fracture healing by indomethacin in rats. *Europ J Clin Invest* **9** (In press).

dence to Einar Sudmann, M D, Hagavik Orthopaedic Hospital, University of Bergen, Hagavik, Norway

hop scand 50, 629–634, 1979

ECTS OF CYCLOPHOSPHAMIDE ON MECHANICAL PERTIES OF BONE AND SKIN IN RATS

IK WIE, LARS B ENGESAETER & EVA I. BECK

te for Surgical Research, Rikshospitalet, University of Oslo, Norway

The effects of several different doses of cyclophosphamide on weight increase, longitudinal bone growth and mechanical properties of bone, intact skin and skin wounds, were studied in 30 young, male rats. The cytostatic effect was evaluated by counting white blood cells (WBC) in arterial blood at the end of the medication period

Compared with the control animals, the longitudinal bone growth, the mechanical properties of the distal femoral metaphysis and the skin wounds were most noticeably affected by the drug Diaphyseal torsional strength of the femoral bone and tensile strength of intact skin were less affected

Key words bones, cyclophosphamide, mechanical properties, rats, skin, tensile strength, white blood cells, wound healing

Accepted 24 III 79

phosphamide has been found to retard aling of open, granulating skin wounds (Wie et al 1979) and to reduce the strength of incisional skin wounds in at doses comparable to intensive eutic dose schedules in man (Cohen et 75)

rference with the development of bone in rats by damaging the cartilage cells epiphyseal plate of the long bones has observed by Giambelli (1961) The drug delays reabsorption of bone fragments e-formation of bone in rats and rabbits fractures (Fesani et al Mangione & Taverna 1964)

our knowledge the effects of osphamide on the mechanical pro- of growing bones have not previously vestigated The present study in rats, was undertaken to assess the of various doses of cyclophosphamide mechanical properties of growing intact skin and sutured skin wounds. The weight increase of the rats and the longitudinal bone growth were also evaluated

MATERIALS AND METHODS

Thirty male, inbred WKY/N/Mol (F 21), SPF rats aged 24 days, with a mean initial weight of 75 3 ± 11 3 g, were used Five to six animals were kept in each cage Standard animal pellets (Bl nr 3155, Mollesentralen, Oslo) and water *ad libitum* were supplied The animals were kept in rooms with automatic regulation of light, temperature and relative humidity The animals were weighed every second day An additional six rats were sacrificed immediately to provide initial bone length values. For the experiments the rats were divided into two weight-matched groups, one was given cyclophosphamide, the other placebo

Cyclophosphamide (Sendoxan*, Pharmacia, Uppsala, Sweden) was dissolved in sterile water and injected intraperitoneally every second day for

0079 060629–06$02.50 0

© 1979 Munksgaard, Copenhagen

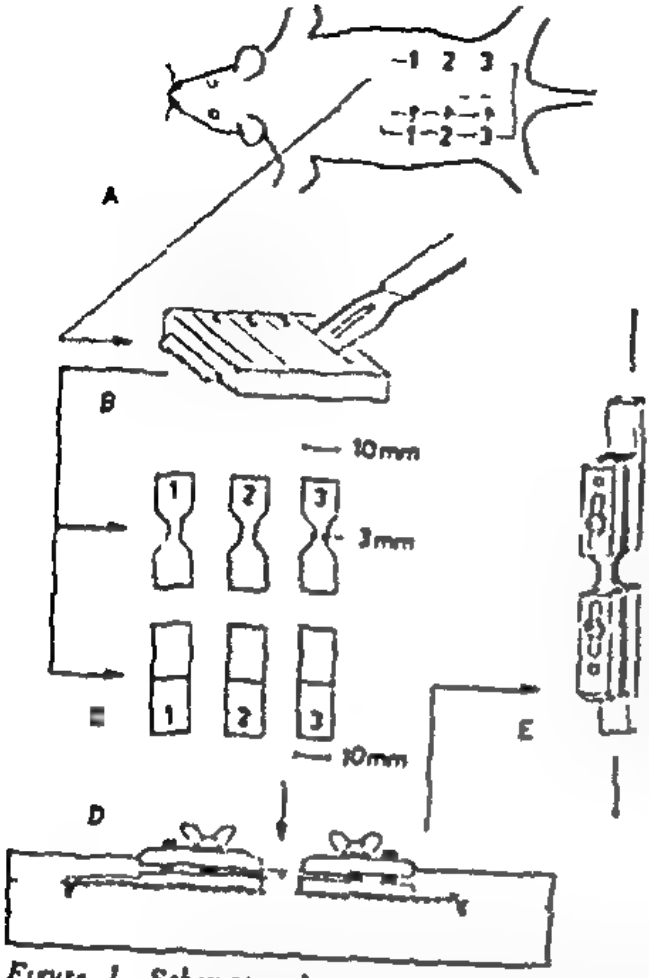

Figure 1. Schematic drawing of the equipment used for preparation and tensile strength testing of intact and sutured skin specimens. (A) rat with specimen sites, (B) template for preparation of specimens, (C) skin specimens, (D) mounting equipment, (E) clamps for mounting in the tensile testing machine.

by counting white blood cells (WBC) at the end of the medication period.

After intramuscular anaesthesia (Hypnorm®, Mekos) the backs of the animals were shaved and cleansed with 0.5 per cent chlorhexidine. Incisional skin wounds were inflicted under aseptic conditions using the following procedure.

One centimeter to the left and parallel to the caudal part of the spine a 3.5 cm longitudinal incision was made through the skin and down to the fascial layer (Figure 1A). The wounds were closed with three interrupted sutures (4–0 Vicryl®, Ethicon) and left undressed. The sutures were removed after 1 week. No signs of infection were seen in the wounds.

Fourteen days after the start of the experiments the rats were anaesthetized with ether and blood was collected by puncture of the aorta at the iliac bifurcation. Death followed by exsanguination. Immediately after death the femurs were dissected free from surrounding tissues and stored (−20° C) until tested.

After thawing in isotonic salt solution [illegible] with a sliding caliper (reading accuracy [illegible]).

The bending strength of the distal right metaphysis was measured 3 mm proximal to the epiphyseal plate as described by Engesaeter (1979).

The left femur was subjected to torsional tests: the distal end of the femur [illegible] the left side of the backs of the animals [illegible] skin from the right side. The skin was [illegible] Petri dishes at −20° C in a naturally moist condition until tensile testing was performed. By means of a special template (Figure 1B) the samples were cut with a scalpel, while still [illegible] into appropriate specimens. The template provided with four main parallel clefts, [illegible] long and 10 mm apart. Between these clefts are two smaller clefts, 7 mm long and 5 mm [illegible]. The wounded skin was cut into three 10 mm strips with the wound in the centre. The intact skin specimens were prepared with a wide central narrowing to prevent rupture in the clamps when tested (Figure 1C). Three [illegible] were obtained from each side of the animal. The clamps and the mounting equipment (Figure 1E, F) ensured a constant separation of 10 [illegible] between the clamps.

Both bending and torsional tests of the femur bones, and the tensile testing of skin samples were performed in a standard electro-hydraulic test strength tester (Type 7–1/1, A/B Lorentzen & Wettre, Stockholm, Sweden) which was run at a constant rate (2.5 degrees per second for bone tests, and 0.125 mm/mm/s for skin). The [illegible] values were transferred by a transducer (Type Kraftaufnehmer Type U 1, load range 0–10 [illegible] Hottinger Baldwin Messtechnik, Darmstadt, Germany) to a chart recorder (Riken Denshi [illegible] Ltd., Tokyo, Japan, model SP-J5B).

Statistical analyses

Medians with 25- and 75- fractiles were used to express the average and dispersion of the measured values. Statistical significance was determined using the Wilcoxon two-sample test and differences were considered significant if $P < 0.05$ (Diem & Lentner 1975).

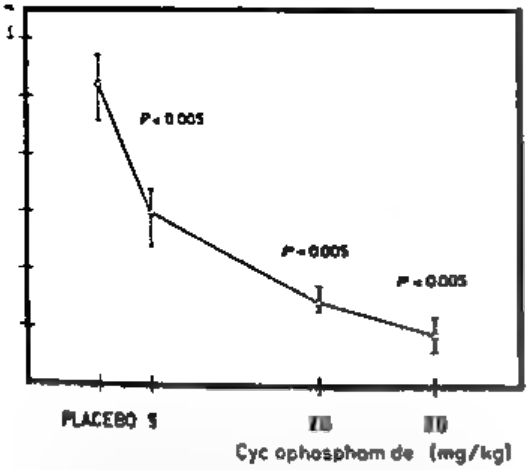

2 Median white blood cell counts (WBC) arterial blood of the rats after 5 20 and /kg body weight of cyclophosphamide and

is

JLTS

14 days of medication the WBC count mm^3 had dropped to 60 per cent in the m the 5 mg/kg dose schedule, to 30 per with the 20 mg/kg dose schedule, and to er cent with the 30 mg/kg dose sched- as compared with the placebo group re 2)

weight increases of the animals d a corresponding course except for on the lowest dose schedule These ls exhibited a significantly greater t increase than the placebo group 05) The weight gain in the 20 mg/kg was about 30 per cent lower and in the /kg group about 73 per cent lower than placebo group (Figure 3)

median initial length of the right was 22 18 mm (Figure 4) The udinal growth of the femurs was ed by the 20 and 30 mg/kg schedules, values about 91 and 89 per cent tively, of control ($P<0.005$) The t dose schedule (5 mg/kg) showed a tion of approximately 1 per cent ared with control values ($P=0.05$) on the initial bone length rements, longitudinal bone accretion showed a reduction of 6 69 5 and 83 per cent respectively, for the 5, 20 and 30 mg/kg schedules when compared with bone accretion in the control animals

The metaphyseal bending moment of the right femurs showed a reduction of about 13 per cent ($P<0.005$) for the 5 mg/kg schedule when compared with the placebo group (Figure 5) In the highest dosage groups, however, the reduction was about 35 per cent ($P<0.005$)

Diaphyseal torsional tests of the left femur did not give as clear-cut results as the bending test of the metaphysis (Figure 5) There was a percentage reduction of 6 to 10 for the 5 and 20 mg/kg schedules but of only 1 to 2 per cent for the 30 mg/kg schedule Only the reduction in the 20 mg/kg schedule was however, significant ($P=0.025$)

The mechanical properties of intact skin of growing rats was not significantly influenced by the 20 mg/kg schedule The 5 and 30 mg/kg schedules, however, resulted in about a 20 per cent reduction in the strength ($P=0.05$ and $P<0.005$ respectively) of intact skin (Figure 6)

Sutured skin showed a linear relationship between tensile strength and dose level (Figure 6) with reductions of about 11, 24, and 37 per cent for the 5, 20, and 30 mg/kg

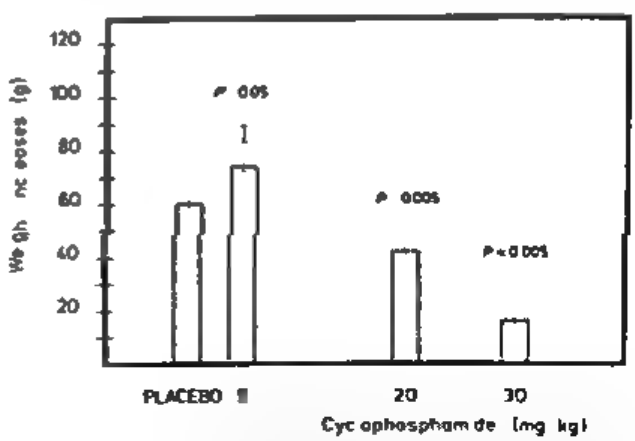

Figure 3 Effect of various dose schedules of cyclophosphamide on the body weight development in rats Columns show median weight increments with 25 and 75 fractiles indicated Cyclophosphamide and placebo were given intraperitoneally every second day for 14 days $P \leq 0.05$ significantly different from controls

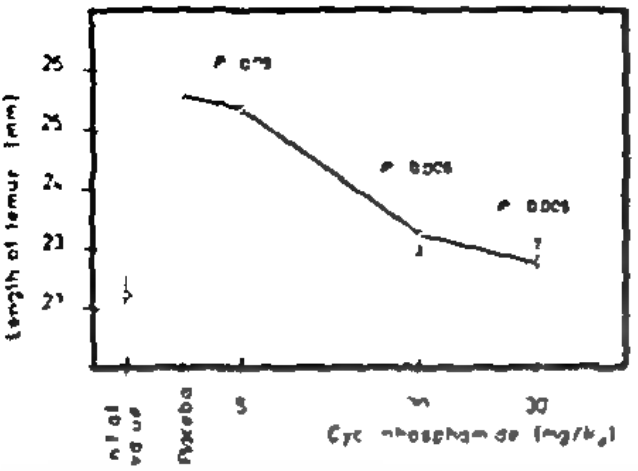

Figure 4 Length of the right femur measured from the top of the caput to the distal end of the medial condyle Cyclophosphamide doses and placebo were given intraperitoneally every second day for 14 days Median values with 25- and 75 fractiles are indicated Dotted line indicates initial length measurements P<0 05 significantly different from controls

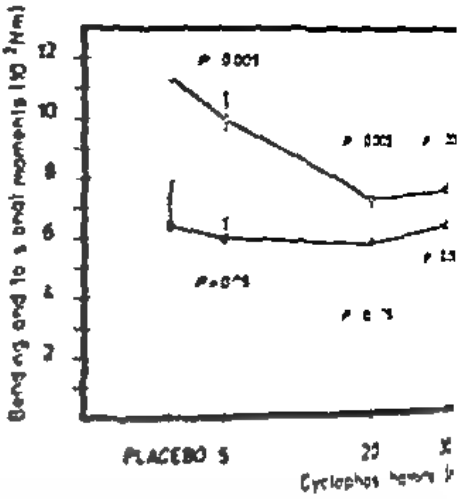

Figure 5 The bending moment of the dis... femoral metaphysis 3 mm proximal ... epiphyseal plate (○–○) and the torsional ... of the left femur diaphysis (□–□) ... of cyclophosphamide and placebo were ... traperitoneally every second day for 14 ... Median values with 25 and 75-fractiles ... dicated Nm = Newton metre P ... significantly different from controls

schedules respectively The effect of the lowest dose schedule was, however, not significant

5 mg/kg schedule as compared w... controls. There seems to be no rea... explanation for this observation

Torsional tests of the left femoral d... did not reveal clear-cut differences b... placebo and the various dose levels

DISCUSSION

The present study has revealed that the longitudinal growth of bone and the development of mechanical strength of bone and skin in young rats are affected by cyclophosphamide These effects seem to be dose dependent, and were observed even with a total dose of 35 mg/kg (5 mg/kg every second day for 14 days) which gave a 40 per cent reduction in the WBC count With doses giving a WBC count reduction of 70 to 80 per cent of normal, the metaphyseal bending strength of the right femur was reduced by about 35 per cent compared with the controls, and the longitudinal bone accretion by 70 to 80 per cent

The weight development of the rats did not follow the expected pattern as there was a seemingly increased growth rate in the

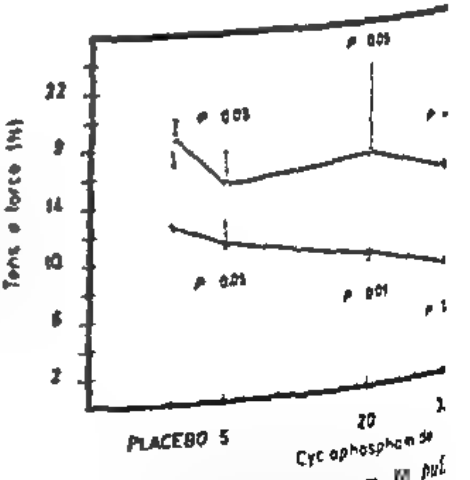

Figure 6 Tensile force necessary ... pul... intact (○–○) and wounded (△–△) sk... sp... from rats given various doses of cyclophosp... or placebo intraperitoneally every second ... 14 days Median values with 25 and 75-f... are indicated N=newtons P≤0 05 signi... different from controls

The reason may be that the torsional not sensitive to drug effects in bone the bending test, which yielded signifi differences at all dose levels The ation may, however, reveal real nces in the susceptibility of the seal and metaphyseal bone to the drug of the explanation may be found in the of growth of the femur (Engesaeter & 1978) During the medication period a small part of the cortex of the seal bone is formed whereas the udinal growth which is mainly confined epiphyseal plate near the knee, was to be 3 to 4 mm in control animals In mg/kg schedule nearly all the tested physeal bone (3 mm proximal to the seal plate) was produced under the nce of the drug and this may explain difference between metaphyseal and seal test results The explanation is however valid for the 20 and 30 mg/kg lules which reduced median bone tion to 1 1 and 0 6 mm, respectively, g the observation period

e tensile strength of intact skin was ed 12 to 20 per cent by the dose levels in the present study as compared with bo controls and skin wound strength reduced by 11 to 37 per cent at the same levels As far as wound tensile strength oncerned the present results are in ment with the findings of DesPrez & n (1960) Also the observations of Calnan Davies (1965) agree with those of the nt study as they found no significant t on wound tensile strength after a total of 35 mg/kg spread over 5 days. The t of elevated dose levels on the tensile gth of incisional wounds are in ment with the results of Cohen et al)

here is a possibility that the highest dose s in the present study produce a ctic condition in the animals, which t explain the marked influence on tudinal bone growth and bending gth of the femurs. The fact that a significant influence on these parameters was observed at the lowest dose level (5 mg/kg × 7) at which the weight increase of the animals was not adversely affected and where the WBC count was kept at a tolerable level, indicates that the effect is not merely a manifestation of generalized toxicity, but may result from a direct influence of the alkylating agent on the tissue components participating in the formation of bone The observation of a concomitant influence on bone and skin tissues supports the assumption (Cohen et al 1975, Hansen & Lorentzen 1975) that the main common denominator of these tissues, the collagen framework, is affected by the drug

ACKNOWLEDGEMENTS

The study was supported by the Norwegian Research Council for Science and the Humanities and the Norwegian Society for Fighting Cancer

REFERENCES

Calnan J & Davies, A (1965) The effect of methotrexate (Amethopterin) on wound healing an experimental study *Brit J Cancer* 19, 505 512

Cohen S C Gabelnick H L Johnson R K & Goldin A (1975) Effects of cyclophosphamide and adriamycine on the healing of surgical wounds in mice *Cancer* 36, 1277 1281

DesPrez J D & Kiehn L (1960) The effect of cytoxan (cyclophosphamide) on wound healing *Plast Reconstr Surg* 26, 301–308

Diem K & Lentner C (eds) (1975) *Documenta Geigy Scientific tables* 7th ed pp 810 Ciba-Geigy Ltd Basel

Engesaeter L B Ekeland A & Langeland N (1978) Methods for testing the mechanical properties of the rat femur *Acta orthop scand* 49, 512 518

Engesaeter L B & Skar A G (1978) Effects of oxytetracycline on the mechanical properties of bone and skin in young rats. *Acta orthop scand* 49, 529–534

Fesani F Mangione F & Taverna L (1964) Chemoterapici antitumorali ed evoluzione del callo osseo Ateno parmenese Sez I *Acta biomedica* 35, 487–513

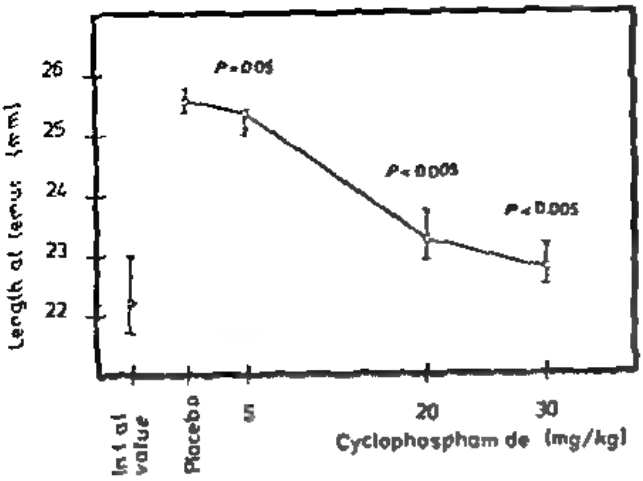

Figure 4 Length of the right femur measured from the top of the caput to the distal end of the medial condyle Cyclophosphamide doses and placebo were given intraperitoneally every second day for 14 days Median values with 25- and 75-fractiles are indicated Dotted line indicates initial length measurements P≤0 05 significantly different from controls

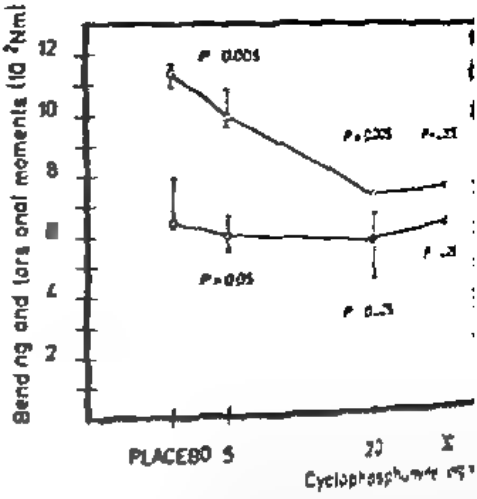

Figure 5 The bending moment of the d... femoral metaphysis 3 mm proximal to epiphyseal plate (○ ○) and the torsional ... of the left femur diaphysis (□–□) ... of cyclophosphamide and placebo were given intraperitoneally every second day for 14 ... Median values with 25 and 75-fractiles ... dicated Nm Newton meter ... significantly different from controls

schedules, respectively The effect of the lowest dose schedule was, however, not significant

5 mg/kg schedule as compared with controls. There seems to be no reason explanation for this observation.

Torsional tests of the left femoral diaphysis did not reveal clear-cut differences between placebo and the various dose levels of

DISCUSSION

The present study has revealed that the longitudinal growth of bone and the development of mechanical strength of bone and skin in young rats are affected by cyclophosphamide These effects seem to be dose dependent, and were observed even with a total dose of 35 mg/kg (5 mg/kg every second day for 14 days), which gave a 40 per cent reduction in the WBC count With doses giving a WBC count reduction of 70 to 80 per cent of normal, the metaphyseal bending strength of the right femur was reduced by about 35 per cent compared with the controls and the longitudinal bone accretion by 70 to 80 per cent

The weight development of the rats did not follow the expected pattern as there was a seemingly increased growth rate in the

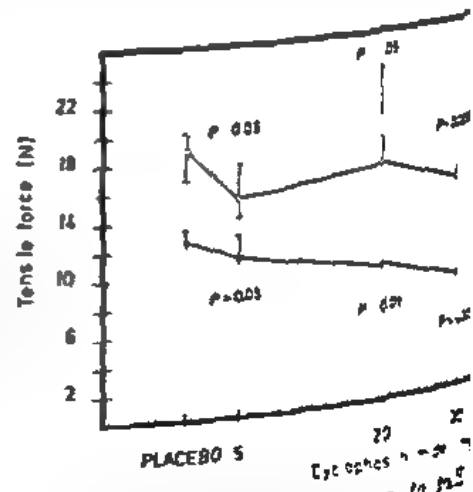

Figure 6 Tensile force necessary to pull intact (○–○) and wounded (Δ–Δ) skin ... from rats given various doses of cyclophosphamide or placebo intraperitoneally every second day ... 14 days Median values with 25- and 75- ... are indicated N=newtons P≤0 05 significantly different from controls

Acta orthop scand 50 635–63 , 1979

E PERIOSTEAL CONTROL OF LONG BONE GROWTH

Experimental Study in the Rat

HOLGHTON & S DEKEL

eld Orthopaedic Centre, Oxford, England

Longitudinal growth of immature rat femurs was studied in diffusion chambers after circumferential periosteal division and stripping After 14 days significant ($P < 0.02$) overgrowth of the periosteally divided femurs had occurred The reason for the observed growth stimulation is discussed.

Key words bone lengthening, growth, leg length inequality, organ culture periosteum

Accepted 24 m 79

v investigations have shown that ping of the periosteum from a long bone ble to stimulate growth plate activity and increase longitudinal bone growth (Ollier 7, Wu & Miltner 1937, Brodin 1955, Sola 1963) This phenomenon has been used cally to correct leg length discrepancy d & Trillat 1948, Taillard 1959, Chan odgson 1970, Jenkins et al 1975)

was not until 1972 that Crilly noted that mferential incision of the periosteum, out extensive stripping, stimulated long growth. This has been confirmed by r investigators (Warrell & Taylor 1976, de Sandt 1977)

revious investigations involving perios- and long bone growth have been carried on orthotopic living bone The experi- t described below studies the effect of osteal division on isolated bone growing in sion chambers.

TERIALS AND METHODS

xperimental technique is shown in Figure 1 was similar to that described by Niv et al.). Six-day-old rat femurs of the Sprague ey strain were dissected extra periosteally utilizing micro-surgical techniques. The periosteum of each right femur was incised circumferentially and the middle one-third stripped, each left femur acted as a control. Before implantation both femurs were measured aseptically using the Vernier on the stage of a microscope Each end of the femur was lined up with a marker in the microscope eyepiece, and the difference on the Vernier scale taken as the femoral length Repeated measurement showed the method to be accurate to within 0 1 mm. After measurement both femurs were placed in the same pre-sterilized millipore diffusion chamber (millipore GS 0 22 μm) and the chamber sealed (millipore MF cement No 1) and then inserted into the peritoneal cavity of an adult male rat Two chambers were inserted intraperitoneally into each host rat and were identified by marking the chamber rim

The femurs of 38 neonatal rats were used and the growth was measured after sacrifice of the host rats at 7 14 and 21 days, respectively Statistical significance was assessed using the Student's *t*-test

RESULTS

At sacrifice of the host rats it was noted that eight diffusion chambers were infected and the enclosed femurs had grown very little These infected chambers were therefore not included in the statistical analysis.

64^0 ^9 060635–03$02.50 0

© 1979 Munksgaard, Copenhagen

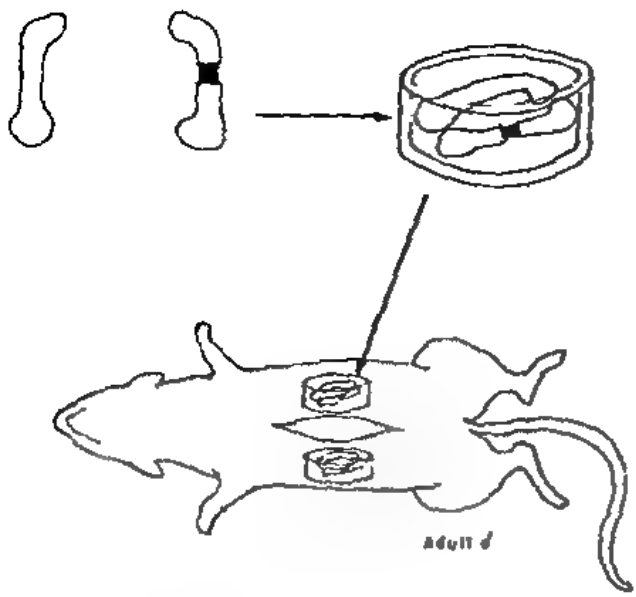

Figure 1 Experimental steps described in the text

Table 1 shows the mean growth of the femurs at 7, 14 and 21 days, respectively As can be seen there was little further growth of the femurs after 14 days, and at this stage the periosteally stripped femurs had grown significantly more than the control femurs.

Table 2 analyses the difference in growth between paired periosteally stripped and control femurs. Overgrowth resulted from periosteal stripping in all animal groups, but reached statistical significance ($P < 0.02$) only in the 14-day group However, no control femur overgrew more than 0 2 mm, which is the accuracy of the method of measurement If the three groups are analysed together then the larger group shows a highly statistically significant overgrowth of the periosteally stripped femurs ($P < 0.0001$)

Table 1 Mean growth of the femurs in [illegible] chambers

Days	n (pairs)	Growth (mm) Control	Experim[illegible]
7	8	0 78 ± 0 08	0 93 ± [illegible]
14	16	0 95 ± 0 09	1.21 [illegible]
21	6	0 92 ± 0 21	1.22 ± [illegible]

* $P < 0.05$
Mean ± s e mean

Table 2 The difference in growth between [illegible] periosteally stripped and control femurs

Days	n (pairs)	Overgrowth (mm) ††	[illegible]
7	8	0 15	0 19*
14	16	0.244	0.54
21	6	0 30	0.34*
7–21	30	0 23	0.[illegible]

* $P > 0.05 < 0.10$
** $P < 0.02$
*** $P < 0.0001$
†† Mean overgrowth of the stripped as compared with control femur

DISCUSSION

The cause of stimulation of long bone growth after periosteal trauma is not known Trueta believed that the important factor was interruption of the metaphyseal vessels with subsequent medullary ischaemia (Trueta & Amato 1960) Other investigators have shown that there is hyperaemia around the growth plate following periosteal injury associated with fracture (Wray & Goodman 1961) Lacroix in 1947 postulated the release [illegible] local hormone, the growth stimulating [illegible] stance, which acted on the growth plate [illegible] the injured bone only

More recently, a mechanical theory [illegible] been postulated (Crilly 1972). The [illegible] elastic periosteum is loosely attached to [illegible] shaft of a growing long bone and [illegible] periosteal attachment at either end of [illegible] bone at the perichondral ring is very [illegible] It is postulated that during growth the [illegible] periosteum is stretched and its tension [illegible] a mechanical restraint on elongation of [illegible] bone at the growth plate If this restraint [illegible] released by circumferential division of [illegible] periosteum, then growth will be accelerated [illegible] Our findings support this theory

The immature femurs in [illegible] chambers have no blood supply so vascular [illegible] disturbances are not operative Local growth [illegible]

r hormones would affect control and ex-
ental femurs similarly

therefore conclude that the intact
teum mechanically checks the growth
and circumferential periosteal division
es this restraint to increase longitudinal
h.

NOWLEDGEMENTS

ould like to thank Professor R B Duthie for
ncouragement, Mrs. O Kingsworth, who
this manuscript, and Mrs. H Rogers and
I Timms for their technical assistance

FRENCES

P & Trillat, A (1948) Le traitement des
ités de longueur des membres inferieurs
la croissance *Rev Chir orthop* 34,
4–311

n H (1955) Longitudinal bone growth, the
ution of the epiphyseal cartilages and the
blood supply *Acta orthop scand*, Suppl
)

K P & Hodgson, A R (1970)
siological leg lengthening A preliminary
Clin Orthop 68, 55–62

R G (1972) Longitudinal overgrowth of
cken radius. *J Anat (Lond)* 112, 11–18

D H R, Cheng D H F & Hodgson, A
(1975) Stimulation of bone growth by
nosteal stripping *J Bone Jt Surg* 57 B
2–484

Lacroix, P (1947) Organisers and the growth of bone *J Bone Jt Surg* 29, 292–296

Niv, A I, Binderman, I, Harell, A & Weissman, E L (1976) Growth of the rat femur in diffusion chambers *Acta orthop scand* 47, 226–230

Ollier, L (1867) *Traité expérimentale et clinique sur la regénération des os et de la production artificielle du tissu osseux* Vol 1, Masson et Cie, Paris.

Sola C K, Silberman F S & Cabrini, R L. (1963) Stimulation of the longitudinal bone growth of long bones by periosteal stripping An experimental study in dogs and monkeys *J Bone Jt Surg* 45-A, 1679–1684

Taillard, W (1959) La stimulation de la croissance des os longs par la deperiostage *Rev med Suisse rom* 79, 28–38

Trueta, J & Amato V P (1960) The vascular contribution to osteogenesis 111 Changes in the growth cartilage caused by experimentally induced ischaemia *J Bone Jt Surg* 42 B 571–587

Van de Sandt H (1977) The influence of transverse section of the periosteum on the growth of the rabbit femur Thesis. Catholic University, Nijmegen Netherlands.

Warrell, E & Taylor, J F (1976) The effect of trauma on tibial growth *J Bone Jt Surg* 58-B 375

Wray J B & Goodman H O (1961) Post-fracture vascular phenomenon and long bone

Wr

to G H Houghton MA FRCS Nuffield Orthopaedic Centre Oxford England

orthop scand. 50, 639–643, 1979

RUM CALCITONIN AND BONE MINERAL NTENT IN PATIENTS WITH TEOGENESIS IMPERFECTA

- NIELSEN, U PEDERSEN, H HVID HANSEN & O ELBRØND

artment of Nuclear Medicine, Radium Centre and Department of Otorhinolaryngology, us Kommunehospital and University of Aarhus, Aarhus, Denmark

Serum calcitonin and bone mineral content in the forearm, measured by photon absorptiometry, were investigated in 21 patients with osteogenesis imperfecta tarda The bone mineral content was significantly reduced as compared with normal controls, whereas the bone mineral content corrected for bone width was normal in adult patients but subnormal in children and young adults. Serum calcitonin did not differ significantly from that in normal individuals and no relation was found between serum calcitonin and bone mineral content

Key words bone mineral content, osteogenesis imperfecta tarda, photon absorptiometry, serum calcitonin

Accepted 29 m 79

genesis imperfecta is an infrequent alized disease in bone and connective characterized by increased bone resorp- osteopenia and spontaneous fractures nberg et al 1977) Both short-term and term studies of calcitonin treatment have sted an improvement in bone changes in nts with osteogenesis imperfecta tarda nberg et al 1977, Castells et al 1972) asurements of serum calcitonin (s-CT) in nts with osteogenesis imperfecta have een reported before and bone mineral nt, measured by photon absorptiometry, nly been investigated in a few patients nberg et al 1977) The present study arried out to describe the bone mineral nt and biochemical values of calcium- horus metabolism, including s-CT, in nts with osteogenesis imperfecta and to ate whether a lack of s-CT could explain ecrease in bone mass in these patients.

PATIENTS AND METHODS

Patients The study comprised 21 patients with osteogenesis imperfecta tarda (13 females and 8 males) 14 – 78 years of age (mean 33 1 years) (Table 1) All patients had previously sustained spontaneous fractures, five had had 10 – 15 fractures, the others more than 15 All patients appeared with blue sclerae No patients had symptoms of gastrointestinal disease and all had normal kidney function

Methods Serum concentrations of calcium, phosphorus, alkaline phosphatase and calcitonin were measured after an overnight fast Serum calcium was corrected for individual variation in serum protein concentration (Pedersen 1973) and calculated as the calcium concentration corresponding to a protein level of 70 g/l (s-calcium corr).

Calcitonin Calcitonin was determined by a radioimmunoassay using a commercial antibody to human calcitonin (Calbiochem, USA) and synthetic human M-calcitonin (Ciba, Switzerland)

470 79 060639–05$02.50/0

© 1979 Munksgaard Copenhagen

Table 1 Clinical and biochemical data in patients with osteogenesis imperfecta

Pat no	Age/sex (years)	s-calcitonin pg/ml	s-calcium mg/100 ml	s phosphorus mg/100 ml	alk. phosphatase [illegible]
1	15/m	20	9 5	4 8	641
2	21/m	45	10 3	3 5	1
3	24/m	35	—	—	—
4	28/m	35	9 9	2.8	1 1
5	28/m	25	9 8	3 2	170
[illegible]	29/m	10	—	—	—
7	46/m	40	9 5	2.6	170
8	77/m	35	9 9	2 7	149
9	14/f	10	9 8	4 2	[illegible]
10	15/f	30	9 7	3 6	316
11	16/f	10	9 8	3 4	215
12	17/f	40	9 5	4 1	177
13	20/f	70	9 2	4 3	204
14	32/f	220	9 3	2 8	131
15	36/f	10	9 5	3 3	134
16	37/f	35	9 4	3 6	149
17	39/f	20	9 4	3 2	225
18	43/f	10	9 8	3 7	1 [illegible]
19	43/f	30	9 6	3 2	177
20	48/f	10	9 9	3 1	150
21	64/f	70	9 6	2 5	22[illegible]
Mean	33 0	39	9 65	3 4	221
Normal range		10–120	9 2–10 5	2.7–4 7	A 80–[illegible] C 200–[illegible]

A – adults
C – children

for standards and iodination ^{125}I-calcitonin was prepared by the chloramin-T method (Tashjian 1969) The labelled antigen was purified by absorption to and elution from Quso G32 (Philadelphia Quartz Co, Philadelphia, USA) (Tashjian 1969) More than 90 per cent of the labelled purified antigen could be bound by the antibody Assay conditions were modified from Dietrich et al (1975) 200 µl serum and 250 µl antibody dilution in 0 1 M tris –0 25 per cent HSA (pH = 7 3) was preincubated for 2 days at 4°C 50 µl ^{125}I-calcitonin dilution giving about 5000 cpm was added followed by 2 days incubation at 4°C Antibody-bound calcitonin was precipitated by polyethylene glycol (PEG 6000). Standards were prepared in serum from totally thyroidectomized patients Each serum was made in duplicate together with a tube without antibody to correct for incubation damage and non-specific binding of the tracer The lowest detectable concentration was 20 pg/ml The precision of double determinations was 10 pg ml Reproducibility was determined using a control serum with calcitonin level of 140 pg/ml In nine assays the coefficient of variation was 14 per cent The normal material comprised 40 healthy subjects with a mean age of 34 years (range 20 – 66)

Bone mineral content (BMC) in the forearm was measured using a GAMMATEC osteodensitometer model GT 30 with a 60–Co source (Christiansen et al 1975). The scan area was selected automatically by the instrument at the most distal position where the separation of radius and ulna exceeds 8 mm and six scans with a separation of 4 mm between each were carried out and the mean values displayed. The combined width of radius and ulna (BW) was measured from the photon absorption curves and the mean of the two arms calculated

The results were expressed as absolute values (g/cm) and in per cent of the mean values of normal controls of the same age and sex

The reproducibility of the BMC measurements

Table 2 Bone mineral content in patients with osteogenesis imperfecta

t no	Age/sex (years)	BMC g/cm	%	BW cm	BMC/BW g/cm²	%
1	15/m	21 5	50	2 6	8 3	85
2	21/m	45 4	80	2.5	18 5	102
3	24/m	37 5	66	2.4	15 6	87
4	28/m	43 7	77	2 6	17 1	94
5	28/m	45 4	80	2.7	17 1	94
6	29/m	43 0	75	2.6	16 4	91
7	46/m	48 3	82	2 5	19 2	108
8	77/m	44 2	102	2 9	15 4	117
9	14/f	20 9	65	2 3	9 1	87
10	15/f	18 0	51	2 6	7 0	54
11	16/f	22 8	65	2 2	10 4	70
12	17/f	26 3	67	3 0	8 8	72
13	20/f	33 7	81	2 0	17 3	111
14	32/f	38 2	92	2 5	15 3	105
15	36/f	38 4	92	2 4	15 9	109
16	37/f	30 9	74	2 6	11 9	82
17	39/f	31 9	78	2 6	12 5	86
18	43/f	29 7	71	2.3	12 7	88
19	43/f	36 2	86	2.9	12 7	88
20	48/f	33 1	79	3 0	11 2	77
21	64/f	29 4	107	2.4	12 2	133
Mean			77 1			92 4

C = bone mineral content
= bone width

essed as the variation coefficient was about 1 cent in normal persons (Christiansen & bro 1977).

atical evaluation For comparisons of group ns the Mann-Whitney U-test was used and for elation analysis Spearman's rank correlation

SULTS

le 2 shows the bone mineral content in ents with osteogenesis imperfecta essed in arbitrary units (dimension g/cm) as per cent of normal sex and age ched controls (BMC per cent) A reduced e mineral content ($P < 0.01$) and a reduced e width ($P < 0.01$) were found in the ents as compared with the controls No ificant relation between the total number fractures and the BMC could be onstrated After correction of the BMC bone width (BW) no difference was found in the bone mass between adult patients and normal controls, whereas the children and young adults showed subnormal values Thus BMC per cent ($R = 0.72$, $P < 0.01$) and to a lesser degree BMC/BW per cent ($R = 0.46$, $P < 0.05$) increased with age

The biochemical values of calcium-phosphorus metabolism including s-CT are given in Table 1 The mean s-CT concentration of 39 pg/ml (range 10 – 220) did not differ from the normal mean value of 38 pg/ml (range 10 – 120) Serum alkaline phosphatase was moderately increased in three patients and normal in the others. All patients revealed normal serum concentrations of calcium corr and phosphorus

DISCUSSION

The present study shows a markedly reduced bone mineral content, measured by photon

absorptiometry, in patients with osteogenesis imperfecta as compared with age and sex matched normal controls Some interference with the BMC measurements caused by post-traumatic osteoporosis following forearm fractures could not be excluded as most patients previously had had one or more fractures of the forearm The decrease in bone mineral content could mainly be explained by a similar reduction in bone width as the bone mineral content corrected for bone width was normal

These findings are supported by a previous radiological study of the width of the second right metacarpal bone in adult patients with osteogenesis imperfecta (Paterson 1978) showing a significant reduction in total bone width whereas the combined cortical width was normal Examination of bone biopsies from the iliac crest of children and young adults by bone histomorphometry (Riley et al 1973) has shown a reduced cortical width a reduced osteoid width and a decreased amount of osteons The bone formation rate was reduced in children less than 10 years old and normal in children more than 10 years of age The difference in cortical width between the two investigations (Paterson 1978 Riley al 1973) may be due to the difference in age between the patient groups The more pronounced reduction in bone mineral content in children found in the present study is in agreement with these observations and indicates that a more severe degree of disease is present in children as compared with adults

In both short-term and long term studies of calcitonin treatment of patients with osteogenesis imperfecta favourable responses have been suggested (Rosenberg et al 1977 Castells et al 1972) The study of Rosenberg et al (1977) showed a rate of increase in forearm bone mass which was greater than that observed in an untreated group of patients with osteogenesis imperfecta tarda As calcitonin inhibits bone resorption both in animals (Wallach et al 1967) and in man (Haddad Caldwell 1972) a lack of calcitonin in patients with osteogenesis imperfecta might be a contributory pathogenic factor The present study shows, however, normal s CT in all but one of the patients included in the study, and there was no relation between bone mineral content and CT

The finding of normal serum calcium concentrations in patients with osteogenesis imperfecta is similar to the finding in patients with Paget's disease in whom calcitonin treatment may induce normalizing biochemical changes (Kanis et al 1975) whereas s-CT is normal (Kanis et al 1977) or even increased (Franchimont & Heynen 1976)

A decreased sensitivity to calcitonin in bone causing a relative lack of calcitonin has been proposed to explain the findings in Paget's disease (Woodhouse et al 1971) and an acquired tissue resistance to calcitonin secondary to a viral infection has been suggested (Rebel et al 1975), as nuclear inclusion bodies have been demonstrated in the osteoclasts (Rebel et al 1975).

ACKNOWLEDGEMENTS

The study was supported by grants from the Danish Medical Research Council (no. 31?-6? and no 512–8159)

REFERENCES

Castells S Inamdar S Baker R A. & Walker S (1972) Effect of porcine calcitonin in osteogenesis imperfecta tarda *Pediatrics* 757–762

Christiansen C & Rødbro, P (1977) Long-term reproducibility of bone mineral content measurements. *Scand J clin Lab Invest* 321–323

Christiansen C Rødbro P & Jensen, H. (19 Bone mineral content in the forearm measured by photon absorptiometry *Scand J clin Lab Invest* 35, 323–330

Dietrich F M Hunziker W H & Fischer J (1975) Synthetic human calcitonin analogs antibodies obtained from various animal species and determination of immunoreactivity

-mone in human sera *Acta endocr (Kbh)* 465–486

himont, P & Heynen, G (1976) *rathormone and calcitonin radioimmunoassay in various medical and osteoticular disorders* Masson Inc, New York

ad J G, Jr & Caldwell, J G (1972) alcitonin resistance, clinical and immunological studies in subjects with Paget's sease of bone *J clin Invest* 51, 3133–3141

s, J A, Fitzpatrick, K & Strong, J A (1975) reatment of Paget's disease of bone with rcine calcitonin clinical and metabolic sponses *Quart J Med* 44, 399–413

a, J A., Heynen, G & Walton, R J (1977) lasma calcitonin in Paget's disease of bone *lin Sci* 52, 329–332

rson, C R. (1978) Metacarpal morphometry adults with osteogenesis imperfecta *Brit ed J* 1, 213–214

rsen, K. O (1973) Calcium in human serum. Biochemical and clinical aspects Thesis, University of Aarhus.

el, A., Malkani, K., Basle, M & Bregon, C (1975) *Calcified tissues*, p 114, FADL's Forlag, Copenhagen

Riley, F C, Jowsey, J & Brown, D M (1973) Osteogenesis imperfecta Morphologic and biochemical studies of connective tissue *Pediat Res* 9, 757–768

Rosenberg, E, Lang, R, Boisseau, V, Rojanasathit, S & Avioli, L V (1977) Effect of long-term calcitonin therapy on the clinical course of osteogenesis imperfecta *J clin Endocr* 44, 346–355

Tashjian, A H, Jr (1969) Immunoassay of thyrocalcitonin I The method and its serological specificity *Endocrinology* 84, 140–148

Wallach, S, Chausmer, A & Mittleman, R (1967) In vivo inhibition of bone resorption by thyrocalcitonin *Endocrinology* 80, 61–64

Woodhouse, N J Y, Reiner, M, Bordier, P, Kalu, D N, Fisher, M, Foster, G V, Joplin, G F & MacIntyre, I (1971) Human calcitonin in the treatment of Paget's bone disease *Lancet* i, 1139–1143

respondence to H E Nielsen, M D, Department of Nuclear Medicine, Radium Centre, mmunehospitalet, DK 8000 Aarhus C, Denmark

thop scand. 50, 645–651, 1979

;ERVATIONS ON LONG BONE MEDULLARY PRESSURES (ELATION TO ARTERIAL PO_2, PCO_2 AND pH IN THE AESTHETIZED DOG

TØNDEVOLD, JØRGEN ERIKSEN & ERIK JANSEN

rtment of Orthopaedic Surgery T-2, Department of Anaesthesiology, Gentofte Hospital, Hellerup, Department of Anaesthesiology, Herlev Hospital, Herlev, Denmark

To investigate the influence of variations in arterial oxygen tensions (PaO_2), arterial carbon dioxide tensions ($PaCO_2$), and arterial pH on long bone medullary pressures, seven anaesthetized dogs were investigated.

Comparing the control medullary pressures, i.e. the mean medullary pressures obtained at the normal range of PaO_2 (75–110 mmHg) with the mean medullary pressures corresponding to the range of PaO_2 of <75 mmHg, statistically significant ($P < 0.05$) decreases were seen in both epiphyseal, metaphyseal and diaphyseal medullary pressures, from 27.6 ± 5.0 to 15.5 ± 3.6 mmHg, from 23.5 ± 2.9 to 13.9 ± 2.3 mmHg and from 27.7 ± 3.9 to 18.3 ± 2.5 mmHg (all mean values ± s.e. mean), respectively.

Hyperoxia, hypocapnia, hypercapnia or metabolic acidosis had no effect on medullary pressures in any of the regions studied.

Key words: aetiology, blood supply, bone, femur head, osteoarthritis, physiology, regional blood flow

Accepted 8.11.79

ording to Shim (1968) the factors control- medullary blood flow may be divided into ral, hormonal and metabolic. Results ained by Shim & Patterson (1967) suggest t the metabolic control mechanism is the st potent one, and that this control hanism is related to the oxygen and dioxide tensions (PaO_2 and $PaCO_2$), the and the acid metabolites of the arterial

s no direct correlation might be between medullary blood flow rates medullary pressures, several investigators found obvious relationships between two parameters: a low medullary means a low blood flow, and a high medullary pressure means either a high blood flow or a medullary congestion of blood due to obstruction of the venous outflow (Shaw 1963, Axuma 1964, Weinman et al. 1963, Keck & Kelly 1965).

The purpose of this study was to investigate if variations in the arterial PaO_2, $PaCO_2$ and pH caused any changes in the long bone medullary pressures (epiphyseal, metaphyseal or diaphyseal) in the anaesthetized dog.

MATERIAL AND METHODS

The investigation was performed on seven mongrel dogs (weight 29–42 kg). Anaesthesia and some of the monitoring procedures have pre-

0079 060645–07$ 2.50 ©

© 1979 Munksgaard Copenhagen

viously been described (Eriksen et al 1979) The medullary pressure was measured through metal cannulas (diameter 2 mm) placed with their tips in the bone marrow of the left femoral epiphysis, the right femoral metaphysis and the right humeral diaphysis To penetrate the cortex of the bone a 1 8 mm drill was used No leakage of medullary blood was seen when the metal cannulas were placed in the bones S & W AE 840 transducers and S & W BAP amplifiers were used for the measurements of medullary pressures Arterial blood pressures were measured by means of a catheter placed in the left branchial artery Central venous pressures (CVP) were measured in the superior caval vein via a catheter introduced into the left branchial vein Recording was made on Statham P 23Db transducers using Ellab M5-BCM amplifiers

X-ray examinations confirmed the correct positioning of the metal cannulas centrally in the bone marrow and of the CVP catheter

The fraction of inspired oxygen (FiO_2) was at first adjusted to give an arterial oxygen tension (PaO_2) of about 100 mmHg and an arterial carbon dioxide tension ($PaCO_2$) of about 40 mmHg After an equilibration period of 10 minutes in which PaO_2 $PaCO_2$ and pH were kept constant using a continuous blood gas analyser (Henningsen 1968), the following parameters were registered simultaneously PaO_2, $PaCO_2$ and arterial pH (all determined in 1 ml samples on a Radiometer ABL 1 blood gas analyser), medullary pressures (epiphyseal, metaphyseal and diaphyseal), mean arterial pressure (MAP) CVP and temperature

Variations in PaO_2 were obtained by changing the FiO_2 while $PaCO_2$ and arterial pH were kept constant Registration of the above-mentioned parameters was made at various values of PaO_2

After termination of this part of the study, PaO_2 was kept constant at about 100 mmHg and $PaCO_2$ was varied Hypercapnia was obtained by addition of CO_2 to the inspired gas mixture hypocapnia by hyperventilation Registration of parameters took place at various values of $PaCO_2$

infusion of bicarbonate, but before such treatment and at normal values of PaO_2 (about 100 mmHg) and $PaCO_2$ (about 40 mmHg) registration of parameters was made at various values of arterial pH

Equilibration periods of at least 10 minutes, during which stable values were maintained by the continuous blood gas analyser preceded each registration of parameters

In an earlier paper we have shown that long bone medullary pressure remained constant and did not change with increasing arterial b pressure, when the mean arterial blood p (MAP) was above 80 mmHg (Tøndevold e 1979) Consequently, the present study wi deal with results obtained when MAP was 80 mmHg

All medullary pressures in this study are p as "real" medullary pressures, the mea medullary pressures minus the corresp central venous pressures. This has been because of the obvious influence venous obs tion has on the medullary pressures (Arum Keck & Kelly 1965)

Calculations

Medullary pressures/PaO_2. The measure used for this part of the study were taken at values of $PaCO_2$ and arterial pH i.e. a PaC between 35–45 mmHg and an arterial pH 7 36–7 46 Different ranges of PaO_2 were sel (<75, 75–110, 111–200 201 300, >300 mmHg) and within these ranges the values ± s e mean of PaO_2 and the values ± s e mean of the corresp epiphyseal, metaphyseal and diaphyseal med pressures were calculated The normal ran PaO_2 was taken as 75–110 mmHg and the responding medullary pressures within this were the control values

Medullary pressures/PaCO The mea ments used for this part of the study taken at stable values of PaO_2, that is a PaC 75–110 mmHg Variations arterial pH allowed as long as these variations were d changes in $PaCO_2$ Within different rang $PaCO_2$ (<35, 35–45, and >45 mmHg) the values ± s e mean of $PaCO_2$ and the values + s e mean of the corresponding med pressures were calculated The normal ran $PaCO_2$ was taken as 35–45 mmHg and the responding medullary pressures within this were used as control values.

Medullary pressures/arterial pH Medu pressures used for this part of the study taken at stable values of PaO_2 (75–110 m and $PaCO_2$ (35–45 mmHg). The ranges of a pH used for the calculations were < 7 26–7 35 and 7 36–7 46. The mean value mean of arterial pH and the mean values mean of the corresponding medullary pres within these ranges were calculated The n range for arterial pH was taken as 7.36–7 45 the corresponding medullary pressures were control values

Mann Whitney rank sum test was used for ical analysis of the results obtained The .l significance for differences was chosen as ,b

JLTS

able 1 and Figure 1 the corresponding s of PaO_2 and epiphyseal, metaphyseal, diaphyseal pressures are shown paring the mean medullary pressures n the range of PaO_2 of 75–110 mmHg control medullary pressures) and mmHg the decreases in the epiphyseal, physeal and diaphyseal regions were 27 6 mmHg to 15 5 mmHg, from mmHg to 13 9 mmHg, and from mmHg to 18 3 mmHg, respectively The medullary pressures in all three regions sponding to the range of PaO_2 of mmHg were significantly ($P < 0.05$) r than the values obtained at all higher of PaO_2.

ases in PaO_2 above 75 mmHg had no on medullary pressures.

significant differences could be between the mean epiphyseal, seal or diaphyseal medullary res within the different ranges of PaO_2

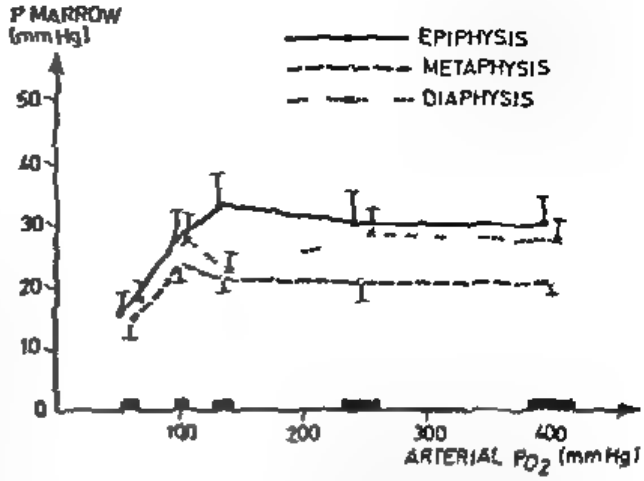

Figure 1 Long bone epiphyseal, metaphyseal and diaphyseal medullary pressures (P_{marrow}) in relation to the arterial oxygen tension (PaO_2) Mean values ± 1 s e mean of the medullary pressures obtained within different ranges of arterial PaO_2 (<75, 75–110, 111–200, 201–300 and >300 mmHg) are shown in relation to the mean arterial PaO_2 within these ranges The horizontal bars on the abscissa indicate the mean values ± 1 s e mean of arterial PaO_2 within the above-mentioned ranges of arterial PaO_2.

Table 2 and Figure 2 show the corresponding values of $PaCO_2$ and epiphyseal, metaphyseal and diaphyseal medullary pressures At the normal range of $PaCO_2$ (35–45 mmHg) the control epiphyseal, metaphyseal and diaphyseal mean medullary

1 Long bone medullary pressures ($P_{epiphysis}$, $P_{metaphysis}$ and $P_{diaphysis}$) in seven anaesthetized in relation to different ranges of the arterial oxygen tension (PaO_2) Mean values ± s e mean of and mean values ± s e mean of the corresponding medullary pressures within the ranges have calculated The control medullary pressures are the mean medullary pressures within the normal range of PaO_2 (75–110 mmHg)

ber of ons	Arterial oxygen tension (PaO_2) (mmHg) Range	Mean ± s.e mean within the range	Medullary pressures (P) (mmHg) $P_{epiphysis}$ Mean ± s.e mean	$P_{metaphysis}$ Mean ± s.e mean	$P_{diaphysis}$ Mean ± s.e mean
	<75	59 9 ± 5 9*	15 5 ± 3 6*	13 9 ± 2.3*	18 3 ± 2 5*
	75–110 (normal range)	101 6 ± 1 5	27 6 ± 5 0 (control medullary pressures)	23 5 ± 2 9	27 7 ± 3 9
	111–200	134 1 ± 7 1	33 3 ± 5 2	21 3 ± 2.5	22.4 ± 2.7
	201–300	246 5 ± 12 2	30 6 ± 4 9	20 6 ± 3 0	28 5 ± 4 1
	>300	401 7 ± 16 7	30 2 ± 4 3	20 4 ± 1 6	27 3 ± 3 1

in the respective medullary region * $P < 0.05$ indicates significance of difference from the control llary pressure

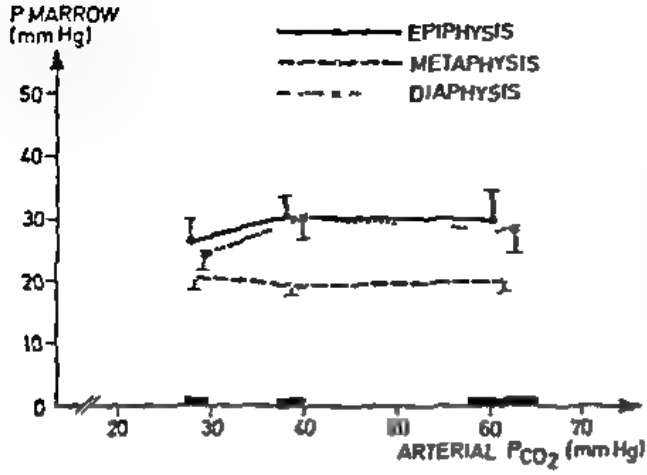

Figure 2 Long bone epiphyseal, metaphyseal and diaphyseal medullary pressures (P_{marrow}) in relation to the arterial carbon dioxide tension ($PaCO_2$) Mean values ± 1 s e mean of the medullary pressure obtained within different ranges of arterial $PaCO_2$ (35, 35–45, and > 45 mmHg) are shown in relation to the mean arterial $PaCO_2$ within these ranges The horizontal bars on the abscissa indicate the mean values ± 1 s e mean of arterial $PaCO_2$ within the above-mentioned ranges of arterial $PaCO_2$

pressures were 30 5 mmHg, 19 5 mmHg and 30 1 mmHg, respectively Variations in $PaCO_2$ caused no significant changes in any of the medullary pressures At the normal range of $PaCO_2$ the mean medullary metaphyseal pressure was significantly lower than both the mean epiphyseal medullary pressure and the mean diaphyseal m pressure At the ranges of Pa <35 mmHg and >45 mmHg no d between the medullary pressu demonstrated

The medullary pressures ob different values of arterial pH are Table 3 and Figure 3 At the normal arterial pH (7 36–7 46) the mean m pressures found were epiphys 27 5 mmHg, metaphyseal = 20 8 mm diaphyseal = 27 2 mmHg Metabolic not even severe (pH 7 26), caused no ch mean epiphyseal, metaphyseal or d medullary pressures At the range o 7 26–7 35 the mean metaphyseal m pressure (20 8 mmHg) was lower t mean medullary pressures in the ep region (27 6 mmHg) and in the di region (27 2 mmHg) No differenc observed between the mean m pressures at the ranges of pH below 7 36–7 46

The control medullary pressures the three sections of the study were

DISCUSSION

In this study we have shown a low epiphyseal, metaphyseal and d

Table 2 Long bone medullary pressu dogs in relation to different ranges of mean of $PaCO_2$ and mean values ± ranges have been calculated The control medullary pressures are the mean medullary p the normal range of $PaCO_2$ (35–45 mmHg)

Number of observations	Arterial carbon dioxide tension ($PaCO_2$) (mmHg) Range	Mean ± s e mean within the range	Medullary pressures (P) (mmHg) $P_{epiphysis}$ Mean ± s.e mean	$P_{metaphysis}$ Mean ± s e mean	P_{dia} Mean
22	<35	28 5 ± 0 8	26 6 ± 3 3	20 5 ± 1 9	24 2
15	35–45 (normal range)	38 7 ± 1 0	30 5 ± 3 4 (control medullary pressures)	19 5 ± 1 5*	30 1
11	>45	61 5 ± 3 6	30 1 ± 4 8	20 6 ± 2 3	28 4

Within the normal range of $PaCO_2$ * $P < 0 05$ indicates that the mean metaphyseal medullary is significantly different from the mean epiphyseal medullary pressure and the mean d medullary pressure

lary pressures, when PaO_2 decreased 75 mmHg, whereas neither hyperoxia, apnia hypercapnia nor metabolic as seemed to have any influence on lary pressures in the long bones in the thetized dog

: problems connected with the measure- of long bone medullary pressures by a of intramedullary metal cannulas have discussed in several studies (Stein et al Herzig & Root 1959, Azuma 1964) The llary pressures measured in this way late qualitatively well with the rodynamic changes in the bone marrow ll in medullary pressure indicates a rase in bone marrow blood flow and a n due to either an increased blood flow an intraosseous congestion of blood ma 1964, Shim 1968)

ypoxia is the most powerful stimulus of pathetic activity, and with increased pathetic activity circulatory priorities are blished by vasoconstriction in tissues no immediate importance, permitting eased circulation in vital organs (Folkow l 1961) The bone marrow does not seem e among the vital organs intravenous in- sions of adrenaline or noradrenaline or a xt stimulation of the cut peripheral end of abdominal sympathetic trunk resulted in reases in medullary pressures (Herzig & Root 1959) Furthermore, Drinker & Drinker (1916) have shown that the arterioles of the bone marrow are supplied with sympathetic nerve fibres with a vasoconstrictor function The results obtained in this study where a decrease in PaO_2 (<75 mmHg) was followed by a decrease in long bone medullary pressures correlate well with the above-mentioned studies

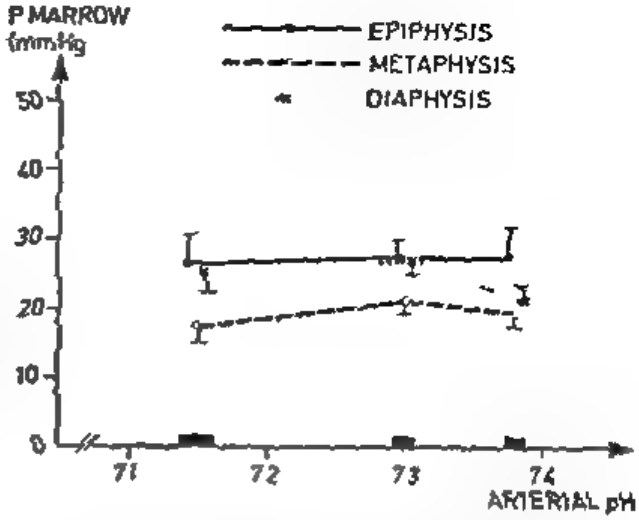

Figure 3 Long bone epiphyseal, metaphyseal and diaphyseal medullary pressures (P_{marrow}) in relation to the arterial pH Mean values ±1 s e mean of the medullary pressures obtained within different ranges of arterial pH (<7 26, 7 26–7.35, 7 36–7 46) are shown in relation to the mean arterial pH within these ranges The horizontal bars on the abscissa indicate the mean values ±1 s e mean of arterial pH within the above mentioned ranges of arterial pH

ble 3 Long bone medullary pressures ($P_{epiphysis}$, $P_{metaphysis}$ and $P_{diaphysis}$) in seven anaesthetized t in relation to different ranges of arterial pH Mean values ± s e mean of arterial pH and mean hues ± s e mean of the corresponding medullary pressures within the ranges have been calculated t control medullary pressures are the mean medullary pressures within the normal range of arterial pH (7 36–7 46)

of ons	Arterial pH		Medullary pressures (P) (mmHg)		
	Range	Mean ± s.e mean within the range	$P_{epiphysis}$ Mean ± s.e mean	$P_{metaphysis}$ Mean ± s.e mean	$P_{diaphysis}$ Mean ± s.e. mean
	<7 26	7 15 ± 0 020	26 4 ± 4 2	16 8 ± 1 8	25 4 ± 3 2
	7 26–7.35	7 30 ± 0 003	27 6 ± 2.4	20 8 ± 1 5*	27 2 ± 2.0
	7 36–7 46 (normal range)	7.38 ± 0 006	27 5 ± 4 1 (control medullary pressures)	19 5 ± 2.0	21 5 ± 2.0

the range of arterial pH of 7 26–7 35 * $P < 0.05$ indicates that the mean metaphyseal medullary is significantly different from the mean epiphyseal medullary pressure and the mean diaphyseal f Pressure

High arterial oxygen tensions cause a small increase in peripheral resistance and a slight decrease in cardiac output (Cotes et al 1963) both apparently not sufficient to produce any changes in medullary pressures

The systemic responses to hypercapnia contain elements of local depression and general autonomic stimulation The circulatory stimulation of central origin consists of increased sympathetic activity and of increased sympathetic activity and of increased plasma levels of adrenaline and mentioned above a decreased medullary blood flow therefore would be expected to be followed by a decrease in medullary pressures Other investigators (Cumming 1962 and Shim & Patterson 1967) have found an increased medullary blood flow during hypercapnia This might perhaps be due to a specific effect of carbon dioxide, which is known to produce peripheral vasodilatation (Cullen et al 1969) That no medullary pressure variations were demonstrated in this study might be due to different $PaCO_2$ increments or different species

An influence of hypocapnia on medullary pressures has not been described and no such influence was seen in this study

Post & Shoemaker (1962) found an increase in blood outflow from the upper and lower venous efflux systems of the femur in the unanaesthetized dog after infusion of small doses of hydrochloric acid A metabolic acidosis did not produce any medullary pressure changes in this study, even if a decreased pressure had been expected because of the severe effects acidosis has on the haemodynamics The "spontaneous" acidosis seen in our dogs might be explained as a dilutional acidosis, caused by the intravenous treatment with saline, which will dilute the plasma bicarbonate

The conditions during metabolic alkalosis were not investigated

In spite of an adequate arterial blood pressure (MAP > 80 mmHg) (Tøndevold et al 1979) severe circulatory disorders seem to occur in the bone marrow during a decreased PaO_2 (<75 mmHg) with significant decreases in medullary pressures in [illegible] metaphyseal and diaphyseal regions

The orthopaedic patient is often [illegible] arterial hypoxia brought about by [illegible] positioning (horizontal, Trendelenburg) [illegible] age (often elderly patients) the presence [illegible] pneumonia, sequelae of anaesthetics [illegible] embolism etc

The results of our study may perhaps suggest a solution to some [illegible] aetiological problems in the orthopaedic [illegible] At the same time, however, they emphasize the importance of maintaining adequate arterial oxygen tensions in [illegible] patients by oxygen therapy, early mobilization, chest physiotherapy, treatment of [illegible] fections etc

ACKNOWLEDGEMENTS

The authors are grateful to L Mohr B Stø[illegible] B Holm and M Kjaerumgaard for their assistance

REFERENCES

Azuma, H (1964) Intraosseous pressure a[illegible] measure of hemodynamic changes in b[illegible] marrow *Angiology* 15, 396–406.

Cotes, J E, Pisa, Z & Thomas, A J (1[illegible] Effect of breathing oxygen on cardiac out[illegible] heart rate, ventilation, systemic and pulmo[illegible] blood pressure in patients with chronic [illegible] disease *Clin Sci* 25, 305–321

Cullen D J, Eger, E I & Gregory G A (1[illegible] The cardiovascular effects of carbon dioxide [illegible] man conscious and during cyclopro[illegible] anesthesia *Anesthesiology* 31, 407–413

Cumming, J D (1962) A study of blood [illegible] through bone marrow by a method of re[illegible] effluent collection *J Physiol* 162, 13–20

Drinker, C K & Drinker, K R (1916) A me[illegible] for maintaining an artificial circulation th[illegible] the tibia of the dog with a demonstra[illegible] the vasomotor control of the marrow ve[illegible] *Amer J Physiol* 40 514–521

Eriksen J, Tøndevold, E, Jansen, E [illegible] Pedersen J E (1979) Relationship bet[illegible] oxygen and carbon dioxide tensions and [illegible]

e balance in arterial blood and in medullary od from long bones in dogs *Acta orthop* nd. 50, 519–525

B Johansson, B & Löfving B (1961) pects of functional differentiation of the mpatho-adrenergic control of the cardio-scular system. *Med Exp* 4, 321–328

ingsen, B (1968) Continuous measurement PO_2 PCO_2 and pH in blood *Scand J clin b Invest* 22, 33–36

g E. & Root, W S C (1959) Relation of mpathetic nervous system to blood pressure bone marrow *Amer J Physiol* 196, 053–1056

, S W & Kelly, P J (1965) The effects of nous stasis on intraosseous pressure and ng tudinal bone growth in the dog *J Bone Surg* 47 A, 539–544

M. & Shoemaker, W C (1962) Bone ectrolyte response to intravenous acid leads *urg Gynec Obstet* 115, 749–756

zer P H, Egbert, L D, Linde, H W, ooper D Y, Dripps R D & Price, H L 1960) Effect of CO_2-inhalation on arterial pressure, ECG and plasma catecholamines and 17-OH corticosteroids in normal man *J appl Physiol* 15, 454–458

Shaw, N E (1963) Observations on the intramedullary blood flow and marrow-pressure in bone *Clin Sci* 24, 311–318

Shim, S S & Patterson, F P (1967) A direct method of qualitative study of bone blood circulation *Surg Gynec Obstet* 125, 261–268

[illegible] C (1957) Variations in normal bone-marrow pressure *J Bone Jt Surg* 39-A, 1129–1134

Tøndevold E, Eriksen, J & Jansen, E (1979) Observations on long bone medullary pressure in relation to mean arterial blood pressure in the anesthetized dog *Acta orthop scand* 50, 527–531

Weinman, D T, Kelly P J, Owen, C A. Jr & Orvis, A L. (1963) Skeletal clearance of Ca^{47} and Sr^{85} and skeletal blood flow in dogs *Proc Mayo Clin* 38 559–570

dence to Erik Tøndevold, M D, Department of Orthopaedic Surgery T-2, Gentofte Hospital, 2900 Hellerup Denmark

thop scand 50, 653–661, 1979

IOMECHANICAL COMPARISON OF THE EFFECTS OF NSTANT AND CYCLIC COMPRESSION ON FRACTURE ALING IN RABBIT LONG BONES*

OHAR M PANJABI,[1]
LSTUS A WHITE III[2] & JOHN W. WOLF JR [3]

meering Laboratory for Musculoskeletal Diseases, Section of Orthopaedic Surgery, Yale University l of Medicine, New Haven, Connecticut, [2]Department of Orthopaedic Surgery, Harvard Medical ol, Boston, Massachusetts, and [3]Division of Orthopaedic Surgery, University of North Carolina ol of Medicine, Chapel Hill, North Carolina, USA

sacrificed at 3, 4, 5, 6, and 8 weeks after the operation The healing bones were tested in a dynamic torsion testing machine Results indicate that on an average basis the cyclic compression treated bones exhibited higher torque and energy absorption to failure, but lower stiffness as compared with the constant compression treated bones, during the 30 to 50 days' healing period These differences were statistically significant Additionally, it was estimated that a 27 per cent saving in healing time may be realized for a bone treated with cyclic as compared with constant compression

Key words biomechanics, constant compression, cyclic compression, fracture healing, torsion test

Accepted 16 v 79

veral different methods may be utilized for treatment of any given long bone fracture e *most* efficient treatment method remains be discovered (White 1975) There have en several experimental studies designed to aluate the effects of different mechanical vironments on intact bones as well as ing fractures. In some the end point was histological evaluation (Hutzchenreuter et 1969, Rahn et al 1971, Harris et al 1977), e in others it was the mechanical strength determined the outcome (Olerud & Danckwardt-Lillestrom 1960, Falkenburg 1961, Lettin 1965, 1968, Tonino et al 1976, Woo et al 1976, Panjabi et al 1977, and White et al 1977a) Previous investigations in this laboratory did not show any significant differences in the response of healing long bone fractures to constant compression versus intermittent cyclic compression as measured by mechanical torsional strength (White et al 1977a) The goal of this study is to compare *more* widely disparate mechanical environments in a rigorously controlled experiment to evaluate the response of healing long bone fractures to large constant compression and rigidity versus cyclic compression and motion

ork supported in part by the Crippled s Aid Society, New Haven, CT

647 0/79 060653–09$02.50/0

© 1979 Munksgaard, C

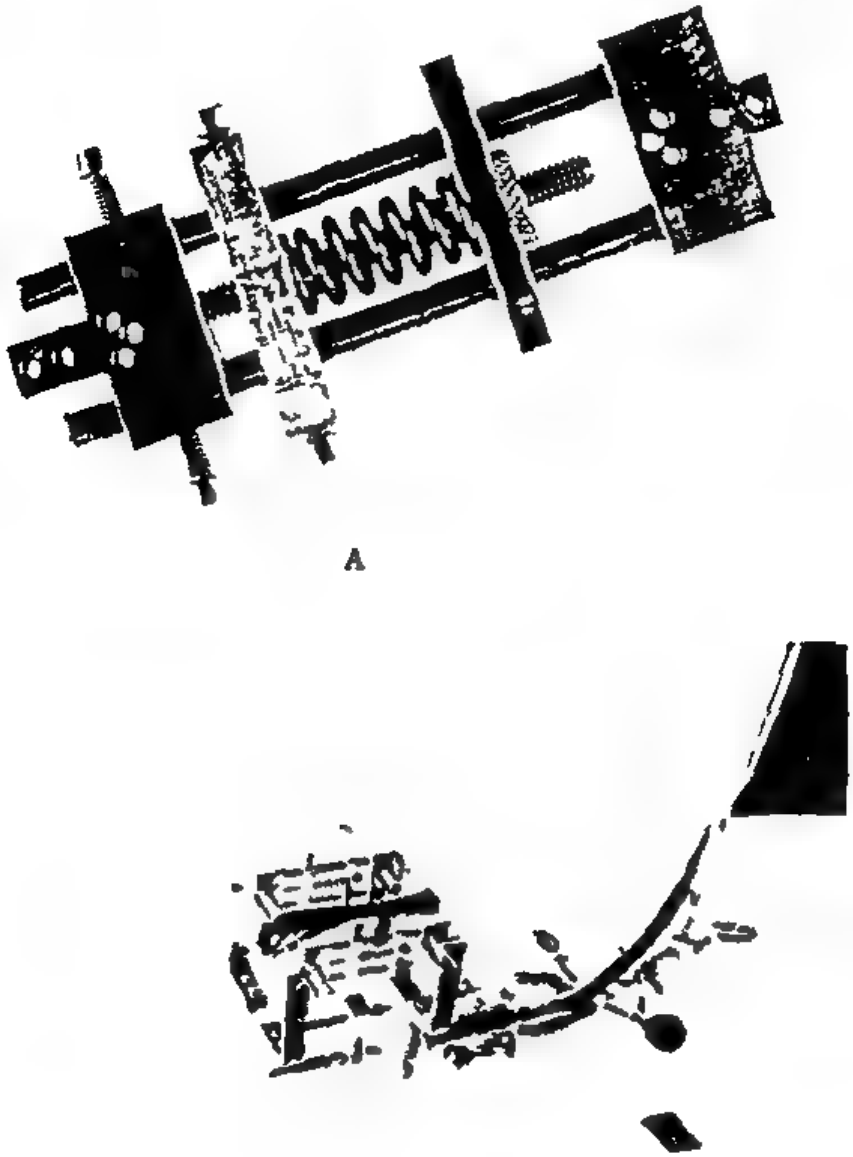

A

B

ure 2 Apparatus for producing the two mechanical environments (A) Constant compres n clamp (B) Cyclic compression system

ositioned 3–5 mm (about 0 2 inch) from the ansverse p ns, and placed so that they penetrated e anterior and posterior tibial cortices but did it through the skin posteriorly

A longitud nal skin incision was then made on anteromedial border of the tibia exposing the muscle mass. The muscle was retracted exposing the shaft of the tibia The was sharply incised in line with the incision and elevated circumferentially A standardized osteotomy (the experimental fracture) was then made midway between the two closest transverse Kurschner wires using a small reciprocating sagittal saw The fracture was reduced and compression was applied by releasing the springs in the two compression clamps. The wound was irrigated and the skin was closed using a running suture of 6–0 Dexon.

The anterior threaded Steinmann pins were next secured in a custom designed sandwich

clamp at a point 5 cm (2 inch) from the anterior surface of the leg The purpose of this clamp on the two anteriorly projecting pins was to control bowing at the osteotomy site in the sagittal plane An identical procedure was performed on both legs The only difference between each leg was the setting of the force in the compression clamps

The foot and the leg were then wrapped in a two inch elastic bandage to minimize subsequent dependent edema Two orthogonal postoperative X-rays were taken to document the position of the osteotomized bones The rabbit was then transferred to a small canvas stretcher that supported the animal on its abdomen, chest and forelegs

Mechanical environment

The rabbits were maintained in specially constructed booths The osteotomized hind legs were unsupported and were attached to an H-shaped aluminum splint to control lateral motion In this way all uncontrolled, extraneous forces on the fracture were kept to a minimum Food and water were available at all times immediately in front of the animals for demand feeding The spring compression clamps were set to provide 80 newtons (18 lb_f) of force on one leg and 8 newtons (1 8 lb_f) on the opposite leg The forces were monitored daily and adjusted as needed to maintain the constant settings. At 1 week following osteotomy, a pneumatic cyclic loading apparatus was attached to the leg with the compression clamp that had been set to deliver the lower constant compression force of 8 newtons The side to receive the cyclic loading was alternated at random The pneumatic system air pressure was adjusted to apply a maximum force of 40 newtons (9 lb_f) The forces are graphically depicted in Figure 3 The cyclic compression load was applied for 3 hours each morning and 3 hours each afternoon Weekly weighings and X-rays were obtained Also shown in Figure 3, for the purpose of comparison are the mechanical environments used in a previous study (White et al 1977a)

Specimen preparation and testing

The rabbits were sacrificed at 3, 4 5 6 and 8 weeks after surgery Each hind limb was disarticulated at the knee joint wrapped in plastic, labeled, and placed in a freezer at −80 degrees centigrade At the time of testing the specimen was removed from the freezer and allowed to thaw The soft tissue at each end of the specimen was then carefully removed using sharp dissection The soft tissue over the healing fracture was not removed It prevented the bone specimen from

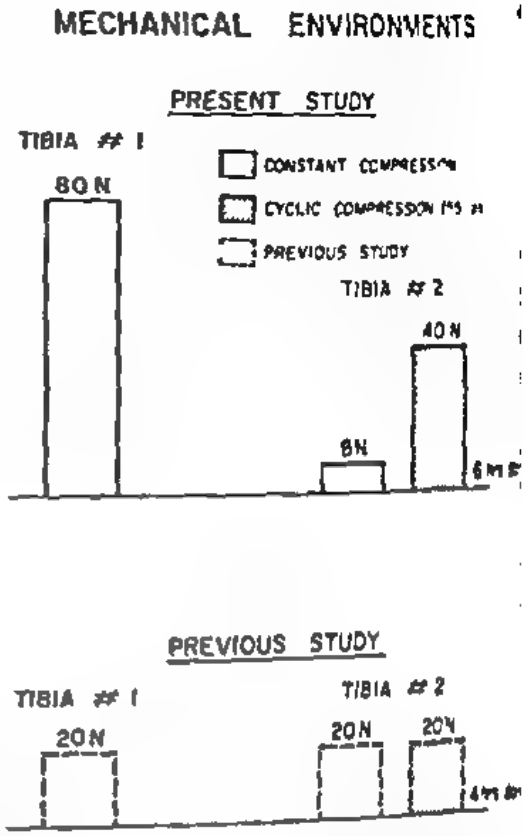

Figure 3 Mechanical environments to which the two tibiae of an experimental animal are subjected Note that in the present study the mechanical environments are more distinct as compared with the previous study

drying out and protected the healing fracture callus The two ends of each specimen were then potted in a quick setting polyester resin in a special mold to provide firm fixation of the specimen in the testing machine AP and lateral X-rays of the prepared specimen were taken

The bone specimen with its ends firmly fixed in the resin was tested in a dynamic torsion testing machine (Burstein & Frankel 1971) In this machine one end of the bone is held rigidly while the other end is suddenly twisted by a falling pendulum The rate of deformation produced was 13 2 radians per second or 750 degrees per second Two transducers continuously measured the torque and torsional deformation of the bone The torsion testing machine was modified in our laboratory to incorporate parallel recording by a mini-computer in addition to the oscilloscope recording Parallel recordings by computer and provided redundancies so that no results were lost due to human error Additionally it made possible to reduce and analyze the data greater in an efficient manner The data was recorded in the form of torque-angle curves Values of the biomechanical parameters were obtained for each

men maximum torque, energy absorbed to e and average stiffness. After testing the specimen was again X rayed

DINGS

ee biomechanical parameters A total of rabbits successfully completed all phases he study The paired design of this experi- nt (a different treatment applied to each *d leg* of the same animal) lends itself to orting the effectiveness of the treatment in form of the differences found in each asured biomechanical parameter The lts are displayed as a set of difference- *phs* in Figures 4, 5 and 6 On the abscissa the healing time in days, while on the *nate* is plotted the parameter difference e the difference between the value of a en parameter obtained for the cyclic *ding* treatment Pc and the value for that rameter for the other hind leg treated with nstant compression P_K. Mathematically $P_C - P_K$. Thus, each single point on the aph represents the *difference* between a pair bones. Using the method of least squares, a *ve* $Y = A + BX + CX^2$ was fitted to the ta. This is the middle curve in the graphs he curves above and below it represent the per cent confidence bands of the mean *ve*

Figure 4 is a graphic representation of the ifference in torque to failure versus healing me As mentioned, each point represents a ir of bones. This graph thus shows that, on e average with 95 per cent certainty, the ylically loaded bones exhibit greater torque failure than the constant compression eated bones between the healing periods of to 52 days. Figure 5 shows a similarly aped curve for the difference in energy sorbed to failure versus healing time in ays. Energy absorbed to failure is probably he best indicator of bone strength It can be een that, considering this parameter, there is n even larger period, 29 to 52 days, within hich the cyclically treated bones had higher alues.

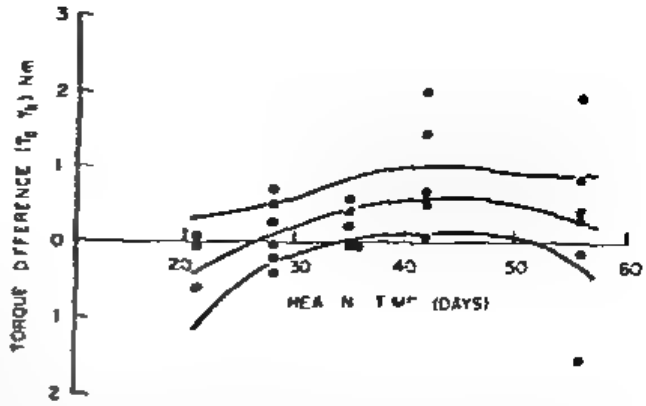

Figure 4 Torque difference ($T_C - T_K$) vs healing time The middle curve, representing the average behavior, was fitted to the raw data with the method of least squares The upper and lower curves are the 95 per cent confidence bounds of the average curve

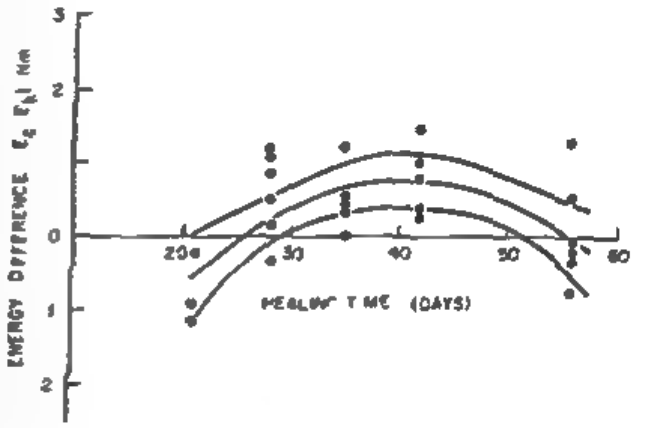

average curve

Stiffness as shown in the graph in Figure 6 exhibits a different pattern In this case it is the constant compression treated bones that have the higher values in the healing period of 27 to 46 days This combination of higher stiffness and less energy absorption before failure indicates that the compression treated bones are more brittle and will break more easily (they also have lower torque values) than their counterparts treated with cyclic compression The data used in the graphs are also numerically analyzed and presented in Table 1 The "mean per cent" columns, for the three biomechanical

clamp at a point 5 cm (2 inch) from the anterior surface of the leg The purpose of this clamp on the two anteriorly projecting pins was to control bowing at the osteotomy site in the sagittal plane An identical procedure was performed on both legs The only difference between each leg was the setting of the force in the compression clamps

The foot and the leg were then wrapped in a two inch elastic bandage to minimize subsequent dependent edema Two orthogonal postoperative X-rays were taken to document the position of the osteotomized bones The rabbit was then transferred to a small canvas stretcher that supported the animal on its abdomen, chest and forelegs

Mechanical environment

The rabbits were maintained in specially constructed booths The osteotomized hind legs were unsupported and were attached to an H-shaped aluminum splint to control lateral motion In this way all uncontrolled, extraneous forces on the fracture were kept to a minimum Food and water were available at all times immediately in front of the animals for demand feeding The spring compression clamps were set to provide 80 newtons (18 lb_f) of force on one leg and 8 newtons (1 8 lb_f) on the opposite leg The forces were monitored daily and adjusted as needed to maintain the constant settings At 1 week following osteotomy, a pneumatic cyclic loading apparatus was attached to the leg with the compression clamp that had been set to deliver the lower constant compression force of 8 newtons The side to receive the cyclic loading was alternated at random The pneumatic system air pressure was adjusted to apply a maximum force of 40 newtons (9 lb_f) The forces are graphically depicted in Figure 3 The cyclic compression load was applied for 3 hours each morning and 3 hours each afternoon Weekly weighings and X-rays were obtained Also shown in Figure 3 for the purpose of comparison, are the mechanical environments used in a previous study (White et al 1977a)

Specimen preparation and testing

The rabbits were sacrificed at 3 4 5, 6 and 8 weeks after surgery Each hind limb was disarticulated at the knee joint wrapped in plastic labeled and placed in a freezer at −20 degrees centigrade At the time of testing the specimen was removed from the freezer and allowed to thaw The soft tissue at each end of the specimen

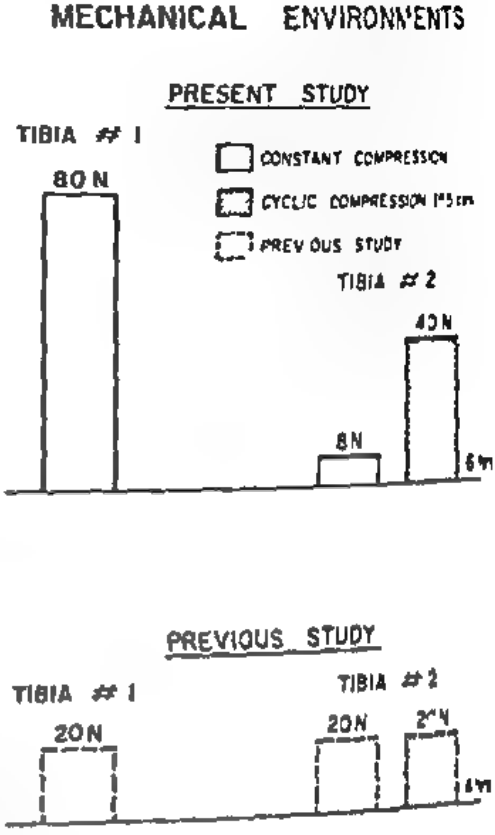

Figure 3 Mechanical environments to which two tibiae of an experimental animal are jected Note that in the present study the environments are more distinct as compared the previous study

drying out and protected the healing fra callus The two ends of each specimen were potted in a quick setting polyester resin special mold to provide firm fixation of specimen in the testing machine AP and la X-rays of the prepared specimen were taken

The bone specimen with its ends firmly fix the resin was tested in a dynamic torsion te machine (Burstein & Frankel 1971) In machine one end of the bone is held rigidly the other end is suddenly twisted by a fa pendulum The rate of deformation produced 13 2 radians per second or 750 degrees per se Two transducers continuously measured torque and torsional deformation of the bone torsion testing machine was modified in laboratory to incorporate parallel recording mini-computer in addition to the oscillo recording Parallel recordings by computer provided redundancies so that no results were due to human error Additionally it was possible to reduce and analyze the data in an efficient manner The data was recorded the form of torque-angle curves Values of biomechanical parameters were obtained for

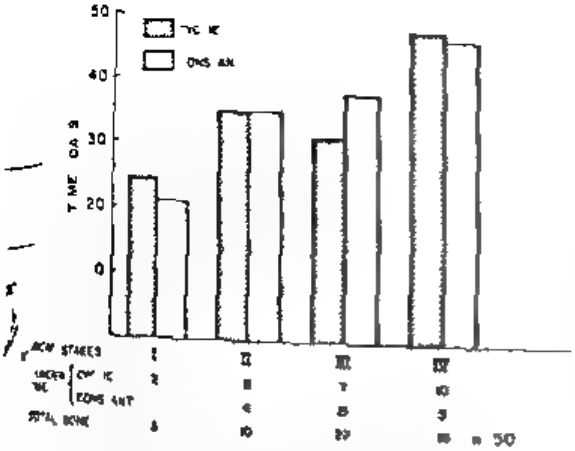

re 8 Time for the healing bones to reach each the four biomechanical stages of healing is rv Time to reach the clinically important ge III of healing is shorter for the cyclical pression treated bones

bone with a flat torque-angle curve that re-ctures at the original site is placed in Stage while bone with a steep torque-angle curve d a re-fracture that does not recognize the iginal fracture site is placed in Stage IV he other two stages have in between aracteristics Further details may be found the original article Using only these teria and without the knowledge of the atment given and the healing periods, ch of the 50 bones were divided into the ur stages.

Results for the amount of time required to ach each of the four stages of healing for se two treatments are seen in Figure 8 ime to reach Stage III is considerably horter for the cyclically treated bones as ompared with that for the bones with onstant compression treatment Another spect of the four biomechanical stages is resented in Figure 9 This is a distribution of the number of bones that reached each of he four biomechanical stages of healing For the sake of comparison, the cyclic and constant compression treated bones are shown separately in Figure 9

DISCUSSION

In our previous study (White et al 1977a) the data showed no significant differences between the biomechanical results of healing

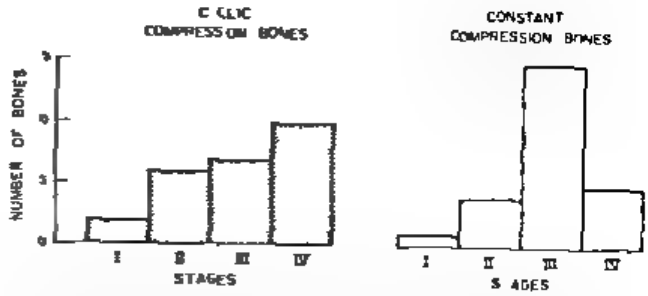

Figure 9 A histogram showing the distribution of the healing bones with respect to the four biomechanical stages of healing for the two treatments Notice a continuous progress for the cyclic compression treated bones from Stage I to IV, while the constant compression bones show some difficulty in going from Stage III to IV

long bones treated by two different mechanical environments The results of the present study convincingly demonstrate the opposite It is seen from Figures 4 and 5 that during the middle phase (about 30 to 50 days) of healing, the strength parameters of maximum torque and energy absorption to failure clearly indicate the superiority of the cyclic over the constant compression treatment This superiority is statistically significant to the 95 per cent confidence level as shown by the 95 per cent upper- and lower-bound curves

In the early and late phases of healing, the two healing environments basically produced similar results (Figures 4 to 6) In fact, the constant compression, especially in the early phase, produced bones that were stronger than their paired counterparts treated with cyclic compression (Figures 4 and 5) This, we believe, is the result of immobilization provided by the large constant compression force During these early phases small blood vessels are developing (Creuss & Dumont 1975) and immobilization protects the delicate vessels and facilitates repair In the late phase, we believe the healing bone has become sufficiently strong to carry the normal physiological loads

Sometimes "Stiffness" is considered a biomechanical parameter synonymous with "Strength", just as torque and energy absorption This is misleading During the middle

phase of healing, the cyclic compression treated bones show higher torque and energy values as compared with the bones with constant compression (Figures 4 and 5) In the same time period, the stiffness parameter shows a completely opposite tendency (Figure 6) We conclude that during this period of healing the cyclic bones are stronger and more flexible while the constant compression bones are weaker and more brittle We hope the planned Histological Studies will shed some light on the above observations

Figure 7 is a composite graph of the values for torque versus healing time for the previous study as well as for the cyclically loaded and constant compression treated bones of the present study The dashed horizontal line represents a torque value of 1 5 newton meters, which is the torque value that correlates with failure no longer taking place at the experimental fracture site The cyclically treated bones reached this clinically important stage of healing at 40 days as compared with more than 56 days for compression treated bones. This is a saving of 27 per cent of required treatment time These findings clearly fit with clinical experience and recent experimental work in rats (Sarmiento et al 1977)

In the previous study although there were differences in the environments of the two legs, these did not show up in the results Thus, we have only one curve for this study in Figure 7 Also shown in this figure is a solid horizontal line representing the strength of the intact rabbit tibia It is interesting to note that at 21 days of healing the constant compression is superior to both the cyclic and the previous study, while at 56 days of healing the cyclic treatment produces bones with superior strength compared with the constant compression treatment and the previous study At this time point, the cyclically treated bones have achieved about 95 per cent of the normal intact strength as compared with 70 per cent for the other two

Grouping the bones into the four biomechanical stages of healing was done to see if the two treatment regimens, manner, differentiate the bones re their biomechanical maturity Fig basically confirms the findings me earlier that the cyclic compression shortens the time taken to reach biomec maturity (Stage III) Another finding is seen in Figure 9 Distributio bones according to the treatment and t stages shows that the constant bones have their peak (15 bones) in Sta while the most cyclic compression bo bones) are grouped in Stage IV There be a continuous progression from Sta Stage IV for the cyclic bones while the c compression treated bones have diffic progressing from Stage III to Stage IV may indicate that the superiority of the c as compared with the constant comp treatment comes into play in the tra from Stage III to IV During this ph bone is probably adapting to the c mechanical environment

What is the type of signal fo adaptation? Cyclic compression seems better than constant compression respect However, the cyclic compr produces intermittent compression fo well as oscillatory motion in the fractu The latter is produced by the cyclic b moment created by the cyclic comp forces that are not precisely aligned respect to the fracture site Because the compression forces are relatively sma believe it is probably the motion fracture site that accelerates adaption.

It has been suggested that the applied at the fracture site to enhance h should be comparable in magnitude wit physiological loads to which the bo subjected during normal activity (Lany al 1977) Lanyon et al. determined physiological load in the rabbit tibia about 200N, i e five times the loads u our study However, as we have been a see the effects of these relatively smaller in our present experiment, the impl cati that larger loads are not a requirement f

asing the efficiency of healing When an nal breaks a leg in the wild and limps, the ls applied to the fracture site during the ling period are generally smaller than the mal physiological loads

n general, our results tend to show that stant compression treatment produces a nger bone during the early phase of ing while the cyclic treatment produces ger union in the middle and later phases ealing This suggests the possibility that a tain combination of the treatments may lt in a type of healing that is superior to er of the two treatments given separately s such combination may be to provide a stant compression treatment in the early se of healing with the intermediate period gned to provide a gradual change from stant to the cyclic treatment. Experiments being designed to explore this possibility

NOWLEDGMENT

e authors are grateful for the help provided by Don Summers and Mr Bennie Mayes with the rperiment and Dr Stephen Walter and Ms Marcia sta with statistical analysis of the data

EFERENCES

rnsten, A H & Frankel, V H (1971) A standard test for laboratory animal bone *J Biomech* 4, 155–158

ruce, R L & Dumont, J (1975) Current concepts, fracture healing *Canad J Surg* 18, 403–413

kenburg J (1961) An experimental study of the rate of fracture healing – assessed from the tensile strength and S^{35} activity of the callus with special reference to the effects of intramedullary nailing *Acta orthop scand*, Suppl 50

rris, W H., Moyen, B, J-L, Lahey, F J & Weinberg E H (1977) Effects of application of metal plates to bone Comparison of rigid with a flexible plate Trans. 23rd Orthop Res. Soc

Tschearreuter, P, Perren, S M., Steinmann, S, Geret, V & Klebl, M (1969) Some effects of rigidity of internal fixation on the healing pattern of osteotomies. *Injury* 1, 78–81

Lanyon, L E, O'Connor, J A & Goodship, A. E (1977) The importance of physiological relevance in biomechanical experiments. A letter to the editor *J Biomech* 10, 611–612

Lettin, A W F (1968) The biological effect of rigid internal fixation on the healing of cortical bones *J Bone Jt Surg* 50-B, 227

Lettin, A W F (1965) The effects of axial compression on the healing of experimental fractures of the rabbit tibia *Proc roy Soc Med* 58, 882

Olerud, S & Danckwardt-Lilliestrom, G (1960) Fracture healing in compression osteosynthesis in the dog *J Bone Jt Surg* 50-B, 844–851

Panjabi, M M, White, A A. III & Southwick, W O (1977) Temporal changes in the physical properties of healing fractures in rabbits. *J Biomech* 10, 689–699

Puhl, J J, Piotrowski, G & Enneking, W F (1972) Biomechanical properties of paired canine fibulas. *J Biomech* 5, 391–397

Rahn, B A, Gallinaro, P, Baltensperger, A & Perren, S M (1971) Primary bone healing (an experimental study in the rabbit) *J Bone Jt Surg* 53-A, 783–786

Sarmiento, A, Schaeffer, J F, Beckerman, L., Latta, L L & Enis, J E (1977) Fracture healing in rat femora as affected by functional weight-bearing *J Bone Jt Surg* 59 A, 369–375

Tonino, A J, Davidson, C L, Klopper, P J & Linclau, L A (1976) Protection from stress in bone and its effects *J Bone Jt Surg* 58 B, 107–113

White, A A III, Panjabi, M M & Hardy, R J (1974) Analysis of mechanical symmetry in rabbit long bones. *Acta orthop scand* 45, 328–336

White, A A (1975) Fracture treatment. The still unsolved problem *Clin Orthop* 106, 279–284

White, A A III, Panjabi, M M & Southwick, W O (1977a) Effects of compression and cyclical loading on fracture healing – A quantitative biomechanical study *J biomech* 10, 233

White, A A III, Panjabi, M M & Southwick, W O (1977b) The four biomechanical stages of fracture repair *J Bone Jt Surg* 59-A, 188–192

Woo, S, L-Y, Akeson, W H, Coutts, R D, Rutherford, L, Doty, D, Jemmott, G F & Amiel, D (1976) A comparison of cortical bone atrophy secondary to fixation with plates with large differences in bending stiffness. *J Bone Jt Surg*, 58 A, 190–195

Correspondence to Manohar M Panjabi, Tek Lic, Dr Tech, Engineering Laboratory for Musculoskeletal Diseases, Section of Orthopaedic Surgery, Yale University School of Medicine, New Haven, Connecticut 06510, U S A

phase of healing, the cyclic compression treated bones show higher torque and energy values as compared with the bones with constant compression (Figures 4 and 5) In the same time period, the stiffness parameter shows a completely opposite tendency (Figure 6) We conclude that during this period of healing the cyclic bones are stronger and more flexible while the constant compression bones are weaker and more brittle We hope the planned Histological Studies will shed some light on the above observations

Figure 7 is a composite graph of the values for torque versus healing time for the previous study as well as for the cyclically loaded and constant compression treated bones of the present study The dashed horizontal line represents a torque value of 1 5 newton meters, which is the torque value that correlates with failure no longer taking place at the experimental fracture site The cyclically treated bones reached this clinically important stage of healing at 40 days as compared with more than 56 days for compression treated bones This is a saving of 27 per cent of required treatment time These findings clearly fit with clinical experience and recent experimental work in rats (Sarmiento et al 1977)

In the previous study although there were differences in the environments of the two legs, these did not show up in the results Thus, we have only one curve for this study in Figure 7 Also shown in this figure is a solid horizontal line representing the strength of the intact rabbit tibia It is interesting to note that at 21 days of healing the constant compression is superior to both the cyclic and the previous study, while at 56 days of healing the cyclic treatment produces bones with superior strength compared with the constant compression treatment and the previous study At this time point, the cyclically treated bones have achieved about 95 per cent of the normal intact strength as compared with 70 per cent for the other two

Grouping the bones into the four biomechanical stages of healing was done to see if the two treatment regimens in manner, differentiate the bones regar their biomechanical maturity Figu basically confirms the findings earlier that the cyclic compression shortens the time taken to reach biomecha maturity (Stage III) Another in ere finding is seen in Figure 9 Distribution o bones according to the treatment and stages shows that the constant bones have their peak (15 bones) in Stag while the most cyclic compression bone bones) are grouped in Stage IV There see be a continuous progression from Stage Stage IV for the cyclic bones whil compression treated bones have difficul progressing from Stage III to Stage IV may indicate that the superiority of the cy as compared with the constant compre treatment comes into play in the trans from Stage III to IV During this phase bone is probably adapting to the ne mechanical environment

What is the type of signal for adaptation? Cyclic compression seems b better than constant compression in respect However the cyclic compre produces intermittent compression forc well as oscillatory motion in the fracture The latter is produced by the cyclic bend moment created by the cyclic compres forces that are not precisely aligned respect to the fracture site Because the c compression forces are relatively small believe it is probably the motion at fracture site that accelerates adaption.

It has been suggested that the k applied at the fracture site to enhance bon should be comparable in magnitude with physiological loads to which the bone subjected during normal activity (Lanyo al 1977) Lanyon et al determined physiological load in the rabbit tibia to about 200N, i e five times the loads use our study However, as we have been able see the effects of these relatively smaller lo in our present experiment the implication that larger loads are not a requirement for

ing the efficiency of healing When an al breaks a leg in the wild and limps, the s applied to the fracture site during the ing period are generally smaller than the physiological loads

general, our results tend to show that tant compression treatment produces a nger bone during the early phase of ing while the cyclic treatment produces nger union in the middle and later phases ealing This suggests the possibility that a um combination of the treatments may lt in a type of healing that is superior to er of the two treatments given separately such combination may be to provide a stant compression treatment in the early se of healing with the intermediate period gned to provide a gradual change from stant to the cyclic treatment Experiments being designed to explore this possibility

KNOWLEDGMENT

e authors are grateful for the help provided by Don Summers and Mr Bennie Mayes with the periment and Dr Stephen Walter and Ms. Marcia ts with statistical analysis of the data

FERENCES

rstein, A. H & Frankel, V H (1971) A standard test for laboratory animal bone *J Biomech* 4, 155–158

reuss, R L. & Dumont, J (1975) Current concepts, fracture healing *Canad J Surg* 18, 403–413

kerburg J (1961) An experimental study of the rate of fracture healing – assessed from the tensile strength and S^{35} activity of the callus with special reference to the effects of in tramedullary nailing *Acta orthop scand* Suppl 50

arris, W H, Moyen, B J L Lahey P J & Weinberg E H (1977) Effects of application of metal plates to bone Comparison of rigid with a flexible plate Trans. 23rd Orthop Res. Soc.

atzchenreuter, P, Perren S M, Steinmann S, Geret, V & Klebl, M (1969) Some effects of ng d ty of internal fixation on the healing pattern of osteotomies. *Injury* 1, 78–81

Lanyon, L E, O'Connor, J A & Goodship A E (1977) The importance of physiological relevance in biomechanical experiments A letter to the editor *J Biomech* 10, 611–612

Lettin, A W F (1968) The biological effect of rigid internal fixation on the healing of cortical bones. *J Bone Jt Surg* 50-B, 227

Lettin A W F (1965) The effects of axial compression on the healing of experimental fractures of the rabbit tibia *Proc roy Soc Med* 58, 882

Olerud S & Danckwardt Lilliestrom G (1960) Fracture healing in compression osteosynthesis in the dog *J Bone Jt Surg* 50 B, 844–851

Panjabi, M M, White, A A III & Southwick, W O (1977) Temporal changes in the physical properties of healing fractures in rabbits. *J Biomech* 10, 689–699

Puhl, J J, Piotrowski G & Enneking W F (1972) Biomechanical properties of paired canine fibulas *J Biomech* 5, 391–397

Rahn, B A, Gallinaro P, Baltensperger, A & Perren, S M (1971) Primary bone healing (an experimental study in the rabbit) *J Bone Jt Surg* 53 A, 783–786

Sarmiento, A Schaeffer, J F, Beckerman, L, Latta, L L & Enis, J E. (1977) Fracture healing in rat femora as affected by functional weight bearing *J Bone Jt Surg* 59 A, 369–375

Tonino, A J, Davidson C L, Klopper, P J & Linclau L A (1976) Protection from stress in bone and its effects *J Bone Jt Surg* 58 B, 107–113

White A A III, Panjabi, M M & Hardy, R J (1974) Analysis of mechanical symmetry in rabbit long bones. *Acta orthop scand* 45, 328–336

White, A. A (1975) Fracture treatment The still unsolved problem *Clin Orthop* 106, 279–284

[illegible] *Jt Surg* 59-A 188–192

Woo S, L-Y Akeson W H, Coutts, R D, Rutherford L, Doty, D, Jemmott, G F & Amiel D (1976) A comparison of cortical bone atrophy secondary to fixation with plates with large d fferences in bending stiffness. *J Bone Jt Surg* 58 A, 190–195

Correspondence to Manohar M Panjabi Tek. Lic Dr Tech., Engineering Laboratory for Musculoskeletal Diseases Section of Orthopaedic Surgery Yale University School of Medicine, New Haven, Connecticut 06510 U S A

Figure 1 Radiography showing a fracture of the scaphoid bone of the wrist

the first examination, four on the 10th day and two on the 20th day Three scintigraphic pictures in the group with fractures dis-

covered on the first day could n evaluated due to the newly fitted plas the remaining 13 cases the radiograph scintigraphic findings corresponded (Figures 1 & 2) Positive scintigraphic u was also seen in the group with fra diagnosed on the 10th and 20th days wa exception of a 13-year-old child in wh increased activity was due to u epiphyseal lines. Increased focal activit seen in ten patients and was caused by fractures not located in the scaphoid bone

Eighteen patients had no fractures at a ten patients, a normal scintigraphy was while the picture in one patient could no evaluated because of a wet plaster Incre activity in the region of the wrist was see seven patients In three cases, no explan for this could be found Of the four rema patients, one was the child with u epiphyseal lines, one patient had a cyst in capitate bone and two patients had arth or halisteresis

Figure 2 A scan of the same patient demonstrates increased uptake radially due to the fracture

DISCUSSION

It is important to make a correct and ear diagnosis of a scaphoid fracture in order to prevent later non-union which might necessitate bone grafting or an arthrodesis (Böhler et al 1964, Herness & Posner 1977, Torma & Sandqvist 1974, Eddeland et al. 1975).

Our material shows that scintigraphy with ^{99m}Tc is a valuable supplementary examination in the diagnosis of fractures of the scaphoid bone This examination is of particular help in those cases in which the fracture does not become radiologically apparent until a week or more has passed If the uptake is normal, fracture can be excluded With a diffuse or focally increased uptake radiological examination can be used to ascertain the presence of a fracture in the scaphoid bone or in the surrounding areas or other bone diseases

Scintigraphy is of lesser value in older patients with arthrosis or halisteresis and in

ren with unfused epiphyseal lines hermore, scintigraphy should be per- ed before a plaster is applied

EREN CES

er L, Torjan, E & Jahna, H (1954) ehandlungsergebnisse von 734 frischen nfachen Bruchen des Kahnbeinkörpers der land *Wiederherstellungschir u Traum* 2, 6–111

eland A, Eiken, O, Hellgren, E & Ohlsson, M (1975) Fractures of the scaphoid *Scand plast reconstr Surg* 9, 234–239

Herness, D & Posner, M A (1977) Some aspects of bone grafting for non union of the carpal navicular *Acta orthop scand* 48, 373–378

Mazet, R & Hohl, M (1963) Fractures of the carpal navicular *J Bone Jt Surg* 45-A, 82–112

Pendergrass, H P, Potsaid, M S & Castronovo F P (1973) The clinical use of ^{99m}Tc-diphosphonate *Radiology* 107, 557–562

Russe, O (1960) Fracture of the carpal navicular *J Bone Jt Surg* 42-A, 759–768

Torngren, S & Sandqvist, S (1974) Pseudarthrosis in the scaphoid bone treated by grafting with autogenous bone-peg *Acta orthop scand* 45, [illegible]

respondence J-H Andresen, Decembervej 16, 8210 Aarhus V, Denmark

orthop scand. 50 667–669 1979

TEOID OSTEOMA OF THE DISTAL PHALANX ' THE THUMB

RAM LEVY * SHIMON ROSENHECK GREIFF & GABRIEL TOROK

artments of Orthopaedic Surgery and Pathology, Soroka Medical Centre, Faculty of Health nces, Ben Gurion University of the Negev, Beer-Sheba, Israel.

An osteoid osteoma of the distal phalanx of the thumb in a 14-year-old girl is described Apart from the rare site of the lesion other unusual features

Key words epiphysis, osteoma osteoid, thumb

Accepted 5 v 79

steoid osteoma of the distal phalanx is a re lesion Rosborough (1966) described an steoid osteoma of the distal phalanx of the th finger and referred to five cases which d been reported in the literature Although r case is somewhat similar to that reported Rosborough, it appears to be the first ported case of an osteoid osteoma of the stal phalanx of the thumb causing epiphyal growth arrest

ASE REPORT

14-year-old girl was admitted to the orthopaedic epartment of our hospital in January, 1978, com laining of a pain in the thumb of her left hand of 2 ears duration The pain was aggravated at night nd during cold weather and was relieved by spirin. There was no history of trauma On ex amination the distal phalanx of the left thumb was nlarged, bulky, somewhat shortened and tender on palpation (Figure 1) The nailbed was hypertrophied. There was no increase in local skin temperature or swelling and no limitation of movement at the interphalangeal joint Routine blood count and blood biochemistry including serum calcium and phosphorus, were within normal limits.

Radiograph of the left thumb (Figures 2 and 3) revealed a soft tissue swelling at the ventral and medial aspects of the distal phalanx and to a lesser degree both laterally and dorsally An ovoid osteolytic lesion 1 × 0 15 cm was evident at the base and on the dorsal aspect of the distal phalanx extending across the entire width of the phalanx. The lesion had a smooth sclerotic anterior border and an ill-defined posterior border simulating a soft tissue mass eroding the bone from without There was a 4 mm radiolucent nidus with a small fleck of calcium in its centre There was evidence of premature closure of the epiphyseal plate at the base of the phalanx.

Operative findings

The lesion was approached by a lateral incision Beneath the apparently intact cortical bone, a semi soft granular lesion was found and curetted The postoperative course was uneventful, and the pain was permanently relieved

Pathology

Several small particles of bone were obtained from the lesion Histologically (Figure 4) the central portion of the lesion was characterized by a rich network of interlacing bony trabeculae

*Present address Department of Plastic Surgery

ISSN 0 0470 79 060667–03$02.50.0

© 1979 Munksgaard Copenhagen

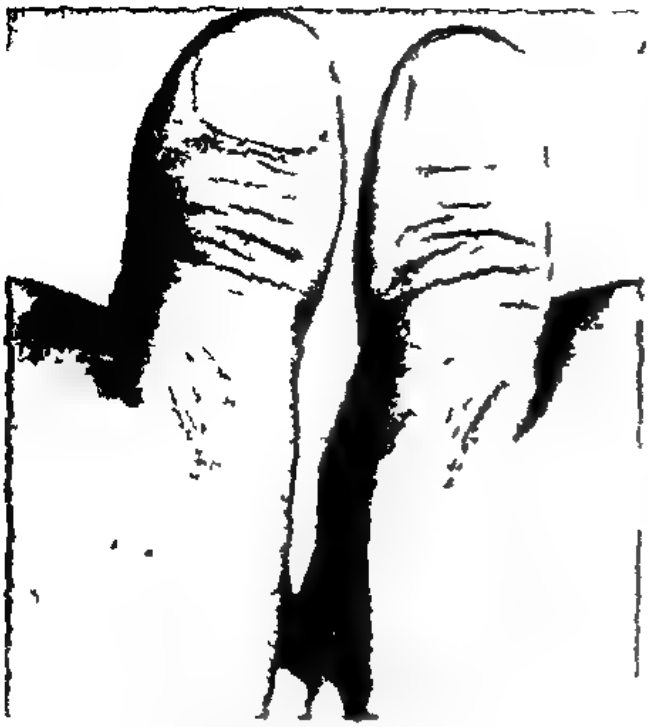

Figure 1 Both thumbs The distal phalanx of the left thumb is swollen and there is hypertrophy of the nailbed

Centrally, the trabeculae were heavily calcified and the peripheral margins consisted of uncalcified osteoid trabeculae of variable thickness, partially bordered by plump oval and spindle-shaped osteoblasts The spaces between the osteoid



Figure 2 Antero-posterior radiographs of the thumbs A small ovoid osteolytic lesion is seen at the base of the distal phalanx of the left thumb with a small fleck of calcium in its centre Note the premature closure of the epiphyseal plate of this phalanx

Figure 3 Lateral radiograph of left thumb The soft tissue swelling on the ventral aspect of the thumb and the faint posterior border of the phalanx gives the appearance of a soft tissue mass eroding the bone from without

Figure 4 Central nidus of the lesion [illegible] cellular fibrous stroma between the [illegible] osteoid trabeculae Multinucleated giant [illegible] prominent capillaries are seen Haematoxylin and eosin × 100

lculae were occupied by cellular and vascular us tissue containing many osteoclasts

e fragments of cortical bone consisted of calcified cortex covered by a cellular steum In some areas there was a small nt of fibrocartilage on the surface which ared to be metaplastic Sections stained for alin revealed the usual lamellar pattern in the ral bone, while the central nidus consisted of en bone

SCUSSION

ce Jaffe (1935) defined osteoid osteoma as entity this benign tumour has been cribed in almost all parts of the skeleton e hand and especially the thumb are rare s (Carrol 1953, Sullivan 1971, Grundberg 7).

The clinical and pathological features of bony lesion in our patient are racteristic of osteoid osteoma, but the ological picture was misleading in that tumour appeared to arise from the soft ues and caused pressure erosion of the e This was the original interpretation of X-ray films The radiolucency of the ntral nidus was recognized only in trospect Tomographic cuts would have en of value in revealing the nidus

An additional finding was the closure of the nphyseal plate In the case described by rundberg (1977) there was no significant deformity of the finger and no early closure of the epiphyseal plate As in our patient, the case described by Rosborough (1966) showed a hypertrophied enlarged finger and nailbed and early closure of the epiphyseal plate Bordelow et al (1975) described an osteoid osteoma of the distal phalanx of the right toe which resulted in premature fusion of the epiphysis.

The hypertrophy of the nailbed seen in our case and in similar cases reported in the literature (Grundburg 1977, Rosborough 1966) can be explained on the basis of the rich vascularity of osteoid osteomas

REFERENCES

Bordelow, R L, Cracco, A, Book, M K. & Rouge, B (1975) Osteoid osteoma producing premature fusion of the epiphysis of the distal phalanx of the big toe *J Bone Jt Surg* 57-A 120

Carrol, R E (1953) Osteoid osteoma of the hand *J Bone Jt Surg* 35 A, 888

Grundberg, A B (1977) Osteoid osteoma of the thumb Report of a case *J Hand Surg* 2, 266

Jaffe, H (1935) Osteoid osteoma *Arch Surg* 31, 709

Rosborough, D (1966) Osteoid osteoma Report of a lesion in the terminal phalanx of a finger *J Bone Jt Surg* 48 B 485

Sullivan, M (1971) Osteoid osteoma of the fingers *Hand* 3, 175

orrespondence to Yoram Levy, M D, Department of Plastic Surgery, Soroka Medical Center, O Box 151, Beer Sheba, Israel

RUM ENZYMES AFTER HIP JOINT SURGERY

ERGLUND* & KURT BERGSTRÖM

rtments of Orthopedic Surgery and Clinical Chemistry,
linska Hospital, Stockholm, Sweden

The effect of hip joint surgery on routine serum enzyme values was studied The increase in creatine kinase was most marked and normal levels were restored again after approximately 1 week. Asparatate aminotransferase

operative values again after only 2–3 days Alkaline phosphatase showed an increase after 1 week whereas S-amylase was essentially normal throughout the 2 weeks studied

Key words hip joint surgery, serum alkaline phosphatase, serum lactate dehydrogenase, serum transaminase

Accepted 3 v 79

eletal muscles are rich in creatine kinase K) asparatate aminotransferase (ASAT) d alanine aminotransferase (ALAT), lactate hydrogenase (LD) and alkaline phosphatase LP) A major enzyme in bone tissue is ALP hereas the erythrocytes contain large mounts of LD Damage to various tissues uses an increase in the serum enzyme lues which may conceal pathological evations due to postoperative complications ch as myocardial infarction and hepatic fections. Thus it was of interest to study e enzyme time-course and levels in patients dergoing hip joint surgery where there is assive tissue damage

ATIENTS AND METHODS

ourteen patients, seven men and seven women, edian age 60 years (range 30–75), who had pidural blockade during hip joint plastic surgery ere investigated preoperatively, immediately fter operation and 1, 2, 3, 7 and 14 days postoperatively as regards the following serum enzymes S-CK, S-ASAT, S-ALAT, S-LD, S-

No per- or postoperative complications were noted

All patients were given antibiotics (Cefalosporin) from the start of the operation, seven patients were sprayed peroperatively and intermittently in the wound whereas seven patients initially received intravenous and after that peroral treatment for 1 week

RESULTS AND DISCUSSION

With the exception of the S-LD values, 2 and 3 days postoperatively, all values from the two groups with different types of antibiotic therapy have been pooled (Figure 1)

S-CK increased from a preoperative value of 1 1 µkat/l (range 0 6–1 5) to a highest mean value of 6 7 µkat/l (range 2 7–12 4) 1 day postoperatively One week after the

Present address Department of Clinical Physiology, Karolinska sjukhuset, S-104 01 Stockholm, Sweden

ISSN 0-0-0 0 79 060671–03$02 50/0

© 1979 Munksgaard Copenhagen

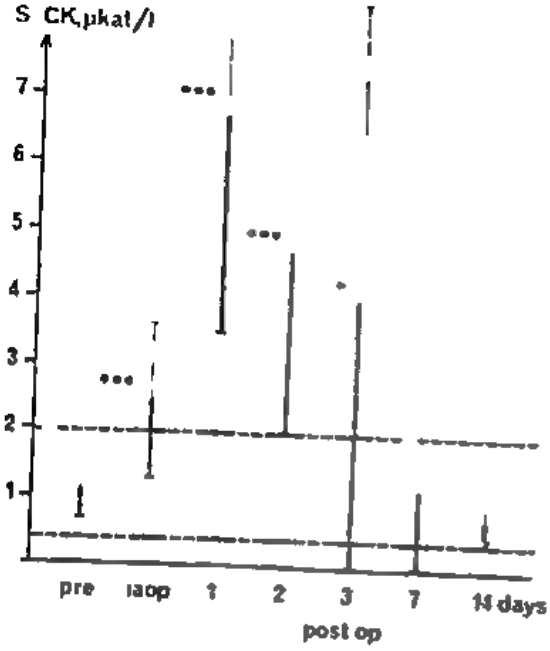

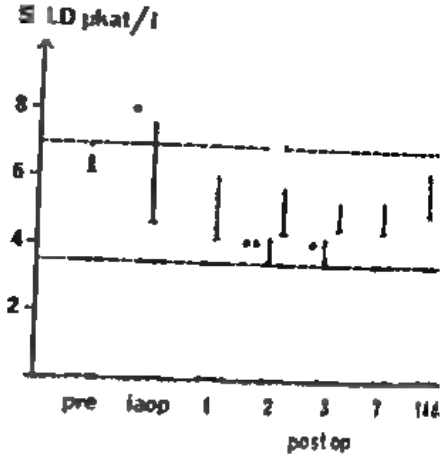

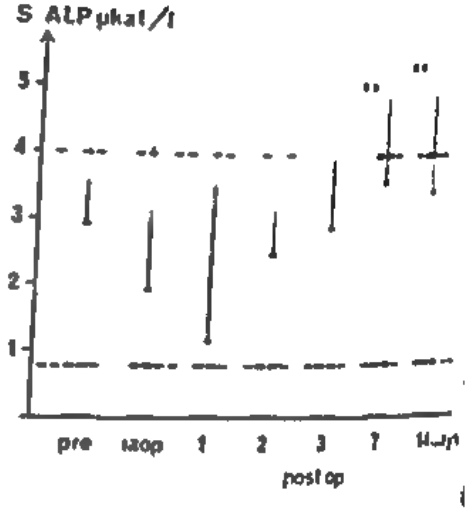

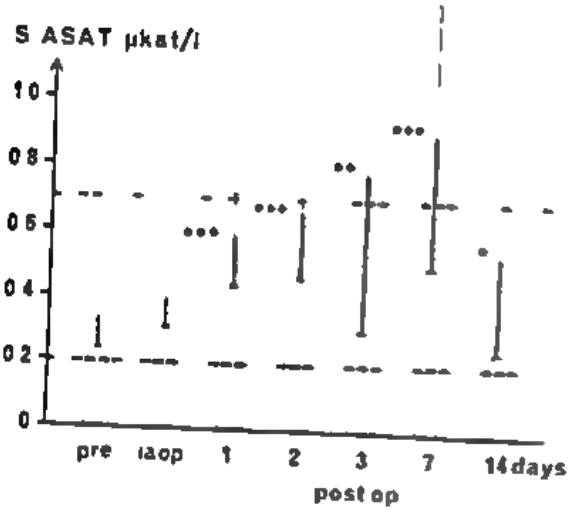

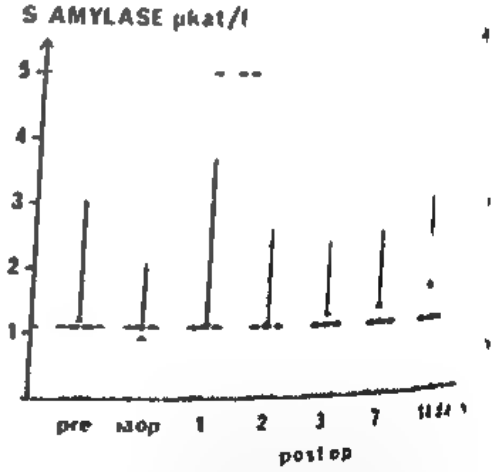

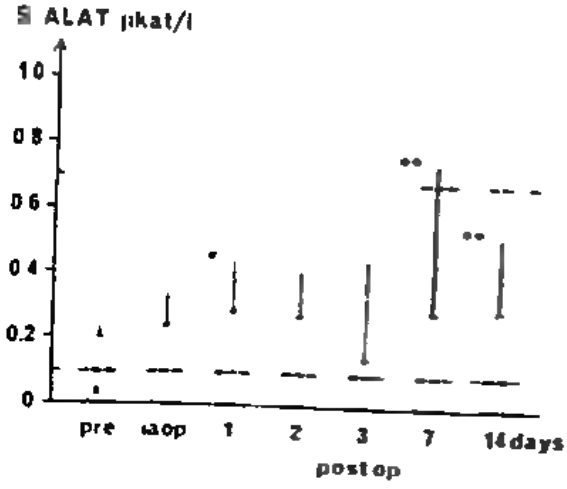

*Figure 1 Serum enzymes (mean ± s.d.) before and after operation Dashed lines denote the reference range of these specified enzymes and *, **, *** mark the significance at comparing with preoperative values at the 5 per cent 1 per cent and 0 1 per cent levels respectively*

pre = preoperative value
iaop = value immediately after operation
post op = postoperative value

ation the mean S-CK value was within reference range.

ASAT increased continuously from 0 33 /l (range 0 20–0 40) preoperatively to µkat/l (range 0 4–1 75) after 1 week weeks after operation the mean S-ASAT e remained higher than before the opera-

ALAT preoperative mean value 0 33 /l (range 0 15–0 62) was fairly constant ng the first 3 postoperative days, the amum mean value 0 75 µkat/l (range 1 7) was noted after 7 days thermore normalization of the S-ALAT m value was not registered after 2 weeks LD increased slightly from a pre-ratuve value of 5 8 µkat/l (range 4 6–7 6) 77 µkat/l (range 3 4–13 0) immediately r operation. Two and three days after ration the patients with peroperative ibotic therapy had lower S LD values n the group of patients with oral antibiotic rapy and the patients' S-LD values were lower than their own preoperative values S-ALP preoperative mean value 3 6 µkat/l nge 2.1–6 1) was almost constant during first three postoperative days After that ALP increased to a mean value of 5 2 t/l (range 2.1–8 8) 14 days post-eratively S-amylase, preoperative mean lue 3 0 µkat/l (range 1 1–6 8) showed significant change during the post-erative period investigated

For further data concerning the enzymes see Figure 1

The postoperative serum enzyme values reflect the contents of enzymes in skeletal muscle (Schmidt & Schmidt 1960) and the contribution from other tissues such as bone and erythrocytes seems less pronounced The increase in the serum enzymes is, however, modest in consideration of the massive skeletal muscle and bone tissue damage, in combination with a varying degree of hemolysis due to hematomas within the wound

REFERENCES

The Committee on Enzymes of the Scandinavian Society for Clinical Chemistry and Clinical Physiology (1978) Revised recommended method for the determination of creatine kinase in blood *Scand. J clin Lab Invest* (In press)

The Committee on Enzymes of the Scandinavian Society for Clinical Chemistry and Clinical Physiology (1974) Recommended methods for the determination of four enzymes in blood *Scand J clin Lab Invest* 33, 291–306

Ceska M Birath K & Brown, H (1969) A new and rapid method for the clinical determination of α amylase activities in human serum and urine *Clin chim Acta* 26, 437–444

Schmidt E & Schmidt F W (1960) Originalien Enzymmuster menschlicher Gewebe *Klin Wschr* 38, 957–962

respondence to Bo Berglund, Department of Clinical Physiology Karolinska Sjukhuset, S-104 01 ckholm, Sweden

Orthop Scand 50, 675–679

PERIMENTAL TESTS CONCERNING THE)MECHANICAL BEHAVIOUR OF RTROCHANTERIC OSTEOSYNTHESES

IARTINEK, E EGKHER, H WIELKE & H SPÄNGLER

nd University Hospital for Accident Surgery and the
tute for Solid State Physics, University of Vienna, Vienna, Austria

The biomechanical behaviour of pertrochanteric fractures stabilized by means of an angled plate or flexible condylar nails was characterized by mechanical testing The stability and the types of motion occurring under dynamic load in the vicinity of the fracture and the effect on the implant were examined The mechanical test results corroborated clinical experiences. In the case of extramedullary anchorage of implants, stability under load is possible only if an intact cortex on the medial side of the fracture guarantees the bearing of compressive load. With flexible condylar nails, however, it is possible to achieve a permanent load capacity up to approximately 100 kp even if medial support is lacking, by putting the fracture in a valgus position so that the load bearing arm is shortened

It was also possible to estimate the actual loading on the operated leg within the immediate postoperative phase by means of the "stabilization effect"

Key words angled nail plate biomechanical investigations, flexible condylar nail, pertrochanteric osteosyntheses

Accepted 10 iii 79

he fate of old people with a pertrochanteric ture of the femur mainly depends on the ssibility of early mobilization of the era ed leg under load Therefore an implant itable for the stabilization of these fractures is to withstand all forces arising under hysiological stress within the area of the acture and to guarantee stability under load ntil osseous healing of the fracture has taken lace. The existence of a great variety of ethods of osteosynthesis for the treatment f pertrochanteric fractures suggests that one of these methods is able to meet all requirements fully

At present the implants generally used in osteosynthesis can be divided into two groups based on fundamentally different principles of load transmission

1 Extramedullary nail and screw models (e g McLaughlin nail Scheuba nail, 130° angle plate), the plates of which are fixed to the exterior side of the femur The forces acting on the hip joint become effective on the metal itself, above all as local bending forces, which the implant alone cannot resist permanently Through an exact reposition of the fracture, and with strong medial support, transmission of load to the bone is possible so that bending or breaking of the nail can be avoided
2 Intramedullary nails (e g Lezius nail, Kuntscher nail, Ender nail) are mainly loaded on their longitudinal axes. Therefore bending forces are not restricted to a small localized area and full advantage can be taken of the intrinsic flexibility and the

ISSN 0-0-0-0-9 060675–05$02.50 0

© 1979 Munksgaard, Copenhagen

statically and dynamically favourable design of the nail

Since 1972 our hospital has been using very successfully the flexible condylar nails, as described by Ender & Simon-Weidner (1970), for the treatment of pertrochanteric fractures in patients past middle age, and in all cases primary load stability was achieved (Passl et al 1975) In an experimental study we have examined the biomechanical qualities of this method of osteosynthesis and compared it with the 130° angled plate of the AO, which mechanically corresponds to be angled nail described by Scheuba (1971), which we had been using before (Martinek et al 1976) Of special interest to us were the forces acting during weight-bearing in the immediate postoperative phase and the resulting deformation of the osteosynthesis.

MATERIALS AND METHODS

Our experiments were carried out on cadaver bones that had been removed 27 hours post-mortem Three experimental groups were compared

Group 1 In six femurs a pertrochanteric fracture running from the tip of the trochanter major to the trochanter minor was artificially produced with the oscillating saw and stabilized in the typical manner with three flexible condylar nails.

Group 2 In six femurs, prepared in the same way as those of group 1, the pertrochanteric fracture was stabilized by means of an angled plate

Group 3 In five patients, who had died within 14 days after the fixation of a fracture by flexible condylar nails, the femurs operated on were removed and compared with those in group 1 This group was of special importance since the standardized experimental fractures of groups 1 and 2 with a smoothly cut surface and the presence of medial support did not fully correspond to fractures occurring *in vivo*

As far as the true load capacity of an osteosynthesis is concerned the results of static measurements seem to be of little value since at cyclic loading as in walking the dynamic interplay of implant and bone determines the true load capacity Therefore the experimental conditions were designed to resemble the physiological conditions under dynamic load as closely as possible For this purpose we use hydraulically operated static-dynamic "closed loop" deformation machine (by Instron, Engl Type 1253) An electronic control enabled load tests which followed a dynamic loading programme, variable at choice simulating sequence of loading occurring in the femur in normal walking The resolution of the pr analyser was 0 05 kp and the resolution of extension measurement 0 001 mm. The reproducibility of the values measured between different specimens (bones) was about +17 cent, the error due to the experimental arrangement was 0 5 per cent

In a specially constructed mounting the distal end of the bone was embedded in bone cement that a punctiform supporting area, with the risk crushing of the cortex layer was avoided head of the femur was held in a ball socket with free rotation of the head permitted deformation the thigh bone In this position we subjected bones to dynamic loading cycles. The load time in our experiments was extended to seconds, corresponding to the careful loading the leg within the immediate postoperative phase (Martinek et al 1976)

By recording the load deformation data during the loading experiments the following could be obtained

1 The bending of the implant per step constant dynamic load amplitude this a measure of irreversible dislocation of proximal part of the femur
2 The number of loading cycles of a certain which causes a lasting shortening of distance femoral head – femoral condyle 10 mm In our opinion an irreversible deformation of the total length of the femur of than 10 mm can be defined as an one since the resulting malposition affecting entire hip joint would lead to considerable vara
3 Information concerning the physical behaviour of the implant (e g relaxation) was obtained keeping the length of the femur constant during the experiments and registering the resulting decrease of load

RESULTS

Group 1

There existed a direct relation between magnitude of the applied force and the extent of the resulting deformation At load under 145 kp the deformation of the osteosynthesis material was almost negligible

ng cycle with a force of 145 kp caused an ersible shortening of the total length of emur of 0 001 mm so that about 10 000 s were tolerated by these osteosyntheses the deformation limit of 10 mm, as it set by definition, was reached An ase of the applied force to 180 kp hed in an irreversible bending of as much 1 mm per step, a value which cannot be ated with a load resisting osteo- hesis. At these load levels the limit of tening of 10 mm was already reached about 100 steps. A load of 210 kp led to destruction of the osteosynthesis which atedly manifested itself in fracture of the al cortex.

he type of motion under load in the ity of the fracture started with a sliding ement of the head fragment along the ace of the osteotomy under slowly in- sing contortion of the flexible condylar s until these nails rested on the medial port. With further loading, the head ment rotated around this point until the ical layer fractured in the area that ported the condylar nails as the breaking (210 kp) was exceeded But even then osteosynthesis had a carrying capacity of

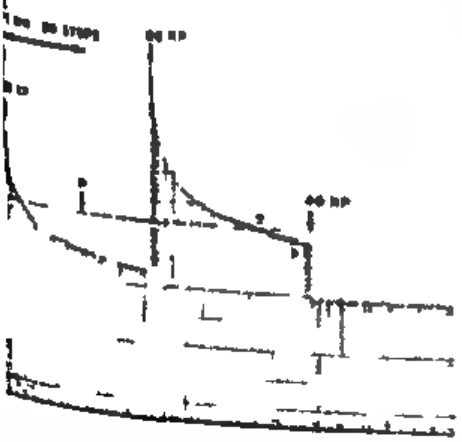

re 1 *Cyclic loading of an osteosynthesis with ant total strain amplitude The load ases with every step due to plastic (i e ersible) deformation After application of a her load e g 80 kp the additional plastic ation proportional to the tangent at any ress load P is much less and is negligible for er loads e g 40 kp 'Hardening has stabil d the osteosynthesis*

50–100 kp, depending on the size of the broken fragment

The stabilizing effect, known in metal physics as "work hardening", was also observed in our experiments It is characterized by a hardening of the implant according to the load applied, so that a further distinct irreversible deformation is to be expected again only under a higher load The effects of this hardening are shown in Figure 1

Group 2

In pertrochanteric fractures fixed by means of an angled plate a lasting shortening of the femur of 0 001 mm occurred already with a single loading of 120 kp An increase of the load to 140 kp resulted in an irreversible deformation of 0 1 mm An intolerable bending of the implant (=a lasting shortening of the total length of the femur of 10 mm) occurred at a load of 165 kp

Under cyclic loading this osteosynthesis showed a type of motion in the vicinity of the fracture completely different from the fractures of group 1, fixed by flexible condylar nails At each loading cycle some rotation of the head fragment round the pivot at the junction blade – plate took place (Figure 2) This results in a strongly localized tensile stress in the metal in this area which may lead to the clinically known fatigue fracture of the implant in this area (A in Figure 2 a), caused by alternating of the deformation load.

Group 3

The qualities of the osteosynthesis based on the laws of metallurgical physics and on the geometry of the implant correspond to the results of group 1 Only at the beginning of the loading at load values of 30 kp, did significant 'consolidation settlement" of 20–40 mm take place This effect was not due to a reduced load capacity, but only after this loading was close contact of the ends of the fractured bone achieved A subsequent loading of 90 kp resulted in a lasting shortening of 0 001 mm and a loading of 110 kp brought about an irreversible deformation of

Figure 2 (a) Angled plate Rotation of the femoral head around axis A The strain is highly localized and sometimes fatigue fracture occurs at this point (b) Condylar nail The strain within the implant is distributed over a considerable length, therefore no localized stress occurs

0 1 mm A load of about 140 kp breakage of the osteosynthesis.

Out of this group, two patients had able to walk well before they died an operated leg had carried weight. As exp the initial shortening at low values lacking in these specimens since "coes tion settlement" of the osteosynthesis already taken place due to the ini loading In these two cases an irreve deformation of the implant could be seen at load values of more than 80 kp. Ta into consideration the stabilizing e described above, we may conclude that extremity had already been loaded up to value before the patient died Intra "consolidation settlement" of the fracture already taken place and an irrever deformation corresponding to a loading 80 kp had developed

In three patients the leg had carried weight before they died Figure 3 show

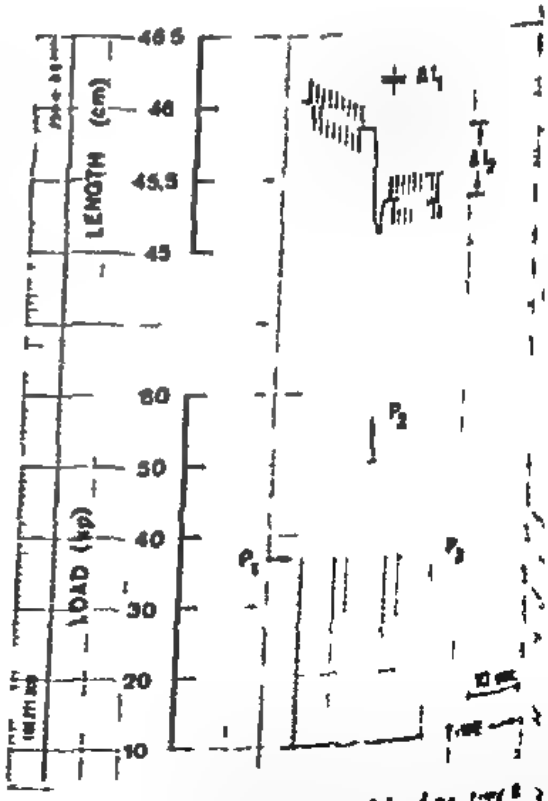

Figure 3 A direct recording of load vs time & strain vs time respectively At P_1, every cycle causes an irreversible shortening Δl_1 of the osteosynthesis Loading up to P_2 brings about a further osteosynthesis At $P_3 = P_1$ ("stabilization effect") further irreversible shortening is observed

:am of this group The lower part nachine-controlled loading cycles :ted to a certain value (P_1) Since nthesis is exposed for the first his load P_1, every step is by an elastic (reversible) as well as a small plastic shortening Δl_1 A single overload ıifted to P_2) causes an irreversible Δl_2, which means that the osteo- :ttles" If we apply the same load ($P_3 = P_1$) no further irreversible occurs The osteosynthesis has :ed by higher load P_2 for any ı e g P_3

)N

ınt and/or the intact or l cortex have to stabilize the carry loads without any essential until osseous healing has taken :dial support exists the load is :d by the bone, the main task of being the fixation of the ends of l bone in an exact position If, ere is no load-carrying medial rse behaviour of both varieties of vident

the angled plate is concerned the ion of the motion shifts from the ɔace to the section between the ıte so that not only the lever arm bly lengthened but due to the tensile stresses a considerable ırreversible) deformation also ıe cyclic loading of the metal in stressed area is the reason for :ture of the implant which ccurs.

f the intramedullary position of :ondylar nails the axis of rotation far outward as in the case of late even if the medial support is result a better biomechanical ɜeen the length of the implant and the length of the lever arm By putting the fracture in a valgus position the load-carrying lever arm can be further shortened so that this relation is improved Localized strain is not expected with this kind of implant since the deformation under load is distributed over a considerable length (Figure 2b) Therefore fatigue fracture cannot appear

As the loading of an extremity in the postoperative phase is of the order of 60 kp, the angled plate and flexible condylar nails are both stable osteosyntheses, provided that there is medial support If medial support is lacking, stable osteosynthesis can be ensured by putting the fracture in a valgus position by means of flexible condylar nails even if osseous contact in the area of the medial cortex is not recreated Consequently the intentional neglect of exact osseous reconstruction in favour of technically simple surgery which can be quickly performed is justified in the treatment of pertrochanteric fractures.

REFERENCES

Ender, J & Simon Weidner, H (1970) Die Fixierung der trochanteren Bruche mit runden elastischen Condylennageln *Acta chir austr* 2, 40–42

Martinek H Wielke, B Egkher, H Fasol P, [illegible]

Ma [illegible] mit Federnagel versorgter pertrochanterer Oberschenkelbruche unter Belastung *Arch orthop Unfall Chir* 86, 235–241

Passl H Martinek H, Paar O & Spangler H (1975) Ergebnisse der Fixierung pertrochanterer Frakturen mit Condylennagel nach Ender und Simon Weidner *Chirurg* 46, 568–571

Scheuba G (1971) Zur Frage der Belastungsstabilitat bei der Osteosynthese pertrochanterer Oberschenkelfrakturen *Acta chir austr* 3, 12–19

ce to Dr Heinz Martinek II Universitatsklinik für Unfallchirurgie Spitalgasse 23 na Austria

rthop. scand. 50, 681–688

HABILITATION AFTER HIP FRACTURE THE ELDERLY

F CEDER, LEIF EKELUND*, SVEN INEROT, LARS LINDBERG
K ODBERG & CARIN SJOLIN

tment of Orthopaedic Surgery and Department of Diagnostic Radiology*, University Hospital of d, Lund Sweden

Sixty-eight patients with hip fracture, mean age 79 years, from the city of Lund, were studied with special reference to functional and social rehabilitation at follow-up 1 year later As compared with patients coming from institutions for permanent care, patients coming from their own homes had a significantly better prognosis in terms of survival, mobility and ability to cope with activities of daily living (ADL) However, patients returning home needed increased domestic help Patients living with someone returned home sooner than those living alone Although many of the patients who returned home could walk without support or with a walking-stick, more than one half did not go out shopping More active measures, e g early home visits by a rehabilitation team, might give the patients more self-confidence and independence Immediate weight-bearing did not appear to impair healing of the hip fracture or increase the risk of necrosis of the femoral head

Key words ADL, early ambulation, femoral neck fractures, fractures, hip fractures, rehabilitation

Accepted 14 iii 79

he last two decades have witnessed ieworthy changes in the population of tients with hip fractures, i e femoral neck d trochanteric fractures of the femur Both e prevalence and the incidence of hip ctures have increased (Alffram 1964, nsen & Neidhardt 1970, Nilsson & Obrant 973). Also the treatment of hip fractures has anged so that there is now a much greater ephasis on early postoperative mobilization d weight bearing of the affected limb Ceder et al, in press) During the period 951–1970 the average stay in our hospital Bergquist 1974) has dropped from 139 to 32 ys for femoral neck fractures and from 125 o 26 days for trochanteric fractures.

Since 1970 uniform principles of treatment and rehabilitation have been applied in the management of hip fractures at the Department of Orthopaedic Surgery in Lund Early operation, early postoperative mobilization and early weight-bearing of the affected limb is the rule This paper reports a prospective investigation of the rehabilitation and the social situation of patients with hip fracture after institution of an active management programme

PATIENTS AND METHODS

The clinical material consisted of 68 patients (11 men and 57 women), over the age of 50, all residents of the city of Lund (58 509 inhabitants), who had sustained a hip fracture in 1972 and had

-84 0/79 060681–08$02.50

© 1979 Munksgaard, Copenhagen

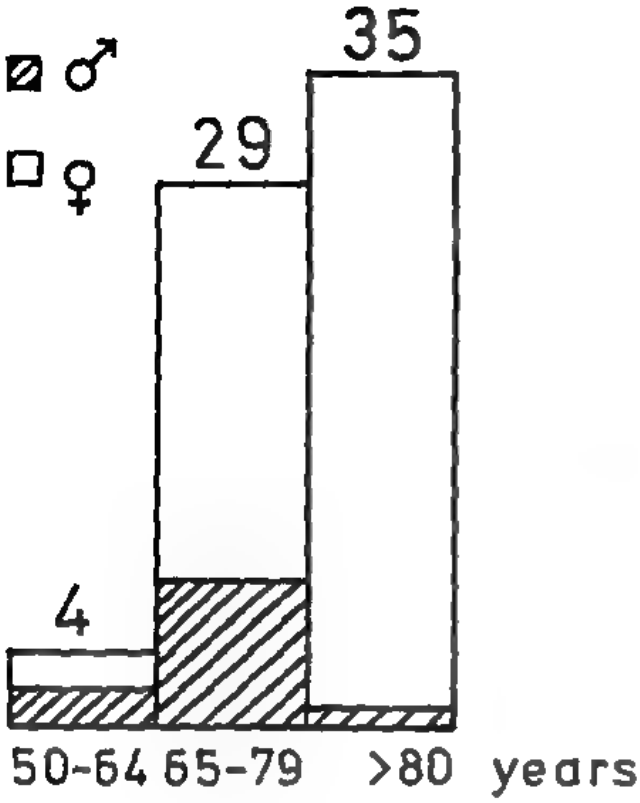

Figure 1 Age and sex distribution of patients with hip fracture

been treated in the Department of Orthopaedic Surgery at the University Hospital of Lund The mean age at the time of fracture was 79 years (Figure 1) Nineteen of the patients were married, 16 single, and 33 widows/widowers or divorced There were 35 fractures of the femoral neck and 33 trochanteric fractures Forty-eight patients came from their own homes and 20 from institutions (nine from old people's homes, seven from nursing homes and four from another hospital unit) The mean age in the former group was 78 years and in the latter 83 years.

Treatment

The detailed surgical and mobilization programme will be described in a separate article (Ceder et al, in press) An endeavour was made in each case to operate within 3 days after admission and to start mobilization with weight-bearing of the affected limb as early as the first postoperative day Only three of the operated patients were not allowed immediate weight-bearing Femoral neck fractures were operatively treated with insertion of a Rydell nail (Rydell 1964) in 21 cases, other types of nails in 6 cases and a hemi-prosthesis in 2 cases. For fixation of trochanteric fractures the Thornton nail and McLaughlin plate were used in 23 cases and Ender nails in 9 cases. Seven patients were not operated upon two died shortly after arrival, three were poor risk patients and two had stable fracture These latter two patients were allowed weight-bearing

Roentgen examination

Routine roentgen examination of the affected hip was done pre- and postoperatively [illegible] weeks, at 6 weeks, at 3 months, sometimes [illegible] months and at follow-up 1 year,

Review

About 12 months after sustaining fractures, the patients were visited in their homes by a specially appointed physiotherapist. They were interviewed, according to a standard questionnaire, regarding their social situation, mobility and ability to cope with activities of daily living (ADL) Fifty-one of the original 63 patients were reviewed Sixteen patients had died and one was lost to follow-up examination.

The interview was followed by roentgen examination of the operated hip Three of the patients (two femoral neck fractures and one trochanteric fracture) could not be examined roentgenologically at follow-up The former were women, aged 93 and 86 years one of them had no symptoms referable to the hip, but required walking support The third patient was in a nursing home after a stroke and bedridden Thus roentgen examination was carried out in 48 patients (21 femoral neck fractures and 27 trochanteric fractures)

The femoral neck fractures were operated according to Rydell in 14 patients, according to Thornton in two, according to Nystrom [illegible] and in one with a nail and plate One patient was not operated upon One patient with Parkinson's was primarily treated with insertion of a hemi-prosthesis. Another patient suffered from thyrotoxicosis and was treated in traction [illegible] weeks Owing to a displacement, she was fitted with a hemi-prosthesis.

The trochanteric fractures were fixed with Thornton nail and McLaughlin plate [illegible] patients or with Ender nails in a few patients. One patient was not operated on [illegible]

The physiotherapist classified the patient's home as modern semi modern or old-fashioned The home was classified as modern if it had running hot and cold water WC and shower or bath, as semi-modern, if it had no shower or bath and old-fashioned if it lacked an indoor WC and/or running water

Mobility indoors was assigned a certain number of points as follows. Confinement to bed or

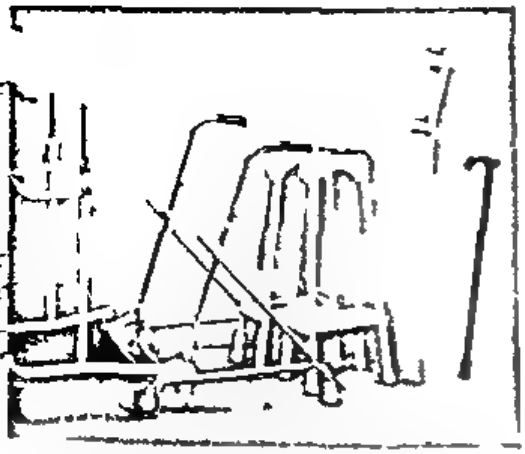

2. Walking aids used in rehabilitation of with hip fracture (from left to right) frame rollator, quatraped, elbow crutch walking stick The elbow crutch was seldom by old patients

or ability to walk only when strongly by another person scored 0 points, frame 2 points (Figure 2), rollator 3 quatraped

ized ADL

going to toilet one point personal one point, and dressing and undressing one point The patient who was able to manage independently and completely each activity was given the maximum score of 4 points.

For statistical analysis the chi-square test was used

RESULTS

Mortality

One quarter (16/68) of the patients had died 1 year after the fracture Nine patients died from cardiovascular diseases (Table 1) The mortality rate among patients who came from their own homes was only 15 per cent (7/48) compared with 45 per cent (9/20) of those institutionalized at the time of fracture (Table 2) This difference is almost significant ($P<0.05$)

Institutional care after discharge from hospital

Four of the 48 patients who lived at home before the fracture died in the Orthopaedic Department, 18 were discharged to institutions and the remaining 26 went directly home (Table 2) Eight of the 18 patients

Table 1 Time of death, cause of death, age and sex

Time of death* (days after fracture)	Diagnosis	Age	Sex
2	Pulmonary embolism†	76	M
4	Ruptured aortic aneurysm†	82	F
7	Aspiration pneumonia†	87	F
10	Myocardial infarction†	81	F
25	Chronic pyelonephritis with uraemia†	82	F
43	Cardiac incompensation	91	F
53	Pleuromesothelioma†	78	M
55	Metastasing breast carcinoma	83	F
74	Bronchopneumonia	72	M
102	Pleuropneumonia	95	F
166	Cardiac incompensation	91	F
174	Cerebral haemorrhage	93	F
174	Cardiac incompensation	87	F
210	Chronic lymphatic leukaemia	78	M
264	Myocardial infarction†	83	F
362	Cardiac incompensation	85	F

*Patient numbers 1–6 died in the Orthopaedic Department
†Diagnosis from autopsy

eventually returned home after they had received an average of 55 days of care with 1 1 admissions each in different institutions after the discharge from the Orthopaedic Department This can be compared with 26 days of institutional care with 0 4 admissions each for the 26 patients who initially returned home Seven of the 18 patients became permanent residents in institutions with an average of 264 days of care and three had died at follow-up after having spent an average of 109 days in institutions

Patients living at home

Patients living alone or with someone Of the 19 patients (mean age 76 years) living with someone before the fracture, 16 could return directly home from the hospital, whereas of the 29 (mean age 79 years) who were living alone before the fracture, only 10 could go directly home Patients living with someone could thus more often return directly home The difference between the groups in this respect is significant ($P<0\ 01$)

Communal home help The need for help successively increased (Table the fracture 10 of the 34 patients returned home at follow up had home and after 1 year 21 of these patients receiving such help This difference is significant ($P<0\ 05$) This is essentially to the fact that more of the patients with someone received home help at foll than before the fracture Thirteen of patients had no communal home help year, but 6 were helped by relatives employed private help and only 7 had no help at all

Patients' homes at the 1 year review 34 who resided at home 20 were living flat, 7 in their own houses, and 7 in pensioners. Twenty-five of the homes modern with toilet and bath and 9 modern with no bath None was fashioned Thirty of the 34 patients climb at least three steps.

Since all the patients lived in the Lund, a good general service was av

Table 2 Accommodation before fracture after discharge from hospital and 1 year later

	From own home ($n=48$)		From institution (n 20)	
	At discharge	At 1 year	At discharge	At 1 y
Own home	26	34	1	1
Old people s home	5	3	4	3
Nursing home	6	4	9	–
Other hospital unit	3	–	3	–
Rehabilitation centre	4	–	1	–
Dead	4	7	2	9

Table 3 Recipients of communal home help before fracture at time of discharge from hosp 1 year later (patients who returned home)

	Before fracture		At discharge		After 1 year	
	Alone	Living with someone	Alone	Living with someone	Alone	Living with someone
With home help	8	2	6	6	11	11
Without home help	10	14	4	10	7	6
Total	18	16	10	16	18	16

only three patients were more than 1 meter from the nearest post office, bank, or bus stop But even when there less than 1 kilometer to the nearest shop, than half (18/31) of the patients could avail themselves of this service because of opaedic and/or other medical or social es. Six of these patients used a quatraped the remaining 12 used a walking-stick or no support

three of the 34 patients at home pensioners three of these had retired than normal A 50-year-old woman half time, having completely from the fracture

bility and ADL

Of the 51 patients reviewed, 17 used some ing support even before the fracture Of 34 patients living at home at the 1-year ow-up, 6 used a quatraped, 17 a walking- and 11 walked unaided Of the six ents living in old people's home, two used rollator two a quatraped and two a ing stick Of the 11 patients in nursing e, six were bedridden, two used a ing frame, one a quatraped, one a ing stick and one no support at all Thus, total of only 12 patients walked unaided the ADL-test, the majority of patients 34) living at home scored the maximal 4 a few (5/34), 3 points, and only one, 2 Half of the patients in old people's scored the maximum number of points Of those in nursing homes, the majority (10/11) scored 0 or 1 point The mobility test showed a similar distribution with the mean close to a maximum of 6 points for patients at home and less than 2 points for patients in a nursing home (Table 4)

Roentgen examination at review

Femoral neck fractures Three of the 19 patients were reoperated upon and fitted with a prosthesis within 1 year of the fracture due to secondary displacement of the fracture in two cases and necrosis of the femoral head in one

Six of the patients had *necrosis of the femoral head* during the follow-up year Five of them had not been reoperated Three of the five patients had no symptoms referable to the hip and locomotion was satisfactory, whereas one had pain but no functional impairment The fifth patient had both pain and a deteriorated hip function A replacement of the femoral head was later performed

Six femoral neck fractures had *not healed* 1 year after the operation Three of these belonged to the group with necrosis of the femoral head described above The remaining patients had in two cases minor discomfort and one also had functional impairment

Trochanteric fractures In three of the 27 patients, the result of the operation after 1 year was unsatisfactory as evaluated by

Table 4 *Mobility and ADL-test scores for patients living at home, in old people's homes and in nursing homes at follow-up 1 year after hip fracture*

Accommodation	Number	Mean score	
		Mobility (max 6 points)	ADL (max. 4 points)
Living home	34	5 1 (range 4–6)	3 8 (range 2–4)
Old people's home	6	4 (range 3–5)	3 (range 1–4)
Nursing home	11	1 7 (range 0–6)	0 6 (range 0–2)

roentgen examination One fracture had not completely healed since the osteosynthesis material had loosened, resulting in a varus position, this patient had no symptoms and the function of the hip was not impaired In an 86-year-old woman the fracture was compressed, the nail having penetrated into the joint The patient was bedridden before the fracture as well as 1 year after the operation One patient was reoperated on because of fracture of the osteosynthesis material In spite of this, the fracture healed in a varus position without the patient having either pain or functional impairment

DISCUSSION

Mortality

Sixteen of the 68 patients had died within 1 year after the hip fracture, 13 of them within the first 6 months This figure agrees well with the increased mortality within the first 3 to 6 months after hip fracture in other series (Fitts et al 1959, Alffram 1964, Hansen & Neidhardt 1970) It is noteworthy that patients coming from their own homes have a better prognosis

Accommodation

Four fifths of the surviving patients coming from their own homes returned home within 1 year (Table 2) Three of the four surviving patients from old people's homes returned there All five survivors from nursing homes were in their institution after 1 year The only patient who required less care at discharge from the hospital than before the fracture came from another hospital unit where he had been investigated for myeloma, he was first discharged to his home but later admitted to the hospital for cytostatic treatment During the first year after discharge from the Orthopaedic Department the patients successively required less institutional care This applied in particular to patients who came from their own homes, eight of whom were first referred t stitution but afterwards returned hor seven of the survivors among those w from their own homes required perma stitutional care However, several patients probably needed institution even before the fracture

Patients living at home

Patients living with someone wer often able to return directly home discharge from the Orthopaedic Depa than patients living alone The forme on average 3 years younger than the However, also the urge to return hom probably stronger for those who somebody waiting for them, making th few weeks after the home-coming (Thomas & Stevens 1974)

The proportion of patients who req home help at follow-up was greater before the fracture (Table 3) This inc occurred gradually during the follow-up most strikingly for patients living someone One year after the fracture t was no difference between the two gr regarding the proportion of patients requ home help This might perhaps be expla by the assumption that the other pa could not, with the passage of time, ma the increased burden of domestic work was also possible that some latent need care before the fracture became more obv after discharge from hospital Eight pers living alone before the fracture w transferred to an institution after discha from hospital but eventually returned ho

Mobility and ADL status

The above unrecognized need for ca might also be reflected in the mobility a the ADL-test The mobility and ADL scor (Table 4) show that some of the pati living at home clearly had a lower score th several of those living in institutions The patients could continue to live at home de the help given by a partner, relatives or ho

2 Patients living alone before the fracture
d it more difficult after the discharge
n the hospital to return home because of
of help at home

ntgen examination at follow up

oral neck fractures The active mobiliza
programme with immediate weight-
ing in this series did not seem to increase
ra e of non union and/or necrosis of the
oral head Of the 19 femoral neck
ctures where immediate weight bearing
allowed necrosis of the femoral head
eloped in six. In an earlier material of 91
tients (Ståhl 1957) also from this depart
nt, the incidence of necrosis 1 year after
accident was 36 per cent in spite of the
that weight bearing was not allowed
l after 4 months Other workers
hlgren 1959 Frangakis 1966 and Ohman
al 1969) found necrosis of the femoral
d in about 40 50 per cent within 1 5 to 5
rs Veminen (1975) did not find that early
ht bearing (after 2 weeks) resulted in
re non union and necrosis of the femoral
d than late weight bearing (after 12
eks) which corroborated the findings of
mann & Cashman (1963)

Six of the 19 fractures had not healed but
ree of these also had necrosis of the femoral
d In a large material Barnes et al (1976)
d that at least 22 per cent of the fractures
women and 16 per cent in men had not
ed within 1 year Ståhl (1957) reported
non-union in 16 per cent

rochanteric fractures Roentgen examina
ion revealed few complications This agreed
ell with earlier publications Ring (1963)
Ainsworth (1971) reported no noteworthy
cations after immediate weight
bearing Alffram (1961) found no correlation
between walking ability and the anatomy of
the healed fracture and claimed that
rehabilitation was dependent almost entirely
on factors other than the actual fracture
Other workers (Laros & Moore 1974 Laros
1975 Jensen & Michaelsen 1975) reported a higher frequency of complications in the form of varus dislocation and penetration by the nail but like earlier investigators they did not consider these complications to be of major clinical significance

CONCLUSIONS

This investigation emphasizes the difference in survival mobility and ability to cope with ADL between patients coming from their own homes and institutions To be living with someone is a good prognostic factor for early return home There were no obvious reasons to explain why the need for home help increased during the follow up year and why more than one half of the patients did not do their own shopping Studies in progress (Ceder et al unpublished) suggest that there should be home visits by nurses physiotherapists or occupational therapists very early after discharge from the Orthopaedic Department to encourage rehabilitation In this way the patients might become more self confident and independent

ACKNOWLEDGEMENTS

Financial support has been obtained from the Swedish Medical Research Council (Project B79 17X-02031 13A) the Swedish Planning and Rationalization Institute of the Health and Social Services (SPRI) Malmohus lans landsting and Stiftelsen for bistånd åt vanföra Helsingborg The authors wish to thank Miss Anna Hakansson for secretarial help and Karl Goran Thorngren MD for statistical analysis

REFERENCES

Ainsworth T H Jr (1971) Immediate full weight bearing in the treatment of hip fractures *J Trauma* **11**, 1031–1040

Alffram P A (1961) Om funktionen efter trochanter femurfraktur *Nord Med* **66** 1153

Alffram P A (1964) An epidemiological study of cervical and trochanteric fractures of the femur

in an urban population *Acta orthop scand*, Suppl. 65

Barnes, R, Brown, J T, Garden, R S & Nicoll, E A (1976) Subcapital fractures of the femur *J Bone Jt Surg* 58-B, 2–24

Bonnin, J G & Cashman, B (1963) Early weight-bearing in low-angle nailing of the femoral neck *Brit J Surg* 50, 640–648

Borgquist, L. (1974) Organisationsnivåer inom sjukvården En studie av höftfrakturer hos aldringar Thesis, Lund

Carroll, D G (1968) Measurement of performance in rehabilitation Activities of daily living (ADL) *Maryland med J* 17, 113–116

Ceder, L, Lindberg L & Odberg, E Differentiated care of hip fracture in the elderly Mean hospital days and results of rehabilitation *Acta orthop scand* (In press)

Ceder, L., Thorngren, K.-g & Wallidén, B Prognostic indicators and early home rehabilitation in elderly hip fracture patients (Study in progress).

Dahlgren, S (1959) Venography in fractures of the femoral neck *Acta chir scand* 117, 494–500

Fitts, W T, Jr, Lehr, H B, Schor, S & Roberts, B (1959) Life expectancy after fracture of the hip *Surg Gynec Obstet* 108, 7–12.

Frangakis, E K (1966) Intracapsular fractures of the neck of the femur Factors influencing non-union and ischaemic necrosis. *J Bone Jt Surg* 48 B, 17–30

Hansen, N & Neidhardt, F O (1970) Mortality in fracture of the neck of the femur *Ugeskr Laeg* 132, 1709–1714

Jensen J Steen & Michaelsen, M (1975) Trochanteric femoral fractures treated with McLaughlin osteosynthesis *Acta orthop scand* 46, 795–803

Katz, S, Ford, A B, Moskowitz, R W, Jac B A & Jaffe, M W (1963) Studies of I in the aged The index of ADL A standar measure of biological and psych function *J Amer med Ass* 185, 914

Laros, G S & Moore J F (1974) Comp of fixation in intertrochanteric fractures *Orthop* 101, 110–119

Laros, G S (1975) Intertrochanteric frac The role of complications of fix *Surg* 110, 37–40

Nilsson, B E & Obrant, K J (19 tendencies of the incidence of fracture upper end of the femur *Acta orthop* 49, 389–391

Nieminen, S (1975) Early weight-bearing classical internal fixation of medial fractu the femoral neck *Acta orthop scand* 782–794

Öhman, U, Bjorkegren, N-Å & Fahlstro (1969) Fracture of the femoral neck. A fi follow-up *Acta chir scand* 135, 37–42

Ring, P A (1963) Treatment of troch fractures of femur *Brit med J* 1, 6

Rydell, N (1964) Osteosynthesis of med fractures with the "spring loaded nail" *orthop scand* 35, 149–157

The Staff of the Benjamin Rose Hospital Multidisciplinary studies of illness in persons II A new classification of func status in activities of daily living *J* *Dis* 9, 55–62.

Ståhl, F (1957) Ett collumfrakturmaterial *Med* 58, 1167–1168

Thomas, T G & Stevens, R S. (19 effects of fractures of the neck of the f *Brit med J* 3, 456–458

Correspondence to Leif Ceder, M D, Department of Orthopaedic Surgery, University Hospital 85 Lund, Sweden.

ST-TRAUMATIC BONE MINERAL LOSS IN IBIAL SHAFT FRACTURES TREATED WITH A EIGHT-BEARING BRACE

RE M. ANDERSSON & BO E NILSSON

ment of Orthopedic Surgery, Malmo General Hospital (University of Lund), 14 01 Malmö Sweden

The bone mineral content in the upper ends of the tibia and the fibula was measured in 27 patients with tibial shaft fracture The loss of bone mineral associated with the fracture did not differ between patients who were allowed weight-bearing in a functional below knee brace and patients treated with a long leg plaster cast without weight bearing

Key words bone mineral, fracture, osteoporosis

Accepted 5 1 79

er the interest and enthusiasm for stable e fixation of tibial shaft fractures declined, ention has been directed towards con- ive methods One such method, which some of the advantages of plate ion, was advanced by Sarmiento (1967, 70). This method includes a "functional" h moulded tightly on the lower leg, which the range of motion in the knee almost ricted. In later designs a movable e joint was also included With this brace, e patients are allowed unrestricted weight- ing

Loss of bone mineral after fracture is a well established phenomenon It is, however, not established to what extent this loss is due to ise or to metabolic changes introduced by e fracture itself

Gird (1934) and Abramson & Delagi (1961) posed that early exercise and weight- ing could be effective means of pre- ing osteoporosis after fracture

Early weight bearing in a functional brace appears to be an acceptable treatment of tibial shaft fractures without serious soft tissue injuries. The time required for union of the fractures is comparable with that after other types of treatment and complications are rare (Önnerfelt 1977) An added advantage is that the treatment is comfortable for the patient

The purpose of the present study was to investigate whether weight-bearing in a functional brace influences the loss of bone mineral in the tibia as compared with standard treatment with a long leg cast without weight-bearing

PATIENTS AND METHODS

The study included 27 cases of fracture of the shaft of the tibia in 17 men and 10 women Twelve fractures were long oblique or spiral whereas 15 were of the transverse or comminuted

ancial support was obtained from the Swedish Medical Research Council (project no B 77-17X 2737-01) and the Greta and Johan Kock, and Alfred Osterlund Foundations.

ISSN 0 44 079 060689-03$02 50 0

© 1979 Munksgaard Copenhagen

types The treatment of these patients was individual during the first 3 weeks after fracture with application of a long leg plaster cast with or without transfixation and in two cases open reduction with screw fixation and a long leg cast However after 3 weeks the patients were randomly divided into two groups. In 14 cases the treatment with the long leg cast was continued In these cases weight bearing was not allowed until the fractures were considered clinically stable In the remaining 13 cases a weight bearing below knee cast

been attained In six of these cases the brace was supplied with a mobile ankle (Sarmiento 1970) The patients were assigned to the two groups according to random numbers

The bone mineral content (BMC) of the injured leg was measured by a recto-linear gamma absorptiometry scan across the proximal ends of the tibia and the fibula 4 cm distal to the joint (Figures 1 2 and 3) From the third week on the patients were measured at approximately monthly intervals until 12 months had elapsed after the injury Subsequently measurements were carried out at approximately 6-month intervals.

The following data were calculated

The rate of change between 3 weeks after fracture and the time for observation of the lowest value

The maximum loss which was usually recorded about 20 weeks after the fracture when weight bearing was permitted in most patients in both the groups

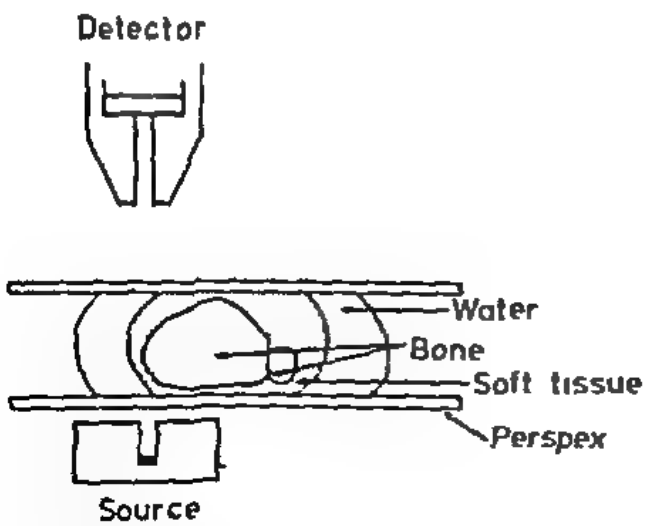

Figure 1 Gamma absorptiometry In Americium 241 source and a detector (collimator 7 mm circular) are moved across the sample at constant speed

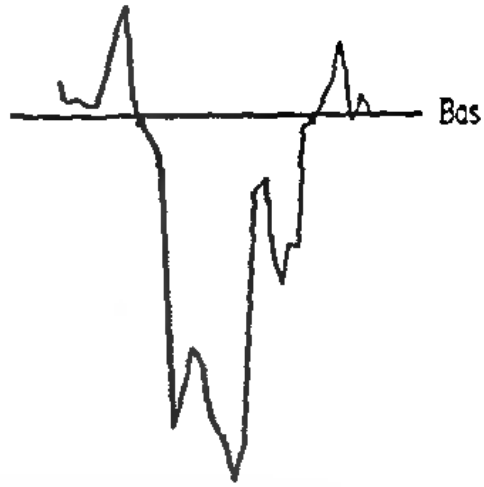

Figure 2 Graphical tracing of absorptiometry printout from the upper ends of the tibia and fibula

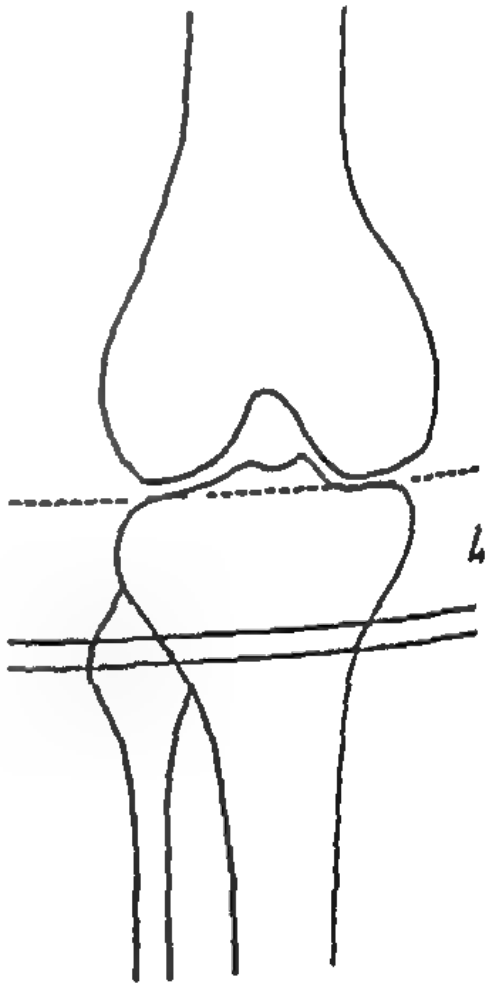

Figure 3 Measuring site In patient measurements the site was located with the aid of roentgen image intensifier

Table 1 Changes in BMC in relation to treatment

	n	Age	Loss, %/week	Gain %/week	Maximum loss %	Final loss %
+ -bearing	13	35±16	2.6±3.3	0.6+0.5	44±14	24 16
-bearing	14	49±14	2.1±1.2	0.5±0.4	46±21	29 1[illegible]

from the lowest value to the
i.e.
final loss (after 1 year).

LTS

rate of loss as well as the rate of gain ightly increased in the weight bearing as compared with the non weight- but there was a considerable scatter in the data and the difference significant (Table 1) The maximum the final loss did not differ sigm- y between the two groups. To some appeared to influence the sequence sets There was a significant negative ation between age and rate of loss 0.42, $0.05>P>0.02$) and between age te of gain ($r_{27}=0.51$, $0.01>P>0.001$) s context, however, age may be replaced BMC value since older subjects BMC This indicates that in older with a smaller amount of bone the changes are less conspicuous and outcome the same

USSION

was no evidence that the type of or the duration of treatment the process triggered off by the Nilsson (1966) found a relationship duration of disability, duration of fixation and bone loss. However, in study those patients with the healing time and the longest disability excluded from the material since open were not included There was no influence of age that could not be ed by the fact that older patients had initially less bone mineral. There were large differences between individual patterns which cannot be explained by imperfections of the method. The most important finding in this study was the similarity of the patterns in those patients who were allowed early weight bearing and those in a long leg weight bearing protected cast. The process of losing bone is neither interrupted nor modified when the patient starts weight bearing just as it tends to continue even when the plaster – in both groups – is subsequently removed The hypothesis that post fracture osteoporosis can be prevented or at least modified by exercise and weight bearing may still hold true However, the weight bearing and the physical activity permitted a patient in a functional brace as treatment for a tibial fracture are not sufficient to break the pattern initiated by the fracture

REFERENCES

Abramson, A S & Delagi, E F (1961) Influence of weight bearing and muscle contraction on disuse osteoporosis. *Arch Phys Med* 42, 147–151

Gurd F B (1934) Post traumatic acute bone atrophy (Sudeck s atrophy). *Ann. Surg* 99, 449–468

Nilsson B E. (1966) Post traumatic osteopenia. A quantitative study of the bone mineral mass in the femur following fracture of the tibia in man using Americium 241 as a photon source *Acta orthop scand*, Suppl. 91

Onnerfelt, R. (1978) Fracture of the tibia shaft treated by primary operation and early weight bearing *Acta orthop scand* Suppl 171

Sarmiento A (1967) A functional below-the-knee cast for tibial fractures. *J Bone Jt Surg* 49 A, 855–875

Sarmiento A. (1970) A functional below-the-knee brace for tibial fractures. *J Bone Jt Surg* 52 A 295–311

to Dr Bo Nilsson, Department of Orthopaedic Surgery Malmo General Hosp
Malmo, Sweden.

-hop srand. 50, 693–697, 1979

™ GTH OF PLANTAR FLEXION AND FUNCTION ıн RESECTION OF VARIOUS PARTS OF THE ICEPS SURAE MUSCLE

ıN MARKHEDE & LARS NISTOR

ts of Orthopaedic Surgery I and II and the Department of bilitation Medicine I, University of Göteborg, Goteborg, Sweden

Nine patients who had undergone resection of various well defined parts of the triceps surae muscle because of tumour were examined The function was estimated from the patient's history and the muscle strength was measured statically and dynamically using a Cybex II dynamometer Two patients

gastrocnemius more active when the foot is in plantar flexion, and that the gastrocnemius is most important in quick movements of the foot

Key words ankle joint, biomechanics, Cybex II, muscle contraction, muscle resection, plantar flexion, soft tissue tumour, surgical treatment

Accepted 22 ɣv 79

ᵐmant and locally aggressive tumours of soft tissues are generally treated sur- y To secure an adequate *margin of* thy tissue the surgeon must choose amputation and wide *en bloc* resec- which often requires excision of an ᵉ muscle or group of muscles The pre- e planning must aim at as radical a cal intervention as *possible with* a loss of function This requires ledge of the effect of loss of certain on the function of the limb This reports the function of the ankle in nine in whom various parts of the triceps muscle had been removed along with a r and demonstrates the strength of ar flexion

TERIAL AND METHODS

ᵉen 1965 and 1976 13 patients were op- d on and various parts of the triceps surae muscle resected The operations were performed at the Department of Orthopaedic Surgery, Sahlgren Hospital, Gothenburg Nine of the patients were reviewed 2 – 13 years after the operation Of the remaining four, two had died in the meantime from intercurrent disease, one had poor function of the muscle already before the

of the patients as well as the diagnosis and the muscles extirpated are given in Table 1

When the patients' history was assessed inquiry was made into their ability to manage their work and into the way they spent their spare time Notes were also made of any complaints of pain, unsteadiness of gait and limp The patients were asked for walking distance walking aids, ability to run and whether they had any difficulty in walking up and down steps. Their ability to walk on tiptoes was examined The range of motion of the ankle joint was measured

The strength of plantar flexion was measured on both sides statically and dynamically with a Cybex II dynamometer In this test the patient was supine with straightened knee The ankle was

ᴴᴳ0–9 060693–05$02 50/0

© 1979 Munksgaard Copenhagen

Table 1 Descriptive data of the nine patients subjected to resection of different parts of the triceps surae

No	Age	Follow-up time (years)	Sex	Diagnosis	Extirpated muscle
1	23	4	M	Haemangioma	Soleus (s)
2	76	13	F	Myxoma	Soleus (s)
3	17	2	F	Haemangioma	Medial soleus (ms)
4	21	3	F	Haemangioma	Lateral soleus (ls)
5	55	7	M	Liposarcoma	Medial gastrocnemius (mg)
6	64	3	M	Intramuscular lipoma	Lateral gastrocnemius (lg)
7	65	2	F	Myositis necroticans	Lateral gastrocnemius + lateral soleus (lg + ls)
8	32	7	M	Myxofibromatous soft tissue tumour	Medial gastrocnemius + medial soleus (mg + ms)
9	20	5	F	Unclassified soft tissue sarcoma	Soleus + medial gastrocnemius (s + mg)

fixed with straps over the front and the back of the tarsus so that the heel could not be raised more than half a centimetre The plantar flexion torque of the ankle was recorded by an x-y-writer Before the test the patients were allowed to practice the various movements and at the same time read the results on an oscilloscope Static muscle strength was measured with the ankle dorsiflexed 15° in neutral position and plantarflexed 15° and 30° The dynamic strength of plantar flexion was measured during slow movement of the joint (30°/s), moderately fast movement (90°/s), and during fast movement (180°/s) The peak torque and its position in relation to the neutral position of the ankle was measured The best of three maximal performances in each position and angular speed was used The patients were allowed to rest for 1 minute between consecutive tests In one patient (No 2) only static strength was measured

RESULTS

Only two patients (Nos. 7 and 9) reported slight symptoms, viz unsteadiness of gait when walking on uneven ground The distance the patients could walk unhindered and their ability to run and walk up and down steps had not been affected in any of them All the patients had returned to their previous work Neither were their spare time activities affected, not even for those four who had regularly taken part in sports more than twice a week All patients could stand and walk on tiptoes. In six patients the range of motion was slightly reduced, but only one was aware of it and the impairment never exceeded 10° in either direction as compared with the normal side All patients were able to dorsiflex a minimum of 15°

The muscle strength recordings are given in Table 2. The ankle torque of the operated side is given relative to that on the other side. Substantial differences in strength between different positions of the ankle and between static and dynamic recordings were found, but only one patient (No 9) was the mean of seven measurements below 80 per cent. The differences in strength between the various positions varied with the part of the triceps surae that had been removed. Thus, the mean static recordings of the strength when the soleus or part of it had been removed (Nos 1–4) was 79 per cent of that on the non-operated side when the ankle was in dorsiflexion and 112 per cent when it was in 30° plantar flexion This difference was statistically significant ($0.01 < P < 0.02$) When only part of the gastrocnemius had been removed (Nos. 5 and 6) the opposite result existed so that in the dorsiflexed position the mean strength was 112 per cent and in

ble 1 Strength of the ankle on the operated side relative (%) to that on the other side (pf plantar on df=dorsiflexion) The shift of peak values relative to that on the unoperated side is expressed in degrees (+ = plantarly, − = dorsally)

e no ected muscle		1 s l	2 s r	3 ms l	4 ls r	5 mg l	6 lg l	7 lg + ls l	8 mg + ms l	9 mg + s l
it torque	15 df	70	85	63	99	129	95	104	80	72
	0	89	97	71	99	99	88	94	89	75
	15 pf	109	116	100	98	72	86	71	93	87
	30 pf	97	117	120	113	76	84	46	89	75
amic torque	30°/s	91		97	110	91	92	90	86	100
	90°/s	100		118	94	88	94	74	88	61
	180°/s	113		103	114	69	76	119	73	143
l difference	30°/s	+9		0	−6	−5	−1	+7	−6	−7
	90°/s	+9		+3	−3	−4	−3	+9	−6	1
	180°/s	+11		+9	−1	−1	[illegible]	+10	−5	−20

tarflexed position 80 per cent, but this rence was not statistically significant se two groups differed in strength in 30° tar flexion $0.01 < P < 0.02$) but not in nflexion As for the dynamic strength, a parison between the group in which only soleus or part of it had been resected (Nos and 4) and the group in which only part of gastrocnemius had been resected (Nos 5 6) showed a statistically significant rence at an angular velocity of 180°/s $.02 < P < 0.01$) At this angular velocity the strength for the group in which the soleus been resected was 110 per cent of the non-ated side compared with 73 per cent for the p in which the gastrocnemius had been ted * In two of the patients in whom only soleus had been resected the peak shifted tarly, whereas in the two in whom only the rocnemius had been resected the peak ed dorsally In the remaining three patients 7, 8 and 9), in whom the soleus or part of ad been resected along with one of the gastrocnemii, the picture varied and no particular pattern could be discerned

se differences are not changed if the results corrected for side differences suggested by bch & Termansen (1978) right leg stronger left – and Fugl-Meyer & Pedersen (personal mmunication) – left leg stronger than right

DISCUSSION

Adequate treatment of malignant or locally aggressive tumours of the soft tissues requires extensive resection and usually excision of an entire muscle with a bordering layer of fascia (Bowden & Booher 1958) Function after such an operation is rarely reported We could trace only one case in the literature in which the strength of plantar flexion had been measured after removal of the entire triceps surae (Murray et al 1976) This patient lost 62 per cent of the plantar flexion torque When theoretical calculations make the triceps surae responsible for 80 per cent of the plantar flexion torque (Fick 1911, Haxston 1944) the difference was explained by compensatory hypertrophy In a later report on the same patient (Murray et al 1978) the gait was analysed The patient was unable to run and had a limited walking speed In our series of nine patients, where up to about 75 per cent of the tissue mass of the triceps surae had been removed, the loss of strength never exceeded 30 per cent when

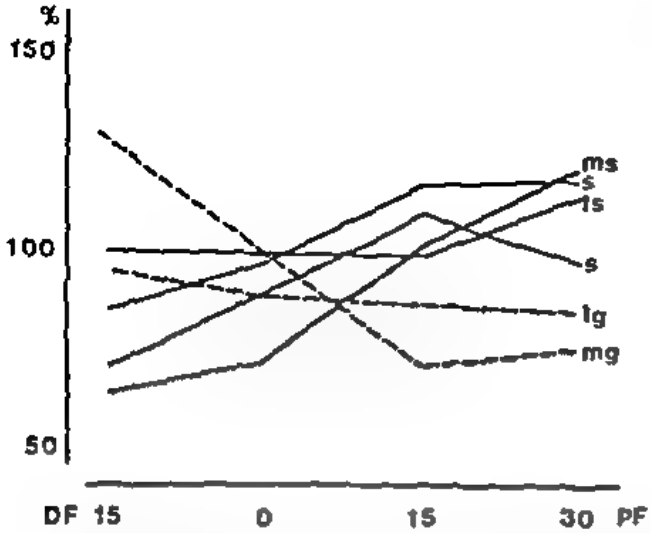

Figure 1 Plantar flexion torque (peak torque) in four positions of the foot expressed relative to corresponding values on the unoperated side (PF=plantar flexion, DF=dorsiflexion) Letters denote muscle resected (ms=medial soleus ls=lateral soleus, s=soleus, mg=medial gastrocnemius, lg=lateral gastrocnemius)

statically measured with the foot in neutral position This is also less than one would expect from theoretical calculations The two patients with slight discomfort (Nos 7 and 9) had a reduction of strength that did not differ substantially from that in the others.

Dambolt et al (1978) recently measured the plantar flexion torque in neutral position during isometric contraction in 30 healthy persons. These authors stated that the difference between symmetrical muscle groups should exceed 15 per cent to be pathological Only two of our patients had lost more than 15 per cent when statistically measured in neutral position The absolute strength of the operated limb did not fall outside the range of a corresponding normal material (Fugl Meyer & Pedersen, personal communication)

All nine patients had been subjected to resection of well defined muscles. The pattern of the loss of strength varied with the muscle resected Static strength varied with the position of the ankle and dynamic strength with the speed [illegible] ar motion of the joints (Figures 1 and 2)

Herman & Bragin ([illegible]) studied the function of the gastrocnemius and [illegible] electromyographically, showed that the [illegible] in more active when the foot is dorsi[illegible] and that the gastrocnemius is more ac[illegible] when the foot is in plantar flexion and du[illegible] rapid contraction These findings w[illegible] confirmed by the present investigation [illegible] which it was observed that in patients [illegible] whom the soleus had been resected the los[illegible] strength was greatest when the foot [illegible] dorsiflexed (Figure 1), whereas in the [illegible] patients in whom parts of the gastrocne[illegible] had been removed the loss of strength [illegible] greatest when the foot was in plantar fle[illegible] (Figure 1) Compensatory hypertrophy of [illegible] residual muscles results in less reduction [illegible] strength than expected in that part of [illegible] range of motion where the resected muscle [illegible] most important The hypertrophy of [illegible] remaining muscles results in an e[illegible] compensation in that range of motion w[illegible] these muscles develop their greatest speed

On fast angular motion of the ankle [illegible] loss of strength was greatest in the [illegible] patients in whom part of the gastrocne[illegible] had been removed (Figure 2) an observa[illegible] that lends support to the view that [illegible] muscle is of greatest importance for [illegible] development of power

CONCLUSIONS

1 Extensive resection if not total, of [illegible] triceps surae causes only relatively [illegible]

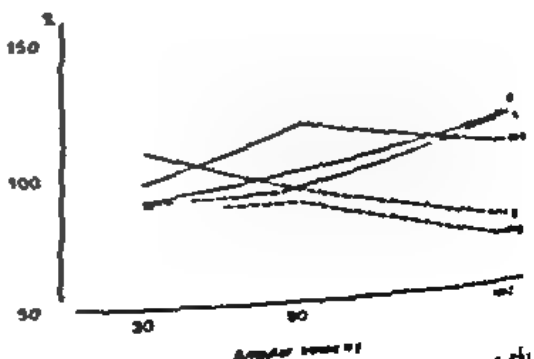

Figure 2 Peak torque of plantar flexion at the speeds of angular motion expressed relative to [illegible] on the unoperated side

significant symptoms and does not affect the patient's ability to walk and run

The loss of plantar flexion strength is small and smaller than might be expected from theoretical calculations, probably because of compensatory hypertrophy

The soleus contributes most to the strength of plantar flexion when the foot is dorsiflexed, whereas the gastrocnemius ps its greatest power when the foot s in plantar flexion

The gastrocnemius is of greatest im- for quick movements of the foot

OWLEDGEMENT

study was supported by grants from the ersity of Goteborg, Greta och Einar Askers the Norbacka Foundation

REFERENCES

Bowden, L & Booher, R J (1958) The principles and technique of resection of soft parts for sarcoma *Surgery* 44, 963–977

Dambolt, V & Termansen, N B (1978) Asymmetry of plantar flexion strength in the foot *Acta orthop scand* 49, 215–219

Fick, R (1911) *Anatomie und Mechanik der Gelenke* Teil III, Spezielle Gelenk und Muskelmechanik Fischer, Jena

Haxston, M A (1944) Absolute muscle force in the ankle flexors of men *J Physiol (Lond)* 103, 267–273

Herman, R & Bragin, J (1967) Function of the gastrocnemius and soleus muscles. *Phys Ther* 47(2), 105–113

Murray, M P, Guten, G N, Baldwin, J M & Gardner, G M (1976) A comparison of plantar flexion torque with and without the triceps surae *Acta orthop scand* 47, 122–124

Murray, M P, Guten, G N, Sepic, S B, Gardner, G M & Baldwin, J M (1978) Function of the triceps surae during gait *J Bone Jt Surg* 60-A, 473–476

to Goran Markhede, M D, Department of Orthopaedic Surgery II, Sahlgren Hospital, 13 45 Goteborg, Sweden.

orthop scand 50 699–704, 1979

INICAL AND SOCIAL STATUS FOLLOWING JURY TO THE LATERAL LIGAMENTS THE ANKLE

ow up of 144 Patients Treated Conservatively

ANSEN V DAMHOLT & N H TERMANSEN

rtment of Orthopaedic Surgery, Odense University Hospital, se Denmark

Out of 174 patients treated conservatively [illegible] ligaments of the ankle 144 were seen at follow-up [illegible] 4 2 years) and clinical as well as social [illegible] diagnostic criterion was a difference in [illegible] between the injured and uninjured [illegible]

Occupational and athletic injuries, [illegible] total of 64 per cent Residual symptoms were [illegible] in the form of functional instability, [illegible] reported daily complaints One patient had [illegible] this was the only patient who had [illegible] treatment There was a close correlation [illegible] ankle joint and residual symptoms [illegible] the degree of primary talar tilt All [illegible] normal range of movement in the [illegible] patients with residual symptoms had [illegible] the working ability was unaffected

The period off work had been [illegible] and fairly heavy work as for those [illegible] with residual symptoms had had [illegible] daily complaints This indicates that [illegible] fact latent symptoms elicited [illegible]

Key words ankle, ankle injuries [illegible] ankle, sprained ankles

Accepted 2 III 79

[illegible] diagnosis and treatment of injuries to the [illegible] ral ligaments of the ankle pose a problem [illegible] ich is still the subject of discussion [illegible] nderson & LeCocq 1954, Ruth 1961, [illegible] eman 1965, Brostrom 1965, Olerud 1967, [illegible] lund Sørensen 1975)

The present study was designed to [illegible] ndate the frequency of residual symptoms [illegible] d their influence upon the working capacity [illegible] d athletic performance in patients treated [illegible]

1-6470/79/060699–06$02 50/0

stress radiographs with the foot in 20–30° plantar flexion, has been the routine practice in the event of clinical suspicion of injury to the lateral ligaments of the ankle in patients without fractures and having closed epiphyseal lines. With a view to follow-up, all inversion stress radiographs from the 3-year period January 1970 to December 1972 were reviewed

The diagnosis of injury to the lateral ligaments of the ankle was made when the difference between talar tilt in the injured and uninjured foot, primary talar tilt=(I−U)° was at least 6 degrees (Freeman 1965) In this case there is rupture of the anterior talo-fibular as well as calcaneo-fibular ligament (Anderson et al 1952) Only patients with unilateral injury were included The criteria were fulfilled by 179 patients. Five treated surgically were excluded, which leaves 174 conservatively treated patients, 144 of whom were seen at follow-up Thirty could not be seen because they had gone abroad or refused to attend There was no difference in primary talar tilt between these 30 patients and those who attended follow-up

Of the 144 patients examined at follow-up 130 had been treated with a walking cast for 6 weeks and 14 by a supporting bandage until the pain had subsided All were out-patients. None had had any special physiotherapy The follow-up period ranged from 3 1 to 6 1 years, mean 4 2 years. The age distribution and sex ratio may be seen from Figure 1 The mean age was 26.9 years (15–75 years) Eighty per cent were 15–35 ye[illegible] two were females and 92 males Of the [illegible] were right-sided and 73 left-sided Ta[illegible] the accident situation The major[illegible] injuries or injuries sustained at work ([illegible] 28 4 per cent, respectively).

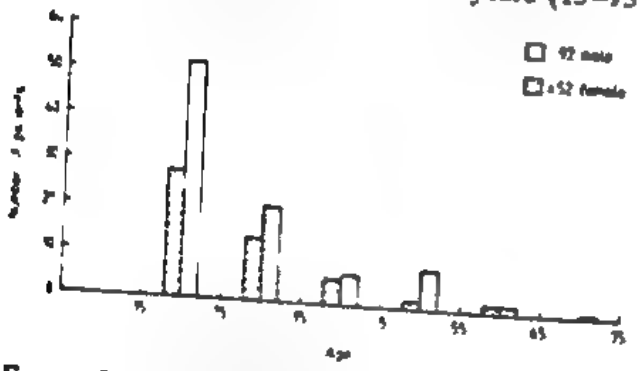

Figure 1 Age distribution and sex ratio of 144 conservatively treated patients

Table 1 Situations of the accide[illegible]

	Number	[illegible]
Traffic	7	[illegible]
Place of work	41	[illegible]
Home	21	[illegible]
Sport	51	[illegible]
Others	24	[illegible]
Total	144	[illegible]

At follow-up the patients were questioned residual symptoms and their influence upo[illegible] working ability and sports performance

"Functional instability" (F I) is here ta[illegible] mean a feeling of insecurity and a tendency [illegible] foot to "give way". The clinical exam[illegible] comprised palpation of the ankle and [illegible] clinical evaluation of instability in the [illegible] joint, assessment of active and passive mo[illegible] the talo-crural and subtalar joints, and record[illegible] pain, if elicited

RESULTS

Residual symptoms At follow-up 30 pat[illegible] (20 8 per cent) had residual symptoms Th[illegible] follow-up period and mean age did not d[illegible] from those in the material as a whole Ta[illegible] 2 gives the residual symptoms. Functional [illegible] stability was the most important resid[illegible] symptom, present in 26 patients. Four h[illegible] merely periodical pain and swelling [illegible] strain Only four patients reported [illegible] complaints, having weekly episodes of [illegible]

Table 2 Residual symptoms at follow-up of 144 patients

	No of pts	Per cent
Pain and swelling	4	2.8
Functional instability (F I)	18	12.5
F I + pain and swelling	8	[illegible]
Total	30	[illegible]

k 3 Residual symptoms in relation to primary talar tilt, (I−U)° I−talar tilt in injured foot U=talar tilt in uninjured foot

I)°	No of pts.	Pts. having residual symptoms
1–9°	58	10
9°	38	8
23°	48	12
tal	144	30

2 chi² test, chi²=[redacted]989, degrees of freedom 2 0 6<*P*<0 7

r One of them had developed reflex strophy Apart from this patient, none had n referred for further orthopaedic therapy [redacted] w[redacted] using a prophylactic supporting dage There was no difference in talar tilt therapeutic result between the 14 patients ated with a supporting bandage and the 0 treated with a walking cast In the lowing therefore, the two groups will be alysed together

Table 3 presents the severity of the uries, assessed by the primary talar tilt U)°, related to the incidence of residual mptoms. In one third of the patients the ference in talar tilt between the injured and njured foot exceeded 10 degrees aximum 23 degrees) There was no atistically significant difference in the equency of residual symptoms between the ee groups Further analysis of the group ving marked instability failed to disclose a ther correlation between the degree of mary instability and the incidence of sdual symptoms. Pain elicited by movement in the talocrural and subtalar joints was present in seven patients, all of whom had residual symptoms None had reduced mobility Tenderness of the lateral ligaments was found in 17 patients, 8 of whom had residual symptoms.

Working ability The patients' work at the time of the accident is graded into heavy, fairly heavy, and light defined as walking work with strain, walking work without strain, and mainly sedentary work

The period off work was assessed according to the sick leave period Table 4 sets out the sick-leave period in relation to the heaviness of the work There was a wide variation but the mean period of sick-leave was approximately the same for patients with heavy and fairly heavy work and twice that for patients with light work The difference is statistically significant Two patients with residual symptoms had stopped working, including the one with reflex dystrophy Three patients had not been working at the

Table 4 Period reported sick in relation to heaviness of work

roup	Work	No of pts.	Mean period reported sick weeks	(range)
	Heavy	34	8 1	(1–30)
I	Fairly heavy	51	8 5	(1–72)
	Light	56	3 6	(1–9)
	Not working	3		
	Total	144		

roup I versus group II unpaired t test 0 490<*P*<0 495
roups I+II versus group III unpaired t test *P*<0 0005

time of the accident and were also not working at follow up. None of them had residual symptoms. Twenty nine patients had changed their occupation during the follow-up period. Ten of them had residual symptoms. However, a change to heavier work was equally common as a change to lighter work. There was no difference in the frequency of residual symptoms between the three occupational groups.

Sports performance. At the time of the accident 92 patients had been active in sport. Fifty-one of them (55 per cent) sustained their injury during sports activities, 35 in competitive sport and 16 while exercising. Table 5 gives the relationship between primary talar tilt (I−U)°, situation of accident and residual symptoms. Competitive sport caused the most severe injuries, but not an increased frequency of residual symptoms. Forty six patients were active football players at the time of the accident and 31 of these (67.3 per cent) sustained their injuries while playing. At follow up residual symptoms were present in 10, 6 of whom had sustained their injury at football. All those having residual symptoms had had to give up playing football. However three took up a lighter sport. Only two had problems in everyday activities. The 36 patients who continued playing football could do so after a mean interval of 18 weeks. Twelve of the 17 handball players sustained the [illegible] playing handball. Five had [illegible] symptoms, but only one had had to give [illegible] playing. Among the other 16 [illegible] interval before resuming handball [illegible] weeks. Twenty nine patients were participating in other types of sport at the [illegible] of the accident and eight of them (7[illegible] per cent) had sustained their injury while [illegible] so. At follow up five had residual [illegible]. All had continued to participate in sport [illegible] two had changed to a lighter type. The [illegible] interval before resuming was 14 weeks.

DISCUSSION

The value of inversion stress radiography [illegible] disputed partly because of the [illegible] physiological variation in talar tilt (R[illegible] Witten 1960) and partly because [illegible] reported to be negative in ligament [illegible] injuries diagnosed by other meth[illegible] (Brostrom 1966).

However a number of authors have fo[illegible] agreement between inversion [illegible] radiographs and operative findings (R[illegible] 1961, Freeman 1965, Clark et al. 1965, W[illegible] & Hupfauer 1969) and also with exper[illegible] findings (Anderson & Anderson et al. 1[illegible]). As a diagnostic criterion we used a di[illegible] of 6 or more degrees in talar tilt on the [illegible] jured and uninjured foot (Freeman 1965). O[illegible]

Table 5. Primary talar tilt (I−U)° in relation to the situation of the accident and residual [illegible] (144 patients)
I° talar tilt in injured foot. U° talar tilt in uninjured foot

(I−U)°	Competitive sport		Exercising		Other accidents	
	Total pts.	Pts. having residual symptoms	Total pts.	Pts. having residual symptoms	Total pts.	Pts. [illegible]
6°–7°	11		8	1	39	[illegible]
8°–9°	10		2	1	26	[illegible]
≥ 10°	14		6	1	28	
Total	35		16	3	93	

apeutic results accord with the results of e other authors also using conservative ment (Brostrom 1966, Clark et al 1965) ers have reported poorer results of conrative treatment Thus Ruth (1961) found dual symptoms in 58 per cent after a w-up period of 8 years, Freeman (1965) 41 per cent after a follow-up period of 1 and Niethard (1974) in 55 per cent after 3 year follow up The treatment consisted, ours, of a walking cast for 6 weeks, in strom's cases, however, it was for only 3 eks Several authors (Anderson & LeCocq 4 Ruth 1961, Weber & Hupfauer 1969, and Sorensen 1975) have recommended erative treatment of these injuries and have orted favourable results. In his 96 erated patients Brostrom (1966) found ctional instability in 3 per cent and esthesia and hypaesthesia at the scar in 7 cent. In Ruth's material (1961) 50 per had symptoms but only 10 per cent had or complaints. Among Freeman's (1965) ents 68 per cent had symptoms – half in form of functional instability Clark et al 65) found no difference between patients ed conservatively and by operation hard (1974) in his surgically treated nts, after a follow up period of 3 5 years, and symptoms in 40 per cent, in half these es functional instability

Thus, apart from the result obtained by ostrom (1966) the results of operative ament have not been better than our s of conservative treatment In the erated patients, moreover there has urred wound infection cutaneous necrosis, paesthesia/dysaesthesia and a restricted ge of movement

The results among the football players dicate that the degree of strain decides ether residual symptoms become manifest the papers quoted above no special ention is made of the conditions under vere strain but according to the varying sults – as in the football players – some ients would seem to have latent symptoms hich do not manifest themselves until cited by severe strain on the foot

CONCLUSION

1. Out of 144 patients treated conservatively for injuries to the lateral ligaments of the ankle 20 8 per cent had residual symptoms after a mean follow-up period of 4 2 years. Only four patients had major complaints.
2. A correlation between residual symptoms and primary talar tilt could not be demonstrated
3. There was a close relationship between pain on moving the ankle and residual symptoms
4. The period reported sick was significantly longer in patients having heavy and fairly heavy work than in patients with light work
5. There was no demonstrable correlation between change of occupation and residual symptoms
6. Residual symptoms influenced athletic performance only in the branches of sport which severely strain the foot (e g football)

REFERENCES

Anderson K J LeCocq J F & LeCocq E A (1952) Recurrent anterior subluxation of the ankle *J Bone Jt Surg* 34 A 853–860

Anderson K J & LeCocq J F (1954) Operative treatment of injury to the fibular collateral ligament of the ankle *J Bone Jt Surg* 36-A 825–832

Brostrom L Liljedahl S-O & Lindvall N (1965) Sprained ankles. II Arthrographic diagnosis of recent ligament ruptures *Acta chir scand* 129, 485–499

Brostrom L (1965) Sprained ankles III Clinical observations in recent ligament ruptures *Acta chir scand* 130, 560–569

Brostrom L (1966) Sprained ankles. V Treatment and prognosis in recent ligament ruptures. *Acta chir scand* 132, 537–550

Clark B L Derby A C & Power G R I (1965) Injuries of the lateral ligament of the ankle conservative vs operative repair *Canad J Surg* 8, 358 363

Freeman M A R (1965) Treatment of ruptures of the lateral ligament of the ankle *J Bone Jt Surg* 47 B 661–668

Kolind-Sørensen, V (1975) Laterale ligament-laesioner i fodled *Ugeskr Laeg* **137**, 1637–1638

Niethard, F U (1974) Die Stabilität des Sprunggelenkes nach Ruptur des lateralen Bandapparates. *Arch orthop Unfall Chir* **80**, 53–61

Olen d, S (1967) [illegible]

and the fibular collateral l[illegible] of the [illegible] *J Bone Jt Surg* 42 A 311 [illegible]

Ruth, C. (1961) The surgical treatment of [illegible] of the fibular collateral ligaments of the [illegible] *J Bone Jt Surg* 43 A, 229–239

Weber B G & Hupfauer W (1[illegible] Behandlung der frischen fibularen [illegible] und der chronischen fibularen [illegible] insuffizienz. *Arch orthop Unfallchir* 251–257

Correspondence to Henning Hansen, Kløvervaenget 24C[II], 5000 Odense Denmark

Orthop scand 50, 703 708 1979

RADIOLOGICAL AND MUSCULAR STATUS FOLLOWING INJURY TO THE LATERAL LIGAMENTS OF THE ANKLE

Follow-up of 144 Patients Treated Conservatively

B TERMANSEN, H HANSEN & V DAMHOLT

Department of Orthopaedic Surgery, Odense University Hospital Odense Denmark

An average of 4 2 years after conservative treatment of injury to the lateral ligaments of the ankle 144 patients attended a follow up examination which included radiography and measurement of the strength of plantar flexion

Prior to treatment all of the patients had a difference in talar tilt of 6 or more degrees between the injured and uninjured side. At follow-up there was instability in 28 patients or 19 4 per cent but no correlation between instability and residual symptoms Nine patients had an anterior drawer sign" exceeding 2 mm but this was also without relation to residual symptoms. Radiological evidence of osteoarthrosis was found in five patients, but four of them had a stable ankle joint and only one had residual symptoms.

The mean age of the patients with osteoarthrosis was twice that for the entire material. Two patients had osteochondritis of the talus

The strength of plantar flexion was measured in 124 patients There was

Key words ankle injuries conservative treatment ligament injuries plantar flexion

Accepted 22 iv 79

Injuries to the lateral ligaments of the ankle give rise to instability which can be confirmed radiologically (Freeman 1965, Olerud 1976) Recently measurements of muscle strength have been used as a means of assessing sequelae to injuries of the lower limbs (Damholt & Zdrakovic 1972 and 1974 Illies & Chalmers 1970)

In the present study the radiologically detectable sequelae to injuries of the lateral ligaments of the ankle were correlated with the clinical sequelae and the possible relationship between these sequelae and the plantar flexion strength was studied

PATIENTS

The 144 patients, described in more datail in a previous study (Hansen et al 1979) were treated conservatively for injury to the lateral ligaments of the ankle The diagnosis was made when the difference in talar tilt between the injured and uninjured foot, on radiographs taken at the time of the accident was 6 or more degrees (Freeman 1965) The follow up period averaged 4 2 years (3 1–6 1 years)

The clinical follow up was described in our previous study (Hansen et al 1979) The radiological follow-up consisted of ordinary radiography of the ankle joint an inversion stress exposure (Freeman 1965) and an exposure for anterior drawer sign (Olerud 1967)

ISSN 0030-6665/79/060703 04$02 50 0

© 1979 Munksgaard Copenhagen

For measuring plantar flexion strength we used a strain gauge dynamometer with an unyielding apparatus for fixing the leg With this arrangement the contraction of the calf muscles could be recorded in metric During the measurements the patient sat as described by Asmussen & Heebøll Nielsen (1961) The isometric strength could be read in arbitrary units on the scale The plantar flexion strength recorded was the maximum tension on the scale that the subject could perform in three attempts

RESULTS

At follow-up 28 patients (19 4 per cent) had secondary instability when using the same criteria of instability as at the time of the accident Table 1 gives the relationship between secondary instability and residual symptoms (pain, swelling, functional instability) Statistical analysis showed no significant correlation between secondary instability and residual symptoms

Nine patients had an anterior drawer sign exceeding 2 mm Table 2 shows that this sign was not significantly correlated with residual symptoms.

At follow-up five patients had radiological evidence of osteoarthrosis in the injured ankle Four out of these five patients had stable ankles. The mean follow-up period for the patients with osteoarthrosis did not differ from that in the total material, but their mean age was higher, viz 55 years as against 27 years Only one of the five patients had complaints on account of the ankle

Two patients, aged 29 and 27 years had developed radiological osteochondritis of the talus during the follow-up period Only one of them had symptoms, and neither had secondary instability or osteoarthrosis of the ankle

Plantar flexion strength was measured in 124 patients as 20 had to be excluded from this test (17 had various diseases of the leg in question 2 had sciatica and 1 was pregnant) In 68 patients the uninjured leg was stronger than the injured one in 32 the injured leg was stronger than the uninjured one, while in 24 patients there was no difference On the average, the uninjured leg was 6.3 per cent stronger than the injured one The group of uninjured legs was significantly stronger than the group of injured legs (t test < 0.01)

Of the 124 patients whose plantar flexion strength was measured 28 had residual symptoms. Among the 96 patients without residual symptoms the uninjured leg was on average of 5 5 per cent stronger than the injured leg whereas the uninjured leg was [illegible] per cent stronger than the injured leg in the 28 patients with residual symptoms The difference in strength reduction between patients with and without residual symptoms was not statistically significant (Student's t test $t = -1.068$, degrees of freedom [illegible] $0.10 < P < 0.15$)

Table 1 Secondary talar tilt (I–U)° in relation to residual symptoms at follow-up of 144 patients treated conservatively for injury to the lateral ligaments of the ankle

Secondary talar tilt (I–U)°	No of pts	Pts having symptoms at follow-up
<6°	116	24 (20 7 per cent)
6–9°	22	4 (18.2 per cent)
≥ 10°	6	2 (33.3 per cent)

3 × 2 chi² test
chi² = 0 657
degrees of freedom = 2
$0.7 < P < 0.8$

Table 2 Anterior drawer sign in relation to residual symptoms at follow-up of 144 patients treated conservatively for injury to the lateral ligaments of the ankle

Anterior drawer sign	No of pts	Pts having symptoms at follow-up
Absent	135	31
Present	9	2

chi² = 0 011
degrees of freedom = 1
$0.90 < P < 0.95$

ıdiography revealed secondary instability of the 124 patients Among the 98 ıts whose ankle was stable the uninjured was an average of 7 6 per cent stronger the injured leg, whereas the cor-nding difference in he group with in-ility was 1 7 per cent The difference in ngth between the group with stable and with unstable ankle joints was not tistically significant (unpaired t test $t =$ 78 degrees of freedom 122, 0 05 $< P <$ 0).

SCUSSION

actional instability (F I) is the most mon residual symptom following injury to lateral ligaments of the ankle According several authors, among others Anderson & Cocq (1954) Brostrom (1966), and Weber Hupfauer (1969), F I is due to mechanical kability of the ankle joint, and they commend operation as the only means of uring stability in the joint By contrast eman (1965) and Freeman et al (1965) and no association between F I and chanical instability, and felt that F I must due to other factors

To assess the stability of the ankle joint vious authors (Anderson & LeCocq 1954 ostrom 1966, Olerud 1967) have used rly inversion stress radiographs and partly anterior drawer sign In the present terial we used inversion stress radiographs well as the anterior drawer sign—both nfirmed radiologically — to assess stability of ankle joint This did not show any cor-lation between F I and ankle stability — in ordance with the findings of Freeman 965) and Freeman et al (1965), but at ntrance with others (Andersen & LeCocq 954, Brostrom 1966 Weber & Hupfauer 969).

Freeman et al (1965) believe that F I is used by a proprioceptive defect due to psular injury connected with the ligament pture In the present material no study was ade of a possible proprioceptive defect at follow-up, but like Freeman et al (1965) we could find no association between unstable ankle joints and F I

The incidence of osteoarthrosis was low after our follow-up period, only five patients having this affliction Osteoarthrosis occurred in an age group considerably more advanced than that of the total material and bore no correlation to unstable ankle joints

There are no previous reports of systematic measurement of plantar strength in patients with injuries of the lateral ligaments of the ankle, but measurements of strength have previously been used as parameters of sequelae to injuries of the lower limbs (Damholt & Zdrakovic 1972 and 1974, Gillies & Chalmers 1970)

A difference of 15 per cent is usually reported as the limit of physiological variation between symmetrical muscle groups (Heebøl-Nielsen 1964) In our material the group "uninjured leg" was an average of 6 3 per cent stronger than the group "injured leg" The reduction of strength in patients with F I was not significantly greater than in symptom-free patients Moreover, patients with unstable ankle joints did not show a significantly greater reduction of strength than did patients with stable ankle joints

Injuries to the lateral ligaments entail only a slight reduction of strength in the ankle assessed by plantar flexion strength, and F I or mechanical instability cannot be ascribed to a reduction of plantar flexion strength

The pathogenesis of F I still seems to be unelucidated and mechanical stability does not appear to afford any guarantee against the occurrence of F I

CONCLUSION

1 Out of 144 patients with injury to the lateral ligaments of the ankle 19 4 per cent still exhibited instability after conservative treatment and a mean follow-up period of 4 2 years
2. There was no correlation between radiological instability at follow-up and residual symptoms.

3 Plantar flexion strength in the group of injured legs was significantly less than in the group of uninjured legs but the mean difference in strength was small

4 There was no statistically significant correlation between residual symptoms and reduced strength or between radiological instability and reduced strength

5 According to the results of the present study and a previous one (Hansen et al 1979) and those reported in the literature we find no reason to change our present principles regarding the routine of the diagnosis and conservative treatment of injuries to the lateral ligaments of the ankle

REFERENCES

Anderson K J & LeCocq J F (1954) Operative treatment of injury to the fibular collateral ligament of the ankle *J Bone Jt Surg* 36-A 825–832

Asmussen E & Heebøl Nielsen K (1961) Isometric muscle strength of adult men and women Common Test Obs. Inst Dan Nat Ass. inf Paral nr 11

Brostrom L (1966) Sprained ankles. V Treatment and prognosis in recent ligament ruptures. *Acta chir scand* 132, 537–550

Brostrom L (1966) Sprained ankles VI [illegible] treatment of "chronic" ligament rupture [illegible] *chir scand* 132, 551–565

Damholt V & Zdrakovic D (19[illegible]) Quality function following fractures of the [illegible] shaft *Acta orthop scand* 43, 148 1[illegible]

Damholt V & Zdrakovic D (19[illegible]) Quality function following fractures of the [illegible] shaft in children *Acta orthop scand* 756–763

Freeman M A R (1965) Instability of the [illegible] after injuries to the lateral ligament of [illegible] ankle *J Bone Jt Surg* 47 B 669 6[illegible]

Freeman M A R Dean, M R C & Hanh[illegible] I W F (1965) Etiology and prevention [illegible] functional instability of the foot *J Bone Jt Surg* 47 B 678–685

Gillies, H & Chalmers J (19[illegible]0) The [illegible] of fresh ruptures of the tendo Achillis *J Bone Jt Surg* 52 A 337 343

Hansen H Damholt V & Termansen N (1979) Clinical and social status [illegible] injury to the lateral ligaments of the ankle *Acta orthop scand* (In press).

Heebøl Nielsen K (1964) Muscular [illegible] normal young men Common Test Obs. Inst Dan Nat Ass. inf Paral nr 18

Ole[illegible]

We[illegible] suffizienz und der Chron[illegible] Bandinsuffizienz *Arch orthop. [illegible]* 65, 251 257

Correspondence to H Hansen Klovervaenget 24CII 5000 Odense Denmark

orthop scand. 50, 709–712

K EVALUATION OF OPERATIVE PROCEDURES THE TREATMENT OF HAMMER TOE

MOND J NEWMAN & JOHN M FITTON

rtment of Orthopaedic Surgery, St James's University Hospital, Leeds, U K

Eighty per cent of 63 patients who had undergone 136 surgical corrections of hammer toes in the 6 years prior to this study were improved by operation In adults proximal phalangectomy was the most successful procedure to relieve symptoms and is suggested as the operation of choice Flexor to extensor tendon transfer was successful in children but not in adults. It is proposed that the operation be performed in an out-patient basis whenever possible

Key words hammer toe, proximal phalangectomy, flexor to extensor tendon transfer, proximal interphalangeal joint arthrodesis

Accepted 1 vi 79

r since Boyer in 1816 published the eration of extensor tenotomy for the cor- ction of hammer toes a multitude of gical techniques have been described ese have ranged from conservative soft sue procedures to, at the other extreme, putation (Ely 1926) In spite of this the rature does not contain any reviews of the ious procedures and the choice of eration has therefore been based upon the geon's personal preference rather than und scientific principle It was for this son that this research was undertaken

ATIENTS AND METHODS

patients who had undergone surgical correc- n of hammer toes in the previous 6 years were ted to attend for review The operations had en randomly performed by all grades of surgical ff and all patients were interviewed and amined by the same impartial observer The patients were asked to assess the success their treatment by choosing from three alterna- e descriptions (a) excellent, i e marked im- rovement and satisfaction (b) fair, i e some improvement and satisfaction, (c) poor, i e no improvement or deterioration and dissatisfaction Two points were awarded for an excellent result, one for a fair result and none for a poor result In this way it was possible to give each operation a score, i e the actual points awarded were expressed as a percentage of the maximum points possible.

RESULTS

Sixty-three patients who had undergone 136 corrections of hammer toes attended for review There were 22 cases of proximal phalangectomy (Trethowan 1925), 56 cases of flexor to extensor tendon transfer (Taylor 1951), 28 cases of excision arthrodesis of the proximal interphalangeal joint (Soule 1910), 15 cases of excision arthrodesis of the proximal interphalangeal joint with Kirschner wire fixation (Taylor 1940), and 15 cases of peg and socket arthrodesis of the proximal interphalangeal joint (Higgs 1931) The average age at the time of surgery was 46 0 years and the average length of follow-up was 2.63 years.

1 64"0 79 060709–04$02.50 0

© 1979 Munksgaard, Copenhagen

Table 1 Overall results of operations as judged by relief of presenting complaint

	Excellent	Fair	Poor	Score
Proximal phalangectomy	77% (17)	5% (1)	18% (4)	80%
Flexor to extensor transfer	34% (19)	50% (28)	16% (9)	[illegible]
Proximal interphalangeal arthrodesis				
Excision only	32% (9)	43% (12)	25% (7)	[illegible]
Excision and fixation with Kirschner wire	40% (6)	30% (5)	30% (4)	57%
Peg and socket	66% (10)	14% (2)	20% (3)	73%

(Figures in brackets indicate actual numbers of operations)

Eighty per cent of those interviewed were improved by operation (Table 1) but the success of each method depended to some extent upon age (Table 2)

Further analysis relating the results to the sex of the patient or to the position of the distal interphalangeal joint prior to surgery failed to establish a correlation

The complications related to particular operations were as follows shortness and flailness of the toe was reported in five cases (23 per cent) of proximal phalangectomy Medial or lateral deviation of the operated toe at the proximal interphalangeal joint was found in six cases (10 per cent) of proximal interphalangeal joint arthrodesis These were distributed equally between the three types of arthrodesis Fanning of the toes, i.e. hyperextension at the metatarsophalangeal joint and an inability to flex the toes was [illegible] not infrequently by some children who had undergone flexor to extensor tendon transfer but this however was not a serious complication

Evidence of fusion was found in only [illegible] per cent of the arthrodesis operations [illegible] was not related to relief of symptoms [illegible] those cases where fusion had occurred the score was [illegible] per cent and in the [illegible] where fusion did not occur the score was [illegible] per cent

Thirty-three per cent of the operations were performed on an out-patient basis the remainder the patients were admitted to hospital for an average of 8.5 days The [illegible] patients resumed work after an average convalescence of 5 5 weeks whereas for the [illegible] patients it was 9 0 weeks When only one toe was operated upon in patients resumed work after an average of 6 weeks compared to 5 weeks for out-patients these single toe operations the two groups patients were comparable with regard to sex and co-existing medical problems

Table 2 Results of operations related to age

	3–15 years	Over 16 years
Proximal phalangectomy	(0)	60% (22)
Flexor to extensor tendon transfer	90% (23)	[illegible] (33)
Proximal interphalangeal joint arthrodesis	[illegible]	[illegible]

(Figures in brackets indicate [illegible] of operations)

SCUSSION

this series 23 flexor to extensor tendon nsfers in 10 children gave a score of per cent These results are almost ical to those in a series of 68 operations, ly in children reported by Taylor (1951) results when converted to a score as in this per were 88 per cent Similarly, operations on mainly children's feet reviewed by Pyper 58) gave a converted score of 90 per cent refore this procedure which appears to e consistently good results and should not ect the growth of toes is to be recommended children.

Many techniques of proximal inter alangeal joint arthrodesis have been scribed (Soule 1910, Higgs 1931, Young 38 Taylor 1940 Selig 1941) but there are published figures regarding their success this survey the peg and socket method was best way of performing the operation but was not quite as successful as proximal alangectomy in relieving symptoms rthowen (1925) was the first to indicate the cess of this technique and Classman et al 949) subsequently reported 54 proximal alangectomies producing "excellent cosmetic sults" with 'active control regained' but ded no further information These results at slight variance with this survey where ur patients (18 per cent) complained of a oor cosmetic result and lack of digital ntrol. However, it should be mentioned t at the time of follow up these patients re free of pain and it was pain which was ir original presenting complaint This eration which can be performed on an out-tient basis should therefore be considered the ethod of choice for adults

In this series the in patients were off-work approximately twice as long as the out-tients. This can probably be explained by e fact that the in patient group often had sociated medical problems. They were also der and usually had several toes operated on at the same time (average 2 0) The out-atients however were often fitter, younger d usually had only one toe operated upon (average 1 6) It is interesting that for single toe operations in otherwise comparable groups the in-patients were off-work longer than the out-patients

CONCLUSIONS

1 All operations reviewed were basically successful in relieving the presenting complaint
2 In adults proximal phalangectomy was the most successful procedure and should be considered the operation of choice
3 Proximal interphalangeal joint arthrodesis performed by the peg and socket technique was the second most successful procedure for the relief of symptoms in adults and is a useful alternative operation for those patients who are reluctant to accept a grossly shortened toe
4 Flexor to extensor tendon transfer was useful only for children
5 Fusion was not required for a successful result when arthrodesis was attempted
6 The operation should be performed on an out-patient bases whenever possible and this approach seemed to be especially useful for children and single toe operations

ACKNOWLEDGEMENTS

We wish to thank Messrs R Brown D J McWilliams B Reeves and F W Shea for permission to study their patients and are grateful to Mr H S Shucksmith for assistance in the preparation of the manuscript

REFERENCES

Boyer B (1816) *A treatise on surgical diseases and the operations suited to them* (Translated from the French by Alexander H Stevens.) Vol 2 p 383 T J Swords, New York.

Classman F., Wohn I & Sideman S (1949) Phalangectomy for toe deformities. *Surg Clin N Amer* 29, 275–280

Table 1 Overall results of operations as judged by relief of presenting complaint

	Excellent	Fair	Poor	Score
Proximal phalangectomy	77% (17)	5% (1)	18% (4)	[illegible]
Flexor to extensor transfer	34% (19)	50% (28)	16% (9)	59%
Proximal interphalangeal arthrodesis				
Excision only	32% (9)	43% (12)	25% (7)	51%
Excision and fixation with Kirschner wire	40% (6)	30% (5)	30% (4)	[illegible]
Peg and socket	66% (10)	14% (2)	20% (3)	73%

(Figures in brackets indicate actual numbers of operations)

Eighty per cent of those interviewed were improved by operation (Table 1) but the success of each method depended to some extent upon age (Table 2)

Further analysis relating the results to the sex of the patient or to the position of the distal interphalangeal joint prior to surgery failed to establish a correlation

The complications related to particular operations were as follows shortness and flatness of the toe was reported in five cases (23 per cent) of proximal phalangectomy Medial or lateral deviation of the operated toe at the proximal interphalangeal joint was found in six cases (10 per cent) of proximal interphalangeal joint arthrodesis These were distributed equally between the three types of arthrodesis. Fanning of the toes, or hyperextension at the metatarsophalangeal joint and an inability to flex the toes was reported not infrequently by some children who had undergone flexor to extensor tendon transfer but this however was not a serious complication

Evidence of fusion was found in only [illegible] per cent of the arthrodesis operations and was not related to relief of symptoms since in those cases where fusion had occurred the score was 88 per cent and in the group where fusion did not occur the score was [illegible] per cent

Thirty-three per cent of the operations were performed on an out-patient basis but the remainder the patients were admitted to hospital for an average of 8.5 days The out-patients resumed work after an average convalescence of 5.5 weeks whereas for the in-patients it was 9 0 weeks When only one toe was operated upon in-patients returned to work after an average of 6 weeks compared to 5 weeks for out-patients [illegible] these single toe operations the two groups of patients were comparable with regard to age sex and co-existing medical problems

Table 2 Results of operations related to age

	3–15 years	Over 16 years
Proximal phalangectomy	(0)	80% (22)
Flexor to extensor tendon transfer	90% (23)	49% (33)
Proximal interphalangeal joint arthrodesis	(0)	40 (58)

(Figures in brackets indicate actual numbers of operations)

ISCUSSION

this series 23 flexor to extensor tendon sfers in 10 children gave a score of per cent These results are almost ical to those in a series of 68 operations ilar in children reported by Taylor (1951) results when converted to a score as in this per were 88 per cent Similarly, operations on mainly children's feet reviewed by Pyper 1953) gave a converted score of 90 per cent erefore this procedure which appears to consistently good results and should not the growth of toes is to be recommended children.

Many techniques of proximal inter-angeal joint arthrodesis have been cribed (Soule 1910, Higgs 1931, Young 1943, Taylor 1940 Selig 1941) but there are published figures regarding their success this survey the peg and socket method was best way of performing the operation but was not quite as successful as proximal angectomy in relieving symptoms Brown (1925) was the first to indicate the ness of this technique and Classman et al 1949) subsequently reported 54 proximal angectomies producing "excellent cosmetic lts" with 'active control regained" but ed no further information These results slight variance with this survey where patients (18 per cent) complained of a r cosmetic result and lack of digital trol. However, it should be mentioned the time of follow-up these patients e free of pain and it was pain which was r original presenting complaint This ation which can be performed on an out-ent basis should therefore be considered the hod of choice for adults.

In this series the in-patients were off work approximately twice as long as the out-ents. This can probably be explained by fact that the in patient group often had ociated medical problems They were also er and usually had several toes operated on at the same time (average 2 0) The out-ents however were often fitter, younger d usually had only one toe operated upon (average 1 6) It is interesting that for single toe operations in otherwise comparable groups the in-patients were off-work longer than the out patients

CONCLUSIONS

1 All operations reviewed were basically successful in relieving the presenting complaint
2 In adults proximal phalangectomy was the most successful procedure and should be considered the operation of choice
3 Proximal interphalangeal joint arthrodesis performed by the peg and socket technique was the second most successful procedure for the relief of symptoms in adults and is a useful alternative operation for those patients who are reluctant to accept a grossly shortened toe
4 Flexor to extensor tendon transfer was useful only for children
5 Fusion was not required for a successful result when arthrodesis was attempted
6 The operation should be performed on an out-patient bases whenever possible and this approach seemed to be especially useful for children and single toe operations.

ACKNOWLEDGEMENTS

We wish to thank Mssrs. R. Brown D J McWilliams, B Reeve and F W Shea for permission to study their patients and are grateful to Mr H. S. Shuckburgh for assistance in the preparation of the manuscript.

REFERENCES

Boyer B (1816) *A treatise on surgical diseases and the operations suited to them* (Translated from the French by Alexander H [illegible] Vol 2, p 331 T J Swords New [illegible]
Classman, F., Wilson, I & Sideman [illegible] Phalangectomy for toe deformities. [illegible] Amer 29 [illegible] 280

Ely L W (1926) Hammer toe *Surg Clin N Amer* 6, 433–435

Higgs S L (1931) Hammer toe. *Med Press* 131, 473

Piper J B (1958) The flexor/extensor transplant operation for claw toes. *J Bone Jt Surg* 40-B 528–533

Selig S (1941) Hammer toe A new procedure for its correction *Surg Gynec Obstet* 72, 101–105

Soule R E (1910) Operation for the correction of hammer toe *N Y med J* 91, 649–650

Taylor R G (1940) An operative procedure for the treatment of hammer-toe and claw-toe *J Bone Jt Surg* 22, 608–609

Taylor R G (1951) The treatment of claw toe by multiple transfers of flexor to extensor tendons *J Bone Jt Surg* 33 B 539–542

Trethowen W H (1925) Treatment of hammer toe *Lancet* i, 1312–1313

Young C S (1938) An operation for the correction of hammer toe and claw-toe *J Bone Jt Surg* 20, 715–719

Correspondence to R J Newman St James's University Hospital Leeds LS9 7TF U.K.

rthop. scand. 50 713 715, 1979

HE MITOTIC ACTIVITY OF BONE MARROW AND HYMUS AFTER COMBINED ANTIGENIC CHALLENGE ND TRAUMA

L. JOHNELL & ANDERS HULTH

partment of Orthopaedic Surgery, Malmö General Hospital
iversity of Lund), Malmö, Sweden

A significant increase in the mitotic rate of cells in thymus and bone marrow occurs 2–3 days after the infliction of various traumas or the injection of antigenic erythrocytes. This cell response probably occurs in order to produce the cells which are needed for the defence of the body after injury The present investigation shows that the cell response after a fracture is abolished if the rats are fractured 3 days after injection of antigenic erythrocytes.

Key words antigen, bone marrow, mitosis, thymus

Accepted 23 iv 79

ns and co-workers found, in 1971, an creased mitosis in the cells of bone marrow d thymus after standardized bleedings. lth & Johnell (1976a) found the same enomenon after fractures, soft tissue uma (Johnell 1977), bone marrow aspiraon (Hulth & Johnell 1976b) and injections f antigenic erythrocytes (Hulth & Johnell 9 8). In 1979, Johnell & Hulth showed that hen two traumatic injuries take place with n interval of only 2 days, the cell response to e second trauma is completely abolished ith an interval of 10 days, however, the llular proliferation returns, although it is layed.

In this paper we have studied the combina- f an antigenic injury, followed on the d day by a fracture

TERIAL AND METHODS

ree groups of 25, 23 and 10 rats, respectively ying 120–130 g were used In addition there was a control group of 15 rats. The first group was given intravenously in a tail vein 0 5 ml of sheep red blood corpuscles (S–RBC) 20 per cent S–RBC in saline = 4 0 × 10^{12} RBC/litre The animals were kept in cages and supplied with water and food *ad libitum* They were killed in groups of five at various times from 1 to 8 days after the injection The second group was also given S–RBC but after 3 days the left femur was broken, the animals being killed in groups of five to six, 1 to 4 days after the fracture. The third group of ten animals was fractured and killed after 1 and 2 days. The control group was killed without prior intervention The rats were given two injections of colchicine intraperitoneally, the first 6 hours (0 2 mg/100 g animal) and the second 3 hours (same dose) before the animals were sacrificed using ether All animals were given the injections of colchicine at the same time, the first injection being between 8 00 and 8 30 a.m., in order to avoid possible circadian variations.

The thymus gland and the right femur were removed Thymocyte and bone marrow cell [illegible] thymocyte suspension was prepared by mincing

ancial support was obtained from the Swedish Medical Research Council (project no 9 17X–05223–02)

64"0/79 060713 [illegible]

Acta orthop. scand. 50, 717–719, 1979

PARA-ARTICULAR OSSIFICATIONS ASSOCIATED WITH MELORHEOSTOSIS LERI

I DISSING & G ZAFIROVSKI

Orthopaedic Department and Neuroradiological Department, University Hospital Copenhagen Denmark

A case of para articular ossifications associated with melorheostosis gave differential diagnostic problems, as the only symptom referred to the ossifications in the left knee region

Key words melorheostosis para articular ossification

Accepted 3 v 79

Melorheostosis is not an unusual disease It was first described 1922 by Léri & Joanny, and since then nearly 200 cases have been published (Campell et al 1968) This figure is probably too low as quite a number of cases are asymptomatic and only found incidentally (Dissing & Pock Steen 1962) Morris et al (1963) mentioned the possibility of para-articular ossifications as a rare condition related to melorheostosis, but gave no figures for the incidence Subsequently, another four cases with para-articular ossifications combined with melorheostosis in other bones have been published (Campell et al 1968 Gold & Murra 1977, Milleret et al 1972 and Simon et al 1976).

In the Orthopaedic Department at the University Hospital we have had a patient with para articular ossifications and melorheostosis.

Figure 1 Left knee region with para articular calcifications close to the capsule

CASE REPORT

A 28-year-old man had noticed a swelling on the postero-medial aspect of his left knee for about 2 years. There were no accompanying symptoms in the left hip joint or the left foot Roentgen examinations showed several, small, round calcifications close to the capsule of the knee without any bony disturbances (Figure 1) The mass was removed and on the primary histological diagnosis indicated that it was probably a highly differentiated chondrosarcoma the patient was referred to the University Hospital A new roentgen examination showed some calcifications still in the knee region but calcifications were also seen close to the capsule of

0001 6470/79/060717–03$02 50/0

© 1979 Munksgaard Copenhagen

Figure 5 Left foot showing melorheostosis in the second metatarsal bone and second and third toes

several difficulties were encountered, as only symptom came from a very manifestation of the disease The genological examinations gave the impression of synovial osteochondromata, and was only because a ^{99m}technetium-phosphate scintigraphy gave a surprisingly uptake in the foot that another roentgen examination was made The [illegible] high uptake of ^{99m}tech[illegible] melorheostosis has, as far as we know [illegible] been reported once ([illegible] was not associated with para[illegible] ossifications.

REFERENCES

Campbell, C. J., Papademetriou, T. & [illegible] M. (1965) Melorheostosis. A report of the clinical, roentgenographic and pathological findings in fourteen cases. *J Bone J Surg* 50-A, 1231–1304

Dissing, L. & Poek-S[illegible], Ch. (1942) Melorheostosis (Leri). *Ugeskr Læg* 124, 1734–1737

Gold, R. H. & Mirra, J. M. (1977) Melorheostosis. Case report 35 *Skeletal Radiol* 2, [illegible]

Janousek, J., Preston, D. F., Martin, N. & Robinson, R. G. (1976) Bone scan in melorheostosis. *J nucl Med* 17, 1106–1108

Leri, A. & Joanny, J. (1922) Une affection non décrite des os hyperostose en coulée sur toute la longueur d'un membre ou "melorheostose" *Bull Soc Med Hop Paris* 46, 1141–114

Millerat, P., Comba, J. & Carbiet, J. P. (1972) Un observation de mélorheostose *Lyon Chir* 68, 201–204

Morris, J. M., Sandson, R. L. & Coeler, C. L. (1963) Melorheostosis. *J Bone J Surg* 45-A, 1191–1206.

Simon, L., Blotman, F., Caillens, J.-P., Brousse, A. & Serre H. (1976) Mélorheostose et pathologie articulaire de la hanche *Rev Rhum* 43, 737–741

Correspondence to L Dissing Tirsbaekvej 6, Vanløse, 2720 Copenhagen, Denmark.

Orthop scand. 50 721–725 1979

TENSION AND CREEP PHENOMENA IN PERIPHERAL NERVE

P KENDALL, I A F STOKES, J P O'HARA
R A DICKSON

Department of Orthopaedic Surgery, Nuffield Orthopaedic Centre
Headington, Oxford England

Tension introduced into peripheral nerves during their surgical repair may reduce the success of this procedure

Two mechanical factors are important, the tension required to effect a repair, and the rate at which this tension changes after surgery These two factors have been investigated in the rat sciatic nerve

The results show an increasing resistance to elongation of the nerves with increasing tension Under a constant elongation the tension in the nerves reduces by about 30 per cent in the first 10 minutes and by a small amount in the following 20 minutes

Key words biomechanics, creep, mechanical properties, microsurgery, nerve repair, peripheral nerve, strength tension

Accepted 12.iv 79

The surgical repair of divided peripheral nerves leaves the nerve in higher tension than in its undisturbed state This may make the repair liable to pull apart and technically more difficult It has been suggested that tension in a nerve restricts its blood flow (Lundborg & Rydevik 1973), causes internal haemorrhaging in the nerve (Terzis et al 1975), and may be implicated in the production of a fibroblastic response (Millesi et al 19 2). These arguments have been used to promote the concept of nerve grafting

The mechanical properties that govern the tension produced by repair are stiffness (the tension required to increase the length of the nerve) and creep (the relaxation of the tension of the nerve at a constant length) Previous investigations have concentrated on stiffness although this has often been measured at a slow rate which would have allowed creep to influence the results. Non-linear elastic behaviour has been reported in both animal and human material (Millesi et al. 1972, Sunderland & Bradley 1961, a, b, c) in that the tension required to increment the length of the nerve is not proportional to the increase in length These nerves were shown to offer an increasing resistance to stretch Some workers have attempted to find the limit of elongation beyond which irreversible changes occur in the mechanical properties (Haftek 1970) In at least one study the elongation produced by a nerve repair has been related to the electrophysiological properties of the nerve after healing (Terzis et al 1975)

In order to establish the magnitude of tensions developing in nerve repair we have measured the mechanical properties of rat sciatic nerves with reference to three factors

1 Stiffness
2 Creep behaviour
3 The relative contribution to the mechanical properties of the exposed section of nerve and of the proximal and distal attachments.

0001 0.79/060721–05$02.50.0

© 1979 Munksgaard, Copenhagen

Figure 1 Arrangement of the apparatus for testing the properties of the proximal nerve section

MATERIALS AND METHODS

Ten domestic white rats of 0.2 kg body weight were investigated. Under intraperitoneal avertin anaesthesia they were taped securely to a wooden block clamped to a bench. About 20 mm of the right sciatic nerve was exposed and freed of mesoneurial attachment from pelvis to knee. The nerve was divided sharply at mid thigh level and proximal and distal segments were tested separately.

The end of the divided nerve was attached to a tension/displacement transducer (Figure 1) by a lightly tied suture passed through the nerve 2 mm from the cut surface. The transducer was clamped to the bench in a position which allowed the suture to pull the nerve close to its correct anatomical line. The transducer could then be manipulated to alter the tension in the divided nerve. Electrical signals from the transducer corresponding to tension and elongation were recorded for subsequent analysis. Stainless steel sutures (size 6–0) were used in these experiments because pilot studies had indicated that nylon sutures had mechanical properties comparable with those of the nerve under investigation. Finally a 20 mm length of nerve was exposed, held rigidly at one end and the length was then tested in a similar way to the proximal and distal sections. During all experiments the nerves were irrigated regularly with normal saline.

In the three tests (proximal, distal and isolated sections of nerve) the following procedure was employed:

1. The nerve was stretched rapidly (within 5 seconds) until the tension was 30 g and then released back to zero tension. This was repeated and an oscilloscope display of the tension and elongation used to check for repeatable stiffness characteristics.
2. The nerve was stretched to a tension of [illegible] and left at this elongation for 30 minutes; tension was recorded over this time to investigate the tension-relaxation behaviour (creep).
3. The stiffness characteristic was recorded again as in the first test. A tension of [illegible] used in the experiments since this responds to the tension involved in repairing severe nerve deficit of several millimetres.

Finally, the stiffness tests were performed on the suture material used in the experiments. This gave the combined stiffness of the suture and tension transducer which could then be subtracted from the measured stiffness of the nerves (Figure 2). Creep tests on the suture and transducer combination showed no measurable tension relaxation over the time scale of the tests.

Construction of the Tension/Displacement Transducer

The tension transducer consisted of a [illegible] length of clock spring with a pair of electrical resistance strain gauges bonded to its surface. Suture was connected to one end of the [illegible] perpendicular to its length and the other end of the clock spring attached to a displacement transducer, an electrical micrometer (Figure [illegible]). Tension in the suture set up bending stresses in the clock spring which produced resistance changes in the strain gauges. These resistance changes were detected by a strain gauge amplifier which converted them into a voltage proportional to suture tension.

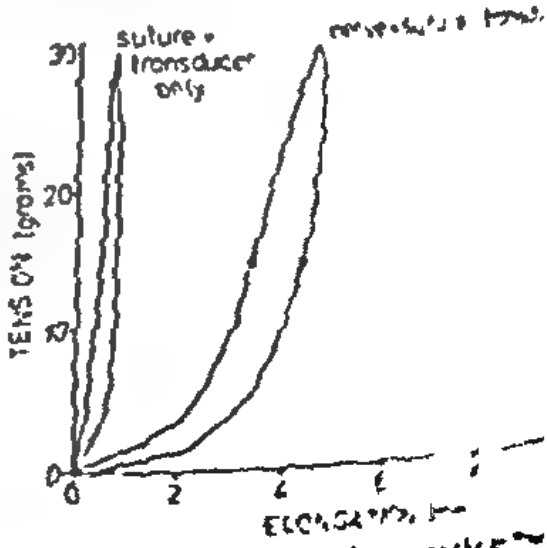

Figure 2 Recordings used to determine the stiffness of a proximal nerve section. [illegible] from the other gives the stiffness of the nerve section alone

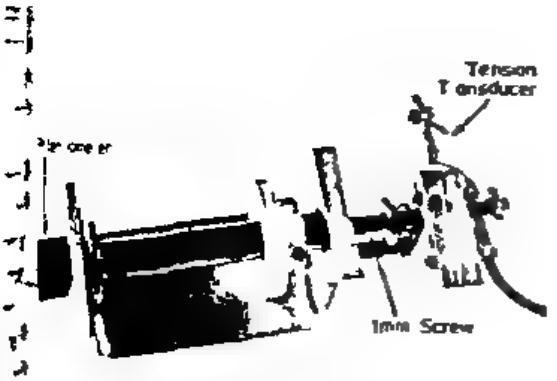

Figure 3 The tension transducer attached to the electrical micrometer

The electrical micrometer used a 1 mm pitch screw mounted in ball bearings A block sliding on a guide rod was fixed to a nut on this screw and the tension transducer was mounted on this block A ten turn potentiometer coupled to the end of the screw was used to determine the position of the block

RESULTS

Stiffness measurements

Graphs of tension against elongation for the ten animals are shown in Figure 4 Three features are apparent

1 All three portions of the nerve have a non linear response to stretching becoming increasingly stiff with increased elongation The difference in the curves for increasing and decreasing tension are due to hysteresis (energy absorption during stretching) Repeated cycling of stretching and relaxation gave similar results

2 The proximal nerve segment was stiffer than the distal segment and the isolated section stiffer than both

3 The shape of the stiffness graph was not significantly altered after tension–relaxation tests at 30 g initial tension However the results showed increases in nerve length at zero tension following the creep tests (Table 1)

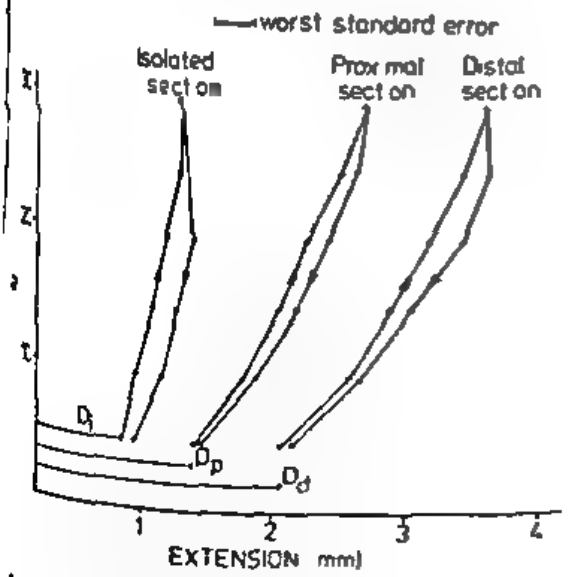

Figure 4 Stiffnesses of the three nerve sections tested. The curves show mean results from the ten animals and the D values give an estimate of the extension produced by 5 g tension

Table 1 Length increases after creep test for the three nerve sections

	Mean length increase after creep test mm (see in brackets)
proximal section	0 6 (0 2)
distal section	0 9 (0 4)
isolated section	0 4 (0 2)

Attempts to find the ultimate strength (rupture tension) of the nerves were frustrated by the suture cutting out of the nerve In one successful experiment a rupture tension of 200 g was measured

Tension–relaxation (creep) measurements

These experiments were intended to simulate the mechanical circumstances of the

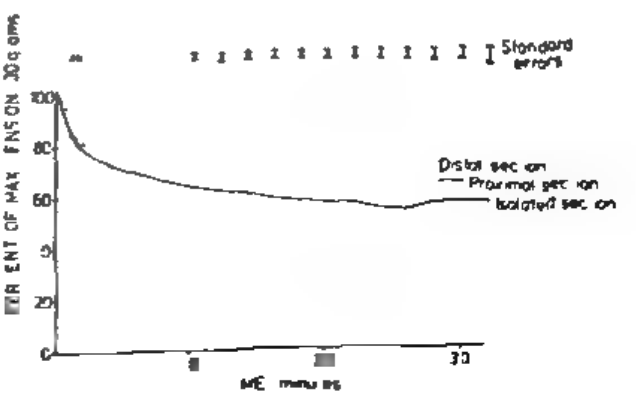

Figure 5 Creep properties of the three nerve sections tested (mean results from ten animals)

nerve after repair under tension. Graphs showing the decay of tension over time are shown in Figure 5. This tension was initially 30 g and fell to about 20 g after 10 minutes. There was a further small reduction in the following 20 minutes. Comparison of the creep results from the three sections tested showed significant differences. The isolated sections displayed the most creep and the distal sections the least.

DISCUSSION

Our results agree with those who found increasing stiffness of peripheral nerves with elongation and that a nerve creeps to reduce applied tension. In our experimental conditions most tension–relaxation occurs in the first 10 minutes following the application of a tension. The total reduction in tension is of the order of 30 per cent. Although from our results it appears that at 30 minutes the rate of creep is close to zero and falling, it is possible that creep continues at a low rate beyond the limit of our measurement leading to a much greater reduction in tension. It is possible that such long term creep does occur as an adaptive response enabling nerves to grow in response to tension. However, experimental work on dogs (Highet & Saunders 1943) failed to demonstrate any such long term increase in nerve length.

The question of what tension is required to damage a nerve is a source of controversy. Liu et al. (1948) claimed that the perineurium was destroyed by an elongation of 6 per cent while Hoen & Brackett (1956) found little evidence of damage with a permanent elongation of 100 per cent. These widely disparate figures probably relate to whether the nerve was measured against its retracted length, its original length, or the length at which a measurable tension was taken up. Many investigations have shown that little tension is required to stretch the nerve in the first phase of elongation. We believe that measuring tension rather than elongation is a more accurate and rep[illegible] method.

It was found that a sustained tension of 30 g produces an elongation of [illegible] per cent in the nerve and an increase in length [illegible] zero tension of 2–5 per cent. This deformation had no significant effect on the [illegible] characteristic. It is possible that creep [illegible] tension is the result of a process such as [illegible] expulsion which can reverse over a period [illegible] time after tension is removed.

The isolated nerve section was stiffer [illegible] the proximal end which in turn was [illegible] than the distal end. The same order [illegible] maintained for creep results, the isolated section creeping most and the distal [illegible] least. Since similar lengths of nerve were involved in each case these results are consistent with the nerve having crept to a [illegible] increase in length rather than reduced tension. Comparison of the stiffness results for the isolated section and proximal and distal ends indicates that about half of the elongation of the proximal and distal [illegible] comes from the exposed length of the nerve, the remainder being in the unexposed [illegible] and its attachments.

REFERENCES

Haftek, J. (1970) Stretch injury of peripheral nerve. Acute effects of stretching rabbit [illegible]. *J. Bone Jt. Surg.* 52-B, 354–365.

Highet, W. B. & Saunders, F. A. (1943) The effects of stretching nerves of [illegible]. *Surg.* 30, 355–369.

Hoen, T. I. & Brackett, C. E. (1956) [illegible] nerve lengthening. I. Experimental. *Neurosurg.* 13, 43–62.

Liu, C. T., Benda, L. E. & Saunders, F. H. (1948) Tensile strength of human nerves. *J. Neurol. Psychiat.* 39, 322–335.

Lundborg, G. & Rydevik, B. (1973) Effects of stretching the tibial nerve of the rabbit. A preliminary study of the intraneural circulation and the barrier function of the perineurium. *Bone Jt. Surg.* 55-B, 390–401.

Millesi, H., Berger, A. & Meek, G. (1[illegible]) [illegible] experimentelle Untersuchungen zur [illegible] durchtrennter peripherer Nerven. *Plastica (Berl.)* 1, 1[illegible]–[illegible].

Sunderland, S. & Bradley, K. C. (1961) Stress-strain phenomena in human peripheral nerve trunks. *Brain* 84, 102–119.

derland, S & Bradley K. C. (1961b) Stress strain phenomena in human spinal nerve roots. *Brain* 84, 120–124

derland, S. & Bradley K. C. (1961c) Stress strain phenomena in denervated peripheral trunks. *Brain* 84, 125–127

Terzis, J., Faibisoff B. S. The nerve gap [illegible] *Plast Reconstr Sur* [illegible]

rrespondence R. A. Dickson, Ch.M., F.R.C.S. Nuffield Department of Orthopaedic Surgery ld Orthopaedic Centre Headington, Oxford OX3 7LD England

percentile). She was initially seen in October 1975, aged 10 years, with pain in the right elbow after a fall 10 days previously. Radiographs showed O.D. of the capitellum. Her symptoms subsided and she was discharged in September 1976. She was referred to Orthopaedic Out-patients in August 1977, this time [illegible] and [illegible] O.D. [illegible] the medial femoral condyle of both knees. There were no symptoms associated with the right knee. Apart from her height and weight, there were no other abnormal findings. Her periods had started at the age of 11 years and breast development was normal. All the investigations listed under AG were carried out and found to be normal.

Case 3

MG was a 39-year-old female (138 cm in height and weighing 68.2 kg) she presented in 1974 with symptoms of bilateral carpal tunnel syndrome and surgical decompression was carried out. In November 1977, she returned with pain and increasing stiffness of the right elbow. She had a history of pain in both knees when in her teens and at that time her family doctor diagnosed Osgood Schlatter's disease. Her knee symptoms had subsided spontaneously. Radiographs [illegible] O.D. of both elbows with loose body fr[illegible] and mild osteoarthrosis (Figure 1). Although typical defects of O.D. were absent fr[illegible] knees, there were changes of osteoarthr[illegible] both knee joints, mainly affecting the p[illegible] femoral compartment. Radiographs of th[illegible] joints were normal but there was coes[illegible] irregularity and increased density aro[illegible] lower lumbar vertebrae and early calc[illegible] the spinal ligaments. Further investi[illegible] including biochemical, chromosomal and br[illegible] studies, as for Cases 1 and 2, reveal[illegible] abnormality. Her husband declined to a[illegible] interview but he was said to have no ye[illegible] plaints.

The relatives of MG were scattered th[illegible] the country, a questionnaire was sent t[illegible] surviving nine of MG's ten siblings (one [illegible] eight female, age range 27–50 years). All w[illegible] normal height and weight and of the seve[illegible] replied four complained of pain and or st[illegible] affecting either the knees or elbows. Radio[illegible] were obtained from only one of the [illegible] symptomatic siblings and these were no[illegible] radiographs were obtained from only one o[illegible] three asymptomatic siblings and these were [illegible] normal (Figure 2). Two of the siblings [illegible] female had had surgery for carpal t[illegible] syndrome (one bilateral, one unilateral) and [illegible] others (both female) had symptoms typical o[illegible] condition (Figure 2).

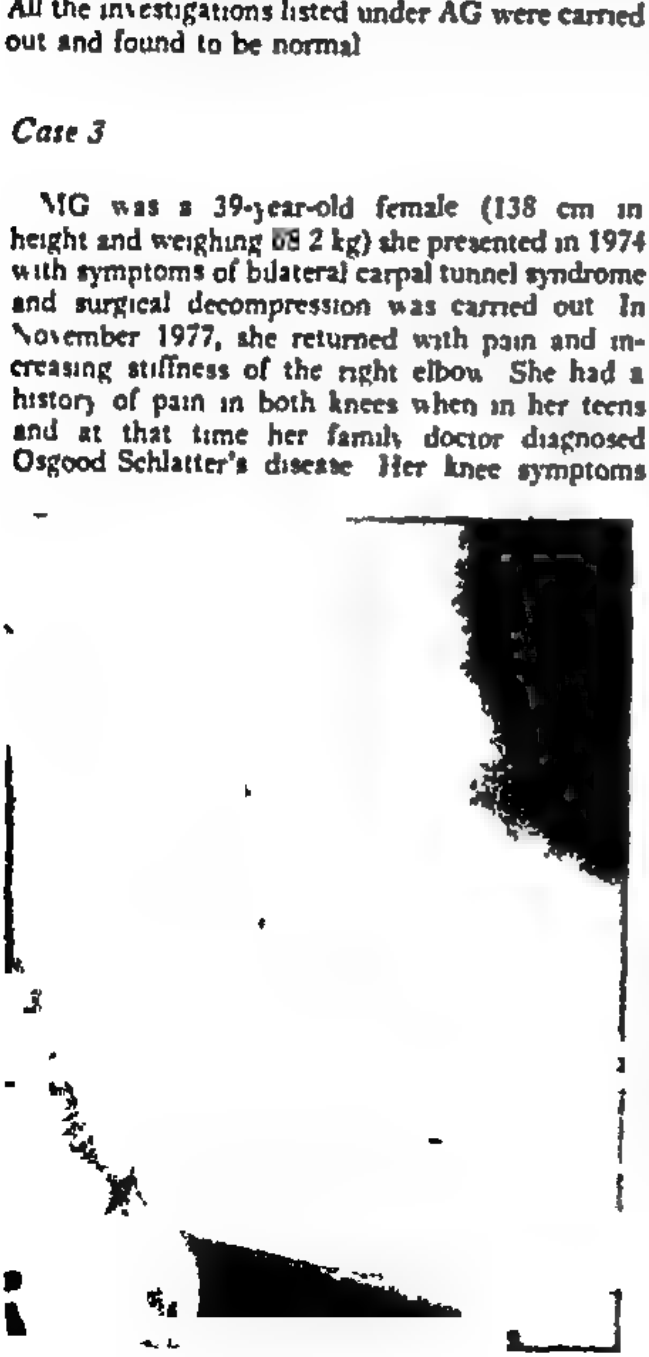

Figure 1. Osteochondritis dissecans of the right elbow in patient MG.

DISCUSSION

This family consisting of mother and [illegible] children all had O.D. affecting the capit[illegible] In addition, the daughter was shown to h[illegible] O.D. affecting both knees, and the wo[illegible] of one knee. The mother had osteoarth[illegible] of both knees but no obvious radiog[illegible] evidence of old O.D. of the medial fe[illegible] condyles. It is likely that the members of [illegible] family fall into the category of juve[illegible] teochondritis in which the lesions are o[illegible] multiple and the condition may be fa[illegible] (Smith 1960). Smith believes that there [illegible] dysostotic constitutional background o[illegible] families leading to the development of [illegible] accessory ossification centre which [illegible] susceptible to trauma (Smith 1960).

White described three cases of [illegible] were of short stature and in whom there [illegible] evidence of endocrine imbalance (19[illegible]

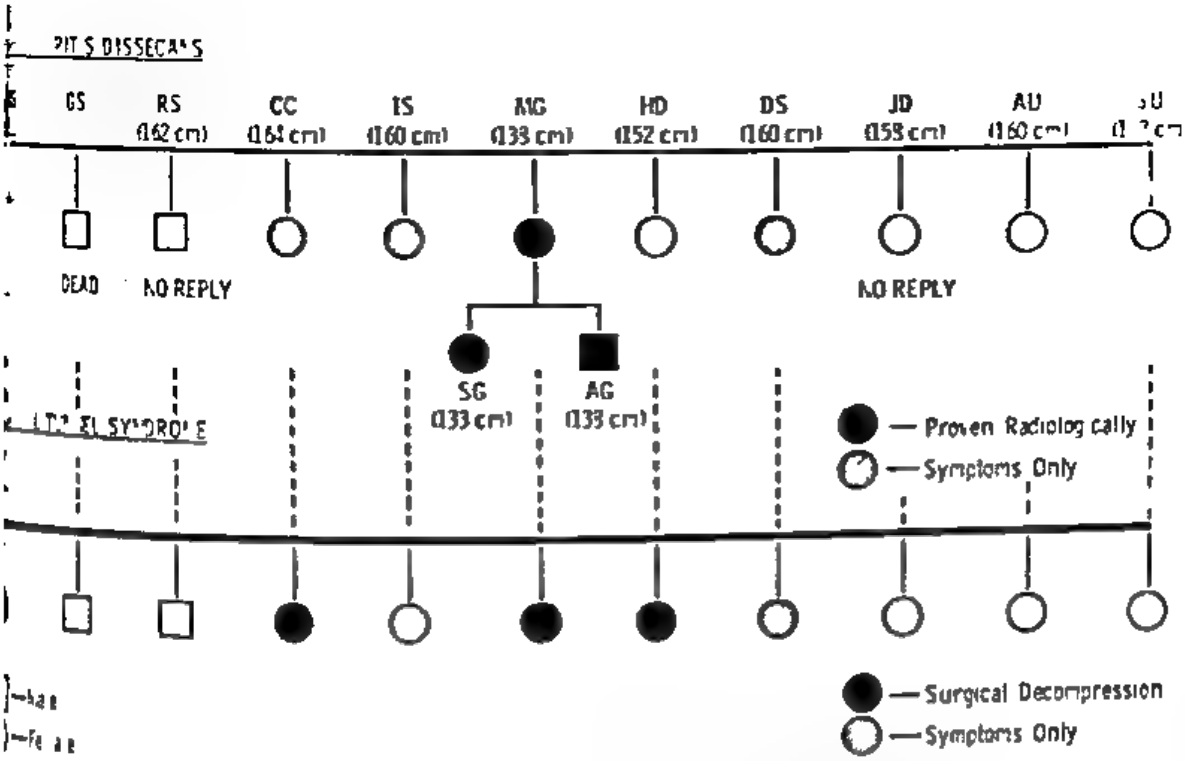

Figure 2 Familial incidence of osteochondritis dissecans and carpal tunnel syndrome

) Hanley described two brothers affected the condition who also demonstrated developmental abnormalities and sted that endocrine factors might play a he aetiology (Hanley et al 1967) he association with short stature was d by Pick in a family who were normally developed, although no rine investigations were carried out 1955) None of the endocrine ties reported by others were found e patients reported here It is likely that condition is incidental to some un- rained hereditary disturbance of hyseal growth as suggested by Smillie 0), although bone development was in all three patients as measured by Tanner-Whitehouse index. Apart from members of this family, four of the er's siblings complained of pain or ess of elbows or knees. Radiographs obtained in only one case and were The siblings were of normal height weight.

Figure 3 Radiograph of the left radio-carpal joint in patient MG

Carpal tunnel syndrome was noted in the mother and four of her siblings. Tanzer described four cases of carpal tunnel syndrome, each of whom had one affected parent, in one case, a grandparent was also affected (Tanzer 1959) A familial incidence has been noted by others (Zabriskie et al 1935, Stephens & Welch 1956, Phalen & Kendrick 1957)

Both O D and carpal tunnel syndrome are well recognised entities but the aetiology of these conditions is uncertain Although both may be associated with an underlying anatomical abnormality, subsequently susceptible to trauma, there was no radiological abnormality of the radio-carpal joint in one such patient (MG) (Figure 3) Whether the two conditions are coincidental in members of this family or not is uncertain but it is possible that a common constitutional factor may increase the possibility of their development

ACKNOWLEDGEMENTS

We would like to thank Mr A Adam, Consultant Orthopaedic Surgeon for his help in the preparation of this manuscript

REFERENCES

Hanley, W B., McKusick, V A. & Barnes, [illegible] (1967) Osteochondritis dissecans with bone malformations in two brothers. *J Bone Jt S[illegible]* 49 A, 925–937

Phalen, G S & Kendrick, J I (1957) Compression neuropathy of the median nerve in carpal tunnel. *J Amer med Ass* 524–530

Pick M P (1955) Familial osteochondritis dissecans. *J Bone Jt Surg* 37 B 142 14[illegible]

Smillie, I S (1960) *Osteochondritis dissecans loose bodies in joints Aetiology p[illegible] treatment* p 30 E. S Livingstone Edinburgh

Smith A D (1960) Osteochondritis of the joint *J Bone Jt Surg* 42 A, 2[illegible] 2[illegible]

Stephens, J & Welch, K. (1956) Aetiography A symptom of median nerve compression at the wrist *Arch Surg* 73, 849 85[illegible]

Stougaard J (1964) Familial recurrence osteochondritis dissecans, *J Bone Jt Surg* 542–543

Tanzer R C. (1959) The carpal tunnel syndrome *J Bone Jt Surg* 41-A 626–634

White J (1957) Osteochondritis dissecans association with dwarfism. *J Bone Jt S[illegible]* 39-B 261–267

Zabriskie, E. G Hare C. C. & Wasserman (1935) Hypertrophic arthritis of cervical vertebrae with thenar muscular atrophy in sisters. *Bull neurol Inst* [illegible]

Correspondence to Dr C D Auld, Department of Surgery, Medical Buildings, Forresterhill, Aberdeen.

scand. 50, 731–739 1979

?IODELLING AFTER DISTAL FOREARM FRACTURES CHILDREN

?e Final Orientation of the Distal and Proximal Epiphyseal Plates of the Radius

AL FRIBERG

ment of Orthopaedic Surgery, University of Umeå, Umeå, Sweden

In 39 children the steric orientation of both the distal and the proximal epiphyseal plates of the radius was evaluated 4 months to 10 years after distal forearm fractures that had healed with residual angulation

[illegible] was found to induce a change in orienta-

[illegible]

overcorrection

In two of the four cases with a primary angulation exceeding 20 degrees considerable normalization occurred, but a "normal" state was not reached. This indicates an upper limit for angulations permitting normalization of the orientation of the distal epiphyseal plate of the radius.

Key words children, epiphyses, forearm, fracture growth, remodelling

Accepted 3 m 79

is recently been demonstrated that the yseal plates participate in the total delling procedure after diaphyseal ures of the long bones. In experimental es on the tibia of the rat and dog py & Karaharju (1974) and Karaharju et 976) found that both the distal and the mal epiphyseal plates changed their ions of growth after mid-diaphyseal ures that had healed with residual ation In children, Friberg (1974, 1979) nstrated that after a distal forearm re the distal epiphyseal plate of the shows a tendency towards spontaneous ation of its normal orientation

r present knowledge of the behaviour of piphyseal plates after fracture healing residual angulation can be summarized lows. Residual angulation will induce a nbution of growth at the epiphyseal (Ryöppy & Karaharju 1974) The redistribution of growth will subsequently lead to the normalization of an abnormal inclination of the epiphyseal plate The rate of the normalization is independent of the age of the child and of the distance between the fracture and the epiphyseal plate, whereas the degree and direction of the primary angulation influences the rate of the correction The reduction in abnormal inclination follows an exponential course (Friberg 1979) However, the final orientation of the epiphyseal plate after completion of the process of normalization has not yet been established Furthermore, the maximum primary angulation still resulting in the complete normalization of an abnormal epiphyseal inclination is unknown

The capacity of the epiphyseal plates to bring about spontaneous normalization of an abnormal inclination is important as it leads to a normalization of the inclination of the

1'0/79/060731 09$02 50/0

© 1979 Munksgaard Copenhagen

adjacent joint surface In addition, it is probably of direct interest with regard to the correction of a residual fracture angulation since a normalization of the inclination combined with longitudinal growth at the plate must automatically reduce any abnormal inclination of the diaphyseal part of a bone (Friberg 1979).

In the present study an investigation was made of the spatial orientation of the distal and proximal epiphyseal plates of the radius after distal forearm fractures that had healed with residual angulation The aim was to investigate the final orientation of the epiphyseal plate after completion of the process of normalization

MATERIAL AND METHODS

The inclination of the distal and proximal epiphyseal plates of the radius was studied in 39 children with residual angulation of the fracture at the time of healing All fractures were located in the distal fifth of the forearm. The patients were selected from all cases of distal forearm fractures treated in the Department of Orthopaedic Surgery at Umeå during 1965–1973 The selection was made so as to obtain a representative series with regard to ages, observation times and degrees of angulation

The radiographs taken at the time of healing of the fracture were used as a basis for the selection At re-examination, radiographs with frontal and lateral views of both the fractured and the contralateral wrists and forearms were obtained In 12 cases both epiphyseal plates of the radius were closed at the follow-up examination

Forty observations were made In [illegible] observations the fractures had an angulation visible in the dorso-volar plane (lateral view) Twenty five of these were dislocated in the dorsal direction and nine in the volar direction In the radio-ulnar plane (frontal view) four had an abnormal inclination in the radial direction two in the ulnar direction. A concomitant fracture occurred in none of the cases Further details of the characteristics of the material are given in Table 1

Radiographic technique

The radiographic technique used in this investigation was identical with that previously described by Friberg (1979).

Measuring technique

The *primary angulation* of the distal epiphyseal plate at the time of healing of the fracture was defined as the angle between the epiphyseal plate and a plane oriented 90 degrees to the axis of the distal third of the radius.

The measurements pertaining to the follow-up examination were performed on [illegible]

Table 1 Distribution in the series of the variables used for the statistical analysis of the [illegible] Means and standard deviations are indicated where not otherwise stated Total number of observations = 40

Age at fracture, years months (range)	9.8 ± 3.5 (2.5 – 16 4)	*Primary angulation of* the epiphyseal plate degrees	12.4 ± 4.1
Sex no. of boys girls	19 21	Type of fracture	
Side, no. of right left	19 21	No. of Torus	12
Observation time years months (range)	4.5 ± 3.9 (0 4 – 11.0)	Greenstick	14
Corrected observation time* years months (range)	3.6 ± 3 2 (0 4 – 10 8)	Complete	14
		Distance of fracture from the distal epiphyseal plate millimetres (range)	1.2 ± 1.* (0 – [illegible])

* Corrected observation time in the 12 cases with closed epiphyseal plates at follow-up the time of healing of the fracture [illegible] completion of longitudinal growth at the distal epiphyseal plate of radius (boys 16 and girls 15 years of age (cf Marsh 1955, Kothari 1976), in the remaining cases radiographically normal epiphyseal plates, the actual period of observation

gs of the radiographs as illustrated in 1 and were all expressed as a difference n the normal and fractured side The prox- alf of the diaphysis up to the proximal hyseal area of the radius was used as a for the superimposition of the raphs. The *final angulation* of the distal roximal epiphyseal plates at the follow-up ation was defined as the difference in in- on between the epiphyseal plates on the l and on the fractured side The *orientation long axis* of the fractured radius was d as the angle between the two lines con- g the midpoints of the proximal and the ep physeal plates on the normal and on the ed side The final angulation of the al epiphyseal plate and the orientation of the long axis were only measured in fractures showing angulation in the dorso-volar plane Two of these observations had to be excluded due to technically inadequate X-ray films.

The total error of the measuring procedures was evaluated by repeated measurements by the author and was found to be 0 8 degrees + s.d = 0 3 for the final angulation of the distal epiphyseal plate For the final angulation of the proximal epiphyseal plate the mean error was 0 5 degrees ± s d = 0 4, and for the orientation of the long axis of the bone the figure was 0 2 degrees ± s.d = 0 5

Statistics

The means and standard deviations are given Standard computer programs were used for the



e 1 The primary angulation of the distal epiphyseal plate of the radius in a boy aged 5 years 5 hs at the time of the fracture and the final angulation of the distal and proximal epiphyseal plates he orientation of the long axis of the bone when the boy was 14 years and 9 months old

At the time of healing of the fracture, 21 degrees dorsal inclination of the epiphyseal plate (b, c, Normal and fractured wrist and normal and fractured forearm at the follow-up examination Superimposed drawings of b–e, the distal epiphyseal plate shows an overcorrection of 2 degrees the proximal epiphyseal plate and the total long axis of the fractured bone have changed their tation by 1 degree

–Final angulation of the distal epiphyseal plate V_2=Final angulation of the proximal epiphyseal . V_3=Orientation of the long axis of the fractured bone R=Part of the radius used for reference when mposing the forearm films

adjacent joint surface. In addition, it is probably of direct interest with regard to the correction of a residual fracture angulation since a normalization of the inclination combined with longitudinal growth at the plate must automatically reduce any abnormal inclination of the diaphyseal part of a bone (Friberg 1979)

In the present study an investigation was made of the spatial orientation of the distal and proximal epiphyseal plates of the radius after distal forearm fractures that had healed with residual angulation The aim was to investigate the final orientation of the epiphyseal plate after completion of the process of normalization

MATERIAL AND METHODS

The inclination of the distal and proximal epiphyseal plates of the radius was studied in 39 children with residual angulation of the fracture at the time of healing All fractures were located in the distal fifth of the forearm. The patients were selected from all cases of distal forearm fractures treated in the Department of Orthopaedic Surgery at Umeå during 1965–1973 The selection was made so as to obtain a representative series with regard to ages, observation times and degrees of angulation.

The radiographs taken at the time of healing the fracture were used as a basis for the eva tion. At re-examination, radiographs with fro and lateral views of both the fractured and no contralateral wrists and forearms were obtai In 12 cases both epiphyseal plates of the ra were closed at the follow-up examination.

Forty observations were made. In observations the fractures had an inclinat visible in the dorso-volar plane (lateral vie Twenty five of these were dislocated in the do direction and nine in the volar direction. In radio-ulnar plane (frontal view) four had abnormal inclination in the radial direction two in the ulnar direction. A concomitant ul fracture occurred in nine of the cases. Furt details of the characteristics of the material given in Table 1

Radiographic technique

The radiographic technique used in this vestigation was identical with the previou described by Friberg (1979)

Measuring technique

The *primary angulation* of the distal epiphys plate at the time of healing of the fracture w defined as the angle between the epiphyseal pl and a plane oriented 90 degrees to the axis of t distal third of the radius.

The measurements pertaining to the follow- examination were performed on superimpos

Table 1 Distribution in the series of the variables used for the statistical analysis of the resu Means and standard deviations are indicated where not otherwise stated Total number observations = 40

Age at fracture years months (range)	9 8 ± 3.5 (2 5 – 16 4)	Primary angulation of the epiphyseal plate degrees	12.4 ± 6.5
Sex, no of boys/girls	19/21	Type of fracture	
Side no of right/left	19/21	No. of Torus	12
Observation time, years months (range)	4 5 ± 3 9 (0 4 – 11·0)	Greenstick	14
		Complete	14
Corrected observation time* years months (range)	3 6 + 3.2 (0 4 – 10 8)	Distance of fracture from the distal epiphyseal plate millimetres (range)	16.2 + 6.* (6 – 29)

* Corrected observation time in the 12 cases with closed epiphyseal plates at follow-up, the time fro healing of the fracture to expected completion of longitudinal growth at the distal epiphyseal plate of th radius [boys 16 and girls 15 years of age (cf Maresh 1955 Kothari 1974)]. In the remaining cases wi radiographically normal epiphyseal plates, the actual period of observation.

dorsal direction, are not included in the wing analysis of the results noted at the l plate

final angulation At follow-up the cases 22) with a primary angulation in the al direction had a final angulation of the hyseal plate of 0 5 degrees ± 2 8 The l angulation in the cases with a primary ation in the volar direction showed a t overcorrection of the epiphyseal plate nting to −1 2 degrees ± 1 4 ($n = 9$) The inclination for primary angulations in radial direction was 0 degrees ± 0 ($n = 4$) for angulations in the ulnar direction 0 rees ± ($n = 2$) No influence (χ^2 analysis) of different directions of the primary angula- on the final angulation of the plate was nd. For this analysis the cases with a mary angulation in the radial and ulnar ction were combined into one group It was shown that a concomitant distal ulnar cture ($n = 9$) had no influence (Student's *t*-t) on the final angulation of the plate

uence of different variables on the final gulation The final angulation of the physeal plate ($n = 37$) was tested to termine the effect of the different variables ed for classification of the material (Table The methods used were bivariate correla- on analyses and stepwise regression alysis Only significant relations between e dependent and independent variables are ven.

The correlation analyses showed that a ger primary angulation of the plate P 0 032, corr coeff = 0 31) resulted in a ger final angulation However, when the o cases with a final angulation of 7 and 10 grees, respectively, were excluded the same alysis showed the reverse relationship in e 35 remaining cases A larger primary gulation ($P = 0\ 034$, corr coeff = −0 31) den resulted in a more pronounced rcorrection In this part of the material it was further found that an increase in rrected observation time resulted P 0 020 corr coeff = −0 35) in a more pronounced overcorrection of the epiphyseal plate The orientation of the epiphyseal plate in the 19 cases with a corrected observation time under 2 years was an overcorrection of −0 05 degrees ± 0 40 In the 16 cases with longer observation times this overcorrection had increased to 1 00 degree ± 1 63

According to the stepwise regression analysis none of the variables had any influence on the final angulation of the distal radial epiphyseal plate

In conclusion, the statistical analysis showed that large primary angulations resulted in less complete normalization of the epiphyseal plate When the two cases with large primary angulations and a lack of normalization were excluded, increased observation times and larger primary angulations resulted in a more pronounced overcorrection of the plate

The final angulation in relation to the orientation of the long axis of the bone The cases with a primary angulation in the dorso-volar plane ($n = 29$) were analysed in relation to the orientation of the long axis of the radius by the statistical methods described above The general finding was that the epiphyseal plate on the fractured side was overcorrected 1 3 degrees ± 2 0 in relation to the long axis of the bone The correlation analyses showed that the orientation of the long axis of the fractured radius was highly significantly ($P = 0\ 00001$, corr coeff = 0 79) correlated with the final angulation of the epiphyseal plate When the two cases with inadequate normalization were excluded, the relationship between the two variables was weaker ($P = 0\ 046$, corr coeff = 0 33) (Figure 3) Stepwise regression analysis confirmed the intercorrelation between the two variables

Prediction of the time needed for full correction In a previous study the following exponential formula was suggested for estimating the time needed for adequate correction of the epiphyseal plate

$$t = \frac{\ln (V_o/2)}{\beta}$$

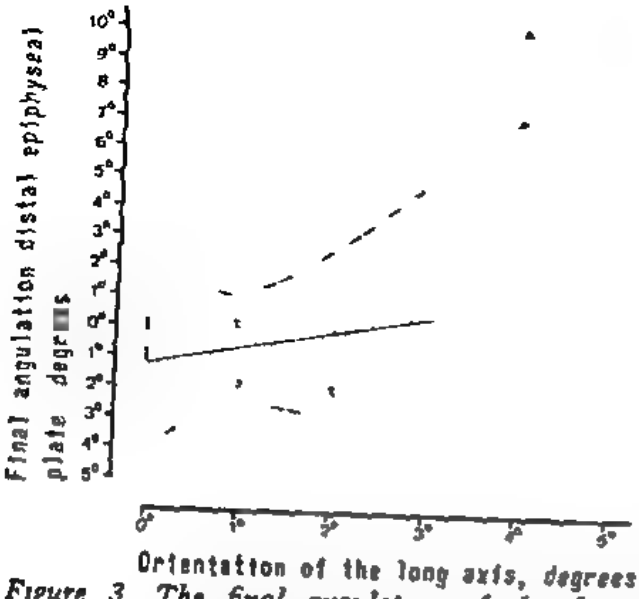

Figure 3 The final angulation of the distal epiphyseal plate in relation to the orientation of the long axis of the bone The linear regression line and 95 per cent confidence intervals are given A minus sign signifies overcorrection The two cases with inadequate correction are indicated in the figure (▲), but are not included in the statistics

This formula was applied to the 19 cases with an observation time of less than 2 years using the mean values of β for each direction of angulation (Friberg 1979) When the time calculated from the formula was compared with the corrected observation time, it was found that the "normal" position was reached 2 4 months ± 5 5 before the mean time predicted by the formula

The proximal radial epiphyseal plate

The two patients aged 16 years with closed epiphyseal plates at the time of the fracture are not included in the analyses of the results obtained at the proximal epiphyseal plate In 16 of the 30 remaining observations a change in inclination was observed The change in inclination of the proximal epiphyseal plate was without exception in the same direction as that of the distal epiphyseal plate, e g a fracture with a primary angulation in the dorsal direction resulted in a reorientation of both the distal and proximal epiphyseal plates in a volar direction

The final angulation For a primary angulation at the fracture site in the dorsal direction ($n = 23$) a volar inclination of th amounting to 1 2 degrees ± 1 5 was f volar angulation at the fracture site resulted in an inclination in the direction of 2 3 degrees ± 0 8 No dif (χ^2 analysis) existed between the res the two directions of primary angulatio

Influence of the different variables final angulation The influence variables used for classification material ($n = 30$) on the final angula the proximal epiphyseal plate was ar by bivariate correlation, and stepwise sion analysis Only significant re between the dependent and indep variables are indicated

The correlation analyses showed th increase in the primary angulation ($P =$ corr coeff $= 0\ 48$) and an increase i distance between the fracture and the epiphyseal plate ($P = 0\ 008$ coeff $= 0\ 44$) increased the amount of c tion found at the proximal epiphyseal In addition, a more complete fracture res in an increased correction ($P = 0\ 0002$, coeff $= 0\ 60$) In this context it mus noted that a more complete fracture was significantly correlated with an incre primary angulation ($P = 0\ 01$) and with increase in the distance between the frac and the distal epiphyseal plate ($P = 0\ 003$)

The stepwise regression analysis on other hand showed that the type of frac was the only variable that significa ($P < 0\ 001$) influenced the results.

To sum up the statistical analysis show that the type of fracture exerted the m influence on the final angulation. Howe the type of fracture was also closely related the primary angulation and the distan between the fracture and the distal epiphys plate, variables which in turn had a stro influence on the results.

The final angulation in relation to t orientation of the long axis of the bone T final angulation of the proximal epiphys plate of the radius was very closely correla ($P = 0\ 00001$, corr coeff $= 0\ 80$) with t

ation of the long axis of the bone 30) In fact, the proximal epiphyseal almost completely normalized its ation in relation to the long axis of the (Figure 4) The results of a stepwise

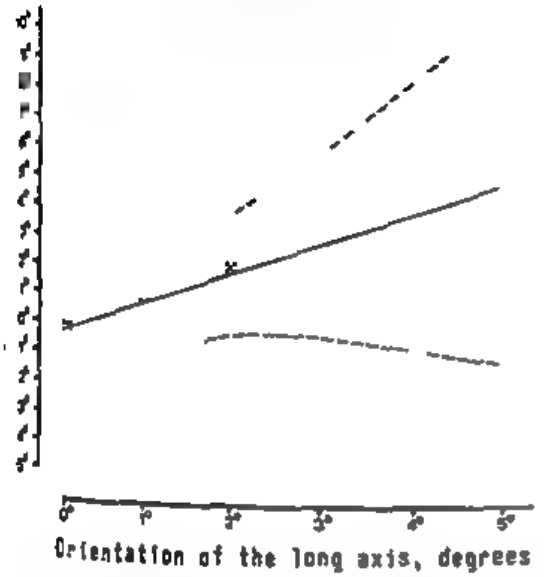

e 4 The final angulation of the proximal ysical plate in relation to the orientation of long axis of the bone The linear regression and 95 per cent confidence intervals are A minus sign signifies overcorrection

ession analysis, also including the ables used for classification of the erial, confirmed that the change in ntation of the long axis of the bone was variable which had the greatest influence he final angulation of the plate

separate regression analysis was ormed to study the relations between the ntation of the long axis and the variables d for classification of the material This wed that the distance between the fracture the epiphyseal plate ($P < 0.001$) and the nary angulation ($P = 0.015$) were the only variables which influenced the orienta- of the long axis of the radius.

SCUSSION

final spatial orientation of the distal and proximal epiphyseal plates of the radius was investigated in children after distal forearm fractures that had healed with residual angulation

The result was that in the majority of the cases the epiphyseal plates of the radius had normalized their inclinations in relation to the long axis of the fractured bone This confirms that the epiphyseal plates react with a redistribution of growth after fracture healing with residual angulation (Friberg 1974, 1979, Ryoppy & Karaharju 1974, Karaharju et al 1976) Furthermore, it shows that this process in the forearm is capable of restoring an almost normal orientation of the epiphyseal plates.

An exception to this general finding was noted in two of the four cases with a primary inclination of more than 20 degrees. In these two cases the normalization of the orientation of the epiphyseal plate was incomplete This suggests that an upper limit exists for the normalization process. The number of observations is of course too small to permit any definite conclusions, but until proven otherwise, one cannot assume that complete normalization will take place after a distal forearm fracture healing with a primary angulation of more than 20 degrees This view is also supported by the results obtained from studies of the correction of residual fracture angulations Nonnemann (1969) ascertained as a general rule an upper limit of 30 degrees for adequate correction Buch et al (1966) concluded that angulations of more than 20 degrees should not be tolerated in a distal radial fracture, as the correction in these cases was incomplete

When the two cases with incomplete normalization were excluded, the analyses of the orientation of the distal epiphyseal plate of the radius showed that in the patients with an observation period of less than 2 years an almost complete normalization of the inclination of the plate had occurred However, the orientation found during the two first years was, in reality not the "final position" as a longer period of observation showed a slight

but significant overcorrection of the plate The orientation of the plate was further influenced by the primary angulation in the sense that a larger primary angulation increased the amount of overcorrection achieved This tendency towards an overcorrection is of importance because as growth proceeds in the epiphyseal plate, it results in an automatic reduction of the remaining adaxial displacement of the distal epiphyseal plate and thus must enhance the automatic reduction of angulations at the fracture site produced by longitudinal growth

The finding that a substantial increase in the observation time resulted in an overcorrection supported the view that the course of the process of normalization of an abnormal epiphyseal inclination can be described by an exponential equation (Friberg 1979) It also indicates that the equation should not be formulated with a completely normal position as the final position of the epiphyseal plate Instead, it suggested that an overcorrection of 1 to 2 degrees should be used

The exponential formula was further tested for accuracy by applying it in those cases where the normal position of the epiphyseal plate could be assumed to have been attained recently (obs time < 2 years) It was found that the formula resulted in a slight overestimation in relation to the actual observation time This safety margin is desirable, however Thus, the present results confirm that the formula is valid for clinical use

The orientation of the distal epiphyseal plate was also found to be closely related to the orientation of the long axis of the fractured bone This indicates that the orientation of the long axis of the bone is of importance for the final orientation of the distal epiphyseal plate and thus indirectly supports the suggestion that a biomechanical factor governs the process of normalization (Ryoppy & Karaharju 1974 Pauwels 1975) Earlier experimental work (Appleton 1934, Haas 1945, Strobino et al 1952 Arkin & Katz 1956, Hinrichsen & Storey 1968 shown that alterations in the directi amplitude of the normal forces acting epiphyseal plate are capable of influe growth in the plate The general resul these experiments show that an increa pressure results in a reduced potential However the duration amplitude of the pressures applied in experiments must be considered to be be the limits normally encountered in skeletal system Pauwels (1975) advocate opposite view and suggested that fractures the epiph physiologi increased growth This theory seems plausible to the present writer mainly bec it is compatible with the results found Ryoppy & Karaharju (1974) and Karahar al (1976)

In their experimental studies of the e of mid-diaphyseal fractures Ryoppy Karaharju (1974) and Karaharju et al (1 showed that both epiphyseal plates of tibia reacted with a change in their direct of growth However, no studies have made of the reaction of an epiphyseal pla a fracture near the other end of the bon the present study the residual angulation a fracture in the distal fifth of the for was found to influence the distribution growth within the proximal epiphyseal p of the radius The redistribution of growt this plate resulted in a change in orienta of the proximal epiphyseal plate in the s direction as that found at the distal pl Similar to the findings at the distal epiphy plate the new orientation of the long axi the bone was found to influence the f orientation of the proximal plate

In conclusion the present study show that both the distal and proximal epiphy plates will normalize their orientations afte distal radial fracture that has healed w residual angulation The orientation fin attained by the epiphyseal plates is clos related to the orientation of the long axis the fractured bone

TERENCES

...on, A. [illegible] (1934) Postural deformities and growth. *Lancet* i, 451–454

...M A. & de Katz J F (1956) The effect of ...ssure on epiphyseal growth. *J Bone Jt* ...rg [illegible] A, 1056–1076

...P., Folschveiller, J & Jenny, G (1966) Über ... Behandlung von 376 Vorderarm-...bruchen bei Kinder *Hefte Unfallheilkl* 89, ...54

...g S. (1974) Spontan korrektion av felställ-...g efter läkning av distala under-...fakturer hos barn Lakarsällskapets ...stamma sammanfattningar, 353, Stockholm.

...g S. (1979) Remodelling after distal forearm ...tures in children I The effect of residual ...lation on the spatial orientation of the ...physeal plates. *Acta orthop scand* 50, ...546

...L. (1945) Retardation of bone growth by ...re loop *J Bone Jt Surg* 27, 25–36

...sen, G J & Storey, E (1968) The effect of ... on bone and bones *Angle Orthodont* 38, ...165

...ju, E O Ryoppy, S A [illegible] Makinen, R J (1976) Remodelling by asymmetrical epiphyseal growth *J Bone Jt Surg* 58-B, 122–126

Kothari, D R (1974) Age of epiphyseal union [illegible] elbow and wrist joints in Marwar region of Rajasthan *J Indian med Ass* 63, 252–256

Maresh, M M (1955) Linear growth of long bones of extremities from infancy through adolescence *Amer J Dis Child* 89, 725–742

Nie, N H, Hull, C H, Jenkins J G Steinbrenner, K & Bent, O N (1975) *Statistical package for the social sciences* 2nd ed McGraw-Hill Co, New York

Nonnemann [illegible] C (1969) Grenzen der spontankorrektur Fehlgeheilter Frakturen bei Jugendlichen *Langenbecks Arch klin Chir* 324, 78–86

Pauwels, F (1975) Eine klinische Beobachtung als Beispiel und Beweis fur funktionelle Anpassung des Knochens durch Langenwachstum *Z Orthop* 113, 1–5

Ryoppy, S & Karaharju E O (1974) Alteration of epiphyseal growth by an experimentally produced angular deformity *Acta orthop scand* 45, 490–498

Strobino, L J, French, G O [illegible] Colonna, P C (1952) The effect of increasing tension on the growth of epiphyseal bone *Surg Gynec Obstet* 95, 694–700

...ondence to K. S I Friberg, M D, Department of Orthopaedic Surgery, University of Umeå ...15 Umeå, Sweden

orthop scand. 50, 741–749, 1979

REMODELLING AFTER DISTAL FOREARM FRACTURES IN CHILDREN

III. *Correction of Residual Angulation in Fractures of the Radius*

K S I FRIBERG

Department of Orthopaedic Surgery, University of Umeå, Umeå, Sweden

The outcome of residual angulation of the radius after 38 distal forearm fractures in children was investigated The period of observation ranged from 4 months to 10 years and 8 months

The correction of a residual angulation after a fracture was shown to be governed by three factors.

1 An increase in the time between healing of the fracture and completed growth at the epiphyseal plates resulted in a more complete correction.
2. A larger adaxial dislocation of the epiphyseal plate at the time of healing of the fracture, reflecting a larger primary fracture angulation and a greater distance from the fracture to the epiphyseal plate, resulted in a less complete correction
3 A more complete correction or overcorrection of the distal epiphyseal plate increased the correction of the angulation of the fracture

These findings strongly indicate that the process of correction of a [illegible]

than 1 degree

Key words child, epiphyses, forearm, fracture, growth, remodelling

Accepted 3 iii 79

he spontaneous correction of residual gulations after fractures of the long bones children is a well-known phenomenon hne & Sandblom 1949, Attenborough 1953 andhu et al 1962, Miyagi & Murayama 64, Lanzi 1965, Bennek & Steinert 1966, rwe & Niemann 1966, Nonnemann 1969, ssak et al. 1969, Swaan & Oppers 1971, nsen et al 1976, Hogstrom et al 1976) The major concepts of the process of spontaneous correction have been summarized Blount (1955), Sharrard (1971) and oppy (1972) Thus, it is generally accepted t a younger child has a greater capacity for rrection Also, a larger angulation at the time of healing of the fracture and a longer distance between the fracture and the epiphyseal plate are factors claimed to result in a less complete correction Finally, the plane of movement in an adjacent hinge-joint is said to be of significance, viz a residual angulation located in the same plane as the movement is claimed to have a greater capacity for correction than an angulation in a plane not used by the joint However, a more detailed analysis of the contribution of each of these factors to the correction obtained has not yet been made This is reflected in clinical practice where only crude predictions can be made of the amount of

-6470/79/060741–09$02.50/0

© 1979 Munksgaard Copenhagen

correction to be expected in a specific patient with a specific fracture

It has recently been proved that the epiphyseal plates at both ends of a fractured long bone take an active part in the remodelling process The epiphyseal plates change their direction of growth and normalize their inclinations in relation to the long axis of the bone (Friberg 1974, 1979a,b, Ryoppy & Karaharju 1974, Karaharju et al 1976) This normalization of the steric orientation of the epiphyseal plates has been suggested to be of immediate importance for the correction of a residual angulation of a fracture Normalization of the epiphyseal inclination combined with longitudinal growth will automatically reduce any abnormal angulation of the diaphyseal part of the bone (Friberg 1979a,b)

The recent finding that the epiphyseal plates play an active role in the remodelling process after fractures made it necessary investigate the correction of angulations the fracture site with regard to the combi effect of the change in orientation of epiphyseal plates and longitudinal growth. the present study the process of correction residual angulation after distal forea fractures was investigated

MATERIAL AND METHODS

Thirty seven children with residual angula after a fracture in the distal fifth of the forea were studied The primary angulation of the di radial fracture at the time of healing compared with the angulation at the time of follow-up examination The patients were selec from all cases of distal forearm fractures tre the Department of Orthopaedic Surgery in L during 1965–1973 The selection was made to obtain a representative series with regard

Table 1 Distribution in the series of the variables used for the statistical analysis of the results T number of observations = 38 Means and standard deviations are given where not otherwise Ranges in brackets

Age at fracture, years months	9 4 ± 3 2 (2 5–14 9)	Primary fracture angulation degrees	11 84 ± (1–30)
Sex, no of boys/girls	19/19		
Side, no of right/left	19/19	Distance of fracture from the distal epiphyseal plate millimetres	16.2 ± (6–35)
Observation time, years months	4 6 ± 3 10 (0 4–11 0)		
Corrected observation time*, years months	3 8 ± 3 3 (0 4–10 8)	Distance of fracture from the distal epiphyseal plate in per cent of the total diaphyseal length of the radius	10.1 ± (2 19)
Type of fracture			
No of Torus	12	The adaxial displacement ** of the distal radial epiphyseal plate, millimetres	3 35 ± (0 2–11
Greenstick	14		
Complete	12		
		The final angulation of the distal epiphyseal plate of the radius, degrees	0.32 ± (–4–12

*Corrected observation time In 10 cases with closed epiphyseal plates at follow-up the time [illegible] growth at the distal epiphyseal pl [illegible] thari 1974)}. In the remaining [illegible] tion time

**Adaxial displacement = sine of primary angulation of the fracture x distance of fracture fro epiphyseal plate (cf Figure 5)

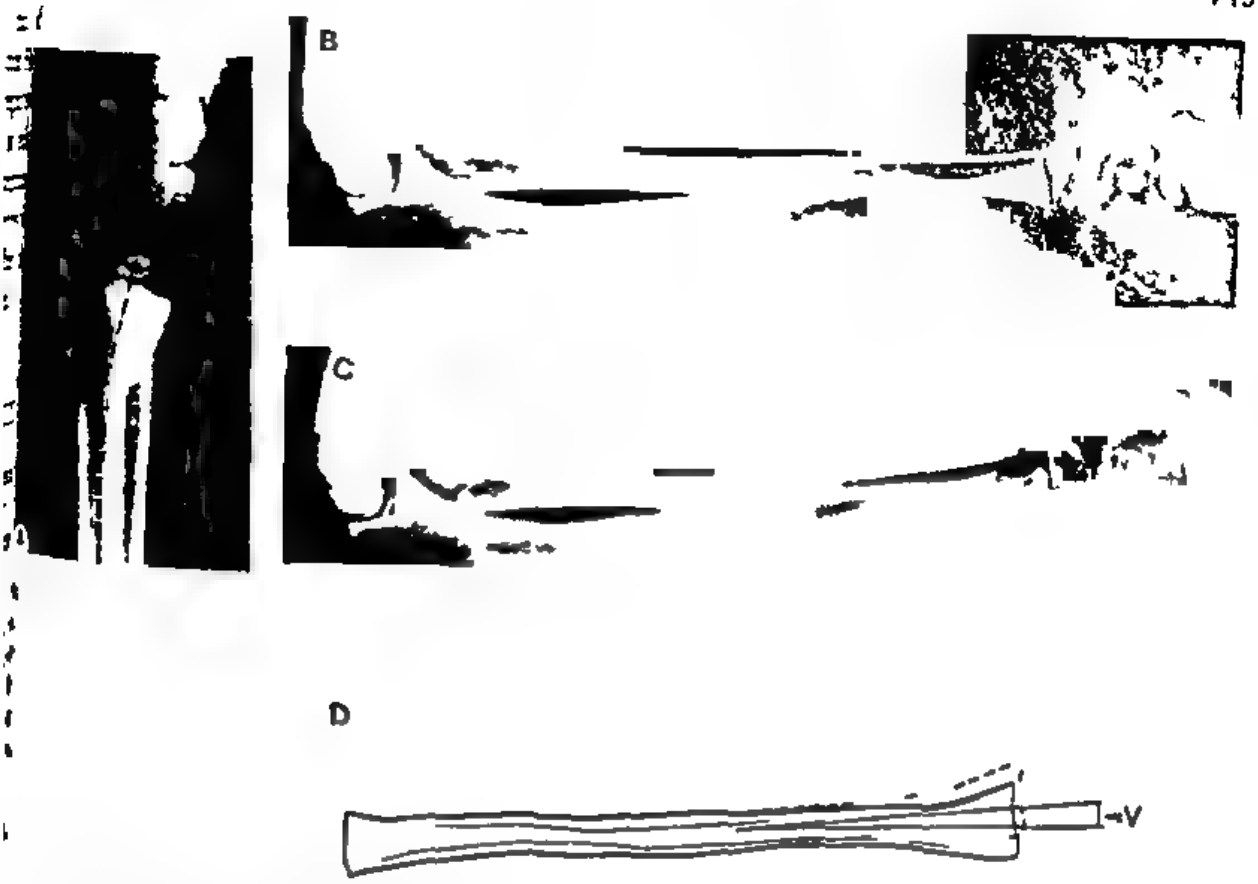

igure 1 A boy aged 3 years at the time of a fracture in the distal part of the radius The follow up ex amination was performed 9 years later
. The fracture at the time of removal of the cast An angulation of the epiphyseal plate of 16 degrees in the dorsal direction is present
The fractured forearm at follow-up
The normal forearm at follow-up
Superimposed drawings of B and C The residual fracture angulation is 3 degrees

ferent ages observation times and degrees of idual angulation Radiographs taken when the ctures were considered to be healed were used a basis for the evaluation. At re-examination ographs in the frontal and lateral view of both fractured and normal contralateral wrists and arms were obtained

Thirty-eight observations were made In 32 the tures had a visible inclination in the dorso- ar plane (lateral view) Twenty three of these e dislocated in the dorsal direction and nine in volar direction In the radio-ulnar plane ntal view) four had an abnormal inclination in radial direction and two in the ulnar direction oncomitant ulnar fracture was present in nine hal cases. Further details of the characteristics he series are given in Table 1

he radiographic technique used in the in- gation was identical with that previously ribed by Friberg (1979a).

Measuring technique

The *primary angulation* of the fracture at the time of healing was defined as the angulation of the epiphyseal plate in relation to a plane oriented 90 degrees to the axis of the distal third of the proximal fragment All measurements pertaining to the follow up examinations were performed on superimposed drawings of the radiographs and were expressed as the difference between the normal and fractured side The proximal half of the diaphysis up to the proximal metaphyseal area of the radius was used as a reference for the superimposition of the radiographs. The *remaining angulation of the fracture* at follow up was defined as the angle between the axes of the distal part of the radius on the fractured and on the normal side (Figure 1) The method used for determining the *final angulation of the distal epiphyseal* plate was identical with that previously

described by Friberg (1979b)

The total error of the measuring procedure was evaluated by repeated measurements and was found to be 0 6 degrees ± s d = 0 4 for the residual angulation of the fracture The errors of the other measurements have been given in previous studies (Friberg 1979a b)

Statistics

The means and standard deviations are given Standard computer programs were used for the stastistical procedures (SPSS vers. 6) (Nie et al 1975) The influence was not considered to be significant at levels of $P > 0\ 05$

RESULTS

A reduction of the primary fracture angulation had occurred in all of the 38 cases studied However, despite prolonged observation times complete normalization was found in only four cases. A slight overcorrection had occurred in one fracture

A concomitant distal ulnar fracture ($n = 9$) did not influence (Student's t-test) the rate of correction No differences (X^2analysis) in the rate of correction were found when the different directions of primary angulation were compared The reduction in fracture gulation is illustrated in relation to the ected observation time (cf Table 1) in gure 2

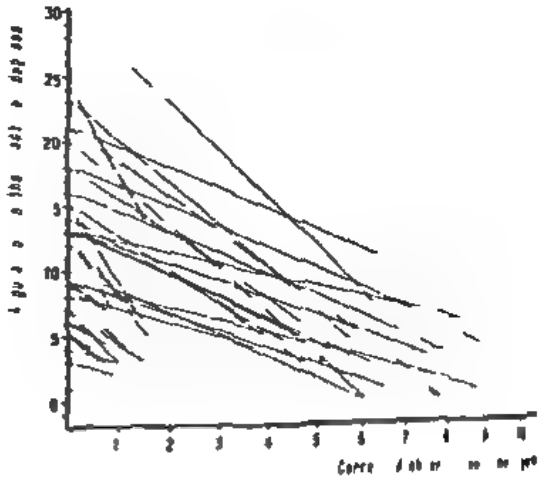

Figure 2 The angulation of the fracture relation to the corrected observation time should be noted that the lines do not illustra t course of the process but only connect observat in the same patient

Influence of different variables on the residual fracture angulation

The residual angulation in all planes was tested to determine the effect of the different variables used for classification of the material (Table 1) The total number of observations was 38 The methods used were bivariate correlation analyses, stepwise regression analysis and direct discriminant analysis. Only significant relations between the dependent and independent variables are indicated

The correlation analyses demonstrated that a longer corrected observation time ($P = 0\ 0086$, corr coeff $= -0\ 38$) resulted in a more complete correction of the angulation the fracture Furthermore, the younger t child was at the time of the fracture the m complete was the correction ($P = 0\ 00$ corr coeff $= -0\ 45$) It should be noted t the correlation between age and the correct observation time was very high ($P = 0\ 0$ corr coeff $= -0\ 73$)

A larger primary angulation in the fract ($P = 0\ 023$ corr coeff $= 0\ 33$) and increase in the distance from the fracture the distal epiphyseal plate of the radius (P 0 0086, corr coeff $= 0\ 42$) resulted in a l complete correction The combined effects these two parameters were also reflected the finding that an increased adaxial displa ment of the distal epiphyseal plate resulted a greater residual angulation ($P = 0\ 00$ corr coeff $= 0\ 60$)

Finally, a more complete correction overcorrection of the distal epiphyseal pl ($P = 0\ 00001$, corr coeff $= 0\ 75$) was c related with a smaller residual angulation the fracture The stepwise regression anal showed that the final position of the dis epiphyseal plate ($P < 0\ 001$), the correc observation time ($P = 0\ 007$) and the ada displacement of the plate ($P < 0\ 001$) w the only three variables which significa

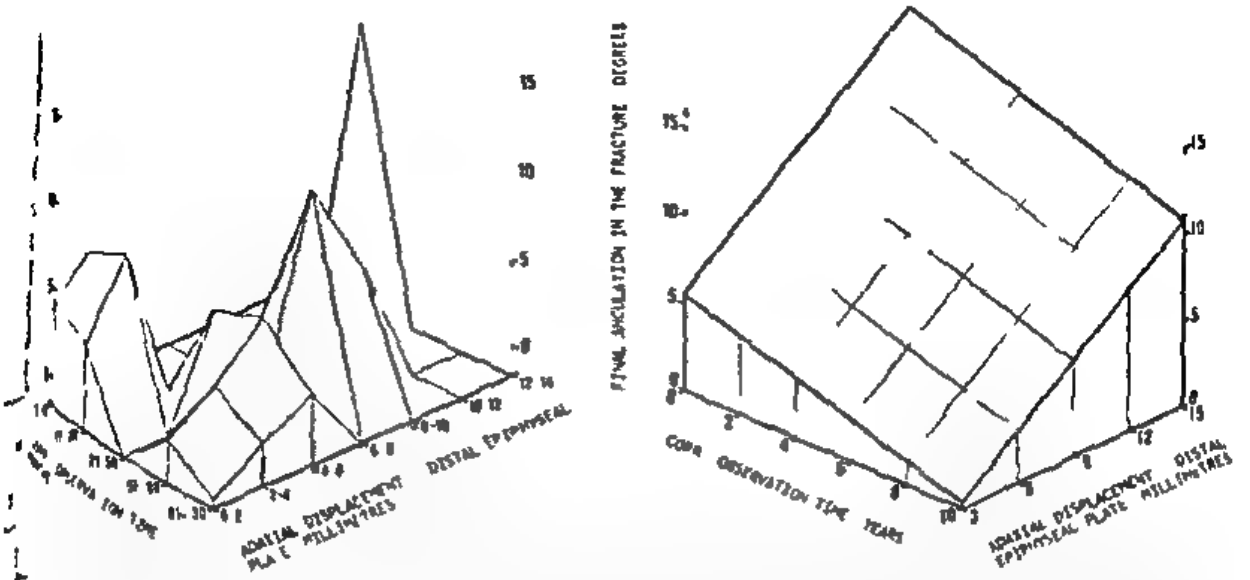

Figure 3 Three dimensional plots of the relations between the residual fracture angulation the corrected observation time and the adaxial displacement In Figure 3A the height of each pyramid illustrates the mean value or value for the residual angulation found in the cases or case constituting the pyramid. The values of the parameters defining the cases in each pyramid are given in the figure Figure 3B illustrates the regression plane of the three parameters

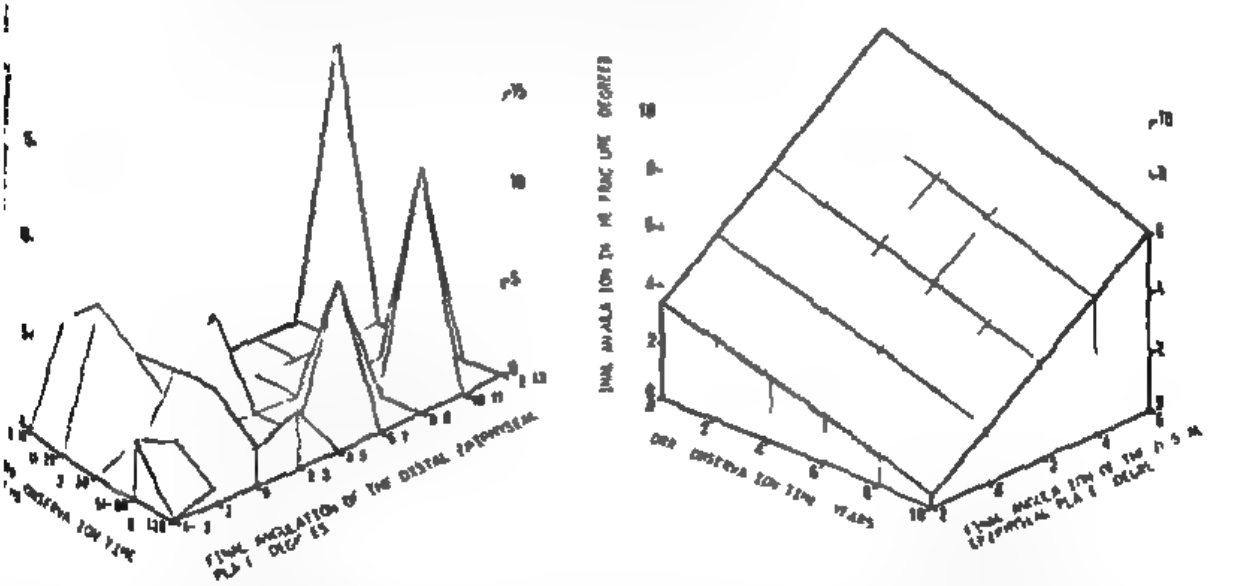

Figure 4 Three dimensional plots showing the relationship between the residual fracture angulation, the corrected observation time and the final angulation of the distal epiphyseal plate In Figure 4A the height of each pyramid illustrates the mean value or value for the residual angulation found in the cases or case constituting the pyramid The values of the parameters defining the cases in each pyramid are given in the figure Figure 4B illustrates the regression plane of the three parameters

obtained (79 per cent) the variance found in results.

For the discriminant analysis the series was divided into two groups. The first group consisted of 18 cases with a residual fracture angulation of 3 degrees or less, the second group of 20 cases had a residual angulation of 4 degrees or more The analysis showed that 90 per cent of the cases were correctly classified when all variables were used for the prediction ($P < 0.001$) A second discriminant analysis including only the corrected observation time and the adaxial displacement of the epiphyseal plate as independent variables

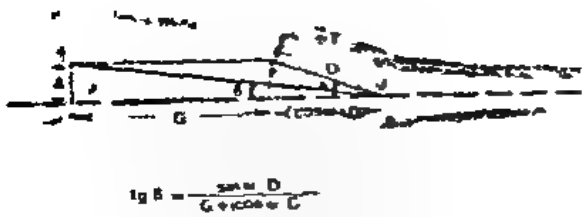

Figure 5 The formula used for calculation of the theoretical residual fracture angulation
G — The longitudinal growth produced by the epiphyseal plate
D — Distance from the fracture to the epiphyseal plate
A — Sin α × D = Adaxial displacement of the epiphyseal plate
α = Angulation of the fracture at the time of healing
β Residual angulation of the fracture

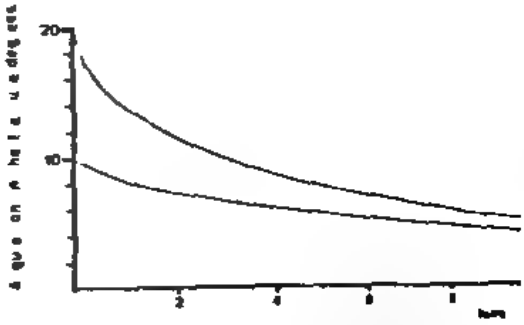

Figure 6 The correction of angulation of d forearm fractures in four hypothetical according to the formula used in the study
——— = 10 mm of adaxial displacement the distal epiphyseal plate
– – – – – = 5 mm of adaxial displacement the distal epiphyseal plate

resulted in a correct classification in 82 per cent of the cases ($P < 0.001$)

In conclusion the statistical analysis showed that the residual angulation of the fracture at the follow up examination was explained by three different circumstances An increase in observation time up to the time of completed growth at the epiphyseal plates resulted in a more complete correction A larger adaxial displacement of the distal epiphyseal plate, reflecting a greater primary angulation and a longer distance from the fracture to the epiphyseal plate, increased the residual angulation. A more complete correction or overcorrection of the distal epiphyseal plate resulted in a more complete correction of the angulation of the fracture The relations between these three circumstances are illustrated in Figures 3 and 4

Theoretical correction versus actual correction of the fracture angulation

For the calculation of the theoretical correction of the fracture angulation a formula was devised on the assumption that no "correction of angulation" would occur at the site of the fracture The basis for this calculation was, then, that the direction and amount of longitudinal growth at the distal epiphy plate were the only factors influencing reduction in angulation at the fracture The formula is illustrated in Figure 5 and correction in hypothetical cases according the formula in Figure 6

In the calculations the slight increase adaxial displacement that might theoretic occur before the orientation of the ep phys plate normalized was ignored Also, overcorrection of the distal epiphyseal pl that occurs with a longer period of obser tion was not taken into account. Thus final orientation of the plate was assumed be equal to that on the normal side calculations of the longitudinal growth figure of 0 94 mm/month was used for first 12 months. This was the figure for mean longitudinal growth actually prod by the distal epiphyseal plate of the rad during the first year after a distal fore fracture (Friberg 1977) After the first yea growth rate of 0 64 mm/month was u This figure was based on a total increase the diaphyseal length of the radius of 0 mm/month (cf Maresh 1955 Diethelm 1 and Valk 1971) and the finding that afte distal forearm fracture 80 per cent of the t increase in diaphyseal length is produced the distal epiphyseal plate (Friberg 1977)

When the correction actually achieved the calculated theoretical correction w

mpared it was found that the formula resulted in a slight but nonsignificant (Students *t* test) underestimation of the correction (0 34 degrees ± 172) The theoretical correction was also compared with the actual correction of the fracture angulation by a univariate correlation analysis The correlation found between the theoretical and the actual correction of fracture angulation was 0 83 (*P* < 0 00001) Thus the residual angulation of the fracture was almost completely explained by the effect of longitudinal growth provided that normalization of the orientation of the plate had occurred

SCUSSION

e correction of residual fracture angulation the radius after healed distal forearm ctures in children was studied The general lt was that a correction of the primary ulation had occurred in all cases, but pite extensive periods of observation only ated cases had reached full correction wever, the residual angulation of the ture at the follow-up examination, was tively small in the cases with longer rvation times Thus, the present results generally in agreement with the view that, nded adequate time has elapsed, a more ess complete normalization of a residual ture angulation can be expected after a al forearm fracture (Önne & Sandblom 9, Gandhi et al 1962, Miyagi & ayama 1964, Lanzi 1965, Buck et al 5, Blount 1967, Nonnemann 1969)

order to investigate in detail the process orrection of residual fracture angulation, ral variables were analysed for their ific influence on the residual angulation tarily, the factors already claimed to ence correction were investigated, i e the degree of primary angulation of the ure, the distance from the fracture to the cent joint (Blount 1955, Sharrard 1971, ppy 1972) In addition, the influence of orientation of the distal epiphyseal plate taken into account as it has been proved that the epiphyseal plates normalize their inclinations in relation to the long axis of the bone (Friberg 1974, 1979a, b, Ryöppy & Karaharju 1974, Karaharju et al 1976) On theoretical grounds, normalization of the orientation in combination with longitudinal growth at the plate has been suggested to reduce automatically the measured angulation of the fracture (Friberg 1979a,b)

The results showed that the observation time up to the time of completed growth at the distal epiphyseal plate was one of the major factors explaining the residual angulation of the fracture This is also reflected in the finding that the younger the patient was at the time of the fracture the more complete was the correction This finding is compatible with the general opinion with regard to the correction of fracture angulation (Blount 1955, Önne & Sandblom 1949, Miyagi & Murayama 1964, Hogstrom et al 1976) However, it is important to note that further analysis of the results indicated that it is not the age of the child *per se* that is of importance, but the remaining period of time up to epiphyseal closure Gandhi et al (1962) and Hansen et al (1976) also found in their studies on the correction of residual fracture angulation that the age of the child at the time of fracture did not influence the rate of correction

The primary angulation of the fracture and the distance from the fracture to the epiphyseal plate have also been known to influence the capacity for correction of residual fracture angulation (Blount 1955, 1967) These two variables were shown also in the present investigation to have a decisive influence on the results However, the analysis strongly suggests that it is the combined effect of the two variables which is more important, i e the adaxial displacement of the epiphyseal plate

Studies regarding the correction of angulations of the tibia have shown that the capacity for correction is not equal in all planes (Bennek & Steinert 1966, Spissak et al 1969) According to Blount (1955) the plane of motion of an adjacent hinge-joint in-

fluences the capacity for correction In the present study the direction of the angulation of the fracture was of no importance for the results. However, the wrist joint has a range of movement that incorporates all the directions the fracture was measured in Thus the relevance of this factor could not be studied in the present investigation

It has been suggested by Ryoppy & Karaharju (1974) Karaharju et al (1976) and Friberg (1979a b) that the orientation of and growth at the epiphyseal plates should be of importance for the correction of residual angulation after a fracture The present results show that the orientation of the distal epiphyseal plate of the radius is of primary importance for the correction of a fracture angulation in the distal part of the radius.

The actual mechanism of the correction of a residual angulation of a diaphyseal fracture has not been fully investigated. However, it is generally implied that the correction occurs at the fracture site (Blount 1955, Sharrard 1971) Certainly, resorption of bone on the convex side and apposition of new bone on the concave side occur at the fracture site (Frost 1964) However, this process will not alter the actual inclination between the fracture fragments but will make angulation ss prominent to the eye when radiographs are compared Furthermore, an error may be introduced if the midpoint of the fracture is used as one of the measuring points when the correction of a fracture angulation is assessed

The findings of the present study strongly support the suggestion (Friberg 1979a b) that the correction is an effect of the orientation of the epiphyseal plate in combination with longitudinal growth The results clearly showed that the orientation of the distal epiphyseal plate was of primary importance for the results. Furthermore it was shown that an increase in the period of observation up to the time of completed growth increased the degree of correction This can be translated to mean that an increased potential for longitudinal growth increases the amount of correction to be expected Finally, the finding that the primary angulation and the distance of the fracture to the epiphys plate and especially the combined effect these two parameters, i.e the adaxial c placement of the epiphyseal plate, plave decisive role in the correction furt supported the hypothesis that the correct is due to the orientation of and growth i plate (cf Figure 5)

With a view to predicting the exper correction of a residual fracture angulatio trigonometrical formula (Figure 5) devised This formula was deduced f the hypothesis mentioned above, accordingly, it was assumed that no real c rection occurs in the diaphyseal part of bone It was demonstrated that the form produced an accurate prediction of residual angulation actually observed in series. The findings imply that no m change in the adaxial displacement of epiphyseal plate occurred during the period observation Consequently, the res indicate that no real correction of clinical portance occurred at the fracture site that, for example, "cortical drift" (En 1962, Garn et al 1969 Stanek 1969) pla no role as a remodelling factor in remaining part of the diaphysis of the bo Thus the results strongly support the opin that the process of correction of a resid angulation of a fracture is a fictive correct and that, in reality, it is brought about by combined effects of the direction and amo of growth at the epiphyseal plate

REFERENCES

Attenborough, C. G (1963) Remodelling of humerus after supracondylar fractures childhood. *J Bone Jt Surg* 35 B 386–3

Bennek, J & Steinert V (1966) Knoch wachstum nach deform verheilten Un schenkelschaften bei Kindern. *Zbl Chir* 633–639

Blount, W P (1955) *Fractures in children* Pp Williams & Wilkins Co., Baltimore

Blount, W P (1967) Forearm fractures children *Clin Orthop* 51, 93–107

Folschveiller, J & Jenny, G (1966) Uber Behandlung von 376 Voderarmfibruchen bei Kindern *Hefte Unfallheilkd* 51–54

n, L (1968) *Handbuch der Medizinischen ologie* Band IV Teil 2, Springer Verlag, n

D H (1962) A study of the postnatal th and remodelling of bone *Amer J* 110, 79–101

S (1974) Spontan korrektion av felstallefter lakning av distala underarmsfrakturer barn. Lakarsällskapets riksstamma anfattningar, 353, Stockholm

S (1977) [illegible]

(1979a) Remodelling after distal rm fractures in children I The effect of al angulation on the spatial orientation of piphyseal plates *Acta orthop scand* 59, 546

S (1979b) Remodelling after distal rm fractures in children. II The final tation of the proximal and distal yseal plates of the radius *Acta orthop* 50, 731–739

M (1964) *The laws of bone structure* es C Thomas [illegible]

M, Goodspeed, G & Hertzog, K (1969) ngitudinal test of angular remodelling *J phys Anthrop* 30, 311–313

H E & Niemann, F (1966) istumsstorungen nach Frakturen im ssalter *Bruns' Beitr klin Chir* 212, 205

B A, Greiff, J & Bergman, F (1976) ures of the tibia in children *Acta orthop* 47, 448–453

n, H, Nilsson B E & Willner, S (1976) ction with growth following diaphyseal rm fractures. *Acta orthop scand* 47, 103

u, E O, Ryoppy, S A & Makinen, R J) Remodelling by asymmetrical epiphyseal growth *J Bone Jt Surg* 58-B, 122 126

Kothari, D R (1974) Age of epiphyseal union at elbow and wrist joints in Marwar region of Rajasthan *J Indian med Ass* 63, 252–256

Lanzi, F (1965) Evoluzione delle fratture di avambraccio dell' infanzia e dell'adolescenza *Arch Ortop (Milano)* 78, 327–335

Maresh, M M (1955) Linear growth of long bones of extremities from infancy through adolescence *Amer J Dis Child* 89, 725–742

Miyagi, S & Murayama, T (1964) Clinical observations on spontaneous correction of fracture of the shaft of growing long bones. *Kurume med J* 11, 19–37

Nie, N H, Hull, C H, Jenkins, J G, Steinbrenner, K & Bent, D N (1975) *Statistical package for the social sciences* 2nd ed McGraw-Hill Co, New York

Nonnemann, H C (1969) Grenzen der Spontankorrektur fehlgeheilter Frakturen bei Jugendlichen *Langenbecks Arch klin Chir* 324, 78–86

Önne, L & Sandblom, P H (1949) Late results in fractures of the forearm in children *Acta chir scand* 98, 549–567

Ryoppy, S (1972) Injuries of the growing skeleton *Ann Chir Gynaec Fenn* 61, 3–10

Ryoppy, S & Karaharju, E O (1974) Alteration of epiphyseal growth by an experimentally produced angular deformity *Acta orthop scand* 45, 490–498

Sharrard, W J W (1971) *Paediatric orthopaedics and fractures* Blackwell Scientific Publ, Oxford and Edinburgh

Spissak, L, Majesky, I & Holleitnerova, M (1969) Nase skusenosti s autoremodelaciou diafyzarnych zlomenin predkolenia u deti *Acta Chir orthop Traum čech* 36, 176–178

Stanek, J (1969) Modelling of the diaphysis of long bone during the postnatal growth Lateral drift *Folia morph* (Praha) XVII, 329–341

Swaan, J W & Oppers, V M (1971) Crural fractures in children *Arch Chir Neerl* 23–24, 259–272

Valk, I M (1971) Accurate measurements of the length of the ulna and its application in growth measurements. *Growth* 35, 297–310

ndence to K S I Friberg Department of Orthopaedic Surgery, University of Umeå, 5 Umeå, Sweden

n orthop. scand. 50 751–754 1979

TREATMENT OF PARA-ARTICULAR OSSIFICATION AFTER TOTAL HIP REPLACEMENT BY EXCISION AND USE OF FREE FAT TRANSPLANTS

ERIK B RISKA & JARL-ERIK MICHELSSON

The Department of Orthopaedics and Traumatology, University Central Hospital in Helsinki, Finland

Six patients with para articular ossification after total hip replacement were treated by excision and free fat tissue transplantation The results of treatment were good and at the follow-up examinations, 2 to 8 years after the operation, a good range of movement of the hip joint was noted in all cases It was apparent that the free fat transplant had prevented the recurrence of the para-articular ossification.

Key words fat transplant, hip joint, para articular ossification

Accepted 12 v 79

n articular ossification after total hip lacement is a severe condition without known cure (Nollen & Slooff 1973) cording to Eftekhar 1971 and Patterson Brown 1972, it occurs in about 10 per t of patients after total hip replacement, many authors have reported much higher es (Nollen & Sloof 1973, Rosendahl al. 1977) The severity of ossification has graded at Grade I the hip joint is ost asymptomatic, but at Grades II and with a bony bridge between the femur the pelvis a marked limitation of the ge of movement is always present, and at de III the hip joint can be totally immobilized In patients developing ossification Grades II and III the total hip replace- t operation must be classified as a re, and there have been no reports of essful methods of treatment Thus a llestone procedure was carried out in two s of periarticular ossification in the series ented by Patterson & Brown 1972.

nce 1965, Langenskiold has been using free fat transplants, placed on the spinal dura, after operations on lumbar discs The transplanted free fat prevents the formation of firm scar tissue adherent to the dura, which is thus easily exposed by blunt dissection in connection with new operations (Langenskiold & Kiviluoto 1976) These results were confirmed by an experimental study on rabbits (Kiviluoto 1976) With free fat grafts, scar tissue formation between the dura and the surrounding tissue was prevented in 92 rabbits after laminectomy operations.

In our clinic free fat transplants have also been used in hip surgery after excision of para-articular ossification following total hip replacement operations The results will be given in this report

PATIENTS

Between 1967 and 1977 468 total hip replacement operations were performed All cases were operated on by one surgeon (EBR). Of these, 80

6470/79/060751–04$02.50/0

© 1979 Munksgaard Copenha

Table 1 Para-articular ossification after total hip replacement

Diagnosis	Age (years)	Sex	Year of replacement	Type of prosthesis	Grade of ossification
Necrosis of the femoral head and osteoarthritis	79	Female	1968	McKee-Farrar	II
Post-traumatic osteoarthritis	63	Male	1970	McKee-Farrar	III
Post-traumatic osteoarthritis	77	Female	1971	McKee-Farrar	III
Post-traumatic osteoarthritis	45	Female	1972	McKee-Arden	II
Degenerative joint disease	59	Female	1973	McKee-Farrar	II
Post-traumatic osteoarthritis	52	Female	1974	McKee-Farrar	II
Degenerative joint disease	60	Male	1976	McKee-Arden	III

were bilateral operations The McKee-Farrar prosthesis was used in the first 311 cases, after which a high density polyethylene cup was employed for the rest of the cases. The follow-up examinations were undertaken 1 month, 3 months, 6 months and 12 months after the operation, and then once a year Seven patients developed para articular ossification of Grades II or III with pain and limited range of movement of the hip joint and were in need of additional surgical treatment (Table 1) Severe osteoarthritis had been the indication for replacement in three cases and post-traumatic osteoarthritis in four cases

OPERATIVE TECHNIQUE

In six of the patients the para articular ossi tissue was completely resected and the exci was followed by transplantation of free fat tis taken from gluteal or abdominal subcutane tissue Local application of Neomycin Bacitracin solution (Nebacetin®) was used d the operation and suction drainage was applied 48 hours. The patients were mobilized after of the drainage tube on the second postopera day One patient was not treated by surgery, as was bedridden following a cerebral thrombosis

Table 2 Results of treatment of para-articular ossification

Grade of ossification	Interval between the operations (months)	Follow-up period (years)	Results of treatment
III	3	8	Good
III	20	3	Good
II	-	6	Excellent
II	4	5	Excellent
II	9	3	Excellent
III	1	2	Good

Fig 1a Fig 1b Fig 1c

e 1 (a) Osteoarthritis of the hip joint in a man of 60 years (b) Three months after total hip cement with a McKee-Arden prosthesis Para articular ossification surrounds the hip joint h is almost completely stiff (c) Nine months after excision of the ossification and free fat plantation The result of treatment was classified as good after a follow up of 2 years

Fig 2a Fig 2b

Figure 2 (a) Para articular ossification 45 days after McKee-Farrar total hip replacement in a woman of 59 years (b) Four years after excision and free fat transplantation The result of treatment was classified as excellent with a normal range of movement of the hip joint

Follow up

The follow up period after the second operation varied from 2 to 8 years (Table 2) One patient died of a heart infarction 3 years after the second surgical intervention

RESULTS

The result of treatment was classified as *excellent*, if a good range of movement of the hip joint was achieved and no recurrence of ossification appeared, and as *good*, if a good range of movement was achieved but an insignificant amount of ossified tissue was noted at the follow-up examination Fair or

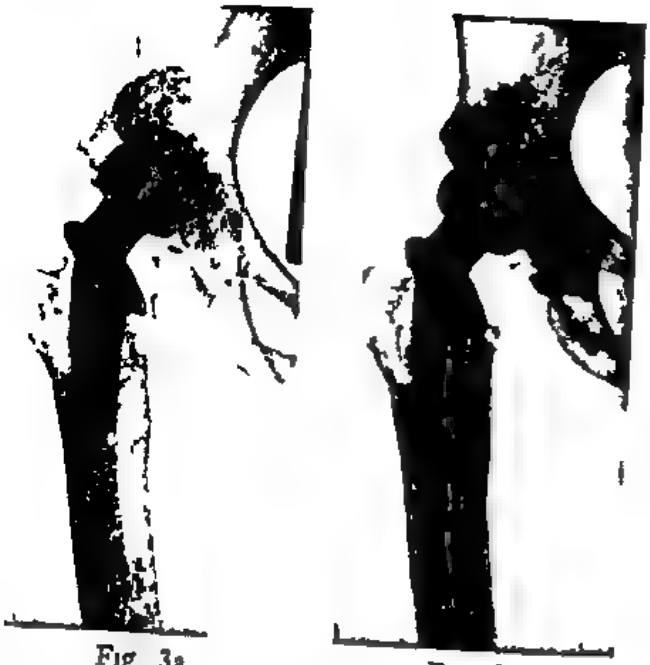

Fig 3a Fig 3b

Figure 3 (a) Para articular ossification in a woman of 52 years, 9 months after a McKee-Farrar total hip replacement because of fracture of an anchylotic hip joint (b) Three years after excision and free fat transplantation The result of treatment was excellent

poor results were not encountered in this series of patients

A good range of movement of the hip joint was regained in all cases At the follow-up examination no disturbing para articular ossification was noted, as illustrated in Figures 1, 2 and 3

A late infection appeared in one patient 2 years after the second operation *Staphylococcus epidermidis* was cultured and antimicrobial therapy was indicated

DISCUSSION

According to Somerville (personal communication, 1973) acrylic cement has been used with good results for the packing of bone surfaces after excision of ossified tissue around the hip joint

In the present report the actual number of patients was small, seven cases ut of 468 developed para-articular ossificat n after total hip replacement, and in six operated cas results of this treatment were good Ther no recurrence of the ossification and a range of movement of the hip joint maintained

Apart from this there have so far bee reports of successful methods of treatmen para-articular ossification It may be pos to prevent it by skilful surgical techn but, nevertheless, there will always be s patients who develop ossified tissue aro the hip joint after replacement proceed without there being a known reason. In t cases excision and free fat transplantation indicated Enough fat tissue should be ta to fill up the gap after excision of calcification There is always suffic abdominal subcutaneous tissue even in m

During the past few years, free transplants have been utilized in our clinic many instances to prevent scar tiss formation in myositis ossificans, in plas surgery operations, in connection wi antero-lateral decompression of the spin cord, and to produce artificial pseudarthrose The results in these cases have also bee encouraging

REFERENCES

Eftekhar N (1971) Low friction arthroplasty Indications contraindications and com plications. *J Amer med Ass* 218, 705 710

Kiviluoto O (1976) Use of free fat transplan s to prevent epidural scar formation. An ex perimental study *Acta orthop scand* Suppl 164, 1–75

Langenskiold A & Kiviluoto O (1976) Preven tion of epidural scar formation after open ope on the lumbar spine by means of free fa transplants. *Clin Orthop* 115, 92–95

Nollen A J G & Slooff T J J H (1973) Para articular ossification after total hip replace ment *Acta orthop scand* 44, 230–241

Patterson F P & Brown, C. S. (1972) The McKee-Farrar total hip replacement. *J Bone Jt Surg* 54 A 257–275

Rosendahl, S Christoffersen J K & Norgaard M (1977) Para articular ossification followed hip replacement *Acta orthop scand* 48, 400–404

Correspondence to Erik B Riska M D Department of Orthopaedics and Traumatology University of Helsinki Topeliuksendatu 5, 00260 Helsinki 6 Finland

rthop scand 50 755–758 1979

HYMESOPHALANGY AND LOOSE BODIES IN THE ACARPOPHALANGEAL JOINTS

& U LUCHT

dic Hospital Aarhus Denmark

A family with autosomal inherited brachymesophalangy is presented Some of the family members also had loose bodies in the metacarpophalangeal joints. This condition is similar to osteochondritis in other joints New loose bodies may be formed after operative removal and arthritic changes may occur The patients were not able to perform hard physical work with their hands

Key words brachydactyly, brachymesophalangy, [illegible]

Accepted 3 III 79

fingers or brachydactyly is due to alous development of any of the con ing phalanges or metacarpals and is most thoroughly studied congenital mality of the hand (Kelikian 1974) ydactyly has been conveniently fied into five main groups but there is derable variation of the anomaly (Chen) The most common type of ydactyly is brachymesophalangy, which s when the middle digital phalanges have same length or are shorter than the mal phalanges (Witt et al 1966) steochondritis dissecans is very rare in hand A few cases in the scaphoid bone been reported (Meves & Schneider- ert 1975) Recently Andrén et al (1978) ribed a combination of brachymeso- langy and osteochondritis dissecans in the acarpophalangeal joints This report sents the second family to be described in literature with this rare syndrome

easily recognized by [illegible] It has therefore been [illegible] some members of the family [illegible] (Figure 1) All members of the first three generations except two [illegible] dead while all members of the [illegible] generations are alive [illegible] members are very [illegible] has not been possible [illegible] Five of the examined [illegible] addition to brachymesophalangy [illegible] the metacarpophalangeal joints [illegible] will be referred to here [illegible]



Figure 1 [illegible]

TIENTS

some years we have had the opportunity to [illegible] several members of a family with [illegible] The family members can be [illegible] chymesophalangy

1 6470/79 060755 04$02.50/0

Table 1 Abnormalities of the hands

Number in pedigree		IV-12	IV 13	IV 15	V-4	V-
Sex		M	F	M	M	M
Age		52	48	41	30	25
Brachymesophalangy	II	+	+	+	+	+
	III	–	+	+	–	–
	IV	+	+	+	+	–
	V	+	+	+	+	+
Deformity of metacarpal heads		+	+	+	+	+
Metacarpal joints with loose bodies Right hand	II	+	+	+	+	–
	III	+	–	+	+	+
	IV	–	–	–	–	–
Left hand	II	+	–	+	+	–
	III	–	–	+	–	–
	IV	–	–	–	+	–
Short styloid ulnar process		+	+	+	+	+

RESULTS

The main abnormalities of the hands are summarized in Table 1 All five patients had brachymesophalangy of the second and the fifth fingers whereas the third and the fourth fingers were not affected in all cases (Figures 2 and 3) The length of the metacarpals was normal but the metacarpal heads were flattened and occasionally irregular This deformity was most pronounced in the second third fingers and to a lesser degree in the fourth and fifth fingers. As seen in the Table the majority of loose bodies were located in the second and third metacarpal joints The loose bodies were usually discoid (Figure 4).

Figure 2 Patient with shor nd and little fingers

In one case the loose body was exam histologically and consisted of normal surrounded by cartilage All the patients a short and blunt ulnar styloid process.

Clinically the patients had pain in

Figure 3 X ray of the same patient as in F demonstrating the short middle phalanges index and little fingers

4 A loose body is present in the meta ophalangeal joint of the index finger

ted joints especially if they tried to rm hard work. There was episodic anical blocking of the joint motion The ination revealed varying degrees of ness and restricted movements of the s with loose bodies

e loose bodies were removed by ition except in one patient, who had only complaints. The operation resulted in pearance of the mechanical blocking and pain was reduced However, in one (IV-15) three joints were reoperated cause of new symptoms. In one joint a body, formed since the last operation emoved In the two other joints no free s were found and the pain could be ned by arthrotic changes. Another it (IV-12) was reoperated on in one joint se of pain but only arthrotic changes found Clinical examination of patient half a year after the first operation ed a new loose body in the second metacarpophalangeal joint but the symptoms were so mild that the patient did not want reoperation

These five patients also had short or absent middle phalanges of the toes but no loose bodies were found The feet were without symptoms. The patients did not present other congenital abnormalities

DISCUSSION

In the present family brachymesophalangy appears as an inherited autosomal dominant disorder and this is in agreement with other studies (Kelikian 1974, Andrén et al 1978) In addition to being an isolated anomaly, brachymesophalangy may be part of a generalized disorder (Kelikian 1974) The predisposition to shortening of the phalanges is greater the later the enchondral ossification occurs (Witt et al. 1966) and therefore the middle phalanges of the index and the little fingers are most often affected (Kelikian 1974) The present syndrome which includes brachymesophalangy, deformed metacarpal heads loose bodies in the metacarpal joints hypoplasia of the ulnar styloid process and brachymesophalangy in the feet, in general is consistent with the syndrome described by Andren et al (1978) However, in contrast to the latter description our patients did not have clinodactyly and some, besides the dwarfing of the index and little fingers, also had short middle phalanges of the third and the fourth fingers.

The aetiology of loose bodies in the finger joints is unclear, but the condition is rather similar to osteochondritis dissecans in the knee This process is defined as separation of a cartilage-bone fragment from the joint surface (Smilie 1960) Accordingly, the microscopy of a loose body in the present study demonstrated that it consisted of bone and cartilage It may be suggested that the deformity of the metacarpal heads plays an important role in the formation of the loose

interest in connection with a study of equilibrium in scoliotics. During vestibular imbalance, caused by stimulation or disease, skeletal muscle tone can be influenced reflexively through afferent tracts, resulting in a deviation and rotation of the body towards the side with least tone (Fukuda 1959, Henriksson et al 1962, Torok & Kahn 1960, Wodak & Fischer 1923) The abnormal asymmetric posture demonstrated by the spine in these circumstances resembles the characteristics of the scoliotic deformity

In the light of this observation, it is possible that a functional asymmetry or disturbance at some level in the vestibulospinal reflex-arch in the labyrinth or in the brain stem, might be a contributory mechanism in AIS

Nystagmus is often used for studies of disturbances of equilibrium It is an important sign of various vestibular and neurological disorders (Barber 1975, Norre 1975) Its analysis is important in the diagnosis of these disorders.

Yamada & Yamamoto (1972) have studied some equilibrium factors in a group of scoliotics with various aetiologies. They only ested spontaneous and positional nystagmus ing Fresnel's glasses and were not able to demonstrate any significant vestibular dysfunction with these tests.

The main purpose of the present study was to investigate spontaneous nystagmus, positional nystagmus and caloric response in a group of patients with adolescent idiopathic scoliosis and to compare the results with those obtained in a control group of children with a straight spine The questions we hoped to answer were as follows

1 Is there any difference in vestibular function between children with AIS and control children with a straight spine?
2. Is there any correlation between vestibular dysfunction and the convexity of the curvature?
3 Is any vestibular dysfunction primary or is it secondary to the deformed spine?

METHODS

The nystagmus was recorded with the elect nystagmographic technique (ENG) using ELEMA direct writing Mingograph. The pa speed was 5 mm/s. The advantages of t method are well known (Stahle 1958).

Before the ENG registration all subjects w examined for neurological disorders and ear n and throat diseases according to a spe schedule The children were also asked questi about whether they experienced motion sicks in the various situations which are known produce vestibular stimulation. They were asked how they felt at high altitudes.

The recordings were performed in a dark, s room with the test subject supine and with e closed Electrodes were placed at each o canthus for recording horizontal nystag Nystagmus, which is a diphasic reflex movem of the eye has a slow phase as an expressio the reactions in the vestibular apparatus an rapid phase as a result of extra vestibular cere correction (Aschan et al 1956). The directio nystagmus is indicated in the usual way by direction of the rapid phase

Spontaneous nystagmus (SN) is nystagmus effected by the position of the head and constant in all positions (Stahle 1958). Positi nystagmus (PN) is nystagmus that develops i in certain positions (Figure 1 a b). It can direction fixed i e beating in the same direct regardless of the position of the head or it can direction-changing i e reversing direction w the position of the head is changed, and it can irregular i e changing direction in a [illegible] 1966) Posture tests sig [illegible] ed

follows

1 Head in 30° flexion before the Mingograph calibrated.
2. Head in 30° flexion after calibration.
3 Head in rotation to the left side
4 Head in rotation to the right side
5 Head in 30° extension

The recording time in each position was at l 60 seconds. The direction of nystagmus intensity were registered

The caloric tests were performed according the method of Fitzgerald & Hallpike with s modifications (Fitzgerald & Hallpike 1942) syringing was done for 30 seconds with a w volume of 100 cc The registration of movements started simultaneously with syringing and was continued for 210 seconds T time between two syringings was 10 minutes T syringings were performed with carefully c



re 1 a, b ENG recording illustrating evaluation in the posture test In 1 (a) an obvious left-beating tional nystagmus is considered to be present Figure 1 (b) illustrates a less intensive left-beating tional nystagmus, at the lower limit taken account of



e 2 a, b ENG recording illustrating evaluation in the caloric test (30°, right ear) In 2 (a) the 10- d period that was assessed as being the peak of reaction, maximum intensity (degrees/second), is in- Figure 2 (b), which is an enlarged copy of the first part of 2 (a), illustrates periods of ythmia, there are indicated by the arrows

l temperatures, 30° and 44°
following four test situations were studied
supine position with the subject's head in
xion
d water, left ear
elicits a nystagmus to the right
d water, right ear
elicits a nystagmus to the left
m water, left ear
elicits a nystagmus to the left
m water, right ear
elicits a nystagmus to the right
nystagmus was assessed with regard to
n, rhythmicity and maximum intensity
aximum intensity is the mean eye speed in
w phase of nystagmus during a 10-second
at the peak of the reaction (Figure 2). It is
sed as the best way to quantify an induced
(Riesco-MacClure 1964 Stahle 1958).
mplitudes of more than 2 mm were

When analysing the registration it is important to determine whether or not symmetry exists in the sensitivity of the labyrinths or between the right beating and left beating nystagmus. The isolated reactions are of less importance (Stahle 1958) The following two relationships are therefore compared

1 Right/left sensitivity (2+4) — (1+3)
2 Right-beating/left-beating nystagmus (1+4) — (2+3)

There is a great normal interindividual variation in the caloric reactions We therefore determined the difference in sensitivity between the labyrinths and between right- and left-beating nystagmus in relation to the total response, as recommended by Jongkees & Philipszoon (1964). Differences in labyrinthine sensitivity, labyrinth predominance, can be expressed by the formula

$$\frac{(2+4) - (1+3)}{1+2+3+4} \times 100\%$$

A negative value means a predominance of the

left labyrinth and a positive value a predominance of the right labyrinth

The difference in right- and left-beating nystagmus, directional preponderance, can be expressed by the formula

$$\frac{(1+4) - (2+3)}{1 + 2 + 3 + 4} \times 100\%$$

A negative value means a dominance of left-beating nystagmus (i e preponderance to the left), and a positive value means a dominance of right-beating nystagmus

The registrations from the control children were used for calculation of reference values for the two formulae and were set at M ± 2 SD

Dysrhythmia was considered to be present when a subject had alternating periods of high and low intensive nystagmus, sometimes being completely absent for several seconds (Figure 2) (Stahle 1958)

In the statistical analysis Student's *t*-test and the chi-square test with Yate's correction has been used (Baily 1973)

MATERIAL

The participants in this study were 47 patients with adolescent idiopathic scoliosis (AIS) with a single major structural curvature They were referred to the Department of Orthopaedic Surgery I, Sahlgren hospital, during 1975 and 1976 The control group comprised 30 non-scoliotic, healthy subjects in the same age group and with about the same sex ratio (Table 1) The controls were randomly recruited from a mas of healthy children previously described Petersen & Eeg-Olofsson (1971). The reason this recruitment of controls was that t children had been very carefully examined e regarding their history and their som neurological status

The patients were subgrouped with regar the magnitude and convexity of the curv (Table 2) The magnitude of the scolios classified with regard to whether the defor required treatment or not As a rule the indic for treatment (brace or surgery) was a curv of more than 20° (Cobb 1948) in a patient skeletally immature Two patients who requir brace and who both had a curvature of 17° the only exceptions to this rule Eight pat required surgery The two different subgr requiring treatment were analysed together the patients participated in this investigation to any treatment

Nine scoliotics with double-primary curv constituted a fifth subgroup in this study was analysed separately These patients had curvatures of major degree, both with struc changes The classification of these pa follows the definition proposed by the Sco Research Society (1976)

All the subjects had been extensively vestigated as regards past history and b thorough somatic investigation emphasizing neurological status according to a special sch None was taking any drugs and all abstained using tobacco or coffee on the day of th vestigation

Table 1 Material

	Scoliotics *Single curves*	Controls
Number	47	30
Mean age (years ± SD)	13 4 ± 1 6	13.5 ± 2.4
Age range	10–16	10–16
Sex ratio ♂/♀	8/39 (17% ♂)	4/26 (13% ♂)

Table 2 Subgrouping of the scoliotics with regard to magnitude and convexity of the curve

	Patients placed under observation	Patients requiring treatment	Total
Right convex single curves	9	16	25
Left convex single curves	11	11	22
Total	20	27	47

'SULTS

...tory and clinical investigation

There was no difference between the ...liotic patients and the controls when the ...swers to the questions about motion ...kness were analysed The scoliotic patients ...d nystagmus in the posture test or values ...side the reference values in the caloric test ...d not differ from the other patients in this ...pect The frequency of a history of otitis ...dia was the same in the scoliotic patients ...n the controls.

...ture tests

...pontaneous nystagmus was observed in ...n cases Positional nystagmus was ...ent in 17 patients and in all of them the ...tagmus was direction-fixed The only ...ption was one patient who had ...agmus beating towards the left in ...tions 1, 3 and 5 and changing between ...and right in position 4 All of the patients ...PN, except one patient with nystagmus ...in position 1, had nystagmus in at least ...positions. The total frequency of patients ...nystagmus in the posture test was 51 per cent

In the control group there was only one subject with PN and it was direction-fixed None had SN The difference between the scoliotics and the controls is significant ($P < 0.001$)

The frequency of patients with nystagmus in the posture test was statistically independent of the convexity or magnitude of the scoliosis (Table 3) No correlation was found between the convexity of the curvature and the direction of nystagmus in posture tests (Table 4) When nystagmus was present in posture tests in patients with left convex scoliosis the nystagmus reaction was, however, directed to the left in 12 cases out of 14

Caloric test

Differences in sensitivity between right and left labyrinths In the control group the mean difference in the sensitivity between the right and left labyrinths was 3 7 per cent

The mean difference in patients with convex curvatures was 8 6 per cent and with left convex curvatures it was −4 0 per cent There was no significant difference between

...e 3 Number of patients with nystagmus in the posture test in relation to magnitude and convexity of the scoliosis + denotes presence of nystagmus — absence of nystagmus

	Right convex		Left convex		Total	
	+	−	+	−	+	−
...nts placed ...observation	3	6	6	5	9	11
...nts requiring ...ment	7	9	8	3	15	12
...l	10	15	14	8	24	23

...e 4 Relation between convexity of the curve and direction of nystagmus in the 24 patients with nystagmus in the posture test

		Nystagmus-direction	
		Right	Left
	Right	4	6
...vexity	Left	2	12

the patients and the control subjects as regards peripheral sensitivity However, the right convex scoliotics differed significantly from the left convex scoliotics (Tables 5 and 7) These tables also show that the magnitude of the curvature did not significantly increase the observed difference Ten patients had values outside the reference values

Differences between right and left-beat nystagmus In the controls the mean value the difference between right and le beating nystagmus was −3 3 per cent (Ta 6) There was no difference between rig and left-beating nystagmus when pa with right or left convex scoliosis w compared with the controls (Table 7) Ne

[illegible] Mean values (M) a

	Right labyrinth M ± SEM degrees/second	Left labyrinth M ± SEM degrees/second	Difference M ± SEM* per cent
Right convex scoliotics	33 4 ± 1 6	29 2 ± 1 7	8 6 ± 1 9
Placed under observation	32 2 ± 1 3	29 3 ± 2 1	6.1 ± 2.3
Requiring treatment	34 0 ± 2 6	28 9 ± 2.3	10 0 ± 2.9
Left convex scoliotics	30 8 ± 2 0	33 3 ± 2.1	−4 0 ± 2.7
Placed under observation	26 7 ± 2 7	28 1 ± 2.9	−2.5 ± 4.5
Requiring treatment	34 9 ± 2.7	38 6 ± 2.7	−5 6 ± 3.4
Double primary scoliotics	32.1 ± 6 4	29 3 ± 4 3	2.9 ± 5 6
Controls	35 9 ± 3 0	32.5 ± 2.2	3.7 ± 1 8

* Positive value means right sensitivity dominance and negative value means left sensitivity domin

able 6 Right and left beating nystagmus in scoliotics and controls Mean values (M) and standard erro the means (SEM) are expressed in degrees/second and differences in percentage of the total reactio calculated according to Jongkees & Philipszoon (1964)

	Right beating M ± SEM degrees/second	Left beating M ± SEM degrees/second	Difference M ± SEM* per cent
Right convex scoliotics	30 7 ± 2.8	31 5 ± 3 1	−4 6 ± 4 0
Placed under observation	27 7 ± 2 7	32.9 ± 2.6	−8.7 ± 4 3
Requiring treatment	32.4 ± 4 1	30 7 ± 2.5	−2.7 ± 5 9
Left convex scoliotics	31 6 ± 2.9	32.5 ± 2.9	−0.6 ± 4 0
Placed under observation	27 7 ± 3 5	27 2 ± 3 8	2.4 ± 5 9
Requiring treatment	35 5 ± 4 5	39 9 ± 4 0	−6.4 ± 4 4
Double primary scoliotics	28 5 ± 4 9	33 0 ± 5 9	−6.6 ± 6.9
Controls	32.5 ± 2.4	35 8 ± 2.9	−3.3 ± 2.6

* Positive value means right beat ng dominance and negative value means left-bearing do ce

*Table 7 Summary of statistical analyses**

	Posture test	Caloric test		
		Right/left labyrinthine sensitivity	Right/left-beating nystagmus	Dysrhythmia
s single curves	$P < 0.001$			$P < 0.05$
ntrols right convex scoliotics	$P < 0.01$	NS	NS	$P < 0.01$
ntrols/left convex scoliotics	$P < 0.001$	NS	NS	NS
ntrols/double primary curves		NS	NS	
ht/left convex scoliotics	NS	$P < 0.05$	NS	NS
ents placed under ervation/patients uring treatment				
ngle curves	NS			NS
ght convex curves		NS	NS	
ft convex curves		NS	NS	

fferences between the groups were investigated by means of Student's t test at the 5 per cent level of ificance
– Not significant

there any difference between the patients right and left convex scoliosis.
ight patients had values outside the rence values and nystagmus was noted in n of these in the posture test Nystagmus, was present in both of these tests, ys had the same direction

rhythmia Dysrhythmia was observed in coliotics (28 per cent) and in 2 controls (6 cent) The difference is statistically ificant ($P < 0.05$) No difference in the uency of dysrhythmia was found in tion to the magnitude of the curvature of the patients with dysrhythmia had a t convex and three a left convex scoliosis, difference is not statistically significant

patients with double primary curvatures

three patients nystagmus was noted in posture test There was no difference een the control subjects and patients with double primary curvatures regarding sensitivity between right and left labyrinth or right- and left-beating nystagmus Dysrhythmia was only present in one patient

DISCUSSION

Yamada & Yamamoto (1972) have previously studied vestibular function in scoliosis About 100 patients with scoliosis of varying aetiology were given a vertical writing test and spontaneous or positional nystagmus was measured using Fresnel's glasses However, Fresnel's glasses are considered a rather insensitive means of testing nystagmus (Aschan et al 1956) Yamada & Yamamoto's tests did not include any caloric stimulation. From their results they concluded that the scoliotics did not have any demonstrable peripheral vestibular dysfunction

In this study we have used ENG to find out whether the vestibular function differs in

a group of children with idiopathic scoliosis and a group of control children without deformed spines

The vestibular function was tested with caloric bithermal stimulation, which is currently a principal method for testing labyrinthine function This is an important basic test and is superior to the rotary test because it enables each labyrinth to be tested independently (Stahle 1958) It has also been suggested that the value of rotatory testing is slight, since it rarely provides information that can not be obtained by the caloric test (Stahle 1958)

The registration of the nystagmus using the ENG is a well-known method with obvious advantages (Stahle 1958) The nystagmus reaction after caloric tests can be evaluated with regard to duration and intensity parameters, i e frequency, total amplitude, and maximum intensity The intensity parameters are a more sensitive means of diagnosing labyrinthine dysfunction than duration (Stahle 1958) The frequency, total amplitude, and maximum intensity usually give similar results and an investigation can therefore be simplified to include analysis of only one of these parameters (Stahle 1958)

or our investigation we chose the maximum ensity, i e velocity in the slow phase at the ak of the reaction, as it is the most frequently used intensity parameter

In order to analyse the results of our study we had to compare the responses of the patients with those of a control group consisting of subjects of the same age and sex as the scoliotics.

Differences in vestibular function between children with AIS and control children

Twenty-four of the 47 patients had nystagmus in the posture test compared to only one of the control subjects.

The observation of this nystagmus indicates the presence of a vestibular dysfunction (Norré 1975, Stahle 1958) As the frequency of nystagmus in the posture test was significantly increased in the scoliotics compared to the controls it may be taken as evidence of a vestibular imbalance in t scoliotic patients.

A dysrhythmic nystagmus reaction w found significantly more often t scoliotics. An analysis reveals that it is mai the right convex patients who have th reactions. The interpretation of this di turbance in nystagmus rhythm may l difficult (Henriksson & Nilsson 1975). S ah (1958) observed this phenomenon only e ceptionally in cases with peripheral lesion Dysrhythmia may indicate either a low lev of alertness or a disorder in the brain ste (Henriksson & Nilsson 1975). It is difficult t understand why our scoliotics should hav been more sleepy than the controls, as th conditions and test procedure were the sa for all subjects participating in this stud Thus, the right convex patients may possib for some unknown reason, have a disorder the brain stem

Relationship between convexity of the curvatu and vestibular asymmetries

In the posture test there was no statistic relationship between the direction of th convexity and the nystagmus reactio Twelve patients out of fourteen with le convex scoliosis, however, also had a le beating nystagmus in the posture test.

It is interesting to note that the right a left convex scoliotics had significan different patterns in the caloric test. Th patients with the convexity to the right had sensitivity predominance in the ri labyrinth and the left convex patients had sensitivity predominance in the left labyrin We can therefore establish that they differ in their pattern of reaction to a calor stimulus and that there is a clear side correl tion between the convexity and the predom nant labyrinth

These findings indicate the possibl an asymmetric postural tone in the tru during conditions when the labyrinths a exposed to stimulation The presence nystagmus in the posture test suggests th possibility even at rest

Is the vestibular dysfunction primary or is it secondary to the scoliosis?

Yamada et al. (1969) suggested the presence of a positive feed-back mechanism between the proprioceptors of the trunk and the equilibrium centre in the brain stem in scoliosis. They observed an improvement of a disordered optokinetic nystagmus after active correction of a scoliotic curvature or after a change of posture, from standing or sitting to the supine position.

In our patients a significantly higher frequency of nystagmus was found in the posture test During and after labyrinthine dysfunction nystagmus can be observed in the posture test When the dysfunction is compensated for the nystagmus often disappears. A unilateral peripheral vestibular lesion can be compensated for by a specific vestibular phenomenon called accommodation and a non specific vestibular phenomenon (Pfaltz & Kimath 1970) Spontaneous nystagmus after labyrinthectomy, however, may persist for many years even in young individuals (Lachan et al 1956) Spontaneous and positional nystagmus can also be a symptom of a central vestibular disorder (Uemura & Cohen 1972)

We do not know whether any compensatory mechanisms are operating in our patients or whether a vestibular imbalance can be compensated for to a certain degree There might be some peripheral vestibular imbalance remaining which caused a nystagmus in the posture test. We must, however, consider both a central and a peripheral origin if the observed vestibular dysfunction is primary and a contributory factor to the idiopathic curvature

Patients with disorders of the neck can have a very slight spontaneous nystagmus or have positional nystagmus (Jongkees 1969). These patients also have other symptoms such as tinnitus, variable deafness and symptoms from the cervical spine such as stiffness and pain None of our scoliotic patients presented with these clinical symptoms. Moreover, patients with cervically induced nystagmus in the posture test hardly ever show any significant differences in the caloric test (Jongkees 1969) In the scoliotics we found significantly different asymmetries in the sensitivity of the labyrinth

Anatomical observations have shown that spinovestibular pathways originate mainly from the lumbo-sacral level of the spinal cord and terminate in the medial and descending vestibular nuclei (Pompeiano 1972) The spinal influence on the vestibular nuclei is mainly an excitatory one This response is rather generalized, since it involves the neurons of the vestibular nuclei complex on both sides.

A feed back from the proprioceptors in the intervertebral joints and in the soft tissues surrounding the deformed spine might therefore be possible In that case, one would expect a higher frequency of nystagmus in the posture test among the scoliotics who had a more pronounced curvature, i e among patients requiring treatment. However, there was no difference between patients with curvatures requiring treatment and those not requiring treatment Neither was there any consistent and statistical correlation between the direction of the deformity and the nystagmus Nor did the magnitude seem to influence the results of the caloric tests, although there is a non-significant tendency towards a more pronounced mean difference between right and left labyrinthine sensitivity for patients requiring treatment

An analysis of the double primary curvatures did not elucidate the question of cause and effect The patients in this group did not differ from the controls in right- and left beating nystagmus. The peripheral sensitivity was exactly the same as in the controls The explanation for this result may be that the impulses from their two structural curvatures which are of equal size but in different directions, counterbalance each other when the afferent information from the proprioceptors in the trunk reaches the brain stem If the vestibular dysfunction were primary in these cases, the disturbance must

obviously already have been compensated for

It is also possible that a vestibular imbalance, of hitherto unknown origin acted initially as a trigger mechanism for the idiopathic curvature After a period this imbalance might be compensated for and the curvature continues to progress for other reasons This might cause an equilibrium disturbance calling for a change in central vestibular mechanisms If this development is possible, we have to consider at what stage in the scoliosis disease we are investigating the vestibular function An injury to the peripheral vestibular end organ may be a complication in connection with delivery due to anoxia, icterus neonatorum, and rubeola-embryopathy (Stahle 1977, personal communication) When delivery files were studied in the subjects participating in this study two patients were found to have had vacuum extractions and one patient had had icterus neonatorum No rubeola-embryopathy was revealed In these three patients signs of vestibular dysfunction were observed Thus, there was a possible explanation for a vestibular imbalance in these few patients In the other patients who showed signs of vestibular dysfunction there is nothing obvious in the past history to explain a primary vestibular imbalance The control children did not have any of the mentioned complications in connection with birth, nor any other disease in the past known to affect the vestibular apparatus.

To sum up, it is difficult to draw any definite conclusions as to whether a vestibular imbalance may be a contributory factor to adolescent idiopathic scoliosis or whether the vestibular findings are secondary to the deformity of the spine

ACKNOWLEDGEMENT

This investigation was supported by grants from The Swedish Medical Research Council (Proj B76-29X-04553-02) Greta och Finar Askers Stiftelse and Stiftelsen Sigurd och Elsa Goljes Minne

REFERENCES

Aschan G Bergstedt, M & Stahle J (195 Nystagmography recording of nystagmus clinical neuro-otological examinations *Acta ot laryng (Stockh)* Suppl 129

F

I

vestibular system Ed. Naunton, R. F p 303–319 Academic Press, London.

C

Fitzgerald G & Hallpike C. S (1942) Studies i human vestibular function *Brain* 65, 115

Fredricksson J M Schwarz D & Kornhuber H H (1966) Convergence and interaction of vestibul and deep somatic afferents upon neurons in t vestibular nuclei of the cat *Acta oto-laryn (Stockh)* 61, 168–188

Fukuda T (1959) The stepping test (two phases the labyrinthine reflex) *Acta oto-laryng (Stock* 50, 95–108

Guyton A (1976) Organ physiology *Structure a function of the nervous system* W B Saunde Co London

Henriksson, N G Dolowitz D A. & Forssman, (1962) Studies of cristospinal reflex (laterotorsion) *Acta oto-laryng (Stockh.)* 33–40

Henriksson N G & Nilsson A (1975) Plas dynamic properties of the vestibulo-ocular s *Basic mechanisms of ocular motility and th clinical implications*, Wennergrens Cen International Symposium Series, Vol. 24 247–260 Pergamon Press, Elmsford, N Y

Jongkees L B W (1969) Cervical ver *Laryngoscope* (St Louis) 79, 1473–1484

Jongkees L B W & Philipszoon, A. J (19 Electronystagmography *Acta oto-lary (Stockh)* Suppl 189–191 1–109

Norré M (1975) The diagnostic and ENG record in the evaluation of a spontaneous nystagm *Acta oto-rhino-laryng belg* 29, 555 564

Petersen I & Eeg-Olofsson, O (1971) The devel ment of the electroencephalogram in nor children from the age of 1 through 15 ye *Neuropadiatrie* 3, 247–304

Pfaltz, C. R & Kamath, R (1970) Central co pensation of vestibular dysfunction. *Pract. o rhinolaryng (Basel)* 32, 335–349

Pompeiano O (1972) Spinovestibular rela Anatomical and physiological aspects B aspects of central vestibular mechan ms P *Brain Res* 37, 263–296.

-Macclure, J (1964) Caloric tests Methods and interpretation *Ann Otol (St Louis)* 73, 829–837

-ts, T D M (1967) *Neurophysiology of postural mechanisms* Butterworths, London

-, J (1958) Electro-nystagmography in the clinic and rotatory tests. *Acta oto-laryng (Stockh.)* Suppl 137

-k, V & Kahn, A (1960) Vestibular lateropulsion. *Ann. Otol (St Louis)* 69, 61–72

-ura, T & Cohen, B (1972) Vestibulo-ocular reflexes. Effects of vestibular nuclear lesions. Basic aspects of central vestibular mechanisms. *Prog Brain Res* 37, 515–527

Wodak, E & Fischer, M H (1923) Vestibulare Körperreflexe und Reaktionsbewegungen beim Menschen *Klin Wschr* 2, 1802–1804

Yamada, K & Yamamoto, H (1972) Equilibrium function in scoliosis and active corrective plaster jacket for treatment The Amer Digest of Foreign Orthop Literature, Third Quarter, 182–185

Ya

-respondence to Tage Sahlstrand, M D, Department of Orthopaedic Surgery I, Sahlgren -ospital, University of Goteborg, S-413 45 Göteborg, Sweden

rthop. scand. 50, 771–775, 1979

OSTURAL EFFECTS ON NYSTAGMUS RESPONSE DURING CALORIC LABYRINTHINE STIMULATION IN PATIENTS WITH ADOLESCENT IDIOPATHIC SCOLIOSIS

II An Electro-Nystagmographic Study

ICE SAHLSTREND & BJÖRN PETRUSON

Departments of Orthopaedic Surgery I and Otorhinolaryngology, Sahlgren Hospital, University of Gothenburg Goteborg, Sweden

An electro-nystagmographic study of postural effects on the nystagmus response has been performed in 40 patients with adolescent idiopathic scoliosis aged from 10 to 16 years. The control group comprised 29 healthy children of the same age Caloric labyrinthine stimulation was done in the supine and erect position. The results were analysed with the aim of finding out whether an increased scoliotic deformity might influence the labyrinthine response For comparison of the nystagmus response in the two different positions a quotient of the values (degrees/second) obtained from cold water stimulation in the erect and supine position was calculated. In the control children the labyrinthine response in erect posture was half of the response in supine posture

In erect posture the scoliotic deformity increased This obvious change in the spine did not increase the caloric response from the convex side labyrinth The predominance of the convex side labyrinth observed in the supine position was thus not seen in the erect position

The results of this study did not support the assumption that a postural deformity in the spine can influence a calorically induced labyrinthine response

Key words aetiology, electronystagmography, nystagmus, posture, scoliosis

Accepted 1 11 79

In a previous study (Sahlstrand & Petruson 1979) it was found that right and left convex scoliotics had significantly different patterns of response in caloric tests of vestibular function The patients with the convexity to the right had a predominant sensitivity in the right labyrinth and the left convex patients had a predominant sensitivity in the left labyrinth Thus, there seemed to be a clear relationship between the convexity and the more dominant labyrinth It was difficult, however, to draw any conclusions as to whether this asymmetry was a causative factor in relation to the idiopathic curvature or whether it might be a feed-back effect from the deformed spine

Caloric stimulation of the labyrinth is usually done in the supine position After vestibular stimulation in erect posture there is a decreased response on both sides which can be explained by the orientation of the affective semicircular canal with response to the gravity vector (Proctor 1975) A scoliotic patient becomes more deformed in the spine

01-6470/79 060771-05$02.50.0

© 1979 Munksgaard Copenhagen

when changing from the supine to the erect position We do not know of any other asymmetric change that occurs when the patient alters his posture In this study caloric vestibular stimulation has been performed in the supine and erect positions in an attempt to find out whether a change in posture influences the vestibular response differently in scoliotics compared to controls. This might be due to a changed asymmetry in the trunk and an altered asymmetric postural tone in the spine

METHODS

[illegible]

subjects had been stimulated in the supine position an interval of at least 1 hour was allowed before stimulation in the erect position After this period none of the tested subjects had vertigo or nausea

The recording was performed with the subject standing on a platform with his head straight forward making the direction of the gaze horizontal i e the horizontal semicircular canal was at an angle of about 30 degrees to the horizontal plane The subjects had their eyes closed If the subject experienced a strong instability during the stimulation he could support himself with his hands against a surrounding barrier

The Mingograph was calibrated before the ENG in erect posture was begun The syringing was done first in the left ear and then in the right ear for 30 seconds with cold water (30°) and using a volume of 100 cm³ Registration of nystagmus started simultaneously with the syringing and was continued for 210 seconds. The time interval between the syringing was 10 minutes

Nystagmus was analysed with regard to direction and maximum intensity

The following variables were recorded during the tests

I Subjective reaction
1) None
2) Vertigo
3) Vertigo + nausea
4) Vertigo + nausea + vomiting
5) Test interrupted because of severe subjective discomfort

II Need for support
1) One hand
2) Two hands
3) Not able to remain the platform

III Rotation
1) None
2) Head
3) Head + shoulders
4) Head + shoulders + trunk

[illegible]

stimulated side

For comparison of the nystagmus response in t two different positions, we calculated a quotient the values (degrees/second) obtained from the c water stimulation in the erect and the sup position

$$\frac{\text{stimulation erect}}{\text{stimulation supine}} \times 100\% = \text{quotient erect sup}$$

In the statistical analysis Student's *t* test and c square test have been used (Bailey 1973)

MATERIAL

This study included 40 children with adolesc idiopathic scoliosis (AIS), all of them with a sm major structural curvature The material has b described in a previous paper (Sahlstrand Petruson 1979) Five patients from that were not able to tolerate continued ca stimulation in erect posture because of persis vertigo or nausea after the caloric test in supine position One patient discontinued study during stimulation of the right labyrin erect posture and one patient was excl because the amplitude of the nystagmus re did not exceed 2 mm during left labyrint stimulation

Eight scoliotics with double primary curv are included as a subgroup and are ana separately One further patient was excl because of persisting vertigo and nausea after caloric test in the supine position

The control group comprised 29 children F the controls presented in the original resea study one subject was excluded bec amplitude of the nystagmus did not exceed 2 during left labyrinthine stimulation.

RESULTS

There was no significant difference betw the scoliotics and controls regarding subjective reaction after caloric[illegible] in

Nystagmus response (degrees/second) in supine and erect posture Mean values and standard errors of the means

	Supine		Erect	
	Right	Left	Right	Left
Right convex scoliotics	21 4 ± 1 3	18 7 ± 1 9	8 6 ± 1 0	7 5 ± 0 7
Placed under observation	22.4 ± 1 9	17 7 ± 2 8	9 2 ± 1 7	7 1 + 0 6
Requiring treatment	20 8 ± 1 5	19 2 ± 2.1	8 3 ± 1 0	7 7 ± 0 8
Left convex scoliotics	20 5 ± 2.1	21 3 ± 2.2	13 2 ± 2.9	8 7 + 1 3
Placed under observation	16 0 ± 2.5	16 9 ± 2 4	12 0 ± 3 0	8 7 + 1 6
Requiring treatment	25 1 ± 2.1	25 7 ± 2.2	14 2 ± 3 1	8 8 ± 1 1
Double primary scoliotics	23 3 ± 5 1	19 6 ± 3 0	8 8 ± 0 7	7 6 ± 2.7
Controls	22.9 ± 2.2	19 7 ± 1 5	10 1 ± 0 9	9 2 + 0 9

position Neither did they differ regarding the visually estimated rotation effect. A need for support with one or two hands against the barrier was noted in nine of the patients and in one of the controls ($P < 0.05$).

Results in absolute values (degrees/second) and relative values (i e nystagmus quotient in per cent) are shown in Tables 1 and 2

Table 2 The quotient of the values of nystagmus intensity in erect and supine posture Mean values and standard errors of the means

	Right labyrinth stimulation %	Left labyrinth stimulation %
Right convex scoliotics	40 ± 4	50 ± 6
Placed under observation	40 ± 9	42 ± 4
Requiring treatment	40 ± 8	54 ± 8
Left convex scoliotics	67 + 10	47 ± 7
Placed under observation	68 + 12	63 ± 13
Requiring treatment	67 + 17	33 ± 4
Double primary scoliotics	52 ± 7	45 ± 5
Controls	46 + 3	50 ± 4

Nystagmus quotient in right labyrinthine stimulation

the controls the quotient was 46 per cent the patients with right convex scoliosis the quotient was 40 per cent and in those with left convex scoliosis it was 67 per cent (Table 2) The statistical analysis showed a difference ($P < 0.05$) between controls and patients with left convex curvatures The right convex scoliotics did not differ significantly from the controls but differed from the left convex scoliotics ($P < 0.05$)

Nystagmus quotient in left labyrinthine stimulation

In the control group the quotient was 50 per cent In patients with right convex scoliosis the quotient was 50 per cent and in those with left convex scoliosis it was 47 per cent There was no difference in the quotient between the controls and right and left convex scoliotics (Table 2)

When the patients were subgrouped the patients with left convex curvatures requiring treatment had a significantly ($P < 0.05$) lower quotient than the controls and the right convex scoliotics.

DISCUSSION

The aim of this investigation was to find answers to the following questions

1 Does an increased lateral rotatory deformity of the spine influence the vestibular system?

2. Does vestibular dysfunction in some way contribute to idiopathic scoliosis?

In this study we have compared labyrinthine stimulation in the erect and

supine position In the controls the nystagmus response during vestibular stimulation in the erect position was half of the response in the supine position This might be due to the change in position of the lateral semi-circular canal The inclination from the horizontal plane is 30 degrees in the upright position compared to 60 degrees in the supine position with the head in anteflexion (Jongkees 1975)

When the patients change from the supine to the erect position the scoliotic deformity increases. This change might influence labyrinthine responses via spinovestibular pathways In the right convex patients the quotient of the values of reactions in erect and supine position was 6 per cent lower than in the controls during stimulation of the right side (Table 2) This difference was not significant After calorisation on the left side, i e the concave side, there was no difference at all These results indicate that an erect posture and an increased right convex curvature did not influence the vestibular response after caloric stimulation.

In the left convex group patients requiring treatment had a significantly smaller quotient for left side stimulation The patients only placed under observation had, as a group, a higher quotient because two patients had values above 100 These high quotients are difficult to explain When the labyrinth on the concave side was stimulated there was a significantly larger quotient when all left scoliotics were compared to the controls. In the patients with left convex scoliosis the results of the vestibular stimulation were thus somewhat different from the right convex scoliotics.

From the results of this study and the findings from the previous study (Sahlstrand & Petruson 1979) we draw the following conclusions

1 Such an obvious change in the spine as an increase in the deformity does not increase the quotient of the caloric response from the labyrinth on the convex side significantly In the left convex patients requiring treatment, the quotient of t caloric response instead decrea significantly (Table 2)
2 There is a tendency towards a hig quotient for concave side labyrinth stimulation in left convex patients T difference between right and left con scoliotic patients cannot be explai solely by the opposite direction of t scoliosis. The absolute values shown Table 1 indicate that this tendency seem to be explained by a higher concave s labyrinthine response in erect postu This finding may indicate some facilitat mechanism operating in left con patients under these conditions.

To summarize, in the supine position convex side labyrinth was predominant wh the labyrinth was tested with cold and wa water When the convex side was tested erect posture with cold water this p dominance was not observed Thus, increase in the scoliotic curvature in er posture did not increase the predominan This effect would have been expected if idiopathic scoliosis were able to influe labyrinthine sensitivity The results of t study, therefore indicate that the differen in labyrinthine response observed in previous study are more likely to be an eff of a primary vestibular imbalance On t basis of such as assumption, and in view the knowledge about the role vestibular sp mechanisms have in postural control, t observed vestibular asymmetries might a be a contributory causative factor in adol cent idiopathic scoliosis.

ACKNOWLEDGEMENT

This investigation was supported by grants fr The Swedish Medical Research Council (P B76–29X–04553–02), Greta och Einar Ad Stiftelse and Stiftelsen Sigurd och Elsa Go Minne

EFERENCES

Bailey N T J (1973) *Statistical methods in biology* Engl Universities Press, London

Cogdell, L. B W (1975) On the physiology and the examination of the vestibular labyrinths *The vestibular system*, pp 227–247, Ralph F Naunthon, N Y

Proctor, L R (1975) Testing the vestibular system Value of the caloric test *The vestibular system*, pp 249–260, Ralph F Naunthon, N Y

Sahlstrand, T & Petruson, B (1979) A study of labyrinthine function in patients with adolescent idiopathic scoliosis. *Acta orthop scand* **50**, 759–769

Correspondence to Tage Sahlstrand, M D, Department of Orthopaedic Surgery I Sahlgren Hospital, University of Goteborg, S-413 45 Göteborg, Sweden

rthop scand. 50, 777–785, 1979

CIAL REHABILITATION FOLLOWING P FRACTURES

TEEN JENSEN, E TØNDEVOLD & P HOVE SØRENSEN

rtments of Orthopaedic Surgery T-2 & T-3, Gentofte Hospital, enup and the Department of Orthopaedic Surgery O, leriksborg County Hospital, Hillerød, Denmark

A prospective 6 months' study of 518 patients with hip fractures was un-
d
a
d
This dependency increased with the age of the patients. Life tables for the case material showed that the mortality depended more on pre-fracture social function than on age

At the follow-up, the risk of death or increased social dependency among primarily independent patients was found to be 38 per cent compared with 48 per cent among slightly dependent patients and 62 per cent in moderately dependent patients. A total of 17 per cent of the surviving patients admitted from home became nursing home patients. The pre-fracture social assessment determined the end-result to a greater extent than the age at the time of fracture

About 75 per cent of the patients discharged to their homes maintained their social function compared with 68 per cent of the patients discharged to a convalescent home and 47 per cent of the patients discharged to rehabilitation clinics

Key words fractures, rehabilitation, femoral neck fractures, rehabilitation, femoral neck fractures, mortality

Accepted 29 m 79

ing the past few decades the average age the population in the Western countries increased, resulting in an increased ber of hip fractures (Jensen & Tøndevold, ress) According to Bauer (1977) the risk of taining a fracture of the hip doubles for ry 5-year increment of age after the fifth ade. This means, that one woman out of five ve the age of 80 years will sustain a hip cture

Much attention has been paid to the hn cal details concerning the treatment of hip fractures In dealing with geriatric orthopaedics, however, it is important to realize, that in the elderly loss of function means loss of independence (Devas 1974) In spite of this the problem of social rehabilitation including the way hip fractures affect the quality of life in the elderly is rarely discussed (Cobey et al 1976, Clark & Wainwright 1966, Katz et al 1964 and 1967, Thomas & Stevens 1974) We have therefore analysed our experience of social rehabilitation following hip fractures

1-6470/79 060777-09$02 50, 0

© 1979 Munksgaard Copenhagen

Table 2 The assessment of social function

	Social function groups	Definition
I	Independent	Manages everything Possibly working
II	Slightly dependent	Manages household Meals-on-wheels, Home-help ≤ 4 hours/week Manages personal needs
III	Moderately dependent	Home-help ≥ 5 hours/week Possibly District Nurse
IV	Totally dependent	Living in nursing home or long term nursing at home

Table 3 Assignment to social function groups on admission to hospital

Social function group	I	II	III	IV
Number	148	128	106	136
Percentage	28 6%	24 7%	20 5%	26 3%
Median age	69	79	81	84

ased dependence Thus, the mortality ng patients assigned to group III was e as high as that occurring in group II, ough the median ages were 81 and 79 s and the hospitalization times 33 and 30 , respectively

t the 6 months follow-up the mortality was 15 6 per cent (81/518) Figure 3 demonstrates that the mortality increased with increased dependence, as classified on admission, although the median age in the groups also increased Applying a Cox regression analysis the mortality was found to depend more on the pre-fracture social function than on the age of the patients ($P < 0\ 001$) A six times higher mortality was

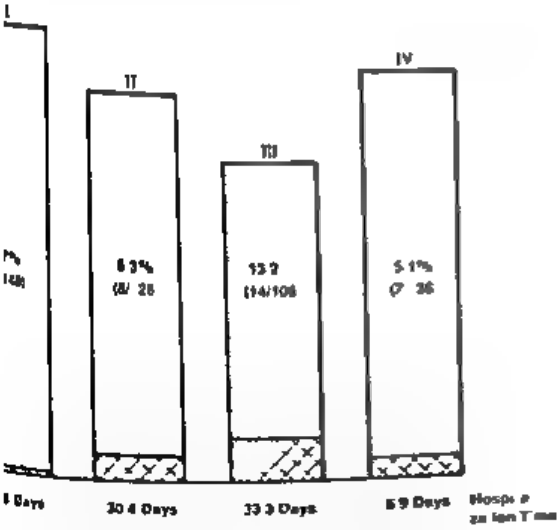

ure 2 Mortality in hospital related to pre-cture social groups Mortality rate 5 8 per cent 518)

percentages listed in the columns indicate the rtality in the different social function groups average hospitalization times for the four ups are listed below the columns

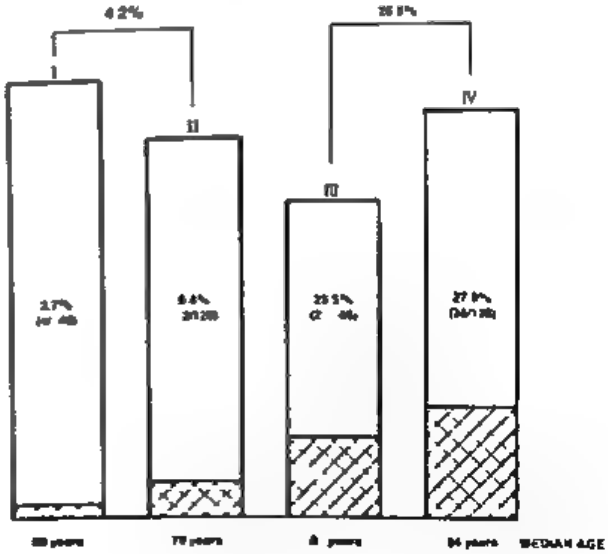

Figure 3 Mortality after 6 months related to pre-fracture social function groups Mortality rate 15 6 per cent (81/518)

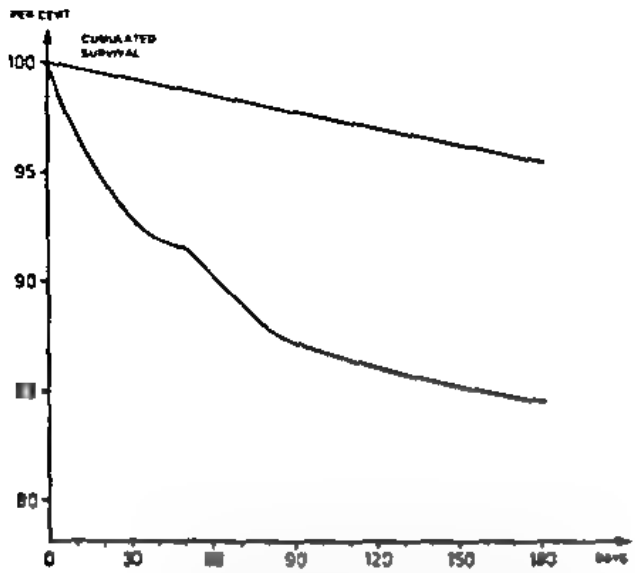

Figure 4 Life table for 518 patients with hip fractures The lower curve is the life table for the case material. The upper curve is the life table for a population of the same age and sex distribution.

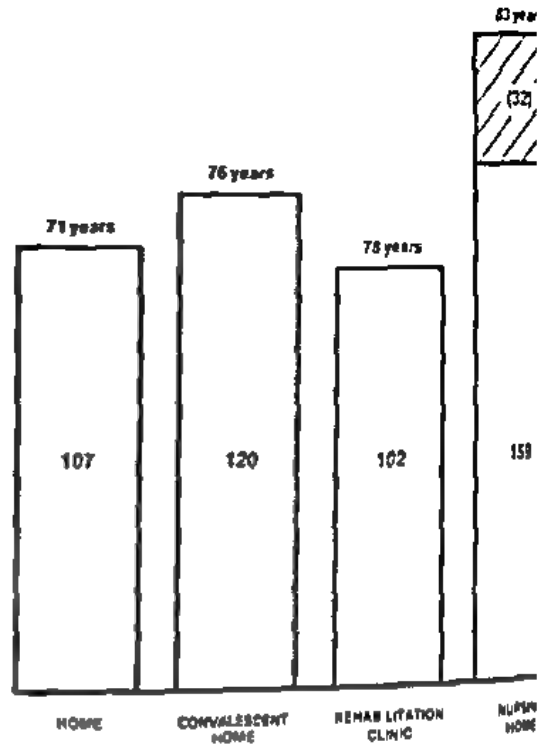

Figure 5 Placement after discharge from hosp after hip fracture in 488 patients (with indicatio median age)
Admitted from home 107+120+102+32 patients (One nursing home patient, admitted fr a rehabilitation clinic returned there)
Discharged to a nursing home 32/360 – 8 9 per ce

encountered among patients in groups III and IV compared with the two more independent groups.

The life table in Figure 4 illustrates that there was an initial high mortality rate within the first 3 weeks. After this the mortality rate decreased slowly with a temporary increase, however, between the 7th and the 11th weeks. This temporary increase was mainly caused by a cumulative high death rate among nursing home patients during the first 3 months after the fracture and also among patients in group III not yet discharged from hospital

According to Figure 5, 488 patients were discharged from hospital Among these were 360 patients admitted from home, 29 7 per cent (107/360) of the patients admitted from home returned directly home again, whereas 8 9 per cent (32/360) were discharged to nursing homes. Another 33 3 per cent (120/360) of the patients coming from home were discharged to a convalescent home, whilst 28 1 per cent (101/360) went to a rehabilitation clinic There was a slightly significant difference between the age groups going to the two types of institutions ($P < 0\ 05$, Mann-Whitney test)

Figure [illegible] shows the placement of patients after discharge from hospital relation to the pre-fracture social funct groups The majority of the patients (27/ admitted from home and discharged nursing homes were assigned to group III admission to hospital, whereas four were group II and one in group I There was significant difference ($P > 0\ 05$, Chi squ test) in the composition of the social funct groups between the two different types of stitutions for after-treatment Nearly tw thirds (66/107) of the patients discharged their own homes were assigned to group and only about 10 per cent (10/107) to gro III

Re-assessment of social function after months was performed in 437 cases, shown in Table 4 In group I we found 2 per cent (92/437) of the patients with median age of 65 years, whereas 22.9 per ce



Figure 6 Placement after discharge from hospital related to pre fracture social function groups in 488 patients with hip fractures

100/437) with a median age of 76 years were assigned to group II, 20 1 per cent (88/437) with a median age of 76 years to group III and 35 9 per cent (157/437) with a median age of 83 years to group IV The dependence on the social welfare system at follow-up thus increased with age ($P<0\ 0001$, Kruskall-Wallis test)

The deterioration of social function is also shown in Table 4 Of the 148 patients in group I pre-fracture 2 7 per cent (4/148) had died, 63 9 per cent (92/144) of the survivors had maintained their pre-fracture level of social function 23 6 per cent (34/144) had dropped one group and 11 1 per cent (16/144) two groups Two patients (1 4 per cent) became nursing home patients. The total risk of death or deterioration in group I was thus 37 8 per cent (56/148)

In group II 9 4 per cent (12/128) of the patients had died, 56 9 per cent (66/116) of the survivors maintained their pre-fracture level of social function 27 6 per cent (32/116) had dropped one group and 15 5 per cent (18/116) became nursing home patients The risk of death or deterioration was thus 48 4 per cent (62/128)

In group III the mortality was 25 5 per cent (27/106) Deterioration in this group meant nursing home placement, which was necessary in 49 4 per cent (39/79) of the survivors. The total risk of death or deterioration among patients primarily assessed in group III was thus 62 3 per cent (66/106)

Among patients admitted from home the risk of death was 11 2 per cent (43/383) and the risk of social deterioration 41 6 per cent (141/340) among survivors The risk of death or deterioration among patients admitted from home was thus 48 0 per cent (184/383)

Among 383 patients admitted from home, 340 survived for 6 months, 82 4 per cent (280/340) of these were back in their homes at the follow-up, although 29 3 per cent (82/280) were more dependent on the social welfare system than before the fracture

A multivariate logistic analysis has revealed that the pre-fracture social function groups determined the end-result to a greater extent than the age at the time of fracture The social function groups as assessed at the 6

Table 4 The deterioration of social function and the mortality 6 months after hip fracture

Fracture segment into social function groups	No of patients	No of deaths	Social function groups at 6 months follow-up: I	II	III	IV	Risk of death or Deterioration of social function
I	148	4 (2.7%)	92 (63 9%)	34 (23 6%)	16 (11 1%)	2 (1 4%)	56/148 = 37 8%
II	128	12 (9 4%)		66 (56 9%)	32 (27 6%)	18 (15 5%)	62/128 = 48 4%
III	106	27 (25 5%)			40 (50 6%)	39 (49 4%)	66/106 = 62.3%
IV	136	38 (27 9%)				98	38/136 = 27 9%
	518	81 (15 6%)	92 (21 1%)	100 (22.9%)	88 (20 1%)	157 (35 9%)	222/518 = 42.9%

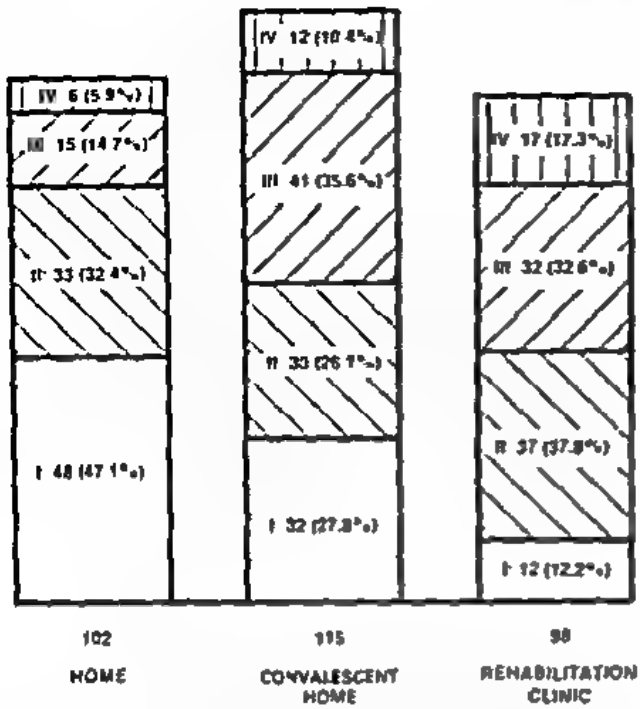

Figure 7 Social function groups at the 6 months follow-up of 315 hip fracture patients related to the placement after discharge from hospital

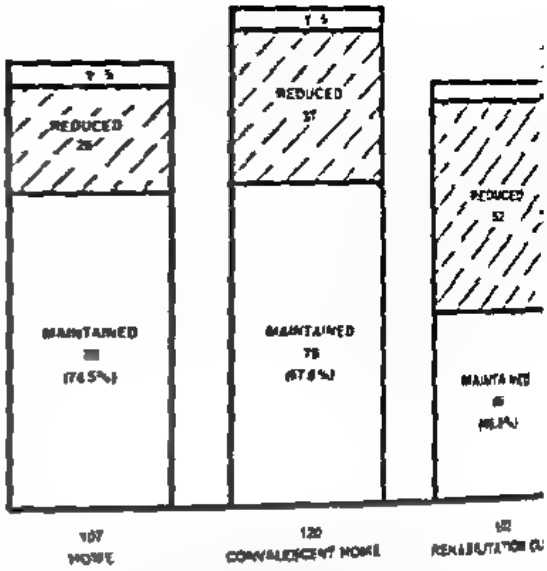

Figure 8 The social function at the 6 months follo up related to the pre-fracture assessment and to t placement after discharge from hospital.

months follow-up are related to the placement of the patients after discharge from hospital in Figure 7 Only six of the patients discharged to their homes were nursing home patients at the follow-up, including one patient who was assigned to group IV on admission to hospital Thus 5 0 per cent (5/101) of the patients discharged to their homes had become nursing home patients during the 6 month period. Among the patients discharged to convalescent homes 10 4 per cent (12/115) became nursing home patients compared with 16 5 per cent (16/97) of the patients discharged to rehabilitation clinics, into which group one patient was already assigned pre-fracture The risk of becoming a nursing home patient was thus found to be significantly higher ($P < 0\ 0001$, Chi-square test) for patients discharged to rehabilitation clinics.

The risk of social deterioration related to placement after discharge from hospital is summarized in Figure 8 Among survivors discharged from hospital directly to their homes 74.5 per cent (76/102) had maintained their social function at follow-up 6 months after the fracture. By comparison 67 8 per cent (78/115) of the patients discharged convalescent homes maintained their functi but this applied to only 46 9 per cent (46/ of those discharged to rehabilitation clin These differences are highly signifi ($P < 0\ 005$, Chi-square test)

Technical failures after the treatment femoral neck fractures were encountered 15 2 per cent (34/223) of cases. The risk social deterioration among survivors was 5 per cent (17/33) compared with 27 3 per c (44/161) in uncomplicated cases ($P < 0$ Chi-square test) Following the treatment trochanteric fractures a technical failure r of 5 8 per cent (17/295) was recorded. T risk of social deterioration was 37 5 per c (6/16) among survivors following techn failures compared with 32 5 per cent (74/2 in uncomplicated cases, which is statistically different ($P > 0\ 05$, Chi-squ test)

DISCUSSION

The average hospitalization time of 23 d after hip fracture agrees well with figures gi in other recent studies (Ceder et al. 19 Jansson 1977, Jensen & Tøndevold 1979). T mortality rates seems to be slightly lo

in stated in previous studies (Alffram 1964, Cown & Miller 1976, Jensen & Tøndevold 979) however, in the present series all ients with hip fractures were considered, esulting in a slightly lower median age In a ner report (Jensen & Tøndevold 1979) he mortality after hip fracture was found to e related to age and sex In this series, owever the pre-fracture social function was cluded and found to influence the mortality a greater extent than the age and sex

As found by others (Beals 1972, Jensen & ndevold 1979) a secondary increase in ortality was observed between the 7th and th weeks after the fracture In earlier series it could not be explained, but in the present ies this secondary increase was found to be used by a prolonged high mortality among tients assigned to groups III and IV

About 30 per cent of the patients admitted om home returned directly to their homes milar results were stated by Gylling (1960), hile Ceder et al (1977) claimed 60 per cent, ark & Wainwright (1966) 86 per cent and degård & Unsgård (1978) 48 per cent As in her series from urban districts (Campbell 76 Gylling 1960) we used rehabilitation nics or convalescent homes to a great tent which is not as possible in rural areas e total consumption of resources is dealt th in another paper (Jensen et al 1979)

The number of patients admitted from me but discharged to nursing homes is viously of greater interest In our series is applied to about 9 per cent of the tients, which is slightly less than the 12–20 r cent stated by others (Campbell 1976 ark & Wainwright 1966, Gylling 1960) der et al (1977) and Ødegård & Unsgård 978) however, needed nursing home cilities in about 40 per cent of cases, but d not use rehabilitation institutions.

Very little has been published about the ects of hip fractures on social function In r series about 83 per cent of the surviving tients coming from home were back there 6 onths after the fracture, whereas the mainder were in nursing homes. These ures agree with those of Ceder et al (1977) whose series is from a rural district Among these patients about two-thirds maintained their social function, as also mentioned by Thomas & Stevens (1974), while the remainder became more dependent on the social welfare system This is in accordance with the results of others (Campbell 1976, Ceder et al 1977, Clark & Wainwright 1966, Dolk & Westerborn 1977, Gylling 1960) In the present study, however, we found that the patients discharged directly to their homes were younger and less dependent on the social welfare system The risk of deterioration of social function was thus only about 25 per cent

Surprisingly enough we found the risk of deterioration of social function among patients discharged to rehabilitation clinics to be 53 per cent compared with 32 per cent for those discharged to a convalescent home with facilities for physical therapy The median age of the patients was however 78 years for those discharged to rehabilitation clinics compared with 76 years for those going to a convalescent home, but the composition of pre-fracture social groups was not significantly different

The rehabilitation clinics offer a significantly higher level of socio-medical care than do convalescent homes The costs of running the rehabilitation clinics are higher and the rehabilitation course is, in addition, considerably prolonged (Jensen et al. 1979) This social care system leads obviously to more support from home-help, meals-on-wheels and even the district nurse, which the patients are to a marked degree still dependent on 6 months after the fracture As stated by Devas (1974) loss of function in the elderly means loss of independence, and we are not sure that the increased dependence on social support as encountered in the patients discharged from rehabilitation clinics, improves the quality of life. As also mentioned by Jansson (1977) we feel that the goal for our treatment should be to bring the patient back to the pre-fracture level of function We therefore feel that the extended socio-medical care system as applied by the

rehabilitation clinics is of less benefit to patients with hip fractures and that more general benefit can be obtained from ordinary convalescent homes with facilities for physical therapy, other categories of patients can benefit more from the rehabilitation clinics and their facilities. Whether the increased number of patients requiring nursing home care following a stay at a rehabilitation clinic is a secondary effect of an increased passivity is of course an open question There is, however, no doubt that the need for some sort of rehabilitation institution is mandatory in the post fracture treatment of these rather feeble patients suffering from hip fractures. It is also obvious that it is extremely important to consider the entire rehabilitation course in dealing with patients in this category

The assessment system applied in this series, however, does not consider the walking ability or activities of daily living as is the case in assessment systems suggested by others (Cobey et al 1976 Katz et al 1964 and 1967) This might therefore favourably influence the results in comparison with those presented by Cobey et al (1976) and Katz et al (1967) who found that only 25–50 per cent of the patients maintained their function There is, however a clear relationship using our assessment system between a reduced independence at admission and the risk of death or deterioration of social function after fracture The assessment system presented here as originally described by Thomas & Stevens (1974) is thus found to be applicable in the evaluation of the patients future needs and it can easily be applied by any member of the hospital staff

In conclusion we found based on a simple assessment system that risk of death or deterioration of social function for patients admitted from home with hip fractures can be estimated to be about 54 per cent

ACKNOWLEDGEMENTS

Gratitude is expressed to Leif Mortensen M Sc. Department for Data Processing Herlev Hospital, for invaluable help with the statistical analysis.

REFERENCES

Alffram E A (1964) An ep demiolog c stud cervical and trochanteric fractures of the f in an urban population *Acta orthop sc* Suppl. 65

Bauer G (1977) *Vårdprogram för hoftfrak. hos aldre* pp 5–8 SPRI publ. No S Stockholm

Beals, R K. (1972) Survival following hip fra – long follow up of 607 patients. *J chron* 25, 235–244

Campbell A J (1976) Femoral neck fractur elderly women A prospective study *Age A* 5, 102–109

Ceder L Inerot S Lindberg L. Odberg Sjolin, C (1977) *Vårdprogram hoftfrakturer hos aldre* Ed Bauer G 54–56 SPRI publ. no S 73 Stockholm.

Clark A N G & Wainwright D (1966) Man ment of the fractured neck of the femur i elderly female *Geront clin. (Basel)* 321–326

Cobey J C. Cobey J H Conant L. Wei H Greenwald W F & Southwick, W (1976) Ind cators of recovery from fractur the hip *Clin Orthop* 117, 258–262

Devas, M B (1974) Geriatric orthopaedics. *med J* 1, 190–192

Dolk T & Westerborn O (1977) Komplikat och mortalitet i ett hoftfrakturmat *Lakartidn* 74, 3554–3558

Gylling B (1960) Collumfrakturen socialmedicinskt problem *Opuse (Stockh)* 5, 178–183

Jansson B W (1977) *Vårdprogram hoftfrakturer hos aldre* Ed Bauer G 65–66 SPRI publ no S 73 Stockholm.

Jensen J Steen & Tøndevold E. (1 Mortality after h p fractures. *Acta or scand* 50 161 167

Jensen J Steen & Tøndevold E. A p nostic evaluation of the hospital resou required for the treatment of hip fractures. *orthop scand* (In press)

Jensen J Steen Tøndevold E & Sorensen Hove (1979) Costs of treatment of fractures. *Acta orthop scand (In press)*

Katz S Ford A B Heiple K G & Newill A (1964) Studies of illness in the a Recovery after fracture of the h p *J Ge* 19, 285–293

Katz S Heiple K. G Downs, T D Ford, & Scott C P (1967) Long term course of patients with fracture of the hip *Surg Gy Obstet* 124, 1219–1230

McCown P L. & Miller W A (1976) Long follow up of hip fractures. *South med. (Bgham Ala)* 69, 1540–1542

O & Unsgård, G (1978) Social-
nske aspekter på patienter med
ørhalsbrudd *Nord Med.* 93, 16–18

Thomas, T G & Stevens, R S (1974) Social effects of fractures of the neck of the femur *Brit med J* 3, 456–458

Correspondence to J Steen Jensen, MD, Dept Orthop Surgery T-2, Gentofte Hospital, DK-2900 Hellerup, Denmark.

ca orthop scand. 50, 787–790 1979

REATMENT OF PATHOLOGICAL FRACTURES

IRS HEISTERBERG & TORBEN STAEHR JOHANSEN

partment of Orthopaedic Surgery, Gentofte Hospital, Copenhagen, Denmark

The treatment of 30 patients with 34 pathological fractures is reported Twenty-six femoral fractures and one ulnar fracture were fixed internally, whereas five fractures of the humerus, one of the radius, and one of the clavicle were treated non-operatively Twenty-two of the patients were discharged from hospital (21 were mobilized) and eight died in the postoperative period. All patients became free of pain and bony union occurred in 12 of the fractures. Thirteen per cent of the patients lived less than 1 month whereas 20 per cent lived more than 24 months after fracture *Previously published figures and our results indicate the place of prophylactic nailing of certain femoral metastases, perhaps also in connection with local irradiation of the metastases.*

Key words fractures, internal fixation, fractures, internal fixation, intramedullary, pathological fractures, prophylactic fixation of pathological fractures

Accepted 24 iv 79

he number of patients with pathological tures attending orthopaedic surgical artments can be expected to increase reover, there is presumably now a longer rival time after treatment for pathological tures. In order to promote healing of the tures, to relieve the patients of their pain, to mobilize them, we have used operative tment or plaster bandage followed by ibilitation and early discharge The object his paper has been to analyse the results his intensive treatment

IENTS AND METHODS

n 1971 to 1975 30 patients with pathological ures have been treated in the Department of opaedic Surgery in Gentofte Hospital. There 19 women and 11 men, and the age range from 38 to 90 years with a median of 69 The 30 patients were treated for a total of fractures. There were 26 fractures of the ur, five fractures of the humerus, one of the us, one of the ulna and one of the clavicle

The fractures of the lower extremities were treated with a McLaughlin nail, Jewett nail, Moore prosthesis, sliding nail, or AO intramedullary nailing The ulnar fracture was treated with a medullary screw whilst the remaining fractures of the upper extremities were immobilized in plaster The fracture of the clavicle was treated with the three-slings method

The type of primary tumour and the number and localization of the fractures are listed in Table 1 The primary diseases had started from 0 to 24 years prior to the fracture In three patients the fracture was the first symptom.

Four patients had received local radiation therapy *for metastases before the fracture* Two of these patients received radiation for femur

fracture within 1 month after the treatment had started and one patient with a mammary cancer and metastasis to the humerus had X-ray therapy and fractured the humerus within the following month.

In our material four patients received radiation in connection with the osteosynthesis. One patient with renal cancer was given cobalt radiation for

-6470/79/060787–04$02.50/0

© 1979 Munksgaard, C

demonstrated other bony metastases in 67.5 per cent of their operated patients] and considering the palliative nature of the operation, it seems reasonable to take this presumably slight risk

Thus, we may conclude that pathological fractures in general should be treated with internal fixation and that metastases to the femur, in selected cases, possibly should be treated by prophylactic nailing The value of local irradiation therapy for bony metastases before, as well as after, osteosynthesis is unclarified, though it may promote bony union

REFERENCES

Altman, H (1953) Metallic fixation for pathological fracture and impending fracture of long bones. *J int Coll Surg* **XIX**, 612–617

Beals, R K., Lawton, G D & Snell, W. E (1971) Prophylactic internal fixation of the femur in metastatic breast cancer *Cancer* **28**, 1350–1354

Bennish, E L & Hammond, G (1955) Treatment of actual and imminent pathological frac of the femur by intramedullary nailing *Clin N Amer* **35**, 865–872.

Bremner, R A & Jelliffe, A M (1958) management of pathological fracture of major long bones from metastatic cance *Bone Jt Surg* **40-B**, 652–659

Ehrenthaft, J L & Tidrick, R T (Intramedullary bone fixation in patholo fractures *Surg Gynec Obstet* **88**, 519–5

Fitts W T, Roberts H & Ravdin, I S (Fractures in metastatic carcinoma *Ame Surg* **85**, 282–289

Johnson, E W, (1957) Intramedullary fixati pathological fractures *J Amer med Ass* 417–419

Katzner, M, Petit, R & Schvingt E. (Traitement chirurgical des metastases fractures metastaques des os longs. *Rev orthop* **60**, 387–400

Koskinen, E V S & Nieminen, R A (Surgical treatment of metastatic fractu major long bones. *Acta orthop scand.* 539–549

Peltier, L F (1951) Theoretical hazards treatment of pathological fractures by Küntscher intramedullary nail *Surgery* 466–472

Correspondence to Lars Heisterberg, Åbrinken 24, 2830 Virum, Denmark

Acta orthop scand. 50 791–795, 1979

MENISCECTOMY IN CHILDREN

JYRKI VAHVANEN & KARI AALTO

Orthopaedic Children's Hospital, Helsinki, Finland

The results of 42 meniscectomies in 41 children were evaluated 1 to 1[illegible] years (mean 5 6 years) after the operation At the follow up 11 patients (1[illegible] operated knees) had complaints. In four of these patients all having ha[illegible]

operative treatment are presented

Key words children, meniscus, operative treatment, results

Accepted 22.iv 79

In large series of meniscectomies the percentage performed on children is low, for example, 1 5 (Springorum 1959) and 0 16 (Barucha 1967) Typical indications for meniscectomy in childhood are developmental lesions, discoid menisci, meniscal cysts ganglions and abnormally *mobile menisci* According to the authors cited above, these lesions account for 20–24 per cent of all meniscectomies in children, and for 15 5 per cent according to Jeannopoulos (1950)

In adult series a discoid meniscus has been reported to be the indication for surgery in only 2.2 per cent (Smillie 1948) and in 11 out of 16,239 meniscectomies (Barucha 1967) The results of meniscectomies in children seem to compare unfavourably with results in adults (Tapper & Hoover 1969) Among children post-operative complaints and roentgenological changes are frequent (Bhaduri & Glass 1972, Schultz 1973 Cotta 1976, Baryluk et al 1977) The results of this surgical treatment in children have been reported, moreover, to be influenced by the age of the patient, by the side of the knee from which the meniscus is excised and by the duration of preoperative symptoms (Bhaduri & Glass 1972, Cotta 1976) Because the diagnosis of the meniscal pathology, including the assessment of symptoms and arthrographic findings, is sometimes difficult, many unnecessary meniscectomies tend to be performed – with results that are not always acceptable (Ritchie 1965)

PATIENTS AND METHODS

In 1978 a clinical and roentgenological follow up examination was performed on 41 patients (42 knees) who had undergone [illegible] medial side in 22 knees and on the lateral side in 20 knees – in five of which the meniscus was discoid Seventeen operations were performed on the left knee, 25 on the right Antecedent injury to the knee was established with certainty for 36 knees. The interval between the initial symptoms and the operation was less than 6 months in 24

0001-6470/79/060791-05$02.50

© 1979 M[illegible]

knees, 6–12 months in 10 knees and longer than 12 months in 8 knees All patients had been examined preoperatively with contrast medium arthrography

Preoperative findings

The complaints of 16 patients corresponded to the classical triad of symptoms in meniscal lesions, i e pain, intermittent swelling and intermittent locking The most frequent preoperative complaint, however, was pain (Table 1)

Table 1 Preoperative subjective symptoms of 41 children (42 knees) who subsequently underwent a meniscectomy

Symptom	No of knees
Pain	39
Intermittent effusion	29
Snapping sensation	27
Feeling of the knee giving way	26
Intermittent locking	22
Acutely locked joint	3

At the time of the preoperative clinical examination the clinical finding was effusion in 21 knees, pain on extension in 11 knees, pain on palpation of the joint space in 11 knees, pain on flexion in 2 knees, gastrocnemius semimembranosus bursitis in one knee, and multiple exostoses on both knees one patient A combination of two or more of ese symptoms – listed above – was observed in 12 knees No clinical symptoms were found at the time of the preoperative examination in 12 knees, in spite of the presence of meniscal lesion in all but one knee – which was confirmed later at the operation

Operative findings

In 25 knees (59 per cent) arthrotomy revealed a ruptured meniscus – in 15 on the medial and in 10 on the lateral side (Figure 1) A congenital discoid meniscus was removed from five knees One discoid meniscus showed slight degenerative changes In 12 knees a meniscectomy was performed, on the lateral side in eight and on the medial side in four, because clinical and arthrographic examination had raised the suspicion of a meniscal lesion At operation, however, these 12 knees showed no such lesion The probable cause of the clinical symptoms observed in these knees was in nine knees, adhesions (removed at surgery) that might have

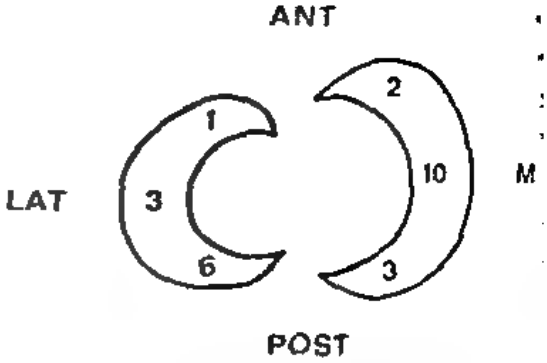

Figure 1 The sites of the meniscal ruptures

resulted from traumatic injury to the synovia one knee, patellar chondromalacia, and in c knee, multiple exostoses. No explanation for t symptoms could be found in one knee Changes the joint cartilage were detected in only t knees in the knee with patellar chondromala and in one knee with a cartilaginous loose bo unaccompanied by any visible changes in the jo cartilage

Recovery after the operation was uneventful all patients except one in whom a haematoma a rupture of the wound resulted in slight instabil at follow-up A remnant of the posterior horn w removed at a later reoperation in three kn because of the persisting pain. In two cases t was on the medial side and in one on the late side (discoid meniscus)

RESULTS

The interval between operation and follow- ranged from 1 to 13 years (mean 5 6 year At follow-up 30 patients (71 per cent) we completely symptom-free, and stability, ran of motion and roentgenological status of t knee were normal Eleven patients (29 p cent), one of whom had had a med meniscectomy on both knees, complained intermittent pain during physical activi Among these 11 patients (12 knees) who h persisting postoperative symptoms t meniscus had been removed from six on t lateral and six on the medial sa Interestingly, of the six lateral meni removed, three were discoid Six of these patients also had the feeling of the kn giving way, and two experienced a snappi sensation in the knee joint during strain

e 12 knees clinical examination revealed on extension in four and slight rolateral instability, a postoperative com- ation, in one

f these 11 patients (12 knees), moreover, had had an intact meniscus removed, five the medial and one from the lateral side findings surgery had been synovial sions and folds which might have been ed by trauma In each case the meniscus removed because of long-standing ptoms that resembled the symptoms of a sceal lesion in a knee joint for which the ography was positive

follow-up bilateral roentgenograms were of all patients They showed pathological ges in four knees (10 per cent) os- ondritis dissecans in two and sclerosis and owing of the joint space in two (Figure 2 A and B) These changes were all on the lateral side after excision of the lateral meniscus, and all were graded as grade III according to Ricklin (1976) From two of these four knees a discoid meniscus had been removed All these four patients had complaints at follow-up The interval between the operation and follow-up was over 12 5 years in three of these cases and 3 5 years in one

DISCUSSION

Because an accurate history of trauma in childhood is often not available, the mechanism of the trauma that causes the meniscus to tear is naturally often obscure In our series, the trauma and the date on which it occurred could be established for 36

ure 2A Preoperative roentgenogram of the it knee joint of a 13 year-old boy

Figure 2B The same knee joint seen 3 5 years after the lateral discoid meniscus had been removed Note the arthritic changes

patients i e 86 per cent, which is a high percentage compared with the 47 per cent reported by Baryluk et al (1977) By far the largest number of meniscal lesions (in 36 knees) were seen in patients older than 10 years, which conforms with the observations of Ritchie (1965) Bhaduri & Glass (1972) and Schulitz (1973)

Many investigators seem to agree that arthrography is more difficult to evaluate in children than in adults (Barucha 1967, Schettler 1972, Stenstrom 1975) Our results point to the high incidence of false positive interpretations of arthrographic findings which, in turn, lead to unnecessary meniscectomies. The incidence of unnecessary meniscectomies has been reported by Ritchie (1965) to be 15 8 per cent, and by Barucha (1967) to be 15 6 per cent in the age group 11–14 years and even higher, 22 2 per cent, in the age group under 10 years A more critical appraisal of the indications, a careful operative exploration of the meniscus and a preoperative arthroscopy might have prevented as many as 12 of the 42 meniscectomies reported here, an observation we share with Laasonen & Wilppula (1976) That the results of meniscectomies in children tend not to be very satisfactory becomes apparent even after a short follow-up period In our series the percentage of symptom-free patients was 71 The corresponding figure reported by Bhaduri & Glass (1972) was 41 per cent, by Schulitz (1973) 30 per cent, by Cotta (1976) 51 per cent, and by Baryluk et al (1977) 75 per cent

Tapper & Hoover (1969) observed, moreover, that the duration of preoperative symptoms has no bearing on the long-term effects of meniscectomy This conforms with our experience as well as with that of others (Schulitz 1973, Cotta 1976) Some investigators have observed that the results of meniscectomies differ in male and female patients Co workers Schulitz (1973) and Cotta (1976) reported poorer results in male patients, Bhaduri & Glass (1972) and Ricklin (1976) reported poorer results in female patients For adult series the latter observation seems to be more prevalent (Tapper Hoover 1969, Dietschi 1973) Of the patients in our series who complained persisting symptoms at follow up 8 (67 cent) were female

CONCLUSIONS

The results after meniscectomy in children are not encouraging, and the results after removal of a lateral, especially discoid meniscus seem not to be satisfactory

Arthrographic findings are not reliable indications for surgery because they can often be falsely positive Reliance on arthrographic findings has resulted in a large number of unnecessary meniscectomies Surgery should not be considered until after the knee has been carefully observed and the existence of mechanical symptoms, restricted motion locking effusion and disabling pain has been established Minor and intermittent symptoms call for conservative treatment

REFERENCES

Barucha E (1967) Meniskusrisse bei Kinder *Orthop* 102, 430–436

Baryluk K Oblonczek G & Zolmowski (1977) Kniegelenksmeniskusverletzungen Kindesalter mit Berücksichtigung Nachuntersuchungen *Arch orthop Unfa Chir* 87, 65–71

Bhaduri T & Glass, A (1972) Meniscectomy children *Injury* 3, 176–178

Cotta H (1976) Kindlicher Meniskusschad *Hefte Unfallheilk* 128, 59–65

Dietschi C (1973) Spatresultate n Meniscectomie *Z Orthop* 111, 39f

Jeannopoulos C L (1950) Ob discoid menisci *J Bone Jt* 649–652

Laasonen, K M & W meniscectomy fails. 672–675

Ricklin P (197 Meniscektomie

Ritchie D (1965) *Bone Jt Surg* 47

ıtler (1972) Beitrag zum Meniskusschaden a Kindesalter *Z Orthop* 110, 443–449
ıllitz, K. P (1973) Meniscusverletzungen im Kindes- und Jugendalter *Arch orthop Unfall* Chir 76, 195–204
ıle, I S (1948) The congenital discoid men scus. *J Bone Jt Surg* 30 B, 671–682
ngorum P W (1959) Meniskuslasionen bei

Ste

Ann Radiol 18, 391–394
Tapper, E M & Hoover, N W (1969) Late results after meniscectomy *J Bone Jt Surg* 51 A, 517–526

respondence to Veijo Vahvanen, M D, Aurora Hospital Nordenskioldinkatu 20, SF 00250 Helsinki Finland

thop scand 50, 797–801, 1979

COMPUTED TOMOGRAPHY OF THE ANKLE

ULF LINDSJÖ*, ANDERS HEMMINGSSON**, BO SAHLSTEDT**
GÖRAN DANCKWARDT-LILLIESTRÖM*

*Department of Orthopaedic Surgery and ** Department of Diagnostic Radiology,
University Hospital, Uppsala, Sweden

Transverse computed tomography of injured ankles gives additional information compared with conventional roentgen diagnostic techniques. In transverse sections the distal tibio-fibular joint and the suprasyndesmotic region can be examined with regard to incongruence and synostoses It is also possible to examine the relations between the talus and the malleolar facets in different ankle positions The technical problems and advantages are discussed

Key words ankle, fractures, function of, roentgen diagnostics, computed tomography

Accepted 5 v 79

injuries of the ankle roentgen diagnosis can netimes meet with problems Owing to the ature of the articular surfaces, a detailed luation of the different ankle structures not always possible with conventional ntgen techniques Tomography in different es has previously been used to improve possibilities of assessment However, contional axial tomography requires special pment and often gives images that are h too blurred for a detailed evaluation

TIENTS AND METHODS

have used computed tomography for the ination of nine patients with sequelae to ures of the ankle joint, in order to evaluate the nostic advantages of this method With an Nuclear Delta 50 FS body scanner nerse tomograms of the distal end of the leg the ankle joints were taken with the patient e and the talocrural joint in the neutral ion, in maximal extension and in flexion Frontal and lateral tomograms were taken at an angle of about 15° to the true frontal plane and to the true sagittal plane, respectively

RESULTS

In transverse tomograms the space between the fibula and tibia could be assessed with respect to calcifications and to the position of the fibula in the fibular incisure of the tibia (Figure 1) The fit of the trochlea of the talus in the ankle mortise can be seen in Figure 2, which shows transverse sections immediately below the level of the joint space

Figure 3 shows frontal tomograms Tibiofibular calcifications can be seen and followed through such sections Defects of the articular surface and lack of congruence between the distal tibial articular surface, the malleoli and the talar trochlea can also be observed

The lateral view through the ankle and the 1st metatarsal demonstrates the trochlear curvature and a defect in the distal tibial

6470/79/060797-05$02.50.0

© 1979 Munksgaard, Copenhagen

Figure 1 CT-scanner transverse sections through the tibio-fibular joint immediately above the ankle mortise

Figure 2 Transverse section of the ankle in the malleolar plane with the ankle joint in dorsal extension (dorsiflexion) (top) and plantarflexion (bottom)

Figure 3 Section through the ankle at 15° to frontal plane

Figure 4 Supination-eversion ankle fract grade IV

articular surface In addition the tarsal sinus and the small joints in the first ray of the midfoot can be evaluated (Figure 8)

To illustrate the usefulness of the method in different conditions resulting from ankle injuries, some typical cases are presented below

The first is a grade IV supination-eversion injury in a 40-year-old woman (Figure 4) A post-traumatic arthrosis of the ankle j developed (Figure 5)

In a series of transverse sections (Figur through both ankles, the subchondral scler in the left ankle can be seen on the upper of images, where the section lies immedi above the articular surface plane. On lower image, where the section p through the malleoli, the irregularities of

re 5 Post traumatic arthrosis in the ankle m in Figure 4

Figure 7 Post traumatic arthrosis deformans Section 15° to the frontal plane



igure 6 Post traumatic arthrosis deformans ransverse section just above and through the ural tibial joint surface

Figure 8 Post traumatic arthrosis deformans Section 15° to the sagittal plane

lar articular surface on the anterior margin re visible In the frontal tomogram (Figure) part of the distal articular surface of the bia is destroyed with formation of a gap in e medial angle Sections in the sagittal lane reveal the corresponding defect on the istal tibial articular surface (Figure 8)

A few patients with tibio-fibular synos- osis were examined Figure 9 shows ansverse sections above the ankle joint revealing distinct bridging callus between the tibia and fibula In Figure 10 corresponding images from another patient are seen, but here there is an open gap in the synostosis.

DISCUSSION

Our investigation has shown that computed tomography can be used for examination of the ankle joint both in more conventional projections and in transverse sections for evaluating, for example, a tibio-fibular synostosis, the fit of the fibula into the fibular incisure of the tibia at the level of the syndesmos



Figure 9 Tibio fibular synostosis as seen in transverse sections through the distal leg



Figure 10 Tibio-fibular synostosis without complete bridging The open gap in the callus is clearly visible in a transverse section through the distal leg

the position of the talus in relation to the malleoli in different ranges of movement

Many theories have been put forward concerning the shape of the talus and its fit into the ankle mortise The talar trochlea has been considered to be wedge-shaped and a certain degree of play between the talar trochlea and ankle mortise has been assumed to occur on tar flexion (Fick 1911, Bonnin 1950) mputed tomograms taken as horizontal sections in the malleolar plane in living patients show that neither in dorsiflexion nor in plantar extension does any play occur between the talus and the malleolar facets. The talar trochlea fits well between the malleoli on all images This is in agreement with the observations of Inman (1976), who described the trochlea tali as a section of a frustrum of a cone

After injuries of the interosseous membrane and the syndesmosis and also after the use of suprasyndesmotic screws, a bony bridge between the distal ends of the fibula and tibia is sometimes seen It may be of importance to be able to determine whether there is a complete synostosis or whether an open gap is present Soft tissue ossifications in the syndesmotic area are more easily evaluated by

Figure 11 Artefacts from metallic implants Transverse sections just above the ankle joint.

transverse computed tomography than by more conventional methods

The technical problems encountered in our examinations have been partly related to the position of the patient It is difficult, for example, to examine a standing patient with a whole-body scanner that is constructed and intended for a supine patient It is also difficult, therefore, to take pictures under weight-bearing stress

Even the slightest difference in the length of the legs makes it difficult to get exactly comparable tomographic sections of the injured and intact ankle joints Furthermore screws and plates used for internal fixation may cause interfering blurs which make impossible to evaluate tomographic sections passing through metallic implants (Figure 11)

In frontal and sagittal sections the image quality offers no advantages over conventional tomographic techniques. In transverse computed tomographic sections the detailed resolution in the image is better than in many conventional axial tomographic methods The density of the image can be varied and information regarding the bone structure, the appearance of the joint spaces and the soft tissues, muscles, tendons and blood vessels can be obtained Studies using the image processing unit are of considerably greater value than those in which only paper copies of screen images are employed.

The costs of conventional roentgen diagnostic methods and computed tomographic examination of the ankle are about the same

computed tomograph is available in the for other purposes it is well worthwhile t also for the analysis of selected cases of injury

CLUSIONS

ated tomography of the ankle gives diagnostic information than con onal roentgenography in certain cases method also permits experimental dies of joint congruence in different ranges movement If used correctly and with strict lications, computed tomography constitutes valuable addition to the diagnostic arsenal pathological conditions following ankle uries

ACKNOWLEDGEMENTS

This investigation was supported by grants from the med cal Faculty Uppsala University Forenade Liv Mutual Group Life Insurance Company Stockholm Sweden the Swedish Association for Traffic and Polio Injuries.

REFERENCES

Bonnin Grant J (1950) *Injuries to the ankle* 1st ed pp 47 48 William Heinemann Medical Books Ltd London

Fick Rudolf (1911) Mechanik des oberen Sprunggelenkes. In *Handbuch der Anatomie und Mechanik der Gelenke* pp 596–612, Verlag Gustav Fischer Jena

Inman Verne T (1976) *The joints of the ankle* pp 11–34 The Williams & Wilkins Co, Baltimore

respondence to Ulf Lindsjo M D Department of Orthopaedic Surgery University Hospital 750 14 Uppsala Sweden

Orthop scand 50 803–808 1979

PROCEEDINGS OF THE NORWEGIAN ORTHOPAEDIC ASSOCIATION

EDITOR ARNT JAKOBSEN

Oslo September 23rd, 1978

ROTATIONAL OSTEOTOMY FOR RECURRENT DISLOCATION OF THE SHOULDER

Ingar Vestad
Hamdal County Hospital Namsos

In the mechanism of recurrent dislocation of the shoulder the posterior defect in the humeral head, described by Hill & Sachs (1940) plays an important *role* In the presence of such a defect dislocation occurs when the defect slides over the damaged *glenoid* rim during external rotation

To prevent this, a subcapital transverse osteotomy is performed rotating the head inwards 25° The osteotomy is fixed with a right angled compression plate

Five patients are presented all with satisfactory functional results. In spite of delayed union in one patient working capacity and sporting activities were not restricted There were no redislocations

AN UNUSUAL COMPLICATION AFTER TOTAL HIP REPLACEMENT

Kjell Matre
Ålesund County Hospital Åsestranda

After re-insertion of a loose total hip prosthesis, a large amount of acrylic cement protruded into the pelvic cavity One and a half years later a thrombosis of the external iliac artery developed in this region Two years after the re-operation the prosthesis was removed because of severe pain A large haematoma was evacuated and a brisk haemorrhage from a hole in the iliac artery was found

Oslo, October 26th – 28th, 1978

TREATMENT OF FRACTURES WITH DISPLACEMENT OF THE TALARIC PORTION OF THE OS CALCIS

Kjell Matre
Ålesund County Hospital Åsestranda

In a series of 24 patients with displaced fractures of the talaric portion of the os calcis 15 patients were primarily treated conservatively a few of these patients had early subtalar fusion one were treated with open reduction and fixation with Kirschner wires *ad modum* Soeur & Gremy

In the latter group the anatomical and functional results were superior to those in the first group and likewise the hospital stay and the time off work were much shorter in the surgically than in the conservatively treated group

[illegible]

A survey was given of 51 patients (49 girls 2 boys) with idiopathic scoliosis previously treated with the Milwaukee brace (Mb) The curves were judged by standard a p roentgen pictures The final correction of the curves with Mb was compared with the curves standing without the brace and the initial correction of the same curves with the Boston brace (Bb) Every case served as her (his) own control

The mean age before changing to the Bb was 15½ years and ended a mean 2 year correction period with the Mb There were 3 juvenile and 48 adolescent scolioses. The cases were divided into groups according to the apex of the curve double primary – 24 cases, thoracic – 11 cases thoracolumbar 9 cases lumbar – 7 cases

The mean correction percentage *for the four* groups of curves were summarized and gave the results thoracic curves – Bb 21 per cent/Mb

0001 6470/79 060803–06$02.50

© 1979 Munksgaard C

per cent, thoracolumbar/lumbar curves – Bb 48 per cent/Mb 26 per cent, lumbosacral curves – Bb 58 per cent/Mb 28 per cent The more caudal the localization of the scoliosis, the better the correction with the Bb For single thoracic curves above T-10, the Mb gave the best results For all other curves the Bb should be the brace of choice in the treatment of idiopathic scoliosis.

BY

During the years 1969 to 1975, 110 patients, aged 20 to 40 years were treated for spondylolisthesis by posterolateral fusion None of them had sciatica and the listhesis ranged from grade 1 to 3 (Meyerding 1932) From the second week after operation half of the patients wore a plaster of Paris corset which included one thigh, and the other half a metal reinforced cloth corset, for 4 months

At follow-up examination 1 to 8 years after operation (average 4 4 years) 61 per cent had no pain, 33 per cent were improved, while 6 per cent still had distinct back problems Ninety-four per cent had full working capacity Roentgen examination showed fusion in 90 per cent of the cases. No differences were found between the two groups with different after-treatment

DIAGNOSIS AND TREATMENT OF GIANT-CELL TUMOUR OF BONE

Ø Hagen
Martina Hansens Hospital, Sandvika

Fifteen patients, nine female and six male, with giant-cell tumour of bone were followed up for a mean period of 8 years Three patients were nearly 15 years, nine between 15 and 30, and three between 30 and 50 years Five tumours were located in the proximal tibia and three in the distal femur, three in the distal tibia, one in the proximal and one in the distal radius, and one in the thumb and a lumbar spinal process, respectively

The recurrence rate was 40 per cent, and a malignant course was found in 13 per cent Patients under the age of 25 years rarely had recurrences. A high recurrence rate was recorded in the knee region and in tumours penetrating the cortex, regardless of tumour size and spontaneous fracture

Primary *en bloc* resection combined with autologous bone transplantation and arthrodesis are recommended in patients over 25 years Alternatively, the new porous fibre-titanium thesis or an intramedullary nail can be inserte

CHRONIC RECURRENT MULTIFO OSTEOMYELITIS

Ludvig Fjeld Solheim, Kjell Liverud, Ber Paus & Erling Steen
Martina Hansens Hospital Sandvika
The Norwegian Radium Hospital, Oslo
Orkdal Sanitetsforening Hospital Orkanger

Chronic recurrent multifocal osteomyelit characterized clinically and radiologically multiple bone lesions, sometimes occu symmetrically, and a prolonged course several years with relapses and new lesions. aetiology and pathogenesis is unclear

A 5-year-old girl with this disease is repo Osteolytic lesions were found in the d epiphysis in the left femur and tibia, in both d tibial metaphyses, and in the distal end of the talus Culture of bone biopsy material for bac was negative, and the histopathological find indicated a non-specific inflammatory pro Symptoms from the left ankle domin subsiding under 5 months without antibiotic t ment

MALIGNANT VERTEBRAL TUMO WITH NEUROLOGICAL MANIFESTATIO

Terje Terjeten
Regional Hospital Trondheim

In a series of 36 patients with malig vertebral tumours, back pain was usually initial symptom, and was often present m months before neurological symptoms appeared

Laminectomy and decompression of the c improved pareses in most of the patients, and four cases walking ability was regained The b results were obtained in cases with metast from prostatic and breast carcinoma and multiple myeloma

Early diagnosis, myelography and prom laminectomy are mandatory if patients with complete paraplegia are to be offered any cha of relief

PULMONARY EMBOLISM AFTER OSTE SYNTHESES ON THE UPP EXTREMITY

Ulf Slungaard
Aker Hospital Oslo

Two cases of pulmonary embolism after ost syntheses on the upper extremity are reported

A 36-year-old healthy man was re-operated 18 rs after injury for a simple fracture of the ecranon which re-dislocated after the primary peration. He was ambulatory from the day after ch operation. The wound healed primarily Six eks after the second operation he complained of best pain and dyspnoea, and 5 days later he ddenly died without any treatment Autopsy vealed massive occlusion of the pulmonary ssels.

A 33-year-old man with a fracture of the meru had a similar history, but was treated ch anticoagulants, and survived.

OLKMANN'S ISCHEMIC CONTRACTURE F THE FOREARM

tor Reigstad & Cato Hellum
ronprinsesse Märthas Institute, Oslo

Twenty-three cases of established Volkmann's ntracture of the forearm treated with excision of irreparably damaged muscles, lengthening of tendons and lysis of the median and the ulnar ve are reported. Fourteen of the patients were ldren, two-thirds were male Supracondylar ctures of the humerus, all treated with plaster Paris, caused 10 contractures. Nerve damage s seen in 17 cases The cases were classified as en of the mild type, three moderate and 13 ere

Twelve patients achieved normal/good function the hand after treatment, five had obvious ctional reduction, four achieved only a support ction of the hand, and two patients had to have forearm amputated It is concluded that early sion of the necrotic muscles, lysis of the ves and lengthening of the flexor tendons prove the functional results.

ST-TRAUMATIC OSTEOLYSIS OF THE TER END OF THE CLAVICLE

e Lebostad
rstad County Hospital, Harstad

One case of osteolysis of the acromial end of the vicle is reported The positive roentgen findings re seen 4 months after injury, with almost nplete restitution 12 months later The main mptom is pain, which usually is mild and tran- ory Thirty three cases have been recorded so but the condition is probably often overlook-

COMPARTMENTAL SYNDROME OF THE ABDUCTOR POLLICIS LONGUS AND EXTENSOR POLLICIS BREVIS MUSCLES

Ludvig Fjeld Solheim & Rolf Hagen
Martina Hansens Hospital, Sandvika

A 32-year-old man experienced recurrent pain and swelling during exertion, in an area corresponding to the fascial compartment of the abductor pollicis longus and extensor pollicis brevis muscles. The symptoms which were provoked by overuse (rowing) did not respond to conservative therapy

One year after the onset of the symptoms, a decompression of the bellies of the mentioned muscles was performed After the fasciotomy the symptoms subsided, and eventually disappeared completely

FRACTURES IN THE LOWER LEG WITH SEVERE SOFT TISSUE COMPLICATIONS

T Bjerbaek, A Molster, G E Johnson & A Alho
Haukeland Hospital, Bergen

A consecutive series of 17 patients with compound comminuted fractures of the lower leg was analysed For the primary skeletal fixation, Hoffmann osteotaxis was used in all cases. In two cases an arterial reconstruction was performed, four cases were complicated by nerve injury, two with permanent damage

[illegible]

amputation Five infections occurred, but they could be controlled, and did not lead to chronic osteomyelitis.

The following principles of treatment were outlined debridement, primary fixation, arterial but not nerve repair, primary skin coverage in non-contaminated cases, effective drainage, active postprimary care with debridements and repeated skin graftings to cover necrotizing skin areas.

INTERNAL FIXATION OR PRIMARY PROSTHETIC REPLACEMENT FOR TREATMENT OF ACUTE FEMORAL NECK FRACTURES IN THE ELDERLY A PROSPECTIVE RANDOMIZED STUDY

Odd Søreide, Anders Molster & Tor Steinar Raugstad
Haukeland Hospital, Bergen

A prospective randomized study has been performed in 104 patients with an acute femoral

neck fracture, comparing internal fixation (v Bahr screws) with primary prosthetic replacement [illegible] patients were [illegible] 1, 6 and 12 months after operation, was similar in both groups Internal fixation was found to be a less time-consuming operation, was associated with a significantly reduced morbidity rate, and gave a shorter hospitalization time compared with prosthetic replacement

Primary prosthetic replacement was associated with earlier postoperative [illegible] gave a [illegible] operations, [illegible] follow-up examination

INTERNAL FIXATION VERSUS PRIMARY PROSTHETIC [illegible] ACUTE COST

[illegible] urgery &

Internal fixation (v Bahr screws) and primary prosthetic replacement (Christiansen's endoprosthesis) have been used for treatment of acute femoral neck fractures in patients older than 67 years (prospective, randomized)

The cost of each type of treatment was calculated on the basis of relevant parameters (hospitalization time, operation time, devices used, blood tests performed, X-ray examinations, follow-up, readmissions and reoperations etc) For first stay in hospital, primary prosthetic replacement was 2 4 times more expensive than internal fixation This large difference in costs was reduced, but not abolished, by a less expensive follow-up for the prosthetic group and more readmissions and reoperations for the internal fixation group On the whole, prosthetic replacement was found to be 1 7 times more expensive than internal fixation

RECONSTRUCTION OF THE LATERAL LIGAMENTS OF THE ANKLE

Olav Reikerås
Kronprinsesse Marthas Institute, Oslo

A follow-up examination of 22 patients age 16 – 60 years, operated for lateral instability of the ankle joint ad modum Watson Jones is presented Mean observation time was 7 years.

Objective evaluation based on stability range of movement and peroneal strength showed 92 per cent excellent, 4 per cent good and 4 per cent poor results. Patients' own opinions 64 per cent had complaints, 23 per cent were improved, and 13 per cent were not improved

It is concluded that although the operation gives a good stability, many patients will still have moderate or slight complaints.

REOPERATIONS OF INFECTED TOTAL HIP PROSTHESES

Hans K Dahl & Mons Lie
Ullevål Hospital, Oslo

In 520 Muller-Charnley total hip replacement operations, infection occurred in 14 resulting in loosening of the prostheses. Eleven of these have been reoperated, using Pallacos Garamycin Cement* to fix the new prostheses. In 7 of the 11 cases, previous operations on the same hip had been performed prior to the first total hip replacement During an observation time from 1–[illegible] months (average 12 months) only one of the [illegible] reoperated hips has become reinfected.

It is concluded that Garamycin cement should be used in all cases where the hip joint has been surgically exposed prior to insertion of a total hip prosthesis. Short-term results are good when an infected hip prosthesis is exchanged using prophylactic antibiotics and Garamycin cement

ARTHROSCOPY OF THE KNEE JOINT

Anders Molster & Antti Alho
Haukeland Hospital Bergen

One hundred and six diagnostic arthroscopies were performed on 103 knees. Two-thirds of the procedures were performed using local anaesthesia without a tourniquet, on an outpatient basis. A knee operation was performed in 52 cases. In five cases the arthroscopic diagnosis was inaccurate and resulted in two unnecessary arthrotomies.

On the other hand, non-operative treatment was selected in 12 cases where a prearthroscopic diagnosis based on clinical and arthrographic findings suggested an arthrotomy

The diagnoses were ruptured meniscus – 57 chondromalacia – 9 ruptured anterior cruciate – 4, osteoarthrosis – 4, osteochondritis – 4 synovitis – 2, and others – 5 Arthroscopy was helpful in the diagnosis of acutely locked knee in 24 out of 30 cases the arthroscopy gave the indication for operation (20 meniscal tears) No complication attributable to the arthroscopy occurred

It is concluded that arthroscopy is an indispensable tool in a busy department

TRAUMATIC DISLOCATION OF THE PATELLA

S Raugstad, A Alho, A Molster, S Haukaas
K Heidsten
Haukeland Hospital, Bergen

In a series of 16 cases of acute traumatic dislocation of the patella, predisposing factors played an important part in two cases. Fourteen cases were operated on primarily One redislocation required reoperation In both the cases with non-operative treatment the dislocation recurred, and operation was performed later

At follow-up examination, observation period over 3 years, the functional end-result was normal in all but three cases with some residual pain and extensor weakness

The diagnosis is easily missed because the patella is most often in a reduced position when the doctor sees the patient The dislocation is often accompanied by osteochondral fractures, which may be difficult to visualize radiologically Oblique and axial views of the patella are important.

TOTAL REPLACEMENT OF THE SHOULDER JOINT IN RHEUMATOID ARTHRITIS

Jan A Pahle
Oslo Sanitetsforening Rheumatism Hospital, Oslo

A follow-up study of 29 synovectomies of the shoulder joint, performed between 1968 and 1978, indicated fairly good results as regards relief of pain, range of motion and total function In the same period 18 arthroplasties of the shoulder joint were performed Of the 13 Stanmore prostheses inserted five are loose and two are infected with *staphylococcus aureus* The remaining eight patients are pain-free and have a relatively satisfactory range of motion Five non-constrained prostheses *ad modum* Engelbrecht were implanted recently The preliminary results are better than in the Stanmore group, and the training is easier

Only five out the total material were early cases.

TOTAL ANKLE REPLACEMENT PROSTHESIS IN PATIENTS WITH RHEUMATOID ARTHRITIS

Jens Teigland
Oslo Sanitetsforening Rheumatism Hospital, Oslo

Twenty-two patients with rheumatoid arthritis of the ankle joint operated since 1975 with the so-called TPR total ankle prosthesis are reported All the patients are pain free The mean dorsal flexion postoperatively was 9° and plantar flexion 20° None are infected, and so far no loosening of the prostheses has occurred

Prior to the total replacement operation, triple arthrodesis had been performed or spontaneous ankylosis had occurred in 18 patients

It is pointed out that pantalararthrodesis is a very poor solution for patients with rheumatoid arthritis.

ARTHRODESIS OF THE KNEE JOINT

Jette Johansen & Imre Gabor
Sophies Minde Orthopaedic Hospital, Oslo

In a follow-up study of 27 patients who had had an arthrodesis of the knee joint after various lesions, all answered a questionnaire, and 18 were examined by the authors

Twenty-two were satisfied with the result of the operation, 17 had returned to their previous occupation No adverse effects on the neighbouring joints were recorded, if these were normal before the operation

In the authors' opinion, arthrodesis of the knee joint still remains the best operation in cases of proximal focal femur defect or chronic joint infection

Oslo, December 16th, 1978

CANCELLOUS AUTOLOGOUS BONE GRAFTING IN OPEN DENUDED LOWER LEG FRACTURES

Einar Sudmann
Regional Hospital, Tromsø

Five consecutive patients with seven lower leg fractures and two femoral fractures were treated with external and/or internal fixation, systemic antibiotics and grafts of cancellous autologous bone All fractures were open and of severity grade 3, except one femoral fracture All seven uni-level to quadruple-level fractures were without skin cover (denuded)

In the first case with one uni-level lower leg fracture, bone grafting followed full-thickness skin grafting whereas in the following four patients bone was grafted to the open fractures as soon as possible, and full-thickness skin grafting was, when necessary, deliberately postponed until the fracture was healed

Gross infection of the fracture, chronic osteomyelitis and pseudarthrosis development followed full-thickness skin grafting in the first case By contrast, bone grafts seemed to prevent these complications in the latter four patients who had more severe fractures.

EARLY DIAGNOSIS OF ACUTE HEMATOGENOUS OSTEOMYELITIS BY COMPUTED TOMOGRAPHY

John K Hald Jr & Einar Sudmann
Regional Hospital, Tromsø

Computed tomography was utilized in simultaneous examinations of the affected extremity, and the presumedly normal contralateral one, in nine patients. The difference in intramedullary attenuation values between matched pairs of contralateral bones was evaluated The attenuation values were always increased in the regions with osteomyelitis It seems to be possible to detect the bone marrow involvement of osteomyelitis by computed tomography, prior to the appearance of bony changes on the routine X-rays.

OPERATIVE TREATMENT OF IDIOPATHIC NEONATAL AND RELAPSED CLUBFOOT

Einar Sudmann
Regional Hospital, Tromsø

A series of operatively treated clubfeet comprised 25 patients (39 feet) median age 3 5 years, with relapse after treatment with plaster casts, and 15 patients (23 feet), median age 9 days, who were untreated prior to operation

A posterior and medial soft tissue release, usually combined with resection of the middle third of the cuboid bone and tenotomies of the tibialis posterior and Achilles tendons were used in relapsed, and untreated feet, respectively Postoperatively all patients were treated by plaste bandages for 4–5 months.

One relapse was noted within 1 year after : release operation, while there were no relapses o the hind foot deformity 4 to 22 months afte neonatal surgery

It is suggested that the results of treatment o the hind foot deformity can be estimated clinicall by measuring the range of movement in th subtalar joint by externally rotating the foo relative to the leg

IDIOPATHIC SACROILIAC SYNDROME

E Sudmann, J A Sundsfjord, K Middelfart & J K Hald Jr
Regional Hospital, Tromsø

The sacroiliac syndrome (SIS) is characterize by low-back pain, irradiating leg pain absence o neurological deficits, and normal X rays. Howeve the sacroiliac tests are positive The aetiology an pathology of the SIS remains obscure

More than 40 patients with a presumed SI were diagnosed over a 2-year period Thus, th syndrome seems to be common in orthopedi practice Three patients so far have been treate by sacroiliac intra-articular arthrodesis

A profile-scan bone scintigraphy technqu (technetium – 99m) has been developed but it value in SIS is in yet unclear

Acta Orthopaedica Scandinavica

EDITOR
KNUD JANSEN
Copenhagen, Denmark

ASSOCIATE EDITOR
POUL S RASMUSSEN
Copenhagen Denmark

EDITORIAL BOARD

STEFAN HARALDSSON
Reykjavik Iceland

MAGNOR FOSS HAUGE
chairman Oslo Norway

TOR HIERTON
Uppsala Sweden

KNUD JANSEN
Copenhagen Denmark

ERIK B RISKA
Helsinki Finland

K HARRY SØRENSEN
Odense Denmark

Vol. 50 Nos. 1–6 1979

MUNKSGAARD Copenhagen

The following specialists have kindly assisted in the editorial preparation of volume 50

Kjeld Skou Andersen
P Thestrup Andersen
Gunnar Andersson
C C Arnoldi
Rune Axelsson
Troels Barfred
Goran Bauer
Pål Benum
Espen Berntsen
Hans Bohr
Håkan Brattström
Carl-Axel Cedell
Jens Krogh Christoffersen
Hans K Dahl
Martin Dyrbye
Bent Ebskov
Svante Edshage
Hans Emnéus
Hans Chr Engbaek
K S I Friberg
Poul Glenting
Ian Goldie
Jørgen Greiff
David Haffajee
Rolf Hagen
Lars-Ingvar Hansson
M Foss Hauge
Niels Højgaard
Tor Hierton
Åke Hjelmstedt
Anders Hulth
Erik Jansen
J Steen Jensen
Torben Ejsing Jørgensen
Jørgen Kjølbye
Anders Langenskiold
Lars-Erik Laurent
Jørgen Lauritzen
R Lempberg
Lars Lidgren
Lars Lindberg
Erland Lysell
Erik Moberg
Niels Mossing
Ole Munck
Alf Nachemson
Bo Nilsson
Erik Nordentoft
Sven Olérud
Henning Paaby
Bernhard Paus
Björn Persson
Søren Pilgaard
Wolfgang Rauschning
Kurt Rechnagel
Inge Reimann
Erik B Riska
Arne Rosenklint
Arne Rugtvett
Jørgen Saugmann Jensen
Pär Slätis
O Sneppen
K Harry Sørensen
Bertil Stener
Anders Stenström
Erik Tøndevold
Stig Willner
Lis Zachariae

© MUNKSGAARD 1979

Munksgaard
International Booksellers and Publishers Ltd
35 Nørre Søgade DK-1370 Copenhagen K, Denmark

PRINTED IN ENGLAND BY THE WHITEFRIARS PRESS LTD LONDON AND TONBRIDGE

BJECT INDEX

NORMALITIES
enatal hip instability 315

HILLES TENDON
ice of treatment in subcutaneous Achilles tendon rupture (Proc.) 112
air of subcutaneous rupture of the Achilles tendon (Proc.) 124

KALINE PHOSPHATASE
um enzymes after hip joint surgery 671

IELOBLASTOMA
amantinoma tibiae 97

MINOTRANSFERASES
um enzymes after hip joint surgery 671

MPUTATION
amantinoma tibiae 97
ne vascularization and bone healing in the amputation stump 39
tal blood pressure measurement in lower-limb amputees 571
ndardized temporary prosthesis with total contact socket for below knee amputees (Proc.) 359
e vascularization in the amputation stumps of rabbits 399
und healing in above-knee amputations in relation to skin perfusion pressure 59
und healing in below-knee amputations in relation to skin perfusion pressure 49

GIOGRAPHY
giography in the diagnostics of malignant soft tissue tumours 605

GIOMATOSIS
prognosis in congenital lower limb hypertrophy 307

KLE
ical and social status following injury to the lateral ligaments of the ankle 699
nputed tomography of the ankle 797
Computerized tomography of the ankle (Proc.) 116

ANKLE JOINT
Anatomical basis of variability in injuries of the medial malleolus and the deltoid ligament I Anatomical studies 217
Anatomical basis of variability in injuries of the medial malleolus and the deltoid ligament. II Clinical studies 225
Operative or conservative treatment of lesions of the lateral ligaments of the ankle (Proc.) 104
Recurrent instability of the ankle joint 337
Triplane epiphyseal ankle fractures (Proc.) 117

ANTIBIOTICS
Effects of cloxacillin, doxycycline, fusidic acid and lincomycin on the mechanical properties of bone and skin in young rats 245

ANTIGENS
The mitotic activity of bone marrow and thymus after combined antigenic challenge and trauma 713

AORTA THORACIC
Rupture of the thoracic aorta due to blunt trauma diagnostic aspects (Proc.) 124

APATITES
Physical and chemical investigation of free bodies in articular osteochondromatosis 533

ARTHRITIS
A comparison of the functional performance of patients with Charnley and Müller total hip replacement 563
A histochemical study of alkaline and acid phosphatase activity in subchondral bone from osteoarthrotic human hips (Proc.) 105

ARTHRITIS RHEUMATOID
Arthrodesis of the wrist in rheumatoid arthritis (Proc.) 604
Total hip replacement in juvenile rheumatoid arthritis 197

ARTHRODESIS
An evaluation of operative procedures in the treatment of hammer toe 709

ARTHROPLASTY
An alternative method for exchange operation of infected arthroplasty 93
Antibiotic treatment in patients with infected total hip arthroplasty (Proc) 352
Bacterial flora in infected total hip arthroplasties (Proc) 352
Brunswick arthroplasty of the hip joint operative technique early complications and results (Proc) 602
Christiansen endoprosthesis in osteoarthritis of the hip (Proc) 344
A comparison between the surgeons evaluation of the result after total hip arthroplasty and the patient s evaluation of hip pain and mobility (Proc) 349
Complications after total hip replacement (Proc) 347
Correlation between position of duocondylar prosthesis and function of the knee joint (Proc) 351
Deep infection after total hip replacement (Proc) 345
Diagnosis and treatment of infected knee arthroplasties 352
Diagnosis of deep infections following total hip replacement (Proc.) 352
Ectopic bone formation following low friction arthroplasty of the hip *ad modum* Charnley (Proc) 347
Functional status after Marmor knee arthroplasty studied by means of isometric muscle strength measurements and gait angle diagram technique (Proc) 350
Hematogenous infection after arthroplasty an experimental study in the rabbit (Proc) 114
ICLH arthroplasty of the knee joint results and complications (Proc) 351
Infection after total knee replacement (Proc) 344
Late results of revision arthroplasty using a total hip prosthesis (Proc.) 113
McKee-Farrar arthroplasty – successes and failures (Proc) 345
Measures against superficial wound infection and deep sepsis in total hip arthroplasty (Proc.) 345
Mechanical loosening of the femoral head prosthesis in total hip replacement according to Charnley (Proc) 346
Nine years experience with total hip replacement with special regard to loosening and infection (Proc) 346
Postoperative complications after 605 Charnley total hip replacements (Proc.) 347
Precautions and intensive treatment in knee arthroplasty (Proc.) 350
Preliminary results of a trunnion bearing prosthesis (Christiansen) in total hip replacement (Proc) 113
Preoperative reduction of weight in hip alloplasty (Proc) 348
Primary complications after Marmor resurfacing arthroplasty (Proc) 351
The primary complications of total hip replacement (Proc.) 347
Prophylactic antibiotics against deep infections after total hip replacements (Proc) 113
Prospective multicenter study of knee arthroplasties (Proc.) 113
Prospective multicenter study of knee arthroplasties (Proc) 350
Rearthroplasty of the hip joint (Proc.) 112
Reoperation of total hip replacements in Sweden during the period 1/1/1976 31/8/1977 (Proc.) 112
Resurfacing arthroplasty of the hip *ad modum* Wagner (Proc) 348
Roentgenographic determination of the rotation position of the femoral portion of the hip prosthesis (Proc.) 349
The role of the resurfacing arthroplasty in the treatment of osteoarthrosis of the hip (Proc) 109
Total hip replacement by the Muller-Charnley prosthesis 457
Total hip replacement in juvenile rheumatoid arthritis 197
Total hip replacement with a trunnion bearing prosthesis 205
274 total hip replacements with Christiansen s trunnion bearing prosthesis Complications and social aspects (Proc) 346

ARTHROSCOPY see ENDOSCOPY

ATHLETIC INJURIES
Clinical and social status following injury to the lateral ligaments of the ankle 699
Football injuries in children and youths (Proc) 341
Operative treatment of tennis elbow (Proc.) 344

AUTORADIOGRAPHY
Trypsin induced mitosis in the articular cartilage of adult rabbits 15

BACKACHE
Acute low back pain in industry a co-

trolled prospective study with special reference to therapy (Proc) 111
uto-traction in the treatment of chronic low back pain and sciatica (Proc.) 110
uto-traction in the treatment of low back pain and sciatica a multicentre controlled study of 82 patients (Proc) 109
uto-traction in the treatment of chronic low back pain and sciatica effect on neurological symptoms (Proc) 110
Denervation of the intervertebral joints Treatment for lumbago and sciatica (Proc) 111
he idiopathic sacroiliac syndrome (Proc) 808
ow back pain – sick leave and working environment (Proc) 363
alen & D ckson s syndrome – a follow up (Proc.) 111
terior fusion of the lumbosacral spine 415
e role of apophyseal joints in low back pain and sciatica (Proc) 602
e role of HLA B27 in the diagnosis of low back pain 411

NECHANICS
physeal bone at ultimate failure (Proc.) 115
physeal bone strength adaption to rigid internal plate fixation an experimental study on rabbits (Proc) 115
ture-suspending effect of the patellar tendon bearing cast 237
ullary compartment of diaphyseal bone tors on (Proc) 115
linear properties of diaphyseal bone 139
ficance of free dorsiflexion of the toes walking 471

PSY NEEDLE
needle aspiration cytology in the agnosis of tumours of soft tissue (Proc) 120

OD CIRCULATION
vascularization and bone healing in amputation stump 39

E AND BONES
mass in primary coxarthrosis 187
s of cloxacillin doxycycline fusidic d and lincomycin on the mechanical perties of bone and skin in young rats 245
s of cyclophosphamide on mechanical perties of bone and skin in rats 629
tensions and intraosseous pressure in long bones of the anesthetized dog oc.) 365
healing of experimental fractures by ompression synthesis. I Torsional ength 369
The healing of experimental fractures by compression synthesis II Morphometric and chemical analysis 375
Histoquantitative analysis of bone tissue (Proc) 123
Non linear properties of diaphyseal bone 139
Observations on long bone medullary pressures in relation to arterial PO_2, PCO_2 and pH in the anaesthetized dog 645
Observations on long bone medullary pressure in relation to mean arterial pressure in the anaesthetized dog 527
Relationship between oxygen and carbon dioxide tensions and acid base balance in arterial blood and in medullary blood from long bones in dogs 519
Repair of bone defects by bone inductive material 21
Treatment of chronic osteomyelitis by free grafts of cancellous autologous bone tissue 145

BONE CEMENT
An alternative method for exchange operation of infected arthroplasty 93
Further experiences with acrylic cementation of giant cell tumours of bone (Proc) 119
Peroperative variations in blood pressure during cementing of total hip alloplasties ad modum Charnley (Proc) 348
Reoperation of hip arthroplasties with gentamicin cement (Proc) 352
Specific properties of Gentamicin Palacos R (Proc) 352

BONE DISEASES DEVELOPMENTAL
Effect of chlorpromazine on skeletogenesis 151

BONE LENGTHENING
The periosteal control of long bone growth 635

BONE MARROW
Bone-marrow pressure and bone strength 507
The mitotic activity of bone marrow and thymus after combined antigenic challenge and trauma 713
Observations on long bone medullary pressures in relation to arterial PO_2, PCO_2 and pH in the anaesthetized dog 645
Observations on long bone medullary pressure in relation to mean arterial blood pressure in the anaesthetized dog 527
Relationship between oxygen and carbon dioxide tensions and acid-base balance in arterial blood and in medullary blood from long bones in dogs 519

BONE MATRIX
Indomethacin induced inhibition of haversian remodelling in rabbits 621

Post traumatic bone mineral loss in tibial shaft fractures treated with weight-bearing brace 689
Serum calcitonin and bone mineral content in patients with osteogenesis imperfecta 639

BONE NEOPLASMS
Allogeneic transplantation in low-grade malignant bone tumours 129
Diagnosis and treatment of giant-cell tumour of the bone (Proc.) 804
Malignant vertebral tumours with neurological manifestations (Proc.) 804
Primary malignant tumours 874 cases (Proc.) 125
Transplantable osteosarcoma in mice 481

BONE PLATES
The healing of experimental fractures by compression osteosynthesis. I Torsional strength 369
The healing of experimental fractures by compression osteosynthesis. II Morphometric and chemical analysis 375

BONE REGENERATION
Diagnosis of traumatic growth disturbance with rontgen stereophotogrammetry (Proc) 356
Healing of large surgical defects of the epiphyseal plate an experimental study (Proc.) 357

CALCANEUS
Fractures of the calcaneum (Proc) 361

CALCIFICATION, PHYSIOLOGIC
Calcification of aging articular cartilage in man 613

CALCINOSIS
Tumoral calcinosis in a patient undergoing hemodialysis 27

CALCITONIN
A case of Albright's syndrome treated with calcitonin 251
Secretion of calcitonin in relation in trauma (Proc) 358
Serum calcitonin and bone mineral content in patients with osteogenesis imperfecta 639

CALCIUM
A case of Albright's syndrome treated with calcitonin 251
The healing of experimental fractures by compression osteosynthesis. II Morphometric and chemical analysis 375

Parathyroid hormone secretion after operative bone trauma 2

CALLUS
Electrical stimulation of fracture callus cells *in vitro* (Proc.) 6

CARBON DIOXIDE
Relationship between oxygen and carbon dioxide tensions and acid base balance in arterial blood and in medullary blood from long bones in dogs 5

CARPAL TUNNEL SYNDROME
Familial osteochondritis dissecans and carpal tunnel syndrome 7

CARTILAGE
Trypsin induced mitosis in the articular cartilage of adult rabbits

CARTILAGE, ARTICULAR
Calcification of aging articular cartilage in man 6
Localized regressive articular cartilage changes in the hip joint of the rabbit following an induced synovitis 1

CHILD
Meniscectomy in children 7
Remodelling after distal forearm fractures in children I 5
Remodelling after distal forearm fractures in children II 7
Remodelling after distal forearm fractures in children III 7
The significance of associated lesions including dislocation in fractures of the neck of the radius in children
Torsion deformities after traction treatment of femoral fractures in children 5
Traumatic hip dislocation in childhood

CHLORPROMAZINE
Effect of chlorpromazine on skeletogenesis 1

CHONDROSARCOMA
Surgery of chondrosarcoma of the pelvis (Proc) 1

CLAVICLE
Clavicular function 2
Post traumatic osteolysis of the outer end of the clavicle (Proc.) 8

CLUBFOOT
Operative treatment of idiopathic neonatal and relapsed clubfoot (Proc.) 8

OLLATERAL CIRCULATION
e vascularization in the amputation stumps of rabbits 399

OST BENEFIT ANALYSIS
ost-benefit analysis of posterior fusion of the lumbosacral spine 427

RYSTALLOGRAPHY
ysical and chemical investigation of free bodies in articular osteochondromatosis 533

YCLOPHOSPHAMIDE
ffects of cyclophosphamide on mechanical properties of bone and skin in rats 629

IABETIC ANGIOPATHIES
ound healing in above-knee amputations [illegible] 59
[illegible] 49

PHOSPHONATES
ositis ossificans progressiva 33

SABILITY EVALUATION
nical and social status following injury to the lateral ligaments of the ankle 699
terior fusion of the lumbosacral spine 415

SLOCATION
dislocation of the trapezium (multangulum majus) 85
ntaneous dislocation of the sterno-clavicular joint 269

ECTROENCEPHALOGRAPHY
ctroencephalographic investigation of patients with adolescent idiopathic coliosis 283

BOLISM
monary embolism after osteosynthesis in the upper extremity (Proc) 804

ERGENCY SERVICE HOSPITAL
ims of fights and assaults attending a asualty department (Proc) 601

DOSCOPY
uroscopy clinical and technical considerations (Proc) 114
uroscopy of the knee joint (Proc) 353
uroscopy of the knee joint (Proc.) 806
uroscopy of the knee joint using the hyonics needlescope (Proc.) 353

EPIPHYSIS
Injuries of epiphyseal plates. Anatomy pathophysiology and classification of injuries (Proc.) 357
Osteoid osteoma of the distal phalanx of the thumb 667
Remodelling after distal forearm fractures in children I 537
Remodelling after distal forearm fractures in children II 731
Remodelling after distal forearm fractures in children III 741
Treatment of deformities in epiphyseal injuries (Proc) 357

FEMORAL FRACTURES
Distal femoral fractures. An 8 year study (Proc) 361
Experimental tests concerning the biomechanical behaviour of pertrochanteric osteosyntheses 675
Femoral shaft fractures treated with closed intramedullary nailing (Proc) 104
Growth remodelling of femoral shaft fractures (Proc) 358
Roentgenographic determination of rotational displacement in fractures of the femur (Proc) 353
Rotational deformity after femur fracture in children a 10-year follow up study (Proc) 354
Supracondylar femoral fractures in old patients (Proc) 343
Torsion deformities after traction treatment of femoral fractures in children 87

FEMORAL HEAD
Migration of the femoral head in Legg Calvé-Perthes disease and its significance for the prognosis (Proc) 106
Radionuclide uptake of ^{99m}Tc-phosphate compounds in human osteoarthritic femoral heads illustrated by autoradiography impulse counting and comparative histological histochemical studies (Proc.) 104

FEMORAL HEAD NECROSIS
Containment of the femoral head in Legg Calvé-Perthes disease and its prognostic significance 191
Experience with the treatment of Perthes disease (Proc) 123
Localized regressive articular cartilage changes in the hip joint of the rabbit following an induced synovitis 179
Necrosis of the femoral head of 8 years

duration without radiological collapse (Proc) 106
Subcapital fractures of the femur 451

FEMORAL NECK FRACTURES
Fractures of the femoral neck in young adults between 17 and 50 years of age (Proc) 116
Internal fixation or primary prosthetic replacement of acute femoral neck fractures a prospective randomized study (Proc) 805
Internal fixation versus primary prosthetic replacement in acute femoral neck fractures Cost effectiveness analysis (Proc) 806
Is early weight bearing permissible after intertrochanteric fracture treated *ad modum* McLaughlin? (Proc) 104
Mortality after hip fractures 161
Osteosynthesis of displaced fractures of the femoral neck 443
Rehabilitation after hip fracture in the elderly 681
Social rehabilitation following hip fractures 777
Subcapital fractures of the femur 451
The treatment of per- and subtrochanteric fractures *ad modum* Ender (Proc) 104

FERRICYANIDES
Controlled hypotension in hip joint surgery 433

FINGER INJURIES
Fractures of the phalanges of the hand (Proc) 105
Fractures through the retrocondylar fossa of the proximal phalanx of the finger (Proc.) 343

FINGERS
Brachymesophalangy and loose bodies in the metacarpophalangeal joints 755

FOREARM
Remodelling after distal forearm fractures in children I 537
Remodelling after distal forearm fractures in children II 731
Remodelling after distal forearm fractures in children III 741

FOOT
Significance of free dorsiflexion of the toes in walking 471

FRACTURE FIXATION
Caput fixed sliding nail for treating epiphysiolysis capitis femoris (Proc) 356
The healing of experimental fractures by compression osteosynthesis. I Torsional strength
The healing of experimental fractures by compression osteosynthesis II Morphometric and chemical analysis
Hoffman instrumentation for unstable pelvic ring fracture – discussion (Proc.)
Hoffman instrumentation in the treatment of unstable pelvic ring injury A case report (Proc)
Osteosynthesis of displaced fractures of the femoral neck
Subcapital fractures of the femur
Tibial shaft fractures

FRACTURE FIXATION, INTERNAL
Experimental tests concerning the biomechanical behaviour of pertrochanteric osteosyntheses
Treatment of pathological fractures

FRACTURE FIXATION INTRA MEDULLARY
35 years' experience of Kuntscher nailing in Finland (Proc)

FRACTURES
Assessment of fracture healing by vibration
Biomechanical comparison of the effects of constant and cyclic compression on fracture healing in rabbit long bones
Fracture healing in rabbits after osteotomy using the CO_2 laser
The healing of experimental fractures by compression osteosynthesis. I Torsional strength
The importance of rotational deformities in the development of angle deformities after fracture (Proc)
Mechanisms in spontaneous correction of angular deformities following fractures in children (Proc)
Mortality after hip fractures
Post traumatic bone mineral loss in tibial shaft fractures treated with a weight bearing brace
Remodelling after distal forearm fractures in children I
Remodelling after distal forearm fractures in children II
Remodelling after distal forearm fractures in children III
Repair of bone defects by bone inductive material
The significance of associated lesions including dislocations in fractures of the neck of the radius

atment of fractures with displacement of the talaric portion of the os calcis (Proc) 803

FRACTURES SPONTANEOUS
Pathologcal fractures. A review (Proc.) 366
Pathological fractures following kidney transplantation (Proc) 367
Pathological fractures in benign bone tumours and tumour like conditions in children (Proc) 366
Spontaneous fractures in the hip and shoulder joints (Proc.) 367
Treatment of pathological fractures 787

GAIT
A comparison of the functional performance of patients with Charnley and Muller total hip replacement 563
External work of gait (Proc) 103
Kinetics of gait (Proc) 103
The normal gait measurement of forces and the time relations to foot-to-ground forces (Proc.) 365
Osteotomy in osteoarthritis of the hip 555
Significance of free dorsiflexion of the toes in walking 471

GAS GANGRENE
Gas gangrene (Proc) 343

GLYCOSAMINOGLYCANS
Glycosaminoglycan metabolism of the medial meniscus the medial collateral ligament and the hip joint capsule in experimental osteoarthritis caused by immobilization of the rabbit knee 465

GOLD RADIOISOTOPES
Synoviorthesis with radioactive gold in hemophiliacs 513

HALLUX
Lateral hallux saltans 599

HAND
Compartmental syndrome of the abductor pollicis longus and extensor pollicis brevis muscles (Proc.) 805
Normal grip strength 255

HEMODIALYSIS
Periarticular calcinosis in a patient undergoing hemodialysis 27

HEMOPHILIA
Synoviorthesis with radioactive gold in hemophiliacs 513

HEMORRHAGE
Controlled hypotension in hip joint surgery 433

HIP
Osteotomy in osteoarthritis of the hip 555
Reoperations of infected total hip prostheses (Proc.) 806
An unusual complication after total hip replacement (Proc) 803
Traumatic hip dislocation in childhood 549

HIP DISLOCATION
Traumatic hip dislocation in childhood 549

HIP DISLOCATION CONGENITAL
Neonatal hip instability 315
The results of open reposition of late diagnosis congenital hip dislocations (Proc) 359

HIP JOINT
Bone mass in primary coxarthrosis 187
Indomethacin treatment in osteoarthritis of the hip joint 169
Rehabilitation after hip fracture in the elderly 681
Serum enzymes after hip joint surgery 671
Total hip replacement by the Muller-Charnley prosthesis 457
Total hip replacement with a trunnion bearing prosthesis 205
Treatment of para articular ossification after total hip replacement by excision and use of free fat transplants 751

HL-A ANTIGENS
The role of HLA B27 in the diagnosis of low back pain 411

HUMERAL FRACTURES
Intercondylar Y shaped fractures of the humerus (Proc) 354
Late results after severely displaced supracondylar fractures of the humerus vertical extension versus closed reduction (Proc) 355
Neurological examination in supracondylar fractures of the humerus (Proc) 355
Non-union of fractures of the humerus (Proc) 342
Open reduction of supracondylar fractures of the humerus in children (Proc) 356
Supracondylar fractures of the humerus (Proc) 355
Supracondylar fractures of the humerus in children (Proc.) 355

Surgical and conservative treatment of supracondylar fractures of the humerus in children (Proc) 356

HYDROXYPROLINE
The healing of experimental fractures by compression osteosynthesis. II Morphometric and chemical analysis 375

HYPERSENSITIVITY
Value of epicutaneous tests for allergy to metals in implantation surgery (Proc) 348

HYPERTROPHY
The prognosis in congenital lower limb hypertrophy 307

HYPOTENSION CONTROLLED
Controlled hypotension in hip joint surgery 433

IMMOBILIZATION
Glycosaminoglycan metabolism of the medial meniscus, the medial collateral ligament and the hip joint capsule in experimental osteoarthritis caused by immobilization of the rabbit knee 465
Osteoarthritis of the knee in the rabbit produced by immobilization 1

INDOMETHACIN
Indomethacin induced inhibition of haversian remodelling in rabbits 621
Indomethacin treatment in osteoarthritis of the hip joint 169

RFERON
an leukocyte interferon (Proc.) 117
ide effects of human leukocyte interferon therapy (Proc.) 117

ISCHEMIA
Experimental tourniquet ischaemia (Proc.) 123

JOINT PROSTHESIS
A comparison of the functional performance of patients with Charnley and Muller total hip replacement 563

KNEE
Osteoarthritis of the knee in the rabbit produced by immobilization 1

KNEE JOINT
Arthrodesis of the knee joint (Proc) 807
Diagnosis of acute knee ligament injuries (Proc.) 603
Intra articular shaving of pa ellar chondromalacia (Proc.) 353
Lateral discoid meniscus combined with hypoplasia of the lateral femoral condyle (Proc.) 1
Lateral release in the treatment of dislocation of the patella and other disorders of the knee (Proc.) 1
Lesions of the cruciate l gaments of the knee joint (Proc.) 1
Long term results of surgery for non acute anteromedial rotatory instability of the knee 3
Popliteal cysts (Baker s cysts) in adults 5
Results of operative treatment of lesions of cruciate ligaments a follow up study (Proc.) 1
A stress radiographical follow up investigation of 30 patients 2 years after Jones operation (Proc.) 1

LABYRINTH
A study of labyrinthine function in patients with adolescent idiopathic scoliosis. I 7

LASERS
Fracture healing in rabbits after osteotomy using the CO_2 laser 3

LEG
Fractures of the lower leg with severe soft tissue complications (Proc) [illegible]
The painful chronic anterior lower leg syndrome 5

LEG LENGTH INEQUALITY
The periosteal control of long bone growth 6
The prognosis in congenital lower limb hypertrophy 3

LIGAMENTS
Medial dislocation of the tendon of the long head of the biceps brachii [illegible]

LIGAMENTS ARTICULAR
Anatomical basis of variability in injuries of the medial malleolus and the deltoid ligament. I Anatomical studies 2
Anatomical basis of variability in injuries of the medial malleolus and the deltoid 2
[illegible] 3
knee
Reconstruction of lateral ligaments of the ankle (Proc.) 8 3
Recurrent instability of the ankle joint

MEDIAN NERVE
Processus supracondyloidea humeri with

omitant compression of the medial e (Proc) 125
onator teres syndrome (Proc) 342

RHEOSTOSIS
--tucular ossifications associated with melorheostosis Léri 717

MENINGOMYELOCELE
Hip problems in myelomeningocele (Proc) 343

MITOSIS
The mitotic activity of bone marrow and thymus after combined antigenic challenge and trauma 713
Trypsin-induced mitosis in the articular cartilage of adult rabbits 15

MORTALITY
Mortality after hip fractures 161
Social rehabilitation following hip fractures 777

MSH
Effect of MSH on growth and remodelling of long bones (Proc) 358

MUSCLE CONTRACTION
ormal grip strength 255
adiological and muscular status following injury to the lateral ligaments of the ankle 705
rength of plantar flexion and function after resection of various parts of the triceps surae muscle 693

MYOSITIS OSSIFICANS
yositis ossificans localisata as a complication of tetanus 547
yositis ossificans progressiva 33

NERVE COMPRESSION SYNDROMES
e painful chronic anterior lower leg syndrome 573

NERVE REGENERATION
e neurovascular island pedicle flap 67

NERVE TISSUE
nsion and creep phenomena in peripheral nerve 721

NEUROFIBROMATOSIS
eration on peripheral nerve in Mb Recklinghausen Considerations of two cases (Proc.) 121

NYSTAGMUS
ctural effects on nystagmus response during caloric labyrinthine stimulation in patients with adolescent idiopathic scoliosis II 771

ORTHOPEDIC FIXATION DEVICE
Orthopaedic rehabilitation after open femoral fracture and arterial injury (Proc) 359
The Unna Paste bandage after amputation (Proc) 359

ORTHOPEDICS
Centralized orthopaedic oncology – tumour suspected – what was the final diagnosis? (Proc) 366
Nordic Orthopaedic Association 60th Anniversary 609

OSSIFICATION PATHOLOGIC
Treatment of para articular ossification after total hip replacement by excision and use of free fat transplants 751
Para articular ossifications associated with melorheostosis Léri 717

OSTEITIS
Classification and treatment of osteitis (Proc) 107

OSTEOARTHRITIS
Bone mass in primary coxarthrosis 187
Bone thickening in osteoarthrosis 501
Glycosaminoglycan metabolism of the medial meniscus the medial collateral ligament and the hip joint capsule in experimental osteoarthritis caused by immobilization of the rabbit knee 465
Indomethacin naproxen and osteoarthritis (Proc) 342
Indomethacin treatment in osteoarthritis of the hip joint 169
Intraosseous pressure bone density and roentgenological and clinical findings in primary osteoarthritis of the hip joint (Proc.) 365
Joint debridement for osteoarthritis of the knee (Proc) 351
Osteoarthritis of the knee in the rabbit produced by immobilization 1
Osteoarthritis of the hip epidemiology and clinical role (Proc.) 365
Osteotomy in osteoarthritis of the hip 555

OSTEOCHONDRITIS
Brachymesophalangy and loose bodies in the metacarpophalangeal joints 755
Familial osteochondritis dissecans and carpal tunnel syndrome

ceedings of the Scandinavian Orthopaedic Association Odense Denmark, June 1978 345
Proceedings of the Swedish Orthopaedic Association Stockholm May 1978 109

PROSTHESIS
Fibre metal prosthesis in segmental replacement of long bones in baboons and humans (Proc) 364
An ultralight below-knee prosthesis (Proc) 114

PSEUDARTHROSIS
Congenital pseudarthrosis of the antebrachium (Proc) 105
Effect of human growth hormone in the treatment of pseudarthrosis (Proc) 117
Osteogenic activity of free periosteal and osteoperiosteal grafts and their use in the treatment of infected pseudarthroses of long bones (Proc) 360

PSYCHOPHYSIOLOGIC DISORDERS
Psychiatric aspects in an orthopaedic surgical hospital (Proc) 341

RADIAL NERVE
Entrapment neuropathy of the radial nerve in the forearm (Proc) 604

RADIOGRAPHY
Popliteal cysts (Baker's cysts) in adults 583
The value of routine X-ray examination of the cervical spine in cases of acute trauma to the head and neck (Proc) 105

RADIONUCLIDE IMAGING
Scanning and radiology of the carpal scaphoid bone 663

RADIUS
The significance of associated lesions including dislocation in fractures of the neck of the radius in children 79
Strength reduction after total resection of caput radii following fracture Follow up of 28 cases (Proc) 117

REGIONAL BLOOD FLOW
Distal blood pressure measurement in lower limb amputees 571
Observations on long bone medullary pressures in relation to arterial PO_2 PCO_2 and pH in the anaesthetized dog 645
Observations on long bone medullary pressure in relation to mean arterial blood pressure in the anaesthetized dog 527

REHABILITATION
Rehabilitation after hip fracture in the elderly 681
Social rehabilitation following hip fractures 777

REIMPLANTATION
Nine reimplantations (Proc) 366

SARCOMA
Soft tissue sarcomas A report of 153 consecutive cases (Proc) 604

SARCOMA, OSTEOGENIC
Electron microscopic histochemical and biochemical studies in osteosarcoma (Proc) 118
Endocrinological aspects in osteosarcoma (Proc) 118
Interferon as adjuvant therapy in osteosarcoma – 3 year follow-up study (Proc) 118
Local resection of osteosarcoma instead of amputation (Proc) 119

SCOLIOSIS
A comparison between the correction of idiopathic scoliosis achieved with the Boston and Milwaukee braces 803
The effect of physical training on exercise ability in adolescent idiopathic scoliosis 303
Electroencephalographic investigation of patients with adolescent idiopathic scoliosis 283
Estimation of vertebral rotation in structural scoliosis by computerized 111
407
341
295
Parathyroid hormone secretion after operative bone trauma 241
Postural effects on nystagmus response during caloric labyrinthine stimulation in patients with adolescent idiopathic scoliosis II 771
Scintigraphic and thermographic studies of the thorax in idiopathic thoracic scoliosis (Proc) 112
A study of labyrinthine function in patients with adolescent idiopathic scoliosis I 759
Thromboembolic complications following scoliosis surgery in Scandinavia 175
Treatment by traction *ad modum* Cotrel in idiopathic scoliosis (Proc) 105
Vestibulospinal reflex activity in patients with adolescent idiopathic scoliosis 275

SEMILUNAR CARTILAGE
Long term results of surgery for non acute anteromedial rotatory instability of the knee 329
Meniscectomy in children 791

SHOULDER
Total replacement of the shoulder joint in rheumatoid arthritis (Proc) 807

SHOULDER DISLOCATION
Posterior dislocation and posterior fracture-dislocation of the shoulder (Proc) 124
Recovery after primary dislocation of the shoulder (Proc) 124
Rotational osteotomy for recurrent dislocation of the shoulder (Proc) 803

SHOULDER JOINT
Medial dislocation of the tendon of the long head of the biceps brachii 73

SKELETON
Effect of chlorpromazine on skeletogenesis 151

SKIN
Effects of cyclophosphamide on mechanical properties of bone and skin in rats 629
Effects of cloxacillin doxycycline, fusidic acid and lincomycin on the mechanical properties of bone and skin in young rats 245

SOCIAL ADJUSTMENT
Socio medical evaluation of the patient's life after Charnley hip alloplasty (Proc) 348

SPINAL CANAL
Spinal stenosis (Proc) 342

SPINAL FUSION
Cost benefit analysis of posterior fusion of the lumbosacral spine 427
Posterior fusion of the lumbosacral spine 415

SPINAL INJURIES
Fractures of the thoracic spine (Proc) 125
Paraplegia and tetraplegia in spinal injuries (Proc) 602
The halo in the management of unstable cervical spine lesions (Proc) 116

SPINE
Cloward's anterior fusion in the treatment of traumatic injury and degeneration of the cervical spine (Proc) 602
Fracture of the cervical spine (Proc) 363
Fractures of the thoracolumbar (Th_{12}–L_1) spine (Proc)
Posterior fusion in instability of the cervical column in rheumatoid arthritis and fractures (Proc)

SPRAINS AND STRAINS
The effect of ibuprofen and indomethacin on recent ankle and foot sprains (Proc)

SPONDYLOLISTHESIS
Spondylolisthesis treated by posterolateral fusion (Proc)

STERNOCLAVICULAR JOINT
Spontaneous dislocation of the sternoclavicular joint

STRESS MECHANICAL
A biomechanical comparison of the effects of constant and cyclic compression on fracture healing in rabbit long bones
Bone-marrow pressure and bone strength
Effects of cloxacillin doxycycline fusid c acid and lincomycin on the mechanical properties of bone and skin in young rats
Experimental tests concerning the biomechanical behaviour of pertrochanteric osteosyntheses
Tension and creep phenomena in peripheral nerve
Torque strength of experimental fractures treated by plate fixation with and without compression (Proc)

[illegible] ATROPHY
[illegible] drome

SURGERY
Allogeneic transplantation in low grade malignant bone tumours
The neurovascular island flap
Replantation of amputated fingers and hands (Proc)

SYNOVITIS
Localized regressive articular cartilage changes in the hip joint of the rabbit following an induced synovitis
Synoviorthesis with radioactive gold in hemophiliacs

SYRINGOMYELIA
A late neurologic complication of scoliosis surgery in connection with syringomyelia

TALUS
Aspects of anatomy and treatment of

[illegible]ucal talus (congenital convex pes [illegible]lus) (Proc.) 354

[illegible] 73

[illegible]NS
[illegible] saltans 599

[illegible]OSYNOVITIS
[illegible]al hallux saltans 599

[illegible]TANUS
[illegible]ous ossificans localisata as a complica[illegible]ion of tetanus 547

[illegible]ROMBOSIS
[illegible]omboembolic complications following [illegible]mbosis surgery in Scandinavia 175

[illegible]UMB
[illegible] neurovascular island pedicle flap 67
[illegible]oid osteoma of the distal phalanx of the [illegible]umb 667
[illegible]onstruction of the thumb (Proc.) 344
[illegible] to thumb transfer by micro[illegible]eurovascular anastomosis (Proc.) 604

[illegible]MUS
[illegible] mitotic activity of bone marrow and [illegible]ymus after combined antigenic [illegible]allenge and trauma 713

[illegible]AL FRACTURES
[illegible]ture-suspending effect of the patellar [illegible]ndon-bearing cast 237
[illegible] frequency of osseous complications in [illegible]al shaft fractures treated by internal [illegible]mpression osteosynthesis (Proc.) 360
[illegible]al shaft fractures 593
[illegible]al osteosynthesis with the Lane plate [illegible]d with AO compress on osteosynthesis. [illegible]comparison (Proc.) 360

[illegible] JOINT
[illegible]ficance of free dorsiflexion of the toes [illegible] walking 471

[illegible]S
[illegible]valuation of operative procedures in the [illegible]atment of hammer toe 709

[illegible]OGRAPHY COMPUTERIZED
[illegible]IAL
[illegible]uted tomography of the ankle 797
[illegible] diagnosis of acute hematogenous [illegible]teomyelitis by computed tomography [illegible]roc.) 808

TRACTION
Torsion deformities after traction treatment of femoral fractures in children 87

[illegible]n
807
The osteogenic capacity of free periosteal and osteoperiosteal grafts 491
Repair of bone defects by bone inductive material 21
Treatment of chronic osteomyelitis by free grafts of cancellous autologous bone tissue 145
Treatment of para articular ossification after total hip replacement by excision and use of free fat transplants 751

TRANSPLANTATION HOMOLOGOUS
Allogeneic transplantation in low grade malignant bone tumours 129
Transplantable osteosarcoma in mice 481

TRYPSIN
Trypsin induced mitosis in the articular cartilage of adult rabbits 15

TUBERCULOSIS OSTEOARTICULAR
Tuberculosis of the greater trochanter – still an important and current condition (Proc.) 341

VESTIBULAR APPARATUS
Vestibulospinal reflex activity in patients with adolescent idiopathic scoliosis 275

VIBRATION
Assessment of fracture healing by vibration 391

VIRUS CULTIVATION
Transplantable osteosarcoma in mice 481

VOLKMANN'S CONTRACTURE
Volkmann's ischemic contracture of the forearm (Proc.) 805

[illegible] 59
[illegible] 49

WRIST
Scanning and radiology of the carpal scaphoid bone 663

WRIST JOINT
[illegible] dislocation of the trapezium (multangulum *majus*) 85

AUTHOR INDEX

Aalto, K & Österman, K Intra-articular shaving of patellar chondromalacia (Proc.)

Aalto, K, Slätis, P & Karaharju E Resurfacing arthroplasty of the hip *ad modum* Wagner (Proc.)

Aalto, K see *P Slätis*

Aalto K see *V Vahvanen*

Aaro, S & Dahlborn M Estimation of vertebral rotation in structural scoliosis by computerized tomography (CT) (Proc.)

Aaro, S see *J A Sevastikoglou*

Aaro S see *E Spangfort*

Aarstrud O J Non union of fractures of the humerus (Proc.)

Aarstrud O J Spinal stenosis (Proc.)

Ahl, T see *R Kalén*

Ahlberg, A & Pettersson H Synoviorthesis with radioactive gold in hemophiliacs. Clinical and radiological follow up

Ahnfelt, L., Andersson, G B J & Herberts, P Reoperation of total hip replacements in Sweden during the period 1/1/1976–31/8/1977 (Proc.)

Aho, A J see *H Aro*

Aherman M see *A Rydholm*

[illegible]

fractures in benign bone tumours and tumour like conditions in children (Proc.)

Alho, A Raugstad T S & Hvidsten, K. Growth remodelling of femoral shaft fractures (Proc.)

Alho, A see *I Bjørbaek*

Alho, A see *F V S Voskinen*

Alho, A see *A Walster*

Alho, A see *T S Raugstad*

Alho, A see *O Søreide*

Almby, B, Hjelmstedt A & Lonnerholm, T Neonatal hip instability Reason for failure of early abduction treatment

Althoff, D see *I F Goldie*

Andersen, A see *H Hansen*

Andersen J L Diagnosis and treatment of infected knee arthroplasties (Proc.)

Andersen, L J & Hvid, I Bilateral hallux valgus figure of a case

353 *Andersen, L L* see *I Hvid*

Andersen, G B J Gauthier A, Galetti J & Rutsher W Fibre metal prostheses in segmental replacement of

348 long bone in baboons and human

73 (Proc.)

791 *Andersen G B J & Herberts P* ICLH arthroplasty of the knee joint results and complications (Proc.)

Andersen G B J Ortengren R & Henriksson B The importance of

111 rotational deformities in the development

112 of angle deformities after fracture (Proc.)

111 *Andersen G B J* see *L Ahnfelt*

342 *Andersen G B J* see *C Zetterberg*

342 *Andersen G B J* see *C Zetterberg*

117 *Andersen, S W & Chow B E* Po[illegible] traumatic bone segmental loss in the shaft fracture treated with a weight

513 bearing brace

Andresen, J R see *I M Jørgensen*

Aparisi, T Electron microscopic histochemical and biochemical studies

112 osteosarcoma (Proc.)

601 *Arnonsson, S* see *L L Hansson*

120 *Aro, H, Penttinen, R & Aho A* Electrical stimulation of fracture [illegible]

603 cells *in vitro* (Proc.)

Arstila A see *S Sotaniemi*

Auld, C D & Chow R B Fr[illegible] osteochondritis dissecans and [illegible]

366 tunnel syndrome

Axer, A see *D H Gerber*

358 *Bang G* see *E Sudmann*

805 *Barfred, T & Plas J*

129 reimplantations (Proc.)

806 *Barfod, B & Boe S* Results [illegible]

807 treatment of cruciate [illegible]

806 follow-up study (Proc.)

Barquet A Traumatic hip [illegible] childhood A report of 26 [illegible]

315 review of the literature

364 *Bauer, G, Knutsson, K & Lin[illegible]*

353 Prospective multicenter stu[illegible] arthroplasties (Proc.)

352 *Bauer, G, Knutsson K & Lin[illegible]*

Prospective multicenter study of knee arthroplasties (Proc) 350
Bak E I see *H Wie* 629
Berum P , Ertresvag, K & Høiseth, K Torsion deformities after traction treatment of femoral fractures in children 87
Berg P see *A Wigren* 350
Berglund, B & Bergstrom, K Serum enzymes after hip joint surgery 671
Bergquist Ullman, M , Larston, U & Nachemson, A Acute low back pain in industry a controlled prospective study with special reference to therapy (Proc) 111
Bergstrom, K see *B Berglund* 671
Berntsen, E see *V Damholt* 353
Bertheussen, K & Kramhøft, J Supracondylar fractures of the humerus in children (Proc) 355
Bjerkholt, H see *R Hagen* 343
Bjerkreim, I see *O Valle* 804
Bjerbaek T , Malster, A , Johnson, G E & Alho, A Fractures in the lower leg with severe soft tissue complications (Proc) 805
Blomgren, G & Lindgren, U Hematogenous infection after arthroplasty an experimental study in the rabbit (Proc) 114
Blom Hagen, T Gas gangrene (Proc) 343
Boe, S Dislocation of the trapezium (Multangulum majus) A case report 113
Boe, S The neurovascular island pedicle flap 67
Boe, S & Lucht, U Brachymesophalangy and loose bodies in the metacarpophalangeal joints 755
Boe, S see *B Barfod* 103
Bohr, H Letter to the Editor 127
Bohr, H On the skeletal age in coxa plana (Proc) 106
Bojsen Møller, F & Lamoreux, L Significance of free dorsiflexion of the toes in walking 471
Bonsdorff, H v see *E B Riska* 362
Boquist, L see *S E Larsson* 481
Brattström, H Fractures in patients with rheumatoid arthritis (Proc.) 364
Bremerskov, V see *H Svend Hansen* 237
Brewer, B J see *M P Murray* 563
Broström, L -A Endocrinological aspects in osteosarcoma (Proc.) 118
Broström, L.-A Interferon as adjuvant therapy in osteosarcoma – 3 year follow-up study (Proc) 118
Brummer H see *K A Solonen* 604
Buring, K see *A Hjelmstedt* 354
Bylander, B see *L I Hansson* 356
Cappelen-Smith, J see *I F Goldie* 351
Carlsson, A Diagnosis of deep infections following total hip replacement (Proc) 352
Carlsson, A see *G Josefsson* 352
Carlsson, A , Nilsson, B E & Westlin, N E Bone mass in primary coxarthrosis 187
Carlsson, A S & Gentz, C -F [illegible] 346
Carlsson, C A see *I F Goldie* 364
Ceder, L , Ekelund, L , Inerot, S , Lindberg, L., Odberg, E & Sjolin, C Rehabilitation after hip fracture in the elderly 681
Chesney, R B see *C D Auld* 727
Choler, U see *U Larsson* 109
Christensen N O Lateral release in the treatment of dislocation of the patella and other disorders of the knee (Proc) 106
Christensen, S B Radionuclide uptake of ^{99m}Tc-phosphate compounds in human osteoarthritic femoral heads illustrated by autoradiography impulse counting, and comparative histological-histochemical studies (Proc) 104
Collert, S & Gillstrom P Osteotomy in osteoarthritis of the hip A prospective study 555
Colville, J & Rauntio, P Total hip replacement in juvenile rheumatoid arthritis Analysis of 59 hips 197
Cooperman, D R , Spiegel, P G & Laros, G S Triplane epiphyseal ankle fractures (Proc) 117
Dahl, H K & Lie, M Reoperations of infected total hip prostheses (Proc.) 806
Dahlborn, M see *S Aaro* 111
Dahlborn, M see *J A Sevastikoglou* 112
Damholt, V Classification and treatment of osteitis (Proc) 107
Damholt, V see *H Hansen* 699
Damholt, V see *N B Termansen* 705
Damholt, V & Berntsen, E Arthroscopy of the knee joint using the Dyonics needlescope (Proc) 353
Danckwardt Lilliestrom G see *U Lindyö* 116
Danckwardt Lilliestrom, G see *U Lindyo* 797
Davis, P R see *S Kumar* 507
Dekel, S see *G R Houghton* 635
[illegible] *P Kendall* 721
[illegible] 717
Dolk T , Jamet, U & Mattsson, H S Neurological examination in supracondylar fractures of the humerus (Proc.) 355

Dovey, H see *P Holstein* 59
Dyreborg, E, Jørgensen, J, Krogh P, Petersen, E K, Rohr, R & Schlanbusch, C Postoperative complications after 605 Charnley total hip replacements (Proc) 347
Edsberg, B, Rubinstein, E & Reimers, J Containment of the femoral head in Legg-Calvé-Perthes' disease and its prognostic significance 191
Edsberg, B see *J Reimers* 106
Egkher, E see *H Martinek* 675
Ekeland, A & Gautvik, K M Secretion of calcitonin in relation to trauma (Proc) 358
Ekelund, L see *L Ceder* 681
Elbrønd, O see *H E Nielsen* 639
Elmstedt, E see *J A Sevastikoglou* 112
Elves, M W see *M Walton* 501
Engesaeter, L B & Skar, A G Effects of cloxacillin doxycycline, fusidic acid and lincomycin on the mechanical properties of bone and skin in young rats 245
Engesaeter, L. B see *H Wie* 629
Eriksen, J, Tøndevold, E, Jansen E & Petersen J E Relationship between oxygen and carbon dioxide tensions and acid base balance in arterial blood and in medullary blood from long bones in dogs 519
Eriksen, J see *E Tøndevold* 365
Eriksen, J see *E Tøndevold* 527
Eriksen, J see *E Tøndevold* 645
Eriksson K see *P Netz* 115
Eriksson, K see *P Netz* 139
Erin Madsen J & Nielsen, E K Operative or conservative treatment of lesions of the lateral ligaments of the ankle (Proc.) 104
onen, I see *T Videman* 465
rsmark, H see *R Kalén* 116
Ertresvag, K see *P Benum* 87
Essen, C v see *I F Goldie* 364
Evaldsen, J see *P Ottsen* 356
Farine, I see *C Tauber* 385
Fedders, O Femoral shaft fractures treated with closed intramedullary nailing (Proc.) 104
Fitton, J M see *R J Newman* 709
Frandsen, P A Osteosynthesis of displaced fractures of the femoral neck A comparison between Smith-Petersen osteosynthesis and sliding nail plate osteosynthesis – a radiological study 443
Friberg, K S I Remodelling after distal forearm fractures in children I The effect of residual angulation on the spatial orientation of the epiphyseal plates
Friberg, K S I Remodelling after distal forearm fractures in children II The final orientation of the distal and proximal epiphyseal plates of the radius 731
Friberg, K S I Remodelling after distal forearm fractures in children III Correction of residual angulation in fractures of the radius 741
Frigaard, E see *C Kromann Andersen* 347
Friman, C see *T Videman* 465
Gabor, I & Reikerds O Nine years' experience with total hip replacement with special regard to loosening and infection (Proc) 346
Gabor, I see *J Johansen* 807
Gaechter, A see *G B J Andersson* 364
Galante, J see *G B J Andersson* 364
Galatius, H see *S Rosendahl* 347
Gardner, G M see *M P Murray* 563
Gassner, S see *C Tauber* 385
Gautvik K M see *A Ekeland* 358
Gentz, C F see *A S Carlsson* 346
Gershuni, D H, Axer A & Siegel B Localized regressive articular cartilage changes in the hip joint of the rabbit 179
329
555
362
pelvic fractures (Proc.)
Goldie, I, F, Althoff, B, Carlsson C A & Essen, C v Posterior fusion in instability of the cervical column in rheumatoid arthritis and fractures (Proc.) 364
Goldie I, Johansson C, Irstam, L. & Roos, O Preliminary results of a trunnion bearing prosthesis (Christiansen) in total hip replacement (Proc) 113
Goldie I F & Raner, C Total hip replacement with a trunnion bearing prosthesis Biomechanical principles and preliminary clinical results 205
Goldie, I F, Raner, C & Cappelen Smith, J Correlation between position of duocondylar prosthesis and function of the knee joint (Proc) 351
563
Gore, D R see *M P Murray* 120
Graffman, S see *A Wigren*
Greiff, J Necrosis of the femoral head of 8 years duration without radiological collapse (Proc) 106
667
Greiff M see *Y Levy* 604
Grohn, P see *S Santavirta*
Grønmark, T Operative treatment of tennis elbow (Proc.) 344
Haerum, O Arthroscopy of the knee joint (Proc.) 353
Hagen, R Diagnosis and treatment of giant-cell tumour of bone (Proc.) 804
Hagen, R 274 total hip replacements with

Christiansen's trunnion bearing prosthesis. Complications and social aspects (Proc) 346
gen, R. Pathological fractures following kidney transplantation (Proc) 367
gen, R & Bjerkholt, H Paget's disease of bone treated with calcitonin (Proc.) 343
gen R see *L. F Solheim* 805
kkinen S see *O Kiviluoto* 124
kkinen, S see *E B Riska* 362
ld, J K & Sudmann, E Early diagnosis of acute hematogenous osteomyelitis by computed tomography (Proc.) 808
ld J K see *E Sudmann* 808
nnukiela, M see *T Silvennoinen* 348
nsen, H & Andersen, A Supracondylar fractures of the humerus (Proc.) 355
nsen, H, Damholt, V & Termansen, N B Clinical and social status following injury to the lateral ligaments of the ankle Follow-up of 144 patients treated conservatively 699
nsen, H H see *T M Jørgensen* 663
nsen, H see *N B Termansen* 705
nsen, H H see *H E Nielsen* 639
nsen Leth, C Bone vascularization and bone healing in the amputation stump An experimental study
nsen Leth, C The vascularization in the amputation stumps of rabbits. A microangiographic study
nsson, J, Nachemson, A & Välljfors Low back pain – sick-leave and working environment (Proc)
nsson, L. I, Arnonsson, S, Bylander, B & Selvik, G Diagnosis of traumatic growth disturbance with rontgen stereophotogrammetry (Proc) 39
nsson, L I & Norman, O Rotational deformity after femur fracture in children – a 10-year follow up study (Proc) 363
nsson, L. I, Ordeberg, G, Stenstrom, A & Thorngren, K.-G Caput fixed sliding nail for treating epiphysiolysis capitis femoris (Proc.) 251
nsson, L. I see *K -G Thorngren*
raldsson, S Spontaneous fractures in the hip and shoulder joints (Proc.) 356
rkönen, M, Keski Nisula, L., Lepistö, P, Paakkala, T, Patsala H & Rokkanen, P Fractures of the thoracic spine (Proc.) 354
rkonen M, Keski Nisula, L Lepisto P, Paakkala T, Patsala, H & Rokkanen, P Fractures of the cervical spine (Proc) 358
rkönen, M, Lepisto P, Keski Nisula, L, Paakkala, T, Pätiälä, H & Rokkanen, P Fractures of the thoracic thoracolumbar (Th_{12}–L_1) spine (Proc) 367
Harkönen, M see *P Lepisto* 602
Haukaas, S see *T S Raugstad* 807
[illegible] 15
[illegible] by the Watson-Jones method 337
[illegible] 604
[illegible] *S* 787
[illegible] in 343
Hellum, C see *A Reigstad* 805
Hemmingsson, A see *U Lindsjö* 116
Hemmingsson, A see *U Lindsjo* 797
Henriksson, B see *G B J Andersson* 354
Herberts, P & Magnusson A An [illegible] 114
[illegible] 112
[illegible] 351
[illegible] 359
Hierton, T, Rolstad, [illegible] Sahlstedt, B Adamantinoma tibiae 97
Hierton T, Wigren, A & Marsh, L. Orthopaedic rehabilitation after open femoral fracture and arterial injury (Proc) 359
Hierton, T see *H Holmsen* 33
Hirayama, T see *T Sekiguchi* 391
Hjelmstedt, Å & Ljunghall, S A case of Albright's syndrome treated with calcitonin 251
Hjelmstedt, Å, Sahlstedt, B & Buring, K Aspects of anatomy and treatment of vertical talus (congenital convex pes valgus) (Proc.) 354
Hjelmstedt, Å see *B Almby* 315
Hockerstedt, K see *S Santavirta* 123
Højlund, A P & Riegels Nielsen, P Fractures of the phalanges of the hand (Proc) 105
Høiseth K see *P Benum* 87
Holmsen, H, Ljunghall S & Hierton, T Myositis ossificans progressiva Clinical and metabolical observations in a case treated with diphosphonate (EHDP) and surgical removal of ectopic bone 33
Holstein, P, Dovey, H & Lassen, N A Wound healing in above-knee amputations in relation to skin perfusion pressure 125
Holstein, P, Sager, P & Lassen, N A Wound healing in below-knee amputations in relation to skin perfusion 363

Paavilainen, T see *E B Riska* 362
Paavolainen, P, Slätis, P, Karaharju, E & Holmström, T The healing of experimental fractures by compression osteosynthesis. I Torsional strength
Paavolainen, P, Penttinen R., Slatis, P & Karaharju, E The healing of experimental fractures by compression osteosynthesis. II Morphometric and chemical analysis
Paavolainen, P see *T Holmström*
Padmanabhan, R see *S Singh*
Pahle, J A Total replacement of the shoulder joint in rheumatoid arthritis (Proc.) 151
Panjabi, M M, White, A A & Wolf, J W A biomechanical comparison of the effects of constant and cyclic compression on fracture healing in rabbit long bones
Pankovich, A M & Shivaram, M S Anatomical basis of variability in injuries of the medial malleolus and the deltoid ligament. I Anatomical studies
Pankovich, A M & Shivaram, M S Anatomical basis of variability in injuries of the medial malleolus and the deltoid ligament. II Clinical studies
Pasila M see *H Jaroma* 124
Pasila, M see *J L. Michelsson* 603
Pätiälä H, Vaahto K, Lehto, K & Rokkanen P Brunswick arthroplasty of the hip joint operative technique, early complications and results (Proc.) 602
atiäla, H Histoquantitative analysis of bone tissue (Proc.) 123
" ialä H see *M Harkönen* 125
ätiälo, H see *M Harkönen* 363
Patiala, H see *P Lepistö* 602
Patiäla, H see *T Tunturi* 415
Pätiala, H see *T Tunturi* 427
Paul, B see *L. F Solheim* 804
Pedersen, J E see *E Jansen* 103
Pedersen, J E see *E Jansen* 365
Pedersen U see *H E Nielsen* 639
Pedersen, V M The value of routine X-ray examination of the cervical spine in cases of acute trauma to the head and neck (Proc.) 105
Penttinen, R see *H Aro* 601
Penttinen, R see *P Paavolainen* 375
Persson, B M Standardized temporary prosthesis with total contact socket for below-knee amputees (Proc.) 359
Persson, B M & Rydholm, A Further experiences with acrylic cementation of giant cell tumours of bone (Proc.) 119
Persson B M see *A Rydholm* 120
Persson, B M see *A Rydholm* 366
Petersen, E K see *E Dyreborg* 347
Petersén, I, Sahlstrand, T & Selldén U Electroencephalographic investigation of patients with adolescent idiopathic scoliosis 283
Petersen J E see *J Eriksen* 519
Petruson, B see *T Sahlstrand* 275
Petruson, B see *T Sahlstrand* 759
Petruson B see *T Sahlstrand* 771
Petterson, H see *Å Ahlberg* 513
Pickles, B see *S Kumar* 507
Pintér, J, Lénárt, G & Rischák G Physical and chemical investigation of free bodies in articular osteochondromatosis 807
Pless, J see *T Barfred* 533
Poussa M & Laurent, L.-E Experience with the treatment of Perthes' disease (Proc.) 366
Poussa, M & Ritsila V The osteogenic capacity of free periosteal and osteoperiosteal grafts A comparative study in growing rabbits 653
Poussa, M see *V Ritsila* 121
Ramsing, P & Jensen, I T The treatment of per- and subtrochanteric fractures *ad modum* Ender (Proc.) 225
Raner, C see *I F Goldie* 491
Raner, C see *I F Goldie* 360
Rasmussen, O see *J H Kjaer* 104
Raugstad, T S, Alho A, Molster A. Haukaas, S & Heidsten K Traumatic dislocation of the patella (Proc.) 205
Raugstad, T S see *A Alho* 351
Raugstad T S see *A Alho* 360
Raugstad, T S see *O Sørede* 807
Raunio, P see *J Colville* 358
Rauschning, W & Lindgren P G Popliteal cysts (Baker's cysts) in adults. I Clinical roentgenological results of operative excision 366
Rechnagel, K Primary complications after Marmor resurfacing arthroplasty (Proc.) 805
Reigstad, A Christiansen endoprosthesis in osteoarthritis of the hip (Proc.) 197
Reigstad, A & Hellum C Volkmann's ischemic contracture of the forearm (Proc.) 583
Reikerås, O Infection after total knee replacement (Proc.) 351
Reikerås O Joint debridement for osteoarthritis of the knee (Proc.) 344
Reikerås, O Reconstruction of lateral ligaments of the ankle (Proc.) 806
Reikerås, O see *I Gabor* 345
Reikerås, O & Rugtvest, A Deep infection

after total hip replacement (Proc.) 345
Reiman, I A histochemical study of alkaline and acid phosphatase activity in subchondral bone from osteoarthritic human hips (Proc)
Reimers, J , Edsberg, B & Rubinstein, B Migration of the femoral head in Legg-Calvé-Perthes' disease and its sign fcance for the [illegible]
[illegible]
[illegible] *timen,*
[illegible] *&*
[illegible] *n of*
[illegible] *timen,*
[illegible] *&*
[illegible] *ol of*
massive hemorrhages in comminuted pelvic fractures (Proc)
Riska E B & Michelsson, J -E Treatment of para articular ossification after total hip replacement by excision and use of free fat transplants
Riska E B see *K Saikku*
Ritsila V , Poussa, M & Laurent, L -E Osteogenic activity of free periosteal and osteoperiosteal grafts and their use in the treatment of infected pseudarthroses of long bones (Proc)
Ritsila, V see *M Poussa*
Roaas, A & Nilsson, S Football injuries in children and youths (Proc)
Rohr, R see *E Dyreborg*
Rokkanen, P see *M Harkonen*
Rokkanen, P see *M Harkonen*
Rokkanen P see *P Lepisto*
Rokkanen, P see *H Patiala*
Rokkanen P see *T Tunturi*
Rokkanen, P see *T Tunturi*
Rokkanen, P see *T Tunturi*
Rønningen, H & Langeland N Indomethacin treatment in osteoarthritis of the hip joint Does the treatment interfere with the natural course of the disease?
Rosendahl, S & Galatius, H The primary complications of total hip replacement (Proc.)
Rosenheck, S see *Y Levy*
Roslund, J see *U Nilsson*
Ross, O see *I Goldie*
Rottoker, W see *G B J Andersson*
Rubinstein E see *B Edsberg*
Rubinstein, B see *J Reimers*
Rugtveit, A Reconstruction of the thumb (Proc) 344
Rugtveit, A see *O Reikerås* 345
Rulnjević, J see *I Jajić* 547
Rydholm, A , Idvall, I , Per on B M & Åkerman M Fine needle aspirat on cytology in the diagnosis of tumours of soft tissue (Proc) 20
Rydholm, A & Persson B M Certain and orthopaedic oncology – tumour suspected what was the final diagnosis? (Proc) 366
Rydholm, A see *B M Persson* 119
Ryöppy, S Injuries of epiphyseal plates. Anatomy pathophysiology and classification of injuries (Proc) 357
Ryöppy, S Mechanisms in spontaneous correction of angular deformities following fractures in children (Proc) 357
Sadr B & Swann M Spontaneous dislocation of the sterno-clavicular joint 769
Sager, P see *P Holstein* 79
Sahlstedt, B see *T Hierton* 97
Sahlstedt, B see *A Hjelmstedt* 354
Sahlstedt B see *U Lindsjo* 116
Sahlstedt, B see *U Lindsjo* 797
Sahlstedt, B see *A Wigren* 120
Sahlstrand, T Hoffman instrumentation in the treatment of unstable pelvic ring injury A case report (Proc.) 116
Sahlstrand, T & Petruson B A study of labyrinthine function in patients with adolescent idiopathic scoliosis. I An electro-nystagmographic study 759
Sahlstrand T & Petruson B Postural effects on nystagmus response during caloric labyrinthine stimulation in patients with adolescent idiopathic scoliosis. II An electro-nystagmographic study 771
Sahlstrand T Petruson B & Örtengren R Vestibulospinal reflex activity in patients with adolescent idiopathic scoliosis. Postural effects during caloric labyrinthine stimulation recorded by stabilometry 275
Sahlstrand, T see *I Petersén* 283
Saikku K Laasonen E & Riska, E B Rupture of the thoracic aorta due to blunt trauma diagnostic aspects (Proc.) 125
Salenius P see *O Kiviluoto* 603
Salenius P see *E V S Koskinen* 129
Saloranta L see *P Jussila* 125
Sandelin J see *S Santavirta* 604
Santavirta, S , Aritula, A , Höckerstedt, K & Nimikoski, J Experimental tourniquet ischaemia (Proc) 123
Santavirta, S , Gröhn P , Heinonen E , Sandelin J & Sundell B Soft tissue sarcomas. A report of 153

cases (Proc) 604
Santavirta, S see *P Slatis* 361
Santavirta, S see *S Totterman* 605
Schlanbusch, C see *E Dyreborg* 347
Schmidt, H see *I Heid* 104
Sekiguchi T & Hirayama T Assessment of fracture healing by vibration 391
Selldén, U see *I Petersén* 283
Selvik, G see *L I Hansson* 356
Sepic, S B see *M P Murray* 563
Sevastikoglou, J A, Dahlborn, M, Elmstedt E, Aaro, S & Levander, R Scintigraphic and thermographic studies of the thorax in idiopathic thoracic scoliosis (Proc.) 112
Sevastikoglou, J see *E Spangfort* 111
Sezai, Y see *K Suzuki* 27
Shitama, K Calcification of aging articular cartilage in man 613
Shivaram, M S see *A M Pankovich* 217
Shneerson, J M & Madgwick, R The effect of physical training on exercise ability in adolescent idiopathic scoliosis 303
Siegel B see *D H Gerthuni* 179
Siewers P see *A Lager* 341
Sigurdsson, F, Lâftman, P & Strömberg L Diaphyseal bone strength adaptation to rigid internal plate fixation an experimental study on rabbits (Proc.) 115
Silvennoinen, T, Karaharju, E, Slätis, P & Hannuksela, M Value of epicutaneous tests for allergy to metals in implantation surgery (Proc.)
Singh, S & Padmanabhan R Effect of chlorpromazine on skeletogenesis. The result of materal administration of the drug in experimental rats 151
Sjolin, C see *L Ceder* 681
Skar, A G see *L B Engesaeter* 245
Slatis, P & Aalto, K Medial dislocation of the tendon of the long head of the biceps brachii
Slatis, P, Kiviluoto, O, Santavirta S & Laasonen E Fractures of the calcaneum (Proc.) 73
Slatis P see *K. Aalto* 348
Slatis, P see *T Holmström* 364
Slatis, P see *P Paavolainen* 369
Slatis, P see *P Paavolainen* 375
Slatis, P see *T Silvennoinen* 348
Slungaard, U Pulmonary embolism after osteosynthesis on the upper extremity (Proc.) 804
Slungaard, U Supracondylar femoral fractures in old patients (Proc) 343
Solheim, L. F, Litterud, K, Paus B & Støen, E Chronic recurrent multifocal osteomyelitis (Proc.) 804
Solheim, L F & Hagen R. Compartmental syndrome of the abductor pollicis longus and extensor pollicis brevis muscles (Proc) 805
Solonen, K A, Brummer, H & Telaranta T Toe-to-thumb transfer by microneurovascular anastomosis (Proc.) 604
Solonen, K see *M Vastamäki* 124
Solonen, K A see *M Vastamaki* 604
Søreide, O, Mølster, A & Raugstad, T S Internal fixation or primary prosthetic replacement for treatment of acute femoral neck fractures in the elderly a prospective randomized study (Proc.) 805
Søreide, O, Rietti, D & Alho, A Internal fixation versus primary prosthetic replacement in acute femoral neck fractures. Cost effectiveness analysis (Proc.) 806
Sørensen P H see *J S Jensen* 777
Sørensen, T S & Hougaard K Is early weight bearing permissible after intertrochanteric fracture treated *ad modum* McLaughlin (Proc.) 104
Sørensen T S see *C Kromann Andersen* 347
Sørensen, T S see *K Lund* 348
Spangfort, E, Sevastikoglou J & Aaro S Phalen & Dickson s syndrome – a follow up (Proc.) 111
Spangler, H see *H Martinek* 675
Spiegel, P G see *D R Cooperman* 117
Stenstrom A see *L. I Hansson* 356
Stenstrom, A see *K-G Thorngren* 358
Støen, E see *L F Solheim* 804
Stokes, I A F see *J P Kendall* 721
Storvik, H M Fractures through the retrocondylar fossa of the proximal phalanx of the finger (Proc) 343
Strander, H Human leucocyte interferon (Proc.) 117
Strander, H see *S Ingimarsson* 117
Strömberg, L. see *P Netz* 115
Strömberg, L. see *P Netz* 139
Stromberg, L. see *F Sigurdsson* 115
Stulberg, S D The role of the resurfacing arthroplasty in the treatment of osteoarthrosis of the hip (Proc.) 109
Sudmann, E Cancellous autologous bone grafting in open denuded lower leg fractures (Proc.) 807
Sudmann, E & Bang G Indomethacin-induced inhibition of haversian remodelling in rabbits 621
Sudmann, E Operative treatment of idiopathic neonatal and relapsed clubfoot (Proc.) 805
Sudmann, E Relief of Sudeck s post

l traumatic syndrome by fasciotomy
t (Proc)
Sudmann, E , Sundsfjord, J A , Middelfart, K & Hald, J K The idiopathic sacroiliac syndrome (Proc)
Sudmann, D The painful chronic anterior lower leg syndrome A prospective clinical and experimental study
Sudmann, E Treatment of chronic osteomyelitis by free grafts of cancellous autologous bone tissue A preliminary report
Sundell, B see *S Santavirta* 145
Sudmann, E see *J K Hald* 604
Sundholm, A see *H Jaroma* 808
Sundholm, A see *J-E Michelsson* 124
Sundsfjord J A see *E Sudmann* 603
Suzuki K , Takahashi, S , Iti, K , Tanaka, Y & Sezai, Y Tumoral calcinosis in a patient undergoing dialysis 808
Svend Hansen, H V , Bremerskov, V & Ostri P Fracture-suspending effect of the patellar tendon bearing cast 27
Swann, M see *B Sadr* 27
Takahashi S see *K Suzuki* 237
Tanaka, Y see *K Suzuki* 269
Tauber, C , Farine, I , Horoszowski, H & Gaisner, S Fracture healing in rabbits after osteotomy using the CO_2 laser 27
Teglbjerg P S see *N B Termansen* 27
Tegland, J Total ankle replacement prosthesis in patients with rheumatoid arthritis (Proc) 385
Teranta, T see *K A Solonen* 365
Tesen, T Malignant vertebral tumours with neurological manifestations (Proc.) 807
Termansen, N B , Hansen, H & Damholt, Radiological and muscular status following injury to the lateral ligaments of the ankle Follow up of 144 patients treated conservatively 604
Thansen, N B & Teglbjerg, P S Intraosseous pressure bone density and roentgenological and clinical findings in primary osteoarthritis of the hip joint (Proc) 804
Thansen, N B see *H Hansen* 365
Thomsen, P see *T M Jørgensen* 699
Thorblad, J & Tillberg B McKee-Farrar arthroplasty – successes and failures (Proc) 663
Thorgren, K G , Hansson L I & Lindstrom A Effect of MSH on growth and remodelling of long bones (Proc) 345
Thorgren, K G see *L I Hansson* 358
Thorgren, K G & Werner C O Normal grip strength 356
Tillberg, B see *J Thorblad* 345
Tondevold, E , Eriksen, J & Jansen E Gas tensions and intraosseous pressure in the long bones of the anaesthetized dog (Proc) 255
Tondevold, E , Eriksen, J & Jansen E Observations on long bone medullary pressures in relation to arterial PO_2, PCO_2 and pH in anaesthetized dog 573
Tondevold, E , Eriksen, J & Jansen, E Observations on long bone medullary pressure in relation to mean arterial [illegible] 645
[illegible] 527
[illegible] 519
[illegible] 161
[illegible] 777
Torok, G see *Y Levy* 667
Totterman, S & Santavirta, S Angiography in the diagnostics of malignant soft tissue tumours (Proc) 27
Tryggo, D see *A Jernberger* 605
Tryggö, D see *S S Olsson* 113
Tunturi, T , Leikkonen, O Paakkala, T , Lepistö, P & Rokkanen, P Cloward's anterior fusion in the treatment of traumatic injury and degeneration of the [illegible] (Proc) 457
[illegible] 602
[illegible]
fusion of the lumbosacral spine Evaluation of the operative results and the factors influencing them 807
Tunturi, T , Niemela, P , Laurinkari, J , Patiäla, H & Rokkanen, P Cost-benefit analysis of posterior fusion of the [illegible] 804
[illegible] 415
[illegible] 427
[illegible] 175
[illegible] 705
[illegible] 354
[illegible] 602
[illegible]
(Proc) 365
Vahvanen, V & Aalto, K Meniscectomy in children 699
Valle, O & Bjerkreim, I Spondylolisthesis treated by posterolateral fusion (Proc.) 663
Vallfors, B see *J Hansson* 345
Vastamäki, M & Solonen, K A Entrapment neuropathy of the radial nerve in the forearm (Proc.) 804
Vastamäki, M & Solonen, K Posterior dislocation and posterior fracture-dislocation of the shoulder (Proc.) 363
604
124

Acta

Scandinavica

ITOR: KNUD JANSEN, Copenhagen, Denmark



UNKSGAARD, Copenhagen

Vol 50, No 6, Part 2, December 1979

ACTA ORTHOPAEDICA SCANDINAVICA

is the official publication of the Scandinavian Orthopaedic Association

Acta Orthopaedica Scandinavica publishes original papers on orthopaedic surgery including traumatology Authors are also invited to publish follow-up notes and comments. Papers previously published in other periodicals are not accepted

EDITOR *Knud Jansen*, Dept of Orthopaedic Surgery, Gentofte Hospital, DK-2900 Hellerup.
ASSOCIATE EDITOR *Poul S Rasmussen*, Copenhagen, Denmark.

EDITORIAL BOARD

Stefan Haraldsson, Reykjavik, Iceland
M Foss Hauge, (chairman), Oslo, Norway
Tor Hierton, Uppsala, Sweden
Knud Jansen, Hellerup, Denmark
Erik B Riska, Helsinki Finland
K Harry Sørensen, Odense, Denmark

DEPUTIES

Goran Bauer, Lund, Sweden
Hans K Dahl, Oslo, Norway
Bragi Gudmundsson, Reykjavik, Iceland
L E Laurent, Helsinki, Finland
Søren Pilgaard, Aarhus, Denmark

Editorial Correspondence Manuscripts should be addressed to the Editor No part of this journal may be reproduced by any process without written permission from the author(s) and the editor

Business communications, including subscriptions and orders for offprints or advertisements, should be sent to the publishers *Munksgaard*, International Booksellers and Publishers Ltd., 35 Norre Sogade DK-1370 Copenhagen K, Denmark

Acta Orthopaedica Scandinavica is published bimonthly The subscription price per volume of six issues is at present Danish kroner 260 00 plus postage D kr 40 00 (US $60 00, £30 00, DM111 00) payable in advance. Prices are subject to exchange rate fluctuation

© 1979 Munksgaard International Publishers Ltd The appearance of the fee codes in this journal indicates the copyright owner's consent that copies of articles may be made for personal or internal use, or for the use of specific clients. This consent is given on the condition, however, that the copier pay the [illegible] New York [illegible] other

INSTRUCTIONS TO CONTRIBUTORS

It is expected that any manuscript submitted represents unpublished original work that is not being considered for publication elsewhere

The paper should be written in English. The title, which is not to exceed 12 words should be chosen with great care Most of the indexing and abstracting services depend on the accuracy of titles. The manuscript must be typewritten on one side of the paper only (quarto), with wide margins and be double spaced The first page should contain, on separate lines, the title of the article and the authors' names and institutions. If the title is longer than 45 letters and spaces, a short title, containing the essence of the article and not exceeding this limit, will be required for use in the running head The last page should include the full postal address of the author to whom communications and proofs are to be sent and from whom reprints are to be requested.

The manuscript including tables and figures should if possible, be sent in duplicate to facilitate rapid refereeing, and the author should retain a further copy for his own use No roman numerals should be used in the text. In decimal fractions a full stop and not a comma, must be used The % sign should be replaced in the text by "per cent" The minus sign should be shown as –

All papers will be read and corrected for language by the editorial office Manuscripts produced in poor English will be returned for revision.

Articles should not exceed 16 printed pages. Additional pages must be paid for by the authors at a rate of 400 Danish kroner per page Articles of more than 20 pages are not accepted.

Papers should normally be divided into the following sections

Abstract The purposes of the abstract are to convenience the readers of the journal and to expedite the work of the abstracting journals. The opening sentence

(Cont cover page 3)

Second-class postage paid at Jamaica, N Y Airfreight and mailing in the U.S by Publications Expediting Inc., Elmont, N Y 11003 Printed in Great Britain by The Whitefriars Press Ltd, London and Tonbridge.